

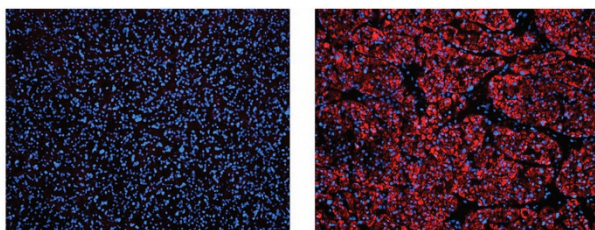
## INSIDE THE USCAP JOURNALS

doi:10.1038/labinvest.2015.122

### MODERN PATHOLOGY

#### Mitochondrial DNA mutations distinguish rare renal tumors

See page 1458

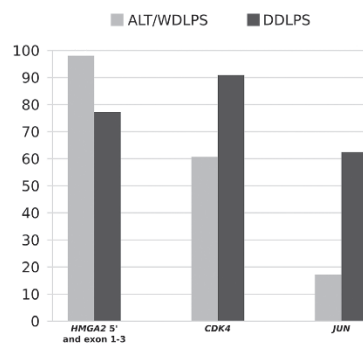


Sporadic renal oncocytomas, which are usually benign, are characterized by conspicuous accumulation of defective mitochondria resulting from deleterious mitochondrial DNA (mtDNA) that imparts their characteristic cytoplasmic features. Some heritable syndromes that are driven by germline somatic mutations, such as Birt–Hogg–Dubé (BHD), are known to be associated with oncocytomas, but Lang *et al* explored whether mitochondrial DNA mutations also have a role. By sequencing the entire mitochondrial genome of 25 samples from patients with multiple oncocytomas (but not BHD), they determined that this cohort is universally associated with detrimental mitochondrial DNA mutations that impair the assembly and function of the NADH–ubiquinone oxidoreductase complex. BHD-associated oncocytomas lack these mitochondrial DNA mutations, as do some non-oncocytic renal tumors. This segregation of mitochondrial DNA mutations helps refine our understanding of renal tumor pathogenesis and may also have diagnostic value in certain settings.

#### HMGA2, CDK4, and JUN amplifications in liposarcoma

See page 1404

The well-differentiated/dedifferentiated liposarcoma tumor spectrum has conspicuous amplifications and deletions that dominate their genomic landscape. Amplifications are especially prominent and punctuated in the 12q13–15 chromosomal interval, where the *MDM2* driver gene encoding a TP53 inhibitor is universally amplified. Saâda-Bouid *et al* specifically examined *HMGA2*, *CDK4* (both in the 12q13–15 interval but not always amplified, unlike *MDM2*), and *JUN* (1p32) amplifications in a large series of 48 well-differentiated and 68 dedifferentiated tumors. In summary, although several significant associations with various clinicopathologic features and outcomes were identified via amplification of the three genes, *HMGA2* amplification

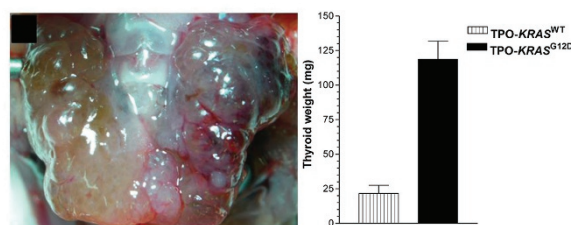


was associated with good differentiation and outcome whereas amplification of *CDK4* and *JUN* was associated with dedifferentiation and poor outcome. Additional study will refine the roles of *JUN* and *CDK4* in dedifferentiation; prospective assessment of these loci could be predictive of dedifferentiation, a major driver of liposarcoma outcome.

### LABORATORY INVESTIGATION

#### Oncogenic transformation of thyroid follicular cells

See page 1269



*KRAS<sup>G12D</sup>* is sufficient to cause malignant transformation in the lung but not in the thyroid. The other factors necessary to induce thyroid carcinoma have not been clearly defined. To explore possible cofactors, Zou *et al* used a *KRAS<sup>G12D</sup>* knockin mouse model that expresses the mutated oncogene only in the thyroid at physiologic levels under the control of its endogenous promoter. They used propylthiouracil to block thyroid function and induce compensatory thyroid-stimulating hormone (TSH) production. The *KRAS<sup>G12D</sup>* mice developed thyroid hyperplasia with maintenance of follicular architecture, and a subset developed follicular carcinoma over the following year. The *KRAS<sup>WT</sup>* mice developed papillary hyperplasia only, with no carcinoma. Expression of *SPRY1*, a downregulator of receptor tyrosine kinase signaling, was increased in the *KRAS<sup>G12D</sup>* mice and shunted TSH-RAS signaling through the PI3K/AKT pathway. This contrasts



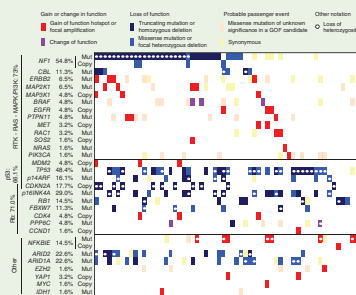
## nature.com/pathology

### Genomic landscape of desmoplastic melanoma

There have been reports on the genomic landscape of standard cutaneous melanoma, but Shain *et al*, as reported in *Nature Genetics*, have now characterized desmoplastic melanoma specifically. Genome and exome sequencing studies reveal an excessively high mutational burden (median: 62 mutations/megabase)

that places it among the most highly mutated types of cancer. Consistent with the clinical setting of desmoplastic melanoma on severely sun-damaged skin, there is a strong ultraviolet radiation mutation signature. Activating mutations in common ERK pathway activators in conventional cutaneous melanoma, such as *NRAS* and *BRAF*, were not seen, although inactivation of *NF1*, encoding a RAS GTPase-activating protein, was observed. A variety of genetic alternations known to activate the ERK and/or PI3K pathway was seen in about 75% of cases. As in conventional cutaneous melanoma, activation of these two pathways remains paramount, albeit by alternative events. A novel finding was recurrent promoter mutations in *NFKBIE*, encoding nuclear factor (NF)- $\kappa$ B inhibitor  $\epsilon$ , suggesting a role for inhibition of NF- $\kappa$ B signaling.

*Nature Genetics* 2015;47:1194–1199; doi:10.1038/ng.3382




### In situ single-cell analysis of breast cancer

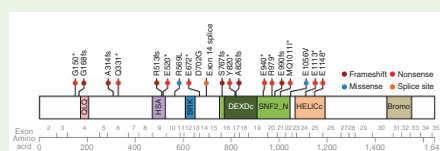
Both *HER2* amplification and activating *PIK3CA* mutations are common in breast cancer. Increased activity in the PI3K-AKT pathway is an important factor in resistance to trastuzumab therapy. In an article in *Nature Genetics*, Janiszewska *et al* describe a novel method called specific-to-allele PCR-FISH (STAR-FISH) that can detect targeted single-nucleotide and copy-number alterations

in single-cell nuclei using intact formalin-fixed paraffin-embedded tissue sections. Applying this powerful technology to clinical breast cancer specimens, the authors discovered that these two events are not always in the same cell nuclei and that standard chemotherapy selects for *PIK3CA* mutations that are usually minor subpopulations in untreated specimens. The spatial distribution of genetic diversity in tumor nuclei seems to be selected by chemotherapy, and certain patterns correlate with a poor outcome following adjuvant trastuzumab therapy. A fascinating implication is that prior standard chemotherapy may promote resistance to subsequent HER2-targeted therapy.

*Nature Genetics* 2015;47:1212–1219; doi:10.1038/ng.3391



### A novel thoracic sarcoma with SMARCA4 inactivation



In a study reported in *Nature Genetics*, Le Loarer *et al* used RNA transcript sequencing to investigate a cohort of unclassified sarcomas. The authors identified a set of cases with inactivation of *SMARCA4*, an ATPase involved in the

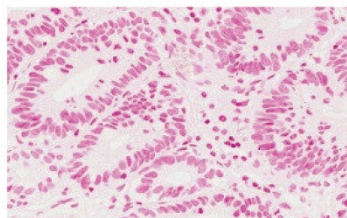
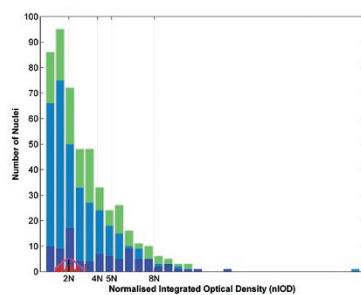
BAF chromatin remodeling complexes. The cases presented as compressive mediastino-pulmonary masses in young adults, with very poor survival. Their gene expression profiles were compared with those for small-cell carcinomas of the ovary, hypercalcemic-type (*SMARCA4*-mutated); malignant rhabdoid tumors (with *SMARCB1* inactivation); and lung carcinomas (of which ~10% have *SMARCA4* mutations). The novel thoracic sarcomas were related to the ovarian and rhabdoid tumors, but not the lung carcinomas. Further analysis demonstrated that increased expression of *SOX2* was consistent, and immunohistochemistry showed that *SOX2* nuclear expression and loss of nuclear *SMARCA4* were characteristic. Thus these newly defined “*SMARCA4*-deficient thoracic sarcomas” have potential markers for differential diagnosis in the clinical setting as well.

*Nature Genetics* 2015;47:1200–1205; doi:10.1038/ng.3399

with *BRAF*<sup>V600E</sup> papillary thyroid carcinoma, in which *SPRY1* expression is reduced to activate the PI3K/AKT and ERK pathways simultaneously.

## Whole-slide image cytometry in Barrett's esophagus

See page 1319



Barrett's esophagus is an important precursor of esophageal adenocarcinoma. Both low- and high-grade dysplasia in Barrett's esophagus are known to confer this increased risk, but interpretation and grading of dysplasia are subjective and poorly reproducible. Wang *et al* applied whole-slide imaging and DNA image cytometry to a series of 20 Barrett's esophagus cases, including low- and high-grade cases as well as several that were negative for dysplasia. This technique documents abnormal nuclear DNA content in Feulgen-stained sections. The authors found abnormal DNA content in both low- and high-grade dysplasia and determined that the method can be used both for grading and to distinguish dysplasia from nondysplasia cases in a robust and reproducible fashion. The technique is relatively inexpensive and has potential as a diagnostic aid for clinical assessment of Barrett's esophagus as well as for characterization of research materials.

Laboratory Investigation | Volume 95 November 2015

1221

