

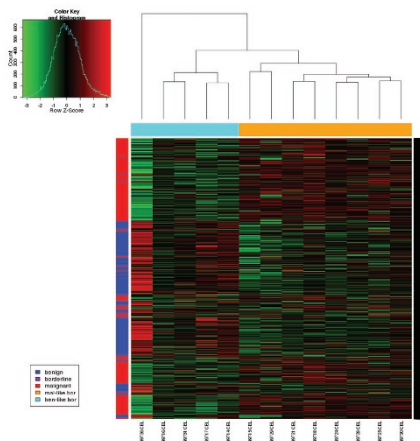
INSIDE THE USCAP JOURNALS

doi:10.1038/labinvest.2014.9

MODERN PATHOLOGY

Not all ovarian borderline tumors are created equal

See page 433

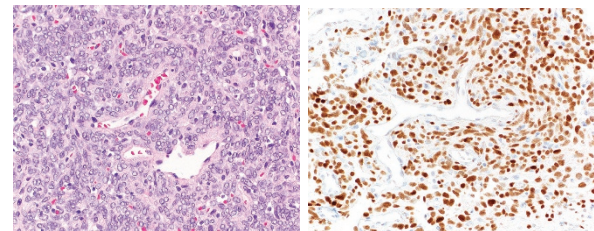


Borderline ovarian tumors present both diagnostic and prognostic challenges. Most do not progress when confined to the ovary, but some are more aggressive. Currently, these bad actors cannot be robustly differentiated from their more indolent counterparts by morphologic or other means. Curry *et al* obtained gene expression profiles from benign serous cystadenomas, low-grade serous carcinomas, and serous borderline ovarian tumors. Their initial, unsupervised clustering revealed a clear distinction between carcinomas and cystadenomas, with the borderline tumors falling into both groups. Further analysis defined two groups of borderline tumors: those more similar to cystadenomas and those more similar to carcinoma at the gene expression level. Cell-adhesion pathways were a major differentiator between groups. More study is needed to determine whether this more malignant signature seen in some of the borderline tumors correlates with more aggressive behavior.

NAB2-STAT6 translocation in solitary fibrous tumor yields diagnostic marker STAT6

See page 390

Solitary fibrous tumor is usually readily recognized by its patternless architecture, conspicuous stromal collagen, and hemangiopericytoma-like or staghorn vessels. Diffuse reactivity with CD34 on immunohistochemistry is characteristic, although it is also seen in many other tumors. Despite these striking characteristics, diagnosis challenges can arise, particularly in small biopsies or when variant

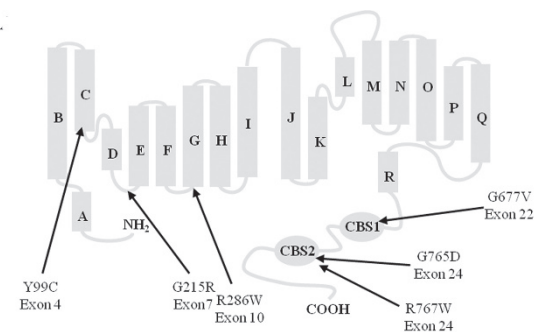


histologic patterns are present. The *NAB2-STAT6* fusion results in accumulation of nuclear STAT6 protein, which can be detected by antibodies against the carboxy terminus of the protein. When Doyle and colleagues examined 60 solitary fibrous tumors, 98% showed strong nuclear expression of STAT6. In an additional 171 mesenchymal tumors, only 4 showed weak nuclear STAT6 expression. We therefore seem to have a new, robust, and much more specific marker for this tumor, although additional studies are needed because it is the natural history of markers to exhibit decreased specificity over time as more cases are studied.

Laboratory Investigation

Study of ADO II improves our understanding of osteoclast function

See page 275

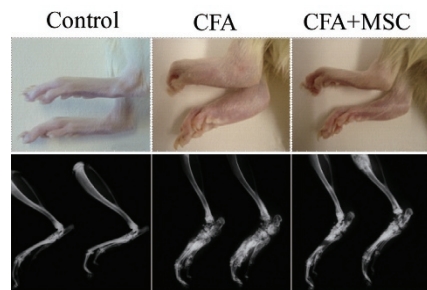


Autosomal dominant osteopetrosis type II (ADO II), also known as Albers-Schönberg disease or “marble bones,” is a rare and heritable bone disorder in which insufficient osteoclast activity results in high bone mass. The disease is associated with mutations in *CLCN7*, a gene that encodes a member of the voltage-gated chloride-channel family that acts as a Cl^-/H^+ exchanger. The responsible mutations, which are usually heterozygous, are believed to result in loss of function, with perhaps a dominant negative mode of action. Mice lacking a functional *CLCN7* gene have osteoclasts that lack a ruffled border and are unable to acidify and resorb bone. Coudert *et al* compared the gene expression profiles of isolated osteoclasts from ADO II

patients with those from normal donors. They discovered changes in expression from multiple genes: *ITGB5* was increased whereas *SERPINE2*, *WARS*, and *PRF1* were decreased. Some of these changes were replicated by overexpression of mutated *CLCN7*. Further study of these pathways should further our understanding of osteoclast biology.

Mesenchymal stem cell infusion can inhibit bone destruction associated with arthritis

See page 286



Using a rat model of adjuvant-induced arthritis, Takano and colleagues observed that administration of mesenchymal stem cells (MSCs) can alleviate the bone destruction associated with this condition. MSCs are best known for their multipotency and ability to differentiate along multiple cell lineages, but they also display anti-inflammatory and immunomodulatory effects and thus have regulatory functions as well. Because arthritis is often mediated by inflammatory destruction of bone and joints, the investigators studied the ability of MSCs to ameliorate these processes. MSCs were recruited by proinflammatory chemokines to active areas of arthritis, where they secreted cytokines that suppressed osteoclastogenesis in the authors' rat model. MSCs have properties that were useful in this model: they home to the affected area, they downregulate inflammation, and they directly inhibit the bone destruction mediated by osteoclasts.

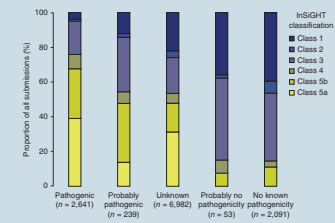
Laboratory Investigation | Volume 94 March 2014

nature.com/pathology

Better predictions of which mismatch-repair gene mutations are pathogenic

Loss-of-function mutations in DNA mismatch-repair (MMR) genes such as *MLH1*, *MSH2*, *MSH6*, and *PMS2* underlie hereditary nonpolyposis colorectal carcinoma (HNPCC), or Lynch syndrome. Although mutations that encode a truncated protein are often suggested to be deleterious, many single-nucleotide polymorphisms (SNPs) are difficult to assess if they are associated with only a single amino acid substitution. Thompson and the InSiGHT group carefully examined many thousands of MMR gene sequences and developed a robust, five-tiered system to predict the likelihood that microsatellite instability would result from the SNP. They then demonstrated the efficacy of this system to predict the effects of a variety of variants in these genes. Application of this system in clinical genetics practice should improve the ability to provide informative counseling for patients and their families when HNPCC is a clinical consideration.

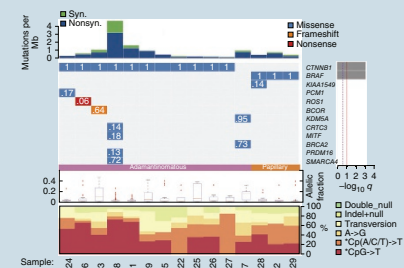
Nature Genetics 2014;46:107–115; doi:10.1038/ng.2854



Papillary craniopharyngioma joins the family of cancers with *BRAF* mutations

Brastianos and colleagues examined craniopharyngiomas using exome sequencing. They studied two forms of this neoplasm: the adamantinomatous form, which is cystic and more common in children, and the papillary form, which tends to be solid and is more common in adults. Mutations in exon 3 of *CTNNB1*, the gene encoding β -catenin, were identified in virtually every adamantinomatous craniopharyngioma whereas V600E mutations in *BRAF* were seen in virtually all the cases of papillary craniopharyngioma. These mutations, which were mutually exclusive events, were the only driver-type mutation identified in these tumor types. Overall, the mutational load—primarily random passenger mutations—in craniopharyngiomas was low compared with other cancer exomes. Immunohistochemistry demonstrated nuclear accumulation of β -catenin in adamantinomatous craniopharyngiomas, whereas the distribution was membranous in the papillary form. The papillary form showed reactivity to antibodies specific to the V600E-mutated *BRAF* protein; this was not detected in the adamantinomatous form. These two variants of craniopharyngiomas seem to be driven solely by these two driver mutations.

Nature Genetics 2014;46:161–165; doi:10.1038/ng.2868



Dietary fiber influences gut microbe composition, allergic airway reactions, and hematopoiesis

It has long been known that diet influences both the population mix and the metabolism of gut microbes, with profound effects on gut function. Dietary fiber can calm inflammatory gastrointestinal disorders and protects against colon cancer. How and whether such effects could extend to other organs is not known. Using a mouse model, Trompette *et al* found that high-fiber diets alter the ratio of Firmicutes to Bacteroidetes by maintaining an expansion of the latter. This alters gut metabolism, resulting in the release of circulating short-chain fatty acids. These products were protective against pulmonary allergic reactions and mobilized the bone marrow to seed the lungs with dendritic cells that further inhibit allergic reaction. A low-fiber diet was associated with opposite effects. This report presents a mechanism through which diet can affect the function of organs other than the gut. Reduced fiber in the diet of populations in developed countries may thus be causally linked to the coincident dramatic increase in allergic asthma.

Nature Medicine 2014;20:159–166; doi:10.1038/nm.3444

