

Design: We performed a retrospective review of the pathology of 749 patients who underwent thyroidectomy at our institution from 1/2010 to 7/2013. 297 cases with chronic thyroiditis were identified and 196 had either an anti-thyroglobulin or anti-thyroid peroxidase antibody testing done. 4 cases with malignancies other than PTC were excluded. 192 cases were included, 102 had positive ATA. We compared the final histologic diagnoses according to the presence of ATA and the severity of CLI. **Results:** Our study demonstrated a higher rate of PTC in cases with CLT compared to benign thyroid disease (62% vs 38%, $p < .0001$). After comparing the cases according to the severity of CLI and presence of ATA, the results were not statistically significant.

Table 1. Final diagnoses of cases with CLT, number (%)

	With CLT	Without CLT	P
PTC	119 (62%)	170 (31%)	<0.0001
Benign thyroid	73 (38%)	387 (69%)	

CLT=chronic lymphocytic thyroiditis

Table 2. Final diagnoses of cases with CLT according to the presence of ATA and severity of chronic inflammation, number (%)

	Benign thyroid	PTC	P
With ATA	38 (37%)	64 (63%)	0.8819
Without ATA	35 (39%)	55 (61%)	
Mild CLI	44 (39%)	69 (61%)	0.7651
Moderate to severe CLI	29 (37%)	50 (63%)	

ATA=antithyroid autoantibody, CLI=chronic lymphocytic infiltrate

Conclusions: Chronic thyroiditis is associated with significantly higher risk of PTC, likely due to inflammatory microenvironment. The severity of CLI and the presence of ATA such as anti-thyroglobulin or anti-thyroid peroxidase antibody which are considered hallmarks of autoimmunity do not appear to be specifically associated with this risk.

652 BRAF V600E Mutation in Anaplastic Thyroid Carcinoma

AE Waltz, A Pao, S Bose. Cedars-Sinai Medical Center, Los Angeles, CA.

Background: Anaplastic thyroid carcinoma (ATC) is an uncommon but highly aggressive tumor that is characteristically refractory to radioiodine therapy. BRAF mutation has been reported in up to 40% of ATC. Identification of a differentiated or poorly differentiated cancer component in some ATC raises the possibility of transition from a differentiated carcinoma. Recently, targeted therapy with Vemurafenib has shown some efficacy in BRAF mutated ATC. Intratumoral heterogeneity is recognized as an important determinant of a cancer's response to targeted therapy. This study was designed to assess BRAF genetic heterogeneity (BRAF GH) within ATC.

Design: 13 ATC [9 with area(s) of differentiated or poorly differentiated papillary thyroid carcinoma (ATC-PTC) and 4 without differentiated area(s) (ATC-ATC)] were identified in our database. After slides were reviewed, diagnoses confirmed, and patient demographics recorded, formalin fixed paraffin embedded sections of the ATCs were macrodissected and analyzed for BRAF V600E (1799T>A) mutation using real-time PCR. BRAF GH was assessed in 2 groups of paired tumor samples: ATC-PTC group: PTC component vs. anaplastic component in the same tumor ATC-ATC group: two separate areas of anaplastic tumor in ATC without PTC component.

Results: The 13 patients (8 females, 5 males) ranged from 70 to 89 years in age (median 76 yrs) at operation. The tumors ranged from 3.5 cm to 9.0 cm. The BRAF mutation was detected in 9 (69.2%) of the cases including 7 (77.8%) of the ATC-PTC and in 2 (50%) of the ATC-ATC tumors. Analysis for the presence of the BRAF mutation yielded concordant results in 100% of the paired samples.

Conclusions: BRAF V600E mutation occurs frequently in ATC and its incidence is higher in ATC that exhibit a PTC component than in those that lack this feature. Heterogeneity for BRAF mutation status is infrequent within primary ATCs. Our findings support PTC as the origin of a subset of ATC and suggest that the BRAF mutation is an early event in their development. Testing for the presence of BRAF V600E mutation may improve therapy selection in ATC.

653 Phosphohistone H3 (PHH3) Is a Reliable Proliferation Marker in Grading Pulmonary and Pancreatogastrointestinal Neuronendocrine Neoplasms

W Zhou, J Balakrishna, V Ghali. St. Luke's - Roosevelt Hospital, New York, NY.

Background: Pathologic grading of neuroendocrine tumors (NET) is established by scoring the number of mitoses per 10 high-power fields (/10 HPF), and immunostaining of proliferating cell nuclear antigen or MIB-1/Ki-67. However, Ki-67 is expressed throughout the cell cycle from late G1 phase. Many Ki-67+ nuclei may not survive the cell cycle and are driven into apoptosis, thereby blurring the prognostic value. Anti-PHH3 antibody detects specifically the core protein histone H3 only when phosphorylated at serine 10 or serine 28 - a process almost exclusively occurring during mitosis.

Design: We studied anti-PHH3 staining in 41 cases of pulmonary and 39 cases of pancreatogastrointestinal NET. We compared anti-PHH3/10 HPF with MIB/Ki-67 and H&E mitosis/10 HPF. The staining of PHH3 was evaluated by counting of positive nuclei ($\times 400$). In general, the staining of PHH3 was strong and crisp even at cauterized areas, with no background. Some interphase nuclei with sparse granular staining were not counted. 80 cases were scored blindly by two observers showing good agreement (Spearman's correlation coefficient 0.81, $\kappa = 0.70$).

Results: The median of PHH3-positive mitotic figures were 1.1, 8.5 and 52/10HPF for grade 1, grade 2 (atypical) and grade 3 (small cell carcinoma) of pulmonary NET. The median of PHH3-positive mitotic figures for pancreatogastrointestinal NET were 0.8, 5.5 and 22 for grade 1, grade 2 and grade 3 NET (Table 1). Increasing PHH3-positive mitotic figures was strongly correlated to increased tumor grading ($P < 0.001$; Mann-Whitney). The PHH3 positive figures, H&E mitotic count and Ki67 index were well correlated (Spearman's correlation coefficient 0.62, $P < 0.001$). Only 6 cases (67%) of grade 3 pulmonary NET and 3 cases (43%) grade 3 GI NET showed some PHH3

negative mitotic figures (<10% of total mitotic cells). In 10 pulmonary grade 2 NET, 4 cases with distant metastasis (bone, liver) had higher PHH3 count (>10/10HPF, average 12/10HPF), raising the possibility that these tumors should be upgraded.

Conclusions: PHH3 is a rapid and reliable method assessing mitotic figures in grading pulmonary and GI neuronendocrine neoplasms.

Table 1. Mitotic count, Ki67 and PHH3 count in association with tumor grading

	PHH3/10HPF		Mitotic count /10HPF		Ki-67	
	N	Median	P-value	Median	P-value	Median
Lung			0.001<		0.001<	0.001<
G1	20	1.1		0.8		1.5
G2	10	8.5		6.2		14
G3	9	52		60		88
GI			0.001<		0.001<	0.001<
G1	28	0.8		0.6		1.5
G2	4	5.5		3.5		22.5
G3	7	22		23.5		48

* 2 cases were excluded due to limited tissue amount (<3HPPF)

Gastrointestinal Pathology

654 Endoscopic Abnormalities of the Pre-Pouch Ileum Are Strongly Predictive of Subsequent Crohn's Disease in Patients with an Ileal Pouch-Anal Anastomosis

CA Adackapara, A Agoston, M Hamilton, RD Odze, A Srivastava. Brigham and Women's Hospital, Boston, MA.

Background: Approximately 10% of patients with an ileal pouch-anal anastomosis (IPAA) for ulcerative colitis (UC) develop refractory pouchitis or have their diagnoses revised to Crohn's disease (CD) on follow up. The clinical and pathologic features best predictive of pouch revision/failure and a revised diagnosis of CD are unknown. The aim of our study was to determine the significance of pre-pouch abnormalities as a predictor of pouch revision/failure and CD.

Design: 152 patients with IPAA for UC, identified over a 20 year period at a tertiary academic medical center, were evaluated. For each patient, the presence and type of endoscopic abnormalities in the pre-pouch ileum, a histologic diagnosis of pre-pouch ileitis, the number of episodes of clinical pouchitis, and the presence of refractory pouchitis were recorded. The major outcomes of interest were pouch revision/failure and a revised diagnosis of CD. Multivariate linear regression analysis was performed to identify features most predictive for the outcomes above.

Results: 71 men and 81 women (mean age 51.7 years) with a mean follow-up of 12.2 years (range 1-31 years) formed the study group. 40/152 patients had pre-pouch ileitis on biopsy whereas 27/152 had endoscopic abnormalities noted in the pre-pouch ileum (including erythema, erosion, ulcer, and stricture). The mean number of episodes of clinical pouchitis for all patients was 2.2. Sixteen (10%) patients developed refractory pouchitis, 20 patients (13%) had pouch revision/failure and 18 (12%) had a diagnosis revised to CD on follow-up. The presence of any pre-pouch abnormality on endoscopy (OR 3.86; $p = 0.034$), refractory pouchitis (OR 5.17; $p = 0.015$), and a revised diagnosis of CD (OR 4.30; $p = 0.025$) were predictive of pouch revision/failure unrelated to surgical issues. In addition, more than 2 episodes of clinical pouchitis (OR 7.54; $p = 0.002$), pre-pouch abnormality on endoscopy (OR 6.91; $p = 0.002$), and pre-pouch ileitis either by endoscopy or biopsy (OR 3.28; $P = 0.049$) were most predictive of a subsequent diagnosis of CD.

Conclusions: Refractory pouchitis and endoscopic abnormalities of the pre-pouch ileum are most predictive of eventual pouch revision/failure. Multiple episodes of clinical pouchitis and pre-pouch abnormalities on endoscopy are strong predictors of a revised diagnosis of CD.

655 The Expression of CD44v6 in Colon: From Normal to Malignant

A Ajfijy, A Viridi, H Jess. UC Davis, Sacramento, CA.

Background: CD44v6, an integral transmembrane protein belonging to a family of adhesion molecule receptors, plays an important role in tumor growth, proliferation, and metastasis. Its expression in normal tissue is highly restricted. Transfection of tumor cells with CD44v6 exons confers an aggressive metastatic behavior. The purpose of this study was to evaluate the expression of CD44v6 in benign, hyperplastic, dysplastic and malignant colonic epithelium.

Design: Formalin-fixed, paraffin-embedded archival tissue from 178 cases of normal colonic tissue ($n = 25$), hyperplastic polyps (HP, $n = 45$), tubular adenomas (TA, $n = 57$), villous adenomas (VA, $n = 25$) and adenocarcinomas ($n = 26$) of the colon were retrieved from the surgical pathology files. All cases were reviewed histologically for diagnosis confirmation and stained using a monoclonal antibody to CD44v6 (1:1500, Bender MedSystems). Positive staining was defined as uniform strong membranous staining in at least 10% of cells. The staining intensity (0+ to 3+) and distribution (focal vs diffuse) was assessed in a semi-quantitative fashion and scored.

Results: All cases of normal colonic tissue and HP expressed strong (3+) CD44v6 staining limited only to the cells located at base of the crypt. CD44v6 was expressed in 49 (86%) cases of TA (3+ in 30 cases and 2+ in 19 cases) and 18 (72%) cases of VA (3+ in 8 cases and 2+ in 10 cases). In both TA and VA the epithelial cells at the base of the crypt were negative, while the surface adenomatous epithelium showed diffuse CD44v6 staining. CD44v6 was expressed diffusely in 24 (92%) of adenocarcinomas (3+ in 13 cases, 2+ in 11 cases). Stromal cells in normal, benign or neoplastic lesions did not express CD44v6.

Conclusions: In normal colonic epithelium CD44v6 is exclusively expressed in cells located at the base of the crypt, the same location of colonic epithelial stem and progenitor cells. The gain of expression of CD44v6 in surface epithelium with loss of

expression in the crypts in dysplastic colonic polyps with subsequent diffuse expression in malignant colonic lesions suggests that CD44v6 may be functionally involved in the development and progression of colon cancer.

656 Role of Intraepithelial Lymphocyte Density in the Transcriptome of Microsatellite Stable Primary Colon Cancer

A Agarwal, G Manyam, Z-Q Jiang, N Neishaboori, S Agarwal, M Overman, B Broom, P Roepman, I Simon, S Kopetz, D Maru. Baylor College of Medicine, Houston, TX; The University of Texas MD Anderson Cancer Center, Houston, TX; Agendia, Amsterdam, Netherlands.

Background: High tumor intraepithelial lymphocytes (IEL) is associated with microsatellite instability high status and better prognosis in primary colon cancer. However, molecular context associated with IEL in the absence of microsatellite instability is unknown.

Design: HE sections from resection specimens of stage II/III microsatellite stable primary colon cancer from 168 patients were reviewed. Number of IEL per 100 tumor cells were manually counted in the area of the invasive tumor with highest density of IEL. Gene expression profiling was performed by Agilent Microarray Assay on the manually microdissected fresh frozen tumor samples with more than 30% tumor cell density. RNA from these samples was hybridized with reference genome from pool of primary colon cancers. Lowess based normalization was performed using the Agilent feature extraction software. A differential expression analysis was performed using t-tests. The p-values were obtained by multiple t-tests and corrected for false discovery rate (FDR) by Beta-Uniform Mixture (BUM) method. Gene Set Enrichment Analysis (Broad Institute, Boston, MA) was utilized to assess pathway enrichment differences between high and low IEL groups.

Results: The study included 91 men and 77 women with median age of 63 (range 30-94) years. Correlation of IEL with gene expression profiling was performed with IEL count as a continuous variable and dividing the patients in two groups based on median of 2 IEL per 100 tumor cells. IEL 2 or less were identified as low IEL and higher than 2 IEL identified as high IEL. With a stringent lowest FDR threshold of 0.05 there were 436 gene transcripts which were differentially expressed between low and high IEL groups. Critical pathways of cancer enriched in tumors with high IEL are associated with apoptosis, cell cycle, DNA replication, and cellular adhesion. PPAR signaling pathway is enriched in tumors with low IEL.

Conclusions: Association of tumor IEL density with differential gene expression and pathway enrichment provide support in favor of a biologic interdependency between tumor immunity and molecular characteristics of colon cancer. Future studies should focus on inclusion of this HE feature in molecular subtyping of colon cancer.

657 Prevalence and Concordance of Subtypes of Dysplasia in Patients with Barrett's Esophagus-Associated Adenocarcinoma

AT Agoston, A Srivastava, Y Zheng, R Bueno, RD Odze. Brigham and Women's Hospital, Boston, MA.

Background: Adenocarcinoma develops in Barrett's esophagus (BE) via a metaplasia-dysplasia-carcinoma pathway. Two types of dysplasia have been previously identified termed "intestinal" (INT) and "foveolar" (FOV) (i.e. gastric), but the prevalence, significance, and relationship to carcinoma subtypes remain unknown. The aim of this study was to determine the prevalence, and types, of dysplasia in a consecutive series of non-neoadjuvant treated BE-associated adenocarcinomas (BEAd), and to evaluate potential relationships between dysplasia and carcinoma subtypes in order to identify possible multiple pathways of carcinogenesis.

Design: The study group consisted of 156 consecutive patients with BEAd resected without neoadjuvant chemoradiation, at the Brigham and Women's Hospital (mean age: 66; 83% male). The types, prevalence, and percentage of dysplasia subtypes (INT, FOV, serrated) were evaluated in background mucosa, and correlated with the types of invasive carcinoma. Both dysplasia and adenocarcinoma were defined as "pure" or "predominantly" INT or FOV if $\geq 90\%$ or $>50\%$, respectively, of the cells showed INT or FOV differentiation.

Results: 122/156 patients (78%) showed dysplasia in background mucosa. The dysplasia was purely INT in 26%, predominantly INT in 34%, purely FOV in 8%, predominantly FOV in 11%, and mixed ($\leq 50\%$ INT and FOV) in 55% of cases. Only one case showed focal serrated dysplasia. Of the 156 carcinomas, 15% showed pure INT, 22% showed predominantly INT, 2.6% showed pure FOV, 5.8% showed predominantly FOV, and 72% showed mixed pattern INT and FOV differentiation. Patients with pure INT dysplasia were significantly associated with pure INT carcinomas (OR=4.74, $p=0.002$), patients with pure FOV dysplasia were associated with predominantly FOV carcinomas (OR=24.2, $p=0.001$), and patients with mixed differentiation dysplasia were associated with mixed differentiation carcinomas (OR=6.25, $p<0.001$).

Conclusions: Intestinal, FOV, or mixed INT/FOV are the most common types of dysplasia in BE. In general, the type of dysplasia correlates with type of carcinoma. This data suggests that multiple distinct pathways of carcinogenesis may occur in BE, and that genetic alterations leading to divergent differentiation may occur early in the pathogenesis of disease, at the dysplasia stage.

658 Predictors of Durable Treatment Response after Radiofrequency Ablation for Barrett's Esophagus Associated Intramucosal Adenocarcinoma

AT Agoston, PS Dulai, RI Rothstein, RD Odze, A Srivastava. Brigham and Women's Hospital, Boston, MA; Dartmouth-Hitchcock Medical Center, Lebanon, NH.

Background: Radiofrequency ablation (RFA), with or without endoscopic mucosal resection (EMR), has been validated as an effective treatment option for Barrett's esophagus (BE) associated dysplasia. Its efficacy in eradicating intramucosal carcinoma

(IMC) is debatable. The aim of our study was to determine the clinicopathologic factors that predict durable treatment response after RFA for IMC.

Design: 36 patients who underwent RFA for IMC at the two participating institutions were identified and systematically evaluated for a predefined set of pathologic parameters where slides were available ($n=27$). The primary outcome of interest was durable complete eradication of IMC. Complete IMC eradication was defined as eradication of all IMC and concurrent dysplasia after one or more cycles of RFA with or without EMR. Durable eradication was defined as completed eradication with no recurrence until last follow up.

Results: Of the 36 patients (26 male : 10 female; mean age 64 yrs; mean BE segment length 3.5 cm), 35 (97%) had concurrent high-grade dysplasia. EMR was performed in 31 (86%) patients prior to RFA. Durable complete eradication of IMC and intestinal metaplasia was achieved in 29/36 (81%) and 22/36 (61%) patients, respectively, after a mean follow-up period of 24 months. Depth of invasion measured from the mucosal surface (odds ratio [OR] = 24.4, $p=0.013$), and EMR performed prior to the RFA (OR = 10.1, $p=0.04$) were the most significant predictors of durable eradication of IMC. The overall size of IMC, extent of IMC (% of tissue involved), depth of IMC invasion (as measured from muscularis mucosa), and extent of high grade dysplasia (# of crypts, and % of tissue involved) were not significantly associated with durable eradication of IMC, dysplasia, or intestinal metaplasia.

Conclusions: Durable and complete eradication of IMC in BE can be achieved by RFA in greater than 80% of patients. Depth of invasion and performance of an EMR prior to RFA are positively associated with durable eradication of IMC. This is likely due to increased visibility of lesions on endoscopy thereby ensuring better removal of the most aggressive component of the lesion prior to RFA.

659 Comprehensive Genomic Profiling of Gastric Carcinoma by Next Generation Sequencing Reveals Frequent Actionable Genomic Alterations and New Routes to Targeted Therapies

SM Ali, K Wang, GA Otto, GA Palmer, R Yelensky, D Lipson, D Morosini, VA Miller, PJ Stephens, JS Ross. Foundation Medicine Inc, Cambridge, MA.

Background: Gastric carcinoma (GC) in Western societies is typically diagnosed as advanced stage disease, which carries a high mortality rate. For both adjuvant and metastatic disease, systemic chemotherapy is minimally effective. Clinical genomic profiling by next generation sequencing of the GC genome may reveal new treatment pathways by identifying genomic alterations that predict responsiveness to targeted therapies.

Design: Hybridization capture of 3,769 exons from 236 cancer-related genes and 47 introns of 19 genes commonly rearranged in cancer was applied to ≥ 50 ng of DNA extracted from 54 GC FFPE specimens and sequenced to high (average 833X), uniform coverage. Genomic alterations (base substitutions, small indels, rearrangements and copy number alterations) were determined and then reported for these patient samples. Actionable genomic alterations (GAs) were defined as those identifying targeted anti-cancer drugs on the market or in registered clinical trials (CT).

Results: There were 29 male and 25 female patients with a median age of 62 (range 31-87 yrs). Twelve GCs were grade 2, and 41 GCs were grade 3 (grade N/A for 1 sample). Two GCs were Stage I, 5 GCs were Stage II, 9 GCs were Stage III, and 37 were Stage IV at time of sequencing. Thirty seven were primary tumors, and 17 were biopsies of metastases. A total of 218 alterations were observed, yielding an average of 4.0 alterations per tumor (range 0 to 17). The most common non-actionable alteration was TP53 (48%). One hundred ninety two actionable alterations were identified yielding an average of 3.55 per tumor (range 0 to 16). Forty eight (88%) GC harbored at least 1 actionable GA with an average of 1.62 actionable GA per patient including alteration in RTK's: amplifications in *MET* (5.5%) and *FGFR2/3* (5.5%), and alterations in *ERBB2* (7.4%), which are half amplifications and half activating base substitutions. *ARID1A* altered (14/54; 26%) GCs did not have focal copy number alterations (0/14), but the *ARID1A* wild type GCs often possessed gene amplifications (24/40). *CDHI* alterations were present in 14.8% (8/54) of GCs, but only 37.5% (3/8) of such cases were diagnosed as diffuse GCs.

Conclusions: The majority of GCs harbored actionable alterations, which indicate potential responsiveness to commercially available therapies and therapies in clinical trials. The many genes altered, including several RTKs, indicate the need for comprehensive genomic profiling to demonstrate all possible avenues for molecularly targeted treatment for GC patients.

660 High Expression of Matrix Metalloproteinases (MMPs); MMP-2 and MMP-9 Predicts Poor Outcome in Colorectal Carcinoma

J Al-Maghrabi, N Saleem, A Buhmeida, A Abuzenada, I Kamal, M Al-Qahtani, M Al-Ahwal. Faculty of Medicine, King Abdulaziz University, Jeddah, Saudi Arabia; King Abdulaziz University, Jeddah, Saudi Arabia; Faculty of Science, King Abdulaziz University, Jeddah, Saudi Arabia.

Background: The current staging system along the conventional prognostic factors is the gold standard for prognosis of colorectal cancer (CRC). In spite of that, it is unable to distinguish those patients who might carry high risk of recurrence and poor outcome, which highlights the need for new molecular factors that could stratify patients into different risk categories. This study is aimed to assess the expression of selected group of matrix metalloproteinases (MMPs); MMP-2, MMP-7 and MMP-9 in a subset of primary CRC and determine its relation to different clinico-pathological factors and survival.

Design: Paraffin blocks of 127 CRC patients were retrieved. Antigen expressions of MMP-2 and -9 were analyzed by immunohistochemistry (IHC) and their cytoplasmic and stromal staining was evaluated.

Results: The results showed that overexpressions of both MMP-2 and MMP-9 were a significant sign of poor outcome and recurrence as evaluated by univariate Kaplan-Meier for disease-free survival (DFS) ($p=0.012$, $p=0.001$) and disease-specific survival

(DSS) ($p=0.012$, $p=0.038$). In multivariate survival (Cox) analysis, MMP-2 and -9 also were significant independent predictors of DFS ($p=0.006$, $p=0.018$) and DSS as well ($p=0.004$, $p=0.049$).

Conclusions: These results implicate the usefulness of MMP-2 and -9 expressions in predicting outcome of patients with CRC.

661 Patterns of Gastric Mucosal Atrophy in Neuroendocrine Tumours of the Duodenum

A Ananthamurthy, M Correa, M Patil. St. John's Medical College, Bangalore, India.

Background: Neuroendocrine tumours (NET) of the duodenum are believed to be rare tumours. However, well differentiated NETs (carcinoids) of the proximal duodenum accounted for more the 60% of all NETs seen in our centre. Of the 52 carcinoids of the duodenum over the past 7 years, 18 also had either biopsies (17 cases) or excision of the stomach (1 case). The purpose of this study is to document the histopathological changes in the gastric mucosa of patients with duodenal NETs with a special emphasis on patterns of atrophy.

Design: The histopathology findings in the subset of 18 cases were reviewed for the presence and extent of atrophy and intestinal metaplasia. The changes were assessed on Haematoxylin and Eosin (H & E) and AB-PAS stains. The Updated Sydney guidelines were applied for the assessment of chronic gastritis and atrophy.

Results: Of the 18 cases, 11 were male. The ages ranged from 42 to 77 years. None of the patients gave history of long term use of proton pump inhibitors. The endoscopic sizes of the nodules ranged from 5 mm to 12.5 mm. In the antral mucosa, mild non metaplastic atrophy was seen in 5 cases, moderate non metaplastic atrophy in 3 cases, moderate metaplastic atrophy in 5 cases and severe non metaplastic atrophy in 2 cases. The antral mucosa was negative for atrophy in 3 cases. The corpus mucosa was included in 12 of the biopsies and showed mild non metaplastic atrophy in 3 cases, mild metaplastic atrophy in 1 case and moderate non metaplastic atrophy in 1 case. In 6 cases, no atrophy was seen in the corpus and in 1 case was indefinite for atrophy. One patient had a concomitant carcinoma of the stomach (which also showed mild atrophy in the corpus) and another, a concomitant carcinoid in the antrum of the stomach (which also showed moderate non metaplastic atrophy). In all, 16 of the patients (89%) showed some degree of gastric mucosal atrophy in the antrum or corpus or both.

Conclusions: Antral predominant atrophy and intestinal metaplasia were prominent features seen in the gastric mucosa of this cohort of 18 cases with duodenal carcinoids. H pylori induced multifocal gastric atrophy is a well known cause of gastric carcinoids which is due to the trophic effect of gastrin on the ECL cells of the stomach. The high prevalence of duodenal carcinoids in our population and the finding of gastric atrophy in 88% of the biopsies in this study suggests that H pylori induced gastric atrophy may be a triggering factor for the occurrence of duodenal carcinoids also.

662 Significance of Proximal Margin Involvement in Low Grade Appendiceal Mucinous Neoplasm

T Arnason, M Kamionek, X Yang, RK Yantiss, J Misdraji. Queen Elizabeth II Health Sciences Centre, Halifax, NS, Canada; Massachusetts General Hospital, Boston, MA; University of Massachusetts Medical School, Worcester, MA; Weill Cornell Medical College, New York, NY.

Background: Low grade appendiceal mucinous neoplasms (LAMN) confined to the appendix are generally cured by appendectomy, whereas those that have penetrated the muscularis mucosae are at variable risk of recurrence and/or pseudomyxoma peritonei. The risk of developing pseudomyxoma peritonei is highest when neoplastic epithelial cells are present outside the appendix. Some authors have also suggested that involvement of the proximal appendiceal margin by tumor also represents a risk factor for disease recurrence and, thus, advocate labeling such lesions as having uncertain malignant potential. The purpose of this study is to determine whether involvement of the proximal appendiceal resection margin by a LAMN or adenoma is an independent risk factor for local recurrence or pseudomyxoma peritonei.

Design: We searched the pathology archives of three institutions over a 23 year period and identified LAMNs and appendiceal adenomas with positive proximal margins, as defined by the presence of neoplastic mucinous epithelium or acellular mucin dissecting in the wall. Cases with serosal perforation by tumor, or less than six months of follow up were excluded. Pathology reports and slides were reviewed to confirm the diagnosis and classify margin involvement. Clinical and radiology records were reviewed to determine outcomes.

Results: 15 patients (13 female, 2 male) with LAMN ($n=14$) or adenoma ($n=1$) and a positive proximal resection margin were identified, including 9 with neoplastic mucosa in the lumen at the margin and 6 with acellular mucin dissecting in the appendiceal wall at the margin. Four patients had a second resection: 3 had no residual disease and 1 had acellular mucin in the cecal wall. No patient had recurrence upon clinical follow up (mean 4.2, range 0.5-11.2 years).

Conclusions: Involvement of the appendectomy margin by neoplastic epithelium or acellular mucin is not associated with recurrence of disease, even without further surgery. Additional surgery may not be indicated for patients with LAMN involving the proximal appendiceal margin, provided the lesion is entirely confined to the appendiceal wall.

663 Long-Term Outcome Study of Barrett's Esophagus with Basal Crypt Dysplasia

S Askari, BR Lindgren, G Niehans, RD Odze. Fairview Ridges Hospital, Burnsville, MN; University of Minnesota, Minneapolis, MN; Veterans Affairs Medical Center, Minneapolis, MN; Brigham and Women's Hospital, Boston, MA.

Background: Basal crypt dysplasia (BCD) (dysplasia without involvement of upper crypt/surface epithelium) has been previously identified as an early neoplastic precursor lesion in Barrett's esophagus (BE). The clinical significance of BCD with regard to

progression to higher grade of dysplasia/carcinoma (CA) has never been evaluated. The purpose of this study was to determine outcome of a cohort of BE patients (pts) with BCD and to compare the results to pts with negative (NEG) or low-grade dysplasia (LGD).

Design: A retrospective search of pathology files of a major academic hospital, over a 5-year period (pr) was performed in order to identify newly enrolled BE pts. All follow-up (f/u) biopsies (bxs) obtained over a 20-yr pr were reviewed to identify initial (index) bxs showing BCD, LGD, or NEG. The highest degree of subsequent dysplasia was then investigated during the f/u pr after the index biopsy. Two gastrointestinal pathologists confirmed the diagnosis of BCD in each pt. Outcome in BCD pts was compared with LGD and NEG pt cohorts. Dysplasia, including BCD, was graded as per previously published criteria (NEG, BCD, LGD, HGD, and CA).

Results: Overall, the study included 123 BE pts who underwent 1019 bxs during the entire study pr that included 839 pt-yrs of f/u. Of the 123 pts, 35 had BCD, 14 had LGD, and 74 were NEG for dysplasia in index biopsies.

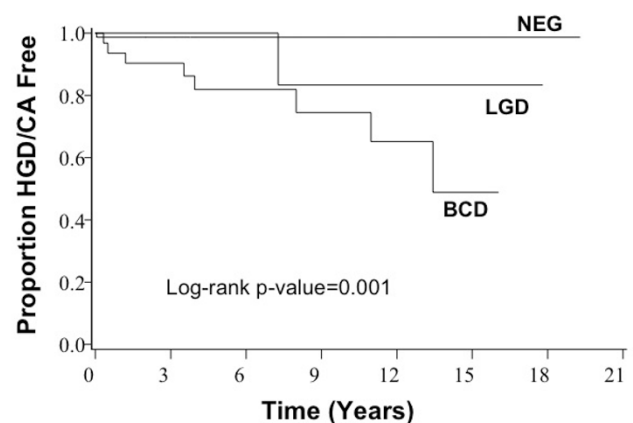
Outcome Analysis by Patient Cohort

	F/U Pr (Yrs) Median [Min/Max]	# of Bxs	Outcome			
			NEG	BCD	LGD	HGD/CA (%)
BCD (N=31†)	5 [0.3/16]	288	4	18	1	8 (25.8)
LGD (N=12†)	6 [0.6/17.8]	123	3	2	6	11 (8.3)
NEG (N=74)	5 [0.04/19.3]	481	73	0	0	1 (1.4)
Total=119	5 [0.04/19.3]	892	80	20	7	10 (8.4)

†2 BCD and 2 LGD pts excluded for absence of f/u bx after index bx; 2 BCD pts excluded for presence of HGD/CA in index bx.
‡No BCD during f/u pr.

p-values for progression to HGD/CA (using Fisher's exact test) - BCD vs NEG: <0.001 ; BCD vs LGD: 0.405; NEG vs LGD: 0.261. Overall: <0.001 .

Time to HGD/CA (Using Kaplan-Meier Method)



Conclusions: BCD is a significant neoplastic precursor lesion in BE. Based on our data, pts with this lesion should be managed similar to those with conventional LGD.

664 Incidence and Role of CMV Detection in Inflammatory Bowel Disease Biopsies by PCR and Real Time PCR. A Clinicopathological Study in 201 Samples

A Azueta, P Munoz, S Lazuen, M Nicolas, I Zabalza, S Pereda, J Freire, J Gomez-Roman. Hospital Universitario Marques de Valdecilla-IFIMAV, Santander, Cantabria, Spain; Servicio Cántabro de Salud, Santander, Cantabria, Spain; Hospital Galdakao-Usansolo, Galdakao, Bizkaia, Spain.

Background: Cytomegalovirus (CMV) role in Inflammatory Bowel Disease (IBD) is controversial, and it is discussed if its presence is the primary cause of the patient worsening or only a non pathogenetic consequence of treatment and immunosuppression. Otherwise only isolated papers discuss the issue of CMV molecular detection in biopsies of IBD patients.

Design: To evaluated the prognostic significance and clinical impact of CMV detection by conventional PCR and quantitative-PCR in tissue in IBD patients and to relate the results with type of treatment administered, we selected all patients diagnosed with IBD, at our institution from 2005 to 2010, with at least one biopsy or surgical specimen suitable to be analyzed by molecular methods (102 patients and 201 samples). A semiquantitative PCR-ELISA and real-time quantitative PCR for CMV were performed from formalin fixed paraffin embedded tissue. Semiquantitative PCR was also performed in 16 colon biopsies from patients without IBD. Clinical follow-up was analyzed, detailing drug, surgical therapy and hospital stay in each episodes.

Results: All 16 samples without IBD were negative. CMV was positive in 26.4% of all biopsies with IBD. It was most frequently found in Ulcerative Colitis (UC) than in Crohn's Disease (CD). The average stay for patients without CMV was 7.12 days and with CMV was 20.26 days ($p<0.05$). Nine of 102 patients were subjected to total colectomy. Patients with CMV suffered colectomy (12.1%) more frequently than patients without CMV (5.4%). Patients treated with azathioprine were most frequently positive (35.8%) compared to those treated with anti-TNF (16.7%).

Conclusions: We have observed CMV PCR amplification in 26.4% of IBD biopsies. It was more common in UC than in CD. There was a statistically significant tendency to present more hospitalization days in patients with CMV. Azathioprine treated patients were more likely to have amplification of CMV in their biopsies compared with anti-TNF.

665 Sub-Staging of Nodal Status in Ampullary Carcinomas as N1 (<3) and N2 (≥3) Has Significant Prognostic Value: Proposal for Revised Staging Based on an Analysis of 313 Cases

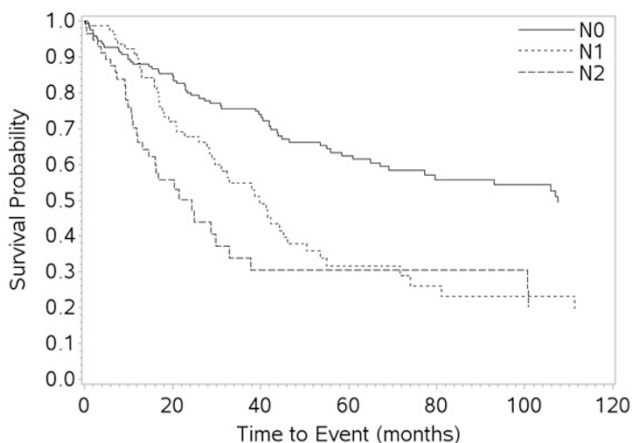
P Bagci, S Balci, B Saka, S-M Hong, K-T Jang, N Ohike, G Kim, A Krasinskas, O Basturk, J Sarmiento, D Kooby, B El-Rayes, S Maitheil, J Knight, M Goodman, V Adsay. Emory, Atlanta, GA; AMC, Seoul, Korea; SMC, Seoul, Gangnam, Korea; Showa, Tokyo, Japan; UCSF, San Francisco, CA; MSKCC, NY, NY.

Background: Current N-staging of ampullary carcinomas in the AJCC/UICC TNM recognizes only N0 and N1 categories, but does not address the possible prognostic significance of number of metastatic lymph nodes (LNs).

Design: 313 well-characterized ampullary carcinomas, resected (pancreaticoduodenectomy) and well-sampled, were analyzed. Pancreatic ductal, non-ampullary duodenal, and distal common bile duct carcinomas, and unusual tumor types such as neuroendocrine were carefully excluded with purist's approach. Applicability and prognostic value of a revised N-stage protocol similar to that used in other organs as N0, N1 (1-2 LNs) and, N2 (≥3) were analyzed.

Results: The median number of LNs examined was 11 (range, 1-61). 142/313 (45%) cases had LN metastasis. Median number of metastatic LNs in LN-positive cases was 2 (range, 1-19). Median survival of LN-negative cases was significantly better than that of LN-positive cases (107 vs 32 mos; $p < 0.001$). When LN-positive cases were further classified according to the proposed staging protocol, 82 cases (26%) fell into N1, and 60 cases (19%) into N2 categories, with a median survival of 40 and 25 mos, respectively. The 1-, 3- and 5-yr survival rates were **N0:** 88%, 76%, 62%; **N1:** 90%, 55%, 32%; and **N2:** 68%, 34%, 30%, respectively ($p < 0.001$).

Kaplan-Meier Survival Curves



There was statistically significant correlation between proposed N-stage and frequency of lymphovascular invasion ($p < 0.001$), perineural invasion ($p < 0.001$), surgical margin positivity ($p = 0.001$), as well as invasive tumor size ($p < 0.001$). In a multivariate model adjusted for age, sex, invasion size, stage of invasive tumor, perineural invasion, surgical margin and site specific classification; N2 cases had 1.9 times and N1 cases had 1.6 times hazard ratio (death risk) compared to N0 cases ($p = 0.018$).

Conclusions: Classification of nodal status in ampullary carcinomas based on the number of metastatic lymph nodes as < 3 vs ≥ 3 has significant prognostic value. A revised N-staging protocol ought to be incorporated into the TNM-staging of ampullary cancers in the next edition of AJCC/UICC.

666 Clinicopathologic Associations of Mismatch Repair Protein Expressions in Ampullary Carcinomas

S Balci, B Saka, A Krasinskas, G Kim, N Dursun, W Shaib, B El-Rayes, B Quigley, M Reid, AB Farris, S Bandopadhyay, R Everett, J Knight, V Adsay. Emory, Atlanta, GA; UCSF, SF, CA; WSU, Detroit, MI.

Background: The data on the clinicopathologic associations of microsatellite instability (MSI) in ampullary carcinomas (AC) is rather limited. There are also conflicting results, some presumably due to the prior imperfections in the performance & interpretation of these markers.

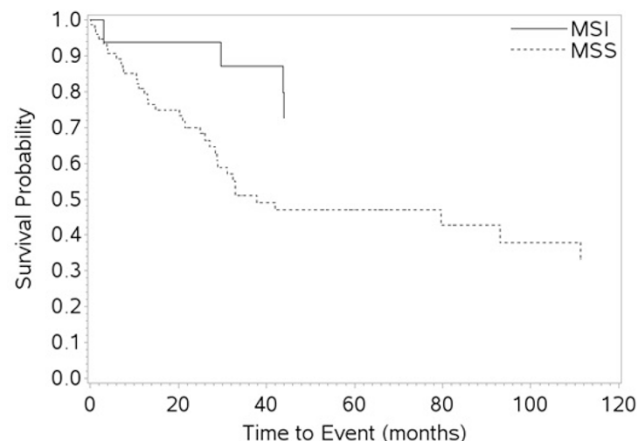
Design: MSI IHC was performed in 94 select ACs including tumor types known to be associated with MSI in the lower GI tract [8 medullary, 15 mucinous and 11 focal-mucinous ($< 50\%$ mucin)]. Pancreatic, CBD, non-ampullary duodenal carcinomas were carefully excluded.

Results: 18/94 (19%) of this select group of ACs showed MSI: MLH1 loss in 12, MSH2 in 3, MSH6 in 2, PMS2 in 15. 12 cases had combined MLH1/PMS2 loss, 2 MSH2/MSH6, 3 PMS2 only, 1 MSH2 only (found to be HNPCC by sequencing). Mean age of MSI cases was similar to microsatellite stable (MSS) cases (61 vs 63). However, there was striking male predominance in the MSI group (M/F: 16/2 vs 43/33; $p = 0.01$) and size of invasion was slightly larger (27.8 vs 21.3; $p = 0.06$). The frequency of MSI in different tumor types is listed in Table. Additionally, 14/18 had pushing-border infiltration, 4/18 plaque-like growth; 6/18 neutrophilic infiltrates (33% vs 17% in MSS, $p = 0.188$), 5/18 prominent eosinophils. MSI cases were less likely to show signs of aggressiveness such as LN metastasis (31 vs 59%, $p = 0.05$) or PNI (11 vs 46%, $p = 0.007$). LVI was also less common but not statistically significant (56 vs 68%; $p = 0.407$). More importantly, clinical outcome was significantly better: Median, 3- and 5-yr survival rates were 55 mos, 87% and 73 % in MSI group vs 25 mos, 51% and 47% in MSS group ($p = 0.02$).

MSI in Different Types

MSI in Different Types	MSI (%)
Medullary	7/8 (87)
Mucinous	0/15 (0)
Focal-Mucinous	6/11 (54)
Tubular-PB	3/18 (16)
Tubular-Intestinal	1/11 (9)
Tubular-Mixed	3/31 (10)

Kaplan-Meier Survival Curves



Conclusions: In the ampulla, MSI by IHC has striking predilection for men (88%) but no correlation with age. There is close association with medullary or pushing-border patterns, peritumoral inflammation (including neutrophils & eosinophils) and focal mucin production. Despite often presenting as relatively larger tumors and being "poorly differentiated" patterned, MSI cases have less tendency to show invasiveness (less LN mets, less PNI and LVI) and have significantly better prognosis.

667 Genomic Instability in Barrett's Esophagus and Disease Progression

TM Barr, SD Finkelstein, MA Styn, JF Silverman. Allegheny General Hospital, Pittsburgh, PA; RedPath Integrated Pathology, Inc, Pittsburgh, PA.

Background: Risk stratification of Barrett's Esophagus (BE) for progression to esophageal adenocarcinoma (EAC) relies on histological classification of dysplasia. Progression of BE is causally associated with accumulation of genomic instability, mutational change and clonal expansion of genetically unstable cells. We examined the presence and extent of genomic instability, assessed by cumulative mutational load (ML), in BE patients over time.

Design: BE patients were assessed over time (median interval=6 mo, range=2-38): 1) non-progressors with only BE/low-grade dysplasia (LGD) and 2) progressors showing BE/LGD and subsequent high-grade dysplasia (HGD)/EAC. Multiple microdissected targets were chosen based on histology for each biopsy slide. DNA from each target (N=33; n=11 (non-progressors), n=22 (progressors)) was blindly tested for loss of heterozygosity (LOH) and microsatellite instability (MSI) at 10 genomic loci near known tumor suppressor genes using a panel of 22 PCR-based microsatellite markers. The presence/quantitative extent of clonal expansion of LOH mutations were combined into an overall measure of ML to assess the presence/extent of genomic instability using weightings for low and high clonality and MSI.

Results: On average, ML was significantly higher in progressors than non-progressors (Table 1, $p = 0.03$); with a trend for increasing ML with more advanced histology. In addition, the average ML in cases of BE/LGD was higher for progressors (ML=1.6, n=7) than non-progressors (ML=1.0, n=3) prior to detection of HGD/EAC.

Conclusions: 1) Using quantitative LOH and MSI mutational results to assess ML provides an objective measure of the presence/extent of genomic instability in BE. 2) Patients with progressive disease generally have a higher ML than those without progressive disease, even prior to detection of HGD/EAC. 3) Assessment of ML in patients with BE may be a more sensitive marker for predicting progressive disease to complement histopathology evaluation prompting possible earlier intervention.

Mutational Load

Target Histology	Non-progressors (n=11)	Progressors (n=22)	All (N=33)
NORM (n=1)		0.8 (1)	0.8 (1)
BE (n=13)	0.3 (8)	0.7 (5)	0.5 (13)
LGD (n=7)	1.2 (3)	2.0 (4)	1.7 (7)
HGD (n=9)		1.9 (9)	1.9 (9)
EAC (n=3)		1.3 (3)	1.3 (3)
All (N=33)	0.6 (11)	1.5 (22)	

668 Differential Expression Patterns of IL-33 and ST2 in Ulcerative Colitis and Crohn's Disease

EM Bashover, W Xin, A Awadallah. University Hospitals Case Medical Center, Cleveland, OH.

Background: Though the precise etiology of inflammatory bowel disease (IBD) is still not fully understood, there is mounting evidence that imbalances between inflammatory mediators are a key feature in the pathogenesis of IBD. Distinguishing Ulcerative colitis (UC) and Crohn's disease (CD) is clinically important, but sometimes can be difficult. It has been shown that UC is associated with a Th2 pattern of inflammation, while CD

has a Th1 predominated inflammatory response. IL-33, a part of the IL-1 family, has been shown to induce production of Th2 associated cytokines IL-4, IL-5, and IL-13 in vivo. IL-33 mediates its effects via IL-1 receptor, ST2. In this study we would like to investigate whether the immunohistochemical (IHC) patterns of IL-33 and ST2 could help to differentiate UC from CD.

Design: A representative slide from colon resections of 6 normal (uninvolved areas of ischemic colon), 13 UC, and 19 CD cases were selected. IHC for IL-33 (Thermo Scientific Pierce, clone 12B3C4) and ST2 (R&D, polyclonal) at dilutions of 1:200 using a BondMax Automated Immunostainer (Leica) was performed at our hospitals' diagnostic lab. The percentage of deep crypt epithelial cells with nuclear staining were scored as follows; 0 = 0% staining, 1 = 1-24% staining, 2 = 25-49% staining, 3 = 50-89% staining, and 4 = 90-100% staining. Student t test was used for statistics.

Results: Strong diffuse nuclear staining of normal colon with IL-33 was seen, with a mean score of 4; both UC and CD had a partial loss of IL-33 expression in all cases, with a mean score of 2.62 and 2.37 respectively. For ST2 expression, normal colon had a mean staining score of 2.17, UC had a slightly decreased mean score of 1.38, and CD had a significantly decreased mean score of 0.59 ($p < 0.05$, t-test).

Mean IL-33 and ST2 IHC Score in Normal, UC, and CD Colon Samples			
Marker	Normal Colon	UC Colon	CD Colon
IL-33 (mean IHC score)	4	2.62 (P<0.01)*	2.37 (P<0.01)*(P=0.46)**
ST2 (mean IHC score)	2.17	1.38 (P=0.16)*	0.59 (P<0.01)*(P<0.05)**

Student t test: *UC or CD versus normal; **CD versus UC

Conclusions: Both UC and CD demonstrated an abnormal expression pattern of the inflammatory mediator IL-33 and its receptor ST2 compared to normal colon. IL-33 was significantly decreased in both UC and CD versus normal colon, while ST2 was only slightly decreased in UC and significantly decreased in CD. Our data supports different inflammatory pathways mediating UC and CD, showing that IL-33 and ST2 differential staining patterns can help separate IBD from non-IBD cases, as well as UC from CD.

669 HER2 Over-Expression Is Not Involved in Signet Ring Cell Carcinoma of Stomach: Single Institution Large Cohort Study

A Beattie, K Ma, H Li, J Liao, N Beaubier, SM Rao, G-Y Yang. Northwestern University, Chicago, IL.

Background: Over-expression of HER2 in gastric carcinoma ranges from 12-22% and correlates with poor prognosis. Trastuzumab (Herceptin) combined with other chemotherapeutic drugs is efficacious for treating metastatic HER2-positive gastric cancer. HER2 over-expression shows high correlation with the intestinal-type gastric carcinoma, but HER2 expression in signet ring cell carcinoma of stomach is not well characterized.

Design: Fifty-four cases of signet ring cell carcinoma and 9 cases of intestinal-type gastric carcinoma were retrieved from a single institution from 2008-2013. The patients' ages ranged from 38 years to 87 years, and the average age was 65 years. Among the 54 cases of signet ring carcinomas, 31 were males and 23 were females (M:F = 1.3:1). Among the 9 cases of intestinal-type gastric carcinomas, 4 were males and 5 were females (M:F = 0.8:1). The expression of HER2 was determined by immunohistochemistry on 5 um sections of paraffin embedded tissue. The CAP recommended scoring criteria were used for evaluating the expression of HER2. Additionally, tumor samples classified as immunohistochemistry 2+ were retested by fluorescence in situ hybridization (FISH) and scored using the recommendation from Ruschoff and colleagues. In addition, signet ring carcinomas were immunohistochemically analyzed for the expression of MUC2 and E-cadherin.

Results: Signet ring cell carcinoma of stomach showed absence of expression of HER2 in 96% (52/54) and 1+ expression of HER2 (score negative) in 4% (2/54) of cases. Intestinal-type gastric carcinoma showed 3+ over-expression (positive) of HER2 in 11% (1/9) cases. Among the signet ring carcinomas, 38% (13/34) displayed loss of E-cadherin expression. Additionally, expression of the goblet cell mucin MUC2, was identified in 44% (15/34) of signet ring cell carcinoma {5 cases were focally positive (15%), 10 cases were diffusely positive (29%) and 19 cases were negative (56%) for MUC2}. Intestinal-type gastric carcinoma showed strong positive staining for E-cadherin and MUC2.

Conclusions: Our single institutional large cohort study indicates that over-expression of HER2 is not involved in the signet ring cell carcinoma of stomach regardless of absence or presence of the goblet cell mucin MUC2 expression. As such, our study calls into question the utility of HER2 immunohistochemical testing in signet ring cell carcinoma of stomach. Our study confirms loss of E-cadherin is a common event and further genetic mutation analysis is warranted.

670 Submucosal Lipoma and Sessile Serrated Adenoma/Polyp, More Than Just a Coincidence?

A Bdeir, B Bhattacharya, P Parag. Miraca Life Sciences, Phoenix, AZ.

Background: In our practice we noticed that sessile serrated adenomas/polyps (SSA/P) were frequently associated with submucosal lipomas (SL). While this finding has been reported by other experts, it is unclear if this phenomenon represents anecdotal association between SSA/P and SL or a distinct form of an epithelial and mesenchymal interaction. The aim of this study was to examine the prevalence of SL in association with SSA/P.

Design: We searched our database for patients with the histologic diagnosis of SSA/P, including those with low and high grade cytological dysplasia. We included 357 consecutive cases diagnosed between January 2011 and July 2011. We reviewed the pathology reports and the H & E stained sections for each patient and collected the following data from the pathology report: age and gender of the patient, and the number, size and location of the SSA(s). The total number of SSA/P identified were 436, (cecum and ascending colon:249, transverse: 153 and left colon: 34). For control population, the database was searched for patients with the histologic diagnosis of

tubular adenoma (TA) diagnosed between January 2011 and July 2011. For each patient, the pathology report and the H & E stained sections were reviewed and the following data was collected from the report : age and gender of the patient, and the number, size, location and configuration (sessile vs pedunculated) of TA(s). We included 445 consecutive TA(s) that were sessile and larger than 8mm. (cecum and ascending colon: 250 transverse: 160 left colon:35). All the histological sections were evaluated for the presence of submucosal adipose tissue and assigned a score of 0 (no adipose tissue present), 1 (focal adipose tissue present without formation of a distinct lipoma), or 2 (a well circumscribed collection of adipose tissue replacing the normal submucosal structures). Only cases that were graded as 2 were considered positive for SL.

Results: SL was identified in 77 SSA/P obtained from 51 patients. The prevalence of SL in SSA/P (77/436, 17.7%) was higher than that seen with TA, (12/446, 2.7%) with $p < 0.0001$. Among patients with SSA/P, those with SL showed higher prevalence of multiple SSA (31/51, 60.7%) as compared to those that did not show SL (42/306, 13.7%) with $p < 0.0001$. They also had higher prevalence of cytological dysplasia (6/51, 11.8%) as compared to those that did not show SL (11/306, 3.6%) with $p = 0.0225$.

Conclusions: There is a high prevalence of SL with SSA/P. Additionally, patients with SSA/P and SL are more likely to have multiple SSA/P and SSA/P with cytological dysplasia.

671 A Clinicopathological and Molecular Appraisal of a Large Series of Traditional Serrated Adenomas

M Bettington, N Walker, I Brown, C Rosty, A Clouston, D McKeone, S-A Pearson, B Leggett, V Whitehall. QIMR Berghofer Medical Research Institute, Brisbane, Queensland, Australia; University of Queensland, Brisbane, Queensland, Australia; Envoi Pathologists, Brisbane, Queensland, Australia; Pathology Queensland, Brisbane, Queensland, Australia; Royal Brisbane and Women's Hospital, Brisbane, Queensland, Australia.

Background: The traditional serrated adenoma (TSA) is a precursor of the serrated neoplasia pathway and among the least common of colorectal polyps. The biology of the TSA remains unclear. Herein we provide detailed clinicopathological and molecular data on the largest series of TSAs so far reported.

Design: A total of 166 TSAs were collected retrospectively from Envoi Pathology and centrally reviewed using strict diagnostic criteria. All were assessed for the common *BRAF* and *KRAS* mutations and for the CpG island methylator phenotype (CIMP). A subset (52) have been tested for immunohistochemical markers, including MLH1 and B-catenin.

Results: The clinicopathological and molecular features of the TSAs are provided in table 1.

Table 1. Clinicopathological and Molecular Features of Traditional Serrated Adenomas

Mutation Status	Total number	Age	Female	Proximal location	CIMP-high	MLH1 loss	Nuclear B-catenin
<i>BRAF</i> mutant	106 (63.9)	65.8	54 (50.9)	43 (40.6)	69 (65.1)	0/29	1/29 (3.4)
<i>KRAS</i> mutant	36 (21.7)	64.9	20 (55.6)	1 (2.8)	6 (16.7)	0/23	4/23 (17.4)
Wild type	24 (14.5)	61.0	13 (54.2)	6 (25.0)	3 (12.5)	-	-

Number in parentheses indicate percentages

A component of SSA was present in 48 (45.3%) of the *BRAF* mutant TSAs but was never seen associated with *KRAS* mutant or wild type TSAs. IHC was performed on 29 *BRAF* mutant and 23 *KRAS* mutant TSAs, including 14 cases with either high-grade dysplasia (HGD) and/or early cancer. Nuclear B-catenin expression was present in 5 of these 14 cases (1/6 *BRAF* mutant and 4/8 *KRAS* mutant).

Conclusions: TSAs are a heterogeneous molecular group of polyps united by similar morphological appearances. The key division is between *BRAF* mutant and *KRAS* mutant/wild-type polyps. *BRAF* mutant TSAs are often proximal, frequently arise from SSAs and are mostly CIMP-H; *KRAS* mutant TSAs are mostly rectal, have no apparent precursor and are CIMP-low or negative. MLH1 staining was retained in all TSAs tested in this series, thus TSAs appear to give rise to microsatellite stable (MSS) carcinomas regardless of *BRAF* or *KRAS* status. As such, a subset are precursors of the aggressive *BRAF* mutant, MSS carcinomas. Strong wnt pathway activation appears rare in the *BRAF* mutant cancers, which is divergent from the majority of colorectal carcinoma.

672 Lgr5 Is Widely Expressed in the Human Gut and Overexpression Is a Biomarker of Colonic and Barrett's Esophagus-Related Dysplasia

JR Bledsoe, M Shahid, DT Ting, MN Rivera, OH Yilmaz, V Deshpande. Massachusetts General Hospital, Boston, MA.

Background: Leucine-rich repeat-containing G-protein-coupled receptor 5 (Lgr5) is a robust marker of intestinal stem cells and has been implicated as a cancer stem cell marker. Much of the data on the normal distribution of Lgr5 expression in humans is extrapolated from mouse studies, and little is known about Lgr5 expression in human neoplasia. To better define this distribution, we examined the expression of Lgr5 in a wide range of normal and neoplastic human tissues.

Design: Evaluation of Lgr5 expression was performed on tissue microarrays of 13 non-neoplastic gastrointestinal tissues from 65 people, as well as 37 cases of Barrett's esophagus (BE) with and without dysplasia, 12 colonic tubular adenomas, 10 sessile serrated adenomas, and 20 cases of pancreatic neoplasia. Expression of Lgr5 and the house keeping gene GAPDH was evaluated using a highly sensitive in situ hybridization assay based on branched DNA technology (QuantiGene® ViewRNA, Affymetrix, Santa Clara, CA). Quantitation of expression was performed by counting distinct Lgr5 mRNA foci (red dots) within the 200x200 uM field with the highest expression in each tissue core.

Results: Lgr5 expression in the non-neoplastic human gut was similar to prior murine findings, except that no expression was seen in the normal liver or pancreas. Compared to the corresponding normal colon (mean 100 red dots per 200x200uM field)

an expanded Lgr5+ population and increased Lgr5 expression was seen in colonic tubular adenomas (mean 2317 red dots; $p < 0.001$) and colitis-associated dysplasia but not sessile serrated adenomas. No expression was seen in the squamous esophagus or esophageal submucosal glands. An increase in Lgr5 expression was seen in BE with intestinal metaplasia (mean 89) compared to normal gastric cardiac mucosa (mean 2.2; $p < 0.001$). Furthermore, Lgr5 expression in BE with dysplasia (mean 375) was significantly higher than in BE without dysplasia ($p = 0.003$). Lgr5 expression was also present in pancreatic neoplasia.

Conclusions: Lgr5+ cells occupy a predictable niche in the human gastrointestinal tract. Our findings lend evidence to a potential origin of BE from the gastric cardiac glands at the squamocolumnar junction. Neoplastic lesions in the colon, esophagus, and pancreas consistently and significantly overexpress Lgr5 with a stepwise increase in expression along the metaplasia-dysplasia sequence, suggesting that Lgr5 plays a role in the pathogenesis of these lesions. These results have implications for the diagnosis and surveillance of gastrointestinal neoplasia and Lgr5-targeted chemoprevention in neoplasia.

673 BRAF V600E Immunohistochemistry Is Sensitive and Specific for Mutation Status in Colorectal Adenocarcinoma and Is Valid before and after (Neo)Adjuvant Therapy

JR Bledsoe, M Kamionek, M Mino-Kenudson. Massachusetts General Hospital, Boston, MA.

Background: BRAF mutation occurs in a range of human neoplasms including colorectal adenocarcinoma (CRC) and causes constitutive activation of the MAPK signaling pathway leading to oncogenesis. In CRC, BRAF mutation is associated with a worse prognosis and decreased responsiveness to EGFR inhibitor therapy. Therefore, BRAF mutation status is of great clinical interest. Immunohistochemistry (IHC) for mutant V600E BRAF is widely available but there are conflicting reports of its sensitivity and specificity, and little is known about its reliability in tissues post-chemo/radiation therapy.

Design: We performed IHC for mutant BRAF (clone: VE1, 1:100 [Spring Bioscience, Pleasanton, CA]) on tissue microarrays (TMAs) of 336 tissue cores from 164 cases of CRC. BRAF V600E mutation was present in 42 cases, as determined by PCR. Cases included tissues taken from primary (n=124) and metastatic (n=40) sites, and those collected before (n=109) and after (n=55) chemo/radiation therapy. Two TMAs (6 BRAF mutants and 33 non-BRAF mutants) were used as a validation cohort to establish the most specific staining pattern. The remaining TMAs were independently evaluated for BRAF staining (+/-) by pathologists at three levels of training (attending, fellow, and resident). In 11 cases, pre- and post-chemo/radiation therapy specimens from the same patient were examined.

Results: Consensus examination of the validation cohort revealed a specific staining pattern: diffuse cytoplasmic +/- membranous staining of tumor cells with uniform intensity (which varied from weak to strong). Non-specific nuclear staining occurred in a minority of BRAF mutants and, in the absence of the above criteria, was taken as negative. Averaged across all three observers, and including both pre- and post-treatment specimens, this pattern had: 94% sensitivity, 98% specificity, 95% PPV, and 98% NPV. There was 100% agreement between the 11 cases with pre- and post-treatment specimens. Fleiss' kappa for inter-observer agreement was 0.96. Pitfalls causing misinterpretation included: signet-ring cell morphology (false negative) and limited tissue for evaluation (false positive).

Conclusions: Evaluation of BRAF V600E IHC for a specific staining pattern (diffuse and uniform cytoplasmic) is highly sensitive and specific for BRAF mutation. This pattern is reliable in tissues both pre- and post-chemo/radiation therapy. Interpretation is highly concordant between pathologists at all stages of training. These findings support the use of IHC for primary evaluation of BRAF mutational status in CRC.

674 Clinicopathologic Features of GREM1-Associated Hereditary Mixed Polyposis Syndrome: A Review of 154 Polypectomies

KB Brown, B Heald, C Burke, J Church, M Kalady, TP Plesec. Cleveland Clinic, Cleveland, OH.

Background: Since first described in 1997, patients with hereditary mixed polyposis syndrome (HMPS) have been difficult to identify due to lack of well-established diagnostic criteria or known mutation. Recently, HMPS was found to be caused by a duplication on chromosome 15 spanning the 3' end of the SCG5 gene and a region upstream of the GREM1 locus. With specific genetic testing now available, we aim to further characterize clinicopathologic features of mutation-confirmed HMPS cases.

Design: We identified 7 patients with PCR-confirmed 40kb duplications on chromosome 15 spanning the 3' end of the SCG5 gene and the region upstream of the GREM1 locus. Clinical records and histology of all colorectal polyps removed at our institution (154 total) were reviewed for polyp type, presence/grade of dysplasia, and unique morphologic features.

Results: All patients were of Ashkenazi Jewish descent. Mean age at presentation, which was most often due to rectal bleeding or family history, was 30.8 years. One patient had a personal history of colon cancer. The patients had a mean of 24.1 polyps (range 7-63) with a mean of 3.8 polyps per colonoscopy (range 0-20). Mean intact polyp size ranged from 0.3 to 1.3 cm per patient. Polyp types (see table) included 65 tubular/tubulovillous adenomas (42%), 58 polyps with mixed features of hyperplastic and inflammatory polyps (38%), 20 hyperplastic polyps (13%), 7 inflammatory polyps (4.5%), and 4 polypoid mucosal prolapse (2.5%). One tubulovillous adenoma had inflammatory polyp-like areas. Ninety-five polyps (62%) displayed smooth muscle bundles within the lamina propria (prolapse-type changes). High-grade dysplasia or carcinoma was not present.

Histology of polyps in HMPS

Patient	Total polyps (# endoscopies)	Mean polyp size, cm (range)	Adenomas	Hyperplastic polyps	Inflammatory polyps	Hyperplastic/inflammatory polyps	Polyps with prolapse change
1	26 (5)	1.3 (0.3-5.7)	9	9	1	5	23
2	16 (8)	0.7 (0.2-1.9)	3	0	1	9	11
3	15 (3)	0.3 (0.1-0.7)	3	3	1	7	8
4	12 (6)	0.6 (0.2-1.0)	5	3	0	4	2
5	30 (6)	0.4 (0.2-0.7)	16	2	4	6	14
6	63 (11)	0.5 (0.1-1.8)	29	3	0	23	33
7	7 (2)	Unknown (0.2-0.4)	0	0	0	4	4

Conclusions: This cohort of GREM1-associated HMPS is characterized by oligopolyposis (7-63 polyps per patient) with small polyps that are predominantly adenomas or a fairly unique hybrid inflammatory/hyperplastic polyp. Prolapse-type changes with smooth muscle fibers in the lamina propria are quite common in both polyp types. These clinical and histologic features may help identify patients with GREM1-associated HMPS in the future.

675 Diagnostic Utility of p40 in Gastrointestinal Squamous Neoplasia

K Brown, I Gordon, X Liu, X Liu, D Allende. Cleveland Clinic, Cleveland, OH.

Background: With new targeted therapies available, it is increasingly important to identify squamous differentiation in poorly differentiated carcinomas in the gastrointestinal (GI) tract. Traditional markers of squamous differentiation include p63 and CK5/6. Recently, p40 has demonstrated superior specificity and sensitivity compared to p63 for squamous cell carcinomas (SCC) of the lung, and its use as a single marker has been proposed. We aim to compare the sensitivity and specificity of p40 to those of p63 and CK5/6 in squamous neoplasia of the GI tract.

Design: An electronic search was conducted to identify the study groups (SCC and adenosquamous carcinomas (ASCA), and poorly differentiated carcinomas (PDCA) of the GI tract) and control group of adenocarcinomas (AdCA). H&E stained slides were reviewed by a GI pathologist to confirm the diagnosis. Immunohistochemical (IHC) staining for p40, p63, and CK5/6 was performed in all cases; expression of each marker was assessed and scored from 0-5 based on the % of positively stained cells (0: 0%, 1: 1-5%, 2: 6-25%, 3: 26-50%, 4: 51-75%, 5: >75%).

Results: A total of 74 GI tumors (28 SCC, 2 ASCA, 20 PDCA, and 24 AdCA) were included and stained for the above markers. An IHC score ≥ 2 was defined as positive for each marker. p63 was positive in 100% of SCC/ASCAs (96.7% of cases with score 5) as opposed to 12.5% of AdCAs (8.3% with score 2, 4.2% with score 3). In contrast, p40 was positive in only 86.7% of SCC/ASCAs (63.3% of cases with score 5, 23.3% of cases with score 2-4) and 4.2% of AdCAs (1 case with score 2). CK5/6 was positive in 96.7% of SCC/ASCAs (86.7% of cases with score 5) and 20.9% of AdCAs (12.5% with score 2, 4.2% score 3, 4.2% score 4). Sensitivity, specificity, positive (PPV) and negative (NPV) predictive values are listed in Table 1. PDCA were p40 positive in 10% of cases (all cases with score 5), p63 positive in 35% of cases (15% with score 2, 5% score 3, 15% score 5) and CK 5/6 positive in 15% of cases (5% with score 3, 10% score 5).

Sensitivity, specificity, PPV, NPV of p40, p63, and CK5/6 for SCC/ASCA vs. AdCA

	Sensitivity (%)	Specificity (%)	PPV (%)	NPV (%)
p40	86.6	95.8	96.3	85.1
p63	100.0	87.5	90.9	100.0
CK5/6	96.6	79.1	85.2	95.0

Conclusions: p63 and CK5/6 are more sensitive than p40 for SCC/ASCA in the GI tract. p40 is superior to p63 and CK5/6 in specificity (but with more patchy staining pattern than p63), with CK5/6 being the least specific of the three. These findings support p63 as the best single marker, rather than p40 or CK5/6, for diagnosing SCC in the GI tract. The clinical significance of using these markers to help classify PDCA in the GI tract needs further study.

676 Implication of Leptin-Signaling Proteins and Epstein-Barr Virus in Gastric Carcinomas

S-J Byeon, E Choi, SH Kim, HJ Lee, HJ Kwon, WH Kim, MS Chang. Seoul National University Boramae Hospital, Seoul, Korea; Seoul National University College of Medicine, Seoul, Korea; Yeonsei University College of Medicine, Seoul, Korea; Soonchunhyang University Cheonan Hospital, Seoul, Korea.

Background: Leptin is a hormone produced by adipose tissue and its role was initially known to be in controlling food intake and energy balance. Recently, however, leptin and its receptor, and its signaling such as JAK/STAT, Raf/MER/ERK, PI3K/PEN/Akt/mTOR, and HIF-1 alpha pathways were revealed to be a potent regulator of carcinogenesis in various organs. In the present study, we investigated prognostic values in gastric carcinomas, in terms of leptin-related proteins and Epstein-Barr virus (EBV)-infection status.

Design: We evaluated leptin, leptin-receptor, pSTAT3, ERK, pAKT, mTOR and HIF-1 alpha using immunohistochemistry, and EBV-infection status using in situ hybridization for EBV-encoded small RNAs in 343 cases of gastric carcinomas.

Results: Immunorepressions of leptin and leptin-receptor were observed in 37% and 58% of gastric carcinomas, respectively. The group with leptin-receptor positive showed more frequent metastasis to lymph nodes and larger tumor size ($p < 0.05$). And leptin-receptor positivity was related with EBV-infection status ($p < 0.05$). Also, EBV was inversely correlated with mTOR ($p < 0.05$). The examined seven proteins showed positive relationships each other, except for the inverse correlation between leptin-receptor and ERK. As concerns patients' outcome (median follow-up: 77 months),

148 (43%) patients died among a total of 343, which included 10 (31%) decrease from 32 EBV-positive group. In total 343 patients, pTNM stage was an absolute prognostic factor ($p < 0.05$). Additionally, in 207 advanced gastric carcinomas, leptin-receptor immunopositivity was correlated with a poor survival of patients in univariate and multivariate analyses ($p < 0.05$). Furthermore, EBV-positivity in advanced gastric carcinomas tended to match a good survival of patients ($p = 0.06$). In 32 EBV-positive carcinomas, pAKT immunopositivity was related with a good survival of patients ($p < 0.05$), but lost a significance on multivariate analysis.

Conclusions: Leptin signaling-related proteins show different significances on patient's survival according to subsets of gastric carcinomas, and pTNM stage is the undisputed prognostic factor in any circumstance. Leptin-receptor and EBV-infection may predict patients' prognosis in advanced gastric carcinomas, and pAKT may function as a prognostic factor in EBV-positive gastric carcinomas.

677 Next Generation Sequencing and High Resolution Melting for Molecular Diagnosis in Gastrointestinal Stromal Tumors (GIST)

CI Caballero, R Gonzalez, J Freire, S Pereda, J Gomez-Roman. Hospital Universitario Marques de Valdecilla-IFIMAV, Santander, Cantabria, Spain.

Background: Gastrointestinal Stromal Tumors (GISTs) are the more common mesenchymal tumors of the gastrointestinal tract. Its treatment is based in surgery and targeted therapies based on molecular biomarker detection. However, there are no simple and validated methods for the analysis of mutations in KIT and PDGFRalpha genes in the routine diagnosis.

Design: 47 cases diagnosed of GIST in the service of Pathology of the University Hospital Marques de Valdecilla were found from 1996 to 2011. Eight cases were removed of the study because they do not have a good quality for molecular analysis. Two independent pathologists revised blindly the histology and immunohistochemistry that include CD117 and DOG1. Molecular analysis by High Resolution Melting (HRM) for exons 9, 11, 13 and 17 of KIT, and 12 and 18 of PDGFRalpha and by Massive Sequentiation (454 Roche Junior) for the entire genes including intronic regions, both of them developed in our laboratory were performed in all cases (39). A clinical chart revision with follow-up and treatment characteristics were made.

Results: By HRM, we found mutations in 25 cases (65%). Some of them were multiple in KIT and PDGFRalpha. By next generation sequencing, we found mutations in 18 cases (46%). Only one case showed a double mutation in exon 12 and 18 of PDGFRalpha. Two cases displayed mutations in KIT exon 11 intronic regions. Several recurrent polymorphisms with a high incidence were discovered in different regions.

		HRM	NGS
	Exon 9	3/39	3/39
KIT	Exon 11	14/39	10/39
	Exon 13	1/39	0
	Exon 17	1/39	0
PDGFRalpha	Exon 12	10/39	2/39
	Exon 18	3/39	3/39

Conclusions: We describe two new methods that show divergent results for GIST molecular diagnosis. HRM detects more mutations than Massive Sequentiation probably due to the intrinsic nature of mutations (deletions) in these kind of neoplasms. Several intronic mutations have been detected by Massive Sequentiation that should be carefully studied as well as polymorphisms with a high level of association to GIST.

678 miRNA Gene Profiling Sheds Light onto New Putative Tumorigenic Circuitry for Colorectal Cancer Metastases

L Casadei, S Costinean, V Balanti, L Cascione, CM Croce, WL Frankel. The Ohio State University, Columbus, OH.

Background: Colorectal cancer (CRC) is a worldwide problem, with an annual incidence of 1 million and an annual mortality of more than 500,000 patients. Many of these deaths are due to the lack of early diagnosis and widespread metastases at the time of presentation. Recent efforts have been focused on elucidating the molecular mechanisms of cancer metastasis. MicroRNAs (miRs) are a recently discovered type of non coding genes involved in posttranscriptional regulation that seem to be tissue and disease specific. Regulation of specific miRs could be responsible for the metastatic potential of a tumor. Knowing the mechanism of metastasis, could have prognostic and therapeutic applicability. Here we compare miR profiles of microsatellite stable CRC to corresponding lymph node metastases (LN).

Design: 40 right sided microsatellite stable (all 4 mismatch repair proteins expressed) CRC and 42 corresponding LN metastases were selected from the archives. RNA was analyzed using nanostring. RT-PCR with Taqman probes was used to confirm miR regulation.

Results: We found a specific signature in LN metastases vs. CRC and identified 12 deregulated miRs. 6 miRs were upregulated (miR150, miR142-3p, miR342-3p, miR195-5p, miR146-5p and miR4741) and 6 were downregulated (miR1, miR200a-3p, miR200b-3p, miR200c-3p, miR429, miR196b-5p). By RT-PCR, we confirmed regulation of the most significantly deregulated miRs: miR150-5p and miR200b-3p. In silico experiments showed miR150-5p to target TP53 and APC, genes involved in well-known tumorigenic mechanisms. Additionally, in silico studies showed miR200b-3p to target ZEB1 and ZEB2, which encode transcriptional repressors of E-cadherin.

Conclusions: We identified a specific miR signature in LN metastases vs. MSS CRC. In particular, deregulation of miR150-5p targets TP53 and APC which are involved in promotion of cancer cell proliferation. In addition, we confirmed downregulation of miR200-3p that may play a critical role in repression of E-cadherin by ZEB1 and ZEB2 during epithelial mesenchymal transition, enhancing migration and invasion during cancer progression. These miR signatures might suggest new targets to help decrease metastatic disease. Transfection of colon cancer cells to validate these targets for regulating miRs is ongoing.

679 Digital Images Versus Glass Slides: How Do They Compare in Gastrointestinal Pathology at All Levels of Training?

H Chen, T VandenBoom, S Al Duffalha, R Gamez, S Pambuccian, S Yong. Loyola University Medical Center, Maywood, IL.

Background: While virtual microscopy continues to gain increased acceptance, static digital images are still the most frequently used for teaching and consultation. Few studies were performed to compare the diagnostic accuracy by using digital images versus traditional glass slides. The aim of this study is to compare the performance of pathologists at different training levels interpreting digital images versus glass slides of gastrointestinal (GI) pathology entities.

Design: Forty common GI pathology entities were selected, including 10 benign neoplastic conditions, 10 malignancies, and 20 nonneoplastic conditions. A single representative H&E stained glass slide was chosen for both capturing digital images and for testing under light microscopy. Three digital images at 2x, 10x and 40x magnification were taken from each slide using a high resolution video camera (Nikon DS-L2 Ver 4.4). Pathologists at different training levels, including 3 at attending/fellow level, 5 at PGY IV, 3 at PGY III, 4 at PGY II and 4 at PGY I, participated in the two test sessions: digital and glass slide at one month apart. The data was collected and statically analyzed using 2x2 table Chi-square study and concordance analysis.

Results: 1. The diagnostic accuracy between using digital images versus glass slides showed fair agreement beyond chance ($\kappa=0.296$). 2. Similarly, no statistical differences were found for diagnosing the three disease categories. 3. Overall, the diagnostic accuracy was better achieved by using glass slides, compared to using digital images. 4. The best concordance between these two systems was observed in the highest training level. 5. Surprisingly, PGY I performed better when using glass slides; and the trend of achieving higher diagnostic accuracy using digital images is increased with the level of training.

Table 1. Concordance analysis of diagnostic performance with digital images versus glass slides at different pathology training levels.

	PGY I	PGY II	PGY III	PGY IV	Attending/fellow
Concordance	66.25%	63.13%	72.50%	76.50%	84.17%
Glass slides better than digital images	21.25%	17.50%	18.33%	14.00%	10.83%
Digital images better than glass slides	12.50%	19.38%	9.17%	9.50%	5.00%

Conclusions: 1. Performance in digital image-based diagnosis is increased with the level of pathology training. 2. Pathologist with lower level of training performed much better with glass slides, therefore, glass slides should be continuously used in education. 3. Our results positively support the increased trend of image-based pathology practice.

680 Small Bowel Inflammatory/Hyperplastic Polyps: Can Histology Differentiate Syndromic from Sporadic Cases?

D Chen, S-Y Xiao, M Dugum, B Horvath, X Liu. Cleveland Clinic, Cleveland, OH; University of Chicago, Chicago, IL.

Background: Small bowel inflammatory/hyperplastic polyps occur either in patients with a polyposis syndrome or sporadically. However, comparison of histologic features of polyps between these two settings has not been previously reported. In this study, we aim to compare the histology of syndromic to sporadic inflammatory/hyperplastic polyps of the small bowel.

Design: Nine small bowel polyps from 5 juvenile polyposis syndrome patients and 1 Cowden disease patient, 1 hyperplastic polyp from a MYH-associated polyposis patient, and 1 inflammatory polyp from a familial adenomatous polyposis patient were included. All cases were genetically confirmed. Twenty-six sporadic small bowel inflammatory/hyperplastic polyps were used as controls. The number and location of polyps were retrieved from endoscopic reports. Presence of pure intestinal epithelium, hyperplasia, cystic dilation of glands (CDG), stromal overgrowth, stromal edema, acute inflammation, chronic inflammation, prominent vessels, erosion, and Brunner's gland hyperplasia were recorded for each polyp. Student's *t*-test and Chi-square analysis were used to compare these features between the two groups.

Results: Patients with syndromic small bowel polyps were younger (48 vs. 63 yrs, $p=0.007$) and 37.5% of them were male (vs. 50%, $p=0.06$). Syndromic polyps were less likely to be located in the duodenal bulb (18.2% vs. 57.7%, $p=0.03$). Multiplicity of polyps was seen in 75% of syndromic patients (vs. 42.6%, $p=0.23$). Interestingly, the syndromic polyps more often were of pure intestinal type (45.4% vs. 4%, $p=0.005$) and had prominent vessels (81.8% vs. 42.3%, $p=0.04$). Other examined features showed no statistically significant differences between the two groups (Table 1).

Conclusions: Syndromic and sporadic small bowel inflammatory/hyperplastic polyps have many overlapping histologic features. Attention to polyp location, epithelial composition, and vasculature may help predict the syndromic status of patients.

Table 1. Frequency of histologic features in small bowel inflammatory/hyperplastic polyps.

	Pure intestinal type	Hyperplasia	CDG	Stromal overgrowth	Stromal edema	Chronic inflammation	Prominent vessels
Syndromic (%)	45.4	72.3	36.4	45.5	36.4	90.9	81.8
Sporadic (%)	4	84.5	42.3	50	30.8	88.5	42.3
P-value	0.005	0.3	1	1	1	1	0.04

681 Clinical and Demographic Clues to Syndromic Inflammatory/Hyperplastic Small Bowel Polyps

D Chen, S-Y Xiao, M Dugum, B Horvath, X Liu. Cleveland Clinic, Cleveland, OH; University of Chicago, Chicago, IL.

Background: Inflammatory/hyperplastic small bowel polyps (SBPs) occur either in patients with a polyposis syndrome or sporadically. Histologic features of polyps between these two settings show significant overlap, at least in the colon and stomach.

In this study, we aim to identify clinical and demographic factors associated with inflammatory/hyperplastic SBPs to improve detection of polyposis syndromes.

Design: Nine patients with genetically confirmed polyposis syndromes (6 juvenile polyposis, 1 Cowden disease, 1 *MYH*-associated polyposis, and 1 familial adenomatous polyposis) who had hyperplastic/inflammatory SBPs were included. Twenty-eight patients with sporadic inflammatory or hyperplastic SBPs were used as controls. Demographics (age and gender), presence of hemorrhagic telangiectasia, presence of gastric polyps, reflux, use of medications (NSAIDs and anti-reflux agents), presence of anemia, personal cancer history, family history of colon cancer, and family history of stomach cancer were recorded. Student's *t*-test and Chi-square analysis were used to compare these features between the two groups.

Results: Patients with syndromic inflammatory/hyperplastic SBPs were younger (48 vs. 63 yrs, $p=0.007$). Syndromic patients had higher rates of hemorrhagic telangiectasia (44.4% vs. 0%, $p=0.002$), gastric polyps (87.5% vs. 21.8%, $p=0.0006$), and family history of colon cancer (62.5% vs. 11.1%, $p=0.013$). Meanwhile, sporadic cases were more frequently associated with reflux (35.7% vs. 0%, $p=0.08$) and anti-reflux medication use (55.5% vs. 11.1%, $p=0.049$). Other examined features including male gender (33.3% vs. 53.6%), NSAIDs use (11.1% vs. 29.6%), anemia (33.3% vs. 50%), personal cancer history (22.2% vs. 11.1%), and family history of stomach cancer (12.5% vs. 5.5%) showed no statistically significant differences between syndromic patients and patients with sporadic inflammatory/hyperplastic SBPs.

Conclusions: While syndromic and sporadic small bowel polyps demonstrate morphologic overlap, patients with syndromic SBPs tend to be younger, are less likely taking anti-reflux medication, and have higher rates of hemorrhagic telangiectasia, gastric polyps, and family history of colon cancer. Attention to these clinical and demographic clues helps triage inflammatory/hyperplastic SBPs for the possibility of polyposis syndromes.

682 Frequent Heterogeneity of HER2 Amplification in Colorectal Carcinoma

M Chevarie-Davis, K Baden, P Fournier, MC Magat, E Thorpe, J Lopategui. Cedars-Sinai Medical Center, Los Angeles, CA.

Background: The use of anti-HER2/neu receptor monoclonal antibodies has had a major impact on the treatment of breast and gastric cancers with HER2 amplification. Although there has been some suggestion of HER2 amplification in other cancer types as well, the data is still incomplete. A limited number of studies on colorectal carcinoma (CRC) have begun to reveal HER2 amplification, although the prevalence has been variable, ranging from a few percent to 50%. These discrepancies may be attributed to a variety of factors, including methodology and tumor selection. In addition, we hypothesize that tumor heterogeneity in HER2 amplification can play a significant role. In this study, we aimed to assess the prevalence of HER2 amplification in CRC, with a particular emphasis on tumor heterogeneity, to ultimately guide therapeutic decision-making.

Design: A total of 10 metastatic and 10 non-metastatic cases of colorectal carcinoma resected in our institution were selected at random from within our archives. Fluorescent in situ hybridization (FISH) for the detection of HER2 gene amplification was performed on one representative tumor block per case, according to our routine protocol. The ratio of HER2 signals to CEP17 signals was noted for 20 individual cells, and the average ratio was calculated. The gene was considered amplified if the ratio reached 2.2 or more, and equivocal if between 1.8 and 2.2. HER2 heterogeneity was defined as 5-50% cells with a ratio of above 2.2, but an average ratio below 1.8. HER2 amplification was correlated with tumor characteristics.

Results: A total of 19 cases were evaluated, as one FISH test could not be interpreted due to technical failure. Four cases (21%) had between 1 and 4 individual cells displaying HER2 amplification, with individual cell ratios ranging from 2.3 to 6, but an overall ratio below 1.8. In addition, 1 case (5%) was considered amplified based on the 20 cell average, with a ratio of 16.7. Although it seems that HER2 amplification may be more frequent in metastatic tumors, with 4/5 cases belonging to this group, this difference did not reach statistical significance. There was no association between HER2 amplification and tumor location, micro-satellite instability, histologic differentiation, KRAS mutational status or BRAF mutational status.

Conclusions: We identified conventional HER2 amplification in 5% of our CRC cases and heterogeneous amplification in an additional 21%. The clinical significance of heterogeneous amplification remains to be examined. Nonetheless, HER2 may be a valuable target in CRC treatment, and heterogeneous amplification warrants careful evaluation.

683 The Utility of Peripherin Versus MAP-2 and Calretinin in the Evaluation of Hirschsprung Disease

KM Chisholm, TA Longacre. Stanford University School of Medicine, Stanford, CA.

Background: Hirschsprung disease (HSCR) is a congenital malformation resulting from the lack of migration of ganglion cells in the colon. The absence of ganglion cells in rectal suction biopsies aids in diagnosis. However, identifying ganglion cells in these small biopsies can be difficult and a variety of special stains has been suggested for use in frozen and formalin-fixed paraffin embedded (FFPE) colon biopsies. In this study, we compare the performance of microtubule associated protein-2 (MAP-2) antibody, Calretinin, and Peripherin. Peripherin is a marker for peripheral neurons, including enteric ganglion cells.

Design: The pathology database was searched using the terms "Hirschsprung disease" and "ganglion cells" between 1/1999 and 6/2008. A total of 78 biopsies from 53 cases/patients had diagnoses of "ganglion cells identified", while 83 biopsies from 41 cases/38 patients had diagnoses of "no ganglion cells identified". In addition, 82 biopsies which were equivocal for ganglion cells were identified, representing 59 cases/52 patients.

Selected slides from the original slide series for each biopsy were decoverslipped, destained, and stained for the immunohistochemical antibodies MAP-2, Calretinin, and Peripherin.

Results: MAP-2 specifically highlighted ganglion cells without labeling other neural elements, while Calretinin highlighted nerve fibers and ganglion cells, and Peripherin highlighted ganglion cells and neural elements (band-like pattern). Of 78 biopsies with ganglion cells identified on H&E, MAP-2 was positive in 73 (94%), Calretinin in 76 (97%), and Peripherin in 78 (100%). Of 83 biopsies with no ganglion cells identified on H&E, Calretinin and Peripherin highlighted ganglion cells in 3 biopsies, all from non-HSCR patients, while MAP-2 was positive in only one of these 3 biopsies. Of the 82 biopsies equivocal for ganglion cells, 16 cases were positive by all three stains, 1 case by Calretinin and Peripherin, and 2 cases by Peripherin only. All of the newly positive cases were from non-HSCR patients. Many equivocal cases lacked submucosa.

Conclusions: While MAP-2 specifically and only highlights ganglion cells, Calretinin highlights small nerve fibers, and Peripherin differentially highlights all neural elements. Peripherin highlights ganglion cells in all cases with ganglion cells, whereas MAP-2 and Calretinin are less sensitive for identification of ganglion cells: These data suggest that Peripherin is superior to MAP2 and Calretinin. Peripherin should be included in the HSCR panel for FFPE colon biopsies.

684 Unexpected TTF-1 Positivity in a Subset of Gastric Adenocarcinomas

S Choi, EE Furth, PJ Zhang. Hospital of the University of Pennsylvania, Philadelphia, PA.

Background: Thyroid transcription factor-1 (TTF-1) is normally expressed in lung and thyroid and is commonly used as a marker for tumor of lung or thyroid origin. However, TTF-1 positivity has occasionally been observed in carcinomas of other sites. We have recently observed TTF-1 reactivity in an unequivocal gastric adenocarcinoma (GA), which has not been reported thus far. We were prompted to study TTF-1 positivity in a cohort of GA.

Design: 75 GA from 2009-2013 were chosen. TTF-1 expression was evaluated immunohistochemically on paraffin section with the SPT24 clone on Bond III autostainer. TTF-1 nuclear staining was evaluated for intensity and quantity of positivity. When present, non-neoplastic and dysplastic epithelium was also evaluated for TTF-1 expression.

Results: TTF-1 was positive in 24% of GA (n=75). TTF-1 reactivity was detected in 46% of antral GA (n=13) and 23% of GE junction GA (n=31). Among TTF-1+ cases (n=18), intensity varied from weak to strong, and the quantity ranged from <33% up to 66% of tumor cells showing positive staining. TTF-1 reactivity was seen in both resection and biopsy specimens. 85% of TTF-1+ cases were moderately differentiated compared with 62% of TTF-1 negative cases. Two of these cases also showed TTF-1 positivity in adjacent high grade dysplasia. Surprisingly, five cases also demonstrated bright TTF-1 positivity within focal benign-appearing glands, particularly in association with the presence of chronic inflammation. In three of these cases with TTF-1+ benign glands, the tumor itself was negative for TTF-1. Lastly, one case with a lymph node metastasis demonstrated positivity in both the metastasis and primary tumor.

Conclusions: Overall 24% of GA demonstrate TTF-1 positivity. A higher percentage of antral GA (46%) shows TTF-1 positivity than GE junction GA (23%). This finding suggests possible site dependence in TTF1 expression. TTF-1 could also be detected in a GA metastatic lesion. GA should be added to the list of tumors with TTF-1 reactivity and caution should be exercised in using TTF-1 immunohistochemistry in evaluating tumor of unknown primaries. Furthermore, TTF-1 positivity in benign appearing, chronically inflamed gastric glands is interesting. It is unclear if this represents a reactive or potentially an early or pre-dysplastic phenomenon. Further investigation is warranted.

685 Serrated Lesions of the Appendix: Immunohistochemical and Molecular Analysis

EK Choi, M Divatia, H Takei. Houston Methodist Hospital, Houston, TX; Weill Cornell Medical College of Cornell University, Houston, TX.

Background: Right-sided sessile serrated adenomas/polyps (SSA/P) have been extensively studied due to their association with defective DNA mismatch repair gene and microsatellite instability. SSA/P are usually diagnosed incidentally in appendectomy specimens. Although appendiceal and colorectal mucosal surfaces are histologically similar, appendiceal mucosa is composed of cells with differing functions. Unlike colonic SSA/P, appendiceal SSA/P have not been extensively studied. This study comprehensively analyzes gene mutations with matrix-assisted laser desorption/ionization-time-of-flight mass spectrometer (MALDI-TOF; Sequenom Inc., San Diego, CA, USA) and loss of MLH1 protein by immunohistochemistry (IHC) in a series of appendiceal SSA/P cases.

Design: 11 appendiceal SSA/P were screened with MALDI-TOF mass spectrometry for 238 somatic mutations across 19 common oncogenes. A positive result for MLH1 IHC was defined as a loss of nuclear staining in the epithelium of SSA/P. The result was interpreted as complete (diffuse loss in all areas), incomplete (preserved staining in the deep crypt region and loss in remaining areas) or no loss of expression.

Results: 6 SSA/P showed *KRAS* gene mutations (55%), one SSA/P had *MET* gene mutation (9%), and one SSA/P had *BRAF* gene mutation (9%). 7 cases showed no loss of MLH1 protein (64%) and 4 cases showed incomplete loss (36%). Complete loss of MLH1 protein was not observed. One case each with incomplete MLH1 loss had *KRAS* and *BRAF* mutations.

Conclusions: Appendiceal SSA/P showed similar mutations as seen in colonic SSA/P. We observed *MET* gene mutation, which is uncommon in colonic SSA/P and adenocarcinoma. Our small size study does not establish a definite association between serrated neoplastic lesions and *KRAS/BRAF* mutations, but opens a wider gateway for DNA sequencing studies to identify biological changes for tumorigenesis.

686 Utility of IMP3 in the Assessment of Dysplasia in the Patients with Inflammatory Bowel Disease

S Chopra, M Guindi, D Dhall. Cedars-Sinai Medical Center, Los Angeles, CA.

Background: Long standing inflammatory bowel disease (IBD) is associated with increased risk of dysplasia and colorectal cancer. Surveillance endoscopy is performed to identify dysplastic precursor lesions via endoscopic biopsy. Prophylactic colectomy is the procedure of choice when high grade/low grade dysplasia is associated with a mass and when low grade dysplasia is found in the flat mucosa. Thus it is critical to diagnose dysplasia correctly. IMP3 is an oncofetal protein that affects cellular proliferation, adhesion, and invasion of malignant neoplasms. It is overexpressed in a number of fetal tissues and malignant tumors. The present study is undertaken to examine the staining pattern of IMP3 in carcinoma (CA), high grade dysplasia (HGD) and low grade dysplasia (LGD) in the setting of IBD, and to evaluate its utility as an ancillary tool in the diagnosis and grading of dysplasia.

Design: Patients with the diagnosis of CA, HGD, and LGD in the setting of IBD were identified from the pathology database. Cases of severe IBD were used as controls. Tissue blocks of 11 HGD/CA (7 resection specimens and 4 biopsies) from 9 patients, 17 LGD (2 resections and 15 biopsies) from 14 patients, and 18 severe IBD with reactive epithelial changes (2 resections and 16 biopsies) from 11 patients were stained with IMP3.

Results: In the HGD/CA group, there were 6 males and 3 females, mean age 39 yrs; 5 had ulcerative colitis (UC), 2 had Crohn's (CD), and 2 indeterminate (IND). In the LGD group, there were 3 females and 11 males, mean age 63 yrs; eight patients had UC, 5 had CD and 1 IND. Among the severe IBD control cases, 4 patients were females and 7 were males, mean age 53 yrs; 6 patients had UC, 3 had CD, and 2 were IND. All the HGD/CA cases showed diffuse moderate to strong positivity for IMP3 (100%). Only 7 of 17 (41%) LGD showed moderate to strong staining for IMP3; Four showed focal positivity (5%). The two resection cases with multifocal low grade dysplasia lesions were negative for IMP3. Of the 18 reactive cases, 4 (22%) demonstrated focal moderate positivity and 3 (17%) had weak positivity.

Conclusions: 1) Diffuse strong positivity for IMP3 may be helpful in supporting the diagnosis of HGD

2) Caution is necessary when interpreting focal staining for IMP3 as it can be positive in reactive epithelium

3) Negative staining for IMP3 would argue against the diagnosis of HGD as all cases of HGD dysplasia were positive for IMP3

4) IMP3 negativity does not rule out low grade dysplasia as only 46% of LGD were positive for IMP3.

687 Epidemiologic and Pathologic Risk Factors for Nodal Metastases in Early Esophageal Adenocarcinoma: Bayesian Regression Analysis

NA Ciomek, AD Polydorides, N Harpaz, DE Henson, AM Schwartz. Icahn School of Medicine at Mount Sinai, New York, NY; George Washington University Cancer Institute, Washington, DC; George Washington University, Washington, DC.

Background: Upper endoscopy is increasingly identifying early invasive esophageal adenocarcinomas that may be at risk for lymph node metastases, an important prognostic factor in management. However, the epidemiologic and pathologic risk factors for nodal spread need to be identified and quantified. The generation of an odds ratio (T1N1/T1N0) and the use of Bayesian analysis can estimate the probability of T1N1 given a spectrum of epidemiologic and pathologic risk factors.

Design: Data were retrieved using the NCI SEER Program from 1988-2005. Extent of disease codes from 1988-2003 were used to assess T1 invasion and positive or negative lymph node involvement (N1 and N0, respectively). A Bayesian analysis was used to calculate the odds ratio of T1N1/T1N0 according to age cohorts, sex, racial/ethnic group, histologic grade, and location. Our surgical pathology material was reviewed to determine concordance of pathologic factors. Mucosal vs. submucosal invasion and size data are not available in SEER.

Results: The overall T1N1/T1N0 ratio was 0.36 among 2596 cases in the SEER registry and was similar for men and women (6:1 predominance of T1 tumors among men). The ratio for individuals younger than 45 was nearly 3-fold higher than the ratio for those older than 65. The ratios for low-grade tumors (well and moderately differentiated) and high-grade tumors (poorly differentiated) was 0.25 and 0.5, respectively. In our 64 resection specimens, the overall T1N1/T1N0 ratio was 0.1 and was slightly higher in women (8:1 predominance of T1 cases among men). The ratios for low-grade and high-grade tumors were 0.1 and 0.13, respectively, confirming the SEER registry trend. The T1N1/T1N0 ratio for tumors with submucosal invasion (T1b) was more than 4 times that of intramucosal tumors (T1a). Using a size cutoff of 2.5 cm, the ratio for larger tumors (0.36) was more than 7 times that of small tumors (0.05).

Conclusions: Using the odds of prognostic variables (age, sex, histologic type), a combined risk for nodal metastases can be assessed for esophageal adenocarcinoma. The rate ratio overlaps between men and women but is increased in the youngest age cohort and higher grade tumors. Our surgical pathology data indicates that predictors of the highest probability for nodal positivity among T1 esophageal adenocarcinomas include high histologic grade as in SEER, but also size more than 2.5 cm and submucosal invasion.

688 Anal and Perianal Squamous Intraepithelial Lesions (SIL): Histology, p53/p16 Biomarkers and Association with Carcinogenic HPV Types

O Clavero, VN Pimenoff, JM Godinez, V Marco Molina, M Felez Sanchez-Ocana, JE Klausmeier, B Quiros Blasco, IG Bravo, X Bosch, J McCloskey. Unitat d'Infeccions i Càncer, L'Hospitalet de Llobregat, Barcelona, Spain; Royal Perth Hospital, Perth, WA, Australia; Hospital Quirón Barcelona, Barcelona, Spain.

Background: The Lower Anogenital Squamous Terminology (LAST) project recommends a 2-tier system with anal low-grade SIL (LSIL) and high-grade SIL (HSIL). The use of immunohistochemical markers is recommended in selected situations, among which are the coexistence of LSIL and HSIL, and cases with difficulty in the differential diagnosis including squamous metaplasia. This study reports our experience using LAST, and its correlation with detected Human Papillomavirus (HPV) genotypes.

Design: Seventy-three anal or perianal biopsies from patients who had surgery for anogenital warts with a prior diagnosis of SIL or equivalent were classified according to LAST. In addition, biopsies were classified according to their overall lesion architecture either as flat or condylomatous. In 18 HSIL cases immunostaining for p16 and p53 antigens were performed. 25 different HPV types detection and genotyping was performed using SPF10 PCR, and LiPA reverse hybridization line probe assay.

Results: From 18 HSIL cases, 12 (66.6%) were flat and four (22.2%) were condylomatous lesions. Two HSIL biopsies (11.1%) showed focal LSIL, with both flat and condylomatous pattern. LSIL classified biopsies (N=55) were mostly condylomatous (96.4%, N=53) with only two cases (3.6%) showing flat pattern. Immunohistochemical staining among the HSIL biopsies showed a correlation with the morphological categories: all of the flat HSIL lesions (N=12) were p53 negative and also 91.7% of these lesions were p16 positive. The condylomatous HSIL biopsies were mostly p53 positive (75%) and p16 negative (75%), with only one case being p16 positive. Furthermore, among the flat anal HSIL biopsies a total of ten different HPV types were detected, all classified as carcinogenic. In contrast, mostly non-carcinogenic HPV's (6 and 11) were detected among the condylomatous HSIL biopsies.

Conclusions: Our results showed a good correlation between histological diagnosis and lesional architecture with p16 and p53 biomarkers. More importantly, carcinogenic HPV types were associated with flat anal or perianal HSIL lesions.

689 Eosinophilic Esophagitis – An IgG4-Related Disease with Serum IgG4 Food-Specific Antibodies

F Clayton, LA Vinson, KA Peterson. University of Utah, Salt Lake City, UT.

Background: Eosinophilic esophagitis (EoE) is generally triggered by foods, but the mechanism is unclear. Some features suggest an allergy, but the evidence is conflicting. Since IgG4 is implicated in a variety of similar fibrotic, allergic-like, and autoimmune disorders, we examined IgG4 production, content, and reactivity in EoE.

Design: We studied an esophagectomy from an EoE patient who also had a gastroesophageal junction adenocarcinoma. We did IgG4 indirect immunofluorescent and immunoperoxidase staining of paraffin sections of biopsies from the 11 EoE subjects and 8 normal controls and from the esophagectomy. To quantify tissue immunoglobulins by class/subclass, Luminex assays on unfixed esophageal biopsy homogenates from these same subjects were done. To quantify total serum IgG4 and serum IgG4 antibodies to the 6 foods most commonly triggering EoE (wheat, milk, egg, soy, nuts, and fish/shellfish), we developed IgG4 ELISA assays. Sera from 11 EoE subjects and 27 healthy controls (no gastrointestinal or autoimmune disorders and no allergies) were studied.

Results: Esophagectomy: The esophagectomy subject was a 68-year-old male who had a 20-year history of dysphagia and up to 127 eosinophils/hpf by biopsy while on maximal dose proton pump inhibitors. The esophagectomy had mucosal fibrosis and a plasma cell-rich infiltrate in the deep mucosa and superficial muscularis mucosae. There were up to 300 IgG4 plasma cells/hpf. Esophageal biopsies: EoE esophageal biopsy homogenates had a 45-fold increase in IgG4 content relative to controls ($p < 3 \times 10^{-5}$), with only 1.4 to 2.4-fold increases in IgM, IgA, and other IgG subclasses. Granular intercellular IgG4 staining, often abundant, was seen in 91% of EoE subjects versus 12% of controls ($p = 0.001$). Serum IgG4: Total serum IgG4 was increased 3.2-fold in EoE ($p < 0.001$), although only 2 of 11 had serum IgG4 content $> 1,400 \mu\text{g/ml}$ (the IgG4-related disease criterion). Increased IgG4 antibodies to the six common EoE trigger foods were present ($p \leq 0.03$ for each), with an 109-fold increase in anti-wheat antibodies ($p < 1 \times 10^{-6}$). Increased IgG4 antibodies ($> 2 \mu\text{g/ml}$) to one or more foods were present in 10 of 11 EoE subjects and 5 of 27 controls (91% versus 19%, $p = 6 \times 10^{-2}$).

Conclusions: EoE has strikingly increased esophageal mucosal IgG4 content and high levels of serum IgG4 antibody reactivity to common trigger foods. These findings, together with the failure of anti-IgE (omalizumab) therapy to resolve esophagitis, implicate food-reactive IgG4 in the possible pathogenesis of EoE.

690 Lymphocytic Esophagitis in Barrett's Esophagus: Correlation with Patient Symptoms and Risk Factors

JR Conner, CA Sanchez, BJ Reid, TL Vaughan, PL Blount, HH Wang, RD Odze, A Srivastava. Brigham and Women's Hospital and Harvard Medical School, Boston, MA; Fred Hutchinson Cancer Center and University of Washington, Seattle, WA; Beth-Israel Deaconess Hospital and Harvard Medical School, Boston, MA.

Background: Lymphocytic esophagitis (LE) is a recently described entity with poorly defined etiologic risk factors. The clinical significance of LE in patients with Barrett's esophagus (BE) is poorly understood. The aim of this study was to evaluate the clinical, pathologic, and endoscopic features of LE in a well characterized cohort of patients with BE.

Design: Biopsies of squamous mucosa from 183 patients in a long-term BE surveillance program were evaluated. 145 (79%) patients were on PPIs at the time of biopsy. Biopsies were categorized as positive or negative for LE based on the presence of

dense peripapillary lymphocytic infiltrates (≥ 12 lymphocytes per hpf) and spongiosis, in the absence of eosinophilic or neutrophilic infiltration. LE was also graded as low (12-29 lymphocytes per hpf) or high-grade (≥ 30 lymphocytes per hpf). Clinical, endoscopic, and demographic data, including age, race, smoking and alcohol intake history, BMI, waist circumference, heartburn and reflux symptoms, presence of hiatal hernia, and medication history were retrieved from a prospectively collected database. Correlations were performed using a three-way ANOVA for continuous and a χ^2 analysis for categorical variables.

Results: 24/183 (13.1%) patients had LE [12 (6.6%) low-grade and 12 (6.6%) high-grade]. Seven (58%) patients with high-grade LE reported at least once daily reflux at the time of biopsy, compared to one (9%) patient with low-grade LE and 17 (11%) without LE ($\chi^2=21.6$, $p<0.0001$). The frequency of current smoking, in each group, was 33%, 8%, and 6.9% respectively ($\chi^2=9.76$, $p=0.008$) and the mean numbers of alcoholic beverages per week were 49, 21, and 16 [$F(2,170)=3.56$, $p=0.031$]. Patients with LE were significantly more likely to have had an ulcer at some point during surveillance (62.5% with and 25.6% of patients without LE; $\chi^2=13.4$, $p=0.0003$). No correlation was noted between the presence or degree of LE and any other clinical or pathologic variable analyzed. A multivariate logistic regression analysis including reflux and heartburn frequency, current smoking, and number of alcoholic drinks per week revealed a significant independent correlation only between daily reflux and high-grade LE ($p=0.02$).

Conclusions: These findings suggest that LE, in patients with BE, is a marker of ongoing severe reflux related mucosal injury.

691 MiR Profiling of Microsatellite Unstable Colorectal Cancer and SSA Reveals Intriguing New Tumorigenic Pathways

S Costinean, L Casadei, V Balatti, L Cascione, CM Croce, WL Frankel. The Ohio State University, Columbus, OH.

Background: Sporadic microsatellite unstable (MSI) colorectal cancer (CRC) can develop through the serrated pathway with hypermethylation of the *MLH1* promoter and frequent *BRAF* mutation. Sessile serrated adenomas (SSA) are thought to progress through SSA with dysplasia (SSA-D) to MSI CRC. It has been shown that APC, MSH3, and MSH6 are frequently mutated in MSI CRC (Nature, 2012). MicroRNAs (miRs) are involved in the posttranscriptional regulation. Here, we investigate the miR deregulation in MSI CRC and precursors to identify specific signatures and investigate novel tumorigenic pathways.

Design: To investigate the MSI serrated pathway, 16 SSA, 8 SSA-D and 22 MSI CRC were selected. MSI CRCs were identified by MLH1 and PMS2 immunostain absence together with *BRAF* mutation. RNA was analyzed with Nanostring. RT-PCR validated the results.

Results: Comparing MSI CRC to SSA and SSA-D, 68 miRs were differentially expressed. For SSA to CRC, 32 genes were up and 36 down. For SSA-D vs CRC, 33 were up and 35 down. SSA-D and SSA were similar with only 14 miRs differentially expressed of which 10 down (miR199a and b-5p, miR125b-5p, etc) and 4 up (miR203, miR183-5p, miR135b-5p and miR621). We confirmed by RT-PCR the downregulation of miR199a and b-5p. In silico studies showed that these miRs target APC and KRAS. miR125b-5p downregulation was validated, and in silico studies showed it targets APC, KRAS and p53. Interestingly, miR199a and b-5p, miR181c-5p and miR125b-5p were validated as up and not down in MSI CRC vs. SSA-D. For SSA vs. MSI CRC, miR1246 upregulation was validated. In silico showed miR1246 could target nucleoporin 50 and CAV1.

Conclusions: MiR profiles show that each lesion is characterized by a specific signature with SSA and SSA-D closer together than to MSI CRC. Validation of the deregulated miRs reveals that miR199a and b-5p and miR125b-5p downregulation is more important for the transition from SSA to SSA-D than to MSI CRC. Alternatively, miR181 upregulation might play a role in the transition from SSA-D to MSI CRC, whereas the miR1246 upregulation might be important for the SSA to MSI CRC transition. Thus, SSA-D might not be a mandatory step in the transition from SSA to MSI CRC. Additionally, APC, KRAS and p53 might have a role in the initiation of the tumorigenesis for the MSI pathway and BRAF may become more relevant at a later stage.

692 P53-miR1246-DYRK1A-NFAT – A Novel Tumorigenic Pathway in Microsatellite Unstable Colorectal Cancers with BRAF Mutation

S Costinean, L Casadei, V Balatti, L Cascione, CM Croce, WL Frankel. The Ohio State University, Columbus, OH.

Background: Gene profiling has identified two distinct types of colorectal cancers (CRCs): microsatellite stable (non-mutated-MSS) and unstable (hyper-mutated-MSI). The non-mutated variants are characterized by APC and TP53 mutations, whereas the mutated are defined by APC, MSH3, MSH6 and BRAF mutations. BRAF mutations are associated with sporadic MSI CRCs due to epigenetic inactivation of MLH1. MicroRNAs (MiRs) are noncoding RNAs with roles in posttranscriptional regulation. Our aim was to identify a specific miR signature for MSS vs MSI CRCs that could lead to unraveling new tumorigenic pathways.

Design: MSS CRCs were identified by intact immunostains for mismatch repair proteins. Sporadic (methylated) MSI CRCs were identified by MLH1 and PMS2 immunostain loss together with BRAF mutation. 40 MSS CRCs and 22 MSI CRCs were selected from tissue archive. Representative areas of the tumors were cored. RNA was analyzed using Nanostring; RT-PCR was used for validation of deregulated miRs.

Results: Nanostring miR profiling of MSS vs. MSI CRCs identified only 19 miRs differentially expressed: 13 downregulated (miR1246, miR592, miR548, miR582, miR552, miR4443, etc) and 6 upregulated (miR181c-5p, miR31-5p, miR582, miR625, miR590-3b and miR146b-5p). We ran validating RT-PCR on 5 of the most deregulated miRs: miR1246, 181c-5p, 199a and b-5p and miR125b-5p and were able to confirm

that miR1246 had higher values in MSS than in MSI. In silico experiments showed miR1246 to target nucleoporin 50, CAV1 and DYRK1A.

Conclusions: The limited number of confirmed miRs deregulated in MSS vs. MSI CRCs, shows that even though many proteins are differentially expressed in the two pathways there are only a few miRs that differ. This indicates that the pathways are more similar than different and that miRs differentially deregulated are highly specific to each pathway. MiR1246 is of particular interest as it was validated by RT-PCR. Recent studies (Cell Cycle, 2012) showed that miR1246 is a target of p53, p63 and p73, and is downregulated in Down syndrome. In silico studies identified nucleoporin 50, CAV1 and DYRK1A as targets of this miR. Hence, we could surmise that the downregulation of miR1246 in MSI CRC might be related to mutated p53 and higher levels of DYRK1A that in turn inactivates NFAT. Thus, p53 mutations might play a larger role in tumorigenesis of the MSI pathway than previously thought.

693 How Reliable Is pN0 H&E Lymph Node Staging in Colon Cancer? Preliminary Results from a Multicenter Study

M Cuatrecasas, I Aldecoa, J Tarragona, B Atares, L Bernet, T Pereda, J Palacios, J Zamora. H.Clinic, Barcelona, Spain; H.A.Vilanova, Lleida, Spain; H.U.Alava, Txagorritxu, Spain; H.L.Alcanyis, Xativa, Spain; H.C.Sol, Marbella, Spain; H.R.y Cajal, Madrid, Spain; H.RyC, Madrid, Spain.

Background: Colon Cancer (CC) is the second cause of death from cancer in developed countries. Pathological lymph-node staging (pN) results from the analysis of 2-5µm thick slices stained with H&E of each lymph-node, which represent <2% of the entire node. About 25% of stage I-II patients (pN0) may develop local recurrence or distant metastases within 5 years of surgery. The sensitivity of H&E for detection of "H&E occult metastases" is low and does not identify those patients that could benefit from adjuvant therapy.

Design: The aim of this study was to assess lymph-node staging differences between H&E staining versus molecular lymph-node staging using One-Step Nucleic Acid Amplification (OSNA), in stage I-II CC patients. This observational, multicenter, prospective study included 199 stage I-II CC patients (16 pTis, 38 pT1, 40 pT2, 89 pT3, 16 pT4), selected from 10 hospitals. Fresh lymph node dissection was done within 50 minutes after surgery. A total of 2.817 lymph-nodes were freshly dissected (mean 13; 8-35). Upon size of the lymph node, a central 1 mm section or ½ of the lymph node was analyzed by H&E, and the rest by OSNA. OSNA is an automated molecular diagnostic assay using nucleic acid amplification technology (RT-LAMP) for the detection of CK19 mRNA. The amount of CK19 mRNA copies correlates with the size of metastatic foci (macrometastases >5.000 copies; micrometastases between 250 and 5.000 copies). Lymph-node staging with H&E was compared to the OSNA lymph-node staging results. The pathology report did not include the OSNA staging, which was blind to the clinician. Patient's follow-up was recoded.

Results: Of the 199 patients, 162 patients were staged pN0 with H&E, while only 89 resulted N0 using OSNA analysis. 73 patients (45.3, 95% CI 35.6 – 55.2%) contained one or few positive lymph nodes. In only 10% of the patients the total tumor load found within the lymph nodes was high.

Conclusions: Molecular lymph-node staging using OSNA is more sensitive than H&E staging. It allows the analysis of the entire lymph node. Most discordances among H&E and OSNA results may be due to tissue allocation bias of non-analyzed tumor by H&E. Molecular lymph node staging may help to select stage I-II CC patients that could benefit from adjuvant therapy. Long-term follow-up of these patients will allow determining the prognostic value of metastases detected by molecular methods.

694 Lymph Node Molecular Staging of Early Colon Cancer – Malignant Polyps (pT1). Is Colon Cancer a Systemic Disease from the Beginning?

M Cuatrecasas, I Aldecoa, M Pellise, F Balaguer, N Planell, S Delgado, L Herrero, R Almenara, A de Lacy, A Castells. H.Clinic, Barcelona, Spain; H. Clinic, Barcelona, Spain; H. Clinic-IDIBAPS, Barcelona, Spain.

Background: A malignant polyp is an endoscopically benign polyp with a pathologic diagnosis of an infiltrating adenocarcinoma into the submucosa (pT1), thus an early colon cancer (ECC). With the introduction of bowel cancer screening, the diagnosis of malignant polyps and ECC has increased. After a malignant polyp diagnosis, either a conservative approach, or a surgical resection of the colon segment is performed, depending on the presence of high-risk histologic factors within the polyp.

Design: The aim of this study was to determine the presence of lymph-node metastases using the molecular method OSNA, in colectomy samples performed after a diagnosis of high-risk malignant polyp, with a pathological staging of pN0 with H&E. Fresh lymph node dissection was performed within 50 minutes after surgical extraction of the colon. A total of 684 lymph-nodes were freshly obtained (mean 12; 9 to 15). Depending on the size of the lymph node, a central 1 mm section or ½ of the lymph node was analyzed by H&E, and the rest of the lymph node was analyzed by OSNA. OSNA is an automated molecular diagnostic assay using nucleic acid amplification technology (RT-LAMP) for the detection of CK19 mRNA. The amount of CK19 mRNA copies correlate with the size of metastatic foci, being macrometastases >5.000 copies; micrometastases between 250 and 5.000 copies. Lymph-node staging with H&E was pN0, and was compared to the OSNA lymph-node staging results. Immunohistochemistry stain for CKAE1/AE3 was performed in all lymph nodes with discordant results between H&E and OSNA.

Results: All patients were staged pN0 with H&E. OSNA found positive CK-19 mRNA copies in some of the lymph-nodes from 21 patients (50%). Most of these cases corresponded to very low tumor cell load, being either isolated tumor cells (10 cases; 24%) or micrometastases (11 cases; 26%). Only one lymph node had a tumor cell load (CK19 mRNA copy number) that corresponded to a macrometastasis. CKAE1/AE3 was positive in 14% of negative H&E cases. We also found that the OSNA results were

related to the size of the adenocarcinoma, i.e. bigger tumors had higher tumor cell load or CK19 mRNA copy number. Instead, Haggitt and Kikuchi levels of submucosal invasion in malignant polyps were not related with the OSNA results.

Conclusions: Molecular lymph-node staging with the OSNA method is highly sensitive and reveals the presence of lymph-node metastases at early stages of colon cancer.

695 Loss of ARID1A and SMAD4 Expression Is Associated with Specific Phenotypes of Gastric and Gastroesophageal Adenocarcinoma
EM da Silva, JHTG Fregnani, I Linkov, DS Klimstra, LH Tang. Memorial Sloan-Kettering Cancer Center, NY, NY; Barretos Cancer Hospital, Barretos, SP, Brazil.

Background: Genomic data analyses have provided insights into the molecular pathways that are dysregulated in gastric cancer. Candidate genes that could play a significant role in tumorigenesis have been identified including chromatin-remodeling gene *ARID1A* and tumor suppressor gene *SMAD4*. Previous results have indicated the strong correlation between mutations of these genes and the corresponding protein loss by immunohistochemistry. We thus investigated *ARID1A* and *SMAD4* expression in subtypes of gastric and gastroesophageal junction (GEJ) adenocarcinoma.

Design: Adenocarcinomas were classified into three subtypes based upon the combination of location, histological pattern, as well as their known pathogenesis: (1) GEJ intestinal type (GEJ-Int), (2) distal gastric intestinal type (G-Int), and (3) sporadic gastric diffuse type (G-Diff). Clinicopathological features of 53 patients were reviewed and immunohistochemistry performed on available tissue specimens (n=39).

Results: Subclassification identified: (1) GEJ-Int (n=15) in association with Barrett's esophagus with intestinal phenotype; (2) G-Int (n=15) in association with atrophic gastritis and a spectrum of intestinal metaplasia and dysplasia; (3) Sporadic G-Diff (n=23) with diffuse histological pattern and without any metaplastic or dysplastic intestinal component. Tumors with mixed intestinal and diffuse type were excluded from the study. Immunohistochemistry revealed that loss of *ARID1A* and *SMAD4* expression were mutually exclusive and occurred in 23% and 20% of all subtypes of adenocarcinomas, respectively. Loss of *ARID1A* expression was more prevalent in G-Diff type (13%) (p<0.05) when compared to G-Int (8%) and GEJ-Int (3%) types. In fact, 24% of all G-Diff cases lacked *ARID1A* expression. In contrast, loss of *SMAD4* expression was significantly associated with carcinoma of intestinal phenotype exclusively localized at GEJ (47% of all GEJ-Int cases) (p<0.02).

Conclusions: The expression of *ARID1A* and *SMAD4* are differentially altered in subtypes of gastric and GEJ adenocarcinoma; they may represent an important event in the development of sporadic diffuse gastric cancer and GEJ adenocarcinoma, respectively. Careful phenotype assessment of these subtypes may provide the basis for the investigation of the underlying genetic mechanisms of the disease and facilitate the development of more effective therapeutic strategies.

696 Tumor Border Configuration in Colorectal Cancer: Proposal for an Alternative Scoring System Based on the Percentage of Infiltrating Margin

H Dawson, VH Koelzer, E Karamitopoulou, R Langer, I Zlobec, A Lugli. Institute of Pathology, University of Bern, Bern, Switzerland.

Background: Tumor border configuration in colorectal cancer can be described as pushing, infiltrating or mixed and has been shown to be a valuable prognostic indicator. However, due to lack of reproducibility and established evaluation systems, tumor border configuration is currently not included in most surgical pathology reports. The aim of this study was to evaluate the reproducibility and prognostic impact of an alternative scoring system based on the percentage of infiltrating tumor border component.

Design: A total of 200 primary colorectal cancer resection specimens with complete clinicopathological data were included in this study. For each case, one representative slide was assessed by two independent observers. Tumor border configuration was evaluated by scoring the percentage of infiltrating tumor margin and correlated with clinicopathological features and survival. Interobserver variability was assessed using the intraclass correlation coefficient (ICC).

Results: A higher percentage of infiltrating margin correlated with higher probability of adverse clinicopathological features such as higher tumor grade (p=0.0044), the presence of lymph node metastases (p<0.0001), distant metastases (p=0.002), venous invasion (p=0.0004), lymphatic invasion (p<0.0001), high-grade tumor budding (p<0.0001) and poor survival (p=0.0003). Multivariate analysis confirmed the prognostic effect of tumor border configuration independently of pT, pN and adjuvant therapy (p=0.0289). No association with MMR protein expression (Mlh1, Msh2, Msh6 and Pms2), KRAS and BRAF status was found. Four discrepant cases were resolved by consensus review with a third gastrointestinal pathologist. Overall ICC was 0.86 for the two observers, indicating excellent agreement.

Conclusions: Reporting the percentage of infiltrating tumor border configuration is reproducible, adds additional prognostic value to surgical pathology reports on colorectal cancer resection specimens and may be easily applied in daily routine.

697 Loss of Cdx2 Is a Potential Marker of the Serrated Pathway of Colorectal Cancer Characterized by BRAF Mutation, High-Level CpG Island Methylator Phenotype and Mismatch Repair-Deficiency

H Dawson, VH Koelzer, E Karamitopoulou, A Lugli, I Zlobec. Institute of Pathology, University of Bern, Bern, Switzerland.

Background: Colorectal cancer is a heterogeneous disease at the histomorphological, clinical and molecular level. Approximately 20% of cases are hypothesized to progress through the "serrated" pathway characterized by *BRAF* mutation and high-level CpG Island Methylator Phenotype (CIMP). A large subgroup are additionally microsatellite instable (MSI). Loss of expression of tumor suppressor *CDX2* has been described in connection with these three molecular features. The aim of this study is to determine

the specificity of *Cdx2* protein expression and *CDX2* promoter hypermethylation for *BRAF^{V600E}*, high-level CIMP and mismatch repair (MMR)- deficiency in colorectal cancer.

Design: *Cdx2*, *Mlh1*, *Msh2*, *Msh6* and *Pms2* expression were analyzed by immunohistochemistry using a multi-punch tissue microarray (n=220 patients). *KRAS* and *BRAF^{V600E}* mutation analysis, *CDX2* promoter methylation, *CDX2* RNA expression and CIMP were investigated. Immunohistochemistry for *Cdx2* was additionally performed on 8 well-established colorectal cancer cell lines and 7 sessile serrated adenomas, 9 tubular adenomas and 1 mixed adenoma (tubular/sessile serrated).

Results: Among other features, loss of *Cdx2* correlated with larger tumor size (p=0.0154), right-sided location (p=0.0014), higher tumor grade (p<0.0001), more advanced pT (p=0.0234) and lymphatic invasion (p=0.0351). Specificity was 100% for MMR-deficiency (p<0.0001), 92.2% (p<0.0001) for *BRAF^{V600E}* mutation and 91.8% for CIMP-high. Combined analysis of *BRAF^{V600E}*/CIMP identified *Cdx2* loss as sensitive (80%) and specific (91.5%) for mutation/high status. *CDX2* methylation correlated with *BRAF^{V600E}* mutation (p=0.0184) and with *Cdx2* protein loss (p=0.0028). A strong positive correlation between protein and gene expression was found (r=0.41, p<0.0001). In a hierarchy composed of *BRAF* mutation, followed by CIMP-H and MSI-H, *Cdx2* protein expression was predictive in all 8/8 cell lines. In the adenomas, *Cdx2* staining was diffuse in all cases, but markedly less intense in some sessile serrated adenomas.

Conclusions: These results seem to indicate that *Cdx2* may play a role in the serrated pathway to colorectal cancer as evidenced by strong relationships with *BRAF^{V600E}* mutation, CIMP-high and MMR-deficiency. The use of *Cdx2* as a "surrogate" marker, its function in tumor progression through the serrated pathway and the timing of these molecular events remain to be elucidated.

698 Next-Generation Sequencing Mutational Analysis of Intestinal Metaplasia and Neoplastic Lesions in Barrett's Esophagus from Endoscopic Samples

A Del Portillo, Y Yuan, T Uehara, N Jhala, T Ganguly, S Lagana, JL Gutierrez-Pajares, JL Sepulveda, Y Liu, R Brand, GW Falk, AR Sepulveda. Columbia University, New York, NY; University of Pennsylvania, Philadelphia, PA; University of Pittsburgh, Pittsburgh, PA; Shinshu University, Matsumoto, Japan.

Background: Intestinal metaplasia (IM) in patients with Barrett's Esophagus (BE) may carry specific molecular alterations, including gene mutations that characterize the field defect that may precede the histologic appearance of dysplasia and adenocarcinoma (EAC). The aim of this study is to identify mutational biomarkers using next-generation sequencing (NGS) and endoscopic samples for risk stratification of Barrett's Esophagus (BE) patients at increased risk of dysplasia.

Design: Ion Torrent AmpliSeq and Illumina TruSeq Amplicon Cancer Panels were used to screen for mutations in 50 cancer genes. We tested 30 samples from 24 patients: Intestinal metaplasia from 6 patients (IM-P) with concomitant high-grade dysplasia (HGD)/EAC; IM of 7 patients followed for at least two years without any dysplasia (IM-N), 12 HGD/EAC and 5 samples of gastric cardia type mucosa from patients with dysplasia or negative for dysplasia. Ion torrent suite software, ANNOVAR and NEXTGENE software were used for analysis.

Results: Among the mutation positive patients, their IM or HGD/EAC lesions had TP53 mutations in 82%, CDKN2A (27%), PDGFR (9%), FGFR (9%) and KRA6 (9%) of patients. IM-P patients had TP53 mutations in both IM and HGD/EAC samples tested. None of the 7 IM-N patients had TP53 mutations. Sensitivity of TP53 mutation for presence of concomitant dysplasia was 67% and specificity was 100%. TP53 mutations were detected in 75% of HGD and EAC samples, while none of the cardia mucosa samples had any mutations.

Conclusions: DNA from routine endoscopic samples can be efficiently used to simultaneously detect multiple mutations by NGS. Sample adequacy for molecular testing requires pathology assessment for the presence of IM. The most frequent mutations in IM and HGD/EAC were detected in TP53. TP53 mutations were frequently detected in IM of patients with HGD/EAC but not in patients who did not progress to HGD/EAC, suggesting that TP53 mutational testing may be useful to identify IM-P patients who may benefit from closer surveillance. Scoring for mutations in additional genes such as CDKN2A and PDGFR may increase the sensitivity of detection of IM-progressors who may be at increased risk of progression to HGD/EAC.

699 The Density of Fc Gamma Receptor IIIA-Positive Tumor Infiltrating Lymphocytes Is Associated with HLA-E/β2 Microglobulin Overexpression by Tumor Cells and Could Be a Novel Predictive Factor of Response to Cetuximab in Metastatic Colorectal Carcinoma

M Denis Musquer, P Jamet, C Volteau, R Faroux, S Bezieau, N Gervois, F Jotereau, J-F Mosnier, C Bossard. University Hospital of Nantes, Nantes, France; Hospital of La Roche sur Yon, La Roche sur Yon, France; University of Nantes, Nantes, France.

Background: The Fc fragment of the anti-epidermal growth factor receptor monoclonal antibody, Cetuximab, induced tumor lysis by binding to FcγRIIIa receptor (CD16) expressed by immune cells (ADCC, Antibody-Dependent Cell-mediated Cytotoxicity). However, in vitro studies showed that HLA-E/β2 microglobulin (β2m) expression by tumor cells inhibit Cetuximab-mediated ADCC. We have previously shown that tumor cells overexpressed HLA-E/β2m in 20% of colorectal cancer and was associated with the recruitment of intra-epithelial tumor-infiltrating lymphocytes (IEL-TIL) expressing the inhibitory receptor CD94/NKG2+, specific for HLA-E/β2m (Bossard et al, 2012). The study was designed to correlate the HLA-E/β2m overexpression by tumor cells, and the density of IEL-TIL expressing the FcγRIIIa receptor to the response of Cetuximab in a cohort of patients with a metastatic colorectal carcinomas (mCRC).

Design: Forty patients treated for a wild-type *KRAS* mCRC with Cetuximab were included. HLA-E/ β 2m expression and CD16+ IEL-TIL density were determined in matched primary tumors and metastases by immunohistochemistry and correlated with the therapeutic response.

Results: HLA-E/ β 2m was overexpressed in 39% of primary tumors and in 43% of metastasis. HLA-E/ β 2m overexpression was significantly associated with an increased number CD16+ IEL-TIL both in primary (mean = 0.72% vs 0.24%, $p = 0.028$) and in metastatic tumors (0.98% vs 0.20%, $p = 0.012$). A high density of CD16+ IEL-TIL in primary tumors was associated with a better objective response to Cetuximab (median = 8 months vs 3.9 months, $p = 0.056$).

Conclusions: HLA-E/ β 2m overexpression by tumor cells in patients with mCRC is associated with the recruitment of IEL-TIL expressing the Fc γ R1IIa receptor CD16 in both primary and metastatic tumors. The density of CD16+ IEL-TIL in primary tumors is associated with a better objective response to Cetuximab. These results suggest that the density of CD16+ IEL-TIL with could be a novel predictive biomarker of response to Cetuximab in patients with a wild-type *KRAS* mCRC.

700 Refining the Histological Criteria of IBD-Associated Gastritis and Distinction from H. Pylori-Associated Gastritis

S Dhingra, N Harpaz. Icahn School of Medicine at Mount Sinai, New York, NY.

Background: Chronic gastroenteritis occurs in Crohn's disease (CD) and ulcerative colitis (UC). Although morphological comparisons with H. pylori-associated gastritis (HPG) have noted patterns of inflammatory cell infiltration that seem relatively specific for IBD, such as focally enhanced gastritis (FEG), few studies have been comprehensive and individual morphological parameters have been variably defined. For example, some studies restrict the term FEG to the setting of normal background mucosa whereas others do not. We compared the features of gastritis in CD and UC in adult and pediatric age groups with those of non-IBD H. pylori-associated gastritis (HPG) to better define their respective features.

Design: Biopsies of patients with H. pylori-negative CD and UC-associated gastritis (CDG and UCG, respectively) (cases) and age and sex-matched patients with non-IBD HPG (controls) were identified retrospectively from our pathology database (2009-2013). Histological classification based on the updated Sydney system was refined by identifying (1) "focal" or "diffuse" chronic active gastritis (CAG) based on the distribution of neutrophils and (2) FEG either in the presence of background gastritis (FEG-G) or its absence (FEG-N).

Results: We identified 82 cases of CDG, 51 pediatric and 31 adult, 24 cases of UCG, 17 pediatric and 7 adults and 36 non-IBD HPG controls, 15 pediatric and 21 adults. Focal PMN infiltration ($P=0.001$), FEG-N ($P=0.0370$) and FEG-G ($P=0.006$) were significantly associated with gastritis in IBD compared with HPG. Compared with FEG-G, FEG-N was less prevalent in IBD-associated gastritis but was absent in HPG.

Histological findings in pediatric and adult patients with gastritis

	CAG, focal PMN infiltration	CAG, diffuse PMN infiltration	Chronic inactive gastritis	FEG-N	FEG-G	Granulomas	Lymphoid aggregates/follicles
CDG(n=82)	34(40%)	11(13%)	29(34%)	11(13%)	37(44%)	17(20%)	11(13%)
UCG(n=24)	9(33%)	0(0%)	14(62%)	1(5%)	4(19%)	0(0%)	2(9%)
Non-IBD HPG(n=36)	10(28%)	23(64%)	3(8%)	0(0%)	6(17%)	0(0%)	17(47%)

Conclusions: CAG with focal PMN infiltration and FEG are significantly associated with IBD-associated gastritis compared with HPG. The association between FEG and IBD is even stronger when background gastritis is absent, but this finding is relatively infrequent. IBD is an important diagnostic consideration in patients with biopsies featuring CAG with focal PMN infiltration or FEG.

701 Clinical Spectrum of Gastric Mucinous Metaplasia in Intestinal Biopsies

S Dhingra, AD Polydorides. Icahn School of Medicine at Mount Sinai, New York, NY.

Background: Gastric mucinous metaplasia, also referred to as pyloric gland metaplasia (PGM), is a reactive epithelial change, frequently observed in the small intestine of patients with Crohn's disease (CD), particularly in resection specimens. However, the significance of PGM in mucosal biopsies as a histological feature supporting the diagnosis of CD is controversial. The aim of this study was to evaluate the clinical correlates of PGM in a large cohort of patients undergoing colonoscopy.

Design: A retrospective search of our pathology database and review of electronic medical records over the period 2003-2013 was undertaken.

Results: A total of 232 biopsies with PGM were identified: 174 (75%) were from the ileum, 43 (19%) were pouch biopsies, and 15 (6%) were from the colorectum [Table]. Most pouch biopsies with PGM (77%) were from patients with ulcerative colitis (UC), whereas only 19% carried a diagnosis of CD and 4% had familial adenomatous polyposis (FAP). In contrast, of non-pouch ileal biopsies with PGM, the majority (75%) were from CD patients, 7% were from UC patients, and 18% were from patients that did not have inflammatory bowel disease (IBD), including 5 cases with diarrhea/other symptoms, 3 patients on NSAIDs, 4 HIV patients, 1 patient with history of gastric lymphoma, 1 patient with an ileal allograft, 3 patients undergoing screening colonoscopy, and 14 patients with PGM found in the anastomosis after non-IBD related surgery. In addition, PGM was identified in 15 colorectal mucosal biopsies, of which the majority of patients (53%) had CD. Overall, 146 of 232 (63%) of biopsies with PGM were from patients with CD: 62 female and 84 male with a mean age of 46 years (range: 18-85). The remaining non-CD patients with PGM comprised 33 females and 53 males with mean age of 50 years (range: 25-67).

Clinical correlates of pyloric gland metaplasia in intestinal biopsies

Site	Clinical condition	Number (%)
Pouch, N=43 (19%)	CD	8 (19%)
	UC	33 (77%)
	FAP	2 (4%)
Ileum, N=174 (75%)	CD	130 (75%)
	UC	13 (7%)
	Non-IBD	31 (18%)
Colon, N=15 (6%)	CD	8 (53%)
	UC	3 (20%)
	Non-IBD	4 (27%)

Conclusions: Our results suggest that while CD is the most common setting in which PGM is found in mucosal biopsies, a significant proportion (37%) of gastric mucinous metaplasia occurs in patients with other diagnoses including UC as well as a multitude of other nonIBD clinical settings. In addition, PGM can also be found in biopsies from the left and right colon and rectum. We conclude that PGM is commonly encountered in intestinal mucosal biopsies in a relatively wide variety of clinical settings.

702 Unusual Patterns of MMR Protein Expression in Colorectal Cancer: Correlation with Germline Mutation & Family History

LA Doyle, A Srivastava. Brigham and Women's Hospital, Boston, MA.

Background: Immunohistochemical (IHC) evaluation of DNA mismatch repair (MMR) proteins is becoming routine in the evaluation of colorectal carcinoma. Unusual patterns of expression are likely to be detected more often as universal Lynch syndrome screening is adopted as standard of care. This study aimed to identify unusual MMR protein expression patterns & associations with family history (FH) and germline mutation.

Design: MMR IHC staining patterns of 802 colorectal carcinomas were reviewed. Clinicopathologic features were evaluated, including FH of Lynch associated cancers, microsatellite stability by PCR, & germline mutation status.

Results: As expected, the commonest patterns of loss of MMR proteins were concurrent MLH1&PMS2 loss (115/802, 14%), and MSH2&MSH6 (3%). Isolated loss of PMS2 was found in 1.7%, and of MSH6 in 1.3%: both groups had high level microsatellite instability (MSI-H), and germline *PMS2* and *MSH6* mutations respectively, but only 55% in each group had FH of Lynch syndrome. Unusual patterns of staining were identified in 9 tumors (1%) and could be broadly classified into 4 groups: **1) MLH1 loss with intact PMS2 (n=1):** female (44 yrs), no FH, MSI-H with *MLH1* promoter hypermethylation. **2) MSH2 loss with intact MSH6 (n=2):** FH of Lynch, MSI-H, *MSH2* mutations in both. **3) Abrupt complete loss of MMR expression within a significant proportion of tumor (n=3):** 2 had abrupt loss of MSH2&MSH6, 1 had abrupt loss of MLH1&PMS2. 1 tumor with abrupt loss of MSH2&MSH6 transitioned from glandular to solid growth, correlating with loss of protein expression in solid areas. Targeted PCR showed MSI-H in the area of protein loss and MSS in the area with intact staining for all 4 proteins. No change in morphology was appreciated in the other 2 cases. Both patients with partial loss of MSH2&MSH6 lacked germline mutations (only 1 had a FH suggestive of Lynch). **4) Abnormal MSH6 pattern (n=3):** 2 cases had MSH6 loss in the setting of loss of MLH1&PMS2; 1 with *MLH1* germline mutation and FH of Lynch, the other with no FH or germline mutation. 1 patient had partial loss of MSH6 in a rectal tumor post neoadjuvant therapy-the tumor was MSI-L and germline *MSH6* mutation of uncertain significance was detected.

Conclusions: Unusual patterns of MMR protein expression are rare (1%), and many cases lack germline mutation or FH of Lynch syndrome. Pooled analysis of outcome for these rare phenotypes is critical to develop evidence based surveillance guidelines for these patients. Abrupt loss of MMR expression within some tumors suggests that MSI may rarely develop as a late second hit within an invasive tumor.

703 ARID1a Loss in Esophageal Adenocarcinoma Is Associated with Distinct Morphologic Phenotypes and Bears No Relationship with p53 Expression

MG Drage, M Tippayawong, AT Agoston, Y Zheng, R Bueno, JL Hornick, RD Odze, A Srivastava. Brigham and Women's Hospital, Boston, MA; Bangkok Hospital Phuket, Muang, Phuket, Thailand.

Background: ARID1a is a tumor suppressor gene frequently lost in high grade endometrial carcinomas, with an inverse relationship to p53 mutation, suggesting an independent pathway for carcinogenesis. The aim of our study was to determine the prevalence and clinicopathologic characteristics of esophageal adenocarcinomas (EAC) with ARID1a loss and to examine potential correlation with prognosis.

Design: 92 cases of primary EAC were reviewed for a predetermined set of histologic features. Immunohistochemistry for ARID1a, p53, and MLH1 was performed on tissue sections with carcinoma and adjacent dysplasia when possible. Patient demographics, tumor recurrence, and survival data were obtained by chart review. Loss of staining for ARID1a and MLH1 was scored separately in dysplasia and carcinoma. Diffuse strong staining or completely negative staining for p53 was regarded as a mutant pattern. Multivariate logistic regression analysis was done to determine clinicopathologic correlates of EAC with loss of ARID1a.

Results: The 92 patient cohort included 72 M and 20 F (mean age 67 yr). Dysplastic foci adjacent to carcinoma (42 low grade and 52 high grade) were available for evaluation in 56/92 cases. Loss of ARID1a expression was seen in 12/92 (13%) EAC (2 small clonal foci, 10 confluent loss). Of the 12 cases with ARID1a loss, adjacent dysplasia was present in 4 cases, but ARID1a loss was restricted to the carcinoma. Interestingly, 8/12 (67%) tumors with ARID1a loss showed an intestinal phenotype with mucinous or medullary differentiation and marked intratumoral and peritumoral lymphocytic infiltration, reminiscent of MSI-H colon carcinomas. A p53-mutant pattern was seen in 40/92 (43%) cases, including 6/12 (50%) tumors with loss of ARID1a. ARID1a loss showed no relationship to p53 mutant pattern (50% vs. 43% of tumors with and without ARID1a loss, respectively) or to MLH1 loss, (the latter present in only one

ARID1a-deficient case. EAC with ARID1a loss showed no difference in stage \geq pT1b (7/11 (64%) tumors with loss vs. 30% of ARID1a intact tumors), but showed a trend towards increased nodal disease (58% of ARID1a-deficient tumors had N stage \geq 1 vs. 30% of ARID1a-intact tumors, $p=0.097$).

Conclusions: Unlike Mullerian carcinomas, ARID1a in EAC shows no association with p53 mutation status. These tumors often show a phenotype reminiscent of MSI-H colon carcinomas, suggesting a distinct pathogenesis.

704 **Biologic Behavior of Gallbladder High-Grade Dysplasia: A Long-Term Survival Analysis of 125 Cases Elucidates a Mostly Curable Disease, Which Is a Marker of Biliary Tract Cancer Risk in Some Patients**

N Dursun, B Saka, S Balci, P Bagci, JC Roa, JC Araya, O Basturk, P Terry, F Minhas, L Ducato, V Adsay. Emory, Atlanta, GA; PUC, Santiago, Chile; UF, Temuco, Chile; MSKCC, NY, NY; UT, Knoxville, TN; PH & MC, Southfield, MI.

Background: Estimated some 20-thousand gallbladder dysplasias are encountered in the US annually, and the incidence is much higher in high-gallbladder cancer risk regions. In the meantime, there is virtually no information on biological behavior of gallbladder high-grade dysplasia/carcinoma in-situ (HGD/CIS).

Design: The pathologic findings and clinical outcome in 125 unequivocal examples of gallbladder HGD/CIS were analyzed.

Results: Female/Male was 3.5, mean age was 56. Ninety-eight cases had undergone total sampling of the gallbladder as per the protocol devised by Roa et al (Rev Chil Cirugia 57:436-442), and the remaining cases had been sampled in average of 6 blocks (range, 1-12). In a median follow-up 152 months, 1-, 3-, 5- and 10-year survival rates were 96%, 93%, 90%, and 86%, respectively. Twenty-three patients died at a median follow-up of 88 months, 1 was perioperative mortality. Five patients died at 20, 38, 44, 44 and 46 months of what appeared to be progression of cancer in the gallbladder/biliary tract. Four of these 5 were gallbladders that were incompletely sampled in average of 7 blocks, presumably representing missed invasion, and also 2 had HGD/CIS at the cystic duct margin. Four patients died of other cancers; 1 colon at 8 months, 1 esophagus at 16 months, 1 plasmacytoma at 88 months, 1 cervical at 200 mos. Four died of a biliary tract cancer at around 10 years (104,109, 134 and 138 months) and cystic duct margin was negative in all 4. Nine deaths were related to medical conditions (pneumonia in 5, cardiovascular in 3, sepsis in 1) at a median follow-up of 127 months.

Conclusions: If the possibility of invasive carcinoma is excluded by total sampling, the vast majority of all gallbladder HGD/CIS cases are cured by cholecystectomy. Thus, total sampling of gallbladders with HGD/CIS is crucial. A small subset of patients develop biliary tract cancers at around 10 years, possibly related to field-effect/defect phenomenon. Therefore, long term follow-up of these patients is warranted.

705 **FOXP3+ Tumor Infiltrating Lymphocytes in EBV-Positive Lymphoepithelioma-Like Gastric Carcinoma: Clinicopathologic Features and Survival**

JS Estrella, S Loghavi, GN Fuller, JA Ajani, A Rashid. UT MD Anderson Cancer Center, Houston, TX.

Background: Forkhead box P3-positive T regulatory lymphocytes (FOXP3+Tregs) downregulate antitumor immunity by suppressing the function of effector T cells, hence, inducing immune tolerance. However, the prognostic significance of infiltrating FOXP3+Tregs in cancer is controversial. Increased FOXP3+Tregs were associated with worse prognosis in some tumors and conferred better prognosis in others. In Epstein-Barr virus (EBV)-associated lymphoepithelioma-like gastric carcinomas (LELGC), tumor infiltrating lymphocytes are comprised predominantly of CD8+ T cells which play a crucial role in local immune response. The presence and significance of FOXP3+Tregs in EBV-associated LELGC has not been studied.

Design: We identified 53 LELGC (26 EBV diffusely positive, 19 focally positive and 8 EBV negative) and performed immunohistochemistry using FOXP3, CD4 and CD8 antibodies to characterize the tumor infiltrating lymphocytes (TILs). Within the tumor, two areas with the highest density of FOXP3 staining were evaluated for the number of positive cells/mm² using computer-assisted image analysis with Aperio ImageScope Version 11.2.0.780. The association between TIL characteristics and clinicopathologic features and survival were examined using Mann-Whitney U test, Kruskal-Wallis test or univariate Cox proportional hazard regression model, when appropriate.

Results: Among the 3 EBV groups, the ratio of FOXP3:CD8 was significantly increased in tumors with focal EBV positivity (median = 0.41) compared to those with diffuse EBV positivity (median = 0.24) and negative EBV status (median = 0.22) ($P=0.02$). There was no difference in the median FOXP3+, CD8+ and CD4+ TILs, FOXP3:CD4 ratio and FOXP3:CD3 ratio. Among EBV positive tumors (45 cases), increased FOXP3:CD8 ratio was associated with higher pathologic tumor stage (pT). Median FOXP3:CD8 ratio were as follows: pT1 = 0.36, pT3 = 0.21 and pT4 = 0.58 ($P=0.007$). No association between FOXP3:CD8 ratio and AJCC stage, presence of lymphovascular or perineural invasion, lymph node or distant metastases were seen. By univariate analysis, increased FOXP3:CD8 ratio was associated with worse overall survival (HR=1.8, 95% CI=1.6-2.9, $P=0.03$).

Conclusions: LELGC which were only focally positive for EBV had increased FOXP3:CD8 ratio compared to those tumors with no EBV and diffuse EBV positivity. Among EBV-associated LELGC, increased FOXP3:CD8 ratio was associated with higher pT stage and worse overall survival.

706 **BRAF V600E Immunohistochemistry in Colorectal Carcinoma**

JS Estrella, MT Tetzlaff, C Kazen, S Kopetz, DM Maru, A Rashid, SR Hamilton, RR Broadus. UT MD Anderson Cancer Center, Houston, TX.

Background: Detecting *BRAF* mutation in colorectal carcinoma has important prognostic value. Although sequencing represents the gold standard, a recently

developed antibody specific for the *BRAF* V600E protein has shown promising results in published studies. Immunohistochemistry is a fast, inexpensive, widely available surrogate of molecular studies. Because results of anti-*BRAF* V600E immunohistochemistry may have critical clinical implications, we correlated anti-*BRAF*V600E positivity in a large cohort of colorectal adenocarcinomas with known *BRAF* mutation status.

Design: Colorectal carcinomas harboring *BRAF* V600E mutation (125 cases), non-V600E mutations (11 cases) and no *BRAF* mutation (wildtype, 328 cases) were examined. Immunohistochemistry was performed on formalin-fixed paraffin embedded whole tissue sections in a CLIA-certified laboratory at our institution using *BRAF* antibody clone VE1 (1:50, Spring Bioscience, Pleasanton, CA).

Results: *BRAF* V600E immunohistochemistry yielded a variety of staining patterns, summarized in Table 1.

BRAF V600E Immunohistochemistry in Colorectal Carcinoma

BRAF Cytoplasmic staining	BRAF Molecular Analysis		
	Wildtype (n=328)	V600E (n=125)	Non-V600E (n=11)
Negative	207 (63%)	12 (10%)	7 (64%)
Weak (40%)	89 (27%)	18 (14%)	3 (27%)
Weak (40-80%)	1 (0%)	20 (16%)	0 (0%)
Weak (>80%)	1 (0%)	40 (32%)	0 (0%)
Strong (40%)	22 (7%)	5 (4%)	1 (9%)
Strong (40-80%)	2 (1%)	3 (2%)	0 (0%)
Strong (80%)	6 (2%)	27 (22%)	0 (0%)

The majority (62%) of colorectal carcinomas with known *BRAF* V600E mutation by sequencing exhibited faint/weak cytoplasmic staining; only 28% exhibited strong cytoplasmic staining, often patchy (41%). Nearly 10% of the mutant carcinomas had no staining. Among 11 tumors harboring non-V600E mutations, one exhibited strong cytoplasmic staining in 10% of tumor cells. Among *BRAF* wildtype tumors, up to 9% exhibited strong cytoplasmic staining (strong, diffuse staining in 2%) and up to 28% exhibited faint/weak cytoplasmic staining. Moreover, nuclear staining (without cytoplasmic staining) was seen in 18 (6%) wildtype tumors, similar to normal colonic epithelium. Overall, the sensitivity of immunohistochemistry predicting V600E mutation is 90%, the specificity is 63%, the positive predictive value is 48% and the negative predictive value is 95%.

Conclusions: The relatively low specificity of the anti-*BRAF* V600E antibody together with the often weak-patchy, and occasionally absent, staining among tumors known to harbor the V600E mutation undermine the clinical utility of this immunohistochemical test among colorectal cancer patients.

707 **HLA-E/ β 2 Microglobulin Overexpression Is Associated with Recruitment of Inhibitory Immune Cells and Tumour Progression in MSS Colorectal Carcinomas**

J Eugene-Lamer, S Kury, F Airaud, C Volteau, R Oger, N Gervois, F Jotereau, S Bezieau, J-F Mosnier, C Bossard. Université de Nantes, Nantes, France; Centre Hospitalier Universitaire, Nantes, France; IRS 1, Université de Nantes, Nantes, France.

Background: Recent studies in colorectal cancer (CRC) have associated improved survival with a large number of tumour-infiltrating lymphocytes (TIL), measured by the infiltration of CD8+ cytotoxic T lymphocytes (CTL). However, tumour cells can escape the immune defence during cancer progression, especially by expressing the human MHC class Ib molecule, human leucocyte antigen (HLA)-E, the ligand of the CD94/NKG2A inhibitory receptor expressed by some CD8+ CTL and NK cells. We have previously shown in CRC that HLA-E/ β 2m over-expression by tumor cells was associated with a high density of CD8+ and CD94/NKG2 intra-epithelial TIL (IEL-TIL), and was associated with an unfavorable prognosis suggesting that HLA-E/ β 2m over-expression is associated with recruitment of inhibitory immune cells and tumour progression (Bossard et al, 2012). In addition, it is well known that microsatellite stable (MSS) CRC have a worse prognosis than microsatellite instable (MSI) CRC. However, the influence of these genetic abnormalities on the interactions between tumor cells and TIL-IEL remain unknown.

Design: This prompted us to examine in a series of 215 CRC, 1) the over-expression of HLA-E/ β 2m by tumor cells and the density of the CD8+ or CD94/NKG2+ IEL-TIL depending on the MSI/MSS status, and 2) the prognostic impact of these variables according to the MSI/MSS status. The HLA-E/ β 2m over-expression and the density of IEL-TIL were quantified by immunohistochemistry on tissue micro-arrays. The MSI/MSS status was determined by PCR.

Results: HLA-E/ β 2m was preferentially over-expressed in MSI CRC (43% vs 18% in MSS CRC; $p=0.0004$) and HLA-E/ β 2m over-expression was significantly associated with a high density of CD8+ and CD94/NKG2+ IEL-TIL, both in MSI CRC ($p<0.0001$ and $p=0.02$) and in MSS CRC ($p=0.03$ and $p=0.0002$). Finally, HLA-E/ β 2m over-expression was associated with an unfavorable prognosis only in MSS CRC.

Conclusions: This is the first study demonstrating the preferential overexpression of HLA-E/ β 2m in MSI CRC, and its unfavorable prognostic impact in MSS CRC. These paradoxical results suggest a different biological role of HLA-E/ β 2m in CRC depending on the MSI/MSS status, associated with the recruitment of inhibitory IEL-TIL only in MSS CRC. Further studies are needed to precise the exact role of HLA-E in MSI CRC.

708 **Pathologic Features Differentiating High-Grade Anal Squamous Intraepithelial Lesions from Reactive Transition Zone**

BJ Fogel, KK Lai, MR Lindberg, LW Lamps, CM Quick. UAMS, Little Rock, AR.

Background: The anal transition zone (ATZ) is histologically complex, often composed of a mix of glandular, transitional, and squamous mucosa. In the setting of inflammation, reactive epithelial changes may mimic anal high grade squamous intraepithelial lesions (HSIL). This study evaluated histologic and immunophenotypic features useful in differentiating reactive ATZ from anal HSIL.

Design: 25 cases of anal HSIL and 24 cases of reactive ATZ (from hemorrhoidectomies in patients with no history of anogenital SIL) were evaluated. Five HSIL cases included segments of reactive ATZ. Cases were evaluated for the histologic features enumerated below, and stained with p16, Ki-67 and CK7 (which has previously been identified as a marker of cervical squamocolumnar junction). p16 positivity was defined as diffuse block staining. Increased Ki-67 staining was defined as stratified staining involving the full thickness of the epithelium.

Results: The most useful features distinguishing HSIL from ATZ are listed in Table 1. Less helpful features included overlapping nuclei, vesicular chromatin, and micronucleoli, as many cases from both groups shared these findings.

Table 1

	Increased mitoses	Atypical parakeratosis	Increased dyskeratosis	Nuclear anisocytosis	Spongiosis
HSIL (n=25)	88%	88%	100%	96%	80%
TZ (n=29)	0%	0%	3%	3%	0%
P value	<0.0001	<0.0001	<0.0001	<0.0001	<0.0001

p16 and Ki-67 were positive in 88% of HSIL cases (Table 2), similar to recently published studies. CK7 was positive in only 2 HSIL cases (8%). No cases of reactive ATZ expressed p16 or increased Ki-67 staining; the latter was restricted to the basal layer. All cases of ATZ were CK7+, demonstrating strong full-thickness positivity in the ATZ and superficial staining of the adjacent maturing squamous epithelium.

Table 2

	p16	Ki-67	CK7
HSIL (n=25)	88%	88%	8%
TZ (n=29)	0%	0%	100%
P value	<0.0001	<0.0001	<0.0001

Conclusions: This is the first study specifically comparing the pathologic features of reactive ATZ and anal HSIL. Increased mitotic activity, atypical parakeratosis, inflammation, increased dyskeratotic cells, nuclear anisocytosis, and spongiosis were the most useful histologic features in distinguishing anal HSIL from ATZ. Immunohistochemistry is also helpful, as no cases of HSIL were both CK7+ and p16 negative. This is also the first study to demonstrate that CK7 is a reliable marker of ATZ, and CK7 was negative in all but two cases of HSIL. The strong CK7 staining at the ATZ and superficial staining of the adjacent maturing squamous epithelium is suggestive of a squamoglandular junctional phenotype, similar to that described in the cervix and in Barrett's esophagus.

709 Methylation Microarray Analysis Identifies Differentially Methylated Genes in Serrated Compared to Conventional Colorectal Carcinomas

J Garcia-Solano, E Alcaraz-Mateos, J Wilce, D Torres-Moreno, MC Turpin-Sevilla, C Navarre, A Conesa, A Tuomisto, P Sirnio, M J Mäkinen, M Perez-Guillermo, P Conesa-Zamora. Santa Lucia University Hospital, Cartagena, Murcia, Spain; Morales Meseguer University Hospital, Murcia, Spain; Research Center Principe Felipe, Valencia, Spain; Oulu University, Oulu, Finland.

Background: Serrated carcinoma (SC) is a recently described heterogeneous histologic variant of colorectal carcinoma (CRC), which accounts for 7.5-9.2% of CRC. It constitutes one of the end-points of the serrated polyp pathway, has an adverse prognosis and a more active invasive front compared to the conventional carcinoma (CC). Besides, it has a distinct immunohistochemical (IHC) profile and molecular characteristics including high frequency of BRAF and KRAS mutations and high-level of CpG island methylation phenotype (CIMP). Although its mRNA expression profile has been evaluated by microarrays, there are no studies analyzing the SC methylome. **Design:** DNA from 39SC and 34CC were extracted from frozen tumoral specimens and were subsequently subjected to bisulfite treatment. These DNAs were hybridized onto Infinium Human Methylation 450k by Illumina. Differentially methylated genes from the SC vs CC comparison were validated by Methylation Specific PCR (MSP) and the corresponding protein expression by IHC which was evaluated using a semiquantitative method (strong, moderate & weak).

Results: Our preliminary results have shown 15 differentially methylated genes (p adjusted <0.05). The most differentially methylated gene was type 3 iodotyrosine deiodinase (DIO3) (p adjusted =0.0001) which was selected for validation. A total of bisulfite-treated DNAs from 59SC and 44CC were used for the MSP validation. Primers for methylation-selective amplification of DIO3 gene were design by using MethPrimer application. 39% of SC cases were unmethylated whereas in CC this percentage was 68.2% (p=0.0034). IHC expression of DIO3 (polyclonal, Thermo) was studied in 25CC and 25SC. A strong accumulation of DIO3 in cytoplasmic granules was observed in 52% of SC whereas this staining was seen in only 28% of CC. In addition, no SC showed weak staining which was observed in 24% of CC (p=0.02).

Conclusions: Our preliminary results demonstrated that certain genes are differentially methylated in SC and CC, showing DIO3 the most statistical difference. Validation studies by MSP confirm microarrays results whereas increased granular staining of DIO3 in SC compared to CC suggests a negative feedback mechanism of methylation-driven silencing of DIO3 gene when DIO3 accumulates in the cytoplasm.

710 Abundance of IGG4-Positive Plasma Cells in Post-Neoadjuvant Ulcers of Gastroesophageal Carcinomas

I Genco, B Saka, S Balci, K Bradley, AB Farris, A Khosroshahi, B El-Rayes, A Krasinskas, C Staley, D Kooby, S Maithe, V Adsay. Emory, Atlanta, GA.

Background: Abundance of IgG4-positive plasma cells is regarded as a characteristic of specific immunologic entity, originally described as "autoimmune pancreatitis", and now expanded to include primary idiopathic inflammatory-sclerotic disorders, under the heading of IgG4-Related Disease.

Design: Plasma cell-rich ulcers of 16 post-neoadjuvant resections for gastroesophageal carcinomas (14 adenocarcinomas, 2 squamous cell carcinomas) were immunohistochemically stained for IgG4 and IgG. Eleven patients had chemoradiation therapy, 1 had photodynamic therapy and 1 had radiation therapy. The details of therapy was unknown for 3 patients.

Results: Thirteen of sixteen cases analyzed showed abundant IgG4-positive plasma cells that may have otherwise qualified as IgG4-Related Disease based on the number of positive cells, if the underlying condition was not known. The average age of the patients with abundant IgG4-positive plasma cells was 60, and the patients were 9 males and 4 females. Although only one had history of autoimmune conditions composed of primary biliary cirrhosis, Reynaud's and Sjogren's syndromes; all 13 had more than 50 IgG4-positive plasma cells counted in more 3 high power field [the criterion defined by Dhall et al to distinguish autoimmune pancreatitis from other forms of pancreatitis, Hum Pathol, 2010;41(5):643-52]. The mean number of IgG4-positive plasma cells in these cases was 146. Furthermore, IgG4-positive plasma cells/IgG-positive plasma cells ratio of >40% (the cut-off widely used to define IgG4-related sclerosing disorders) was noted in 5 cases, and an additional 3 cases showed a ratio of 38%, 38% and 39%. Average ratio was 40% (range, 23% - 68%).

Conclusions: Abundant IgG4-positive plasma cells can occur as a secondary, iatrogenically-induced phenomenon, and therefore should not be regarded as sole criterion for IgG4-Related Disease. The mechanisms of recruitment of abundant IgG4-positive plasma cells to the ulcers induced by chemo-radiotherapy may shed new light both to the mechanisms of IgG4-positive plasma cell-rich disorders as well as to immunologic processes involved in tumor response to therapy.

711 Ion AmpliSeq™ Comprehensive Cancer Panel Compares Favorably with Whole Exome Sequencing for Colon Cancer

R Gibson, K Guda, M Veigl, N Molyneaux, J Lutterbaugh, C Schmotzer, S Markowitz, M Quinones-Mateu, J Willis. Case Medical Center, Cleveland, OH; Case Comprehensive Cancer Center, Cleveland, OH.

Background: There is intense interest into the incorporation of massive parallel sequencing [MPS] into clinical care. Initially these devices and their bioinformatics pipelines were too complex to manage and prohibitively expensive for use in most Clinical Pathology Departments. DNA quality after formalin fixation [FFPE] is also a significant limiting problem. We previously demonstrated the ability of MPS to identify known mutations using DNA hybrid capture and early Illumina technologies from FFPE colon cancers [CC]. Several devices currently on the market have potential utility in clinical departments. Here we compared mutation profiles from FFPE CC samples using the 409 gene Ion AmpliSeq™ Comprehensive Cancer Panel [CCP] (Life Technologies) on an Ion Torrent PGM with profiles from matching fresh frozen CCs derived from Illumina whole exome sequencing [WES] analyzed by a sophisticated informatics platform.

Design: Fresh frozen specimens from 5 CC / normal pairs were subjected to WES using the Illumina TruSeq library platform followed by sequencing the libraries on the Illumina HiSeq instrument. Somatic mutations from the paired normal/tumor samples were identified using combined results of the somatic variant callers: MuTect, VarScan 2 and GATK-Indel. Corresponding matched CC / normal FFPE samples were analyzed using an Ion Torrent PGM and analyzed with three variant callers: Ion Reporter™, VarScan 2 and MuTect.

Results: All specimens satisfied previously determined quality metrics. Of 17 mutations identified by WES, 14 were identified by the Ion AmpliSeq™ CCP. Comparison of sequencing results is listed in Table 1.

Table 1. Whole Exome vs. Ion AmpliSeq CCP Sequencing Results

Case #	Gene	Illumina HiSeq	Ion Torrent PGM		
		WES	Ion Reporter	VarScan 2	MuTect
1	APC	Y	Y	Y	N
1	APC	Y	Y	Y	N
1	KRAS	Y	Y	N	N
1	SMAD4	Y	Y	N	Y
1	TP53	Y	Y	Y	N
2	PIK3CA	Y	Y	N	Y
2	TP53	Y	Y	N	N
2	SMAD4	Y	N	N	N
3	KRAS	Y	Y	N	Y
3	APC	Y	N	N	N
3	APC	Y	Y	N	N
4	APC	Y	Y	Y	N
4	FBXW7	Y	Y	Y	N
4	KRAS	Y	Y	N	N
4	TP53	Y	Y	N	N
5	APC	Y	Y	Y	N
5	TP53	Y	Y	N	Y

There were no false positive Ion AmpliSeq™ CCP mutation calls.

Conclusions: The Ion AmpliSeq™ CCP has a high degree of sensitivity and specificity in analysis of CC FFPE derived DNA when compared to WES of fresh frozen samples. Ion Reporter™ identified all WES-identified mutations and was markedly superior to VarScan 2 and MuTect. These findings support the utility of this platform as a diagnostic modality applicable to Clinical Pathology Departments.

712 Clinical Pathologic Assessment of Grade 1 Acute Gastrointestinal Graft Versus Host Disease: Diagnostic Threshold of Crypt Apoptotic Bodies

AJ Gomez, N Kamtham. Stanford Hospital and Clinics, Stanford, CA.

Background: Colon biopsies are often used to determine the presence and severity of acute gastrointestinal graft versus host disease (GVHD) following bone marrow transplant. Based on the 1974 Lerner criteria, the presence of single-cell crypt apoptosis is diagnosed as grade 1 GVHD. In light of recently proposed minimum criteria for

grade 1 GVHD as ≥ 7 crypt apoptotic bodies/10 contiguous crypts, we retrospectively reviewed colon biopsies from post-transplant patients to establish a threshold consensus within our institution incorporating clinical & endoscopic findings.

Design: We evaluated all colon biopsies during 2003-2011 for suspected grade 1 GVHD after excluding cases of CMV colitis, concurrent upper GI GVHD > 1, and post-transplantation time < 21 days. The biopsies were reviewed blindly by a single pathologist, and apoptotic bodies per ten contiguous crypts were counted in areas of highest histological severity. A chart review was performed to assess the clinical & endoscopic impression at the time of biopsy and to determine subsequent patient management and outcome.

Results: Patients were stratified based on their prior diagnoses. In most cases, the diagnoses on retrospective review concurred with the prior diagnoses.

Table 1. Summary of Clinicopathologic Findings on Retrospective Review

Prior Diagnosis*	Average Days Post-transplant (Range; Median)	Average Apoptotic Bodies (Range; Median)	Clinically Managed as GVHD (%)	≥ 7 apoptotic bodies/10 contiguous crypts (%)
GVHD1 (n=33)	178.9 (22-857; 76.5)	10.6 (2-40; 9)	31/33 (94%)	23/33 (70%)
Descriptive (n=35)	259.1 (21-3667; 70)	6.3 (1-35; 4)	13/35 (37%)	13/35 (37%)
NSA (n=21)	323.6 (23-1883; 60.5)	3.6 (0-13; 2)	6/21 (29%)	2/21 (14%)

*GVHD1: grade 1 GVHD; Descriptive: diagnosis mentioning apoptosis; NSA: no significant abnormality

Conclusions: Most patients diagnosed with grade 1 GVHD had ≥ 7 apoptotic bodies/10 contiguous crypts and were successfully treated as such after exclusion of other diagnostic entities. Patients not diagnosed as grade 1 GVHD on biopsy who required no additional management had at most 8 apoptotic bodies per 10 contiguous crypts. However, some patients with as few as 2 apoptotic bodies diagnosed as grade 1 GVHD were treated to resolution based on the presence of overwhelming clinical & endoscopic support. As grade 1 GVHD cannot be entirely excluded below a threshold of 8 apoptotic bodies, our findings emphasize critical assessment of the overall clinicopathologic findings in these patients to direct appropriate management.

713 IMP3 Immunostain Is More Sensitive Than AMACR in Detecting Dysplastic Epithelium and Early Adenocarcinoma in Barrett's Esophagus
MF Gonzalez, RW Cartun, SA Ligato. Hartford Hospital, Hartford, CT.

Background: Alfa-methylacyl coenzyme A racemase (AMACR) and Insulin-like growth factor-II mRNA-binding protein 3 (IMP3) are two markers helpful in detecting difficult cases of dysplasia in Barrett's Esophagus (BE). No comparison studies have been performed to assess their performance in the same population. The aim of this study is to compare the expression of IMP3 and AMACR in dysplastic lesions and early adenocarcinoma (EAC) arising in BE and evaluate their sensitivity and specificity.

Design: 67 specimens (12, BE negative for dysplasia; 9, indefinite for dysplasia (BE-IND); 16, low-grade dysplasia (LGD); 12, high-grade dysplasia (HGD); and 18 EAC) were stained with AMACR (monoclonal anti-AMACR (clone 13H4) and IMP3 (monoclonal anti-IMP3 (clone 69.1), evaluated in a blinded fashion and scored on a degree of positivity (S0= 0-4% cells positive; S1=5-14%; S2= 15-50%; and S3=>50%) and intensity (0-none, 1-mild, 2-moderate, 3-strong).

Results: AMACR and IMP3 immunostain results are summarized (table 1). No staining was seen in all 12 cases of BE. 1/9 (11.1%) cases of BE-IND was positive for IMP3 (with follow-up of EAC) but all were negative for AMACR. AMACR and IMP3 were positive in 18.75% vs. 31.25% of BE-LGD, 16.7% vs. 50% of BE-HGD, and 38.8% vs. 88.8% of EAC respectively. The extent and intensity of stain was diffuse and stronger with IMP3 than AMACR in all cases (table 2).

AMACR and IMP3 expression

AMACR Positivity (n)					
LESION (# of cases)	S0	S1	S2	S3	Positive cases sensitivity (%)
BE (12)	12	0	0	0	0/12 (0%)
BE-IND (9)	9	0	0	0	0/9 (0%)
BE-LGD (16)	13	1	0	2	3/16 (18.7%)
BE-HGD (12)	10	0	2	0	2/12 (16.7%)
BE-AC (18)	11	1	3	3	7/18 (38.8%)
IMP3 Positivity (n)					
LESION (# of cases)	S0	S1	S2	S3	Positive cases
BE (12)	12	0	0	0	0/12 (0%)
BE-IND (9)	8	0	0	1	1/9 (11.1%)
BE-LGD (16)	11	0	2	3	5/16 (31.2%)
BE-HGD (12)	6	0	2	4	6/12 (50%)
BE-AC (18)	2	0	2	14	16/18 (88.8%)

Intensity of staining for AMACR and IMP3

AMACR Positivity (n)			
LESION (# of cases)	1	2	3
BE (n=12)	0 (0)	0 (0)	0 (0)
BE-IND (n=9)	0 (0)	0 (0)	0 (0)
BE-LGD (n=16)	2 (12.5)	0 (0)	1 (6.2)
BE-HGD (n=12)	1 (8.3)	1 (8.3)	0 (0)
BE-AC (n=18)	4 (22.2)	1 (5.5)	2 (11.1)
IMP3 Positivity (n)			
LESION (# of cases)	1	2	3
BE (n=12)	0 (0)	0 (0)	0 (0)
BE-IND (n=9)	0 (0)	0 (0)	3 (33.3)
BE-LGD (n=16)	2 (12.5)	0 (0)	0 (0)
BE-HGD (n=12)	0 (0)	3 (25)	3 (25)
BE-AC (n=18)	0 (0)	5 (27.8)	11 (61.1)

Conclusions: Our study shows that IMP3, has the same specificity (100%) but a better sensitivity, intensity, and extent of staining than AMACR, and may be used as an adjunct with, or as an alternative to AMACR, in detecting difficult cases of dysplasia or EAC in BE.

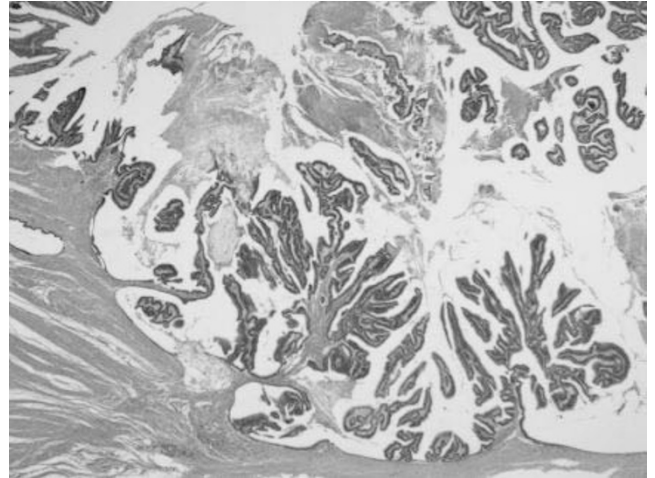
714 Adenoma-Like Adenocarcinoma: A Subtype of Colorectal Carcinoma with Good Prognosis, Deceptive Appearance on Biopsy, and Frequent KRAS Mutation

RS Gonzalez, MK Washington, C Shi. Vanderbilt University Medical Center, Nashville, TN.

Background: Biopsy of a colorectal carcinoma (CRC) occasionally yields tissue that can only be diagnosed as an adenoma microscopically. While this could be due to sampling of a precursor lesion, we have identified a subset of CRCs that architecturally and cytologically resemble adenomatous change, making them difficult to diagnose as malignant on biopsy.

Design: Slides from 1,003 CRC resections were reviewed for an adenoma-like invasive component. We recorded staging information, patient follow-up, whether residual precursor adenoma was present, and whether prior biopsy had been diagnosed as adenoma or CRC. Mutational analysis on *KRAS*, *NRAS*, *BRAF*, *PIK3CA*, *AKT*, *PTEN*, and *SMAD4* was performed using a lab-developed assay.

Results: Twenty-nine cases (3%) demonstrated adenoma-like features, defined as architectural and cytologic blandness such that observing the tissue on biopsy would not allow for the diagnosis of CRC; the glandular architecture resembled that of adenomas, and the lesions lacked dirty necrosis, high-grade nuclear features, desmoplasia, and tumor budding (Figure). These features comprised from 10 to 100% of a lesion. Twenty-two cases (76%) also showed mucinous features at the leading invasive edge. While 21 cases showed advanced T-category (T3 or T4), only 6 cases had nodal metastases, and 4 had distant metastases (2 lung, 1 liver, 1 omentum). Thirteen cases had prior biopsies called adenoma; 16 resection cases showed no adenoma, including 8 cases called adenoma on biopsy. Average follow-up length was 57 months. Two patients died of disease, at 108 and 140 months; 19 were alive at last follow-up. *KRAS* mutation was seen in 8/12 (75%) cases, all but one located at codon 12 or 13. Two of these cases also harbored a *PIK3CA* H1047R mutation. Microsatellite instability (MSI) testing was done on 9 cases, 3 of which were MSI-high with wild-type *BRAF*.



Conclusions: Adenoma-like adenocarcinoma is a subset of CRC with a low rate of metastasis and a good prognosis. Diagnosis of this lesion as carcinoma may be challenging on biopsy, as the surface component resembles an adenoma despite being invasive. In addition, although this type of CRC has a good prognosis, it frequently harbors *KRAS* mutations.

715 Clinical, Pathologic, and Molecular Features of Colorectal Carcinoma with Micropapillary Features

RS Gonzalez, MK Washington, C Shi. Vanderbilt University Medical Center, Nashville, TN.

Background: Micropapillary (MP) features have recently been described in colorectal carcinoma (CRC), though characterization of this subset is still ongoing. Here, we report our pathologic, clinical, and molecular findings in MP CRC.

Design: Slides from 1,003 CRC resections were reviewed for at least focal MP features. We recorded the percentage of the tumor that was MP and the histologic features present in the remaining tumor. We performed staging and recorded patient follow-up data. In addition, mutational analysis on *KRAS*, *NRAS*, *BRAF*, *PIK3CA*, *AKT*, *PTEN*, and *SMAD4* was performed using a lab-developed assay.

Results: We identified 35 cases (3%) with MP features, which were defined as small papillary clusters of malignant cells with prominent eosinophilic cytoplasm occupying lacunar spaces and lacking fibrovascular cores. The percentage of MP features ranged from $\leq 10\%$ (16 cases) to 100% (1 case). The MP component was frequently associated with dense hypercellular stromal reaction. Twenty-four cases featured a prominent cribriform pattern in the non-MP malignant glands, with dirty necrosis present in the small lumina. Eight displayed mucinous features, including 5 wherein the MP component existed solely in a mucinous background. Average patient age was 60 years, and male:female ratio was 1.5:1. Thirty-one cases showed advanced T-category (T3 or T4), 27 cases had lymph node metastases, and 19 had distant metastases; the nodal metastases often appeared as large cystic spaces lined by malignant epithelium and harboring abundant dirty necrotic material, though nodal metastases in 9 cases showed MP features. Average follow-up length was 45 months. Fifteen patients died of disease, with an average survival length of 25 months (range: 1-71 months); 14 were alive at last follow-up. Gene mutations were seen in 7/12 cases, including 5 cases with *KRAS*

mutation at codon 12 or 13, 1 case with *BRAF* V600E mutation only, and 1 case with both *BRAF* V600E and *SMAD4* R361H mutations. In 3 cases, mutational analysis was performed on both cribriform and micropapillary areas separately, with no difference in mutational profile observed. Microsatellite instability (MSI) testing was done on 6 cases; all were MSI-stable.

Conclusions: MP features in CRC portend an aggressive course, with a high likelihood of advanced local disease, nodal and distant metastases, and a poor prognosis. Cases with focal MP features often show cribriforming glands elsewhere and cystic nodal metastases with prominent necrosis. In addition, they are associated with frequent *KRAS* and *BRAF* mutations.

716 Clinicopathologic and Molecular Correlates of Tumor Budding in Colorectal Carcinoma

RP Graham, R Vierkant, LS Tillmans, AH Wang, DJ Weisenberger, CF Lynch, AJ French, SL Slager, SN Thibodeau, JR Cerhan, PJ Limburg, TC Smyrk. Mayo Clinic, Rochester, MN.

Background: Tumor budding has been proposed as a prognostic factor in colorectal carcinoma (CRC) and is being incorporated into routine clinical practice. The correlation of tumor budding to molecular events and specific CRC pathways has not been investigated.

Design: We retrieved hematoxylin and eosin-stained slides from 553 cases of CRC diagnosed between 1986 and 2002 among women enrolled in the Iowa Women's Health Study. We recorded tumor grade, venous, lymphatic and perineural invasion, tumor morphologic patterns, maximum number of tumor infiltrating lymphocytes (TILs) per 40x objective field, and the maximum number of tumor buds per 20x objective field. Tumor budding was classified as high if ≥ 10 buds were seen in a 20x objective field and low if fewer or no buds were identified. Each patient had been previously characterized for clinical parameters including smoking history, treatment with chemotherapy, tumor stage, cancer-specific survival and for molecular alterations including microsatellite instability (MSI), *KRAS* and *BRAF* mutation status, and CpG island methylation (CIMP) status. Histologic review was done blinded to all clinical and molecular data. Statistical analysis was performed to determine the correlations between high tumor budding and other evaluated parameters.

Results: High tumor budding was identified in 180 cases (32.5%) and 83% of these cases were microsatellite stable (MSS) compared to 68% for cases with low budding ($p=0.003$). Increasing numbers of TILs were inversely related to tumor budding. MSI-high cases featured a median of 3 tumor buds compared to a median of 6 tumor buds for cases which were MSS or MSI-low. Tumors with high tumor budding were also characterized by *KRAS* mutations (42% vs 28%; $p=0.006$), advanced stage (78% vs 54%; $p<0.0001$) and receipt of chemotherapy (30% vs 20%; $p=0.02$). There was no correlation between tumor budding and *BRAF* mutation or CIMP status. Kaplan-Meier survival analysis revealed high tumor budding was associated with a worse cancer-specific survival. On multivariate analysis, including all evaluated parameters, high tumor budding was associated with a greater than 2-fold risk of cancer-specific mortality (adjusted HR = 2.11, 95% CI 1.42-3.12).

Conclusions: In this cohort of women with CRC, tumor budding is a marker of aggressive tumor biology, strongly associated with advanced stage and also with MSS, *KRAS* mutations and more cancer-related events. High tumor budding is a predictor of cancer-specific survival.

717 Rates of HER2 Positivity at the Gastroesophageal Junction vs Distal Stomach: Are the Differences Solely Due to Histology?

A Grin, E Hsieh, W Hanna, P Henry, S Hafezi-Bahktari, H El-Zimaity, C Howlett, J Parfitt, EC Marginean, MY Ngai, J Ramsay, T Aziz, CJ Streuter. St. Michael's Hospital, University of Toronto, Toronto, ON, Canada; Sunnybrook Health Sciences Centre, University of Toronto, Toronto, ON, Canada; University Health Network, University of Toronto, Toronto, ON, Canada; London Health Sciences Centre, London, ON, Canada; University of Ottawa, Ottawa, ON, Canada; Health Sciences North, Sudbury, ON, Canada; Hamilton Health Sciences Centre, Hamilton, ON, Canada.

Background: The ToGA trial demonstrated that gastric and gastroesophageal junction (GEJ) adenocarcinomas (AC) respond to trastuzumab, a monoclonal antibody to the HER2/neu receptor. It showed significant differences in the rate of HER2 positivity between GEJ AC (33%) vs distal stomach (21%). Positivity was most often seen in well- to moderately-differentiated intestinal type tumors. These differences were not replicated in later studies. We postulated that the observed differences in HER2 positivity may be related to the greater incidence of diffuse type AC in the stomach vs the distal esophagus/GEJ (E/GEJ) rather than an inherent biologic difference.

Design: We reviewed cases tested as part of the Ontario Gastric AC testing program for data on tumour site (distal esophagus/GEJ vs cardia vs distal stomach) and histology (diffuse/mixed vs intestinal type). Data was correlated with HER2 status.

Results: Overall, 264 of 1166 cases were positive for HER2 (22.6%); 770 cases had data for histologic type of AC (Table 1). HER2 positivity rates in AC arising in the distal stomach and cases of gastric AC site not specified (Stomach NOS) were lower than in proximal gastric AC and E/GEJ AC. However, when the comparison was limited to tumours of intestinal type, there was no significant difference in rate of HER2 amplification.

Conclusions: Our results indicate that differences in Her2 positivity between E/GEJ AC and gastric AC are due to the higher proportion of diffuse type AC in the distal stomach compared to proximal stomach and E/GEJ AC. The HER2 amplification rates in intestinal type AC across all sites are comparable, arguing against significant biologic differences in this area.

Rates of HER2 Amplification by Site and Histology

Location	# of cases	HER2 + (%)	# with Known Histology	Diffuse/Mixed Cases (%)	HER2 + in diffuse/mixed AC (%)	HER2+ in intestinal type AC (%)
E/GEJ	441	123 (27.9%)	297	33/297 (9.1%)	3/33 (9.1%)	88/264 (33%)
Cardia	30	9 (30%)	28	5/28 (17.9%)	1/5 (20%)	6/23 (26.1%)
Distal Stomach	190	43 (22%)	188	59/188 (31.2%)	2/59 (3.4%)	41/129 (31%)
Stomach NOS	505	89 (17.6%)	257	112/257 (43.6%)	6/112 (5.3%)	43/145 (29.7%)
Total	1166	264 (22.6%)	770	207/770 (27%)	12/207 (5.7%)	178/561 (31.7%)

718 A Refined IBD Histopathologic Grading System (ECAP Scheme) – More Sensitive and Informative in Assessment of Mucosal Healing

X Gui, M Fort Gasia, S Ghosh, M Iacucci. University of Calgary, Calgary, AB, Canada.

Background: Histologic grading of mucosal inflammation is required in evaluation of disease activity and treatment effect in inflammatory bowel diseases (IBD). A new trend of using high definition endoscopy to assess mucosal healing particularly demands a meaningful histologic correlation. We developed a modified histologic grading system to meet clinical needs.

Design: ECAP system was designed to fully reflect all histologic changes in IBD, categorized as **E**xtent of inflammation (*focal, multifocal, diffuse*), **C**hronicity (*crypt architectural alteration, Paneth cell metaplasia*), **A**ctivity (*cryptitis, crypt abscess, crypt destruction, lamina propria cellularity and neutrophils, basal plasmacytosis, surface epithelium injury*), and **P**lus others (*eosinophilia and lymphoid follicles*). Each category/element was graded and scored. Total ECAP/ECA scores were also obtained. It was applied in 60 UC patients (F 21, M 39, 19-90 yo) with focus on assessing mucosal healing by high definition iSCAN, a novel endoscopic imaging showing various mucosal and vascular patterns that were also graded. ECAP scores were correlated with the grades of mucosal pattern and vascular pattern on iSCAN as well as with Mayo endoscopic scores. An established histologic grading system, New York Mount Sinai / Harpaz Scheme, was used for comparison.

Results: Our system was validated by Harpaz Scheme with regards to grading inflammation activity. ECAP scores, total or individual ones, were significantly correlated with both mucosal and vascular patterns on iSCAN. The strongest correlation between histologic and iSCAN findings existed in the extent and activity of inflammation. Mucosal or vascular pattern on iSCAN represented the degree of mucosal inflammatory and architectural changes. Of 12 patients with normal routine endoscopy (i.e. Mayo score 0), 7 had abnormal vascular pattern and 6 had abnormal mucosal pattern on iSCAN. On ECAP scoring, 100% of patients showed minor histologic abnormalities including crypt architectural alteration (11), abnormal surface epithelium (6), cryptitis (3), crypt destruction (2), laminal propria neutrophil infiltration (3), increased mononuclear cells (6), and basal plasmacytosis (5).

Conclusions: Our modified ECAP system is sensitive and informative in assessing mucosal changes in IBD. By using it in combination with high definition endoscopy, subtle histologic abnormalities underlying seemingly healed mucosa can be detected and various endoscopic patterns can be understood on histologic grounds.

719 Diagnosis of H. pylori Gastritis on H&E Stains: A Comparison of Community and Academic Pathologists

D Gui, HL Wang, V Ciobanu, N Amini, K Mislick, S Dry. UCLA, Los Angeles, CA.

Background: The cost-effectiveness and necessity of up-front staining for *H. pylori* (HP) on all gastric biopsies has been questioned recently. HP detection studies have involved academic pathologists, but not community pathologists. We compared rates of detection and suspicion for HP between community and academic GI subspecialty pathologists in a series of chronic gastritis cases.

Design: A total of 271 cases of chronic gastritis on which up front Giemsa or HP immunostaining (HP IHC) had been performed were identified in our academic medical center and associated community hospitals. Cases were reviewed by 3 pathologists, including 1 community pathologist (CP) and 2 academic pathologists with a subspecialty GI practice (AP-GI). Diagnosis (positive, suspicious, negative for HP) was first made on H&E, then special stains (SS) were reviewed.

Results: HP was definitively identified on H&E by both CP and AP-GI in 76/271 cases (28%), which were confirmed by SS. In an additional 24 cases (9%), HP was either suspected or identified on H&E (confirmed by SS) by all pathologists. Discordant interpretations were seen in 10 HP IHC and 2 Giemsa cases between CP and AP-GI, including 2 cases with rare organisms and 2 with nonspecific staining. CP called 43 (16%) cases "suspicious" on H&E, compared to 56 (20%) by AP-GI; 33 of these cases had concordant "suspicious" diagnoses. AP-GI was more likely to have negative SS in "suspicious" cases (45%) in contrast to 35% of CP cases. Both CP and AP-GI diagnosed 114 (42%) cases as negative by H&E (confirmed by SS).

Conclusions: On H&E alone, CP and AP-GI had concordant positive or negative HP diagnoses in 70% of cases (190/271). SS were more likely to be negative in AP-GI's "suspicious" cases, probably due to more frequent identification of HP on H&E and greater diagnostic caution. Our study supports calls for using HP SS only if initial review of H&E slides is suspicious, as a more cost-effective protocol in both community and academic practices.

720 Histopathologic Outcome of Microscopic Colitis – A 14 Year Experience

X Gui, Y Yan, P Beck, M Iacucci, S Ghosh. University of Calgary, Calgary, AB, Canada.

Background: Microscopic colitis (MC), i.e. lymphocytic colitis (LC) and collagenous colitis (CC), is a poorly understood low-grade colonic inflammation. Some case reports

suggested that MC can evolve into IBD and that LC can transform to CC and vice versa. However, a large series data regarding histopathologic outcome of MC is scarce. We carried out a study in a Canadian city with a population of 1.2 million.

Design: We retrieved all cases of MC diagnosed over 14 years (1999-2012) from the database of Calgary Laboratory Services, the sole pathology lab serving entire Calgary. The biopsies before and after the first diagnosis of MC were also reviewed. Four subgroups of patients were identified: 1) Good responder (later biopsy normalized), 2) Poor responder (disease persisted till most recent biopsy), 3) Evolved to IBD (IBD diagnosed on later biopsy and confirmed clinico-endoscopically), and 4) Transformed from IBD (MC pattern in otherwise normalized mucosa when IBD was in remission). **Results:** In total, 2687 colonic biopsies of 2324 patients (F 1810, M 314, 15-97 yo) were identified, including LC 963 and CC 1724 (371 with combined LC-CC in different areas of bowel). The subgroups are shown in Tables 1.

Table 1: Four Characteristic Subgroups of MC

Subgroups / Outcome	Number of Cases / (M/F)	% Total Cases	LC/CC / LC-CC	IBD (UC/CD)	Age (Range / Average)	Time of Transition (mons) (Range / Average)
Group 1 / Good Responder	112 (27/85)	4.82	80/30/2		15-88 / 59	2-143 / 41
Group 2 / Poor Responder	173 (31/142)	7.44	78/85/10		16-97 / 65	1-155 / 48
Group 3 / MC to IBD	20 (7/13)	0.86	16/3/1	8/12	30-95 / 61	0-69 / 19
Group 4 / IBD to MC	24 (7/17)	1.03	17/5/2	13/11	29-77 / 55	7-216 / 69

In Group 1 cases, 2 recurred after 1-5 years. Of Group 3 cases, 1 showed coexisting MC and CD in different regions, and 1 developed CD a year after MC was resolved. In another case MC and UC were transformed back and forth over 13 years. MC pattern (LC vs CC vs LC-CC) also changed in some patients, particularly common in Group 2, over the disease course, as shown in Table 2.

Table 2: MC Pattern Shifts Over Disease Course

Pattern Changes	Number of Cases	% of Total Cases
LC → CC	27	1.16
CC → LC	21	0.90
LC ↔ CC	6	0.26
LC → LC/CC	5	0.22
CC → LC/CC	2	0.09
LC/CC → LC	6	0.26
LC/CC → CC	6	0.26

The remaining 1991 patients had no follow-up biopsies.

Conclusions: A small subset (~1%) of MC patients evolved to IBD, whereas a similar proportion of cases were downgraded from treated IBD. Occasionally, MC and IBD coexisted in different regions of bowel. Our findings further support a similarity and link between MC and IBD in pathogenesis.

721 An International Survey on Sessile Serrated Adenomas/Polyps (SSA/P)

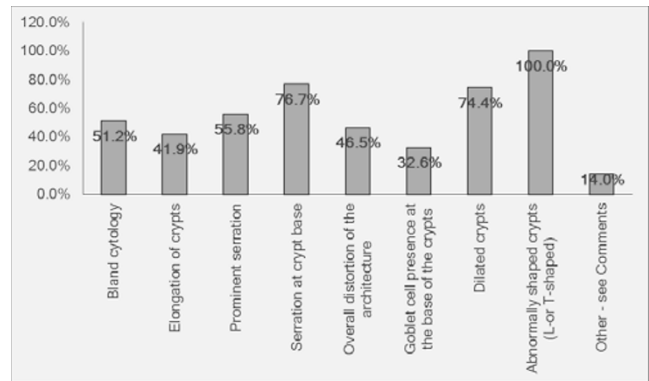
S Hafezi-Bakhtiari, L Wang, AC Bateman, EE Torlakovic, R Chetty. University Health Network, Toronto, Canada; Oxford University Hospitals, Oxford, United Kingdom; University Hospital Southampton, Southampton, United Kingdom.

Background: There still appears to be a lack of awareness regarding diagnostic criteria, terminology and implications of SSA/P. The aim of this survey was to ascertain the approach of Pathologists to SSA/P.

Design: An online questionnaire was circulated to 43 pathologists ascertaining:

1. Type of practice
2. Frequency of all GI polyps encountered
3. Frequency of diagnosis
4. Site of: only the right or left colon, or both
5. Histological criteria used (fig 1)
6. Minimum histological criteria
7. How often are levels performed
8. Use of Ki-67
9. When diagnosing SSA/P, are additional comments made
10. Clinical implications of diagnosis
11. Are clinicians aware of the implications of SSA/P
12. If clinicians are unaware, is a comment made in the report
13. Is there a surveillance program for SSA/P in your institution.

Results: 88% had a special interest in GI pathology. 14% made the diagnosis of SSA/P at least once a week, 81% diagnosed SSA/P in both the left/right colon and 19%, in the right colon only. 70% required "several" crypts to display at least one characteristic histologic feature. 7% did not request deeper sections and 88% did not use Ki67. 12% did not comment on dysplasia but 98% were aware of the clinical implications of SSA/P. Over one-third felt clinicians were unaware of the implications of SSA/P but still 33% did not provide a comment. 67% of participants either did not know if their institution had a surveillance program and/or claimed a surveillance program did not exist.



Conclusions: The site (right vs. left) was a source of bias. The vast majority resorted to deeper sections, but very few used Ki-67. A significant number did not provide an alerting comment to the clinician. Furthermore, only one histologic criterion (abnormally shaped crypts) was stated by all participants as necessary for the diagnosis. Despite the latest ACG recommendation, the majority of participants needed more than one crypt to show typical features to diagnose SSA/P. Despite increasing awareness of SSA/P in the last few years, a more standardized, universally-accepted approach is necessary for minimum diagnostic criteria and surveillance guidelines.

722 Tubulovillous/Villous Adenomas and Traditional Serrated Adenomas in the Left Colon and Rectum Show Histologic Overlap

S Hafezi-Bakhtiari, S Serra, R Colling, L Wang, R Chetty. University Health Network, Toronto, Canada; Oxford University Hospitals, Oxford, United Kingdom.

Background: Traditional serrated adenomas (TSA) and tubulovillous/villous adenomas (TVA/VA) are preneoplastic lesions of the colorectum that lead to colorectal cancer. They progress through potentially different molecular pathways but can pose a diagnostic challenge. The purpose of this study was to explore whether the accepted histologic features of TSA were also seen in TVA/VAs.

Design: 180 polyps of left colon/rectum diagnosed as TVA/VAs (randomly retrieved from archives of the Pathology departments at UHN, Canada and Oxford, UK over a 2-year period) were reviewed and evaluated for the presence of: luminal serration, ectopic crypt formation (ECF)-defined as abnormal development of crypts with loss of orientation toward the muscularis mucosae- leading to short disoriented crypts not reaching the muscularis mucosae and, cytoplasmic eosinophilia.

Results: After review, 20/180 cases were re-diagnosed as pure TSAs or, mixed/hybrid TVA/TSA and these cases were excluded from this study.

1. Luminal serration typical of TSA was not present in any of the pure TVA/VAs
2. ECFs were noted in 55/160-34%- of cases (few <10: 5/160, occasional -10-20: 42/160, frequent->20: 8/160)
3. Cytoplasmic eosinophilia was present in 10/160 of cases (6.2%) cases
4. No correlation was noted between presence of cytoplasmic eosinophilia and ECFs.

Conclusions: Although ectopic crypt formation and cytoplasmic eosinophilia represent prominent and characteristic features of TSAs, they may also be present in a subset of TVA/VAs in left colon. Regardless of presence or absence of ECFs or cytoplasmic eosinophilia, characteristic luminal serration described in TSAs however was not identified in any of the TVA/VAs in our series. Based on our findings, characteristic serration seems to be the most reliable and unique histologic finding in TSAs.

723 Low Risk of Advanced Outcomes in Patients with Serrated Polyps of the Right Colon: A Long Term Outcome Study of 665 Patients

C Hagen, J Anderson, MA Greene, A Andrew, M Goodrich, C Robinson, A Dietrich, L Buttery, A Srivastava. Dartmouth-Hitchcock Medical Center, Lebanon, NH; Brigham and Women's Hospital, Boston, MA.

Background: Prior to 2003, sessile serrated polyp/adenomas (SSP/A) were diagnosed as hyperplastic polyps (HP) and treated as benign lesions with no surveillance implications. HP involving the right colon diagnosed prior to 2003 should, therefore, be associated with a higher than expected incidence of advanced outcomes and this hypothesis was tested in our study.

Design: A retrospective data search was performed for all patients diagnosed with a polyp involving the right colon over a ten year period from 1993-2003. Index colonoscopy was defined as the first colonoscopy at which a neoplastic polyp was identified. Patient demographic and outcome data was retrieved by medical chart review. Polyp level data (location, number, size, histologic type) was retrieved from endoscopy and pathology reports. *Advanced adenoma* was defined as adenoma >1.0cm in size, with a villous component, or high-grade dysplasia. *Advanced outcomes* were defined as any advanced adenoma, multiple (≥3 adenomas), or cancer.

Results: 665 patients (mean age 60.9 years; M:F=375:290) with a neoplastic polyp at index examination and at least one follow up colonoscopy formed the study group. Median follow up duration was 39 mths (interquartile range: 25-60 mths). 9 patients developed cancer at first follow up colonoscopy. The rate of incident advanced outcomes at first follow up colonoscopy stratified by the most advanced lesion on index colonoscopy is shown in Table 1.

Polyp at Index Exam*	# Patients	# Advanced Outcome on Follow Up
NDSP Left Colon	53	6 (11.3%)
NDSP Right Colon (<1.0cm)	135	13 (9.6%)
NDSP Right Colon (≥1.0cm)	27	1 (4%)
1-2 Conventional Adenomas	308	34 (11%)
≥3 Conventional Adenomas	49	11 (22.4%)
Advanced Adenoma	93	23 (24.7%)

*NDSP=non-dysplastic serrated polyp (HP or SSP)

When all follow up colonoscopies were included, 8.9% (12/135) of patients with small (<1.0cm) HP and 7.4% (2/27) of patients with large (≥1.0cm) HP at index exam had an advanced outcome on follow up, compared to 16.2% (50/308) of patients with 1-2 conventional adenomas, and 31% (44/142) of patients with advanced or multiple adenomas. On multivariate analysis, age at time of endoscopy (per year) (OR=1.05; 95% CI: 1.03-1.08) and advanced adenoma (OR=2.03 95% CI: 1.11-3.72) at index colonoscopy were the best predictors of advanced outcomes.

Conclusions: Non-dysplastic serrated polyps of the right colon, even when ≥1.0cm in size and managed by minimal surveillance, are associated with a low risk of advanced outcomes, and may not need aggressive surveillance.

724 Evaluation of Basal Crypt Dysplasia in Neoplastic BE: A Single Center Study of EMR Specimens

C Hagen, D Forcione, W Puricelli, C Hur, N Nishioka, GY Lauwers. Massachusetts General Hospital, Boston, MA.

Background: Basal crypt dysplasia (BCD) arising in Barrett's esophagus (BE) is a dysplastic variant defined by the presence of dysplastic changes exclusively located in metaplastic crypts, without surface involvement. BCD has been noted in about 7.3% of BE patients. It is also believed to be an indicator of surface mucosal neoplasia, as 87% of patients with BCD previously or concurrently are diagnosed with dysplasia or adenocarcinoma.

Design: A consecutive series of 148 endoscopic mucosal resections (EMR) for BE associated neoplasms from 85 patients was evaluated for the presence of BCD. In each case, the distance between BCD and the advancing edge of the neoplastic lesion as well as the distance from the margin of resection was evaluated. Finally, the presence of BCD was correlated with the grade and phenotype of the resected neoplastic lesions and the rate of recurrence.

Results: 29 foci of BCD were identified in 23 EMR from 18 patients. Within the BCD group, 9% (2/23) of EMR were negative for surface dysplasia and 9% were associated with low-grade dysplasia (LGD), 39% (9/23) with high-grade dysplasia (HGD), and 39% with intramucosal carcinoma (IMC). Relative to the non-BCD group, the BCD group contained proportionally more low-grade lesions (BCD and LGD; p=0.0064). Table 1 shows all EMR stratified by dysplasia grade and presence of BCD.

	No Surface Dysplasia	LGD	HGD	IMC	Invasive Ca.
EMR w/ BCD (n=23)	2 (9%)	2 (9%)	9 (39%)	9 (39%)	1 (4%)
EMR w/out BCD (n=125)	0 (0%)	6 (5%)	32 (26%)	56 (45%)	31 (24%)

15 foci of BGD were sufficiently well-oriented to allow measurements. The distance between BCD and the main lesions ranged from 619 to 5366 μm (mean 2181 μm). The distance from the closest lateral margin to the BCD ranged from 414 to 8791 μm (mean 2616 μm). In 15 of 23 (65%) EMRs, BCD was associated with neoplasms of intestinal/hybrid phenotype. Lesions with a foveolar phenotype were associated with 35% of the cases (8/23). These findings were not statistically different from the non-BCD group (p=0.4688). Of the 14 patients within the BCD group with long term follow up (mean:29 mos.), no recurrences were observed.

Conclusions: BCD is associated with a subset of neoplastic BE, present in 15.5% (23/148) of the evaluated EMRs. The proportional association of BCD with low grade lesions suggests BCD serves as a precursor lesion to BE neoplasia. Despite the distribution of BCD at the periphery of resected neoplasias, there does not appear to be an increased risk of neoplastic recurrence.

725 Clinicopathological Spectrum of Stercoral Colitis with Distinctive Cohort-Related Localizations and Severity

A Harbhajanka, D Murro, S Jakate. Rush University Medical Center, Chicago, IL.

Background: Stercoral colitis results from injury caused by fecal impaction. A variety of causes including impaired colonic motility and luminal obstruction may produce stercoral injury. While microscopic changes are nonspecific, clinical presentation varies widely and includes localization to different parts of the colon and varying symptoms such as chronic constipation, overflow diarrhea, abdominal pain, abdominal distention, rectal bleeding, perforation and fatality. We conducted a study to determine if cohorts can be identified with predictive patterns of age, gender, cause, location and severity.

Design: We searched our clinical and pathology databases for the diagnosis of stercoral colitis (25 patients). Histological diagnosis in all cases was verified with other causes such as infectious and ischemic colitis and IBD excluded. We then reviewed the distribution of age, gender, etiology, presentations, colonic sites involved and complications.

Results: The mean age of the entire group was 70 (range 25-97). The majority were females (20/25 or 80%) and 13/25 (52%) were >70. Impaired colonic motility was seen in 15/25 patients, with potentially age-related hypo-motility (9/11 females, median age 85, range 63-97) and colonic inertia (4/25 females, median age 42, range 25-58). These groups presented with constipation, overflow diarrhea and rectal bleeding and showed rectal/rectosigmoid ulcerations without perforation. Obstructive stercoral injury was seen in 10/25 cases (7 females and 3 males, median age 66, range 52-80) either due to diverticulosis (4), carcinoma (3), adhesions (2) or extrinsic compression (1). This group presented with severe abdominal pain, abdominal distention and had high rate of perforation (4/10 cases). Stercoral injury occurred proximal to the obstruction which was anywhere from cecum to the descending colon.

Conclusions: The cohorts in stercoral colitis can be clearly separated in two groups. The larger group (60%) consists of impaired colonic motility related either to advanced age (44%, median age 85) or colonic inertia (16%). In this group, there is overwhelming female preponderance (87%); constipation, overflow diarrhea and rectal bleeding are most common; perforation is rare and the most distal part of the colon (rectum and rectosigmoid) is affected. In the second smaller group (40%), stercoral colitis occurs proximal to an obstructive process (40% cases); F:M ratio is about 2:1; symptoms are severe with acute abdominal pain and distention; any part of colon proximal to the obstruction may be involved and risk of perforation is high.

726 Comparison of Cytokeratin/D2-40 Dual Immunostain with Conventional H&E Detection of Angiolymphatic Invasion and the Risk of Nodal Metastasis in Superficial Esophageal Adenocarcinoma

SM Hastings, MS Landau, KS Nason, DJ Hartman, JM Davison. UPMC, Pittsburgh, PA.

Background: Assessing the probability of lymph node metastasis in the pre-operative setting helps determine whether superficial (stage pT1) esophageal adenocarcinoma (EAC) is amenable to endoscopic management. Angiolymphatic invasion (ALI) is a significant risk factor for lymph node metastasis, but it is sometimes difficult to diagnose on routine histologic sections. To address this, we evaluated a keratin/D2-40 dual immunostain for detecting lymphatic invasion.

Design: Blinded to node stage, two pathologists independently evaluated 111 superficial EAC treated by esophagectomy alone (31 T1a and 80 T1b) using both H&E sections of the primary tumor and a cytokeratin AE1/AE3 plus D2-40 (CK/D240) dual color immunostain. On H&E, ALI was defined as tumor cells within endothelium lined spaces (Figure 1A). By dual stain, a focus of ALI was defined as keratin positive tumor cells completely encircled by D2-40 positive endothelium (Figure 1B). The total number of ALI foci were quantified by dual stain. Risk of nodal metastasis, performance characteristics and interobserver agreement (IOA) were assessed.

Results: Twenty-three cases were positive for ALI by H&E, compared to 30 by CK/D240 (Table 1). By H&E, 9/20 node positive cases had ALI, compared to 11/20 by CK/D240 (Table 1). There was a significant, >4-fold increased odds of nodal metastasis associated with ALI by either method (Table 1). Compared to cases with no ALI by dual stain, the odds of nodal metastasis was significantly higher in cases with ≥3 foci of ALI, but not in cases with only 1-2 foci (Table 1). There was excellent IOA for ALI on H&E (94.6% of cases, κ=.830), but even greater IOA with the dual stain (98.2% of cases, κ=.950).

Conclusions: Detection of ALI by H&E or CK/D240 is associated with >4-fold increased risk of nodal metastasis in superficial EAC, but the dual immunostain detects ALI in a greater number of node positive cases. The odds of node metastasis increases as the number of CK/D240+ foci of ALI increases. There is slightly better IOA with the dual stain than conventional H&E for evaluating this important risk factor, possibly due to ease of interpretation.

Figure 1. (A) Two foci of ALI recognizable on H&E (arrows). (B) Three foci of CK+ tumor cells completely encircled by D2-40 positive endothelium on the dual immunostain in the same tumor (arrows).

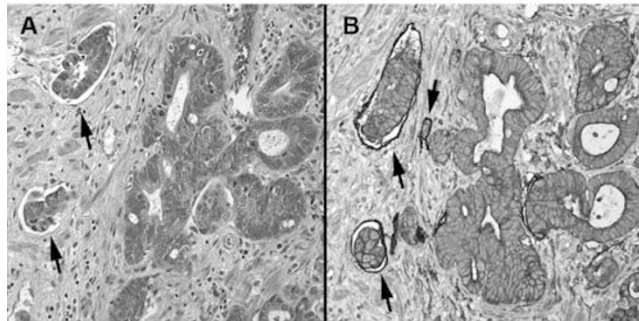


Table 1. Association between angiolymphatic invasion (ALI) and lymph node metastasis at esophagectomy in superficial (pT1) esophageal adenocarcinoma: H&E interpretation versus CK/D2-40 dual immunostain.

Angiolymphatic Invasion	Node Metastasis at Esophagectomy		Odds Ratio (95% CI)
	Negative (N = 91)	Positive (N=20)	
H&E Interpretation			
Negative for ALI	77	11	1.0
Positive for ALI	14	9	4.5 (1.6-12.8)*
CK/D240 Interpretation			
Negative for ALI	72	9	1.0
Positive for ALI	19	11	4.6 (1.7-12.8)†
No. CK/D240+ Foci of ALI			
None	72	9	1.0
1-2 foci of ALI	11	3	2.2 (0.5-9.3)§
≥3 foci of ALI	8	8	8.0 (2.4-27)¶

ALI, angiolymphatic invasion; CK/D240, cytokeratin/D2-40 dual color immunostain; * P=.005; † P=.003; § P=.292 vs none; ¶ P=.001 vs none

727 Clinical Significance of Interobserver Variability in Interpreting Barrett's Esophagus Biopsies with a Diagnosis of Indefinite for Dysplasia
B Horvath, D Allende, R Pai, D Patil, T Plesec, H Xie, P Thota, P Singh, X Liu.
 Cleveland Clinic, Cleveland, OH.

Background: Barrett's esophagus (BE) carries an increased risk for esophageal adenocarcinoma and patient may undergo surveillance biopsies. Biopsies are classified as indefinite for dysplasia (IND), when the epithelial abnormalities are not sufficient to diagnose dysplasia or the nature of the epithelial abnormalities is uncertain due to inflammation or sampling. Furthermore, there are no consensus guidelines directing the management of BE IND. This study aimed to assess the interobserver variability in IND and to examine the potential effect of this variability on practice.

Design: 281 biopsies from 107 cases were reviewed by 5 GI pathologists. All cases contained at least one biopsy that had been previously diagnosed as BE IND. Each reviewer classified cases independently based on the revised Vienna classification. Interobserver agreement was calculated on both biopsy and case levels. In addition, the results of each reviewer and a set of simulation by pooling results from all 5 reviewers were correlated with the patients' outcome. Our set of simulation (S1, S2, S3, S4, and S5) corresponds to scenarios requiring 1, 2, 3, 4, or 5 pathologists to agree upon an interpretation of IND on at least 1 biopsy level for any given case to be considered as IND.

Results: A fair interobserver agreement was reached on both biopsy and case levels among 5 reviewers with Fleiss' kappa 0.33 (95% CI: 0.26-0.39) and 0.28 (95% CI: 0.20-0.38), respectively. Thirty patients (28.7%) had dysplasia on their follow-up biopsies and therefore their initial IND diagnoses were considered clinically significant. There was a considerable variability in diagnosing clinically significant IND among 5 reviewers and a set of simulation (Table 1).

Table 1: Performance of each reviewer and a set of simulation

Reviewer or Simulation	Sensitivity	Specificity	Positive predictive value	Negative predictive value
R1	0.9	0.21	0.31	0.84
R2	0.6	0.71	0.45	0.82
R3	0.63	0.63	0.4	0.81
R4	0.9	0.34	0.35	0.9
R5	0.67	0.63	0.42	0.83
S1	1	0.13	0.31	1
S2	0.87	0.29	0.32	0.85
S3	0.77	0.54	0.4	0.85
S4	0.6	0.74	0.47	0.82
S5	0.37	0.87	0.52	0.78

Conclusions: BE biopsies with a diagnosis of IND can only be classified with a fair level of interobserver agreement. This study suggests that requiring universal agreement on IND at institutional quality assurance conferences for a final diagnosis of IND in BE may fail to identify a substantial number of clinically significant INDs.

728 Barrett's Esophagus with Indefinite Dysplasia: Clinical Outcome and Risk Stratification

B Horvath, D Allende, R Pai, D Patil, T Plesec, H Xie, P Thota, P Singh, X Liu.
 Cleveland Clinic, Cleveland, OH.

Background: Patients with Barrett's esophagus (BE) may undergo surveillance biopsies because of the increased risk of developing esophageal adenocarcinoma (EAD). Biopsies are classified as indefinite for dysplasia (IND), if the epithelial abnormalities are not sufficient to diagnose dysplasia or the nature of these abnormalities is uncertain. This study aimed to determine the prevalence and progression of neoplasia in BE patients with IND and to identify parameters associated with progression.

Design: BE and IND cases were retrieved from our surgical pathology database from 1992 to 2007. Pathologic reports, demographic, and outcome data were reviewed. Incidence of neoplasia was calculated for subgroups of age, gender, number of levels and IND multifocality on index biopsies, and number of follow-up endoscopies and biopsies.

Results: A total of 225 BE patients with a diagnosis of IND were identified. 118 cases were excluded due to a prior diagnosis of neoplasia (N=70), being lost to follow-up (N=37), missing slides or lack of BE (N=11). Among the remaining 107 patients, 85 patients had a follow-up biopsy within 1 year of their index IND diagnosis and 10 (11.7%) patients had prevalent neoplasia including 7 low grade dysplasia (LGD), 1 high grade dysplasia (HGD), and 2 EAD. Among 83 patients without prevalent neoplasia and ≥1 year follow-up, 18 progressed to dysplasia (14 LGD, 4 HGD) and 2 developed EAD during a follow-up period of 421.1 patient years. The incidence of neoplasia (LGD, HGD or EAD) and advanced neoplasia (HGD+EAD) was 4.5 (95% CI: 2.9-7.1) and 1.2 (95% CI: 0.5-2.8) cases per 100 patient years. Multifocality of index IND was associated with significantly increased incidence of progression to neoplasia (Table 1).

Table 1. Subgroup analysis of incidence of neoplasia in BE IND patients

	Incidence rate (LGD/HGD/EAD) (95% CI)	p value
Age (>62/≤62 yrs)	5.5(3.0-10.3)/3.7(1.9-7.2)	0.3
Gender (F/M)	1.9(0.5-7.8)/5.3(3.3-8.6)	0.08
# of biopsy levels on index biopsy (<2/≥2)	3.8(1.9-7.6)/5.2(2.9-9.4)	0.5
IND multifocality on index biopsy (no/yes)	3.5(2.0-6.2)/8.5(4.0-17.8)	0.03
# of follow-up endoscopies (≤2/>2)	5(2.6-9.6)/4.2(2.2-7.7)	0.3
# of follow-up biopsies (≤5/>5)	4.4(2.3-8.5)/4.6(2.5-8.5)	1

Conclusions: BE IND is associated with a significant risk of prevalent and incident neoplasia including HGD and carcinoma. Multifocality of index IND identifies a group at higher risk of progression.

729 Evaluation of pT3 vs pT4 Stage and Radial Margin in Colorectal Cancer: Pitfalls in Interpretation and Correlation with Outcome

M Hosseini, N Shafiqzadeh, S Kakar. UCSF, San Francisco, CA; SCPMG, Woodland Hills, CA.

Background: AJCC staging states that colorectal cancer(CRC) <1 mm from non-peritonealized surface is pT3 with +ve radial margin(RM);CRC with involvement of peritoneal(serosal) surface is pT4a. The relationship of peritoneum with colon varies with site; there is no radial margin in peritonealized areas, while pT4a designation is relevant only in peritonealized areas. This study examines the errors in pT staging and radial margin evaluation in CRC.

Design: The pT stage and radial margin were re-evaluated in 96 CRC originally classified as pT3(n=47) and pT4(n=49) at a large multicenter community hospital network. Tumor <1 mm of margin was called +ve RM. Involvement of peritoneal surface was called pT4a. The pT stage and RM status were correlated with survival.

Results: The pT stage was revised in 11(23%) and 23(47%) CRC that were originally classified as pT3 and pT4 respectively. pT3 to pT4 change was due to tumor involvement of serosal surface (T4a,n=5) and direct extension into pancreas(T4b, n=1). In 3 cases,definite pT3 or pT4 stage could not be determined as peritoneal surface was not clearly identified microscopically and had not been inked. pT4 to pT3 change was due to tumor <1 mm from serosal surface but not involving it (n=15), tumor >1 mm from serosal surface(n=4) and no clear involvement of uninked serosal surface(n=4). pT4 cases were not subclassified as pT4a or pT4b in any report. Errors in RM reporting were noted in 26(27%) cases: RM evaluated based on involvement of serosal surface(n=24), RM called +ve based on tumor <1 mm from serosal surface(n=5), RM called negative with tumor <1 mm of RM(n=1). 5-year survival in pT3 with +veRM was 33% compared to 12% in pT4a (p=0.1).

Revised →	pT3	pT4a	pT4b	pT3 vs pT4	pT2
Original pT3, n=47	36	5	1	3	2
Original pT4, n=49	23	14	12	0	0

5-yr survival	pT3,-ve RM	pT3,+veRM	pT4a
	25%	33%	13%

Conclusions: pT staging and RM evaluation were incorrect in nearly 1/3 of CRC. Most common sources of error were misinterpretation of tumor involvement of serosal surface as +ve RM, failure to recognize serosal surface involvement as pT4a, failure to identify and ink peritoneal surface, failure to call tumor <1mm as positive RM and classifying tumor <1mm from serosal surface as T4a. The 5-year survival is lower in pT4a CRC compared to pT3 with +ve RM, but not statistically significant. Attention

to AJCC criteria and careful gross examination are key to avoiding these errors. If lack of significant difference in pT3 with +ve RM and pT4a is confirmed in large studies, the distinction between the two may become less important.

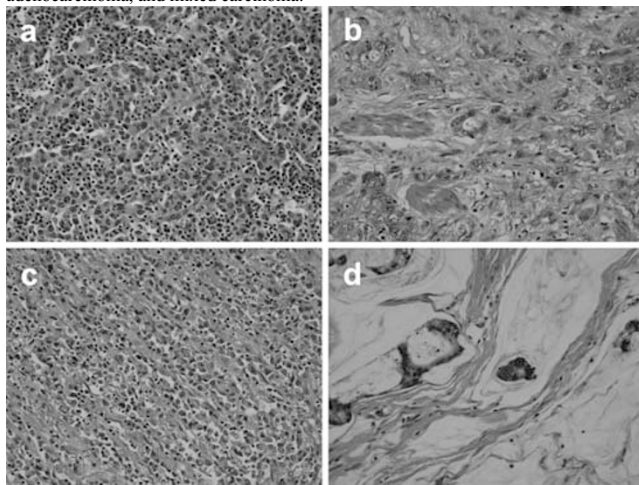
730 Prognostic Factors in Epstein-Barr Virus-Associated Stage I-III Gastric Carcinoma: A Single-Institute Experience

S-C Huang, K-F Ng, K-H Chen, T-S Yeh, T-C Chen. Chang Gung Memorial Hospital, Taoyuan, Taiwan.


Background: Epstein-Barr virus (EBV) has been implicated as an infectious cause of gastric cancer, and EBV-associated gastric carcinoma (EBVaGC) has distinct clinicopathologic features. However, the prognostic factors remain unclear, especially in UICC/AJCC stage I-III cancer.

Design: We retrospectively enrolled 1,020 cases of stage I-III gastric cancer that received radical gastrectomy with lymphadenectomy between 1999 and 2006. Formalin-fixed, paraffin-embedded surgical specimens were retrieved to construct tissue microarrays. EBV positivity was identified by in situ hybridization with EBV-encoded small RNA, and the histological classification was reviewed. Univariate and multivariate analyses were conducted to determine the clinicopathologic correlation and to perform a survival comparison.

Results: A total of 52 (5.1%) cases of EBVaGC were identified, exhibiting a male predominance ($p = 0.003$), a higher prevalence in stump cancer ($p < 0.001$), and poorly differentiated carcinoma ($p = 0.010$) compared with controls. There were 19 lymphoepithelioma-like carcinoma (LELC) cases (36.5%) and 33 non-LELC cases (63.5%), including tubular adenocarcinoma, poorly cohesive carcinoma, mucinous adenocarcinoma, and mixed carcinoma.



The survival analysis revealed no difference in survival between the EBVaGCs cases and the EBV-negative cases of gastric cancer ($p = 0.977$). The multivariate analysis showed that EBVaGC cases with a tumor size > 5 cm, non-LELC, or a lymph node ratio > 0.15 had a worse overall survival (hazard ratio 2.884, 12.178, and 19.352, $p = 0.027$, 0.005, and < 0.0001 , respectively).



The depth of tumor invasion and the number of lymph node metastases did not reach statistical significance ($p = 0.834$ and 0.833 , respectively).

Conclusions: These factors should be considered when selecting high-risk patients for adjuvant treatment.

731 Primary Leiomyosarcomas of the Gastrointestinal Tract: Clinicopathologic Analysis of 25 Cases

D Huang, W Sheng, C Tan, J Wang, X Du. Fudan University Cancer Center, Shanghai, China.

Background: Primary leiomyosarcomas (LMS) of the gastrointestinal tract are extremely rare, and their clinicopathologic features are not fully understood in the "post-GIST" era. We designed this study to characterize the clinical, histologic and immunohistochemical features of primary LMS of the gastrointestinal tract.

Design: Clinical, pathologic and immunohistochemical features were evaluated from all patients who had a diagnosis of primary LMS of the gastrointestinal tract at our hospital between 1.2004 and 12.2012. All pertinent slides, including immunostains, were retrieved and reviewed.

Results: We evaluated 25 primary LMS of the gastrointestinal tract from 13 female and 12 male patients (median age 52 years, range 29-70). The most commonly involved site was ileum (9 patients, 36%) followed by colorectum (8), stomach (6) and esophagus (2). In 8 cases the first diagnosis of LMS was made on GI biopsy. The mean tumor size was 9.4 cm (range 6 to 16 cm). Metastases were reported in 5 patients (2 in the liver, 1 in the lung, 1 in the bladder and 1 in the poststernite). A total of 11 patients

were successfully followed up for survival analysis (the median follow-up time was 12.0 months, range 3-24), and 9 patients (82%) died of LMS. The median survival time was 12.0 months [Standard error (SE) 4.4; 95% CI 3.4-20.6]. Histologically, the tumors showed mitotic activity ($>5/50$ HPF), necrosis and pleomorphism. The staining of CD117, CD34 and DOG1 were not identified in LMS. Tumor cells were highlighted by diffuse staining for SMA in all cases. Desmin and H-caldesom were positive in 87% and 79% tumors respectively. Expression of Vimentin was variable. No patient had documented KIT or PDGFRA mutation.

Conclusions: In the "post-GIST" era, true smooth muscle neoplasms of the gastrointestinal tract, with distinctive clinicopathologic characteristics, are still recognised and panels immunohistochemical markers help differentiate these from GIST.

732 Carbonic Anhydrase IX Is Not a Prognostic Marker in Esophageal Adenocarcinoma, Instead It Is a Unique Marker to Differentiate Squamous Cell Carcinoma from Adenocarcinoma

AR Huber, T Wu, JH Peters, D Zhou. University of Rochester Medical Center, Rochester, NY.

Background: Esophageal carcinoma is a highly aggressive tumor with a 5-year survival rate of about 15%. Targeted biomarkers are urgently being explored. Carbonic anhydrase IX (CAIX) is a transmembrane glycoprotein and is related to tumor hypoxia. High CAIX expression has been associated with shorter survival, cancer progression, and potential targeted cancer therapy in several cancers, including esophageal carcinoma, in European studies. In our study, we attempted to confirm CAIX expression in esophageal carcinoma in the United States (US).

Design: Tissue microarrays consisted of Barrett mucosa (BE), columnar cell mucosa (CM), BE with low or high grade dysplasia (LGD and HGD), adenocarcinoma (EAC), squamous epithelium (SE), and squamous cell carcinoma (SCC). CAIX immunohistochemistry was performed on the tissue microarrays. These cases were scored based on intensity from 0 to 3+. Those cases that stained with intensity of 2 or 3+ in greater than or equal to 10% of cells were considered high expression. Cases were considered low expression if less than 10% of cells expressed CAIX and/or the intensity was 0 or 1. The cases were scored by two pathologists and a consensus score achieved.

Results: CAIX expression was higher in glandular mucosa with or without dysplasia than in squamous epithelium or squamous cell carcinoma. SCC shows rare expression of CAIX. The seven groups had significantly different means of CAIX expression ($p < 0.0001$). There was no significant difference in survival among CAIX high expression and low expression EAC groups. CAIX expression was not lost in poorly differentiated EACs (63/67 positive, 94%).

Table 1 High expression of CAIX in each esophageal lesion.

Sample Diagnosis	High expression	Low expression
Adenocarcinoma	100 (92%)	9 (8%)
Barrett mucosa	22 (76%)	7 (24%)
Columnar cell mucosa	49 (83%)	10 (17%)
Low grade dysplasia	12 (71%)	5 (29%)
High grade dysplasia	11 (79%)	3 (21%)
Squamous epithelium	0 (0%)	51 (100%)
Squamous cell carcinoma	1 (4%)	24 (96%)

Conclusions: High expression of CAIX in EAC indicates that it will be a potential targeted therapy marker for EAC. CAIX may be a useful immunohistochemical marker in differentiating esophageal adenocarcinoma from squamous cell carcinomas. CAIX was not a significant prognostic marker in US EAC patients, which differs from prior studies in Europe.

733 HER2 Status of Gastric or Gastroesophageal Junction Carcinomas and Corresponding Metastases by Immunohistochemistry

AR Huber, BR Koltz, DG Hicks, CL Whitney-Miller. University of Rochester Medical Center, Rochester, NY; Rochester General Hospital, Rochester, NY.

Background: Approximately 20% of gastric and gastroesophageal junction (GEJ) adenocarcinomas are HER2 positive (defined as 3+ overexpression by immunohistochemistry [IHC] or gene amplification by fluorescence in situ hybridization [FISH]). In the ToGA trial, the addition of trastuzumab was shown to prolong survival in patients with advanced gastric and GEJ carcinomas. In this trial, patients with either IHC+ or FISH+ primary tumors were eligible for inclusion. It is well established that gastric and GEJ carcinomas demonstrate heterogenous HER2 expression, even within the same tumor. However, the data regarding HER2 expression among primary tumors and their metastases are sparse, with conflicting results. We hypothesized that HER2 IHC expression is inherently heterogenous in gastric and GEJ cancers and therefore there would be variability in HER2 status between the primary tumor and their metastases.

Design: Thirty-three cases of gastric or GEJ adenocarcinomas with paired lymph node metastases and/or distant metastases/recurrence (mesentery, abdominal wall, hernia sac, liver, ovary) were reviewed. IHC staining using the commercially available Hercep Test (DAKO) was performed and the HER2 expression was scored based on the system outlined by Hofmann.

Results: The results are summarized in table 1.

Table 1. HER2 IHC results for Paired Primary Tumors and Metastases (n=33)

Primary Tumor	Lymph Node Metastasis	Distant Metastasis or Recurrence	Number of Cases
+	+	+	4 (12%)
+	+	+	1 (3%)
+	+	+	1 (3%)
+	+	+	1 (3%)
+	+	+	17 (52%)
+	+	+	3 (9%)
+	+	+	2 (6%)
+	+	+	4 (12%)

Conclusions: Overall, 21% (7/33) of cases had discrepant HER2 IHC expression between the primary tumor and a lymph node or a distant metastasis/recurrence. HER2 expression is heterogeneous not only in the primary tumor but also in the paired lymph node and distant metastases. Our data would suggest that it may be warranted to determine the HER2 status of corresponding metastatic disease, if available, particularly in cases that were determined to be HER2 negative based on their primary tumor analysis, as these patients may benefit from HER2-targeted therapy.

734 HER2 FISH+ Rate in IHC- Gastric/Gastroesophageal Junction Adenocarcinomas

AR Huber, BR Koltz, DG Hicks, CL Whitney-Miller. University of Rochester Medical Center, Rochester, NY; Rochester General Hospital, Rochester, NY.

Background: Approximately 20% of gastric and gastroesophageal junction (GEJ) adenocarcinomas are HER2 positive (defined as 3+ overexpression by immunohistochemistry [IHC] or gene amplification by fluorescence in situ hybridization [FISH]). In the ToGA trial, the addition of trastuzumab was shown to prolong survival in patients with advanced gastric and GEJ carcinomas. In this trial, all patients were screened with both IHC and FISH; patients with either IHC+ or FISH+ tumors, as defined by Hofmann's criteria, were eligible for inclusion. Because of this, some experts have advocated that all gastric/GEJ IHC- cases should undergo FISH testing (not just equivocal cases as is done in breast).

Design: Fifty-one (51) cases of gastric and GEJ adenocarcinomas were reviewed. Paraffin blocks were selected for IHC staining using the commercially available Hercep Test (DAKO). The IHC stained slides were scored based on the scoring system outlined by Hofmann, et al. All cases subsequently underwent FISH analysis using the HER2 PharmDx test kit (DAKO); those cases demonstrating aneusomy or a HER2/CEP17 ratio ≥ 2.0 were considered positive.

Results: Of the 51 cases, 43 (84%) were negative by IHC (0-1+). Of these IHC- cases, 5 (12%) were positive by FISH including one case with aneusomy.

Conclusions: In our population, 12% of IHC- cases were FISH+. Until the benefit of trastuzumab in these patients is better defined, we advocate reflex FISH testing in all cases with non-positive (i.e. equivocal and negative) IHC results.

References: Hofmann M, et al. Assessment of a HER2 scoring system for gastric cancer: results from a validation study. *Histopathology* 2008;52: 797-805.

Ruschoff J, et al. HER2 diagnostics in gastric cancer-guideline validation and development of standardized immunohistochemical testing. *Virchows Arch* 2010;457: 299-307.

Bang Y, et al. Trastuzumab in combination with chemotherapy versus chemotherapy alone for treatment of HER2-positive advanced gastric or gastro-oesophageal junction cancer (ToGA): a phase 3, open-label, randomized controlled trial. *Lancet* 2010;376: 687-697.

735 The Number and Distribution of Eosinophils in the Human Gastrointestinal Tract: A Study of the Effect of Race and Environmental Factors

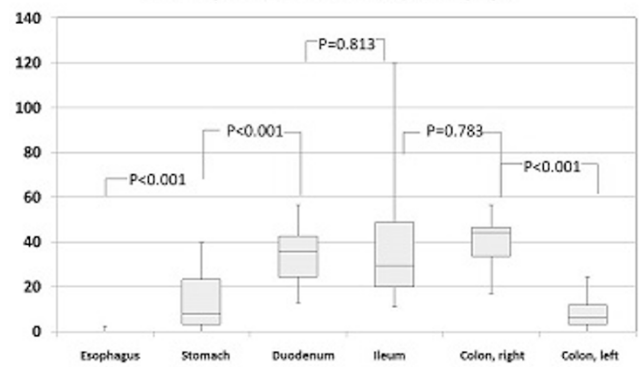
N Ishikawa, R Maruyama, T Matsushita, T Yuki, Y Kinoshita, D Chen, PS Tauchi-Nishi. Shimane University School of Medicine, Izumo, Japan; University of Hawaii/Queens Medical Center, Honolulu, HI.

Background: There is surprisingly little data regarding normal counts or distribution of eosinophils (EOS) in the adult gastrointestinal tract (GIT), despite the increasing incidence of eosinophilic GIT diseases. Moreover, there are no published reports regarding Asians, or the effects of race and environmental factors. The aim of this study is to ascertain the number of EOS in normal GIT mucosa of adult Japanese (J), and to compare them with those of Japanese Americans (JA) and Caucasians (W) living in Hawaii.

Design: The numbers of EOS from the esophagus, stomach, and intestines were quantified on H+E stained slides of biopsies or surgical resections. Immunohistochemistry (IHC) with major basic protein was also employed for biopsies. The number of EOS per high power field (hpf) was counted in 4-5 and 10 randomly selected hpf for biopsies and surgical specimens, respectively. At least 20 samples from each GIT site were examined for all ethnic groups.

Results: Our results showed a statistically significant increase in the number of EOS from the esophagus to the right colon, compared to a decrease in the left colon in all 3 groups (results for J patients, Figure 1). There were significant differences in the EOS counts in the esophageal epithelium between J and JA ($p=0.001$), and J and W ($p=0.028$) patients (Table 1). In comparison, there were no significant differences in the remaining GIT sites among these groups. IHC was superior to H+E in detecting EOS ($p<0.001$ for stomach, duodenum, $p=0.004$ for ileum)

Eosinophil counts/mm²(J, Biopsy)



Eosinophil counts/mm² (J/JA/W)

	Esophagus, E	Esophagus, LP	Stomach	Colon, Rt	Colon, Lt
mean	0.8/0.0/0.4	5.6/4.4/4.5	22.7/36.4/24.0	79.5/73.1/48.2	38.6/24.3/30.7
median	0.4/0.0/0.0	3.8/3.1/2.6	19.8/24.8/13.5	67.0/67.5/38.2	32.0/18.6/20.4
SD	1.4/0.1/1.1	5.6/4.6/5.8	16.8/17.4/26.7	47.0/33.1/43.4	31.4/20.8/31.0

Conclusions: To our knowledge, this is the 1st report of EOS counts in the GIT for J patients with international comparisons among ethnic groups. The number of EOS varied significantly depending on the biopsy site. Interestingly, patient race and geographic location did not appear to have any effect, except in the esophageal epithelium.

736 Growth Arrest-Specific Gas7 Gene Hypermethylation and Reduced Protein Expression in Ulcerative Colitis and Associated Neoplasia

AC Iuga, Y Yao, A Luna, JL Sepulveda, AR Sepulveda. Columbia University Medical Center, New York, NY; University of Pennsylvania, Philadelphia, PA.

Background: Ulcerative colitis (UC) has a higher risk for development of colorectal carcinoma (CRC). Inflammatory bowel disease (IBD)-related CRC is commonly preceded by dysplasia. IBD-associated dysplasia is usually patchy, more difficult to detect endoscopically and often found on random sampling. Identification of molecular alterations in non-neoplastic colitic mucosa that can predict the risk of dysplasia would be helpful for early detection and improved screening efficacy. Growth arrest-specific gene Gas7, preferentially expressed in cells entering a quiescent state, was shown to be methylated in sporadic CRC and associated with genetic risk loci for UC. This suggested that Gas7 may have a role in UC-related neoplasia.

Design: We studied Gas7 CpG promoter methylation and protein expression in neoplastic and corresponding non-dysplastic mucosa in 13 ulcerative colitis surgical resection specimens. Protein expression was evaluated by immunohistochemical staining (LSBio, LS-C98386) and scored on a scale from 0 to 3. Methylation of Gas7 was identified by screening with a GoldenGate methylation cancer panel array. CpG methylation levels were determined using bisulfite-modified DNA by quantitative SYBR green methylation-specific PCR. The results were compared to control colonic mucosa of patients without IBD (non-IBD). Paired t-test analysis was used to compare neoplastic and corresponding non-dysplastic UC mucosa.

Results: We identified altered regulation and expression of Gas7 in UC-associated neoplastic and corresponding non-dysplastic colonic mucosa. Gas7 showed CpG methylation in the promoter region in both UC-related neoplastic and non-dysplastic mucosa. Gas7 methylation was significantly higher ($p<0.001$) in UC-associated neoplasia (average 56.2%, median 42.4%) compared to corresponding non-neoplastic mucosa (average 9.1 %, median 6.4%). Non-IBD control mucosa did not show significant levels of Gas7 methylation ($<1\%$). Gas7 showed cytoplasmic staining in non-IBD colonic epithelium. Gas7 expression was decreased in UC-associated neoplastic and non-dysplastic mucosa, with lower levels in the neoplastic mucosa ($p=0.08$), paralleling the increase in CpG methylation.

Conclusions: Gas7 showed CpG hypermethylation associated with decreased protein expression in UC-related neoplasia. Altered methylation and expression of Gas7 were also present in the non-neoplastic colitic mucosa, albeit at lower levels. This suggests a potential novel role of Gas7 in UC-related neoplastic progression.

737 Biopsy-Initiated Recommendations for Autoimmune Metaplastic Atrophic Gastritis Elicit Limited Clinical Appraisal

S Jakate, D Giusto. Rush University Medical Center, Chicago, IL; 4Path Pathology Services, Justice, IL.

Background: Marked variability in clinical presentation evades recognition of autoimmune metaplastic atrophic gastritis (AMAG). However, purposefully or incidentally biopsied gastric body or fundal mucosa offers a strong indication of AMAG in experienced hands and provides an opportunity to initiate confirmatory clinical investigations. We studied whether clear AMAG microscopic diagnosis with biopsy-initiated recommendations translate into necessary clinical investigations in two different settings - and academic medical center (AMC) and community practice (CP). We also examined the potential causes for deficient clinical followup.

Design: From 2010-2013, 57 patients (F:M=8:2, median age 66, 48 from AMC and 9 from CP) were histologically diagnosed as AMAG based upon gastric oxyntic mucosa (gastrin negative) with depleted/absent parietal cells, variable ECL neuroendocrine hyperplasia (synaptophysin positive), variable chronic gastritis and variable intestinal metaplasia. Additional coexistent findings if present (Helicobacter, carcinoma, dysplasia)

were documented. Recommendations were made in the pathology report that included needed confirmatory serology for anti-parietal cell (APC) and intrinsic factor (AIF) and potential for iron and/or B12 deficiency anemia and hypergastrinemia. For each patient, the electronic medical record (EMR) was reviewed post-biopsy for at least 2 months for followup investigations.

Results: 50/57 (87%) patients had anemia – most (42/50) with iron deficiency and only 8/50 with B12 deficiency. Only 30/57 (53%) patients (28/48 AMC; 2/9 CP) had reflex serology; all were positive for APC (26/30) or AIF (2/30) or both (2/30). Coexistent *Helicobacter gastritis* (4/57), carcinoid tumor (3/57) and dysplasia (1/57) were seen in the small number of patients. All patients with B12 deficiency, carcinoid tumor and dysplasia had testing for serology and gastrin levels. Patients who did not have serological investigation included patients with *Helicobacter gastritis*, iron deficiency anemia and normal hemoglobin.

Conclusions: AMAG histology is a reliable indicator of seropositivity in autoimmune gastritis. Despite clear pathological diagnosis and recommendations, followup investigations are not satisfactorily conducted in both academic centers or community practice. Potential causes for such oversight include normal hemoglobin and presence of iron rather than B12 deficiency and coexistent *Helicobacter gastritis*. B12 deficiency, carcinoid tumor and dysplasia however, trigger adequate workup.

738 Gastrointestinal Neoplasms Arising Post-Bladder Augmentation: Experience at a Tertiary-Care Center

FG Jalikis, SP Yennam, PE Swanson, MP Upton, MM Yeh. University of Washington, Seattle, WA.

Background: Gastrointestinal bladder augmentation, also known as cystoplasty, is a surgical procedure performed to increase the capacity of the bladder in patients by adding a patch of stomach or bowel to the existing organ. Malignant neoplasm arising in the gastrointestinal tissue is a known late complication of this procedure. Neobladder reconstruction, performed in patients who undergo cystectomy, consists entirely of a bowel-derived pouch. The purpose of this study is to review and describe our experience with gastrointestinal malignancies arising in the augmented bladder compared to patients undergoing neobladder reconstruction.

Design: We conducted a retrospective cohort analysis of patients who underwent bladder augmentation and neobladder reconstruction. A file search including the terms “bladder augmentation”, “bladder augmentation cancer”, “neobladder” and “neobladder cancer” was performed.

Results: Among 31 patients who underwent bladder augmentation, 5 (16%) developed gastrointestinal malignancies. 3 arose from gastrocystoplasty and 2 from ileocystoplasty. The stage at presentation varied, with more advanced cases observed in neoplasms arising in gastric augmentation specimens. The mean time to developing malignancy was 12± 2 years. 2 patients with gastrocystoplasty developed adenocarcinoma and 1 patient had at least high-grade glandular dysplasia. 1 patient with ileocystoplasty developed a neuroendocrine tumor and 1 patient developed adenocarcinoma. Among 40 patients that underwent neobladder reconstruction, no malignancies were identified.

Conclusions: Gastrointestinal malignancies are a late complication of bladder augmentation. In our experience, the lack of malignant neoplasms arising in neobladders suggests that the augmentation procedure itself or the residual bladder tissue are independent risk factors for the development of malignancy, and that urine exposure might not play a major role. Further studies are needed to clarify the mechanisms of carcinogenesis in the augmented bladder and to define an appropriate surveillance protocol in this patient population.

739 The Impact of Tumor Deposits on Colonic Adenocarcinoma AJCC TNM Staging

M Jin, JB Rock, R Roth, MK Washington, WL Frankel. Ohio State University Wexner Medical Center, Columbus, OH; Vanderbilt University Medical Center, Nashville, TN.

Background: The TNM staging system was developed by the AJCC to be data-driven, evidence-based and predictive of outcome. Frequent updating is essential, but changes such as the definition of tumor deposits (TD) in colonic adenocarcinoma (CAd) can cause confusion. The definition has progressed from a reliance on size (5th), to shape (6th), and now to a new category of N1c (7th). To better understand how these changes have affected staging of CAd, we restaged right-sided CAd using criteria from each AJCC edition (Ed).

Design: All right-sided CAd (429) with available slides over a 10-year period (2001-2010) were reviewed by pathologists with interest in GI pathology. Cases were restaged using AJCC 5th, 6th, and 7th Ed with attention to precise definitions of TD and metastatic lymph node (LN). The five year survival rates for patients with N1c tumors were determined based on available records.

Results: The numbers of total LN, total positive LN, and average positive LN were decreased with 7th Ed compared to 5th/6th Ed; however, the numbers of cases with TD and <12 LN were increased with 7th Ed compared to 5th/6th Ed. 19 of 429 cases showed a stage change between 6th and 7th Ed due to TD definition change. 17 had stage migration (12 from IIIC in 6th to IIIA/B in 7th and 5 from IIA/B in 6th to IIIB/C in 7th) due to N category changes, and 2 had stage migration (from IIIB in 6th to IIIA in 7th) caused by T category changes. Of 23 cases staged as N1c by 7th Ed, 13 were T3N1c and 10 were T4N1c. The five year survival rates of patients with T3N1c (23%) and T4N1c (10%) were lower than that observed for T3N2 and T4N2 in the SEER database.

Comparison of Lymph Nodes and Tumor Deposits Using AJCC 5th, 6th, and 7th Eds

	Total LN	+LN	Average LN per case	Average +LN	# cases with TD	# cases <12 LN
5th Ed	9477	1037	22.2	2.4	43	46
6th Ed	9349	893	21.9	2.1	55	51
7th Ed	9018	566	21.1	1.3	107	64

Conclusions: The new N1c category and definition of TD in the 7th Ed AJCC affects number of total LN, positive LN and number of cases with TD and <12 LN, but with only minimal effect on final stage. Oncologists and surgeons should expect the number of cases with <12 LN to increase due to TD. Our survival results showed that patients with tumors staged as N1c had a lower 5 year survival percentage than LN positive patients with similar T stage, and suggest that TD may predict worse outcome than positive lymph nodes. The definition of TD will likely continue to evolve as outcome studies using current definitions are completed.

740 Next Generation Sequencing (NGS) Reveals Novel Mutations in Goblet Cell Carcinoids and Carcinoma Ex Goblet Cell Carcinoids of the Appendix

M Johncilla, M Stachler, NI Lindeman, R Odze, A Srivastava. Brigham and Women's Hospital, Boston, MA.

Background: Goblet cell carcinoids (GCC) and adenocarcinomas ex GCC (AGCC) are rare neoplasms of the appendix with limited and conflicting data regarding their molecular phenotype. The aim of this study was to use NGS to evaluate GCC and AGCC to identify novel mutations and potential prognostic and therapeutic markers.

Design: DNA was extracted by macrodissection from five 10u FFPE slides from 5 cases of GCC and 11 cases of AGCC. Illumina TruSeq™ was used to prepare the library for sequencing exons of a custom 265 gene panel using an Illumina HiSeq 2000. All cases had a minimum average coverage depth of at least 50 reads. All detected variants that passed quality control were filtered for known SNPs using the Exome Sequencing Project (ESP) and dbSNP databases. A subsequent search in COSMIC and Pubmed for known pathogenic variants was performed to rule out passenger mutations. PolyPhen 2 was also used to determine pathogenicity of identified mutations.

Results: The number of mutations (after filtering through ESP) per case ranged from 1 – 8 (mean - 3). The most frequent mutations were in MLL2 (3/16), which encodes a histone methyltransferase, ARID1A (2/16), ATRX (2/16), BRAF (2/16), CDH1 (2/16), KRAS (2/16), MET (2/16), PIK3R1 (2/3), RPHN2 (2/16) and SOX9 (2/16). Mutations in TCF7L2 occurred in both the GCC and mucinous carcinoma component of one AGCC case, where both components were analyzed separately. Mutations already described in COSMIC included: RHPN2, SOX9, PDGFRA, PMS1, CRTX2, TP53, KRAS, BRAF, APC, AR and TCF3. On average, there were more mutations in AGCC than GCCs (mean 5 vs 3, p=0.04). SOX9 mutations were only seen in GCC, whereas MLL2, KRAS and ARID1A were only seen in AGCC. TP53 mutations were limited to poorly differentiated AGCC (2/3).

Conclusions: GCC and AGCC contain a wide array of low frequency genetic mutations, including some that are seen in conventional adenocarcinomas of the colon. However, novel mutations were found in this study, including mutations in MLL2, ARID1A and ATRX. These findings suggest that GCC and AGCC are a unique group of tumors distinct from typical carcinoid and conventional adenocarcinomas of the GI tract.

741 Clinicopathologic Features of Colorectal Cancer Arising in or near Sessile Serrated Adenoma

A Jones, F Sinicrope, T Smyrk. Mayo Clinic, Rochester, MN.

Background: The serrated pathway is thought to account for 35% of all colorectal cancer. Mutated BRAF is an initiating event, extensive CpG island promoter methylation (CIMP) is an epigenetic promoter, and sessile serrated adenoma (SSA) is a precursor lesion. Cancers that arise via the serrated pathway are often MSI-high as a result of hypermethylated MLH1; others have hypermethylation at sites other than MLH1 and are designated CIMP+/microsatellite stable (MSS) or MSI-low. Clinicopathologic features of MSI-high cancers are well known; the other group of serrated pathway cancers is less well described.

Design: We searched the electronic pathology data base to find all colorectal cancers diagnosed between 2006 and 2012 that were specifically noted to arise in or adjacent to (2 cm) SSA. Slides from all cases were reviewed for histologic subtype, grade, tumor border, Crohn's-like reaction, tumor infiltrating lymphocytes, and tumor budding. We did immunohistochemistry (IHC) for the V600E BRAF mutation and for MLH1 in all cases and used these two stains as surrogate markers for CIMP+ and MSI-high, respectively. Clinical records were reviewed for demographic information, relevant past medical history, distant metastasis and outcomes.

Results: 33 cases met criteria; 19 of these had a residual precursor lesion and 16 had SSA within 2 cm. The residual precursor was SSA in 17 cases and adenoma in 2. Mutated BRAF was demonstrated by IHC in 31 CRC and in all 17 SSA precursors; the two negative CRC were the two that arose in adenoma. MLH1 was lost in 26 cases. Based on IHC, we classified 26 CRCs as CIMP+/MSI-high, 5 as CIMP+/MSS and 2 as CIMP-/MSS. CIMP+ cancers occurred mainly in elderly women. All 5 patients with CIMP+/MSS cancers were smokers, compared to 56% in the MSI-high group. As expected, MSI-high CRC tended to have many tumor-infiltrating lymphocytes, a Crohn's-like reaction, a pushing border and low tumor budding. CIMP+/MSS CRCs had infiltrative border, high budding, were more likely to show lymphatic invasion, distant metastasis and decreased survival.

Conclusions: IHC for the V600E BRAF mutation is an excellent way to document serrated pathway CRC, particularly when the precursor lesion is not identifiable, as is often the case. Based on this strictly defined series, MSI-high is a much more common end to the serrated pathway than CIMP+/MSS. There are distinct clinicopathologic differences between the two types of serrated pathway cancers. Not all CRC arising adjacent to SSA are serrated pathway cancers.

742 Should a Pathologist Perform CMV Immunostaining If the Clinician Requests It?

G Juric-Sekhar, JR LaPointe, MP Upton, PE Swanson, M Westerhoff. University of Washington, Seattle, WA; Cytolab Pathology, Lynwood, WA.

Background: Cytomegalovirus (CMV) causes clinically significant gastrointestinal (GI) mucosal injury, but there is no consistent practice standard among pathologists that defines when immunostaining (IHC) for CMV should be done. In the context of an ACO model of care delivery, we aimed to determine the cost and efficacy of clinical suspicion for CMV in GI biopsies and whether the request of a clinician alone justifies CMV IHC.

Design: Our electronic pathology database was searched for all GI biopsy reports from 2010–2012 that included CMV status. The resulting study set was divided into those cases driven by a clinician request to rule out CMV and those with CMV analyses initiated by the pathologist without a clinical request.

Results: 537 of 10,910 biopsy reports mentioned CMV. 361 cases included a clinician request to rule out CMV (C-CMV). CMV was detected in 37 of these (10.2%). 26 (7.2%) reported the use of IHC; in 11 (3%), diagnosis was based on readily identifiable viral inclusions on H&E slides, without IHC. The overall cost of IHC for all C-CMV cases was 4 times that of C-CMV IHC+ cases alone. Pathologist-initiated workup without clinical request (P-CMV) identified 26% of all CMV cases (n=13); 3 were reported without IHC. Overall, among 173 P-CMV cases with IHC performed, 10 (5.8%) were positive for CMV. The total cost of IHC for all P-CMV cases was 17 times higher than that of P-CMV IHC+ cases alone. Of the 36 total cases that were CMV IHC+, 19 (52.7%) had obvious viral inclusions seen on routine H&E, but IHC was performed anyway. 50% of all CMV IHC+ cases had no to minimal inflammatory tissue reaction; these were all from solid organ transplant recipients and the majority (15/18) were biopsies of stomach.

Conclusions: In this single institution study, our results indicate that a clinical request to rule out CMV is neither frivolous nor routine. CMV analysis was requested in 3.3% of 10,910 cases; 10.2% of these had CMV identified. However, half of all CMV IHC+ cases had typical inclusions seen on H&E slides. Moreover, pathologist-initiated workup, without stated clinical suspicion, identified CMV accounting for one-third of all CMV+ cases. We conclude that clinical suspicion for CMV has a high yield for CMV detection, but 'up front' testing in this setting is likely not necessary. Special attention should be given to samples from immunosuppressed transplant patients where inflammatory changes suspicious for CMV may be lacking. In all, careful histopathologic review by a pathologist remains a critical element in the efficient and cost-effective detection of CMV.

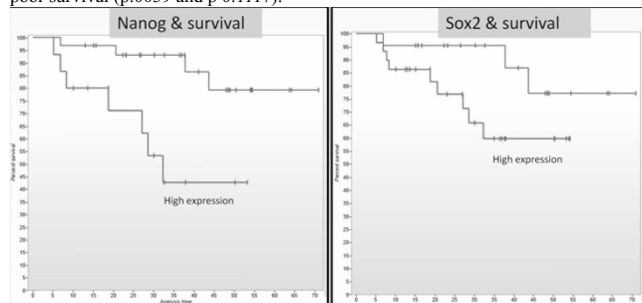
743 Stem Cell Markers (Nanog and Sox2) Are Strong Predictors of Survival in Colorectal Cancer

P Kamalathevan, A Bowman, B Ganeshan, S Wan, A Engledow, J Paterson, A Groves, M Rodriguez-Justo. University College London / UCLH, London, United Kingdom; University College London Hospital, London, United Kingdom.

Background: Transcription factors Nanog and Sox2 play a key role in the induction of pluripotent stem cells, are expressed in cancer stem cells (CSCs) and contribute to carcinogenesis. CSCs not only contribute and sustain tumor growth but it is also believed to mediate cancer relapse and drug resistance. The relationship between Nanog and/or Sox2 have received increased attention in some solid tumour, but the relationship between expression of CSCs markers and the biology and prognosis of colorectal cancer (CRC) is yet unclear.

Design: In this study we aimed to assess the clinicopathological and biological significance of Sox2 and Nanog using immunohistochemistry in a well-characterized series of 50 CRC patients. Correlation with pathology variables, proliferation, angiogenesis/hypoxia and mutation status (KRAS/BRAF) was evaluated using Spearman's and Mann-Whitney testing.

Results: Nanog (>2.635) and Sox2 (>2.5) expression were strongly associated with poor survival (p.0039 and p 0.1117).



Pathological size (>43mm), VEGF expression (>6), lymphovascular invasion (LVI) and mutant BRAF predict also poor survival (p=0.0074, p=0.0453; p=0.0005 and p=0.0004 respectively). Stem cell markers also correlate with VEGF expression (p=0.012); presence of LVI (p=0.007) and high-proliferation ratio (Ki67>20%; mcm2>40%). Using COX regression analysis Nanog in combination (interaction) with disease-recurrence was the best independent predictor of overall survival.

Conclusions: We have shown that increased expression of either SOX2 or Nanog are associated with poor survival. The "cancer stem cell signature" appears to confer a more aggressive phenotype to CRCs (high proliferation, LVI, hypoxia) underlying the importance of Nanog and Sox as prognostic markers, and potentially therapeutic targets, in CRC patients.

744 Deeply Eosinophilic Variant of CDH1 Deficient Hereditary Diffuse Gastric Carcinoma

M Kamionek, T Arnason, GY Lauwers. Massachusetts General Hospital, Boston, MA; Queen Elizabeth II Health Sciences Centre and Dalhousie University, Halifax, NS, Canada.

Background: Patients with germline *CDH1* mutations have greater than 80% lifetime risk of developing poorly cohesive gastric carcinoma. Current management strategies emphasize early detection of carriers and, increasingly, prophylactic total gastrectomy. Detailed histologic examination of prophylactic gastrectomy specimens is essential to detect early foci of carcinoma. Gastric cancers in this setting typically have classic signet ring cell morphology. To date, other histologic patterns of gastric carcinoma have not been described in these patients. Here, we report finding the deeply eosinophilic variant of poorly cohesive gastric cancer in patients with hereditary gastric cancer.

Design: Over an eight year period, 15 *CDH1* mutation carriers identified by full-length *CDH1* gene sequencing at our institution underwent prophylactic gastrectomy. The gastrectomy specimens were entirely submitted for microscopic examination.

Results: Detailed examination revealed a total of 351 foci of poorly cohesive carcinoma (120 in-situ, 227 intramucosal, and 4 submucosal) in the 15 patients. Eight (2.3%) of these cancer foci (2 in-situ, 4 intramucosal, 2 submucosal) from four patients displayed neoplastic cells with deeply eosinophilic cytoplasm, consistent with the deeply eosinophilic variant of poorly cohesive gastric carcinoma. These four patients all had different *CDH1* germline mutations.

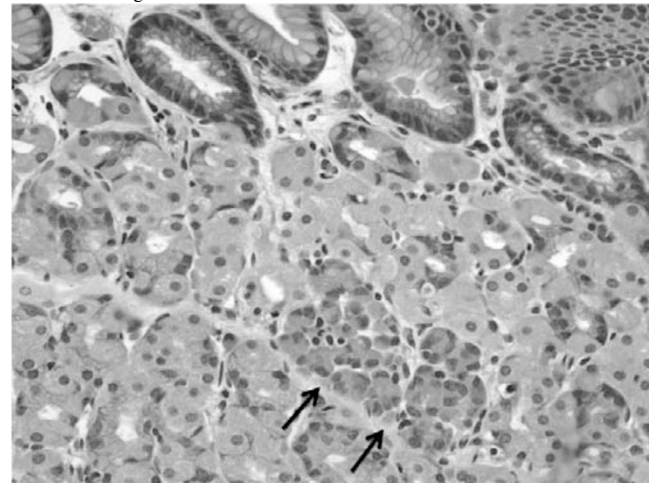


Figure 1. The arrows indicate a small focus of intramucosal poorly cohesive carcinoma, the deeply eosinophilic variant in a patient with *CDH1* germline mutation.

Conclusions: The deeply eosinophilic variant of poorly cohesive carcinoma is recognized in the World Health Organization classification of gastric tumors, but has not been previously reported in patients with hereditary gastric cancer. It is important for pathologists to be aware that the deeply eosinophilic variant of poorly cohesive gastric cancer can occur in this setting, because this variant of carcinoma has morphology closely resembling parietal cells. Consequently, this variant of carcinoma could be missed by pathologists expecting only classic signet ring cell morphology in these patients.

745 MiR Profiling of Tubular Adenomas and Microsatellite Stable Colorectal Cancer Identifies a New Putative Compensatory Mechanism of MIR1246

C Kavran, S Costinean, L Casadei, V Balatti, L Cascione, CM Croce, WL Frankel. Ohio State University Wexner Medical Center, Columbus, OH; OSU Wexner Medical Center, Columbus, OH.

Background: Tubular adenomas (TAs) progress through the chromosomal instability pathway to microsatellite stable (MSS) colorectal cancer (CRC). Studies have shown the importance of p53, KRAS and APC for this pathway. MicroRNAs (miRs) are a recently identified class of non-coding genes that play major roles in posttranscriptional regulation and fundamental biologic processes. MiR profiling can yield a tissue specific signature, and cancers also show a similar distinct miR signature, which can be used to identify novel tumorigenic pathways. CRCs were the first neoplasms identified with deregulated miRs. Herein, we investigate miRs in TAs and MSS CRCs to identify differences and investigate tumorigenic pathways.

Design: Thirty three TAs and 40 MSS CRCs were identified from the archives. MSS CRCs were chosen based on intact expression of immunohistochemical stains for the 4 mismatch repair proteins. RNA was analyzed with Nanostring, RT-PCR and Taqman probes were used to confirm miR and mRNA deregulation.

Results: Analysis of CRC vs. TA showed 54 miRs that were differentially expressed; 37 upregulated and 17 downregulated in CRC compared to TA. We validated miRs that showed the most significant upregulation (>2.5x) and have been shown to be deregulated in cancers: miR1246, miR125b-5p, miR199a-5p, and miR199b-5p. Of these, only miR1246 was confirmed by RT-PCR. In silico studies showed targets of miR1246 to include nucleoporin 50, CAV1, and DYRK1A.

Conclusions: TAs and MSS CRCs have distinct miR signatures. We identified and confirmed upregulation of miR1246 in CRC vs. TA. A recent paper (Cell Cycle, 2012) showed transcription of miR1246 is activated by the p53 family. MiR1246 downregulates DYRK1A, a known oncogene. DYRK1A normally inactivates NFAT,

a protein known to enhance immune response toward cancer cells. MiR1246 acts as a tumor suppressor by downregulating DYRK1A and allowing expression of NFAT. Since p53 is usually mutated in MSS CRC, we expected miR1246 to be decreased. Unexpectedly, we found miR1246 upregulated. Thus, miR1246 activation is achieved through an alternate mechanism, not previously described, which may play a compensatory role. Exploitation of this pathway could potentially lead to therapeutic interventions. Additional studies are ongoing to investigate other miRs involved in the chromosomal instability pathway to CRC.

746 Significance of Paneth Cells in Otherwise Histologically Unremarkable Rectal Mucosa

M Kherad Pezhoh, A Weinberg, JY Park. University of Texas Southwestern Medical Center, Dallas, TX.

Background: Paneth cell metaplasia of the rectal epithelium is a common histologic finding in patients with chronic inflammatory bowel disease.

Design: This study examines the frequency and clinical correlates of rectal mucosa Paneth cells in 250 rectal biopsies obtained from patients (female =137) between the ages of 0 to 20 years in a tertiary care facility during the period of 2010-2011. The clinical indication for biopsy was abdominal pain (n=54), constipations (n=78), Diarrhea (n=31), Bloody stool (n=48) and other causes (n=39). Two hundred thirteen cases were endoscopic biopsies and 37 cases were rectal suction biopsies. All 250 cases were endoscopically and histologically unremarkable. No prominence of eosinophils, altered mucosal architecture or active inflammation was identified.

Results: Paneth cells were present in 44 (17.6%) patients. The number of Paneth cells per 100 crypts in these cases ranged from 1 to 14 and the number of Paneth cells per affected crypt ranged from 1 to 3. There was no difference in age distribution between patients with or without Paneth cells. The patients with Paneth cells were compared with age-matched patients without Paneth cells with a median follow-up of 2 years in both groups. Only 1 out of 44 (2.27%) patients with Paneth cells developed Crohn's disease; this one patient was 13 years old when diagnosed with Paneth cells in otherwise unremarkable mucosa. None of the remaining patients with Paneth cells and none of the age-matched patients that were negative for rectal Paneth cells developed inflammatory bowel disease or other chronic gastrointestinal disorder in the follow-up period.

Conclusions: The high frequency of Paneth cells in otherwise unremarkable pediatric rectal biopsies suggests that rectal Paneth cells may represent a benign developmental heterotopia rather than a metaplastic change. Developmental heterotopias in other sites of the gastrointestinal tract persist into adulthood; therefore, these pediatric findings may be relevant to the identification of isolated Paneth cells in otherwise unremarkable adult rectal mucosa.

747 Correlation of P16 Expression and Clinicopathologic Presentation of Anal Squamous Cell Carcinoma

H Khurana, A Bedeir, S Samaha. Miraca LifeSciences, Phoenix, AZ.

Background: Many studies have shown a strong association between human papilloma virus (HPV) and anal squamous cell carcinoma (ASCC). Recent studies have also shown that HPV-related squamous cell carcinoma typically show abnormal overexpression of P16(INK4a), which is detected by immunohistochemical (IHC) staining. In this study we will compare the clinicopathologic features of P16 positive (p16+) and P16 negative (p16-) ASCC.

Design: The Miraca Life Sciences Data Warehouse was searched for cases with the diagnosis of ASCC on anal biopsies diagnosed between 1/1/2009 and 6/1/2011. The first 50 consecutive cases were included in this study. Original H&E stained slides were retrieved. The slides were reviewed by 3 pathologists and a representative block was selected for P16 immunohistochemical analysis. Pertinent clinical and pathologic details were gathered.

Results: Results are shown in [Table 1]. In the **Abstract Body** section, copy and paste the following tag, including brackets, where you would like your table to appear.

Table 1 : P16 expression in ASCC.

	P16 (+) ASCC	P16 (-) ASCC	
Number of patients	43 (86%)	7(14%)	
Gender			
Male	11	3	
Female	32	4	
Female: Male	2.9:1	1.3:1	
Age			
Range	47-84	54-91	
Mean	63.6	74.8	
Grade			
Moderately differentiated	20 (46.5%)	7(100%)	
Poorly differentiated (including Basaloid)	23(53.5%)	0	P= 0.0113

Conclusions: P16 + ASCC represented the majority of ASCC (86%). This group of patients had a female predominance and a wide range for age of presentation (47-84, mean=63.6). Patients with P16(-) ASCC represent only 14% of cases. They presented at older age (54-91, mean =74.8) and showed almost equal gender distribution. Interestingly, poorly differentiated ASCC was only seen in p16 + ASCC and represented 53.5% of this group.

748 Tumour Budding Is a Risk Factor of Lymph Node and Distant Metastasis in Malignant Colorectal Polyps with Submucosal Invasive (T1) Carcinoma

S Khutti, S Ligato. Hartford Hospital, Hartford, CT.

Background: Only a few studies have assessed tumor budding (TB) as a risk factor in malignant colorectal polyps and no generally accepted definition of what constitutes a significant tumor budding in malignant colorectal polyps has been established. The aims of this study were 1) to establish if TB (cluster of <5 malignant cell) is a risk factor for

metastasis in malignant polyp, 2) to compare TB to other established risk factors, and 3) to define what constitutes a significant TB in malignant polyp.

Design: We searched our database for submucosal invasive T1 adenocarcinoma in polypectomies specimens which subsequently underwent colon resection. 45 cases were blindly reviewed by two pathologists to assess for the presence of total number of tumor buds (at 40x, along the entire advancing front of invasion), tumor size, histological grade, lymphovascular invasion (LVI), morphology (sessile Vs pedunculated) and depth of tumor invasion. Cases with full thickness invasion, fragmentation, or history of familial polyposis were excluded. Of 45 cases examined, 29 met the eligibility criteria. **Results:** Histologically, 16/29 cases (55.1%) exhibited TB (average =6.4 buds/polyp, range 1 to 14) and 7/16 (43.7%) had metastasis (5 in regional lymph nodes, 1 in pleural fluid, and 1 in mesenteric fat). Only 1/13 (7.7%) cases without TB developed regional lymph node metastasis. 8/29 cases had LVI, and only 2/8 (25%) developed metastasis while remainder 6/6(75%) didn't metastasize.

Table 1: Risk factors predictive of metastatic disease in malignant polyps

	Tumor budding	LVI	Close margin(<1mm)	High Grade	Sessile Vs Pedunculated	Tumor size(>8.5mm)
Sensitivity	87.5%	25%	55.5%	0%	27.5%	37.5%
Specificity	57.14%	71.42%	65%	85%	38%	52%
Positive predictive value	43.75%	25%	41.6%	0%	23.5%	23%
Negative predictive value	92%	71.44%	76%	0.69%	66.6%	68.7%
p Value	0.044*	1	0.405	0.540	0.682	1

*2-tailed Fisher exact test

The table summarizes the statistical performance of all risk factors analyzed in this study. TB was the only factor that was significantly associated with lymph node metastasis p=[thinsp]0.044 (2-tailed Fisher exact test).

Conclusions: TB was the only statistically significant factor in predicting the metastatic potential of malignant polyps with a high sensitivity (87.5%), acceptable specificity (57%) and high negative predictive value (92%). The identification of any tumor bud in malignant polyps is significant. TB should be routinely assessed and reported in all malignant polyps in order to manage early colorectal carcinoma properly.

749 Value of SATB2 Immunostaining in the Distinction between Small Intestinal and Colorectal Adenocarcinomas

CJ Kim, T Baruch-Oren, F Lin, X Fan, XJ Yang, HL Wang. UCLA, Los Angeles, CA; Geisinger Medical Center, Danville, PA; Cedars-Sinai Medical Center, Los Angeles, CA; Northwestern University, Chicago, IL.

Background: SATB2 (special AT-rich sequence binding protein 2) is a novel immunomarker that has been recently demonstrated to be highly sensitive and specific for colorectal adenocarcinoma (CRC). In this study, we investigated whether SATB2 could be used to separate CRC from primary small intestinal adenocarcinoma (SIA), which is an uncommon malignancy morphologically similar to or indistinguishable from CRC.

Design: Fifty-four surgically resected nonampullary primary SIAs and 35 CRCs were immunohistochemically examined for the expression of SATB2. Immunostaining for CDX2 was also performed for comparison. A case was considered positive if ≥5% of the tumor cells exhibited nuclear immunoreactivity. Positive staining was further graded as focal (5-50% of the tumor cells stained) or diffuse (51-100%); as well as weak, intermediate, or strong for staining intensity.

Results: The benign colonic epithelium was uniformly positive for both SATB2 and CDX2, but the benign small intestinal epithelium was positive only for CDX2 and was negative for SATB2. Positive SATB2 immunoreactivity was observed in 23 (43%) SIAs in contrast to 33 (94%) CRCs (p<0.0001). Among these, only 4 (17%) SIAs showed strong and diffuse SATB2 staining compared with 27 (82%) CRCs (p<0.0001). CDX2 stained 39 (72%) and 35 (100%) of SIAs and CRCs, respectively (p=0.0018). The frequencies of positive SATB2 and CDX2 immunostains in SIAs (43% vs 72%) were also statistically different (p=0.0035).

Conclusions: SATB2 is not entirely CRC-specific. It is expressed in a subset of SIAs, albeit much less frequently. In comparison with CDX2, SATB2 appears to be a better diagnostic marker in the distinction between SIA and CRC. Lack of SATB2 expression strongly suggests a small intestinal primary when the distinction from CRC is necessary.

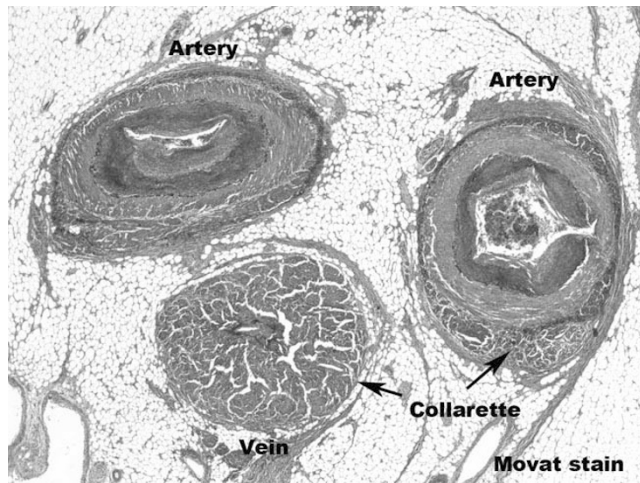
750 Mesenteric Arterial and Venous Dysplasia/Vasculopathy (MAVD/V) Is Distinct from Fibromuscular Dysplasia

J Kissiedu, CD Tan, ER Rodriguez, E Downs-Kelly, X Liu, DT Patil. Cleveland Clinic, Cleveland, OH.

Background: Fibromuscular dysplasia (FMD) is a non-inflammatory, non-atherosclerotic vasculopathy that usually affects the carotid and renal arteries. We have noted rare cases of FMD-like changes within mesenteric vessels of suspected ischemia (ISC) or IBD (especially Crohn's disease, CD) cases. Herein, we describe the clinicopathologic features of a distinct mesenteric vasculopathy (MAVD/V) and compare them with CD and ISC cases.

Design: Vascular findings of 9 suspected FMD cases (5 ileal, 2 colon, 2 ileocolonic) between 2000-2013 were compared with 35 ISC (11 ileal, 16 colon, 8 ileocolonic), 22 CD (13 small bowel, 1 colon, 8 ileocolonic), and 29 normal autopsy controls.

Results: The distinctive features of MAVD/V were (1) concentric/eccentric smooth muscle collarette around the tunica media of both artery and vein in ≥2 foci, (2) varying degrees of intimal and medial hyperplasia, and adventitial fibrosis, and (3) lack of inflammation or thrombi.



None of these features in combination were seen in ISC, CD or normal controls. MAVD/V patients were clinically diagnosed as CD (5/9, 56%), ISC (1), obstruction (1), sclerosing mesenteritis/mass (2). Unlike ISC patients who presented acutely (<1 week; 83%), both MAVD/V and CD patients had symptoms >1 year (78% and 95%); abdominal pain being the most common symptom. There was female predominance (M/F 1:2) with median age of 61 (range 40-86). Most ISC and CD showed mild arterial and/or venous intimal hyperplasia. Perivascular inflammation and granulomas were only seen in CD. Similar to CD, architectural distortion (66%), multifocal ulcers (78%), and pyloric gland metaplasia (78%) were common in MAVD/V. Ischemic-pattern of injury was seen in 2/9 (22%) cases. On follow-up (mean-20 months), 6/9 (66%) MAVD/V cases are asymptomatic, 2 died of unrelated causes, and 1 has neo-terminal ileal inflammation. **Conclusions:** We propose the name mesenteric arterial and venous dysplasia/vasculopathy for a rare and distinct non-inflammatory, non-atherosclerotic, localized form of mesenteric vasculopathy that involves both arteries and veins in close proximity to the bowel, separating it from typical FMD. Long-standing abdominal pain in older women is a common clinical setting. Surgical resection appears to be curative with a favorable clinical outcome.

751 Post -Ablation Esophagitis: An Additional Differential Diagnosis for Lymphocytic Esophagitis

J Kissiedu, T Gohel, R Lopez, P Thota, IO Gordon. Cleveland Clinic Foundation, Cleveland, OH.

Background: Lymphocytic esophagitis (LE) is a recently described clinicopathologic entity characterized by peripapillary lymphocytosis with spongiosis and associated dysphagia or odynophagia. In patients who have undergone radiofrequency ablation (RFA) and/or cryotherapy for treatment of Barrett's esophagus (BE) with low or high grade dysplasia, histologic features of eosinophilic esophagitis (EoE), but not LE, have been described. Our study aims to evaluate the occurrence of EoE and LE in patients who have either undergone RFA, cryotherapy or both for treatment of BE.

Design: A retrospective study was conducted under an IRB-approved protocol by searching the Barrett's esophagus registry for patients who had received RFA, cryotherapy or both for treatment of BE with dysplasia between 2009-2011. Exclusion criteria included patients with only endoscopic mucosal resection, lack of surveillance biopsy, pre-intervention biopsy with EoE or LE, and slides unavailable for review. Clinical and endoscopy data were collected and biopsies were reviewed for inflammation and architectural changes at three time points: pre-intervention, 1st surveillance and most recent surveillance. LE was defined as marked peripapillary lymphocytosis with spongiosis and EoE was defined as >15 eosinophils per high power field with eosinophil microabscesses.

Results: A total of 24 patients met the inclusion criteria. There was significant histologic evidence of post-therapy LE both in the first surveillance biopsy (N=5, 20.8%, p=0.046) and in the most recent surveillance biopsy (N=8, 47.1%, p=0.008). There were no significant clinical or endoscopic features associated with LE. EoE was seen in 1 patient pre-intervention and 2 patients post intervention.

Conclusions: Histologic features of LE are common following ablation therapy for BE with dysplasia. There were no clinical or endoscopic features associated with histologic features of LE. LE may be an incidental finding or a nonspecific inflammatory response to the intervention in patients who have undergone RFA or cryotherapy. Our findings expand the clinical spectrum of the histologic findings in LE. EoE was not a significant finding in this study.

752 Discordant Neuroendocrine Marker Expression between Primary and Metastatic Colorectal Cancer – A Possible Pitfall in Guiding Targeted Therapy

B Kleist, C Loland, C Kersten, M Kempa, M Poetsch. Southern Hospital Trust, Kristiansand, Norway; University Hospital Essen, Essen, Germany.

Background: Neuroendocrine differentiation in metastatic colorectal cancer (CRC) is a promising target for new oncologic treatment approaches, but the optimal tissue source for immunohistochemical testing has not been clearly determined so far. Therefore, this study analyzed the evidence of neuroendocrine differentiation in paired primary and metastatic CRC samples.

Design: Immunohistochemical expression analysis of the neuroendocrine markers chromogranin and synaptophysin was performed on 441 CRC specimens comprising primary and metastatic tumors from 115 patients. Neuroendocrine differentiation status according to a three level system (0: 0%, 1+: >0%/<30%, and 2+≥ 30% of tumor cells positive, respectively) was compared in 71 matched distant metastasis (DM)/primary tumor (PT) pairs, 255 matched lymph node metastasis (LNM)/PT pairs and 53 matched DM/LNM pairs.

Results: Immunohistochemical chromogranin and/or synaptophysin expression comprising both levels, 1+ and 2+, was seen in 36 out of 115 (31.3%) PTs, 19 out of 71 (26.8%) DMs and 51 out of 255 (20%) LNMs. Neuroendocrine differentiation status was discordant in 38% of the DM/PT pairs, 35.3% of the LNM/PT pairs and 30.2% of the DM/LNM pairs, considering all three expression levels. The discordance rates of neuroendocrine marker expression for matched LNM/PT, DM/PT and DM/LNM pairs, respectively, were highest at level 1+ and lowest at level 0. Discordant neuroendocrine marker expression in multiple LNMs and multiple DMs within individual cases was seen in 31.8% and 23.1% of patients, respectively.

Conclusions: To guide therapy targeting neuroendocrine differentiation in metastatic CRC, it is recommendable to analyze the distant metastases instead of drawing conclusions from the primary tumors or lymph node metastases. However, this approach has to be confirmed by studies on larger CRC cohorts with neuroendocrine differentiation.

753 Prognostic Significance of Human Tissue Kallikrein-Related Peptidases 6 and 10 in Gastric Cancer

DL Kolin, K Sy, F Rotondo, MN Bassily, K Kovacs, C Streutker, GM Yousef. St. Michael's Hospital, University of Toronto, Toronto, ON, Canada; Credit Valley Hospital, Mississauga, ON, Canada; Menoufiya University, Monufia, Egypt.

Background: The prognosis of patients following surgery for gastric cancer is often poor and is estimated using traditional clinicopathological parameters which can be inaccurate predictors of future survival. Kallikreins are a group of serine proteases which are differentially expressed in many human tumours and are being investigated as potential cancer biomarkers. The aim of this study was to correlate human tissue kallikrein 6 and 10 (KLK6 and KLK10) expression with histopathological and clinical parameters in gastric cancer.

Design: We constructed a gastric tumour tissue microarray (TMA) from 113 gastrectomy specimens, and used immunohistochemistry (IHC) to measure KLK6 and KLK10 expression. A whole-slide scanned image of the TMA was analyzed using an automated algorithm by first segmenting the images based on stroma and epithelium, then separating the KLK IHC stain from the counterstain, and finally quantifying the staining intensity.

Results: KLK6 expression was significantly positively correlated with nodal involvement (p=0.002), and was predictive of advanced-stage disease (p<0.01). Kaplan-Meier survival curves revealed KLK6 positive tumours were significantly associated with lower overall survival (p=0.04). While KLK10 overexpression was also a predictor of advanced-stage disease (p<0.01), it was not significantly correlated with lymph node involvement or survival period. Interestingly, there was no significant difference in KLK6 expression in stromal vs. epithelial tissue, or Lauren classification.

Conclusions: KLK6 expression shows promise as a novel prognostic marker in gastric cancer. Automated analysis of TMA IHC staining has the potential to reduce both inter- and intra-observer variability and to reveal differences in staining not detected by conventional manual scoring.

754 Biopsy Findings in Patients with Small Bowel Transplantation

J Koo, DW Dawson, S Dry, SW French, B Naini, HL Wang. University of California, Los Angeles, Los Angeles, CA.

Background: Small bowel transplant (SBT) is now increasingly used for the treatment of patients with irreversible intestinal failure. Histologic evaluation of mucosal biopsies of the intestinal allograft is critical in the diagnosis of posttransplant complications particularly acute cellular rejection (ACR), infections and posttransplant lymphoproliferative disorder (PTLD). This study was undertaken to analyze biopsy findings in patients with SBT at our institution.

Design: Retrospective review of pathology reports on small bowel allograft mucosal biopsies occurring at UCLA Medical Center between 1997-2013 were analyzed. ACR was graded according to published criteria into no rejection (grade 0), indeterminate (IND), mild (grade 1), moderate (grade 2), and severe (grade 3). Other data recorded included presence of infectious agents on H&E staining, results of immunohistochemistry (IHC) and in situ hybridization (ISH) for viruses, results of work-up for PTLD, the presence of acute inflammation with or without ulceration, the presence of pyloric metaplasia, significant histologic findings from concurrent native bowel biopsies, and drug history.

Results: A total of 2003 small bowel allograft biopsies from 41 patients were analyzed. There were 22 males and 19 females, ranging in age from 10 month to 62 years (mean, 11.9 years). The majority of the biopsies (1544; 77%) showed no rejection. IND, grade 1, grade 2 and grade 3 ACR were observed in 132 (7%), 174 (9%), 41 (2%) and 67 (3%) biopsies, respectively. A total of 161 biopsies were performed from the native bowel, among which 24 biopsies were helpful in the differentiation between ACR and medication effect. Adenovirus, CMV and cryptosporidia were identified in 25 biopsies from 7 (17%) patients, 11 biopsies from 1 (2%) patient, and 5 biopsies from 2 (5%) patients, respectively. No HSV was demonstrated. Seven (17%) patients developed PTLD, but only 2 had PTLD present in small bowel allograft biopsies.

Conclusions: Moderate to severe ACR is an infrequent finding in small bowel allograft biopsies, seen in only 5% of the biopsies. Adenovirus is the most common infectious agent in the transplant setting, seen in 17% of patients. PTLD is also a common complication, although only a small fraction of the cases (29%) are detected in allograft biopsies.

755 FGFR1 Amplification and Overexpression in Colorectal Cancer with Clinicopathologic Correlation

YJ Kwak, SK Nam, AN Seo, S-B Kang, WH Kim, HS Lee. Seoul National University College of Medicine, Seoul, Republic of Korea; Seoul National University Bundang Hospital, Seongnam-si, Republic of Korea.

Background: Overexpression of FGFR1 has been reported in various cancers, especially squamous cell carcinoma of lung and esophagus, and suggested to be a noticeable therapeutic target. Although overexpression of FGFR1 has been reported in colorectal cancers, its clinicopathologic significance is still unclear. In this study, we investigated FGFR1 expression and amplification in colorectal cancer with correlation of clinicopathologic parameters.

Design: We performed dual color fluorescence in situ hybridization (FISH), RNA ISH and immunohistochemistry (IHC) of FGFR1 on a total of 372 consecutive colorectal adenocarcinomas using tissue array method. FISH was evaluable in 292 cases, RNA ISH in 371 cases, and IHC in 369 cases. FGFR1/CEP8 FISH signals were enumerated using a 100× objective in 100 non-overlapping nuclei of tumor cells per core. RNA level was scored into 5 grades (0 to 4) and protein expression of FGFR1 was scored into 4 grades.

Results: FGFR1 amplification (FGFR1/CEP8 ratio ≥ 2) was found in 4.1% (12/292), amplification and/or high polysomy in 5.5% (16/292), and mean copy number > 2 (amplification by Weiss et al.) in 26.0% (76/292). There was a tendency that left colon cancer had higher rate of FGFR1 amplification or high polysomy than right colon cancer. RNA overtranscription was observed in 52% (193/371) of patients and protein overexpression was in 20% (74/369). RNA overtranscription was significantly correlated with FGFR1 amplification, but protein expression was not correlated with FGFR1 amplification, high polysomy or RNA overtranscription. When FISH positive status was defined as mean copy number > 2 , it was significantly associated with aggressive clinicopathologic features including high pTNM stage ($p=0.018$), distant metastasis ($p=0.009$), lymph node metastasis ($p=0.001$) and perineural invasion ($p=0.017$). The patients with FISH positive status had worse overall outcome ($p=0.013$). However, FGFR1 amplification, high polysomy, or RNA overtranscription did not correlate with aggressive clinical features or patient outcome.

Conclusions: In this study, our results demonstrated that FGFR1 amplification/high polysomy occurred in a subset of colorectal adenocarcinoma suggesting FGFR1 as a therapeutic target. In addition, increased copy number of FGFR1 predicted aggressive clinical features and worse patient outcome.

756 K-ras Genetic Mutational Analyses of Small Bowel Adenocarcinoma in Sporadic Versus Crohn's Disease Associated Cases

HA Kwak, E Whitcomb, X Liu, S-Y Xiao. University of Chicago, Chicago, IL; Cleveland Clinic Foundation, Cleveland, OH.

Background: Although an uncommon gastrointestinal malignancy, small bowel adenocarcinoma (SBA) comprises approximately 40% of small bowel malignancies with a median age in the sixth decade of life. SBAs typically arise from the duodenum; however, small bowel adenocarcinomas associated with Crohn's disease (C-SBAs) frequently occur in the ileum at the site of chronic inflammation and in a younger population. Morphologic and immunohistochemical differences have also been observed between sporadic cases of small bowel adenocarcinomas (S-SBAs) and C-SBAs in our previous study. Currently, there is insufficient data on the molecular analysis of C-SBAs. The current study compares the frequency of K-ras mutations between S-SBAs and C-SBAs.

Design: A search for cases of SBAs was performed from our pathology archives (1992-2012). Six C-SBAs and seven S-SBAs were included in this study. The invasive portion of SBA was macrodissected from formalin fixed paraffin embedded (FFPE) tissues and DNA was isolated using FFPE DNA isolation kit from QIAGEN. Subsequently, K-ras mutational analysis was performed using the TIB MOLBIOL real-time PCR and melting curve analysis kit. The assay also included a locked nucleic acid (LNA) modified oligonucleotide clamp to block amplification of the normal sequence to increase the sensitivity of mutation detection. Selected cases were verified by a lab-developed SNaPshot™ (or single nucleotide extension) assay.

Results: K-ras mutations were seen in 20% of C-SBAs and 71% of S-SBAs.

Tumor type	Cases with K-ras mutation	Cases without K-ras mutation
C-SBAs	1 (17%)	5 (83%)
S-SBAs	5 (71%)	2 (29%)

p value (Fisher's exact test) = 0.08.

Conclusions: While a high frequency of K-ras mutations has been described in colonic adenocarcinoma associated with Crohn's disease and S-SBAs, our pilot study suggests C-SBAs have a lower incidence for K-ras mutations (17%) in comparison. A statistical significance was not reached due to the small number of cases and future study with additional cases is necessary. The findings nevertheless suggest that in contrast to colonic adenocarcinoma associated with Crohn's disease and S-SBAs, a significant portion of C-SBAs develop through alternative tumorigenesis pathways other than K-ras mutations.

757 Angiotensin Receptor Blockers Other Than Olmesartan Are Not Associated with Histologic Evidence of Duodenitis

SM Lagana, ED Braunstein, B Leibold, PHR Green. New York Presbyterian Hospital, Columbia University Medical Center, New York, NY.

Background: Recently, Olmesartan, an angiotensin receptor blocker (ARB) commonly used for treatment of hypertension has been shown to be associated with a severe sprue-like enteropathy with histologic findings of total villous atrophy, chronic lamina propria inflammation, active inflammation, eosinophilia, intraepithelial lymphocytosis, and increased subepithelial collagen thickness. Many of these patients were diagnosed as seronegative celiac disease and discontinued gluten with no clinical or pathologic

improvement. In our experience, all of these changes are reversible following discontinuation of Olmesartan. We were interested in whether other angiotensin receptor blockers caused duodenitis.

Design: We reviewed duodenal biopsies from 10 patients taking an angiotensin receptor blocker other than Olmesartan (Losartan: 8, Valsartan: 1, Telmisartan: 1) and paired them with 10 age and sex matched controls not taking an angiotensin receptor blocker. No patients with celiac disease or active *Helicobacter pylori* infection were included. Biopsies were reviewed by a gastrointestinal pathologist who was blinded to medication status. Features evaluated included villous architecture, maximum intraepithelial lymphocytes and distribution of any lymphocytosis (diffuse vs. focal), lamina propria chronic and active inflammation, subepithelial collagen thickness, crypt apoptosis, and eosinophilia.

Results: There were no statistically significant differences between the ARB users and controls for the variables described above.

	ARB users (n=10)	Controls (n=10)	p value
Villous atrophy	1/8 (13)	1/9 (11)	0.9293
Crypt hyperplasia	2/8 (25)	2/8 (25)	1.0
Mean IEL count	15.1	26.9	0.0549 (Mann-Whitney)
Generalized IEL increase	2 (20)	5 (50)	0.3498
Chronic LP inf	4 (40)	5 (50)	1.0
Increased LP eo	2 (20)	2 (20)	1.0
Active	2 (20)	3 (30)	1.0
Increased crypt apop	5 (50)	5 (50)	1.0
Increased collagen	0	0	1.0

Conclusions: Olmesartan use is emerging as an important association with a debilitating clinicopathologic syndrome in a small proportion of users. Pathologists should be aware of this entity, and should consider/suggest clinical exclusion of it in every case of seronegative villous atrophy. As we investigate more cases, if the data continues to suggest that other angiotensin receptor blockers do not cause any recognizable duodenitis, then this is important information for clinicians to have when analyzing the risk and benefit profile of an antihypertensive drug.

758 Esophageal Squamous Papilloma: No Correlation with Intraepithelial Eosinophils

DJ Lager, JA Nielsen, M Lewin, CA Roberts. ProPath, Dallas, TX.

Background: Traditionally thought to be related to either reflux esophagitis (RE) or human papilloma virus, esophageal squamous papillomas (ESP) are an infrequent benign polypoid squamous epithelial lesion with a prevalence rate estimated to be 0.01 to 0.45% according to endoscopic- and autopsy-based studies. Although the etiology is unknown, a relationship between ESP, eosinophilic esophagitis (EoE), and RE has been recently suggested. The purpose of this study is to describe and correlate the endoscopic features of ESP with the presence of intraepithelial eosinophils (EoE and/or RE) in a large population of adult patients.

Design: Between 1/24/2006 and 8/14/2013, 317 biopsies corresponding to 314 cases from 308 patients with a diagnosis of ESP from two institutions staffed by the same Pathology group were identified. Demographic data, the endoscopic location and features of the ESP, and the presence of concurrent or prior esophageal disease (EoE or RE) was recorded.

Results: Among the 308 patients, which included 197 (64%) females and 111 (36%) males (age range: 22-86 years; mean: 52 years), ESP were most commonly diagnosed between 40 and 69 years and were twice as common in females (20%) vs. males (10%) in the 6th decade of life. Thirty-one (10%) patients had a concurrent or previous morphologic diagnosis of EoE or increased eosinophils, 61 (20%) had RE, and 83 (27%) had either. A greater percentage of the biopsies from males (34%) had increased eosinophils compared to those from females (22%). Sixty-seven ESP (21%) were from the gastroesophageal junction (GEJ) or distal esophagus, 19 of which (28%) were associated with EoE or RE. Of the 92 mid and 93 proximal esophageal biopsies, 44 (24%) were associated with EoE or RE. Of 65 biopsies (21%) in which the location of the ESP was unspecified, 21 (32%) were associated with EoE or RE. ESP not associated with other esophageal diseases occurred more commonly in the distal esophagus in males (35%) and the upper esophagus in females (38%).

Conclusions: ESP show a slight predilection for females over males (F:M=1.8:1), the majority of which occur in the 6th decade. Although present throughout the esophagus, they are more common in the mid or proximal esophagus (59%) than in the distal esophagus/GEJ (21%). Consequently, while nearly 30% of patients with ESP had associated EoE or RE, in this the largest study of ESP yet reported, these data do not support a causal relationship between ESP and EoE or RE.

759 For the Evaluation of Celiac Disease: Single Pass Biopsy Shows Superior Tissue Integrity and Diagnostic Interpretation as Compared to Bite-on-Bite

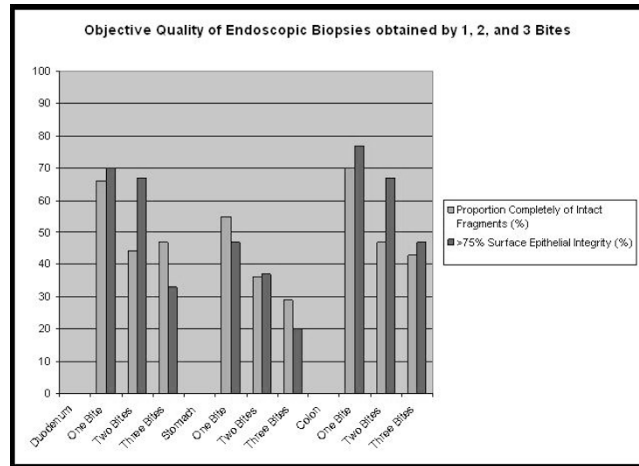
D Lam-Himlin, G De Petris. Mayo Clinic, Scottsdale, AZ.

Background: Diagnosis of celiac disease requires histologic evaluation of duodenal architecture and intraepithelial lymphocytosis, the interpretation of which relies on biopsy quality. The aim of this study was to determine if multiple biopsies obtained with jumbo forceps prior to removal from the endoscope (bite-on-bite technique) affects histological tissue quality or pathologic interpretation.

Design: Three gastroenterologists who consistently biopsy in a 1-, 2- or 3-bite manner, using 8mm jumbo forceps, were identified and 270 consecutive biopsy specimens (30 each from the stomach, duodenum, and colon for each endoscopist) were objectively scored for tissue integrity. Collagenous enteritis, mucosal lesions, and active inflammatory bowel disease were excluded. Objective criteria included: (1) presence of muscularis mucosae (MM); (2) integrity of surface epithelium (scored as 0%, 1-25%, 26-50%, 51-75%, >75%, 100%); (3) presence of crush artifact. Subjective criteria were also evaluated based on confidence of interpretation for: (1) duodenal villous atrophy; (2)

crypt-to-villous ratio; (3) intraepithelial lymphocytosis; (4) gastric mucin cell metaplasia. Confidence was scored as "none," "incomplete," and "complete".

Results: Objective results of 1-, 2- and 3-bites showed, respectively: totally intact fragments 65%, 44%, 41%; >75% integrity in duodenal specimen 70%, 67%, 33%. There was no difference in presence of MM or crush artifact between the bite techniques. "Complete" interpretive confidence of duodenal 1-, 2- and 3-bites, respectively, was seen in: villous atrophy 83%, 67%, 50%; crypt-to-villous ratio 80%, 67%, 40%; intraepithelial lymphocytosis 73%, 67%, 47%; gastric mucin cell metaplasia 47%, 50%, 37%. The decline in interpretive confidence paralleled the decline in tissue quality as the number of bites increased.



Conclusions: Single-bite biopsies of the duodenum are superior in both tissue integrity ($p < 0.006$) and diagnostic value ($p < 0.003$) compared to multiple-bite, a technique which causes surface epithelial stripping. Duodenal tissue appears more sensitive to stripping artifact compared to stomach or colon. Single-pass technique is recommended for duodenal biopsies, particularly for evaluation of celiac disease.

760 BRAF-Mutated Microsatellite Stable (MSS) Colorectal Carcinoma: An Aggressive Adenocarcinoma with Reduced CDX2 and Increased Cytokeratin 7 Immunohistochemical Expression

M Landau, S-F Kuan, S Chiosea, RK Pai. University of Pittsburgh Medical Center, Pittsburgh, PA.

Background: Reduced CDX2 and CK20 expression in colorectal carcinoma (CRC) with BRAF mutation and high-level microsatellite instability (MSI-H) has been well documented. The immunophenotype of BRAF-mutated microsatellite stable (MSS) CRC has not been reported. The aim of this study was to investigate the expression of CDX2, CK20, and CK7 in BRAF-mutated MSS CRC compared to BRAF-mutated MSI-H and BRAF wild-type CRC.

Design: 205 CRCs including 28 BRAF-mutated MSS, 53 BRAF-mutated MSI-H, and 124 BRAF wild-type MSS tumors were analyzed for CDX2, CK7, and CK20 immunohistochemical expression. Positive CK7 and CK20 staining was defined as any positive staining. CDX2 was scored semiquantitatively for intensity (0, absent; 1+, weak; 2+, strong) and percent of tumor cells staining. A modified H score for CDX2 (intensity x percentage of positive cells) was calculated with positive expression defined as > 1 . Each tumor was also analyzed for location, stage, and histologic features.

Results: BRAF-mutated MSS CRC displayed reduced CDX2 expression compared to BRAF wild-type MSS CRC (75% vs. 94%; mean H-score 98 vs 150, $p < 0.001$) (Table). CK7 expression was more often identified in BRAF-mutated MSS CRC compared to both BRAF-mutated MSI-H CRC and BRAF wild-type MSS CRC (39% vs. 6% vs. 6%, $p = 0.0001$). There was no difference in CK20 expression between BRAF-mutated MSS and BRAF wild-type MSS CRC. In contrast, BRAF-mutated MSI-H CRC was less often CK20 positive (70%, $p = 0.001$). BRAF-mutated MSS CRC were more frequently stage IV compared to BRAF-mutated MSI-H CRC and BRAF wild-type MSS CRC (32% vs. 8% vs. 15%, $p < 0.001$).

Immunophenotype of Colorectal Carcinoma Stratified by BRAF Mutation and MSI Status

Immunohistochemistry	BRAF-Mutated MSS CRC (%)	BRAF-Mutated MSI-H CRC (%)	BRAF Wild-Type MSS CRC (%)	P-value
Number of Cases	28	53	124	NA
CDX2 Positive	21 (75)	40 (75)	117 (94)	<0.001
Mean CDX2 H-score	98	85	150	<0.001
CK7 Positive	11 (39)	3 (6)	7 (6)	<0.001
CK20 Positive	26 (93)	37 (70)	110 (89)	0.001
CK20/CDX2				
Immunoprofile				
CK20+/CDX2+	20 (71)	31 (58)	108 (87)	<0.001
CK20+/CDX2-	5 (18)	6 (11)	4 (3)	
CK20-/CDX2+	1 (4)	9 (17)	9 (7)	
CK20-/CDX2-	2 (7)	7 (13)	3 (3)	

Conclusions: BRAF-mutated MSS CRC is an aggressive tumor which often presents with stage IV disease. BRAF-mutated MSS CRC displays reduced CDX2 and increased CK7 expression. Given the frequent presentation of BRAF-mutated MSS CRC with metastatic disease, our findings have implications for diagnostic immunohistochemistry when attempting to identify the origin of metastatic adenocarcinoma of unknown primary.

761 The Clinical Approach to Duodenal Nodules on Mucosal Biopsies: Could We Be Missing Something?

MS Landau, R Pai, DJ Hartman. University of Pittsburgh Medical Center, Pittsburgh, PA.

Background: We often receive duodenal mucosal biopsies to evaluate for endoscopic "polyps", "lesions", "nodules" or "masses". The differential diagnosis for this clinical can range from nodular peptic duodenitis to neuroendocrine neoplasm to adenoma/adenocarcinoma. We have anecdotally identified cases that have shown additional diagnostic findings on deeper levels. We examined our institutional practice for ordering levels on specimens received with this clinical history with a particular emphasis on whether these yielded a diagnosis of a neuroendocrine neoplasm. In addition, we examined duodenal biopsies that had been diagnosed as neuroendocrine neoplasms and the diagnostic findings on deeper levels.

Design: 107 duodenal biopsies from 103 patients diagnosed as neuroendocrine neoplasm or carcinoid from August 2003 to August 2013 were identified. 100 out of 107 biopsies had a recognized endoscopic abnormality. In addition, 225 consecutive duodenal biopsies from 190 patients submitted as "polyp", "lesion", "nodule" or "mass" over a recent one year (August 2012 to August 2013) period were identified. The final diagnosis for each case, the clinical history provided, patient's age, additional levels and additional stains were recorded. The cases with additional levels were reviewed by three pathologists to determine whether the final diagnostic findings were present on the initial levels or were revealed by deeper levels.

Results: Of the neuroendocrine neoplasms identified over a 10 year period from duodenal biopsies, 21/107 (19.6%) had additional levels. Ten out of twenty-one cases (47.6%, or 9.3% of the total) demonstrated the neuroendocrine neoplasm only on the deeper levels. Seventy-four (32.9%) of the 225 cases had deeper levels ordered and of these, only one demonstrated additional findings that were not apparent on the initial sections - an adenoma showed up on deeper levels. Of the 225 consecutive duodenal biopsies, a diagnosis of neuroendocrine neoplasm was rendered in 14 cases (6.2%). Four of these fourteen cases (28.6%) had additional levels performed on the blocks and in all cases diagnostic features were present on the initial sections.

Conclusions: Based on our institutional data, additional levels are frequently requested for duodenal biopsies with descriptions of "mass", "lesion", "polyp" or "nodule". Although there may be a low incidence of additional diagnostic findings by ordering deeper levels, a significant proportion of neuroendocrine neoplasms (9.3%) will be identified only by additional levels.

762 Specimen Length, Surgical Quality and Type of Operation, but Not Neoadjuvant Therapy, Affect Lymph Node Yield in Rectal Cancers

G Langman, AA Metcalf. Birmingham Heartlands Hospital, Birmingham, United Kingdom.

Background: The lymph node yield (LNY) following colorectal cancer (CRC) resection is considered to be a marker of both the pathological and surgical quality. The aim of this study was to study factors influencing LNY and lymph node size in a single pathologist series, with a special interest in rectal cancer reporting.

Design: 305 consecutive rectal resections reported by a single pathologist were identified from a prospectively collected database. All harvested nodes had diameter and area measured using image analysis software and recorded. Factors that may have influenced LNY were studied by univariate and multivariate linear regression analysis.

Results: 12426 lymph nodes were harvested with a median LNY of 38 nodes/patient (IQR 29-51). On univariate analysis increased specimen length ($r = 0.287, p = 0.001$), anterior resection versus abdominoperineal resection ($p < 0.001$) and higher quality total mesorectal excision (TME) ($p = 0.006$) were associated with an increased LNY, and this was confirmed on multivariate analysis. Of note lower T and N stage and neoadjuvant therapy did not statistically influence LNY but were associated with a reduced LN area (T stage $p < 0.001$, N stage $p < 0.001$ and pre-op neoadjuvant therapy $p < 0.001$).

Conclusions: In this series LNY was higher than generally previously reported and only longer specimen length, operation type and quality of the TME were independently associated with increased LNY. Less pathologically advanced tumours and neoadjuvant therapy were not associated with reduced LNY, as has been previously reported, but were associated with a reduction in LN size.

763 Insights from Molecular Profiling in the Clinical Management of Mucinous Carcinoma Peritonei

TC Larman, MA Valasek, GY Lin. University of California San Diego, San Diego, CA.

Background: Although appendiceal mucinous neoplasms are uncommon, they precede the vast majority of clinical cases of pseudomyxoma peritonei, or mucinous ascites. The nomenclature for histologic categorization of both the primary neoplasms and the pattern of intra-abdominal spread remains controversial. As molecular profiling services are increasingly adopted by clinicians, there are new opportunities for studying the molecular characteristics of these tumors, which remain incompletely understood.

Design: A retrospective study was undertaken to analyze commercially-available molecular profiling data obtained from 2011-2013 for patients diagnosed with appendiceal mucinous neoplasms with intra-abdominal spread. This cohort included eleven individuals with low-grade mucinous carcinoma peritonei, seven individuals with high-grade mucinous carcinoma peritonei, and four individuals with appendiceal mucinous adenocarcinoma. Molecular profiling performed included immunohistochemical, RT-PCR, and/or microarray probing of a proprietary panel of well-established proteins involved in tumorigenesis, as well as KRAS and BRAF mutation analysis.

Results: In our cohort, sixteen of twenty-two patients were found to have KRAS point mutations (73%); all but one occurred in exon 12. Low-grade mucinous carcinoma peritonei demonstrated the highest proportion of mutations (82%). Cases with KRAS

mutation were universally negative for BRAF mutation. Further, expression profiling revealed patterns of increased expression of COX-2 (100% of cases assayed), O-6-methylguanine-DNA-methyltransferase (MGMT), and ERCC-1, and decreased expression of thymidylate synthetase (TS) within these tumors.

Conclusions: KRAS mutations appear in the majority of appendiceal mucinous neoplasms in our limited cohort at a rate of nearly 2-fold greater than has been reported in colorectal cancers (approximately 40%). These activating mutations are associated with poor response to EGFR-targeting drugs. An expanded cohort of tumors will be queried to further establish the frequency of these mutations and to determine whether they correlate with histologic tumor grade, treatment course, or patient outcomes. COX-2 overexpression in this cohort, which has been shown to regulate mucin production, further validates proposals for adopting anti-inflammatory drugs into treatment regimens. These data demonstrate the potential for a new classification of these neoplasms based on stratification by molecular signatures, as well as implications for therapeutic approaches.


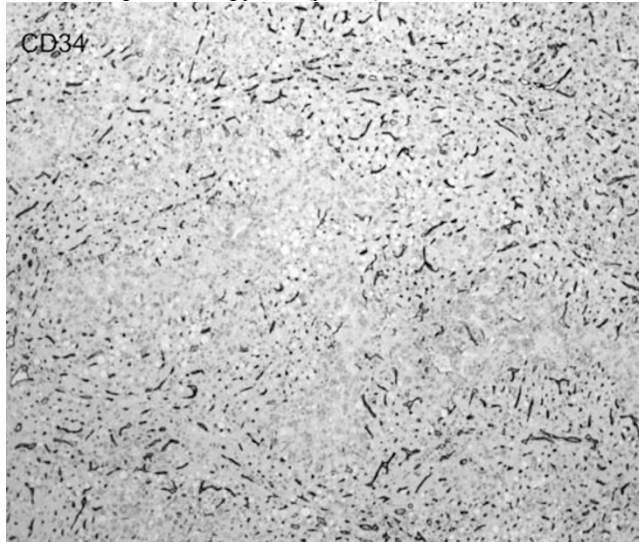
764 Laminin β 1 Deposition Parallels CD34 Antigenicity in Hepatocellular Carcinoma

BK Larson, D Dhall, S Chopra, M Kahn, M Guindi. Cedars-Sinai Medical Center, Los Angeles, CA.

Background: In normal liver, hepatocytes have no supporting basement membrane. However, electron microscopy has shown that basement membrane materials accumulate in the space of Disse in hepatocellular carcinoma (HCC). The sinusoidal endothelium of HCC also gains positivity for CD34. Together, these changes comprise the "capillarization/arterialization" of sinusoids in HCC. Laminins are basement membrane glycoproteins with migratory and signaling functions that have been shown to be therapeutic targets in animal models of several cancers. The laminin β 1 (LB1) subunit is expressed in the sinusoids of HCC, unlike in non-tumor liver. We investigated whether basement membrane acquisition parallels CD34 expression in HCC by comparing patterns of CD34 and LB1 immunostaining.

Design: 40 HCC cases were immunostained against CD34 (Epitomics, Burlingame, CA) and LB1 (Abcam, Cambridge, MA). Canalicular CD34 staining was recorded as positive or negative. Sinusoidal LB1 staining was then recorded as a percentage of the CD34-positive area of HCC. Statistical analysis was performed using the χ^2 goodness-of-fit test, with a p value of <0.05 considered significant.

Results: 39 of 40 (97.5%) cases were positive for CD34. Of these, 31 (79.5%) also stained for LB1. 25 (80.6%) showed co-localization of LB1 staining in 75-100% of the CD34-positive area. 4 (12.9%) showed LB1 staining in >100% of the CD34-positive area. 2 (6.5%) showed LB1 staining in <75% of the CD34-positive area. The number of cases with 75-100% CD34-LB1 co-localization was significantly higher than the number showing other staining patterns ($p=0.001$).



Conclusions: LB1 expression co-localizes with CD34 positivity and contributes to a compositional difference between the basement membrane of background cirrhosis and the capillarized sinusoids of HCC. If LB1 proves to be significantly sensitive and specific, it could potentially be both a diagnostic marker and target for anti-angiogenic therapy.

765 TTF-1 Is Expressed in a Subset of Esophageal Adenocarcinomas

AC Layne, TJ Cummings, CD Guy, DM Cardona, RC Bentley, MJ Shealy, X Zhang, SJ McCall. Duke University, Durham, NC.

Background: Distinguishing primary esophageal adenocarcinoma (EAC) from direct extension of primary pulmonary adenocarcinoma (PA) into the esophagus can be difficult in locally advanced tumors. Caudal-type homeobox 2 (CDX2) has 80% sensitivity and excellent specificity for EAC, and thyroid transcription factor-1 (TTF-1) is a sensitive marker for PA. Three studies, totaling 26 individual cases, have described a complete lack of TTF-1 positive EAC cases. Thus, CDX2 and TTF-1 make an attractive panel to differentiate between these two tumor types. In our present study, we show that this is, in fact, not the case. We have observed a small but significant group of TTF-1 positive EACs with unique clinical characteristics. We speculate that these tumors may be part of a molecularly distinct class of esophageal tumors.

Design: Resection specimens from twenty-four primary EACs were identified in our database after IRB approval. None of the patients had a known history of PA. Formalin-fixed paraffin-embedded 5-um-thick tissue sections from each case were treated with heat-induced epitope retrieval and examined using clinically validated immunohistochemical staining protocols for TTF-1, CDX2, and CK7 in all cases, with cytokeratin 20 and villin staining utilized in difficult or ambiguous cases. Antibody staining was scored semi-quantitatively for both percentage of tumor cells staining (0,1,2,3) and strength of stain (0,1+,2+,3+). Only nuclear staining for CDX2 and TTF-1 was counted as positive.

Results: All cases were determined to be of true esophageal origin based on clinical history, imaging, gross impressions of the surgeon and pathologist, and histologic and broad immunohistochemical evaluation by a group of GI-subspecialty pathologists. 23 of the 24 cases displayed strong expression of CK7 (95.8%). 21 of the 24 cases displayed strong nuclear CDX2 expression (87.5%). Contrary to published literature, 3 of the 24 cases displayed strong TTF-1 nuclear expression (12.5%). Of these three, one is a pT1 tumor in a patient with Barrett's esophagus. These patients were much younger ($p=0.00005$) and two of the three tumors also lacked expression of CDX2.

Conclusions: Nuclear expression of TTF-1 is present in a small subset of EAC cases. TTF-1 positive EACs occur in younger patients and typically lack expression of CDX2. These tumors may represent a unique subtype of esophageal cancer with a distinction antigenic expression pattern. Finally, caution should be used when diagnosing pulmonary adenocarcinoma invading the esophagus based on TTF-1 staining in isolation.

766 Correlation between c-MET Expression and Clinicopathologic Factors and Survival in Gastric Carcinoma

SM Lee, Z Zhou, M Xia, S Hamilton, D Tan. University of Texas MD Anderson Cancer Center, Houston, TX; University of Rochester Medical Center, Rochester, NY; The University of Texas Medical Branch, Galveston, TX.

Background: c-Met is an oncogene protein that express frequently in malignancies. Although several studies demonstrated c-MET overexpression in 18-82% of gastric carcinoma, data on the clinicopathologic parameters and survival of c-MET in gastric carcinoma has been inconsistent. We investigated a correlation between clinicopathologic factors, prognostic significance and c-MET expression in gastric carcinoma.

Design: We retrospectively reviewed 229 resection cases of early and advanced gastric carcinoma and constructed tissue microarrays using the formalin fixed paraffin embedded tissue. Immunohistochemical studies for c-MET were performed on TMA and they were analyzed the expression of c-MET protein by modified HERcept test scoring system which calculates scores for c-MET expression base on the percentage of membranous staining and intensity as follows: 0: no staining; 1: a faint/barely

perceptible membrane staining; 2: a weak to moderate complete membrane staining; 3: a strong complete membrane staining.

Results: In 94% (216/229) of gastric carcinoma, c-MET expression was found. The extent of membranous staining for c-met protein is significantly correlated with diffuse type of gastric carcinoma (versus intestinal, $p=0.0292$) and distant metastasis ($p=0.0108$). However, other clinicopathologic parameters including race, sex, age, degree of differentiation, depth of invasion, lymph node metastasis, and TNM stage did not show any significant correlations. After categorizing patients' population as two groups based on the extent of c-MET expression (low versus high c-Met expressed groups), c-MET high patients' group is significantly associated with lymph node metastasis ($p=0.0238$). However, the survival data between low and high c-Met expressed patients' groups fails to demonstrate a significant prognostic impact between two patients' groups. **Conclusions:** Our study indicates that the extent of c-MET protein expression is correlated with diffuse type and distant metastasis. Furthermore, high level expression of c-MET is significantly associated with lymph node metastasis. Immunohistochemistry of c-MET might be used to provide information for patients with gastric cancer could benefit target therapy of c-MET inhibitor.

767 Serrated Colorectal Polyps in Idiopathic Inflammatory Bowel Disease

L Lee, RK Pai, X Liu, H Xie, D Allende. Cleveland Clinic, Cleveland, OH.

Background: Approximately 20-30% of all colorectal carcinomas arise from serrated precursor lesions and represent $\geq 30\%$ of interval carcinomas. Despite our understanding of the cancer risk of sporadic sessile serrated polyps (SSP), no published data exists on the clinical significance of serrated polyps in patients with idiopathic inflammatory bowel disease (IBD). The study aims to determine the histologic spectrum of serrated polyps in IBD and their association with synchronous dysplasia.

Design: A search from 1987-2013 was conducted using keywords: IIBD, hyperplastic polyp/change, SSP, and traditional serrated adenomas (TSA). H&E slides were reviewed by 3 expert GI pathologists and reclassified as: HP, SSP, SSP with dysplasia (SSPD), TSA and atypical serrated polyps (AP) (non-dysplastic serrated polyps without definitive features of HPs or SSPs). Demographics (age and gender), years in surveillance, smoking history, and presence of synchronous dysplasia (low-grade and high-grade) or adenocarcinoma were recorded.

Results: From the 137 patients (58 females, 79 males) with IIBD (81 ulcerative colitis, 39 Crohn's, 17 indeterminate colitis) there were 166 serrated polyps of which 112 were reclassified as HPs (67.5%), 31 SSPs (18.7%), 4 SSPDs (2.4%), 1 TSA (<1%) and 18 APs (11%). For statistical analysis, the TSA case was eliminated and the SSPs and SSPDs were grouped into a single category ($n=136$ patients). SSPs and APs were more frequently right sided, while HPs were more often left-sided (71%, 53%, and 63%, respectively, $p<0.001$). Of the 39 patient with synchronous dysplasia, 36 patients had low-grade dysplasia (92.3%) and 3 patients had high grade dysplasia (7.7%). Only 1 synchronous adenocarcinoma was found in a patient with an HP. Among the groups, age (mean 53 y, range 18-79 y), gender, years in surveillance (mean: 15 y, range 1-59 y), IIBD type, smoking history (66% were current or ex-smokers), and number of foci of synchronous dysplasia were not statistically significant.

Serrated Colorectal Polyps in Idiopathic Inflammatory Bowel Disease

	HP (n=97)	SSP (n=24)	AP (n=15)	P value
Gender (F:M)	40:57	13:11	5:10	0.4
IIBD (UC:CD:IC)	54:30:13	15:6:3	11:3:1	0.8
Site (L:R:Other)	61:35:1	4:17:3	3:8:4	<0.001
Dysplasia (Y:N)	25:72	8:16	6:9	0.4
No. of Dysplastic Foci (0:1:2+)	72:22:3	16:7:1	9:3:3	0.1

Analysis by Fisher's Exact Test

Conclusions: SSPs/TSAs represent 21.7% of all serrated polyps encountered in this IIBD cohort. Serrated polyps occur preferentially in females with IIBD and in the right colon. Separate foci of synchronous dysplasia can occur (~29% of cases), mostly low-grade dysplasia, but was not statistically different among the groups.

768 Annexin A10 as a Potential Marker of Sessile Serrated Polyps in Idiopathic Inflammatory Bowel Disease

L Lee, RK Pai, X Liu, H Xie, D Allende. Cleveland Clinic, Cleveland, OH.

Background: Sessile serrated polyps (SSPs) are precursor lesions in the serrated neoplasia pathway in colorectal carcinoma. Serrated colorectal polyps, specifically SSPs, have been shown to carry significant risk of synchronous carcinoma and account for $\geq 30\%$ of interval carcinomas. Our prior study showed annexin A10 (ANXA10) as a potential marker of SSPs, differentiating them from the morphologically similar, but prognostically benign hyperplastic polyp (HP). Herein, we investigated the utility of ANXA10 in SSPs in the setting of idiopathic inflammatory bowel disease (IIBD).

Design: Retrospectively, we identified a total of 165 polyps with serrated architecture from 136 patients (58 females and 78 males, ages 18-79 y) with IIBD (80 with ulcerative colitis, 39 with Crohn's, and 17 with indeterminate colitis) from 1987 to 2013. The H&E stained slides were reviewed by 3 expert GI pathologists and classified as: (1) HPs, (2) SSPs, and (3) atypical serrated polyps (APs) (non-dysplastic polyps which could not be definitively classified as either HPs or SSPs). We selected all SSPs and APs and a matching group of HPs for the purpose of the study. Expression of ANXA10 was evaluated by immunohistochemistry and scored in a consensus reading using the following system: 0 (0%), 1 (1-25%), 2 (26-50%), 3 (51-75%), and 4 (>75%). Location of the polyps was recorded.

Results: All SSPs ($n=35$) and APs ($n=17$) along with 66 HPs were stained with ANXA10. 25 SSPs (61%) and 8 APs (20%) showed increased expression of ANXA10 with scores ≥ 3 while 58 HPs (75%) showed lack of or minimal expression of ANXA10 with scores ≤ 2 ($p<0.001$). ANXA10 expression was increased in 31/66 (76%) right colon polyps vs. 10/51 (24%) left colon polyps ($p=0.003$). High ANXA10 expression

(score ≥ 3), as a marker for SSPs, had a sensitivity of 74% (95% CI, 56-87%), a specificity of 88% (95% CI, 78-95%), a PPV of 76% (95% CI, 58-89%), and a NPV of 87% (95% CI, 76-94%).

Utility of ANXA10 as a Marker for SSPs in IIBD

	HP (n=66)	SSP (n=35)	AP (n=17)	P value
ANXA10 ≤ 2	58 (75%)	10 (13%)	9 (12%)	<0.001
ANXA10 ≥ 3	8 (19%)	25 (61%)	8 (20%)	

Analysis by Fisher's Exact Test

Conclusions: Analogous to its sporadic counterpart, about three quarters of SSPs in IIBD express ANXA10 with increased expression more frequently occurring in right colon polyps. An ANXA10 score of ≥ 3 is specific for SSPs with a high negative predictive value. ANXA10 is a potential marker for SSPs in IIBD and is valuable in differentiating SSPs from HPs. In addition, the comparable ANXA10 expression in SSPs and HPs in both sporadic and IIBD cases suggests that their biology may be similar.

769 Adenomatous Lesions in Inflammatory Bowel Disease

LH Lee, M Fort Gasia, M Iacucci, S Urbanski. University of Calgary, Calgary, AB, Canada.

Background: Conventional adenomas (CAs), sessile serrated adenomas (SSAs), and traditional serrated adenomas (TSAs) are pre-cancerous lesions that require increased colonoscopic surveillance. While these lesions are well studied in the general population, they are not well characterized in patients with inflammatory bowel disease (IBD). The objectives of this study are to describe and compare the characteristics of CAs, SSAs, and TSAs in patients with IBD.

Design: All IBD patients with a biopsy between 2005 and 2009 were identified through a search of the regional tertiary care hospital pathology database. A chart review was performed identifying each patient's gender, age at which the biopsy was performed, IBD type (Crohn's disease, CD; ulcerative colitis, UC; indeterminate), biopsy location, and lesion size. All available histology was reviewed by a GI pathologist who was blinded to the original diagnosis. Sporadic adenomas and dysplasia-associated lesions or masses were not differentiated and were considered together as CAs. Data was compared with one-way ANOVA or Fisher's exact test using SPSS 19.

Results: 319 biopsies in 188 patients were identified. 288 biopsies in 164 patients were available for review. Pathology review resulted in 97 CAs, 25 SSAs, and 4 TAs in 84 patients. Comparing the 3 adenoma types, no difference was identified in patient age (in years: CA=56.4 \pm 13.7, SSA=55.3 \pm 13.4, TA=53.2 \pm 20.0, $p=0.86$), or lesion size (in cm: CA=0.58 \pm 0.40, SSA=0.61 \pm 0.34, TA=0.73 \pm 0.25, $p=0.75$). Compared to CA, serrated adenomas (SSAs and TAs) are more prevalent in females ($p=0.03$). There does not appear to be a relationship between adenoma type and IBD type ($p=0.86$). Comparing all IBD patients, there is a significant difference in the anatomic distribution of adenoma types ($p=0.02$) with CAs more common distally, SSAs more common proximally, and TAs evenly distributed. Among only CD patients, a similar difference in distribution is noted ($N=53$, $p<0.001$). However, among UC patients, there is no significant difference in distribution ($N=66$, $p=0.49$) with a more uniform distribution across the colon.

Conclusions: The anatomic distribution of adenomatous lesions differed between CD and UC patients. While CD patients had a distribution similar to that of the general population, UC patients had a more uniform anatomic distribution of all adenoma types. Additionally, serrated adenomas were found to be more prevalent in females. The reasons for these findings are presently unknown. In particular, the adenoma distribution in UC patients may point to a relationship between adenoma and UC pathogenesis, and may have significant clinical implications.

770 Is Gastric Pit Dysplasia a Distinct Subtype of Gastric Epithelial Dysplasia (GED)? Clinicopathological Features and Mucin Expression in 878 Consecutive Endoscopically Resected GED

HJ Lee, J-Y Kim, N Shin, W-Y Park, DY Park. Pusan National University Hospital, Busan, Republic of Korea.

Background: It was previously reported that gastric pit dysplasia (GPD) was microscopically identified in the adjacent mucosa of gastric adenocarcinoma. However, there are debates of existence of endoscopically identifiable GPD, which can be a distinct subtype of gastric epithelial dysplasia (GED).

Design: We have reviewed 878 consecutive cases of endoscopically resected GED specimens during January 2011 to August 2013 for existence of endoscopically distinct lesion composed of GPD. These 878 gastric lesions were endoscopically resected because they were diagnosed as neoplastic lesion on prior biopsy. We evaluated clinicopathologic features of endoscopically resected GED and mucin expression (Muc2, Muc5AC, Muc6 and CD10) by immunohistochemistry.

Results: Among 878 GED cases, we have found 29 cases (3.2%) of endoscopically distinct lesion composed of GPD. Adenomatous type, foveolar type and hybrid type of GED showed 58.7% (515/878), 12.5% (110/878), and 25.6% (225/878), respectively. GPD type GED showed younger age than adenomatous, foveolar type ($p<0.05$) and showed more antropyloric location compared to adenomatous type, similar with foveolar and hybrid type ($p<0.05$). Also they showed high-grade compared to adenomatous type, similar with foveolar and hybrid type ($p<0.05$). GPD type GEDs showed more Muc5AC expression and less CD10 expression compared to adenomatous type, similar with foveolar and hybrid type ($p<0.05$).

Conclusions: We suggested that gastric pit dysplasia is endoscopically identifiable distinct GED lesion. Also they showed different location, grade and mucin expression compared to adenomatous type GED. More detailed and multi-institutional studies are needed to determine precise clinical significance of GPD type GED.

Table 1. Relationship between type of gastric epithelial dysplasia and clinicopathological characteristics

	Case no.	Type of gastric epithelial dysplasia			
		Adenomatous (515)	Foveolar (110)	Hybrid (225)	GPD (28)
Age (years) [†]		64.9±0.4	64.9±0.85	65.2±0.54	61.2±2.0
Sex					
Male	588	348 (67.6)	67 (60.9)	153 (68.0)	20 (71.4)
Female	290	167 (32.4)	43 (39.1)	72 (32.0)	8 (28.6)
Size		1.44±0.04	0.94±0.06*	1.47±0.06	1.30±0.18
Location [‡]					
Upper	135	94 (18.3)	6 (5.5)	33 (14.7)	2 (7.1)
Middle	160	113 (21.9)	14 (12.7)	29 (12.9)	4 (14.3)
Lower	583	308 (59.8)	90 (81.8)	163 (72.4)	22 (78.6)
Gross type					
Elevated	620	368 (71.5)	83 (75.5)	150 (66.7)	19 (67.9)
Flat	164	101 (19.6)	14 (12.7)	45 (20.0)	4 (14.3)
Depressed	94	46 (8.9)	13 (11.8)	30 (13.3)	5 (17.9)
Grade [§]					
Low	692	451 (87.6)	74 (67.3)	145 (64.4)	22 (78.6)
High	186	64 (12.4)	36 (32.7)	80 (35.6)	6 (21.6)
Resection margins					
Negative	815	466 (90.5)	105 (95.5)	216 (96.0)	28 (100.0)
Positive	63	49 (9.5)	5 (4.5)	9 (4.0)	0 (0.0)

*1 p<0.05 between GPD vs adenomatous type, GPD vs hybrid type

†2 p<0.05 between Lower (pylorus, antrum, angle) vs Middle (body) + Upper (fundus, cardia)

‡3 p<0.05

Table 2. Relationship between type of gastric epithelial dysplasia and mucin expression

	Case No.	Types of Clear cell changes			
		Adenomatous (401)	Foveolar (77)	Hybrid (184)	GPD (12)
CD10 ⁺					
< 10%	267	116 (28.9)	49 (63.6)	93 (50.8)	9 (75.0)
= 10%	406	285 (71.1)	28 (36.4)	90 (49.2)	3 (25.0)
Muc2					
< 10%	600	361 (90.0)	68 (88.3)	161 (87.5)	10 (83.3)
= 10%	74	40 (10.0)	9 (11.7)	23 (12.5)	2 (16.7)
Muc5AC ⁺					
< 10%	474	325 (81.0)	30 (39.0)	116 (63.0)	3 (25.0)
= 10%	200	76 (19.0)	47 (61.0)	68 (37.0)	9 (75.0)
Muc6					
< 10%	438	292 (72.8)	39 (50.6)	101 (54.9)	6 (50.0)
= 10%	236	109 (27.2)	38 (49.4)	83 (45.1)	6 (50.0)

*1 p<0.05 between GPD vs adenomatous type

†2 p<0.05 between GPD vs adenomatous type

771 Expression of HMGA2, p16, and p53 in Gallbladder Lesions

H Lehrke, T-T Wu, J Sarah, T Mounajjed. Mayo Clinic, Rochester, MN.

Background: Expression of high-mobility group AT-hook 2 (HMGA2), an architectural nuclear factor associated with tumor invasiveness, histologic grade, and metastasis in certain carcinomas, has not been studied in detail in gallbladder lesions.

Design: Immunohistochemical expression of HMGA2, p53, and p16 was evaluated for extent and intensity of staining (extent: <5% negative, 5-50% focal positive, >50% diffuse positive; intensity score: 0 to 3) in 139 cholecystectomies (38 dysplasia and 101 carcinoma). Pathologic and clinical features of carcinomas were collected. We compared expression of HMGA2 in malignant, dysplastic, and background gallbladder mucosa and correlated it to p16 and p53 expression. HMGA2, p16, and p53 expression was correlated with tumor grade, stage, and patient survival in carcinomas.

Results: Most dysplastic lesions expressed p53 (76%) and a minority expressed HMGA2 and p16 (18% and 12%, respectively). Expression of p53 (extent) was significantly higher in high grade (69%) compared to low grade dysplasia (44%) (p=0.04); no such difference was observed in p16 and HMGA2 expression. HMGA2 showed significantly greater intensity (84% 1) and extent (60% positive) of expression in carcinoma compared

to dysplasia (63% 1, 18% positive) and background mucosa (39% 1, 18% positive) (p=0.01 and p<0.001, respectively) but did not show significant correlation with p53 or p16 expression in carcinomas (63% and 36% positive, respectively). HMGA2 (extent and intensity) expression showed significant correlation with poor differentiation (81%, 71%, and 44% of poorly, moderately, and well differentiated carcinomas were HMGA2 positive, respectively; p=0.02). Lack of p16 expression significantly correlated with higher pathologic T stage (p=0.02), but HMGA2 showed no significant correlation with T stage (p=0.2). No marker correlated with N stage. Five year survival rate was lower in HMGA2 positive and in p53 positive tumors (17% and 21%, respectively) compared to HMGA2 negative tumors and p53 negative tumors (29% each), but these differences were not significant. In contrast, p16 positive tumors had a significantly higher 5 year survival rate (34%) compared to p16 negative tumors (15%) (p=0.03).

Conclusions: HMGA2 expression is common in gallbladder carcinoma and is significantly higher than its expression in dysplasia and background mucosa. HMGA2 expression is significantly associated with higher histologic grade in carcinoma but shows no significant correlation with p16 and p53 expression, pathologic stage, or patient survival. In contrast, p16 negativity is a poor prognostic factor, significantly correlated with poor survival and higher T stage.

772 The Impact of the Regional and Systemic Immune Response on Lymph Node Yields and Survival in Stage II Colorectal Cancer

HH Li Chang, N Assarzadegan, DE Messenger, A Grin, S Hafezi-Bakhtiari, CJ Howlett, CJ Streutker, H El-Zimaity, R Kirsch. University of British Columbia, Vancouver, BC, Canada; University of Toronto, Toronto, ON, Canada; Gloucestershire Royal Hospitals NHS Foundation Trust, Gloucester, United Kingdom; Western University, London, ON, Canada.

Background: An inadequate lymph node yield (LNY) is an adverse prognostic feature in colorectal cancer (CRC). Most guidelines recommend that a minimum of 12 nodes be harvested from each resection specimen. Recent studies have focused on the quality of surgery and pathologic assessment as potential causes of inadequate LNYS, but there are few data addressing the effect of the anti-tumor immune response. Therefore, this study aimed to determine the relationship between the local and peri-tumoral lymphocytic response, regional lymph node immune status and peripheral blood lymphocyte counts (PBLCs) on LNY in stage II CRC.

Design: Resection specimens from 185 patients with stage II CRC were assessed for Crohn's-like inflammatory infiltrates, tumor infiltrating lymphocytes (TILs), LNY, lymph node diameter and germinal centre hyperplasia. A LNY of <12 nodes was defined as inadequate. Patients receiving neoadjuvant treatment were excluded. Pre-operative PBLCs were recorded, in addition to other clinicopathologic variables. Multivariate regression analyses were used to determine factors associated with inadequate LNY and survival.

Results: An inadequate LNY was identified in 39 of 185 cases (21.1%). On multivariate analysis, inadequate LNY was independently associated with age >75 years (Odds Ratio, 3.12 [95% confidence interval, 1.36-7.15; P=0.007], surgery before 2000 (OR, 5.69 [95%CI, 1.87-17.3]; P=0.002), left-sided location (OR, 2.40 [95%CI, 1.01-5.71]; P=0.049) and a smaller mean lymph node diameter (OR, 1.55 per mm [95% CI, 1.01-2.39]; P=0.046). Lower PBLCs correlated with an inadequate LNY on univariate analysis (1.38 vs. 1.64 x 10⁹ cells/L, P = 0.019), but not on multivariate analysis (OR, 1.81 [95%CI, 0.85-3.83]; P=0.122). There was no association between inadequate LNY and germinal centre hyperplasia, Crohn's-like inflammatory infiltrate or the presence of TILs. Age (Hazard Ratio, 1.03 per year [95% CI, 1.01-1.05]; P=0.015) and the PBLC (HR, 0.52 per 1x10⁹ cells/L [95% CI, 0.31-0.86]; P=0.011) were independently predictive of disease-free survival on multivariable analysis.

Conclusions: In addition to age, year of surgery and tumor location, LNYS in stage II CRC may be influenced by lymph node size and systemic lymphocyte counts. In the modern era, the adverse prognosis associated with inadequate LNYS may reflect diminished anti-tumor immunosurveillance, rather than inadequate surgery or pathologic staging.

773 Tumor Budding in Colorectal Cancer Is Associated with a Decreased Local Tumor and Regional Lymph Node Immune Response

HH Li-Chang, N Assarzadegan, DE Messenger, A Grin, S Hafezi-Bakhtiari, CJ Howlett, H El-Zimaity, R Kirsch. University of British Columbia, Vancouver, BC, Canada; University of Toronto, Toronto, ON, Canada; Gloucestershire Royal Hospitals NHS Foundation Trust, Gloucester, United Kingdom; Western University, London, ON, Canada.

Background: High-grade tumor budding (HGTB) is an independent prognostic feature in colorectal carcinoma (CRC). The local lymphocytic response is known to be inversely correlated with tumor budding, but less is known about the impact of the lymphocytic response outside the local tumor environment. This study aimed to determine the relationship between HGTB and reactive features in regional lymph nodes, local tumor/peri-tumor lymphocytic responses, peripheral blood lymphocyte counts (PBLCs) and survival in stage II CRC.

Design: Resection specimens from 185 patients with stage II CRC were assessed for presence or absence of high-grade tumor budding (≥10 buds/20x field), Crohn's-like inflammatory infiltrate, marked tumor-infiltrating lymphocytes (TILs; ≥3/40x field), lymph node yield, lymph node size and reactive changes in individual lymph nodes. A semi-quantitative reactivity [R] score of 1-4 was assigned to each node based on the presence and size of germinal centers. The most frequent R score was recorded for each case, in addition to the proportion of non-reactive nodes (R score 1) and the proportion of highly reactive nodes (R score 4). These features were correlated with PBLCs and outcome.

Results: HGTB was present in 34 of 185 cases (18.4%) and was associated with the absence of marked TILs (P = 0.005), the absence of Crohn's-like reaction (P = 0.032),

a higher proportion of non-reactive lymph nodes (20.5% vs. 10.1%, $P = 0.004$) and a lower proportion of highly-reactive nodes (5.8% vs. 15.3%, $P = 0.001$). There were no statistically significant associations between HGTV and age, T-category, tumor location, lymph node size, lymph node yield, PBLs and neutrophil to lymphocyte ratios. HGTV was associated with decreased disease-free survival on univariate analysis (Hazard Ratio, 2.10 [95% confidence interval, 1.19-3.70]; $P = 0.010$) and narrowly failed to reach significance on multivariable analysis (HR, 1.72 [95% CI, 0.95-3.11]; $P = 0.074$). **Conclusions:** HGTV was inversely correlated with the degree of reactivity in regional lymph nodes, the local tumor lymphocytic response and survival. However, HGTV was not associated with peripheral lymphocyte counts. These findings suggest that there may be a biologic relationship between the development of tumor budding and those factors regulating local and regional anti-tumor immune pathways.

774 Targeted Deep Sequencing Reveals Both Mutational Differences and Similarities between Gastric Cardia and Non-Cardia Adenocarcinomas

HH Li-Chang, DF Schaeffer, Y Ng, A Lum, E Kong, S Kaloger, H Lim, DG Huntsman, S Yip. BC Cancer Agency, Vancouver, BC, Canada; University of British Columbia, Vancouver, BC, Canada; Vancouver General Hospital, Vancouver, BC, Canada.

Background: Despite their anatomical proximity, cardia adenocarcinomas (CAs) differ from adenocarcinomas that arise elsewhere in the stomach (NCAs) with respect to epidemiology, etiology and outcome. Data are lacking comparing mutational frequencies in cancer-related genes between the two sites.

Design: DNA from 93 CA and 78 NCA resection specimens was extracted from formalin-fixed paraffin-embedded tissue. Targeted deep sequencing of 46 cancer-related genes was performed through emulsion PCR followed by semiconductor-based sequencing on the Ion Torrent PGM platform (Life Technologies); minimum cutoffs of 500x coverage and variant allele frequencies of 5% were used to call variants across 739 mutational hot-spots. Mutational profiles were compared with immunohistochemistry and *in situ* hybridization performed on tissue microarrays, as well as corresponding clinicopathologic baseline and follow-up data.

Results: Among all cases, 269 mutations were detected in 32 genes. *TP53* mutations were found in 61 cases (36%), and were more common in CAs than NCAs (43% vs. 27%, $p = 0.027$). *p53* overexpression was also more common in CAs than NCAs (47% vs. 19%, $p < 0.001$), whereas absence of *p53* expression was less frequent amongst CAs (34% vs. 63%, $P < 0.001$). The next most frequently mutated genes were *KIT* (16%), *MET* (6%), *PIK3CA* (6%), *KRAS* (5%), and *CTTNB1* (5%); no significant differences in the frequencies of these mutations were found between the two sites. Two cases of NCAs contained pathogenic mutations in *IDH1*. On multivariable analysis, cardiac location was associated with significantly worse disease-free survival independent of TNM stage, margin status, Her2 amplification, Lauren classification and tumor grade (HR 1.81 [95% CI 1.11-2.94]; $p = 0.018$). Subgroup analysis of only intestinal-type carcinomas showed persistent differences between CAs and NCAs in *TP53* mutation rates ($p = 0.012$), *p53* expression ($p = 0.004$) and disease-free survival ($p = 0.036$).

Conclusions: Differing rates of *TP53* mutations, patterns of *p53* expression, and outcome data support a pathobiologic distinction between adenocarcinomas that arise in the cardia and those that arise elsewhere in the stomach. Other cancer-related genes are mutated at lower rates, which are not significantly different between the two sites.

775 New microRNA Markers Improves Classification of Indeterminate Inflammatory Bowel Disease

J Lin, J Zhang, N Welker, Z Zhao, Y Li, M Bronner. Indiana University School of Medicine, Indianapolis, IN; University of Utah and ARUP Laboratories, Salt Lake City, UT.

Background: Most inflammatory bowel disease can be specifically classified as either ulcerative colitis or Crohns disease, but 5–10% of patients have equivocal features placing them into the indeterminate colitis category. In our previous study, 5 microRNA biomarkers have been suggested to assist in the classification of indeterminate inflammatory bowel disease. This study examines whether additional miRNA markers can increase the diagnostic accuracy.

Design: Fresh frozen colonic mucosa from the distal-most part of the colectomy from 53 patients was used (16 indeterminate colitis, 14 Crohns disease, 12 ulcerative colitis, and 11 diverticular disease controls). Total RNA extraction and qRT-PCR amplification was performed. Analysis of variance was performed assessing differences among the groups.

Results: A significant difference in expressions of miR-19b, 23b, 106a, 191, 629, 147b, 194-2, 383, 615, and 1826 was detected between ulcerative colitis and Crohns disease groups ($P < 0.05$). Among the 16 indeterminate colitis patients, 11 showed ulcerative colitis-like pattern, one with Crohns disease-like pattern, and 4 equivocal.

Conclusions: Ten microRNA analyses systems further provide molecular evidence that most indeterminate colitis is probably ulcerative colitis. MicroRNA study is promised to improve classification of indeterminate inflammatory bowel disease.

776 Novel microRNA Signatures to Differentiate Ulcerative Colitis from Crohns Disease: A Genome-Wide Study Using Next Generation Sequencing

J Lin, NC Welker, Z Zhao, Y Li, J Zhang, MP Bronner. Indiana University School of Medicine, Indianapolis, IN; University of Utah and ARUP Laboratories, Salt Lake City, UT.

Background: The diagnosis of ulcerative colitis (UC) or Crohns disease (CD) can be challenging given the overlapping clinical, endoscopic, and pathological features. MicroRNAs (miRNAs) are small, noncoding RNAs that regulate protein synthesis through post-transcriptional suppression. This study was aimed to identify novel miRNA biomarkers to distinguish UC from CD by using genome-wide RNA sequencing techniques.

Design: Illumina small RNA sequencing was performed on nondysplastic fresh-frozen colonic mucosa samples of the distal-most colectomy tissue from 19 patients with inflammatory bowel disease (10 UC and 9 CD), and 18 patients with diverticular disease serving as controls.

Results: To determine differentially expressed miRNAs, the USeq software package identified 44 miRNAs with altered expression (fold change ≥ 2 and false discovery rate ≤ 0.10) compared to the controls. Among them, a panel of 11 miRNAs was aberrantly expressed between both UC and CD. Validation assays performed using qRT-PCR on additional frozen tissue from UC (n=20), CD (n=10), and control (n=18) groups confirmed specific differential expression of miR-147b, miR-194-2, miR-383, miR-615, and miR-1826 between UC and CD ($P < 0.05$).

Conclusions: In summary, we demonstrate that miR-147b, miR-194-2, miR-383, miR-615, and miR-1826 are differentially expressed between UC and CD, which are potential biomarkers to distinguish the diseases.

777 Exploring Mutational Profiles in Two Major Histologic Subtypes of Ampullary Carcinoma by Targeted Cancer Gene Sequencing

W Liu, J Shia, H Won, M Berger, D Klimstra. Memorial Sloan-Kettering Cancer Center, New York, NY; State University of New York, Buffalo, NY.

Background: Recent clinical studies suggest that typical intestinal type ampullary carcinomas (IN-AC) may have a better outcome than pancreatobiliary type ampullary carcinomas (PB-AC) and the two types of tumors may respond to chemotherapy differently. Comparative mutational profiling may help unravel different molecular mechanisms underlying the IN versus PB type ampullary carcinomas and identify genetic alterations that can serve as prognosticators or predictors for treatment response.

Design: After histological review and confirmation by immunohistochemical stains, fourteen IN-AC cases and eighteen PB-AC were selected. DNA from paraffin embedded tissue of paired tumor and normal samples was analyzed using targeted, deep sequencing assay to identify point mutations, indels, and copy number alterations in 275 cancer-associated genes.

Results: Mutations were identified in all ampullary carcinoma cases. The number of mutations in each tumor in IN-ACs ranged from 1 to 225 with a median of 6 while in PB-ACs they ranged from 1 to 16 with a median of 4. The top mutated, amplified and deleted genes in the two major histologic subtypes of ampullary carcinoma are summarized in Table 1. There is no statistic significant difference on the genomic alterations between IN-AC and PB-AC.

Table 1. Top genomic alterations in two major histologic subtypes of ampullary carcinoma

Gene	Top Mutated Genes									
	<i>P53</i>	<i>KRAS</i>	<i>APC</i>	<i>SMAD4</i>	<i>ERBB2</i>	<i>ARID2</i>	<i>CTNNB1</i>	<i>EPHA7</i>	<i>TGFB2</i>	
IN-AC	57%	29%	43%	36%	21%	21%	14%	7%	7%	
PB-AC	50%	56%	17%	11%	17%	11%	11%	17%	17%	
P value	0.73	0.16	0.13	0.19	1	0.63	1	0.61	0.61	
Gene	Top Amplified Genes					Top Deleted Genes				
	<i>ERBB2</i>	<i>CDK12</i>	<i>CCND1</i>	<i>MDM2</i>	<i>CDKN2A</i>	<i>JUN</i>	<i>SRSF2</i>	<i>CDKN2B</i>	<i>SMAD4</i>	
IN-AC	14%	14%	0%	0%	36%	0%	0%	21%	14%	
PB-AC	17%	6%	11%	11%	6%	28%	22%	6%	6%	
P value	1	0.57	0.49	0.49	0.06	0.05	0.11	0.3	0.57	

Conclusions: Our study illustrates the mutational patterns of commonly implicated cancer-associated genes in ampullary carcinomas. We found significant overlapping of genomic alterations between IN-ACs and PB-ACs. *ERBB2* amplification was found in both IN-ACs and PB-ACs with a frequency of up to 17%, providing a foundation for further evaluation of its use as a target for anti-HER2 therapy.

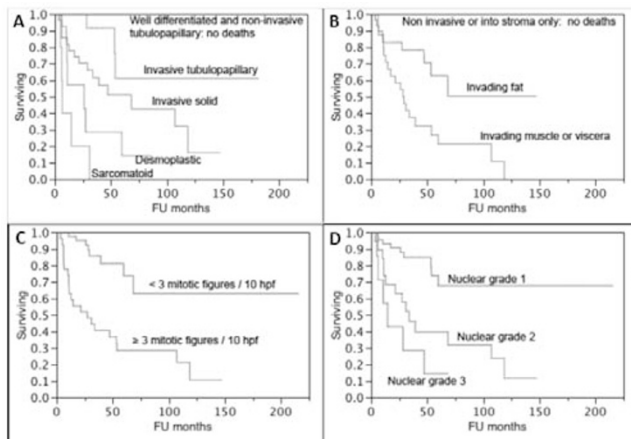
778 Pathologic Factors Impacting Survival in Diffuse Malignant Peritoneal Mesotheliomas

SZ Liu, JA Collins, MP Lee, AP Burke, HR Alexander. University of Maryland, Baltimore, MD.

Background: There are few studies correlating pathologic factors with overall survival with diffuse peritoneal mesotheliomas (DPM).

Design: A cohort of 75 patients with DPM treated with hyperthermic intraperitoneal chemotherapy (HIPEC) were followed for a mean of 44 months (range 13 – 215). Time to recurrence and time to death were correlated with peritoneal cancer index and completeness of resection, and histologic type, depth of invasion, mitotic rate, and nuclear atypia.

Results: There were 2 well-differentiated papillary mesotheliomas, 4 multicystic mesotheliomas, 8 non-invasive epithelioid mesotheliomas, 20 invasive epithelioid mesotheliomas with tubular differentiation, 27 mesotheliomas with solid growth, 7 desmoplastic mesotheliomas, and 5 sarcomatoid mesotheliomas. There was a stepwise decrease in survival with the last four (invasive) categories (Figure 1), $p < .0001$.



There was no correlation between survival and extent of disease. Survival was inversely correlated with depth of invasion, mitotic count, and nuclear atypia. By multivariate analysis, only depth of invasion was statistically significant ($p=0.01$). There was no correlation between pathologic parameters and time to recurrence, including non-invasive tumors.

Conclusions: Non-invasive epithelioid mesothelioma has a similar prognosis as well differentiated types; however non-invasive tumors are prone to recurrence. Poorly differentiated tumors include solid, desmoplastic, and sarcomatoid types. Depth of invasion is the most important prognostic feature.

779 Paneth Cell Phenotype Correlates with Genetics, Transcriptome Profile, Pathologic Hallmark and Predicts Clinical Outcome in Crohn Disease Patients

T-C Liu, K vanDussen, F Gao, D Li, F Towfic, N Modiano, R Winter, D Dhall, S Targan, R Xavier, D McGovern, T Stappenbeck. Washington University, St. Louis, MO; Cedars-Sinai Medical Center, Los Angeles, CA; Massachusetts General Hospital, Boston, MA.

Background: The identification of Crohn Disease (CD) genetic susceptibility loci represents an opportunity to define CD subtypes leading to personalized therapy. A challenge is the multiple susceptibility loci that likely interact with undefined environmental factors. Paneth cells (PCs), an integral innate immunity contributor, are pivotal in CD pathogenesis. We demonstrated that the PC granule morphology is a readout for host genetics and environmental triggers. We hypothesized that PC phenotype (PCP) are an integrative readout to define CD subtypes.

Design: We analyzed 178 genotyped CD patients with ileal resections. Uninvolved ileal sections were analyzed for transcriptional profiles by microarray and PCP by lysozyme immunofluorescence. The morphology of each PC was categorized. The patients' PCP were determined by the sum of PCs with abnormal lysozyme distribution, with bad PCP defined as $\geq 20\%$ abnormal PCs, and $< 20\%$ defined as good PCP. PCPs were then correlated with genotype, pathologic features, transcriptional profiles, and time to recurrence after surgery. We also performed an analysis of 'virtual' biopsies to ascertain whether PCP could also be determined with biopsy samples.

Results: Of the 178 CD patients, 27 (15%) had bad PCP. Patients with one or more CD-associated *NOD2* susceptibility alleles had increased proportions of abnormal PCs compared to those without *NOD2* susceptibility alleles. There is also an additive effect of *NOD2* susceptibility alleles and *ATG16L1 T300A* on PCP ($p=0.0092$). Cases with bad PCP were more likely to be granuloma-poor ($p=0.0160$) and associated with an altered transcriptional signature most strongly associated with immune activation pathways. Clinically, among the 121 patients who received adjuvant therapy with biologics/immunomodulators, those with bad PCP showed shorter time to disease recurrence compared to those with good PCP (median 10 and 14 months respectively; $p=0.0198$). In the same patients, the PCP in involved area was consistent with that in the uninvolved area ($p=0.0001$). Finally, bioequivalence analysis showed that a minimum of 40 crypts from biopsies were sufficient for PCP analysis.

Conclusions: PCP is associated with genetics, pathologic hallmark, and predicts clinical outcome. It can be used as a robust readout that subdivides CD patients into clinically relevant groups. Defining the minimum crypt number required for PCP analysis enables the use of biopsy material for future studies.

780 IL-23 and IL-24 Upregulate Pro-Inflammatory Chemokine Genes in Colonic Epithelial Cells

R Lourie, SZ Hasnain, MA McGuckin, TH Florin. Mater Medical Research Institute, Translational Research Institute, Woolloongabba, Queensland, Australia.

Background: IL-23 and IL-24 are strongly expressed in inflamed colonic mucosa in both ulcerative colitis and Crohn's Disease. Most studies of these cytokines have concentrated on immune cell interaction, particularly the key role of IL-23 in generation of the Th17 response characteristic of active inflammatory bowel disease (IBD). Epithelial cells can be dynamic partners in the initiation and perpetuation of inflammatory responses. We investigated whether IL-23 and IL-24 could act directly upon epithelial cells to potentially amplify the localized mucosal inflammatory response in IBD.

Design: Normal colonic crypts were extracted from resection specimens of patients without a history of colitis, and exposed to IL-23 and IL-24 in both short term and long term colonic crypt culture models. qRT-PCR for expression of genes encoding the pro-inflammatory chemokines IL1 β , CXCL10, IL33 and IL8, and Th17 differentiation transcription factor RAR-related orphan receptor gamma (ROR γ) was performed.

Results: Both IL23 and IL24 upregulated genes encoding the pro-inflammatory chemokines IL1 β , CXCL10, IL33 and IL8 in both short and long term models of colonic crypt culture. In short term cultures, upregulation of chemokine expression occurred regardless of ROR γ upregulation.

Conclusions: IL-23 and IL-24 act directly on normal ex-vivo colonic epithelial cells leading to upregulation of genes encoding pro-inflammatory cytokines. Upregulation in longer term pure epithelial cell cultures, and lack of dependence on ROR γ upregulation in a short term culture model is consistent with a direct effect on epithelial cells, rather than mediation via a lymphocyte dependent Th17 pathway. Perpetuation of a localized chemokine rich inflammatory response by epithelial cells activated by IL23 and IL24 will lead to continued neutrophil recruitment with subsequent loss of epithelial integrity and barrier function, and tissue damage. We provide the first evidence of direct cytokine driven epithelial cell changes which may have important implications for mucosal healing in IBD patients, and targeted therapy against IL-23 and IL-24 in IBD.

781 The Utility of 15-s-HETE as a Noninvasive Serological Marker for Eosinophilic Esophagitis

S Lu, M Herzlinger, L Noble, D Yang, A Matoso, W Cao, M Resnick. Alpert Medical School of Brown University, Providence, RI.

Background: Eosinophilic esophagitis (EoE) is a TH2-mediated allergic disorder involving the esophageal mucosa. Diagnosis and follow-up of EoE requires esophagogastroduodenoscopy (EGD) and histological examination. Noninvasive biomarkers with good sensitivity and specificity have yet to be identified. Arachidonate 15-lipoxygenase (ALOX15) has been recently identified as a reliable histological marker of EoE, based on gene expression studies, and confirmed by immunohistochemistry. The current study examined the utility of 15-s-HETE, a metabolite converted from arachidonic acid by ALOX15, as well as three cytokines involved in the TH2 pathway as noninvasive serological markers for EoE.

Design: The sera of sequential pediatric patients (1-18 years old) with known or suspected EoE undergoing EGD were tested by ELISA for 15-s-HETE and interleukins involved in the TH2 pathway (IL-13, IL-5, IL-4). Peripheral absolute eosinophilic count (AEC) was measured. Diagnosis of EoE was based on intra-epithelial esophageal eosinophils greater than 15 per high power field and correlation with the clinical and endoscopic findings. Fifteen EoE and 6 non-EoE patient sera were tested. The cut-off values for 15-s-HETE, IL-13, IL-5 and IL-4 to be considered as elevated are 7500 pg/mL, 350 pg/mL, 35 pg/mL, and 500 pg/mL, respectively. Chi-square and Spearman correlation were used for statistical analysis.

Results: Six of 15 EoE patients had elevated 15-s-HETE, while all non-EoE patients had normal 15-s-HETE levels ($P=0.026$). Five of 15 EoE patients had elevated IL-13, while all non-EoE patients had normal IL-13 levels ($P=0.0467$). Six out of 14 EoE patients had evidence of peripheral eosinophilia (AEC $\geq 500/\mu\text{L}$), while all non-EoE patients had normal AEC ($P=0.0212$). Four EoE patients had abnormally high IL-5 and IL-4 levels while all non-EoE patients had normal IL-5 and IL-4 levels ($P=0.08$ for both). The sensitivity of 15-s-HETE for the diagnosis of EoE was 40% and the specificity 100%. 15-s-HETE levels also exhibited significant correlation with levels of AEC, IL-13, and IL-5 ($R^2=0.52$; $P=0.0004$, $R^2=0.300$; $P=0.0137$, $R^2=0.352$; $P=0.0046$, respectively).

Conclusions: This is the first study to test the utility of 15-s-HETE as a noninvasive marker to identify EoE. In this study, elevated serological 15-s-HETE was significantly associated with EoE with moderate sensitivity and excellent specificity. We are currently extending this study to add more patients and sequential serum samples.

782 Small Intestinal Intermediate Cells: Spectrum of Associated Diseases and Clinical Implications

C Ma, EA Montgomery, TS Stappenbeck, T-C Liu. Johns Hopkins University, Baltimore, MD; Washington University, St. Louis, MO.

Background: Intermediate cells are small intestinal cells with morphologic features and immunohistochemical characteristics of both goblet cells and Paneth cells. Under routine H&E stain they have the contour of goblet cells, contain cytoplasmic mucin, but also possess antimicrobial granules. While intermediate cells have been observed in mouse models of infectious enteritis, their clinical relevance in humans has not been well characterized. We aim to delineate the spectrum of clinical entities where intermediate cells can be detected.

Design: H&E sections from 245 biopsy material of duodenum and terminal ileum from a variety of clinical indications and diagnoses were reviewed. To avoid misinterpretation of suboptimally oriented tissue fragments, only intermediate cells residing within the small intestinal villi were documented. Lysozyme, defensin 5, and MUC-2 immunofluorescence localization confirmed the presence of intermediate cells in selected cases.

Results: On H&E-stained sections, intermediate cells were most prevalent in cases of ulcerative colitis-associated pouchitis (9/30; 30%) and Crohn Disease (12/48; 25%). There was no significant difference between areas of active and inactive Crohn Disease (8/33; 24% and 4/15; 26%, respectively). Intermediate cells were less common in histologically normal terminal ileum of Crohn Disease (3/22; 14%) or ulcerative colitis (2/21; 10%), as well as backwash ileitis (2/20; 10%). Intermediate cells were also detected in multiple infectious entities including Whipple Disease (2/11; 18%), Mycobacterium Avium-Intracellulare complex enteritis (1/13; 8%), and Cryptosporidiosis (2/4; 50%). Intermediate cells were rarely detected or absent in histologically unremarkable duodenum (2/48; 4%) and terminal ileum (0/17) not associated with inflammatory bowel disease or infection. Also cases of Celiac disease (0/34) and graft versus host disease (0/29) did not contain intermediate cells.

Conclusions: Intermediate cells are relatively common in many forms of inflammatory bowel disease and less commonly seen in selected infectious enteritis entities. They do not appear to be a non-specific response to inflammatory conditions and thus may be associated with underlying etiopathogenesis of inflammatory bowel disease.

783 Upper Tract Juvenile Polyps in Juvenile Polyposis Patients: Dysplasia and Malignancy Are Often Associated with Intestinal and Pyloric Differentiation

C Ma, FM Giardiello, EA Montgomery. Johns Hopkins University, Baltimore, MD.

Background: Juvenile polyposis syndrome (JPS) is a hereditary autosomal dominant disorder characterized by multiple juvenile polyps (JP) throughout the gastrointestinal (GI) tract, with a predilection to colorectum. Affected patients are at increased risk of colorectal adenocarcinoma. The upper GI tract is less often involved by JPS than the colorectum and consequently upper tract JPs are not well studied.

Design: Patients with JPS were identified at a single institution over a 25-year period. Upper endoscopies and corresponding upper GI biopsy specimens from these patients were reviewed. Biopsy specimens with polyps or mass lesions were further studied to characterize the epithelium and the presence of dysplasia.

Results: Upper GI tract biopsies (135) from 78 endoscopies on 21 (51%) of 41 JPS patients (17 male, 24 female) ranging in age from 4-56 (median, 20) were studied. Only 1 of the remaining 20 patients had an upper endoscopy without biopsy. Fourteen of the 21 patients (67%) had one or more upper tract JP. All 14 patients had gastric JP, most commonly in the cardia/fundus (10/14), followed by body (5/14) and antrum (5/14). Six of the 14 patients also had small intestinal JP; 5 were duodenal and 1 was jejunal. JP were identified in the stomach in a 7 year old patient with a *SMAD4* mutation. Two patients (9.5%) had high-grade dysplasia (HGD) in their gastric JP; adenocarcinoma was seen in the subsequent gastroscopy specimen of one patient. Histologically, all 46 gastric polyps identified had gastric foveolar epithelium. Twelve polyps (26%) had intestinal differentiation and 6 (13%) also had co-existing pyloric gland differentiation. Eight of the 12 polyps (17%) had low and/or high grade dysplasia arising from all three types of epithelium. This included 5 of the 7 gastric polyps from the patient with adenocarcinoma and 3 of the 9 gastric polyps from the patient with HGD. Pyloric gland differentiation was only seen in polyps with dysplasia. The flat gastric mucosa was normal or had chronic inflammation but no intestinal metaplasia. Five of the 6 small bowel JP had small intestinal epithelium with focal or extensive gastric mucin cell metaplasia.

Conclusions: Juvenile polyposis can involve the upper GI tract more frequently than reported in literature and patients may have increased risk of gastric adenocarcinoma. Dysplasia and malignancy arising in gastric juvenile polyps in JPS patients are more often associated with intestinal and pyloric gland differentiation in the polyps themselves but not metaplasia in surrounding gastric mucosa.

784 HER-2 Expression and Gene Amplification in Colorectal Liver Metastases; a Potential Target for Trastuzumab

A Mahmoud, D Power, S Carey, TJ Browne, F O'Connell, MW Bennett. University College Cork, Cork, Ireland; Cork University Hospital, Cork, Ireland; Mercy University Hospital (MUH).

Background: Colorectal liver metastases (CRLM) are associated with poor prognosis that limits the overall survival rate of patients with colorectal cancer. The epidermal growth factor (EGF) pathway is a therapeutic target, since it is implicated in the progression of CRLM. Cituximab, a monoclonal antibody directed against epidermal growth factor receptor (c-ErbB-1), is routinely used in the treatment of CRLM. Response to cituximab depends on the presence of wild-type KRAS; however, resistance occurs in up to 40% of patients. Therefore there is a need to investigate other downstream molecules of the EGF pathway that could be implicated in resistance to cituximab. HER-2 is another significant receptor for EGF. Recent studies suggest that HER-2 expression in CRLM is associated with resistance to cituximab. The aim is to evaluate the prevalence of HER-2 protein overexpression and gene amplification in CRLM.

Design: 46 formalin fixed paraffin embedded blocks of CRLM were retrieved from the archives of Cork University Hospital. Clinical data including age, type and dose of chemotherapy were recorded. Tumour response to chemotherapy was scored using Mandat tumour regression grade (TRG). HER-2 immunohistochemistry (IHC) was performed using clone 4B5 (Ventana, USA). Results were evaluated using the HER-2 interpretation method for gastric cancers, as described by Hoffmann et al. in the validated ToGA study. Equivocal cases (score 2+) were evaluated for HER-2 gene amplification by dual colour in-situ hybridization (D-DISH). Results were correlated with clinical history.

Results: HER-2 is expressed in 2/45 cases of CRLM (4.4%). Results were split into 3 groups: positive, equivocal, and negative. The positive group included 2 cases with equivocal IHC score showing basolateral membranous staining for HER-2 on IHC in 10-20% of tumour cells, but on D-DISH HER-2 gene was amplified with HER-2/CEN-17 signalling ratio of 4.2 and 3.1, and HER-2 copy number of 4 and 3. These 2 cases showed minimal tumour regression (TRG 4) with a non-brisk lymphocytic response and central tumour necrosis. The equivocal group comprised of 4 cases with IHC score of 2+, but were not amplified on D-DISH. The negative group included 39 cases (10: IHC score 1+; 29: IHC score 0).

Conclusions: HER-2 is expressed in 4.4% of CRLM. HER-2 expression in CRLM parallels results in primary colorectal cancer (3.6-27% on IHC; 2.4-14.2% on in-situ hybridization). Although expression is low, therapeutic implication is significant, as there is a potential role for Trastuzumab in these patients.

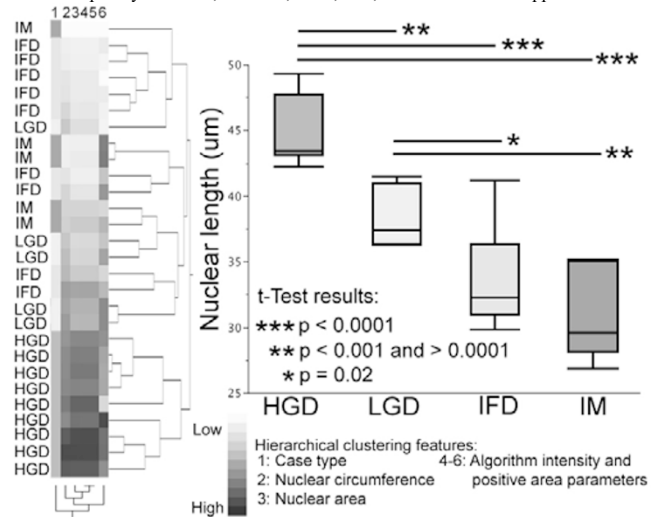
785 Barrett Esophagus Dysplasia Characterization through Digital Image Analysis

DR Martin, DR Braxton, AB Farris. Emory University, Atlanta, GA.

Background: Grading dysplasia in Barrett esophagus (BE) often proves difficult and sometimes necessitates a diagnosis of indefinite for dysplasia. These indefinite lesions require additional endoscopic biopsy procedures to further clarify the disease. We investigated the utility of quantitative digital image analysis in grading BE dysplasia, particularly in the context of indefinite lesions.

Design: Archived cases from 2003 to 2013 were digitally scanned using a whole slide scanner, and representative nuclei were circumscribed for analysis. Diagnoses were verified by two expert GI pathologists. Features analyzed include nuclear circumference (NC; μm), nuclear area (NA; μm^2), and 13 optical measurement parameters assessed by a positive pixel count (PPC) algorithm. Student's t-test was performed with an alpha set at 0.05.

Results: BE cases were grouped as high-grade dysplasia (HGD; n=9), low-grade dysplasia (LGD; n=5), indefinite for dysplasia (IFD; n=9), and intestinal metaplasia negative for dysplasia (IM; n=5). Average NC and NA increased progressively from IM, IFD, LGD, to HGD (Figure). This was found to be statistically significant across groups except for IM versus IFD, which was significant for NC but not for NA. Using the PPC to measure chromatin characteristics, there were significant differences across groups for total number of pixels, except for IM versus IFD. The PPC was able to distinguish diagnostic groups for the percent of pixels that were strongly positive, average positive pixel intensity, and total intensity of negative and positive pixels. When hierarchical clustering was performed using selected parameters that discriminated groups, HGD cases completely clustered; however, LGD, IFD, and IM cases overlapped.



Conclusions: Quantitative digital image analysis can be an effective adjunct for grading dysplasia in BE. Area, circumference, and parameters assessed with the PPC algorithm distinguished most diagnostic group comparisons. HGD cases clustered as expected. The majority of indefinite lesions were similar to IM, while a minority clustered with LGD. With validation on larger cohorts and with follow-up data, this technique may provide an objective means to more accurately risk stratify indefinite lesions without the need for additional endoscopic biopsy procedures.

786 The Diagnostic Utility of ALOX15 Immunohistochemistry in Pediatric Patients with Eosinophilic Inflammation of the Esophagus

A Matoso, D Allen, M Herzlinger, J Ferreira, S Chen, S Mangray, MB Resnick. Rhode Island Hospital/Brown University, Providence, RI.

Background: The diagnosis of eosinophilic esophagitis (EoE) is often complicated by clinical and histological overlap with reflux disease (GERD). We previously identified overexpression of arachidonate 15-lipoxygenase (ALOX15) in the esophageal mucosa in 95% of patients with a definitive diagnosis of EoE. We now aim to determine the utility of ALOX15 immunohistochemistry (IHC) in diagnostically challenging cases.

Design: Esophageal biopsies from pediatric patients with >15 eosinophils per high power field (eos/HPF) were identified from 2009 to 2012 (N=62). Patients were categorized into 3 groups: 1) >15eos/HPF in the distal esophagus only (N=24), 2) >15eos/HPF in the proximal esophagus only (N=5) and 3) >15eos/HPF in both distal and proximal biopsies. Control groups included patients with a definitive diagnosis of EoE (N=42), patients with GERD with up to 5eos/HPF (N=15), patients with GERD with 6-15eos/HPF (N=9), candida esophagitis (N=15), and normal controls (N=17). Immunopositivity was scored based on the extent and intensity of ALOX15 staining. Results were correlated with the clinical diagnosis of EoE or GERD. The diagnosis was performed by the gastroenterologist considering presenting symptoms, history of atopy, findings on endoscopy, and response to therapy (i.e. acid suppression-PPI, topical steroid, or elimination diet).

Results: In the control groups, ALOX15 was positive in 40/42 (95%) of patients with a definitive diagnosis of EoE, in 2/9 (22%) of patients with GERD with 6-15eos/HPF, none of the patients with GERD with <6eos/HPF, and none of the patients with candida esophagitis (P<0.001 for all). IHC results in the study groups and its correlation with the clinical classification is summarized in Table 1.

IHC Results in Study Groups

	Total (N=62)	Group 1 (N=24)	Group 2 (N=5)	Group 3 (N=33)
EoE (positive/total)	48/53	13/16	4/4	31/33
GERD (positive/total)	4/9	4/8	0/1	0/0
Sensitivity	90.5%	81.2%	100%	94%
Specificity	55%	50%	100%	N/A
PPV	92%	76.4%	100%	100%
NPV	50%	57.1%	100%	0%

PPV: positive predictive value; NPV: negative predictive value

Conclusions: ALOX15 is a sensitive marker of EoE, however, it is expressed in a subpopulation of GERD patient biopsies who have over 6 eosinophils per HPF. In

patients with discrepant biopsy findings between the proximal and distal esophagus, ALOX15 IHC is most useful as a biomarker of EoE in patients with distal involvement only. Within patients with >15eos/HPF in the proximal esophagus, ALOX15 IHC as a diagnostic marker is not superior to the histological findings alone.

787 Diagnosis of Anal Intraepithelial Neoplasia: Impact of the 2012 LAST Guidelines

K Matsukuma, C Louie, A Carrigg, MA DiMaio, M Fujiwara, C Kunder, G Lewis, T Ng, L Pan, JL Ziskin, G Berry, D Bingham, T Longacre, C Kong. Stanford University, Stanford, CA.

Background: Distinct treatment paradigms are well established for low grade and high grade anal intraepithelial neoplasia (AIN); thus, it is essential for pathologists to accurately categorize these processes. In 2012, the College of American Pathologists and the American Society for Colposcopy and Cervical Pathology published the Lower Anogenital Squamous Terminology (LAST) guidelines aimed at clarifying terminology, heightening awareness of the biologically distinct behavior of low risk and high risk lesions, and providing guidelines for the use of p16.

Design: To determine if these recommendations have had an impact on inter-observer agreement and accuracy of diagnosis of AIN, 7 pathology fellows reviewed a set of 13 anal biopsies selected from our in-house material, once without specific instructions and then six months later with recommendations from the LAST study provided along with the slides. For comparison, 3 GI faculty also reviewed the cases one time, without any specific instructions. Lesions were categorized as: (1) reactive, (2) LSIL, (3) HSIL, or (4) indeterminate/requiring ancillary studies. If "indeterminate" was selected, the reviewer could view a corresponding p16 stain and finalize the diagnosis accordingly. The interpretation of a separate faculty member expert in HPV-related lesions served as the gold standard.

Results: First round fellow review revealed moderate inter-observer agreement ($k=0.558$), and the consensus interpretation (4/7 or greater) agreed with the gold standard in 11 of 13 cases. In 2 cases, there was a discrepancy between the consensus and gold standard, with the difference being between reactive and LSIL for both cases. Second round results were similar: moderate inter-observer agreement ($k=0.498$) and 3 discrepancies, all between reactive and LSIL. Faculty members had substantial inter-observer agreement ($k=0.668$), and their consensus interpretation (2/3 or greater) agreed with the gold standard in 10 cases. In 2 cases, the discrepancy was between reactive and LSIL, and in one case between reactive and HSIL.

Conclusions: In most cases, fellows and faculty correctly diagnosed anal biopsies. Surprisingly, education on the LAST guidelines did not significantly change inter-observer agreement or outcome for fellows, although p16 use increased by 25%. Regardless, the one major discrepancy between an interpretation of reactive and HSIL underscores the value of utilizing p16 in diagnosis of anal biopsies. In particular, tangential sectioning and transition zone morphology confound interpretation of anal biopsies, and thus there should be a low threshold for requesting a p16 stain.

788 Tumor Budding in Post-Neoadjuvant Chemoradiotherapy Colorectal Cancer

AJ McCarthy, AC Rogers, JMP Hyland, R O'Connell, DC Winter, D Gibbons, K Sheahan. Centre for Colorectal Disease, St. Vincent's University Hospital & University College Dublin, Dublin 4, Ireland.

Background: Our group has recently demonstrated that tumor budding is a potential prognostic & predictive biomarker in rectal biopsies prior to neoadjuvant chemoradiotherapy in rectal cancer (Rogers et al., *Modern Pathology*). The aim of this study was to evaluate the presence or absence of tumor budding in post-treatment rectal cancer resections where residual tumor was identified.

Design: H&E tumor slides from post-treatment rectal cancer resections with residual tumor present (tumor regression grade (TRG) 2 or 3) were reviewed and evaluated for presence or absence of tumor budding. The method used for assessment of tumor budding has been previously published (Wang et al., *AJSP*). Numerous other pathological parameters were also evaluated. The post-treatment resection budding results were correlated with the pre-treatment budding results & with pathologic parameters.

Results: Seventy post-treatment rectal resections were reviewed. Significant correlation with tumor budding was seen for poor differentiation ($p<0.001$), presence of lymphatic invasion ($p=0.001$), presence of extramural vascular invasion ($p=0.02$) and presence of infiltrative tumor margin ($p=0.02$), but not for ypTNM or tumor regression grade (TRG 2, TRG 3). Ten of fifteen pre-treatment budding cases had budding on the resection (concordance 66%).

Conclusions: Concordance of tumor budding in post-treatment resections with tumor budding in pre-treatment biopsies is 66%. Post-treatment tumor budding is significantly associated with a number of pathological adverse features, including poor differentiation, presence of lymphatic invasion, presence of extramural vascular invasion and an infiltrative tumor margin, emphasizing that tumor budding is an increasingly important prognostic feature for pathologists to recognize.

789 HIV Positivity Is Associated with Keratinizing Morphology and Higher Recurrence Rate in Anal Cancer

JE Meyer, M Hawver, EC Pirog. Fox Chase Cancer Center, Philadelphia, PA; Weill Medical College of Cornell University, New York, NY.

Background: Few studies have examined prognostic significance of HIV/HPV positivity, p16 expression and histopathologic tumor differentiation in anal cancer. The goal of our study was to evaluate consecutive cases of invasive anal carcinoma for HPV and p16 positivity in correlation with tumor differentiation and HIV status, to determine the prognostic significance of these clinicopathologic parameters.

Design: The study included patients with squamous cell carcinoma of the anus treated with chemoradiation between 1997 and 2009. The histologic slides were reviewed and tumors were subclassified as either non-keratinizing (including basaloid) or keratinizing categories. All cases were immunostained for p16 and tested for HPV testing using SPF10-PCR.

Results: There were 42 patients, including 23 men and 19 women; 43% of men and 11% of women were HIV-positive ($p=0.04$). 64% of tumors were non-keratinizing (=basaloid) and 36% were keratinizing. The keratinizing tumors were more common in HIV-positive patients (67%), whereas non-keratinizing (=basaloid) tumors were more common in HIV-negative patients (77%) ($p=0.008$). All tumors were positive for high oncogenic risk HPV and all were positive with p16 immunostain. 55% of patients had local disease (stage I and II), 41% were stage III and IV, and 4% stage unknown. 31% of patients had recurrence of disease, including 50% HIV-positive patients and 23% HIV-negative patients ($p=0.09$). The 24-month recurrence-free survival for the cohort was 66% (95% CI = 46%, 81%), with HIV-positive patients having worse recurrence-free survival compared to HIV-negative patients (hazard ratio=2.85, 95% CI = 0.95, 8.53; $p=0.06$). There was no difference in the recurrence rate between non-keratinizing and keratinizing tumor subtypes ($p=0.80$).

Conclusions: HIV-positivity was associated with a higher recurrence rate and worse recurrence-free survival in anal cancer. Keratinizing tumors were more common in HIV-positive patients; however, the regional and distant failure rate was not related to histologic tumor differentiation.

790 Frequency and Nature of Increased Intraepithelial Lymphocytes (IEL) in Biopsies from Patients with Achalasia (ACH)

KE Muller, J Putra, S Gabbard, S Parker, AA Suriawinata, RI Rothstein, M Lisovsky. Dartmouth-Hitchcock Medical Center, Lebanon, NH.

Background: The diagnosis of achalasia may be difficult because it can mimic or overlap with reflux esophagitis (RE). Lymphocytic esophagitis is a frequent finding in esophagectomies from patients with ACH, suggesting that this relatively rare histologic pattern could be useful for screening biopsies for ACH. While RE can also have increased IEL (IIEL), of predominantly CD8 T-cell phenotype, little is known about IEL in ACH biopsies. The goal of this study was to characterize IEL in a series of biopsies from patients with ACH.

Design: From 2011-2013, we collected biopsies of patients with overtly elevated IEL: 5 with ACH and 15 with clinico-histologic reflux esophagitis (RE). Additionally, 186 patients with ACH were identified in the files of our institution from 2003-2012. Biopsies were available for 38 patients. To establish the normal range of IEL, biopsies were obtained at 2, 5 and 10 cm above the GE junction from 12 asymptomatic volunteers with normal Bravo pH monitoring. IEL were counted in one x400 high power field from the most affected area. CD4 and CD8 T-cells were analyzed by routine immunohistochemistry. The data is presented as mean \pm SD.

Results: In the last 3 years, we have encountered esophageal biopsies with overtly elevated IEL, 86 \pm 33, from 5 patients with achalasia, which all demonstrated a predominance of CD4 IEL (CD4:CD8= 4.9 \pm 5.4). In comparison, the majority (12/15, 80%) of the patients (age 56 \pm 15; M:F 1.5:1) with RE and IIEL showed predominance of CD8 IEL (CD4:CD8= 0.5 \pm 0.3), with the remaining 3/15 (20%) showing CD4 predominance (CD4:CD8= 2.2 \pm 0.8). Thus, to address the possibility that IIEL are frequently seen in achalasia and differ immunophenotypically from IIEL of RE, we first established a normal range of IEL. The mean number of IEL at 2, 5 and 10 cm in healthy volunteers (age 36 \pm 8; M:F 1:1.4) was 25 \pm 19, 24 \pm 12, 24 \pm 9, with upper normal cutoffs of 42, 48 and 62 IEL, respectively (mean + 2SD). Of 38 patients (age 62 \pm 23, M:F 1:1) with ACH and biopsies, 7 (18%) had IIEL, 89 \pm 27, that were largely focal and peripapillary. CD4 predominance was evident in 5/7 (71%) cases with IIEL, and CD8 predominance in 2/7 (28.6%) cases (respective CD4:CD8 ratios 2.2 \pm 1.1 and 0.3 \pm 0.1). In total, 10/12 (83%) of analyzed cases of ACH with IIEL showed CD4 predominance ($p=0.002$, ACH vs RE).

Conclusions: A minority of patients with achalasia display IIEL in esophageal biopsies. However, the majority of cases with IIEL show predominance of CD4 IEL, suggesting a distinctive immunophenotypic pattern of lymphocytic inflammation in achalasia that may be useful diagnostically.

791 Radiation Esophagitis Is Characterized by Rarity, Clinical Acuteness, Endoscopic Nonspecificity and Histological Mimicry to CMV Esophagitis

D Murro, L Cheng, A Harbhajanka, S Patel, S Jakate. Rush University Medical Center, Chicago, IL.

Background: Therapeutic radiation dosage to chest/thoracic cancers (lung, breast, esophagus, thoracic vertebrae) commonly exposes the esophagus to radiation injury. However, symptomatic radiation esophagitis requiring endoscopic and histological evaluation appears quite rarely. We studied our Medical Center's large databases to determine its frequency and assess if it shares known characteristics of radiation proctitis such as chronicity, localization (distal rectum) and distinctive angioectasia endoscopically and histologically.

Design: We searched the clinical and pathology databases for radiation esophagitis in our medical center (large tertiary care hospital) for the last 13 years (2000-2013). The patient population in our medical center includes >150 thoracic organ cancers/year and >2500 patients undergoing Esophagogastroduodenoscopy(EGD)/year. The selected patients were reviewed for cause for radiation, time of esophagitis onset after radiation, endoscopic findings, pre-biopsy clinical/endoscopic diagnoses and histological findings including suspected differential diagnosis.

Results: Only 7 cases (6 females and 1 male, age range 33-73 yrs) were identified. The tumors were lung (5) and breast (2). In 6/7 cases (86%), radiation esophagitis occurred within 2 months after therapy. All patients presented with nonspecific symptoms of

dysphagia (3), odynophagia (2) or both (2). Endoscopically, there were ulcerations and/or erythema, and the abnormalities were variably located in the esophagus: entire esophagus (3), mid esophagus (3) and mid and distal (1). Two of the cases showed either mid or upper esophageal strictures on endoscopy. None of the 7 cases were clinically or endoscopically suspected as radiation esophagitis. Histologically, there was radiation atypia of the stromal/endothelial cells, and CMV was ruled out through negative immunostain. Angioectasia was not a feature endoscopically or histologically. **Conclusions:** Radiation esophagitis is quite rare, affects <1% of patients receiving radiation for chest/thoracic cancers and occurs acutely within 2 months. It does not recapitulate the familiar paradigm of radiation proctitis of chronicity, localization or distinctive angioectasia. It remains clinically and endoscopically unsuspected. Histologically, radiation atypia is often confused for CMV which needs to be ruled out by use of immunostain.

792 BRAF Mutation Identifies Serrated Adenomas with an Adenomatous Pattern

E Musulen, L Serrano, AM Munoz-Marmol, C Sanz, C Carrato, E Martinez-Balibrea, A Ariza. Hospital Universitari Germans Trias i Pujol, Badalona, Barcelona, Spain; Fundacio IGTP, Badalona, Barcelona, Spain.

Background: Both *BRAF* and *KRAS* mutations may contribute in a parallel fashion to the serrated pathway, which accounts for about 90% of sporadic microsatellite instability-high (MSI-H) colorectal carcinomas (CRCs) of the right colon (RC). The *BRAF* c.1799T>A (p.V600E) mutation is highly sensitive and specific for the serrated pathway and, due to its strong relation to *MLH1* methylation, is often associated with MSI-H. In contrast, *KRAS* mutations, more commonly found in distal CRCs, are associated with microsatellite stability (MSS). A better knowledge of precursor lesions (PLs) is mandatory to understand the serrated pathway's mechanisms.

Design: MSI-H/MLH1(-) RC CRCs were selected (Lynch syndrome and serrated polyposis were exclusion criteria), with MSS RC CRCs serving as controls. PL occurrence and features and *BRAF/KRAS* mutations were assessed in all cases and controls, which were classified according to *BRAF* (*BRAF*-V600E vs *BRAF*-wt) and *KRAS* (*KRAS*-mt vs *KRAS*-wt) status.

Results: We identified 65 MSS RC CRCs and 66 MSI-H/MLH1(-) RC CRCs. Of the latter, 32 cases (32/66, 48%) were *BRAF*-wt/*KRAS*-wt, 31 cases (31/66, 47%) were *BRAF*-V600E/*KRAS*-wt, and only 3 cases (3/66, 5%) were *BRAF*-wt/*KRAS*-mt. In the control group, 36 instances (36/65, 55%) were *BRAF*-wt/*KRAS*-mt and only 10 instances (10/65, 15%) were *BRAF*-V600E/*KRAS*-wt, while the remaining 19 instances (19/65, 30%) were *BRAF*-wt/*KRAS*-wt. MSI-related distribution of *BRAF/KRAS* mutations was statistically significant ($p=0.000$). Fifteen PLs (7 conventional adenomas [CAs] and 8 serrated adenomas [SAs]) were identified in the MSI-H/MLH1(-) CRC group. Of the 8 PLs in the *BRAF*-V600E/*KRAS*-wt CRC group, 5 (2 CAs and 3 SAs) showed *BRAF*-V600E, while the one PL (1 SA) found in the *BRAF*-wt/*KRAS*-mt CRC group was *BRAF*-wt/*KRAS*-wt. Among the 6 PLs in the *BRAF*-wt/*KRAS*-wt CRC group, 2 (1 CA and 1 SA) were *BRAF*-wt/*KRAS*-wt. Seventeen PLs (10 CAs and 7 SAs) were identified in the control group. As for the *BRAF*-V600E/*KRAS*-wt CRC group, only 1 PL (a *BRAF*-wt/*KRAS*-wt SA) was found. Twelve PLs were identified in the *BRAF*-wt/*KRAS*-mt CRC group, of which 5 (2 CAs and 3 SAs) were *BRAF*-wt/*KRAS*-mt. **Conclusions:** *BRAF*-V600E mutation is characteristic of MSI-H/MLH1(-) RC CRCs and their PLs, which commonly show a serrated pattern. However, in some *BRAF*-V600E PLs the serrated pattern would be obscured by high-degree dysplastic changes giving rise to an adenomatous pattern.

793 MSI Assay on 79 Consecutive Cases with Colorectal Carcinoma in a Tertiary Hospital of Northern Florida: NCI Recommended Panel Revisited, Collateral Findings and beyond

K Nagee, C Ormenisan, R Santiago, C Monteiro, Z Wang. University of Florida College of Medicine, Jacksonville, FL.

Background: National Cancer Institute (NCI) and revised Bethesda guidelines recommend testing three dinucleotide and two mononucleotide microsatellite markers, plus additional mononucleotide marker(s) for microsatellite instability (MSI) assay. The dinucleotide markers, however, provide additional opportunities to evaluate genome stability via loss of heterozygosity (LOH) analysis. Selection of CAT25 as an additional mononucleotide marker is infrequent among molecular diagnostic laboratories. This study sets out to investigate one such opportunity; to provide polymorphic status of each dinucleotide marker in a unique cohort of north Florida patients; to share our experience on CAT25; and to report a case with MSI-H genotype detectable only by dinucleotide markers.

Design: Seventy nine patients with colorectal carcinoma were evaluated. Multiplex PCR amplification was performed on DNA isolated from microdissected tumor and normal tissue from paraffin embedded sections. The PCR products were analyzed by capillary electrophoresis to determine MSI. LOH was determined by the following formula and those with ratios >2 were determined as LOH: (peak height of normal allele 2) / (peak height of normal allele 1); (peak height of tumor allele 2) / (peak height of tumor allele 1).

Results: Nine cases (11%) showed MSI-H genotype. The dinucleotide markers show a high frequency of homozygosity and LOH.

Frequency of homozygosity, heterozygosity and LOH

Dinucleotide Marker	Homozygous	Heterozygous	LOH
D2S123	41 (52%)	38 (48%)	5 (6%)
D5S346	36 (46%)	43 (54%)	14 (17%)
D17S250	39 (49%)	40 (51%)	8 (10%)

CAT25 is as sensitive as BAT25 and BAT26 by displaying MSI genotype in six of seven MSI-H cases. One MSI-H case was detected by dinucleotide markers only.

Conclusions: The results derived from this study on a north Florida population, which is predominantly African Americans, 1) contribute to the epidemiologic data of

polymorphic status of the dinucleotide markers; 2) bring awareness of the polymorphic status of dinucleotide markers that can help MSI evaluation in equivocal cases; 3) serve as a reliable means to evaluate post-amplification cross contamination; 4) highlight the extent of genomic instability of colorectal carcinoma; 5) promote the utility of CAT25 as the additional mononucleotide marker. Finally, the finding of one MSI-H case that is detectable only with dinucleotide markers in our study is exceptional and supports the utility of the NCI recommended panel.

794 Intratumoral Heterogeneity in Gastric Cancer Revealed by Simultaneous Analysis of Protein Over-Expression and Gene Amplification Using a Gene-Protein Assay

YNishida, TKuwata, HNitta, AOchiai. National Cancer Center Hospital East, Kashiwa, Chiba, Japan; Ventana Medical Systems, Inc, Tucson, AZ.

Background: HER2 protein overexpression and gene amplification are important predictive biomarkers for trastuzumab treatment. Because gastric cancer shows high rates of tumor heterogeneity, it may influence the results of HER2 testing. We assessed HER2 protein expression, HER2 gene amplification, and the intratumoral heterogeneity by using a gene-protein assay (GPA) that allows simultaneous analyses of HER2 gene and protein status in a single glass slide.

Design: With tissue microarray (TMA) technique, HER2 status of 875 gastric cancer cases were evaluated by immunohistochemistry (IHC), dual-color insitu hybridization (DISH), and GPA. Intratumoral phenotypic and genotypic heterogeneity was evaluated by comparing the HER2 status on two TMA cores from the same lesion of each case.

Results: There were excellent concordances between GPA and IHC (99.2%) and also GPA and DISH (99.3%). HER2 positivity obtained by GPA was almost identical (99.9%) with the results obtained by IHC and DISH separately. Intratumoral phenotypic heterogeneity was more frequently observed in IHC 2+ cases (47/76; 61.8%) than IHC 3+ cases (15/51; 29.4%). Although there was a strong correlation (Cramer's V statistic of 0.58), phenotypic heterogeneity (62/127; 48.8%) was more frequently observed than genotypic heterogeneity (25/93; 26.8%). Tumor heterogeneities were observed frequently even in early disease stages (T1, N0, and Stage I-II).

Conclusions: HER2-positive gastric cancers possessed different status in HER2 protein expression and gene amplification within the lesion. It will be important to evaluate both phenotypic and genotypic heterogeneity for understanding and predicting the clinical outcome of gastric cancer treated with trastuzumab. Newly established GPA technology may be useful for establishing biomarkers for other molecular targeting drugs.

795 Screening Lynch Syndrome: A Selective Microsatellite Instability Testing Strategy Versus a Universal Testing Strategy

SNolan, W-YHuang. Queen Elizabeth II Health Sciences Centre, Dalhousie University, Halifax, NS, Canada.

Background: The optimal strategy for screening patients with colorectal carcinoma (CRC) for Lynch syndrome (LS) is debated continuously in the literature. While recent studies advocate the universal screening of LS in patients with CRC, our publicly funded laboratory without reimbursement for additional molecular testing continues to apply a selective screening strategy for CRC patients with LS. We are the only regional referral center offering MSI testing to a population of 1 million with an annual incidence of 850 CRC; the objectives of this study were 1. to evaluate the results of MSI testing in our center, and 2. to compare them with those of universal MSI testing from a cohort of 152 CRC.

Design: Physicians referred patients with CRC suspicious for LS to our medical genetics center where genetic counselors reviewed patient's personal and family history. Samples of patients who met revised Bethesda guidelines were sent to our laboratory for MSI testing (selective testing group). We also performed MSI testing on a cohort of 152 CRC collected before 2010 (universal testing group). We divided MSI-H CRC into three groups: sporadic MSI-H CRC (MLH1-/PMS2-, *BRAF*^{V600E} positive), probable LS-associated CRC (MLH1-/PMS2-, *BRAF*^{V600E} negative) and LS (MSH2-/MSH6-).

Results: From January 2012 to September 2013, we tested 40 CRC, representing approximately 3% of the total CRC diagnosed over this period of time. Fourteen out of 40 CRC were MSI-H (35%), of these, 6 were LS, 7 were probable LS-associated CRC and one was a sporadic MSI-H CRC. In contrast, in the universal testing group, 17 out of 152 cases were MSI-H CRC (11%), in which one was LS, 8 were probable LS-associated CRC and 8 were sporadic MSI-H CRC. There were significantly more LS cases identified in the selective testing group compared to the universal testing group (6/14-43% vs. 1/17-6%, $p=0.007$) and fewer *BRAF*^{V600E} positive CRC in the selective testing group as compared to the universal (1/8-12% vs. 8/16-50%, $p=0.05$).

Conclusions: Using personal and family history as a screening strategy and testing about 3% of the total CRC within our population, we were able to identify more individuals with LS than with our universal approach, 4 times the sample size (40 vs. 152). However, given that LS-associated CRC represent 2% of all CRC, we estimate that we missed at least 50% of the LS in our population. It remains a challenging task for a publicly-funded lab to find an optimal strategy for screening LS in the remaining 97% of CRC.

796 Pulse Granulomata (PG) in the Gastrointestinal Tract (GIT): Distinguishing Features of an Under-Recognized Pseudotumor

NB Nowacki, MA Arnold, W Frankel, M Yearsley, CA Arnold. The Ohio State University Wexner Medical Center, Columbus, OH; Nationwide Children's Hospital, Columbus, OH.

Background: PG is best characterized in the oral pathology literature in association with dental caries and dentures. The presumed etiology is entrapped "pulse" or food introduced through mucosal trauma. Herein, we report the largest series of PG in the GIT.

Design: PG involving 16 GIT resections from 11 patients were prospectively collected over a one year period (men=6, mean age=51 years). Pertinent clinicopathologic features were recorded.

Results: Consistent histologic features of PG include nodular collections of eosinophilic ribbons of hyaline material intermixed with abundant histiocytes, circumferential stellate fibrosis in larger lesions, foreign material (favor food, 14/16 cases), and variable amounts of granulation tissue with microabscesses. All cases were nodular and most were multifocal, ranging in size from 0.15-10 cm. Most cases involved the serosa of the small bowel (n=7) or large bowel (n=9). Involvement of the liver, appendix, ileostomy, cervix, ovary, mesentery, omentum, peritoneum, and skin was also seen (n=1 each). Ten patients had a history of tobacco use and bowel injury was documented in all cases: ulcer (n=8), diverticular disease (n=6), perforation (n=5), fistula (n=3), ulcerative colitis (n=2), and appendicitis, abscess, and colorectal cancer (n=1 each). Three cases presented as mass lesions clinically concerning for neoplasia. Hyaline ribbons mimicking amyloid were seen in all cases, prominent fat necrosis mimicking sclerosing mesenteritis was seen in 4 cases, and prominent epithelioid histiocytes with brisk intralosomal lymphocytes mimicking a spindle cell neoplasm were seen in 2 cases. Clinical followup was available in all patients up to 12 months and all patients are alive and well. In addition, a variety of foods were histologically processed and compared to our cases and show similar findings, supporting the prevailing theory of entrapped food debris.

Conclusions: In summary, we report the largest case series of PG in the GIT. Common clinical associations include tobacco usage (91%) and bowel injury (100%). The consistent histologic features include nodular collections of eosinophilic hyaline ribbons intermixed with abundant histiocytes, entrapped foreign material (87.5%), and circumferential stellate fibrosis in larger lesions. Although PG can present as large mass lesions clinically concerning for malignancy, we believe these are benign, reparative lesions that are likely the result of entrapped food material.

797 Predominant Intestinal Differentiation in Esophageal Adenocarcinoma Is Associated with Low Recurrence and Improved Survival

JA Nowak, A Agoston, M Tippayawong, Y Zheng, R Bueno, RD Odze, A Srivastava. Brigham and Women's Hospital, Boston, MA; Bangkok Hospital Phuket, Muang, Phuket, Thailand; Brigham and Women's Hospital and Harvard Medical School, Boston, MA.

Background: Intestinal and gastric phenotypes are the most well recognized patterns of differentiation in esophageal adenocarcinoma [EAC]. The aim of this study was to determine whether the morphologic phenotype of EAC is predictive of tumor recurrence and patient outcome.

Design: 89 patients with T1-T3 EAC treated by surgical resection, without neoadjuvant therapy, and for which tissue was available for immunohistochemical studies, were included in the study. The presence and extent of intestinal or gastric differentiation was scored and used to classify tumors into predominantly intestinal, predominantly gastric or uncertain phenotypes. Expression of intestinal markers CDX-2 and MUC2, and gastric markers MUC5 and MUC6, was also evaluated independently to aid in assessment of tumor phenotype. Follow up data, including overall survival and time to recurrence, was obtained by medical chart review, and was analyzed by both a Cox Proportional Hazards Model and Fisher's Exact Test.

Results: The M:F ratio was 3.2:1 and the mean age of the patient cohort was 67.3 years. 59/89 patients (66%) died and 21 patients (24%) had a documented recurrence (3 local, 12 distant and 4 combined local and distant) during follow up. Tumors that exhibited intestinal differentiation, either morphologically or by strong CDX-2 expression, were significantly associated with increased survival (Odds Ratio [OR]=0.31 for median survival by morphology, p=0.045; Hazard Ratio [HR]=0.53 for median survival by CDX-2, p=0.039). MUC6 expression was independently predictive of lower stage (OR=0.11, p=0.002), absence of nodal metastases (OR=0.14, p<0.001), decreased recurrence (HR=0.17, p=0.0041) and increased survival (HR=0.46, p=0.009). In contrast, tumors that showed an uncertain phenotype were associated with increased tumor recurrence (HR=3.75, p=0.036) and decreased survival (HR=1.74, p=0.040).

Conclusions: Our findings demonstrate that intestinal differentiation in EAC is a strong predictor of low risk of recurrence and increased survival, whereas tumors showing an uncertain phenotype are at higher risk for adverse outcomes.

798 Intestinal Spirochetal Infection Has Pathogenicity on Humans

S Ogata, M Higashiyama, I Ohara, S Hiroi, K Nakanishi, T Kawai. National Defense Medical College, Tokorozawa, Japan; Japan Self-Defense Forces Hospital Yokosuka, Yokosuka, Japan; National Defense Medical College Hospital, Tokorozawa, Japan.

Background: Human intestinal spirochetosis (HIS), a colorectal bacterial infection caused by *Brachyspira* species, has a controversial pathogenicity. Without histologic fringe formation on the mucosal surface, characteristic features of HIS have not been revealed.

Design: We aimed to clarify the characteristic features of HIS cases. For macroscopic view, the endoscopic images examined were obtained from 55 HIS cases (M:F=55:0) and 478 non-HIS cases (M:F=422:6). All had undergone colonoscopic examinations and been confirmed histologically at a single military hospital during a two-year period. For microscopic view, the mucosal thickness of specimens obtained from HIS cases was estimated histologically.

Results: Five endoscopic features were observed frequently in HIS cases: 1) rough mucosa without vascular transparency (65.5%), 2) red spots/hyperemia (52.7%), 3) serrated polyps (27.2%), 4) sticky mucus (21.8%), and 5) lymphoid follicular hyperplasia (9.1%). The first three were most important endoscopic features for identification of HIS. In HIS cases exhibiting only a single feature, rough mucosa without vascular transparency (13 HIS cases) was the most frequent. Both rough mucosa without vascular transparency and red spots/hyperemia were found mostly in the right-side large intestines

of HIS cases. Of the 13 HIS cases exhibiting only a single endoscopic feature, 85% exhibited the former feature in the right-side large intestines. Histologically, an increased stromal thickness of the mucosal layer, implies endoscopically rough mucosa without vascular transparency. That thickness was 405 mm on average in 65 HIS specimens (significantly thicker than in non-HIS cases).

Conclusions: Among HIS patients, several endoscopic characteristics were found. Especially, rough mucosa without vascular transparency was found in the right-side large intestine. Histologic mucosal thickening was considered to be responsible for this endoscopic characteristic. These characteristics drawn from this study also suggested the presence of pathogenicity on humans by intestinal spirochetal infection.

799 The Prognostic Significance of C-Met and EGFR Overexpression in Gastric Carcinomas

A Paliga, H Marginean, B Purgina, B Tessier, D Jonker, EC Marginean. The Ottawa Hospital, Ottawa, ON, Canada; Ottawa Research Institute, Ottawa, ON, Canada; McGill University, Montreal, QC, Canada.

Background: ErbB-1 (EGFR) and c-met are tyrosine kinase growth factor receptors implicated in numerous malignancies, including gastric carcinoma (GC). The aim of this study was to investigate the prognostic value of EGFR and c-met proteins overexpression by immunohistochemistry (IHC) in GC and correlate it with clinicopathologic characteristics.

Design: We constructed Tissue Microarray (TMA) blocks from 120 consecutive GC, between 2002-2008, containing 4 cores/tumor to account for tumor heterogeneity. TMAs were stained by IHC with EGFR and c-met and scored by 2 pathologists from 0-3+, based on membranous and cytoplasmic staining intensity respectively. Overall, 0 and 1+ were considered negative, 2+ and 3+ were considered overexpressed. Descriptive statistics, Kaplan Meyer and Cox regression were used for statistical analyses.

Results: Of 115 interpretable cases - median age 65 (29-94), gender M 72%, F 28%, histologic type: intestinal 75%, diffuse 15%, mixed 10%. Individual overexpression of EGFR and c-met was noted in 17 (15%) and 65 (57%) respectively; co-expression of both EGFR and c-met was observed in 12 (10%) tumors. We observed no correlation between T, N stage, age and tumor location and EGFR or c-met overexpression. Intestinal type was correlated with c-met expression, and metastases were more frequent in EGFR-positive GC. Tumors with EGFR and c-met overexpression showed inferior overall survival (OS): median 13 months vs. 30 months in EGFR +ve vs. -ve GC [HR=1.67, 95% CI 0.95-2.93, p=0.08]; 27 months vs. 49 months in c-met +ve vs. -ve GC [HR=1.22, 95% CI 0.77-1.92, p=0.40], respectively. As previously reported, the prognostic effect of c-met overexpression was time-dependent, with the survival curves separating after 26 months, demonstrating inferior survival in the C-met +ve group. GC co-expressing both EGFR and c-met was correlated with poor survival: 12 months vs. 29 months in +ve vs. -ve tumors [HR=2.38, 95% CI 1.16-4.88, p=0.02]. Except co-expression of both EGFR and c-met, none of the factors showed statistically significant correlation with OS in univariate analysis.

Conclusions: In our study, while individual expression of EGFR and c-met was associated with poor survival in GC, only coexpression of both markers reached statistical significance. Larger studies to confirm our findings are warranted, since targeted therapy may provide a major therapeutic advance.

800 MicroRNA Sequencing Reveals Distinct Expression Profiles in Neuroendocrine Tumors of the Pancreas and Ileum

NC Panarelli, N Renwick, Z Chen, T Tuschl, Y-T Chen. Weill Cornell Medical College, New York, NY; The Rockefeller University, New York, NY.

Background: Neuroendocrine tumors (NETs) of digestive organs share many pathologic features, but differ in their clinical behavior. The genetic and epigenetic mechanisms that contribute to this biologic heterogeneity are mostly unknown. MicroRNAs (miRNAs) are noncoding RNA sequences that bind to messenger RNAs and suppress their expression. Aberrant expression of miRNAs has been shown to contribute to oncogenesis in many types of malignancies, but their expression in NETs of digestive organs has only been evaluated in few studies based on microarrays and qRT-PCR data. In this study, we used a novel small RNA sequencing technique to comprehensively examine miRNA expression profiles in NETs of the ileum and pancreas.

Design: Total RNA was extracted from manually dissected, formalin-fixed, paraffin-embedded tissue sections from well-differentiated ileal (n=10) and pancreatic (n=10) NETs and was subjected to barcoded small RNA sequencing. Unsupervised clustering was performed using normalized data and mean miRNA expression levels were statistically compared between ileal and pancreatic NETs.

Results: All ileal NETs were low-grade and all were associated with lymph node metastases. Distant metastases were present in 6 cases. Pancreatic NETs included 7 low- and 3 intermediate-grade tumors, and one had lymph node and visceral metastases. Unsupervised hierarchical clustering correctly classified 100% of NETs as either ileal or pancreatic based on their miRNA expression profiles. Fifty-eight miRNAs showed statistically different expression levels in ileal NETs compared to pancreatic NETs. The most highly overexpressed miRNAs in ileal tumors included miR-615 and -196a (fold changes: 653 and 248, respectively, p<0.001 for both comparisons), species that have been shown to promote tumor invasion. Expression of miR-216b, a miRNA that negatively regulates *KRAS*, was lower in ileal compared to pancreatic NETs (fold change: 48, p=0.024). Both tumor types overexpressed miR-375, as has been previously observed in NETs.

Conclusions: Barcoded small RNA sequencing reveals distinct miRNA expression profiles among ileal and pancreatic NETs. Ileal NETs in our series displayed higher pathologic stage and were associated with overexpression of oncogenic miRNAs -615 and -196a and low expression of the tumor suppressor, miR-216b. These findings suggest that dysregulation of these miRNAs contribute to local and distant tumor spread in small intestinal NETs.

801 Correlating the Expression of HK2, CD133, iNOS and CK7 in the Progression of Hepatocarcinogenesis

M Pant, JJ Choi, KM Choi, R Chenmuri, S Fidai, H Sreedhar, M Walsh, G Guzman. University of Illinois at Chicago, Chicago, IL.

Background: Hepatocarcinogenesis is a multistep process involving numerous molecular alterations in the hepatocytes that leads to evolution of cirrhosis to dysplasia to hepatocellular carcinoma (HCC). However, the precise molecular mechanisms involved in the pathogenesis of HCC remains unclear. This project aims to examine the expression of four markers, iNOS, CD133, HK2 and CK7, in patients with advanced chronic liver disease to better elucidate their role in liver cell change found in cirrhosis, dysplastic cirrhosis, and HCC.

Design: A retrospective search identified 45 patients diagnosed with HCC who underwent a liver tumor resection between 1999 and 2006. Three core tissue biopsies were taken from each patient, one from each area of cirrhosis, dysplastic cirrhosis and HCC, from the original surgical specimen blocks. These cores were arranged in a tissue microarray (TMA) and stained with immunohistochemistry (IHC) markers HK2, CD133, iNOS and CK7. The stained TMA slides were then analyzed using the Aperio™ to yield staining indexes for these markers. To assess the precision of the staining index, the Pearson's correlation coefficient was calculated. A p-value of 0.05 was used to indicate statistical significance.

Results: The mean staining index for all four IHC markers demonstrated a rising trend with progression of disease from cirrhosis to dysplasia [Table 1]. When comparing the IHC markers, there were statistically significant correlations between all four IHC markers for staining patterns in cirrhosis and dysplasia. In the setting of HCC, HK2 demonstrated significant correlation with iNOS; and CD133 with CK7 [Table 2].

Table 1: Mean staining index per Aperio(TM) analysis

	Cirrhosis	Dysplasia	HCC
HK2	65.54 ± 25.91	91.54 ± 40.48	91.13 ± 32.61
CD133	133 ± 30.27	136.66 ± 30.03	133.47 ± 38.43
iNOS	115.75 ± 31.46	131.66 ± 40.82	141.55 ± 38.77
CK7	92.73 ± 28.16	109.69 ± 28.58	89.78 ± 3.75

Values are mean ± standard deviation

Table 2: Pearsons Correlation Coefficient (with p-value) between immunohistochemistry stains

		HK2	iNOS	CK7
CD133	Cirrhosis:	0.579 (0.0060)	0.604 (0.0038)	0.722 (0.0002)
	Dysplasia:	0.463 (0.0067)	0.357 (0.0412)	0.468 (0.0052)
	HCC:	0.230 (0.1772)	0.021 (0.9018)	0.453 (0.0055)
CK7	Cirrhosis:	0.699 (0.0003)	0.750 (<0.0001)	
	Dysplasia:	0.603 (0.0002)	0.381 (0.0263)	
	HCC:	0.052 (0.7583)	0.005 (0.9780)	
iNOS	Cirrhosis:	0.691 (0.0002)		
	Dysplasia:	0.661 (<0.0001)		
	HCC:	0.665 (<0.0001)		

Conclusions: The above findings support the pivotal role that each of these genes play in the pathogenesis of HCC. Further studies may yield the potential to use these markers as prognostic indicators and in the future, develop targeted therapies.

802 Correlation of Ki-67, Mitotic Count, and PHH3 in Grading Gastrointestinal and Pancreatic Neuroendocrine Neoplasms

A Papanicolaou-Sengos, CE Murphy, KA McCormick, MP Upton, V Shankaran, M Westerhoff. University of Washington, Seattle, WA.

Background: Neuroendocrine neoplasms (NENs) of the digestive system are classified into three tiers (G1, G2, G3) based on Ki-67 index or mitotic count (MC). However, in practice, a discrepancy between grade by Ki-67 and MC can lead to conflicting information and complicate clinical management. Both methods for establishing tumor grade also have important limitations, and previous studies in other cancer types have suggested that phospho-histone H3 (PHH3), a mitosis-specific marker, may be a more clinically useful proliferation marker. Our aim was to determine the rate of concordance in grade assignment based on Ki-67 and MC. We also evaluated the concordance of grade, as determined by PHH3, with both Ki-67 and MC.

Design: 150 surgically resected cases of NEN of pancreatic (n=56) and gastrointestinal (stomach, small and large intestine, appendix) (n=94) origin were assessed for MC (on routine H&E) and immunohistochemically stained for Ki-67 and PHH3. Grades were assigned based on both MC and Ki-67, in accordance with the 2010 World Health Organization classification system. Grade based on PHH3 was determined by counting PHH3-positive tumor cells in 50 HPF, and stratified using the same criteria recommended for MC. Inter-rater agreement between grade assignment by the various assays was determined using a weighted kappa statistic, which accounts for differences in grade assignment by 1 vs. 2 categories.

Results: Grade assignment by all 3 methods (Ki-67, mitotic count, PHH3) was feasible in 99 out of 150 cases. Grading based on Ki-67 stratified NENs into 85% G1, 14% G2, and 1% G3. Grading based on MC stratified NENs into 82% G1, 18% G2, and 0% G3. Grade assignment by PHH3 stratified NENs into 54% G1, 45% G2, and 0% by G3. Grade assignment was discordant in 18% of cases when using Ki-67 and MC (weighted kappa (Kw) 0.37 (p=0.001)). Grade as determined by PHH3 vs. MC was discordant in 31% of cases (Kw of 0.33 (p<0.001)), and grade as determined by PHH3 vs. Ki-67 was discordant in 36% of cases (Kw of 0.21 (p=0.0018)). Median survival was similar for gastrointestinal NEN (60.0 months 95% CI 44.7 – 80.5) and pancreatic NEN (69.8 months 95% CI 59.9 – 80.8) (log rank p=0.79).

Conclusions: This study demonstrated only fair agreement between Ki-67 and MC in assigning tumor grade in patients with NENs of the digestive system. Moreover, using the WHO grading parameters for MC, PHH3 tended to upgrade tumors from grade 1 to 2, and showed less concordance with both MC and Ki-67.

803 The Significance of Signet Ring/Poorly Cohesive Cellular Histological Component as a Risk Factor Associated with Lymph Node Metastasis in Submucosal Invasive Gastric Carcinoma

HK Park, K-Y Lee, M-W Yoo, TS Hwang, HS Han. Konkuk University School of Medicine, Seoul, Republic of Korea.

Background: Mixed carcinoma is a newly-defined histologic type of the gastric carcinoma in 2010 WHO classification. This type shows a mixture of glandular and signet ring/poorly cohesive cellular histological components and the prognostic relevance of the proportion of each component has not been fully understood. This study investigates the significance of the proportion of signet ring/poorly cohesive cellular histological component as a risk factor for lymph node metastasis associated with submucosal invasive gastric carcinoma.

Design: We reviewed the clinicopathologic characteristics of 202 submucosal invasive gastric carcinomas surgically resected with lymph node dissection in the period 2005-2012.

Results: The histologic types of submucosal invasive carcinomas were 123 tubular adenocarcinomas, 52 mixed carcinomas, 18 poorly cohesive carcinomas, 7 medullary carcinomas and 2 mucinous carcinomas. The proportion of signet ring/poorly cohesive cellular histological component in mixed carcinomas ranged from 2% to 95%. In this study, the overall prevalence of lymph node metastasis was 17.3% (35/202). Lymphatic invasion (p<0.001), family history of the any carcinoma (p=0.025), tumor size (p=0.004), depth of invasion (p=0.042) and presence of any signet ring/poorly cohesive cellular histological component (p=0.021) showed a positive correlation with the rate of lymph node metastasis by univariate analysis. Multivariate analyses revealed the presence of any signet ring/poorly cohesive cellular histological component to be the most significant and independent factor related to lymph node metastasis. In review of preoperative biopsy slides, 34.4% of the cases (22/64) did not show any signet ring/poorly cohesive cellular histological component in their biopsy slides.

Conclusions: The presence of any signet ring/poorly cohesive cellular histological component is an independent risk factor associated with lymph node metastasis in submucosal invasive gastric carcinoma. But this histologic component could be missed in preoperative biopsy specimens, multiple biopsy would be helpful for precise prediction.

804 Signet Ring Cell Histology on Pretreatment Biopsy Predicts Poor Response and Survival Outcomes in Patients with Esophageal Adenocarcinoma Treated with Neoadjuvant Chemoradiation and Surgery

V Patel, W Hofstetter, A Correa, A Agarwal, A Rashid, M Bhutani, S Lin, J Ajani, S Swisher, D Maru. Temple University Hospital, Philadelphia, PA; The University of Texas MD Anderson Cancer Center, Houston, TX; Baylor College of Medicine, Houston, TX.

Background: Signet ring cell histology is related to patient outcome in gastric cancer. Significance of signet ring cell histology in pretreatment biopsies from patients with esophageal adenocarcinoma, in terms of patient outcome is unclear.

Design: Two groups of patients with loco regional esophageal adenocarcinoma treated with neoadjuvant chemoradiation and surgery were studied: those with signet ring cell adenocarcinoma (n=85, slides reviewed by two pathologists) and a reference group (n=638) with usual type of adenocarcinoma. Surgical specimens were reviewed for degree of pathologic response and pathologic stage. Cox regression models were used to assess the effects of clinicopathologic variables on survival.

Results: Patients in the signet ring cell group had a lower rate of complete pathologic response (9% vs. 26%, p<0.001) and frequent positive margins (24% vs. 10%, p<0.001) compared with the reference group. Median overall (22 vs. 48 months, p=.003) and disease-free survival (16 vs. 35 months, p=.007) were shorter in the signet ring cell group than the reference group. In multivariate analyses older age, signet ring cell histology and high pathologic stage were significant predictors of decreased overall survival and signet ring cell histology and high pathologic stage were significant predictors of decreased disease-free survival. Survival for patients whose resected specimens showed downstaging after neoadjuvant chemoradiation did not significantly differ from those whose specimens did not show downstaging in the signet ring cell group, unlike the reference group.

Conclusions: Signet ring cell histology on pretreatment biopsy predicts a decreased likelihood of complete pathologic response and survival in patients with esophageal adenocarcinoma treated with preoperative chemoradiation and surgery.

805 Routine Somatic Mutation Testing in Colorectal Adenocarcinoma by Next Generation Sequencing Using the Ion Torrent AmpliSeq Cancer Hotspot Panel v2

JR Pettus, JD Peterson, F de Abreu, AA Suriawinata, GJ Tsongalis. Dartmouth-Hitchcock Medical Center, Lebanon, NH.

Background: Testing for mutation status of KRAS and BRAF in colorectal adenocarcinoma has become a clinically important endeavor with regard to modern diagnostic and therapeutic decision making. Testing for individual clinically relevant mutations can be costly and time-consuming. The Ion Torrent AmpliSeq Cancer Hotspot Panel v2 allows for simultaneous and efficient targeted sequencing of "hot spot" somatic mutations in 50 cancer genes.

Design: Biopsy and resection cases of colorectal adenocarcinoma were routinely submitted for analysis. Surgical pathology synoptic reports were reviewed for demographic and tumor data. DNA was extracted from 8 unstained 4µm, formalin-fixed, paraffin-embedded tissue sections. Each sample was first reviewed and marked by a pathologist for tumor macrodissection, enriching for tumor specific DNA. Barcoded libraries were prepared from up to 10ng of extracted DNA and multiplexed on single Ion Torrent 318 chips. Variants were identified using the Ion Torrent Variant Caller Plugin (v.3.6.59049). Variant annotation and functional predictions were performed using

Golden Helix SVS (v.7.7.3). Remaining variants were individually interrogated using the Broad Institute's Integrative Genomics Viewer (IGV), prior to clinical reporting.

Results: One biopsy case yielded insufficient DNA for analysis, leaving data from 42 cases available for analysis. Mutations were identified in 38/42 cases, averaging 1.5 mutations/case. 57% (24/42) of cases showed a clinically actionable mutation in either BRAF (12/42; 29%) or KRAS (12/42; 29%). In addition, 76% (32/43) showed somatic mutations in cancer-related genes of uncertain clinical significance, notably NRAS (2/42; 5%) and PIK3CA (5/42; 12%), 5/13 (38%) BRAF mutations and 3/5 (60%) PIK3CA mutations were also associated with mismatch repair protein expression loss (MLH1 and PMS2) by IHC. All PIK3CA-mutated tumors were low-grade. Mutations did not appear to correlate with pT stage or other pathologic parameters.

Conclusions: Routine somatic mutation testing using the Ion Torrent AmpliSeq Cancer Hotspot Panel v2 is efficient and able to provide high-quality, clinically relevant, data in a timely fashion. Decision analysis for mutation "calling" requires effective analytical software as well as skilled trained personnel. Overall, our mutation data is compatible with prior prevalence reports; however, our BRAF mutation rate (38%) is higher than expected. The reasons for this aberrancy are uncertain but may relate to our patient population.

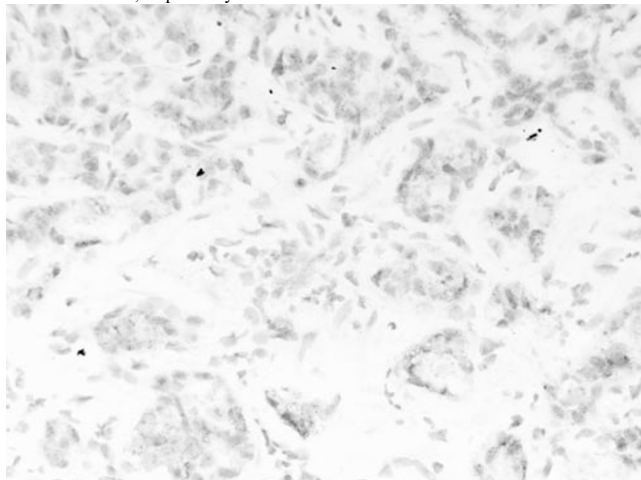
806 Albumin: A Useful Marker of Bile Duct Adenoma in Its Distinction from Metastatic Pancreatic Adenocarcinoma

A Primiani, F Mohamoud, DR Borger, V Deshpande. Massachusetts General Hospital, Boston, MA.

Background: Bile duct adenomas may be difficult to distinguish from metastatic well-differentiated pancreatic adenocarcinomas. This distinction is critical for proper management of patients with pancreatic malignancy. In challenging cases, immunohistochemistry for SMAD4 may help in distinguishing pancreatic ductal adenocarcinoma from a bile duct adenoma; however, SMAD4 is lost in only about half of pancreatic ductal adenocarcinomas. In a prior study, we showed that >95% of intrahepatic cholangiocarcinomas stain positively for albumin. Herein, we investigated the utility of albumin in making the distinction between metastatic pancreatic adenocarcinoma and bile duct adenoma.

Design: We studied 13 bile duct adenomas, 3 bile duct hamartomas, and 95 pancreatic ductal adenocarcinomas. *In situ* hybridization (ISH) was performed using the QuantiGene® ViewRNA technology (Affymetrix, Santa Clara, CA). QuantiGene® ViewRNA ISH is based on the branched DNA technology wherein signal amplification is achieved via a series of sequential steps and provides a unique method to identify cells that produce a secreted protein.

Results: Seven (53.8%) bile duct adenomas were biopsied during surgical resection of a primary malignancy; the remainder were biopsied during surgery for benign conditions or incidental findings in a liver biopsy. Eleven (84.6%) bile duct adenomas were diffusely positive for albumin. Albumin reactivity was also identified in the background hepatocytes. The reactivity within the nonneoplastic liver and bile duct adenomas had a dot-like pattern. The number of dots per cell was significantly less within the bile duct adenoma as compared to within adjacent hepatocytes. Nonspecific reactivity was considered with detection of a single dot per 100 epithelial cells. All pancreatic ductal adenocarcinomas and all bile duct hamartomas were negative for albumin. The sensitivity and specificity of albumin, as detected by branched-chain ISH, for distinguishing bile duct adenomas from metastatic pancreatic adenocarcinomas was 84.6% and 100%, respectively.



Conclusions: Branched-chain ISH for albumin represents a useful marker of bile duct adenomas. Using this platform, diagnostically challenging examples may be distinguished from metastatic pancreatic adenocarcinoma.

807 Increased Intraepithelial Lymphocytes (IEL) Are a Feature of Non-Achalasia Primary Esophageal Motility Disorders (PEMD)

J Putra, KE Muller, S Gabbard, S Parker, AA Surtavinata, RI Rothstein, M Lisovsky. Dartmouth-Hitchcock Medical Center, Lebanon, NH.

Background: IEL consisting predominantly of CD8 T-cells populate normal esophageal epithelium and may be increased in esophagitis of different etiologies. In contrast, a recent study, reported in abstract form, has shown that increased IEL of predominantly

CD4 T-cell type are associated with PEMD (Xue et al. Mod Pathol, 2013, 26, Suppl 2, p188A). The goal of this study was to assess the frequency and nature of IEL in a series of patients with PEMD.

Design: 116 patients with manometry-proven PEMD (study group) and 162 PEMD-negative GERD patients who underwent manometry testing for possible Nissen fundoplication (control group) were identified in the files of our institution from 2007-2013. Esophageal biopsies were available for review in 44 patients with PEMD (age 54 ± 11, M:F=0.7:1) and 42 patients with PEMD-negative GERD (age 55 ± 14, M:F=0.9:1). To establish a normal range of IEL, esophageal biopsies were obtained at 2, 5 and 10 cm above the GE junction from 12 asymptomatic volunteers (age 36 ± 7; M:F=1.2:1) with normal Bravo pH monitoring. IEL counts were performed in the most affected area in 1 high power field (400x). CD4 and CD8 T-cells were analyzed by routine immunohistochemistry. Data is presented as mean ± SD.

Results: In volunteers, the mean number of IEL at 2, 5 and 10 cm was 25 ± 19, 24 ± 12, 24 ± 9, with upper normal cutoffs at 42, 48 and 62 IEL, respectively (mean + 2SD). Distribution of PEMD subgroups is shown in the Table 1. Of 44 patients with PEMD and biopsies, 21 (48%) had increased IEL, 81 ± 46. Increased IEL were present focally in 18/21 (86%) cases and had peripapillary localization in 15/21 (71%) cases. CD4 IEL outnumbered CD8 IEL in 12/20 (60%) of cases available for staining (CD4:CD8=2.2 ± 1.4). The remaining cases showed a predominance of CD8 IEL (CD4:CD8=0.4 ± 0.2). In contrast, only 1/42 (2%) patients with PEMD-negative GERD had increased IEL.

Distribution of specific PEMD in different study subgroups

	Patients with PEMD, %				
	All (n=116)	Available biopsies (n=44)	Increased IEL (n=21)	Increased IEL with CD4 predominance (n=12)	Increased IEL with CD8 predominance (n=8)
Nutcracker esophagus	56	52	57	50	75
Ineffective motility	31	34	29	33	12.5
Diffuse esophageal spasm	13	14	14	17	12.5

Conclusions: Our results suggest that IEL are often increased in PEMD. Predominance of CD4+ T-cells indicates a distinctive type of lymphocytic inflammation, which may be helpful in raising the possibility of PEMD.

808 Increased Expression of Enhancer of Zeste Homolog 2 (EZH2) in High Grade Neuroendocrine Tumors in the Gastrointestinal Tract

J Qin, X Zhang, R Gupta. SUNY Downstate Medical Center, Brooklyn, NY; Yale University School of Medicine, New Haven, CT.

Background: EZH2 is a polycomb group protein that is involved in the progression of multiple human cancers including prostatic, endometrial, and colonic adenocarcinomas. Its expression has been shown to increase from typical carcinoid to atypical carcinoid and further to small cell/ large cell neuroendocrine carcinoma of the lung. Neuroendocrine tumors of gastrointestinal tract are acknowledged to be a group of related neoplasms rather than a single entity with different behaviors. To our knowledge, the expression of EZH2 in different grades of neuroendocrine tumors of the gastrointestinal tract has never been studied.

Design: Seventeen cases of neuroendocrine tumors (Grade I: n=8; Grade II: n=3 and Grade III: n=6) were retrieved from pathology archives. Sites of tumors include esophagus, stomach, small intestine and colon. Expression of EZH2 was analyzed by immunohistochemistry using a monoclonal antibody (EZH2, Biocare Medical, Concord CA) at a concentration of 1:200. More than 10% nuclei showing moderate to intense staining were scored positive for EZH2 expression.

Results: In comparison to the grade I neuroendocrine tumor, EZH2 expression in grade II (p=0.087) and Grade III (p=0.0001) is increased. Similarly, EZH2 expression in Grade III is increased in comparison to grade II neuroendocrine tumor (p=0.023). The grade II neuroendocrine tumor exhibits weak and focal nuclear staining of tumor cells. A grade III neuroendocrine tumor of the esophagus presented with liver metastasis which demonstrated similar EZH2 staining to the primary tumor. There was no difference in the expression with different sites of the neuroendocrine tumors.

Conclusions: EZH2 expression increases incrementally from grade I neuroendocrine tumor to grade II and further to grade III, suggesting a role in progression and differentiation of neuroendocrine tumors. EZH2 expression may be used as a diagnostic marker for differentiating different grades of neuroendocrine tumors.

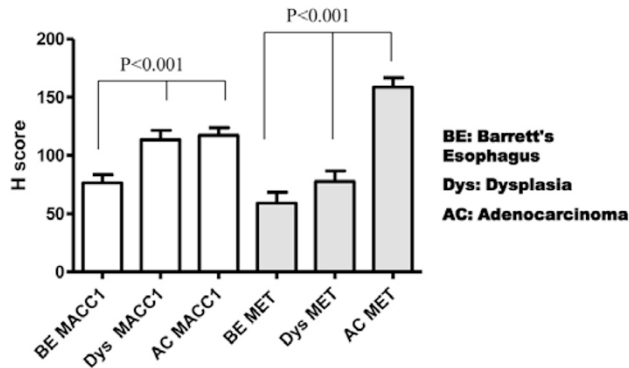
809 Different Roles of MACC1 and MET in Initiation, Progression and Prognosis of Esophageal Adenocarcinoma

B Ren, Z Zhou, M Sharma, W Cao. University of Rochester Medical Center, Rochester, NY.

Background: Metastasis-Associated in Colon Cancer 1 (MACC1), a key regulator of the HGF-MET pathway, is a tumor stage-independent predictor for colorectal cancer metastasis. Recent studies have revealed that MACC1 plays important roles in development and progression of other human cancers including breast, stomach, liver and ovarian carcinoma. Little is known about the roles of MACC1 in esophageal adenocarcinoma (EAC). The aim of this study is to investigate the expression of MACC1 and MET in EAC and its precancerous lesions, and correlate MACC1 and MET expression in EAC with patient survival.

Design: Tissue microarrays (TMAs) were constructed from 48 cases of Barrett's esophagus, 45 cases of dysplasia and 98 cases of EAC. Protein expression of MACC1 and MET was detected by immunohistochemistry (IHC). The stained TMAs were evaluated for the staining intensity (0-3) and percentage of positive cells (H score method). The mean value of the H-score of MACC1 and MET in BE, Dys and EAC was analyzed by one-way analysis of variance. Survival curve was calculated using the Kaplan-Meier method.

Results: *MACC1* expression was low in BE. The expression of *MACC1* was significantly increased in Dys and EAC. No significant difference of *MACC1* expression was found between Dys and EAC. Interestingly, *MET* expression showed different pattern. There was no significant difference of *MET* expression between BE and Dys. However, the expression of *MET* was significantly increased in EAC.



For the patients with EAC, high *MACC1* expression (H-score \geq 150) is associated with a longer survival (median survival, 35.6 months) as compared to low *MACC1* expression (median survival, 18.7 months). However, High *MET* expression (H-score \geq 160) is associated with shorter survival (median survival, 16.8 months) as compared to low *MET* expression (median survival, 35.7 months).

Conclusions: Our results indicate that *MACC1* may participate in EAC initiation. High expression of *MACC1* is associated with better patient survival. *MET* may not be involved in EAC initiation but may play important roles in EAC progression. High *MET* expression is associated with poor prognosis. The data suggests *MACC1* and *MET* may play different roles in EAC initiation, progression and prognosis.

810 Clinicopathologic and Molecular Analysis of Colorectal Carcinoma with Synchronous Peritoneal Dissemination Versus Liver Metastasis: Peritoneal Dissemination Is Frequently Associated with Mucinous and Signet Ring Cell Differentiation

T Reza Kermanshahi, RK Pai. University of Pittsburgh Medical Center, Pittsburgh, PA. **Background:** Colorectal carcinoma with synchronous peritoneal dissemination (CCPD) is associated with a dismal prognosis. Limited literature data exist on the morphologic and molecular features of this aggressive tumor. The aim of this study was to investigate the clinicopathologic and molecular features of CCPD compared to colorectal carcinoma with synchronous liver metastasis (CCLM).

Design: We analyzed 125 stage IV colorectal carcinomas including 60 CCPD and 65 CCLM for clinicopathologic features including grade, tumor location, mucinous/signet ring cell differentiation, angiolymphatic, venous, and perineural invasion, tumor deposits, tumor budding, penetration of visceral peritoneal surface, and "dirty" tumor necrosis as well as for *KRAS* mutations, *BRAF* mutation, and microsatellite instability (MSI) status.

Results: Compared with CCLMs, CCPDs were more frequently located in the right colon (52% vs. 35%, $p=0.03$) and exhibited high tumor grade (32% vs. 14%, $p=0.02$), mucinous differentiation (60% vs. 22%, $p<0.001$), and signet ring cell differentiation (23% vs. 0%, $p<0.001$). Patients with CCPDs were less frequently given neoadjuvant chemotherapy compared to patients with CCLMs (25% vs. 51%, $p=0.005$) indicating that therapy-related changes cannot account for the increased frequency of mucinous differentiation in CCPDs. CCPDs more frequently demonstrated penetration of the visceral peritoneal surface (68% vs. 26%, $p<0.001$). CCLMs more frequently displayed "dirty" tumor necrosis compared to CCPDs (82% vs. 63%, $p=0.02$). There was no statistical significance in gender, age, tumor size, tumor budding, tumor deposits, angiolymphatic invasion, perineural invasion, and venous invasion between the CCPD and CCLM groups. A similar proportion of CCPD and CCLM demonstrated *KRAS* mutation (28% vs. 37%, $p=0.5$), *BRAF* mutation (19% vs. 13%, $p=0.5$), and MSI-H (8% vs. 10%, $p=0.8$).

Conclusions: Colorectal carcinoma with synchronous peritoneal dissemination (CCPD) demonstrates distinctly different tumor morphology with frequent mucinous and signet ring cell differentiation and high tumor grade compared to colorectal carcinoma with synchronous liver metastasis (CCLM). The association of mucinous and signet ring cell differentiation and peritoneal tumor dissemination suggests that mucinous and signet ring cell histology is an adverse histologic feature associated with increased risk for synchronous and possibly metachronous development of peritoneal dissemination.

811 LEF-1 Is Frequently Expressed Colorectal Carcinoma and Not in Other Gastrointestinal Tract Adenocarcinomas: An Immunohistochemical Survey of 602 Gastrointestinal Tract Neoplasms

T Reza Kermanshahi, RK Pai. University of Pittsburgh Medical Center, Pittsburgh, PA. **Background:** LEF-1 is a DNA-binding protein that interacts with β -catenin and activates *Wnt*-responsive target genes important in carcinogenesis. We investigated the immunohistochemical expression of LEF-1 in gastrointestinal (GI) tract epithelial neoplasia and performed a clinicopathologic and survival analysis of colorectal carcinoma (CRC) stratified by LEF-1 expression.

Design: Immunohistochemistry for LEF-1 (clone EPR2029Y, Epitomics, 1:10 dilution) was performed using tissue microarrays of 602 GI tract neoplasms including adenocarcinomas of colorectal (241), esophageal/esophagogastric (72), gastric (103),

pancreatic (109), and appendiceal (7) origin. 46 pancreatic intraductal papillary mucinous neoplasms (IPMN) and 24 pancreatic mucinous cystic neoplasms (MCN) were also included. LEF-1 was scored for intensity (0, absent staining; 1+, weak staining; 2+, strong staining) and percent of tumor cells staining. A modified H score (intensity \times percentage of positive cells) for LEF-1 was calculated with positive LEF-1 expression defined as >5 . LEF-1 in CRC was correlated with clinicopathologic features including grade, stage, location, and tumor histology; CK7, CK20, and CDX2 expression; *KRAS* and *BRAF* mutation; microsatellite instability (MSI); and survival.

Results: LEF-1 nuclear positivity was frequently identified in CRC (88/241, 37%, mean H-score 22). Weak, focal LEF-1 was rarely identified in other GI tract adenocarcinomas: 11% esophagus/esophagogastric, 7% gastric, 1% pancreatic, and 0% appendiceal. 4% of pancreatic IPMNs and no pancreatic MCNs were LEF-1 positive. LEF-1 positivity was seen in 6/17 (35%) CRC that lacked CK20 and CDX2 expression. LEF-1 positive CRC more frequently demonstrated *KRAS* mutation compared to LEF-1 negative CRC (39% vs. 16%, $p=0.005$). There was no statistically significant difference in LEF-1 expression and tumor grade, location, stage, *BRAF* mutation, MSI status, or histopathologic features. Patients with LEF-1 positive CRC with an H-score \geq 90 had a trend to worse overall survival compared to patients with CRC with a LEF-1 H-score <90 (5-year overall survival, 31% vs. 47%, $p=0.15$).

Conclusions: LEF-1 is frequently expressed in CRC and may be useful marker in distinguishing CRC from upper GI tract and pancreatic adenocarcinoma. Importantly, LEF-1 expression was identified in 35% of CRC that lacked CK20 and CDX2 expression. LEF-1 expression is associated with *KRAS* mutations in CRC. Strong LEF-1 expression is potentially a prognostic factor of poor survival in CRC.

812 Chromogenic *In Situ* Hybridization for Albumin Distinguishes Intrahepatic Cholangiocarcinoma from Non-Hepatic Neoplasms

TL Rice-Stitt, A Mubeen, M Shahid, M Rivera, D Ting, V Deshpande. Massachusetts General Hospital, Boston, MA.

Background: Intrahepatic cholangiocarcinoma (ICC), the second-most common primary liver malignancy, cannot be distinguished with certainty from metastatic adenocarcinoma based on histopathologic or immunohistochemical analysis. The current clinical paradigm for suspected ICC requires an exhaustive search for potential non-hepatic primary tumors. Additionally, recent expression profiling data suggests that biliary neoplasms are the most common origin of metastatic tumors of undetermined primary. We aimed to explore albumin's potential as a biomarker for ICC.

Design: We evaluated RNA expression of albumin in 69 ICCs, 42 hepatocellular carcinomas (HCC) and 351 non-hepatic carcinomas -- including known metastases to the liver and primary tumors of the extrahepatic biliary tract, pancreas, stomach, esophagus, colon, lung, breast, ovary, endometrium and urinary tract -- using a novel branch chain chromogenic *in situ* hybridization (CISH) platform (QuantiGene ViewRNA technology (Affymetrix; Santa Clara, CA)). The ICCs examined spanned a range of histologic grades (8 well-differentiated, 43 moderately-differentiated, and 18 poorly-differentiated).

Results: CISH for albumin provided a high signal to noise ratio. Albumin reactivity was noted in proliferating bile ductules as well as in normal hepatocytes, but not in native bile ducts. 66 of 69 ICCs (96%) and all 42 HCCs (100%) were positive for albumin. Histopathologic features allowed ICCs to be distinguished from HCCs. All perihilar and distal bile duct carcinomas as well as carcinomas arising from the other sites studied were negative for albumin. Figure 1 shows a positive albumin CISH in a poorly-differentiated ICC:

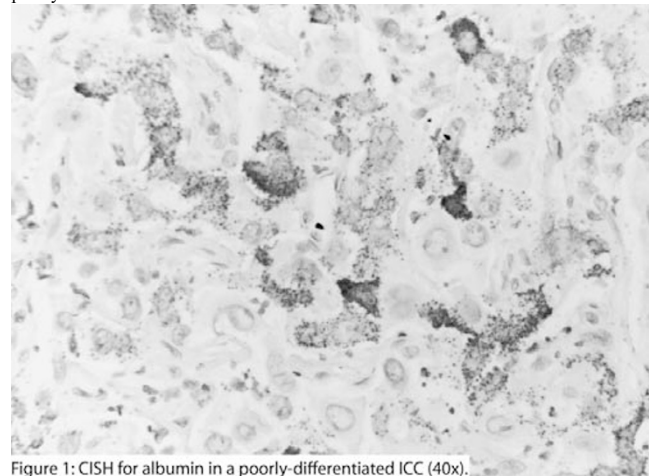


Figure 1: CISH for albumin in a poorly-differentiated ICC (40x).

Conclusions: Branch chain chromogenic *in situ* hybridization for albumin is a highly sensitive and specific marker of hepatocellular carcinoma and intrahepatic cholangiocarcinoma, and in conjunction with morphology a robust biomarker for ICCs.

813 The Utility of Phosphohistone H3 Immunostain in the Assessment of Mitotic Rate in Gastrointestinal Stromal Tumor of the Stomach

MP Riley, SM Voss, P Lokhandwala, Z Yang. Penn State Milton S. Hershey Medical Center, Hershey, PA.

Background: Risk assessment of gastrointestinal stromal tumor (GIST) is based on the size and mitotic rate as assessed in 50 high power fields (HPFs) or 5mm² (cutoff5), which requires significant time and is often considered very burdensome. Phosphohistone H3 (PHH3), a protein concentrated during chromatin condensation, has been shown to be a

specific marker for mitosis in several tumor types. This study aimed to assess the utility of PHH3 antibody in the assessment of mitotic rate in gastric GIST.

Design: Forty-nine cases (M/F=1, age 34-84, median 64) of gastric GIST were retrieved from the anatomic pathology archive. Immunostain for PHH3 was performed on representative tumor sections. Mitotic rate was assessed independently by four readers in 50 HPFs on both HE and PHH3 stains. In addition, the PHH3-labeled mitotic figure was also counted on highly-labeled, single low (10x) and intermediate (20x) power fields (hotspot) by the senior author. Statistical analysis was performed using MedCalc version 12.7.4.

Results: Based on the mitotic rate on HE, there were 33 low-grade and 16 high-grade tumors, and the mitotic rate ranged from 0 to 57 mitoses/5mm² (mean 7, median 2). The intra-class correlation on the raw mitotic count among the 4 readers was 0.94 (single measure). On PHH3 immunostain, the mitotic rate ranged from 0 to 151 / 5mm² (mean 15, median 6). There was statistically significant correlation between mitoses assessed on HE and PHH3 ($p < 0.0001$, $r = 0.76$). The mitotic rate as determined on PHH3 stain showed similar degree of intra-class correlation among the same 4 readers (single measure $k = 0.91$). In addition, there was excellent linear correlation between mitotic rates assessed in 50 HPFs and either single hotspot field (10x or 20x) on PHH3 immunostain ($p < 0.0001$, $r > 0.94$).

Conclusions: Mitotic rate assessed on PHH3 stain correlates with mitotic rate on HE and both show strong inter-observer reproducibility. There is excellent correlation between mitotic rates assessed in 50 HPFs and single hotspot field on PHH3 stain. Our data suggests that counting 50 HPFs may be replaced by counting just one hotspot on PHH3 stain, which will greatly facilitate the assessment of mitotic rate in GIST. Further investigation in a larger patient population with long-term follow-up is needed to validate its prognostic value.

814 The Utility of Phosphohistone H3 Immunostain in the Assessment of Mitotic Rate of Well-Differentiated Neuroendocrine Tumors in the Midgut

MP Riley, SM Voss, P Lokhandwala, Z Yang. Penn State Hershey Medical Center, Hershey, PA.

Background: The grading of well-differentiated neuroendocrine tumors (WDNET) of the midgut is based on either mitotic rate or Ki67 labeling index. The cutoff on mitosis is narrow (2 mitosis / 2mm²). Accurate assessment of the mitotic rate generally requires 50 high power fields (HPFs), which necessitates significant time and carries poor interobserver reproducibility. Phosphohistone H3 (PHH3), a protein concentrated in during chromatin condensation, has been shown to be a specific marker for mitosis in several tumor types. This study aimed to assess the utility of PHH3 antibody in the assessment of mitotic rate in WDNET of the midgut.

Design: Forty-six cases (M/F=1.1, age 39-88, median 61) of WDNET of the midgut were retrieved from the anatomic pathology archive. Immunostain for PHH3 was performed on representative tumor sections. Mitotic rate on both HE and PHH3 stains was assessed by four readers. In addition, the PHH3-labeled mitotic figure was also assessed on single low (10x) and intermediate power (20x) highly labeled fields (hotspot) by the senior author. Statistical analysis was performed using MedCalc version 12.7.4.

Results: Based on mitotic rate on HE, there were 42 G1 and 4 G2 tumors, and the mitotic rate ranged from 0 to 3.3 mitoses/2mm². The intraclass correlation among the 4 readers was 0.19 (single measure) based on the raw mitotic count. On PHH3 immunostain, the mitotic figures ranged from 0.1 to 7 / 2mm². There is a statistically significant correlation between mitoses assessed on HE and PHH3 ($p < 0.0001$, $r = 0.85$). PHH3 immunostain showed markedly improved intraclass correlation among 4 readers (single measure $k = 0.83$). In addition, there was excellent linear correlation between mitotic rates assessed on 50 HPFs and either single hotspot field on PHH3 immunostain ($r > 0.9$).

Conclusions: Mitotic rate assessed by PHH3 stain showed significant correlation with mitotic rate on HE, with much improved interobserver reproducibility. There is excellent correlation between mitotic rate assessed on 50 HPFs and a single hotspot on PHH3 stain, which will greatly ease the assessment of mitotic rate in midgut WDNETs. Further investigation in a larger patient population is needed to validate its prognostic value.

815 Calretinin Immunohistochemistry Can Reduce the Rate of Inconclusive Diagnoses in Rectal Biopsies for Hirschsprung's Disease

MAM Rodrigues, PLTA Lourenco, SA Terra, EVP Ortolan, BK Takegawa. Botucatu Medical School, São Paulo State University, Botucatu, Sao Paulo, Brazil.

Background: The gold standard for the diagnosis of Hirschsprung's disease (HD), which is a developmental disorder of the enteric nervous system, has been histopathological analysis of rectal suction biopsies. However, many difficulties occur during this evaluation. Inadequate biopsy samples and interpretative pitfalls are associated with high rates of inconclusive results. We investigated whether the introduction of calretinin immunohistochemistry (CR) in a diagnostic panel composed of acetylcholinesterase histochemistry (Ache) and hematoxylin and eosin (H&E) staining could decrease the rate of inconclusive results.

Design: We analyzed data from patients undergoing rectal biopsies before and after introduction of CR in the diagnostic workup for HD and determined the rate of biopsies without a conclusive diagnosis. The following diagnostic criteria were used for the HD diagnosis: absence of ganglion cells in H&E sections, positive reaction for Ache histochemistry in nerve fibers of the lamina propria and muscularis mucosa and absence of immunoreactivity for CR.

Results: Data from 82 patients were analyzed including 41 patients in each series. Inconclusive results were obtained in 17 of 45 rectal biopsies (37.8%) in the first series of cases, and 5 of 42 rectal biopsies (11.9%) were inconclusive in the second series of cases ($P < 0.006$).

Conclusions: The introduction of calretinin in the diagnostic workup for Hirschsprung's disease significantly reduced the rate of inconclusive results in rectal suction biopsies. Calretinin immunohistochemistry is a useful ancillary method, and its inclusion in the histopathological panel for HD biopsies may improve the diagnostic accuracy of HD.

816 Distinguishing Features of Sexually Transmitted Infectious Proctocolitis vs Inflammatory Bowel Disease: Clues from a Case Control Study

RM Roth, L Voltaggio, EA Montgomery, C Arnold. Ohio State University Wexner Medical Center, Columbus, OH; George Washington University, Washington, DC; Johns Hopkins Hospital, Baltimore, MD.

Background: We recently reported histomorphologic findings in syphilitic and lymphogranuloma venereum (LGV) proctocolitis ("STI proctocolitis") and found overlap with inflammatory bowel disease (IBD). Herein, we compared clinicopathologic features of STI proctocolitis versus IBD.

Design: The STI proctocolitis group included 8 colorectal biopsies from 8 men (median age=43 years) with clinically confirmed STI (syphilis=5, LGV=1, both=2); all patients responded to antibiotics. The IBD control group included site, age, sex, and race matched patients with Crohn disease (CD=8) or ulcerative colitis (UC=8). The IBD inclusion criteria were an established IBD history (average length of follow-up=102 months), active chronic colitis, and a lack of immunosuppressive therapy at time of biopsy. Pertinent clinicopathologic features were recorded and analyzed by chi-square and Fisher exact tests.

Results: Statistically significant parameters included the following ($p < 0.05$). STI colitis was exclusively identified in HIV+ men who have sex with men (MSM) and almost all presented with pain. Histologically, STI proctocolitis featured intense mononuclear inflammation without prominent crypt-centric damage, architectural distortion, crypt shortfall, basal lymphoplasmacytosis, crypt drop-out, and eosinophilia (>25 eosinophils/HPF was exclusive to IBD). Although plasma cells were the predominant inflammatory cell in the mucosa of both STI colitis and IBD, only STI proctocolitis featured plasma cell rich submucosal inflammation (IBD featured lymphohistiocytic-rich submucosal inflammation). Overlapping features lacking statistical significance included rectal bleeding, endoscopic impressions, aphthoid lesions, granulomata, foreign body giant cells, neural hyperplasia, fibrosis, Paneth cell metaplasia, and lymphoid aggregates.

Conclusions: Important discriminating clues to the diagnosis of STI proctocolitis include a history of HIV+ MSM, pain, intense mononuclear lamina propria expansion with submucosal plasma cell rich infiltrate without prominent active crypt-centric damage, architectural distortion, and mucosal eosinophilia. Based on a marked overlap with features traditionally ascribed to IBD (aphthoid lesions, granulomata, fibrosis, lymphoid aggregates, and Paneth cell metaplasia), awareness of STI proctocolitis is essential to avoid the diagnostic pitfall of IBD and to ensure appropriate management of this curable IBD mimic.

817 BRAF Immunostain in 55 Colon Cancer Cases: Small Cores Are as Useful as Whole Sections

RM Roth, H Hampel, CA Arnold, W Marsh, MM Yearsley, WL Frankel. The Ohio State University Wexner Medical Center, Columbus, OH.

Background: Efficient and reliable assessment of *BRAF* mutation status is becoming more important for several tumors, including colorectal carcinomas (CRC). *BRAF* is an oncogene, and mutations most commonly involve a substitution of valine by glutamic acid at position 600 (V600E) of codon 15. *BRAF* mutations are found in approximately 10% of CRCs and are frequently associated with sporadic microsatellite unstable CRCs, usually occurring due to epigenetic inactivation of the *MLH1* mismatch repair gene rather than germline mutations. *BRAF* mutation essentially excludes Lynch Syndrome and may be associated with poorer response to certain chemotherapeutic agents. We compared *BRAF* immunohistochemistry (IHC) in CRC resection specimens with known *BRAF* mutation status to small core sections to determine the utility of staining in biopsies.

Design: CRC cases diagnosed from 2009 to 2013 with absence of *MLH1* and *PMS2* as well as prior *BRAF* V600E mutation testing by PCR were chosen (57 cases). To mimic small biopsies, tissue microarrays (TMA) with 1-mm cores in duplicate were constructed. IHC for *BRAF* (VE1 clone, 1:900) was performed on TMA and whole section (WS) slides. Cytoplasmic staining was graded as positive or negative, with a 5% threshold. The molecular mutation status was compared with *BRAF* staining on the TMA and WS.

Results: Adequate tumor was available in WS and TMA from 55 cases. All cases showed the same IHC results in TMA and WS. Of the 55 cases, 4 (7%) showed discordance between IHC and mutation. All discordant cases had a negative IHC with a positive mutation. Of the discordant cases, 2 were from women (ages 51, 86) and 2 were from men (ages 63, 70). The sensitivity of IHC for *BRAF* mutation was 88%, and the specificity was 100%.

Comparison of BRAF IHC versus Molecular Status

	Mutation Pos	Mutation Neg
IHC Pos	28/32 (88%)	0/23 (0%)
IHC Neg	4/32 (12%)	23/23 (100%)

Conclusions: Staining results between TMA and WS were concordant, suggesting biopsies are as useful as WS for assessing *BRAF* IHC. Additional molecular analysis is suggested in cases with either negative *BRAF* IHC or molecular results to further evaluate for Lynch Syndrome or *MLH1* promoter hypermethylation. Although IHC is faster and less expensive compared to *BRAF* molecular mutation testing, incorporation of *BRAF* IHC into the screening algorithm would lead to slightly greater numbers of patients needing additional molecular testing. Cost-benefit analyses are ongoing to determine which is more advantageous.

818 Microsatellite Unstable Neuroendocrine Carcinomas (NECS) Are a Distinct Clinico-Pathologic Category of NECS in the Gastroenteropancreatic System

N Sahlane, M Monti, D Furlan, E Vicari, A Vanoli, C Capella, E Solcia, F Sessa, S La Rosa. University of Insubria, Varese, Italy; University of Pavia, Pavia, Italy; Ospedale di Circolo, Varese, Italy.

Background: Gastroenteropancreatic neuroendocrine carcinomas (GEP-NECs) are heterogeneous neoplasms mainly characterized by poor outcome. Recently, microsatellite instability (MSI) has been found in colorectal NECs showing a better prognosis than expected. However, the frequency of MSI phenotype in a large series of GEP-NECs is still unknown. The aim of this work was to investigate the incidence of MSI in GEP-NECs and to characterize their clinico-pathologic and molecular features. **Design:** The tumor series included 89 GEP-NECs (6 oesophagus, 36 stomach, 4 duodenum, 37 colon-rectum, 3 pancreas and 3 gallbladder). MSI analysis and immunohistochemistry for mismatch repair proteins (MLH1, MSH2, MSH6, and PMS2) and CD117 were performed. Methylation of 34 genes and copy number alteration (CNA) of 50 chromosomal regions were studied by MS-MLPA. LINE1 methylation and hotspot mutation analyses of *BRAF* and *KRAS* genes were assessed by PCR-pyrosequencing. **Results:** MSI was observed in 11 NECs (12.4%): 7 intestinal and 4 gastric. All but two MSI-NECs showed MLH1 methylation and loss of MLH1 protein. The remaining two MSI-NECs showed lack of MSH2 or PMS2 immunohistochemical expression. MSI-NECs showed higher levels of gene hypermethylation compared to microsatellite stable (MSS) NECs (40.6% versus 20.2% methylated genes, respectively; $p < 0.003$) suggesting a CpG Island Methylator Phenotype (CIMP) in these tumors. LINE1 hypomethylation was observed in 39 NECs and was inversely correlated with MSI ($p = 0.04$). *BRAF* mutation was detected in six out of 88 cases (7%) and *KRAS* mutation was identified in 15 cases (17%). The presence of *BRAF* mutation was associated with MSI ($p < 0.0008$) while *KRAS* status did not correlate with any clinico-pathologic or molecular feature. CNA levels were lower in MSI compared to MSS group ($p < 0.008$). Univariate survival analyses using all molecular variables identified MSI status and MLH1 methylation as positive prognostic factors ($p = 0.0048$ and $p = 0.002$ respectively). None of the 11 MSI-NECs showed CD117 immunoreactivity, that was observed in 28/48 (58%) MSS-NECs ($p = 0.014$).

Conclusions: Microsatellite instability identifies a subset of gastric and intestinal NECs with distinct biology and better prognosis.

819 RNA In Situ Hybridization as a Surrogate Marker of LINE-1 Methylation

D Sajed, J Bledsoe, K Arora, M Mino-Kenudson, D Ting, V Deshpande. Massachusetts General Hospital, Boston, MA.

Background: Long interspersed nuclear element-1 (LINE-1) is a retrotransposon that accounts for approximately 17% of the human genome. Loss of methylation of LINE-1 is believed to account for much of the genomic hypomethylation observed in human cancer, and serves as a surrogate marker for global methylation status. Epigenetic alterations such as global DNA hypomethylation as well as CpG island hypermethylation are common events in colon cancer. LINE-1 methylation status has been correlated with response to chemotherapy, microsatellite instability, as well as survival in colon cancer. Some controversy remains, however, as studies are not always consistent in their results. We propose to assess LINE-1 RNA by in situ hybridization in colonic cancer as a marker of LINE-1 methylation, as well as a surrogate for global genome methylation. **Design:** In situ hybridization (ISH) using an RNA probe aligned to the open reading frame 1 of LINE-1 was performed on tissue microarrays representing 161 colonic adenocarcinomas and 18 samples of normal colonic mucosa. ISH was performed using the QuantiGene® ViewRNA technology (Affymetrix, Santa Clara, CA) and scored as follows: 1 = absent or minimal nuclear staining, 2 = moderate intensity with partial nuclear staining, 3 = strong reactivity of entire nucleus. Normal colonic mucosa, tumor mucosa, and tumor stroma were independently scored. Microsatellite instability (MSI) status was assessed by immunohistochemistry for MLH1, PMS2, MSH6 and MSH2. *BRAF* mutational status was determined by PCR as part of the clinical workup.

Results: The mean age of the cohort was 62 years. Increased LINE-1 RNA was associated with *BRAF* mutation ($p = 0.09$) and male sex ($p = 0.05$). No correlation was found between the intensity of LINE-1 reactivity and MSI status, age, TNM status, or site of tumor. Tumor stroma and normal colonic mucosa showed significantly less LINE-1 staining (mean scores = 1, $p < 0.001$).

Conclusions: Colorectal carcinomas are associated with a significant increase in LINE-1 RNA expression indicative of global LINE-1 hypomethylation status. We identified a direct relationship between LINE-1 expression and the presence of *BRAF* mutation. We propose that LINE-1 in situ hybridization may provide a more robust assessment of the methylation status of LINE-1 as well as an assay of global cellular methylation, by avoiding the pitfalls associated with current methylation assays including the presence of contaminating stromal tissue.

820 Squamous Morules/Microcarcinoids in Gastroesophageal Polyps; a Mimicker of Invasive Carcinoma

SN Salaria, E Montgomery. Vanderbilt University, Nashville, TN; The Johns Hopkins University, Baltimore, MD.

Background: Colorectal lesions termed microcarcinoids (MC) display squamous and endocrine differentiation in varying proportions and are often found in adenomas with high grade dysplasia thus mimicking invasion. Herein, we describe histopathologic, immunohistochemical classification and clinical correlation of analogous lesions in the esophagus and stomach.

Design: We prospectively identified five cases (3 men, 2 women) from November 2004-March 2013 of gastric and gastroesophageal polypectomies with associated MCs.

Results: Four of the patients were white. The median age was 70 years (range 59–85 years). Two patients presented with gastrointestinal bleeding, 1 was undergoing routine screening, and 2 patients were followed up for Barrett esophagus (BE) and a history of gastric polyps respectively. Three lesions were gastric, one gastroesophageal (GE), and one patient had both GE and proximal gastric lesions. Four patients had multiple polyps; one had a 2.5 cm polypoid GE lesion. The median size of the polyps was 1.5 cm. All of the gastric MCs occurred in hyperplastic polyps (HP) (one patient had separate fundic gland polyps in addition). Two HPs showed high grade dysplasia, 1 low grade dysplasia, and 1 erosions and reactive changes. One of the GE lesions was associated with polypoid papillary high grade dysplasia arising in BE, this patient had follow up biopsy 1 month later showing BE with features indefinite for dysplasia. He died in 2009 (5 years) of unknown cause. The remaining patients are alive. The MCs ranged in size from 1-3 mm. They were multifocal showing a lobular growth pattern connecting directly to the dysplastic epithelium. Four of MCs demonstrated pseudolumina. Immunohistochemical analysis was done on 4 cases. All 4 four showed nuclear beta catenin and a low Ki67 index ($< 2\%$). Endocrine markers (synaptophysin, chromogranin) were expressed in all of the lesions, and P63 showed focal labeling in one lesion.

Conclusions: The histopathological features and immunohistochemical labeling of GE MCs are almost identical to those previously described in the colorectum. GE MCs can be associated with reactive processes and more frequently in a background of dysplasia. Under-recognition of upper gastrointestinal MCs provides potential for over-diagnosis of invasive carcinoma. Familiarity with the histopathologic pattern and immunoprofile can aid in avoiding this pitfall.

821 Gastric Amyloidosis: Clinicopathologic Correlations and Mass Spectrometry (MS) Typing in 43 Cases from a Single Institution

SM Said, KL Grogg, TC Smyrk. Mayo Clinic, Rochester, MN.

Background: Amyloidosis is characterized by extracellular accumulation of Congo-red positive fibrillary deposits. Gastrointestinal involvement by amyloidosis is common.

Design: Forty-three patients (pts) with biopsy (bx)-proven, MS-typed gastric amyloidosis were identified by a retrospective review of our pathology archives, from 2007 to 2013.

Results: The mean age at diagnosis was 60 years (range 36–86). Sixty-five percent of pts were male. AL amyloidosis (AL) was seen in 28 (65%) pts (lambda in 19, and kappa in 9), transthyretin amyloidosis (ATTR) in 10 (23%), AA amyloidosis (AA) in 4 (9%), and AApoA1 in 1 (2%). The amyloidosis was systemic in all pts. Other GI tract sites with bx-proven amyloid were small bowel in 30 of 36 (83%) pts biopsied, colon in 14 of 19 (74%), and esophagus in 6 of 15 (40%). Other organs involved were heart in 67% of pts, kidney in 44%, liver in 26%, nerve in 26%, lung in 5% and gallbladder in 5%. Bone marrow (BM) bx confirmed plasma cell proliferative disorder in 25 of the 28 (89%) pts with gastric AL, and was positive for amyloid in 20 (71%) pts. BM bx was also done in 5 additional pts (3 ATTR, and 2 AA) and showed amyloid deposits in 2 (1 ATTR, and 1 AA) but was negative for plasma cell proliferative disorder. Fat pad bx was positive for amyloid in 27 of 38 (71%) pts tested (20 AL, 6 ATTR, and 1 AA). The most common GI manifestations of amyloidosis were weight loss 42%, abdominal pain/dyspepsia 19%, nausea/vomiting 16%, dysphasia 16%, and diarrhea 16%. Endoscopic findings were not amyloid type-specific and included normal 40%, erythema 28%, erosions 16%, hernia 14%, and nodularity 12%. Additional bx findings included gastritis in 44%, reactive gastropathy in 23%, and intestinal metaplasia in 14%. No case showed associated gastric lymphoma. In 7 pts, the first diagnosis of amyloid was based on the gastric bx. After a median follow up of 15 months (range 0.2–75), mortality from all causes was 26% and was higher in pts with AL 32%, than in those with ATTR 20% or AA 0%.

Conclusions: AL is the most common form of gastric amyloidosis, followed by ATTR. Concurrent small and/or large bowel involvement is present in the majority of pts, while esophageal involvement is present in less than half. Clinical symptoms are diverse and endoscopic findings are nonspecific or normal. There is no association between gastric amyloidosis and MALT lymphoma of the stomach, contrary to MALT lymphoma of other sites. Type of amyloid cannot be predicted based on endoscopic findings and therefore amyloid typing, preferably by MS, is critical for prognosis and treatment.

822 Anti-Secretory Medication Use Is Associated with Decreased Morphologic Detection of *Helicobacter pylori* in Gastric Marginal Zone Lymphoma

KB Schaberg, Z Peng, MF Evans, R Wilcox, MR Lewis. Stanford University, Palo Alto, CA; University of Vermont, Burlington, VT.

Background: *Helicobacter pylori* infection is demonstrable in up to 90% of cases of gastric involvement by extranodal marginal zone lymphoma of mucosa-associated lymphoid tissue (MALT lymphoma). As *H. pylori* status influences the prognosis and the selection of therapy for gastric MALT lymphomas, ensuring accurate determination of *H. pylori* status is of clinical importance. Identification of a comparatively low rate of morphologic positivity for *H. pylori* among gastric MALT lymphoma cases at our institution prompted investigation of the clinical and pathologic features of our patients' cases.

Design: 24 patients (ages 36–90; 9 F, 15 M) were diagnosed with gastric MALT lymphoma with no diffuse large B-cell lymphoma component between 1997 and 2010. Clinical records were reviewed for results of prior testing for *H. pylori*, details of gastric biopsy procurement, and cancer stage. Immunohistochemical (IHC) staining for *H. pylori* and BCL10 was performed, as nuclear localization of BCL10 is more frequently seen in MALT lymphomas that do not respond to *H. pylori* eradication. A patient was considered to be *H. pylori*-positive if serology and/or IHC was positive.

Results: 39% of cases (9/23) were *H. pylori*-positive by IHC, including one case in which the original IHC was negative. Four patients with negative IHC had positive serologic testing results; overall, 57% of cases (13/23) were positive for *H. pylori*.

Treatment with anti-secretory medications (e.g., proton pump inhibitors) was associated with a lower likelihood of histologic/IHC positivity for *H. pylori* (11% among the treated vs. 75% of untreated; $p=0.015$). Nuclear localization of BCL10 (with weak staining) was seen in only two cases (one *H. pylori*-negative, one positive) and was not associated with *H. pylori* status. *H. pylori*-negative cases consistently involved the proximal stomach. **Conclusions:** The rate of *H. pylori* infection among gastric MALT lymphoma patients at our institution is considerably lower than that seen in published reports, even after inclusion of serologic data. Use of anti-secretory medications is associated with a decreased likelihood of morphologic detection of *H. pylori* in cases of gastric MALT lymphoma. Incorporation of results of serologic or other testing is needed to ensure correct classification with respect to *H. pylori* status, which is necessary for selection of appropriate therapeutic modalities.

823 Negative Colorectal Polyp Biopsies: The Utility of Cutting Deeper Levels

BA Schick, CA McLean, DK Driman. London Health Sciences Centre and Western University, London, ON, Canada.

Background: Microscopic examination of colorectal biopsies from lesions identified endoscopically as polyps sometimes fail to identify an abnormality on initial routine sections, but a polyp may be found if deeper levels are cut from the tissue block. The objective of this study was to determine the frequency with which deeper levels reveal a lesion, where none was found initially, and to identify clinical, endoscopic, and/or pathologic features that predict occult lesions.

Design: All "polyp" biopsy specimens where no polyp was identified on the initial, standard sections were consecutively accumulated over an 18-month period, from the practice of two pathologists. Standard sections included preparation, from one block, of three slides, each with two serial sections, with each pair of serial sections cut at deeper levels, 50 μ m apart. In each case where no polyp was identified initially, three to ten additional levels were cut, 50 μ m apart. The presence of any lesion, the level at which it was found, the location, number and size of fragments, number of levels obtained, presence of any lymphoid aggregate, endoscopic size and appearance, and bowel preparation quality were recorded.

Results: There were 214 specimens accrued from 203 patients (104 females, 99 males). The mean age was 61.4 years (range 27-86 years). Deeper levels revealed a lesion in 52/214 (24.3%) cases; of these, 40 (76.9%) were tubular adenomas (TA), 11 (21.2%) were hyperplastic polyps (HP), and 1 was a leiomyoma. All TAs were negative for high-grade dysplasia and malignancy. The mean level at which the TAs were found was 4.85 (range 4-12). Male sex ($p=0.021$) and right-sided location ($p=0.0075$) were statistically significant predictors of an occult TA. The presence of a prominent lymphoid aggregate was predictive of a negative biopsy ($p=0.097$). Endoscopic size, endoscopic appearance, and bowel preparation quality were not predictors of deeper lesions, but were unknown in 48.1%, 82.7%, and 52.8% of all cases, respectively.

Conclusions: Despite cutting three levels from the block initially, in approximately one-quarter of negative cases, deeper levels revealed a lesion, the majority of which were adenomas. As the presence of an adenoma affects subsequent colonoscopic screening of average-risk individuals, pathologists should consider "pursuing" polyps when initial sections reveal no lesion. Individual pathology laboratories should consider ascertaining their own incidence of occult lesions on initially non-diagnostic colorectal biopsies, as histotechnologist practices may vary.

824 Gastrointestinal Basidiobolomycosis Mimicking Malignancy: A Novel Diagnostic Approach

DK Seaquist, JL Pugh, VN Nfonso. University of Arizona Medical Center, Tucson, AZ. **Background:** Basidiobolomycosis (Basidiobolus ranarum) is a rare emerging fungal infection. Most infections involve the subcutaneous tissues of the trunk and arms. Recently, gastrointestinal basidiobolomycosis has been reported in the Southwestern U.S. Patients with gastrointestinal basidiobolomycosis have nonspecific symptoms and diagnosis is usually made following surgical resection for suspected malignancy. We present a case using a novel method for diagnosis, thereby avoiding unnecessary surgical intervention.

Design: A 56 year-old man from AZ with Type 2 DM and previously normal colonoscopy presented with increased nonbloody stools of 5 months duration. The patient also developed rectal pain, bladder outlet obstruction, night sweats and weight loss. Lab evaluation showed leukocytosis with eosinophilia. A CT scan showed a cecal mass and large rectosigmoid mass with anterior displacement of the bladder. Flexible sigmoidoscopy showed a circumferential mass 25 cm from the anal verge. Luminal biopsies showed marked mucosal eosinophilia with no organisms, dysplasia or malignancy. Fungal stains were negative. An MRI revealed extension of the rectosigmoid mass into soft tissues, seminal vesicles, prostate and presacral space. The circumferential cecal mass was also suspicious for carcinoma and superficial and deep lymphadenopathy was present. The patient underwent a CT-guided biopsy of the rectal mass.

Results: Examination of the core needle biopsy revealed fungal organisms, morphologically consistent with basidiobolomycosis, on routine and Gomori methanamine silver stained slides. The fungal hyphae are irregularly branched, thin-walled, occasionally septated and occasionally cuffed by eosinophils (Splendore-Hoeppli phenomenon). The patient was started on oral itraconazole with rapid resolution of his urinary symptoms and improvement in bowel habits. He was discharged to home 3 days later. Follow up at 1 week and 4 months after discharge showed continued improvement. He had no complaints of abdominal or rectal pain, bowel movements had decreased in frequency and he had gained 5 pounds.

Conclusions: Gastrointestinal basidiobolomycosis is an emerging fungal infection in the Southwest U.S. In previously reported cases, diagnosis is often made from the surgical resection specimen. In a patient with findings suspicious for fungal infection, we suggest

a less invasive percutaneous CT-guided needle biopsy for diagnosis. This procedure allows accurate diagnosis with immediate treatment and minimal patient morbidity.

825 Colonic Mucosal Mast Cell Density in Patients with Diarrhea-Predominant Irritable Bowel Syndrome and Mast Cell Activation Syndrome: Implications for Clinical Practice

GJ Sepehr, MJ Hamilton, JL Hornick. Brigham and Women's Hospital, Boston, MA.

Background: Irritable bowel syndrome (IBS) is a relatively common, functional disorder that is characterized by lower abdominal pain and chronic diarrhea. Some studies have suggested that mast cells (MC) are involved in the pathogenesis of diarrhea-predominant IBS. "Mastocytic enterocolitis" has been proposed to describe a subset of chronic diarrhea patients with increased mucosal MC who respond to anti-MC mediator medications. However, the baseline MC density in colonic biopsies from normal patients has not been established in large cohorts; thus, there is no accepted threshold for what constitutes increased mucosal MC. "Mast cell activation syndrome" (MCAS) is a recently described disorder defined by clinical criteria (including IBS-like symptoms), evidence of MC mediator release, and responses to anti-MC mediator therapy. The aims of this study were to determine MC density in normal colonic mucosa from a large patient cohort and to compare these findings to patients with diarrhea-predominant IBS and MCAS.

Design: Study groups included 100 asymptomatic patients undergoing screening colonoscopy (controls), 100 patients with diarrhea-predominant IBS, and 10 patients with well-defined MCAS. All biopsies were histologically unremarkable. Immunohistochemistry was performed using an anti-KIT polyclonal antibody. MC density was determined by counting KIT-positive cells per high power field (HPF) (field size 0.25 mm²); mean MC count per 5 HPF was calculated. Student's *t*-test and Fisher exact test were used; $P < 0.05$ was considered significant.

Results: All biopsies contained singly dispersed MC with no aggregates. Mean MC counts for control patients, IBS patients, and MCAS patients were 19 (range 7-39), 23 (range 9-45), and 20 (range 12-31), respectively (controls vs IBS, $P < 0.001$; controls vs MCAS, NS). If a cut-off of 25 MC (1 standard deviation above the mean for controls) was considered "increased", 15% of normal, 38% of IBS, and 30% of MCAS patients would qualify (controls vs IBS, $P < 0.001$; controls vs MCAS, NS).

Conclusions: MC density in colonic mucosa is highly variable among asymptomatic patients. Although patients with diarrhea-predominant IBS on average have mildly increased mucosal MC, the overlap in range with that of control patients is likely too great for clinical application. MC density in patients with MCAS is not increased. These findings argue against the utility of routine MC enumeration in patients with chronic diarrhea.

826 A New Regression Grading Proposal for Neoadjuvant-Treated Colorectal Cancer: The Regression Scale

S Serra, P Gill, LM Wang, R Chetty. University Health Network, Toronto, Canada; John Radcliffe Hospital, Oxford, United Kingdom.

Background: The aim of the study was to evaluate the level of concordance among gastrointestinal pathologists using a new regression grading system.

Design: An international study group proposed that colorectal cancer regression of the entire tumor bed be assessed by using a composite scoring system:

Each slide/section from the tumour bed should be assessed and given a score as per the following criteria:

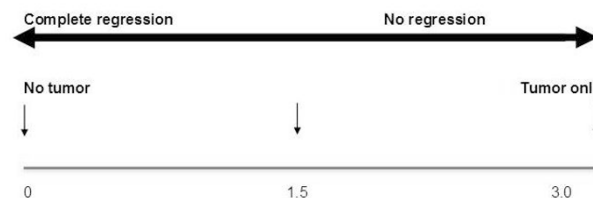
Score 0: complete pathological regression (no tumour present)

Score 1: little tumour present

Score 2: tumour and regression changes/ fibrosis in approximately equal proportion.

Score 3: tumour dominates the slide or no regression

The individual slide scores are added and the sum divided by the total number of slides (a minimum of 5) from the tumor bed. This yields an average score (a cumulative or composite score) that is reflective of the status of the entire tumor bed.



The minimum score per slide is 0 and the maximum 3. Similarly, when a final cumulative score is obtained for a case, the score will lie on a regression scale from 0 to 3. Five to 6 representative slides were selected from 6 cases of colorectal cancer treated with long-course neoadjuvant chemoradiation. The slides were scanned with a whole-slide scanner generating dynamic digitized images. The slides were scored at two separate times and intra-observer and inter-observer variability using Kendall's coefficient of concordance (KCC) were calculated.

Results: The overall (KCC) Kendall's Coefficient of Concordance for first round was 0.939571 ($p=0.0000$). KCC for second round was 0.914579 ($p=0.0000$).

Conclusions: Although the exact additive numerical score between pathologists in each slide of each case resulted in poor *k* stats (largely due to technical issues with the scanned slides and minor variation of figures), the overall level of concordance as measured by the KCC was excellent because of close placement of the case on the regression scale. The advantages of this system is that it allows for objective assessment of the entire tumor bed and provides a numerical value that can be plotted on a scale indicating the degree of regression thus providing the oncologist with an overall assessment of the tumor bed.

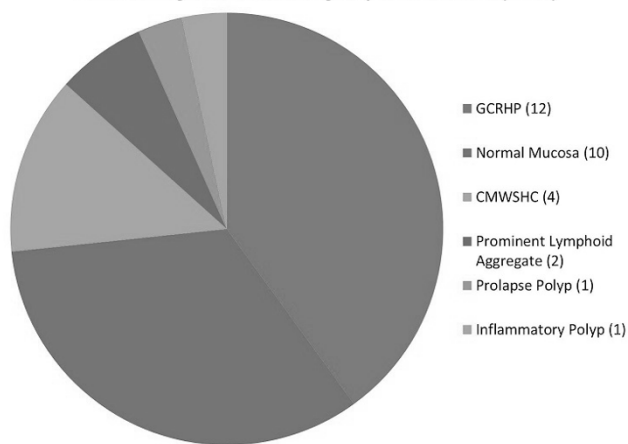
827 Goblet Cell Rich Hyperplastic Polyps Are Misinterpreted as Colonic Mucosa with Surface Hyperplastic Change

A Sethi, JA Hanson. University of New Mexico School of Medicine, Albuquerque, NM. **Background:** Because serrated polyposis syndrome is a phenotypically diverse disease in which clinical criteria depend heavily on polyp counts, pathologists should classify serrated polyps as hyperplastic, sessile serrated, or traditional serrated to ensure a proper accounting of a patient's serrated lesions. An equivocal diagnosis often rendered as *colonic mucosa with surface hyperplastic change* (CMWSHC) should be avoided when possible because it is unclear how clinicians will interpret this result. We hypothesize that many polyps called CMWSHC are goblet cell rich hyperplastic polyps (GCRHPs) which can be subtle and are probably underrecognized. This has not been systematically studied.

Design: We examined 160 clinically apparent polyps that lacked a definitive lesion as interpreted by pathologists with subspecialty interests in areas other than GI pathology. These cases were diagnosed as normal mucosa (126), mucosa with prominent lymphoid aggregate (4), and CMWSHC (30). A GI pathologist reviewed all cases for features of GCRHPs and was blinded to the original diagnosis, polyp location, and polyp size. Previously published criteria for GCRHPs were strictly followed: 1) serration limited to the luminal third of crypts, 2) thickened mucosa with increased goblet cells, 3) basement membrane thickening, 4) mucin present exclusively in the form of goblet cells, 5) absent nuclear stratification, atypia, and mitoses.

Results: Of the 160 cases, 14 (9%) were reclassified as GCRHPs and 12 (86%) of these had an original diagnosis of CMWSHC. The other 2 were originally diagnosed as normal mucosa. 40% (12/30) of CMWSHC diagnoses were reclassified as GCRHPs. After review and consistent with non-microscopic criteria for GCRHPs, all GCRHPs were found to be taken from the left colon and measured less than 5 mm (avg. 2.9 mm, range 1-4 mm). All reviewed diagnoses of the cases originally called CMWSHC are presented in the following figure.

Reviewed Diagnoses for Cases Originally Called CMWSHC (n = 30)



Conclusions: Some GCRHPs are subtle lesions that are underdiagnosed as CMWSHC. Before invoking this diagnosis, one should examine the polyp for the histologic criteria of GCRHP which, if met, should result in an unequivocal diagnosis of hyperplastic polyp. This will ensure a more consistent accounting of a patient's serrated lesions.

828 Clinicopathologic Significance of Macrocytic Change in Esophageal Adenocarcinoma

N Setia, A Agoston, J Shen, M Tippawong, R Bueno, Y Zheng, RD Odze, A Srivastava. Baystate Medical Center/Tufts University (Western campus), Springfield, MA; Brigham and Women's Hospital, Boston, MA; Bangkok Hospital Phuket, Muang, Phuket, Thailand.

Background: Cystic change has been described in adenocarcinomas of various anatomic sites, including pancreas, lung, cervix and prostate. A distinctive macrocytic variant has not been described in esophageal adenocarcinoma (EAC). In this study, we screened a large consecutive cohort of primary EAC for macrocytic change and analyzed its clinical and pathologic significance.

Design: 203 resections for EAC, without neoadjuvant therapy, were evaluated for tumors with macrocytic change, defined as invasive tumor with cystically dilated glands with, at least focally, attenuated luminal lining epithelium with or without intraluminal necrosis. The percentage of tumor exhibiting macrocytic change, presence of other high grade histologic features (lympho-vascular invasion, perineural invasion, single cell infiltration, high grade nuclei, micropapillary differentiation and conventional EAC component), and pathologic T and N stage were recorded. Patient demographic and outcome data were obtained by medical chart review. 11/203 (5.4%) cases [M:F:7:4; mean age 63 yrs (range 46-77 yr)] showed foci of macrocytic change involving <10% →>90% of the tumor mass. A predominant (>90%) macrocytic component was present in 2 cases. Mean tumor size was 3.8 cm (range 1.1-10.0 cm).

Results: Morphologic patterns present in conjunction with macrocytic change included single cells in 5 (45%), a conventional EAC component in 3 (27%) and micropapillary differentiation in 2 (18%) cases. EAC with macrocytic change tended towards a lower N stage compared to conventional EAC (p=0.0576). Survival analysis, after adjusting for T and N stage, showed conventional EAC to have a significantly higher mortality

hazard ratio (HR = 2.32, 90% CI = [1.07, 5.02]). The two tumors with a predominant (>90%) macrocytic component, lacked single cells and a conventional EAC component, and were both T1b lesions without nodal metastasis.

Conclusions: EAC with predominant (>90%) macrocytic change may represent a distinctive morphologic variant associated with early stage disease and better survival. Its independent prognostic value needs to be determined in future studies.

829 Primary Leiomyosarcoma of the Stomach: A Clinicopathologic, Immunohistochemical, and Molecular Genetic Study of 10 Cases

SS Shah, VS Chandan. Mayo Clinic, Rochester, MN.

Background: Primary leiomyosarcomas of the stomach are very rare, as the vast majority of the gastric mesenchymal tumors are gastrointestinal stromal tumors (GISTs). There are only 6 isolated case reports of primary gastric leiomyosarcomas. Hence, there is limited clinicopathologic data on this distinct tumor of the stomach.

Design: In this study we identified 10 cases of primary gastric leiomyosarcomas from our institutional and consultation files. None of the patients had a prior history of leiomyosarcoma. Clinical, histologic and immunohistochemical features were reviewed for all cases. Additionally, mutations of KIT exons 8, 9, 11, 13 and 17 and PDGFRA exons 12, 14 and 18 were analyzed in all cases.

Results: The patients included 5 men and 5 women with a mean age of 64 years (range: 47-84 years). The most common presenting symptom was upper abdominal pain/discomfort (n=8) followed by hematemesis (n=2). The average tumor size was 11.1 cm (range 1.8-22 cm) and all the tumors were located in the fundic region. Morphologically, all tumors were composed of spindle cells with eosinophilic cytoplasm and various degrees of nuclear atypia and pleomorphism. 3 patients had liver metastasis, of which 2 presented at the time of initial diagnosis. Follow up was available in 6 patients. 5 patients died, 4 of which were disease related deaths (mean survival 36 months, range 12 to 58 months). 1 patient was alive at 1 year after diagnosis with no further follow up.

Histopathologic Features

Degree of atypia	1 mild, 7 moderate and 2 severe
Tumor necrosis	7/10
Overlying surface ulceration	3/10
Origin of tumor	10 from muscularis propria
Tumor interface	4 infiltrative and 6 pushing
Perinuclear vacuoles	3/10
Cytoplasmic globules	1/10
Mitotic index (per 50 hpf)	Range 10-72 (mean 40)

Immunohistochemical and Molecular Features

S100	0/10
CD34	0/10
CD117	0/10
Smooth Muscle Actin	10/10 (100%)
Desmin	8/10 (80%)
Estrogen Receptor	0/10
DOG1	0/10
EBV in-situ hybridization	0/10
KIT and PDGFR gene mutation analysis	0/10

Conclusions: Primary leiomyosarcomas of the stomach are extremely rare. These tumors have distinctive clinicopathologic features and exhibit aggressive biological behavior.

830 The Role of Eosinophils and Neuroendocrine Cell Nests in the Assessment of Gastrointestinal Biopsies in Bone Marrow Transplant Patients

MJ Shealy, GG de Ridder, SJ McCall, CD Guy, X Zhang, DM Cardona. Duke Medical Center, Durham, NC.

Background: Acute graft-versus-host disease (aGVHD) of the gastrointestinal (GI) tract following bone marrow transplant (BMT) is a common complication associated with significant morbidity and mortality. Accurate diagnosis with exclusion of histologic and clinical mimics is crucial. In addition to apoptosis and crypt injury, historically the presence of eosinophils and neuroendocrine cell sparing was felt to be an indicator of aGVHD. However, recent literature suggests tissue eosinophilia is specific for mycophenolate mofetil (MMF) colitis. The aim of this study is to assess these claims.

Design: We performed a retrospective review of our LIS from 2004-09 and 50 (25 stomach and 25 colorectal) GI biopsies (bxs) were selected. A chart review was performed. Using the 2006 NIH consensus guidelines, the bxs were reviewed blindly by 3 pathologists, and a consensus diagnosis (not GVHD, possible GVHD, consistent with GVHD, definitive GVHD) and histologic grade (1-4) were rendered. Eosinophil (eos) and residual neuroendocrine cell nests (NECs) were also noted (mean#/high power field (HPF)). The latter was quantified using immunohistochemistry for synaptophysin.

Results: The 50 bxs represent 39 unique BMT patients (pts). Clinically, 28 pts (38 bxs) had a diagnosis of aGVHD, 6 infection, 1 reflux, 2 potential MMF toxicity, and 2 had resolution of symptoms without intervention. Our initial histologic review utilizing only the NIH guidelines yielded a sensitivity of 68% and a specificity of 100% for aGVHD. The mean number of eos/HPF in bxs with clinically diagnosed aGVHD versus not aGVHD was not statistically significant (3.7±3.7 versus 8.0±6.0; p=0.44). Similarly, the presence or absence of NECs was not significant (p=0.26). When looking at biopsies where MMF was being administered versus not, the presence or absence of eosinophils was not significant (p=0.78). However, when present, the number of eos/HPF was significantly higher in bxs where the pt was receiving MMF (18.7±7.1) versus not (8.8±3.9) (p=0.02). Additionally, the NECs per HPF was significantly higher when MMF was being given (7.7±2.0) versus not (2.4±0.9) (p=0.0003).

Conclusions: Our data suggests that the number of eos and the presence NECs are not reliable predictors for the diagnosis of aGVHD. When present, eosinophils and NECs are seen in higher numbers in those biopsies where MMF is being administered and may be useful when evaluating biopsies where MMF colitis is in the differential.

831 Prevalence and Clinicopathologic Significance of Micropapillary Differentiation in Esophageal Adenocarcinomas

J Shen, M Tippayawong, A Agoston, R Bueno, Y Zheng, RD Odze, A Srivastava. Brigham and Women's Hospital, Boston, MA; Bangkok Hospital Phuket, Phuket, Thailand.

Background: Micropapillary differentiation in adenocarcinoma (MPC) has been described at various anatomic sites, but its prevalence and significance in esophageal adenocarcinomas (EAC) have not been evaluated. The aim of this study was to assess the prevalence and clinicopathologic features of MPC in a consecutive series of primary non-neoadjuvant treated EAC.

Design: The pathology archives of a single large academic medical center were searched for all esophageal resections performed between 1989 – 2012. Of the 1076 patients identified, 205 had primary resections for EAC without neoadjuvant therapy, and formed the final study group. A histologic review of all cases was performed to identify tumors with micropapillary differentiation, using standard criteria previously described for other organs. A predetermined set of pathologic variables was examined for each case, including the percentage of micropapillary component, tumor size, nuclear grade, presence of lymphovascular (LVI) and perineural invasion (PNI), and pT, N, and M stage. Age, gender, mortality and duration of survival were obtained by medical chart review. Clinical outcomes for MPC were compared to those for the conventional EAC. Cox proportional hazard models were used to calculate mortality hazard ratios (HRs) according to MPC status, adjusted for age and gender. All statistical analyses were performed using SAS version 9.3.

Results: The prevalence of micropapillary differentiation in EAC was 5.4% (11/205). The proportion of MPC component varied from <5 to 45%. The M:F ratio, age distribution, tumor size, and nuclear grade did not differ significantly between the MPC and conventional EAC groups. MPC was significantly associated with the presence of LVI (MPC: 73% vs. 35% for conventional EAC; $p=0.0125$) and PNI (82% vs. 18%; $p<0.001$), higher T stage ($p<0.0001$), presence of lymph node metastases (55% vs. 33%; $p=0.09$) and higher N stage ($p=0.0118$). The overall duration of survival was shorter, but not significantly so, for MPC compared to conventional EAC (mean 49.9 mth vs. 63.5 mth; $p=0.4650$). However, overall mortality was significantly higher for the MPC group (82% vs. 54%, HR=2.22, 95% CI=1.11, 4.44).

Conclusions: MPC is typically present as a minor (<50%) component in 5% of EAC, and may represent a more aggressive subtype of EAC associated with the presence of LVI and PNI, significantly higher pT and N stages, and increased overall mortality.

832 Do Gastrointestinal Pathologists Miss Gastric Atrophy?

I Siddiqui, J Chien-Hung Chen, S Hafezi-Bakhtiari, H Li Chang, J Liu, S Serra, G Soucy, C Strecker, J Wong, H El-Zimaity. University of Toronto, Toronto, ON, Canada; Queen's, Kingston, ON, Canada; UHN, Toronto, ON, Canada; BC Cancer Agency, Vancouver, BC, Canada; St. Luc Hospital, Montreal, QC, Canada; St. Michael's Hospital, Toronto, ON, Canada; Sunnybrook, Toronto, ON, Canada.

Background: This study examines agreement between pathologists in gastric atrophy (gastric cancer precursor) diagnosis, and explores disagreement reasons.

Design: Gastric biopsies (n = 166) from eighty patients with clinical information on gastric atrophy (e.g., gastrin level) were coded. Gastrointestinal pathologists (9) practicing at different hospitals, and one trainee blindly assessed whole slide images of H&E stained slides. Each pathologist recorded mucosa type (antrum, body, transitional), degree of atrophy (0-3 scale: 0 negative, 1 mild (<25%), 2 moderate (25 - 75%), 3 marked > 75%), and if present atrophy type (intestinal metaplasia, pseudo-pyloric metaplasia, or non-metaplastic atrophy/gland loss). Results were analyzed using k-statistics.

Results: The overall agreement for gastric atrophy absence was 97%. Agreement on atrophy's presence was 76%. Biopsies with atrophic body were misclassified as normal because of misinterpreting the biopsy as antrum (22%) or failure to classify gland loss as "non-metaplastic" atrophy (78%). Atrophy missed in antral biopsies was non-metaplastic (100%). The overall kappa was 0.37 (fair). Agreement increased in biopsies with more atrophy; kappa was 0.07, 0.18, 0.25 in specimens with mild, moderate and severe atrophy. Table 1 shows *inter-observer* kappa. Table 2 shows *intra-observer* kappa compared with patient's clinical status.

Table 1: Inter-observer kappa

Variable	Kappa
Overall	0.37 fair
Negative	0.18 poor
Positive	0.29 fair
Antrum	0.35 fair
Body	0.36 fair
Transitional	0.05 poor
Intestinal metaplasia	0.35 fair
Pseudo-pyloric metaplasia	0.01 poor
Non-metaplastic	0.25 fair

Table 2: Intra-observer kappa

Observer	Overall	Antrum	Body
path. 1	0.38 fair	0.34	0.38
path. 2	0.37 fair	0.44	0.38
path. 3	0.34 fair	0.28	0.39
path. 4	0.33 fair	0.22	0.36
path. 5	0.32 fair	0.45	0.26
path. 6	0.31 fair	0.1	0.39
path. 7	0.31 fair	0.31	0.3
path. 8	0.2 fair	0.07	0.23
path. 9	0.09 poor	0.04	0.12
Fellow	0.32 fair	0.34	0.31

Conclusions: Gastrointestinal pathologists' diagnosis of gastric atrophy is suboptimal. Gastric atrophy is frequently missed in biopsies with non-metaplastic atrophy or pseudo-pyloric metaplasia. Even gastrointestinal pathologists can mistake atrophic

body for antrum; immunohistochemistry for gastrin can aid in determining biopsy site in these cases. Better guidelines and training may be needed to properly diagnose and grade gastric atrophy.

833 Tumor-Infiltrating Lymphocytes (TILs) and TIL Subsets in Rectal Adenocarcinoma Correlate with Radiation Modality

SC Sopha, S Ellsworth, C Drake, J Campian, S Gearhart, J Efron, N Azad, A Hacker-Prietz, S Grossman, J Herman. Johns Hopkins University School of Medicine, Baltimore, MD.

Background: Increased tumor-infiltrating lymphocytes (TILs) are an independent predictor of improved recurrence-free survival in colorectal adenocarcinoma. In particular, increased numbers of tumor-infiltrating CD8+ T-cells and FoxP3+ regulatory T-cells are prognostic factors for improved recurrence-free survival. Patients with locally advanced rectal adenocarcinoma are commonly treated with preoperative radiation therapy, which causes peripheral lymphopenia. Endorectal brachytherapy (EB) is an alternative radiation technique that spares circulating lymphocytes by reducing radiation field size and number of treatments. It is unknown if the two types of treatment have differential effects on tumor-infiltrating lymphocytes. We assessed TILs in locally advanced rectal adenocarcinomas following treatment with standard external whole-pelvis radiation (WPR) versus EB to determine if TIL counts and subsets differed between the treatment groups, and if these correlated with treatment outcomes.

Design: Fourteen cases of rectal adenocarcinoma were evaluated. Nine patients were treated with standard whole pelvis radiation (median dose 50.4 Gy), and five received EB (6.6 Gy x 4). Tissue from total mesorectal excisions (TMEs) was formalin-fixed and paraffin-embedded using standard protocols. TILs were immunostained with antibodies against CD3, CD4, CD8, CD20, FoxP3a, and CD25. One pathologist (SCS) blinded to treatment groups quantified TILs using previously published methods.

Results: TIL-CD3 and TIL-CD8 counts were increased in EB cases as compared with WPR cases, however, these did not reach statistical significance (29.4 ± 15.8 /HPF versus 7.7 ± 8.5 /HPF, $p = 0.09$, and 9.0 ± 15.2 /HPF versus 2.0 ± 10.4 /HPF, $p = 0.09$). TIL-FoxP3 ratios were increased in EB as compared with WPR (7.4 ± 8.3 /HPF versus 0.0 ± 1.5 /HPF, $p = 0.01$). Furthermore, CD8:FoxP3 ratios were increased in EB as compared with WPR (0.0 /HPF versus 0.7 /HPF, $p = 0.02$).

Conclusions: Total TIL counts, CD8+ T-cells, FoxP3+ regulatory T-cells, and CD8:FoxP3 ratios are increased after endorectal brachytherapy as compared with standard whole-pelvis radiation, and further studies will determine if these changes correlate with improved response rates with EB. Validation of these findings with a larger case series is ongoing.

834 Chronic Deep- and Mid-Zone Gastritis: A Morphologically Distinct Inflammation in Search of a Clinical Disease

O Speck, HD Appelman, SR Owens. University of Michigan, Ann Arbor, MI.

Background: There are several well-described patterns of chronic gastritis. *Helicobacter pylori* (*Hp*) gastritis has superficial plasmacytosis and deep lymphoid nodules. Autoimmune atrophic gastritis has lamina propria inflammation, oxyntic gland atrophy, mucus gland and intestinal metaplasia, and ECL cell hyperplasia. Lymphocytic gastritis has superficial plasmacytosis and lymphocytes invading the surface and superficial pit epithelium. Some of these have specific clinical associations that might impact patient management. There are chronic gastritides that do not fit any known pattern, and that do not have published literature. We have seen such gastritides with a band of intense inflammation concentrated in the mid- and deep zones of the mucosa. We decided to study them to see if they were part of a clinicopathologic syndrome.

Design: Biopsies from 54 patients with intense deep and mid-zone dominant gastritis were found during diagnostic practice between 1994 and 2013. They were analyzed for the dominant inflammatory cell type, superficial inflammatory component, and other potential causes of gastritis such as *Hp*. Clinical records were reviewed for demographic information, clinical history, endoscopic findings, presenting symptoms, medications, and history of *Hp* infection. Gastric biopsies from 62 consecutive patients with no comparable findings served as controls.

Results: In the study group 42 were females and 12 were males while in the control group 36 were females and 26 were males. There were no significant differences in the age range and median in the study and control groups for all subjects or separately for males and females. Three cases had positive *Hp* serologies with two of these having received treatment prior to biopsy. There were no differences in the endoscopic findings in the two groups with erythema being the most common. Generalized or epigastric abdominal pain was the most common presenting symptom in both groups. Compared to controls, there were more study patients with autoimmune conditions, gastroparesis, cirrhosis, and Crohn's disease.

Conclusions: Compared to controls, deep and mid-zone gastritis is much more common in females than males. It may be the result of multiple causes, as no single cause surfaced as a result of this study. A few cases occur in patients with past *Hp* infection, but except for increased prevalence of several unrelated diseases, there were no clinical or endoscopic features that defined the study cases. As a result, this deep and mid-zone gastritis remains a spectacular histologic disease still in search of clinical relevance.

835 Genetic Background of Glucagon Cell Adenomatosis – A Recently Recognised Disease of the Alpha Cells

J Sperveslage, T Henopp, M Anlauf, M Hofmeister, G Kloppel, B Sipos. University Hospital Tübingen, Tübingen, Germany; University Hospital Düsseldorf, Düsseldorf, Germany; Technical University Munich, Munich, Germany.

Background: Glucagon cell adenomatosis (GCA) was recently recognized by us as a multifocal neoplastic disease of the endocrine pancreas unrelated to MEN1. Multiple micro- and a few macrotumors are found on the background of a hyperplasia of

glucagon cells. The disease may cause unspecific abdominal symptoms and only rarely a glucagonoma syndrome. We aimed to investigate the genetic alterations of GCGR gene in patients with GCA.

Design: FFPE pancreatic tissues from five patients showing multiple microadenomas and partly macroadenomas of glucagon cells were macro- or microdissected. Following DNA extraction all exons of the GCGR gene were analysed for mutations by Sanger and deep sequencing. Genotyping for all detected GCGR variants was performed by using Taqman Assay in 2560 healthy individuals.

Results: Sequencing of the GCGR gene revealed germ line mutations in three out of five patients. One patient showed two different heterozygous point mutations in the hyperplastic alpha cells as well as in the non-tumorous tissue leading to two premature stop codons. One patient harboured a homozygous stop mutation. The third patient showed two homozygous missense mutations of the GCGR gene that most likely also led to a dysfunction of the GCGR. These variants were not identified in healthy subjects. In the two other patients no germ line or somatic mutations of the GCGR gene were detected.

Conclusions: The finding of germ line "loss of function" mutations of the GCGR gene in three of five GCA cases suggests that deficiency in the GCGR signalling causes glucagon cell adenomatosis via glucagon cell hyperplasia. However, there is a second still unrecognized mechanism that leads to GCA in patients with wild type GCGR gene.

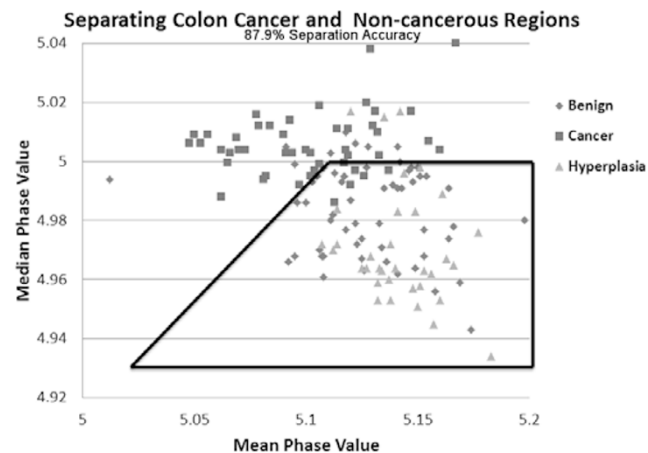
836 Label-Free Quantitative Diagnosis of Colon Cancer

S Sridharan, V Macias, A Patel, A Kajdacsy-Balla, K Tangella, G Guzman, G Popescu. Beckman Institute, University of Illinois at Urbana-Champaign, Urbana, IL; University of Illinois at Chicago, Chicago, IL; Christie Clinic, Presence Covenant Medical Center, Urbana, IL.

Background: Spatial Light Interference Microscopy (SLIM) is a label-free imaging method, that quantitates the refractive index of unstained tissue imaged with white light. It is an add-on module to a commercial phase contrast microscope. In the past, SLIM has been used to diagnose prostate cancer, quantitative Gleason grading and prediction of recurrence of prostate cancer after prostatectomy. Here, we present initial results from quantitative diagnosis of colon cancer.

Design: We analyzed 38 unstained tissue microarray cores which comprised of 7 cores of cancer-associated colonic hyperplasia, 16 normal cores and 15 colon cancer cores. The imaging was performed using a 40X/0.75NA objective in the SLIM system. The final phase image of each core was generated from approximately 120 frames stitched together to a final size of 12,000x12,000 pixels. The resulting image represents a quantitative optical thickness map, which reports on tissue morphology with nanoscale sensitivity.

Results: We selected 132 tissue regions of interest on the final phase images, 48 of which were adenocarcinoma, 35 hyperplastic and 49 normal-appearing colonic mucosa. The mean and median phase values in the epithelial tissue were used as markers for diagnosis. Using this approach, we found that adenocarcinoma had lower mean phase value but higher median phase value than hyperplastic and normal-appearing tissue. Using this method, 87.5% malignant regions were categorized as malignant, whereas 91.4% of hyperplastic tissue samples and 85.7% of normal colon tissue regions were classified as benign.



Conclusions: The 87.9% separation accuracy between colon cancer and non-cancerous regions seen in our testing set is promising. We will validate these results in the remaining 90 cases of the tissue microarray set.

837 Colesevelam and Colestipol: Novel Drug Crystals in the Gastrointestinal Tract (GIT)

B Swanson, MA Arnold, C Crowder, D Lam-Himlin, AD Singhi, CA Arnold. The Ohio State University Wexner Medical Center, Columbus, OH; Nationwide Children's Hospital, Columbus, OH; Mercy Medical Center, Des Moines, IA; Mayo Clinic, Scottsdale, AZ; University of Pittsburgh Medical Center, Pittsburgh, PA.

Background: Colesevelam (Welchol®) and colestipol (Colestid®) are emerging bile acid sequestrants used most commonly to treat hypercholesterolemia. Herein, we report the first series of colesevelam and colestipol crystals in the GIT.

Design: Histologically similar crystals from 4 institutions were prospectively collected over a one year period (10 biopsies, 6 patients). Relevant clinicopathologic features were recorded.

Results: The crystals were black to bright orange on H&E, non-refractile, non-polarizable, and lacked internal "fish-scales". Hyperlipidemia and colestipol or colesevelam were confirmed in all cases. Other comorbidities included GERD (n=4), CAD (n=2), hypothyroidism (n=2), prior malignancy (n=2), and HTN, Crohn, and gout (n=1 each). Crystals were identified in the esophagus (n=1), stomach (n=1), small bowel (n=1) and colorectum (n=7). Associated diagnoses included normal (n=5), erosion/ulceration (n=2), acute inflammation (n=1), adenoma (n=1), hyperplastic change (n=1), and chronic gastritis with intestinal metaplasia (n=1). To validate these observations, colesevelam and colestipol tablets were crushed and submitted for histological processing; the findings were identical to those in the patient specimens. Differential considerations included Kayexalate®, sevelamer, and cholestyramine crystals. Kayexalate is violet on H&E, black on AFB, hot pink on PAS/D and displays narrow, rectangular "fish scales" with perpendicular points of intersection. Sevelamer most commonly displays a two-tone color on H&E, is magenta on AFB and lavender on PAS/D, and has broad, irregular "fish scales" with curved points of intersection. Colesevelam and colestipol were indistinguishable from cholestyramine and, consequently, reconciliation with the medication list was required for definitive diagnosis.

Conclusions: In summary, we report the first description of colesevelam and colestipol in the GIT. These crystals were exclusively found in patients with hyperlipidemia and no strong correlation with mucosal injury was seen. Since their administration was not documented in any requisition, awareness of these entities is crucial for accurate diagnosis and to avoid the diagnostic pitfalls of their mimics.

838 Is the Histologic Diagnosis of Portal Hypertensive Gastropathy Reliable?

J Szafarska, RK Yantiss, KC Piotti, J Jessurun. Hospital de la Santa Creu i Sant Pau, Barcelona, Spain; Weill Cornell Medical College, NY, NY.

Background: Portal hypertension may be associated with portal hypertensive gastropathy (PHG), which is characterized by a distinct "mosaic-like" endoscopic appearance or diffuse erythema. Typical histologic features include the presence of small, ectatic vessels in the mucosa with reactive epithelial changes and variable fibrosis. Although several studies describe differences between the histologic features of PHG and gastric antral vascular ectasia (GAVE), we feel that the more relevant differential diagnosis includes chemical gastropathy. The present study was designed to determine whether the histologic features of PHG are sufficiently distinct to be differentiated from those of other gastropathies.

Design: We evaluated 84 gastric biopsies obtained from 42 patients (male/female: 1/1) with cirrhosis and portal hypertension and 42 sex and age-matched controls with chemical gastropathy, none of whom had portal hypertension or liver disease. All cases were reviewed in a blinded fashion for the presence of vascular abnormalities, including dilatation, congestion, thrombi, and vascular remodeling (proliferation, arterIALIZATION of capillary wall, increased or prominent endothelial cells), regenerative or degenerative changes of foveolar epithelium, fibromuscularized lamina propria, inflammation, hemorrhage and edema.

Results: Biopsies of PHG typically displayed vascular congestion (73%) with ectasia (57%), but these changes were common in chemical gastropathy as well (76% and 43%, p=0.80 and p=0.27, respectively). ArterIALIZED vessels and endothelial cell proliferation were slightly more common in PHG (31% and 38%, respectively) but the differences were not significant compared to controls (14% and 31%, p=0.11 and p=0.65, respectively). Similar numbers of cases and controls showed regenerative or degenerative changes in foveolar epithelium (62% vs. 52%), fibromuscularized lamina propria (60% vs. 50%), mild, focal inflammation (52% vs. 36%), and hemorrhage (14% vs. 14%). None of the cases or controls showed fibrin thrombi in the biopsies. There were no differences between groups with respect to the distribution of findings in the superficial or deep mucosa.

Conclusions: The histologic features of PHG are not at all specific and are commonly seen in patients with chemical gastropathy. The histologic diagnosis of PHG may leave clinicians with a false sense of reassurance and cause them to overlook other causes of gastric blood loss such as drug or alcohol-induced injury in patients with chronic liver disease.

839 Evaluation of Gallbladder Adenocarcinoma by Next Generation Sequencing Reveals Frequent Actionable Genomic Abnormalities and New Routes to Targeted Therapies

AJ Tarasen, RN Al-Rohil, K Wang, JV Rand, DM Jones, HJ Lee, CE Sheehan, GA Otto, G Palmer, SM Ali, D Morosini, VA Miller, PJ Stephens, JS Ross. Albany Medical College, Albany, NY; Foundation Medicine Inc, Cambridge, MA.

Background: Metastatic gallbladder adenocarcinoma (GBCA) has a poor prognosis and systemic therapies are commonly extrapolated from those used in other GI malignancies. We hypothesized that comprehensive genomic profiling of clinical GBCA samples by next generation sequencing (NGS) could identify genomic-derived drug targets of therapy for patients with this lethal cancer.

Design: Hybridization capture of 3 3,769 exons from 236 cancer-related genes and 47 introns of 19 genes commonly rearranged in cancer was applied to ≥ 50 ng of DNA extracted from 53 GBCA FFPE specimens and sequenced to high, uniform coverage. Genomic alterations (base substitutions, small indels, rearrangements, copy number alterations) were determined and then reported for these patient samples. Actionable GA were defined as those identifying anti-cancer drugs on the market or in registered clinical trials (CT).

Results: There were 38 female and 15 male GBCA patients with a median age 60.3 years (range 26-90 years). The study included 2 Grade I GBCA cases, 29 grade II GBCA and 22 grade III tumors. Two GBCA were Stage II, 23 were stage III and 28 were Stage III at time of sequencing. Thirty GBCA had sequencing performed on the primary tumor and 23 on a metastasis biopsy. A total of 179 GA with an average of

3.38 GA per tumor with 53/53 (100%) harboring at least one genomic alteration. The most common non-actionable GA were alterations in *TP53* (64%), *ARID1A* (17%), *APC* (11%), *MYC* (11%), *ARID2* (6%), *MAP2K4* (6%) and *RBI* (6%). 42/53 (79%) GBCA had at least 1 actionable GA with an average of 2.02 actionable GA per patient including: mutation, amplification, homozygous deletion or fusion of: *PIK3CA* (17%), *ERBB2* (11%), *KRAS* (11%), *STK11* (11%), *CCNE1* (9%), *CDKN2A* (9%), *MDM2* (9%), *PTEN* (8%), *FGFR3* (6%), *GNAS* (6%), *BRCA2* (4%), *EGFR* (4%), *ERBB3* (4%), *FBXW7* (4%), *NOTCH1* (4%), *NRAS* (4%) and *RICTOR* (4%).

Conclusions: More than three-quarters of the patients harbored at least one actionable GA. The long tail of altered genes and multiple mechanisms of alteration necessitate broad diagnostic assays from limited biopsy material to maximize targeted therapeutic options in an individual patient. Given the limited treatment options and poor prognosis of patients with metastatic GBCA, comprehensive NGS-based genomic profiling has the potential to identify new treatment paradigms and meet a previously unmet clinical need for this disease.

840 Impact of Peritumoral and Intratumoral Budding in Esophageal Adenocarcinomas

S Thies, J Slotta-Huspenina, I Zlobec, VH Koelzer, D Kroell, CA Seiler, M Feith, R Langer. University of Bern, Bern, Switzerland; Technische Universität München, München, Germany; University Hospital Bern, Bern, Switzerland.

Background: Tumor budding has prognostic significance in many cancers and is defined as the presence of detached isolated single cells or small cell clusters (up to 5 isolated cells) scattered in the stroma. Tumor budding can be observed at the peripheral invasion front (peritumoral budding=PTB) and/or within the tumor (intratumoral budding=ITB). For esophageal adenocarcinomas there are currently only scarce data about the impact of this morphological feature. In the present study we investigated PTB and ITB in a well characterized collective of primary resected esophageal adenocarcinomas of two centers. **Design:** Whole tissue sections of 204 resection specimens were analyzed. Tumor buds were highlighted by pancytokeratin staining. PTB and ITB were scored across 10-high-power-fields (HPF). Results were correlated with clinico-pathological and follow-up data.

Results: Interobserver agreement between two independent investigators was excellent ($p < 0.001$, intraclass correlation coefficient = 0.8 for PTB and 0.78 for ITB). The median count of tumor buds was 136/10 HPF for PTB (range 2-593) and 45/10 HPF for ITB (range 1-656). PTB and ITB correlated significantly with each other ($r=0.9$; $p<0.001$). High PTB/ITB (cut-off: median) was associated with advanced tumor stages ($p<0.001$ each), presence of lymph node metastases ($p<0.001/p=0.002$), worse tumor differentiation (grading; $p<0.001$ each) and higher rate of R1 resection ($p=0.003/p<0.001$). In addition, survival analysis showed an association with worse survival for high grade PTB ($p=0.04$), but this was not independent from pT category (HR 1.6; $p=0.023$) and pN category (HR 2.5; $p=0.007$) in multivariate analysis (PTB: HR 0.9; $p=0.8$).

Conclusions: Peripheral and intratumoral budding can be observed in esophageal adenocarcinomas in various degrees. High grade budding is associated with aggressive tumor phenotype. Assessment of tumor budding may provide additional prognostic information about tumor behavior and used for risk stratification for esophageal adenocarcinoma patients.

841 Diverticular Disease Associated (Segmental) Colitis: Basal Lymphoplasmacytosis Associated with Need for Therapeutic Intervention

KJ Threlkeld, N Lim, JL Conant, M DeSarno, R Wilcox, M Zenali. Fletcher Allen Health Care/University of Vermont, Burlington, VT.

Background: Diverticular disease associated (segmental) colitis (DAC) is a well-recognized entity defined as colitis limited to a diverticular segment, generally within the sigmoid colon. The histologic and endoscopic findings of DAC can mimic those found in IBD often leading to questions from our clinicians regarding clinical management. We sought to characterize the clinical, endoscopic, and histologic features seen in DAC and to determine whether any of these could predict the subset of patients which require treatment.

Design: We identified all biopsy cases of diverticular disease-limited colitis (by histology and endoscopy; 2009-2013). H&E slides, endoscopic images and clinical charts were reviewed for multiple factors (See Table 1) which were compared using a Fisher's exact test. Treatment was defined as: none, 5-ASA, steroids, or surgery.

Results: 56 pts (age 37-85; mean 61) met DAC criteria (45%F; 55%M). 33/56 had documented treatment history (22 none, 9 5-ASA, 0-steroids, 2 surgery; Table 1). The only factor found to be statistically significant for treatment was the presence of mod/severe sigmoid basal lymphoplasmacytosis (BLPC) ($p=0.0350$). There was no significant correlation between histologic and clinic-endoscopic manifestation.

Table 1

Histology/Endoscopy/Symptom	Treatment	
	No (n = 22)	Yes (n = 11)
Sigmoid granuloma -- no. (%)	0 (0)	0 (0)
Sigmoid IEL -- no. (%)	4 (19.1)	2 (18.2)
Sigmoid activity -- no. (%)	9 (42.9)	5 (45.5)
Basal lymphoplasmacytosis -- no. (%)	3 (14.3)	6 (54.6)
Glandular disarray -- no. (%)	12 (57.1)	5 (45.5)
Glandular architectural distortion -- no. (%)	7 (33.3)	5 (45.5)
Paneth cell metaplasia -- no. (%)	6 (28.6)	7 (63.6)
Normal Endoscopy -- no. (%)	2 (22.2)	2 (28.6)
Segmental Endoscopy -- no. (%)	4 (44.4)	4 (57.1)
Erythema/hemorrhage -- no. (%)	13 (59.1)	7 (63.6)
Loss of vascular pattern -- no. (%)	0 (0)	1 (9.1)
Asymptomatic -- no. (%)	7 (31.8)	0 (0)
Symptom - Diarrhea -- no. (%)	5 (22.7)	2 (18.2)
Symptom - Abdominal pain -- no. (%)	4 (18.2)	3 (27.3)
Symptom - Hematochezia -- no. (%)	7 (31.8)	7 (63.6)

Conclusions: DAC is a relatively common entity that at times can be difficult to discern from IBD. In our study DAC occurred in an older population (median 62yrs) with close to equal gender distribution. The clinical, endoscopic and histologic features varied and were for the most part not discriminatory between those who did or did not require treatment. The only factor found to be associated with therapeutic intervention was notable BLPC which was not correlated with any one endoscopy or presenting symptom.

842 Peritumoral Lymphoid Infiltration Is a Favorable Prognostic Factor in Esophageal Adenocarcinoma

M Tippayawong, A Agoston, RD Odze, A Srivastava. Bangkok Hospital Phuket, Muang, Phuket, Thailand; Brigham and Women's Hospital, Boston, MA.

Background: Intratumoral and peritumoral lymphoid infiltration is a favorable prognostic factor in colorectal cancer. CD8+ T cell infiltration has been shown to be a favorable prognostic factor in EAC but the patterns of lymphoid response were not defined in these studies. The aim of our study was to evaluate the patterns of lymphoid infiltration in EAC and determine their prognostic significance.

Design: 156 patients treated with primary resection, without neoadjuvant therapy, for EAC, were included in the study. Histologic review was performed in all cases and the pattern of lymphoid response was classified into four categories: intratumoral lymphoid aggregates (ILA), peritumoral lymphoid aggregates (PTL), stromal lymphoplasmacytic infiltration (SLP), and tumor-infiltrating lymphocytes (TILs). A minimum of 3 well-formed lymphoid aggregates were required within the tumor or along the advancing tumor edge, to be considered positive for ILA and PTL, respectively. SLP was scored as positive only if present distant from foci of tumor/mucosal ulceration. TILs were scored as positive only when present diffusely within the tumor mass and easily identified in every high power field. The predominant pattern of infiltration was recorded, when applicable, and in others, one or more co-dominant patterns were noted. Patient demographic and outcome data was retrieved by chart review. Cox proportional hazard model was used to analyze hazard ratio (HR) for mortality, after adjusting for covariates including tumor size, location, tumor grade and phenotype, LVI, PNI, T and N stage.

Results: The M:F ratio was 129:27 and the mean patient age for the study cohort was 66 yrs. At least one pattern of tumor-associated lymphoid reaction was present in 69/156 (44.23%) cases, of which 30 showed a single predominant pattern (ILA:9, PTL:14, SLP:5 and TILs:2) whereas the remaining 39 showed multiple co-dominant patterns of lymphoid infiltration. A pure PTL pattern was associated with lower tumor grade and stage (OR 0.27, $p < 0.028$ and OR 0.12, $p < 0.019$, respectively), and a favorable outcome (HR 0.27; $p < 0.0262$). Tumors with predominant and admixed ILA pattern, were more likely to be higher T and N stage ($p < 0.013$ and 0.028) but this pattern did not affect survival. SLP and TIL patterns also did not show any prognostic significance.

Conclusions: Peritumoral lymphoid infiltration is a predictor of favorable outcome in EAC. Other patterns of lymphoid response appear to correlate with higher T and N stage, but do not affect overall survival.

843 Gender but Not Active H. pylori Gastritis Predicts Steatosis and Steatohepatitis in Bariatric Surgery Specimens

M Torbenson. Mayo Clinic, Rochester, MN.

Background: Non-alcoholic fatty liver disease (NAFLD) has a wide range of disease activity. The explanations for the variable amount of fatty liver disease are unclear. Recently, several serological studies have suggested a link between H. pylori infection and NAFLD. However, biopsy data to date have been lacking. To further examine this question, histological findings were studied in morbidly obese patients who had both a sleeve gastrectomy during bariatric surgery and a wedge liver biopsy.

Design: Two hundred and two (202) paired, consecutive liver and stomach biopsies signed out by a single pathologist were studied. All liver biopsies and gastrectomy specimens were obtained during the same surgical procedure. Fatty liver disease was evaluated in a semiquantitative fashion using the NAS scoring system. Stomach resections were examined for H. pylori gastritis, with all cases having more than a minimal chronic gastritis stained with a Diff-Quik stain.

Results: Specimens were from 158 women and 44 men. The average age at bariatric surgery was 43±11 years. At least minimal steatosis was seen in 89% of liver biopsies. Steatosis ranged from minimal (25%), to mild (25%), to moderate (23%), to marked (14%). 15% of liver biopsies showed steatohepatitis. *Helicobacter pylori* infection was found in 10% of the gastric specimens. Statistical analysis showed that men were more likely than women to have more severe steatosis (P=0.003) and were more likely to have steatohepatitis (p=0.002). Neither the amount of fat on liver biopsy nor the presence or absence of steatohepatitis was associated with *H. pylori* infection (p=0.24). Separate analysis for men and women also showed no association between *H. pylori* infection and the presence or absence of steatohepatitis. Finally, fibrosis was not associated with the presence of *H. pylori* gastritis (p=0.23).

Conclusions: In wedge liver biopsies obtained at the time of bariatric surgery, men have greater degrees of steatosis and are more likely to have steatohepatitis. The presence of *H. pylori* gastritis does not influence the amount of fatty change, the presence or absence of steatohepatitis, or the amount of fibrosis.

844 MicroRNA Profiles Distinguish Benign from Malignant Gastric Mucosa and Differentiate Molecular Subtypes of Gastric Adenocarcinoma

AL Treece, DL Duncan, W Tang, DR Morgan, MO Meyers, RL Dominguez, O Speck, ML Gulley. University of North Carolina at Chapel Hill, Chapel Hill, NC; Vanderbilt University, Nashville, TN; Western Regional Hospital, Santa Rosa de Copan, Honduras. **Background:** Gastric adenocarcinoma (GA) is often fatal, with advanced stage at the time of diagnosis. There is potential for microRNA (miR) biomarkers to promote early detection and to guide therapy. Epstein-Barr virus (EBV) has been implicated in a subset of GAs, and thus viral as well as human miRs could be important for subtyping tumors in a way that promotes understanding of pathobiology and virus-targeted therapy.

Design: We investigated archival GA tissue and matched non-malignant mucosa to identify differentially expressed miRs using preloaded 96-well plates containing lyophilized Exiqon miRCURY LNA Universal RT microRNA PCR primers to amplify cDNA, and expression was measured by real-time PCR using SYBR Green on the Roche Lightcycler 480. 48 miRs (13 candidate normalizers, 32 previously associated with GA, 2 synthetic controls, and 1 spiked miR) were measured in 6 benign and 6 malignant paired FFPE specimens as well as an additional 16 EBV positive and 33 EBV negative FFPE GA samples. Data was analyzed using Exiqon-GeneEx software.

Results: After housekeeper miR normalization, two human miRs (miR-378, miR-451) were down regulated in tumor compared with non-malignant tissue (p<0.05), and both of these results are supported by a published meta-analysis. Nine human miRs were differentially expressed in EBV positive versus EBV negative tumors: miR-185, miR-146a, miR-34a, miR-155, and miR-378 were upregulated while miR-141, miR-196a, miR-196b, and miR-200a were downregulated (p<0.05). These findings shed light on the unique pathobiology of infected cancers.

Conclusions: In summary, these findings demonstrate significant miR dysregulation in the progression from premalignant to malignant gastric mucosa, and they reinforce the potential that miR profiling could be used for molecular classification of cancer. Furthermore, the Exiqon LNA miR test system is user-friendly and has potential for transition to clinical settings following appropriate validation.

845 Clinicopathological Significance of Tumor Budding in Early Gastroesophageal Adenocarcinoma

M Tripathi, A Grin, C Streutker. University of Toronto, Toronto, ON, Canada; St. Michael's Hospital, Toronto, ON, Canada.

Background: Tumor budding has been shown to be a poor prognostic factor in several tumor sites including colorectal, stomach, gallbladder, bladder and pancreatic cancers. Recently, the significance of tumor budding in esophageal cancers has been explored. Patients with low-grade budding were shown to have a better prognosis and recurrence rate than those with high-grade budding. In this study, we sought to examine the significance of tumor budding in early gastroesophageal (GEJ) adenocarcinoma.

Design: Tumor budding was evaluated in a series of 60 endoscopically resected GEJ adenocarcinomas. A tumor bud was defined as single tumor cell or cluster of ≤5 cells. The entire tumor was scanned to identify areas of budding, if present. The highest count obtained in one 20x field (field diameter=1.2 mm) was used. Cases were stratified into three groups: Absent (no tumor budding), minimal (1-5 tumor buds) and significant (> 5 tumor buds). Additional clinicopathologic features were also evaluated including tumor differentiation, lymphovascular invasion and depth of invasion. Correlation between the groups was established using a univariate analysis by a student t-test.

Results: On univariate analysis presence of significant tumor budding correlated well with high-grade tumor differentiation (p=0.0184) and the presence of lymphovascular invasion (p=0.030) (Table 1).

Table 1

Tumor Budding	Tumor differentiation		Depth of invasion		Lymphovascular invasion
	Low-grade	High-grade	Early intramucosal (M1-M3)	Deep intramucosal or Submucosal (M4-SM1)	
Absent n=30	13(43.3%)	17(56.6%)	17(56.6%)	13(43.3%)	2(13.3%)
Minimal n=15	5(33.3%)	10(66.6%)	1(4.4%)	14(95.6%)	5(33.3%)
Significant n=15	1(4.4%)	14(95.6%)	0	15(100%)	6(40%)

Conclusions: In this study, significant tumor budding was associated with poor tumor differentiation and presence of lymphovascular invasion. Therefore, the presence of tumor budding may be an additional poor prognostic factor in early GEJ tumors and may be an important factor to consider in decision making for further management of endoscopically resected early GEJ tumors.

846 Gastric Antral Vascular Ectasia: Relevance of the Histopathologic Diagnosis

K Turner, RM Genta. Miraca Life Sciences Research Institute, Irving, TX.

Background: Gastric Antral Vascular Ectasia (GAVE) is traditionally considered an endoscopic diagnosis. The role of the gastric biopsy is uncertain, and the relatively obscure criteria proposed by Gilliam (*Dig Dis Sci* 1989; 34:885) are rarely used by practicing pathologists. This study was designed to determine whether the demonstration of mucosal vascular dilatation and thrombi could be reliably used for the histopathologic diagnosis of GAVE.

Design: From a large histopathology database we extracted all patients who had gastric biopsies and a clinical history or an endoscopic description suggestive of GAVE. We then compared the demographic and clinical characteristics of patients whose biopsies were diagnosed as GAVE to those with no histologically detectable vascular dilatations or thrombi. Differences between groups were evaluated by the Mann-Whitney Rank Sum Test and unadjusted odds ratios.

Results: GAVE was suspected clinically or endoscopically in 850 patients. A histopathologic diagnosis of GAVE was made in 142 patients (median age 68 years; 70% women); the most common diagnoses in remaining 708 patients (median age 65 years; 61% women) were reactive gastropathy (72%); chronic inactive gastritis (16%) and *H. pylori* gastritis (4.6%). Patients with histologically documented GAVE were older (68 versus 65), significantly more likely to be male (p<.05), and presented more often with anemia than patients with no definite histopathologic features of GAVE.

Clinical Presentation in Patients with Suspected GAVE

	Histopathologic GAVE (%) (n=142)	No histopathologic GAVE (%) (n=708)	OR (95% CI)
Anemia	78 (55)	221 (31)	2.69 (1.86-3.88)
GERD	32 (23)	286 (40)	0.52 (0.34-0.81)
Nausea/Vomiting	1 (0.7)	74 (11)	0.06 (0.008-0.44)
Abdominal Pain	23 (16)	150 (21)	0.72 (0.44-1.16)

This latter group was more likely to present with GERD, nausea and vomiting, abdominal pain, weight loss and dyspepsia.

Conclusions: Amongst patients with suspected GAVE, simple histopathologic criteria discriminate two distinct populations: one, older and with a greater prevalence of anemia, has histologically visible vascular dilatations and thrombi, and represents true GAVE. The other presents with the more conventional indications for EGD (GERD, pain, and dyspepsia) and has no histopathologic evidence of antral vascular pathology. Therefore, we suggest that the diagnosis of GAVE should not be made on clinical or endoscopic grounds alone; rather, it ought to rest on solid histopathologic foundations.

847 Gastric Polyps: Shifting Paradigms in the Twilight of *Helicobacter*

K Turner, A Sonnenberg, RM Genta. Miraca Life Sciences Research Institute, Irving, TX; Oregon Health & Science University, Portland, OR.

Background: *H. pylori* infection is declining and a parallel shift is occurring in gastric pathology. Multifocal atrophic gastritis, once common, is now rare; reactive gastropathy is the new normal; autoimmune gastritis is increasing. Classically, fundic gland polyps (FGP) were rare; hyperplastic polyps (GHP) and adenomatous polyps (GAP) were associated with *H. pylori*, and neuroendocrine tumors (NET) arose in atrophic stomachs. We hypothesized that the frequency of these polyps and their backgrounds are now different from the classic descriptions.

Design: From a nationwide database we extracted patients with gastric biopsies (2008-2013). Patients with gastrointestinal cancer or surgery were excluded. Our analysis focused on the associations between FGPs, GHPs, GAPs, and NETs and pertinent demographic, histologic, and clinical characteristics. Cases were all patients with any of these polyps; subjects with no polyps served as controls. Associations are described as odds ratios adjusted for individual predictor variables entered simultaneously into the regression model.

Results: There were 741,351 patients and 671,042 controls (median age 58 years; 56% female). The prevalence of each polyp type, sex ratio, most common histopathologic associations, and most frequent indications for EGD are summarized in Table 1.

Gastric Polyps and Their Associations

Polyp	Prevalence	Risk for female gender	Histopathologic association	Inverse association	Major clinical association
FG	57,214 (8%)	1.36 (1.33-1.38)	Normal stomach	<i>H. pylori</i> 0.02 (0.02-0.03)	GERD 1.47 (1.44-49)
GH	13,288 (2%)	0.98 (0.95-1.02)	Atrophy 2.97 (2.63-3.35)	<i>H. pylori</i> 0.55 (0.51-0.59)	Anemia 1.65 (1.57-1.74)
GAP	661 (0.1%)	0.76 (0.65-0.89)	Atrophy 5.89 (4.22-8.03)	<i>H. pylori</i> 0.54 (0.38-0.74)	Anemia 2.39 (1.98-2.86)
NET	412 (0.06%)	1.28 (1.04-1.58)	Atrophy 47.3 (36.7-60.6)	<i>H. pylori</i> 0.19 (0.08-0.37)	Anemia 1.56 (1.20-2.00)

Patients with any type of polyp were older than controls; case-control age difference increased from FGPs (3.8 y) to NETs (7.8 y), GHPs (9.2 y), and GAP (13.1 y). Any one type of gastric polyp was associated with other types, with the strongest association between GAPs and NETs (OR 19.37 95%CI 9.14 – 41.05).

Conclusions: In a population where the prevalence of *H. pylori* has been steadily declining and is now at 10% of gastric biopsy specimens, all types of polyps are negatively associated with *H. pylori*. FGPs, the most common type, arise only exceptionally in *H. pylori* gastritis; GAPs and NETs, strongly associated to each other, have become exceedingly rare.

848 Isolated Eosinophilic Colitis: A Challenging Diagnosis in Search of Criteria

K Turner, RM Genta. Miraca Life Sciences Research Institute, Irving, TX.

Background: Eosinophils infiltrate the colonic mucosa in response to tissue-invading parasites, as part of eosinophilic gastroenteritis (EoG), or as an isolated presumably allergic phenomenon. Focal infiltrates around parasite fragments are easily recognized and the simultaneous involvement of stomach or small intestine readily leads to a diagnosis of EoG. In contrast, no established criteria exist for the diagnosis of primary eosinophilic colitis. The purpose of this study was to examine a large series of such cases in an attempt to create a tentative clinico-pathologic framework for this condition.

Design: From a database of 1.2 million patients with colonic biopsies we extracted those with a histopathologic diagnosis of an abnormal increase in mucosal eosinophils. We reviewed all cases and captured demographic, clinical and pathologic data, including information about eosinophilia in other organs. We counted eosinophils in their densest locations (expressed as eosinophils per mm²) in cases of primary eosinophilic colitis. For comparison, we evaluated the presenting manifestations in 28,767 patients with acute self-limited colitis (ASLC) and 14,964 patients with microscopic colitis (MC).

Results: There were 316 patients with colonic eosinophilia. Parasitic material was identified in 51 subjects; 8 of 92 subjects with biopsies from other organs had EoG. There remained 257 patients (median age 57 years, range 1–87; 52% female) with presumed isolated eosinophilic colitis. Intramucosal eosinophil counts varied from 600 to >5,000/mm² (normal controls range 20–100). Diarrhea was the commonest indication for colonoscopy: 38%, higher than in subjects with parasites (6%; $p < .0001$) and ASLC patients (30%; $p < .01$), but lower than in MC patients (82%; $p < .0001$). Hematochezia was more common in patients with eosinophilic colitis than in those with MC (12% versus 5%; $p < .01$) or parasites (6%; $p < .01$), but less common than in those with ASLC (21%; $p < .01$). No other manifestations were significantly different from controls.

Conclusions: Although cases may have been missed because only subjects with very high colonic eosinophilia were studied, it is clear that primary eosinophilic colitis is extremely rare (<1 in 5,000 patients in this series). In spite of the extreme eosinophilic counts in these patients, their clinical manifestations were not distinctive and could not have led clinicians to suspect this condition. Regularly reporting high colonic eosinophilia may result in increased opportunities for clinicopathologic studies that might lead to a better definition of this still elusive entity.

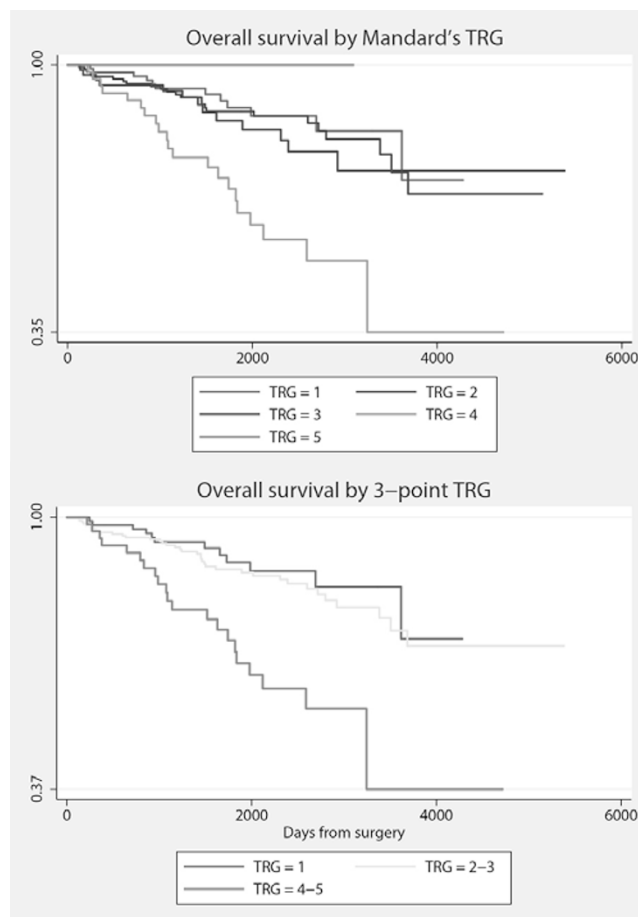
849 Three-Point Tumor Regression Grade Is at Least Equivalent to a Five-Point Score in Predicting Survival in Locally Advanced Rectal Cancer Treated with Preoperative Therapy

FM Vecchio, L Valerio, V Arena, MC Barba, MA Gambacorta, R Ricci, C Coco, GB Doglietto, A Crucitti, B Barbaro, V Valentini. Catholic University, Rome, Italy; University of Amsterdam, Amsterdam, Netherlands.

Background: Mandard's tumor regression grade (TRG) is a good prognostic factor towards overall survival (OS), cancer-specific survival (CSS) and disease-free survival (DFS) for patients with locally advanced rectal cancer treated with preoperative therapy. However, the reproducibility of this 5-point TRG has been questioned, and new TRG scoring systems have been proposed. While 3-point TRGs have been found to be more reproducible than 5-point TRGs, their correlation with survival has not been tested. We compared the prognostic potential towards OS, CSS and DFS of six alternative TRG definitions with Mandard's and each other in a large sample of patients.

Design: We retrospectively studied 445 consecutive patients diagnosed with locally advanced rectal cancer. We tested the predictive ability towards OS and CSS of Mandard's TRG and six TRG redefinitions of Mandard's: two 2-point scores, two 3-point scores, and two 4-point scores. Univariate and multivariate analysis of their impact on OS, CSS and DFS was assessed using Cox proportional hazards model.

Results: TRG 1, 2, 3, 4, 5 were found in 25%, 19%, 41%, 14%, and 0.8% of the resected specimens, respectively. The ternary score 1-23-45 proved to predict OS, and better than Mandard's TRG, with similar results for the binary score 123-45 and the ternary score 12-3-4.



Four of the six tested alternative TRG definitions, including both of the 3-point ones - were equivalent to the 5-point TRG in predicting DFS. The multivariate model best correlated with survival endpoints included these TRG definitions and post-radiotherapy node status.

Conclusions: In patients with rectal cancer receiving preoperative CRT, specific 3-point redefinitions of Mandard's 5-point TRG were at least equivalent predictors of OS, CSS and DFS to Mandard's, with 2-point and 4-point redefinitions showing mixed results. This confirms the added value of including TRG in prognostic models for this group of patients, and suggests that 5-point TRGs could be replaced by more reproducible TRG definitions such as a 3-point TRG.

850 Traditional Serrated Adenomas of the Colon Arise from Precursor Non-Dysplastic Serrated Polyps: A Clinicopathologic and Molecular Study

K Viani, M Stachler, N Lindeman, R Odze, A Srivastava. Brigham and Women's Hospital, Boston, MA.

Background: Traditional serrated adenomas (TSA) are rare precursors of colorectal carcinoma with a predilection for the left colon. Whether TSA arise de novo or from pre-existing non-dysplastic serrated polyps is unknown. We evaluated a consecutive series of TSAs, with particular emphasis on the type of background mucosa, and performed molecular analysis on paired microdissected samples from lesional and background mucosa, when feasible.

Design: The clinical and pathologic features of 253 patients with TSAs were evaluated for polyp location (right vs left colon), size, grade of dysplasia (low vs high), and presence and type of background mucosa: normal, hyperplastic polyp (microvesicular, goblet cell rich or mucin depleted), or sessile serrated polyp/adenoma (SSP/A). TSAs that contained adequate tissue in both the TSA and background non-dysplastic serrated polyp component underwent molecular analysis for *BRAF* (codon 600) and *KRAS* (codons 12 and 13) mutations in both components separately.

Results: TSAs were more frequently located in the left (66%) compared to the right (34%) colon ($p < 0.05$). 14% of TSAs were > 1 cm in size, 2% had high grade dysplasia, and 2% were associated with invasive carcinoma. 135/253 TSAs showed lesional epithelium only while the remaining 118 (47%) showed either normal mucosa (92; 78%) or a hyperplastic polyp (26; 22%) in the background mucosa. 18/26 hyperplastic polyps were microvesicular (MVHP) and 8/26 were goblet cell rich (GCHP). None were associated with SSA/P. Left sided TSAs were significantly more likely to be associated with a hyperplastic polyp compared to right sided lesions ($p < 0.05$). Twelve TSAs with associated hyperplastic polyp (6 MVHP and 6 GCHP) contained adequate tissue for sequencing. All six TSAs with MVHP were positive for *BRAF* V600E mutation (all *KRAS* wild-type) in both the MVHP and TSA components. Of the six TSAs with a GCHP two showed concordant *KRAS* mutant/*BRAF* wild-type genotype in both components, one showed concordant *BRAF* V600E mutant/*KRAS* wild-type genotype, and two were negative for both *KRAS* and *BRAF* mutation. In one case, the TSA was *BRAF* mutant but the GCHP component was wild type.

Conclusions: A precursor non-dysplastic serrated polyp was present in 22% of TSAs in which background mucosa was present in the polypectomy sample. 92% of TSAs showed concordant *BRAF/KRAS* mutation genotype in both components, which suggests that a significant subset of TSA arise from precursor non-dysplastic serrated polyps.

851 Reduced Membranous Expression of EpCAM-ICD Correlates with Poor Patient Outcome in Primary Colorectal Adenocarcinoma

A Wang, C-H Chen, D Hurlbut, R Ramjeesingh, N Hammad, S Davey, HE Feiltoer. Kingston General Hospital, Queen's University, Kingston, ON, Canada.

Background: Epithelial cell adhesion molecule (EpCAM) is a transmembrane glycoprotein involved in cell adhesion, signaling, migration, proliferation and differentiation. It is known to be expressed in normal epithelium and epithelial neoplasms. Altered EpCAM expression correlates with aggressive biological behavior in gastric, breast, renal and thyroid carcinomas. Recent studies have proposed the proteolytic cleavage of the intracellular domain of EpCAM (EpCAM-ICD) triggers a signalling cascade leading to the activation of the Wnt/ β -catenin pathway and aggressive tumour behavior. The expression profile and prognostic value of EpCAM-ICD have not been elucidated for primary colorectal carcinoma. In this study, we examined EpCAM-ICD expression in a large cohort of primary colorectal adenocarcinoma, and assessed its role as a potential prognostic marker and therapeutic target.

Design: EpCAM-ICD immunohistochemical expression was assessed in 137 primary colorectal adenocarcinoma resected in our institution between 2007 and 2008 using tissue microarrays. The presence and intensity of EpCAM-ICD membranous staining was independently scored by 3 pathologists. Patient chart review was performed for a wide range of clinicopathological parameters and correlated with the average staining score by the Pearson correlation coefficients, Mann-Whitney U-tests and two-tailed T-test.

Results: The membranous EpCAM-ICD staining was calculated as a weighted average, based on results from three core samples per tumour. EpCAM-ICD expression levels were positively associated with well (versus poorly) differentiated tumours ($n=18$; $p=0.05$), low preoperative serum carcinoembryonic antigen ($n=76$; $p=0.0002$), and 5 year survival ($n=128$; $p=0.01$). The presence of perineural invasion and macroperforation were associated with lower EpCAM-ICD staining scores, but small sample numbers precluded statistical analysis of these results.

Conclusions: Our study findings demonstrate that reduced EpCAM-ICD membranous expression may be a useful marker to identify tumours with aggressive clinical behavior and poor prognosis. Also, EpCAM-ICD expression in primary colorectal carcinoma may serve as a useful tool for defining a subgroup of patients who could benefit from targeted immunotherapy against the EpCAM antigen.

852 NIK- and IKK2-Binding Protein: A Novel Neuroendocrine Marker That Labels Cells with Unique Pattern of Distribution in Gastrointestinal Tract and Is Useful in Diagnosis of Neuroendocrine Tumor of the Rectum

C Wang, H Wang, Y Huang, W Hu, X Zhang. Temple University Hospital, Philadelphia, PA; Temple University School of Medicine, Philadelphia, PA; Mayo Clinic, Rochester, MN.

Background: NIK- and IKK2-binding protein (NIBP) is a key member of trafficking protein particle (TRAPP) complex II involved in trans-Golgi networking, and the maturation of neuroendocrine cells (NECs). Its overexpression has been associated with poor prognosis in patients with gastrointestinal (GI) malignancies. However, the distribution of NIBP expressing cells has not been studied in human GI tract and the value of NIBP in assisting the diagnosis of GI neuroendocrine tumors (NETs) is unknown.

Design: Immunohistochemistry (IHC) for NIBP was performed on normal tissues of excisional specimens from 10 esophagus, 10 stomach, 10 small intestine, 10 colon, 5 pancreas, and 25 cases of rectal NETs using one or two anti-NIBP antibodies (NP417 and TPPC9). The NETs were also stained with synaptophysin.

Results: NECs with NIBP expression were identified by NP417 in stomach, small intestine and colon with their numbers increased gradually from stomach to colon. These cells were predominantly located at the deep crypt of mucosal epithelium with a granular cytoplasmic staining pattern. Neurons and NECs in the muscularis propria failed to demonstrate NIBP immunoreactivity; and no NIBP expression was identified in the NECs of esophagus. Islet cells of pancreas were strongly positive for NIBP. Besides the NECs, plasmas cells, neutrophils and some mucinous cells in the GI tract were also stained weakly. 17 of 25 (68%) rectal NETs displayed cytoplasmic staining of NP417, and 19 of 25 (76%) were positive for TPPC9. Synaptophysin was positive in 21 of 25 NETs (84%). It was noticed that 4 synaptophysin-negative NETs demonstrated moderate to strong positivity for TPPC9, and 2 of which were also positive for NP417. By a combination of NIBP and synaptophysin IHC, the NETs were properly identified with a sensitivity of 100%.

Conclusions: NIBP is selectively expressed in a subset of NECs of GI tract and may serve as a novel neuroendocrine marker in identifying the NETs that fail to express synaptophysin. Additional investigation with a larger sample size is warranted to validate the findings and to further explore the clinical utility of NIBP immunostaining. The function of the subset of NIBP positive NECs also deserves further study.

853 Clinicopathologic Features and Frequency of KRAS Mutation in Colorectal Adenocarcinoma in Patients \leq 40 Years of Age

R Watson, T-C Liu, M Ruzinova. Washington University, St. Louis, MO.

Background: Colorectal cancer (CRC) in patients \leq 40 years (yr) of age was thought to be rare, and frequently arising in predisposing conditions such as Lynch syndrome, hereditary polyposis syndromes, or inflammatory bowel disease, and associated with poor outcome. Recent studies have reported complicated and contradictory

epidemiology, histology, genetics, and outcomes in these patients. The purpose of this study is to characterize the epidemiological, pathological, and molecular features of CRC in patients \leq 40yr of age in our institution.

Design: Clinical and pathological records from 100 consecutive CRC patients \leq 40yr of age at the time of diagnosis between 2006 and 2012 were reviewed. Clinical information obtained included age, gender, family history, predisposing factors, anatomic tumor site, stage, treatment, and outcome. Histological review included tumor grade, morphological features, extent of invasion, lymph node and distant metastases. Mismatch protein repair and *KRAS* mutation status were also obtained where available.

Results: In our cohort, the mean age at diagnosis was 33.9yr (range 18-40); 51% were male, 80% Caucasian and 17% African-American. Twelve percent had a first degree relative with CRC, while 40% had a family history of CRC in any relative. Only 16% of patients had a predisposing condition. Most cases presented in the left colon (63%), with 56% located in the rectosigmoid colon. Majority (69%) of the cases presented with stage III or IV disease, with 34% showing distant metastasis at presentation. Histologically, all tumors were adenocarcinomas, of which 22% had a mucinous component and 5% showed signet ring morphology. *KRAS* mutational analysis was performed in 45 patients, and among which, 57.8% harbored a *KRAS* mutation. MSI testing was performed in 46 patients; only 6 tumors (13%) showed high microsatellite instability (MSI). The median overall and recurrence-free survival was 27.9 and 16.9 months, respectively, with a mean duration of follow up of 35 months.

Conclusions: Our study showed that the majority of early onset CRC cases were not associated with predisposing conditions. We confirmed that most of these patients presented with tumors in the left colon and with late stage disease, and were rarely MSI-high. However, in contrast to recent studies where only a minority of these patients were shown to harbor activating *KRAS* mutations, the majority of patients in our cohort were positive for *KRAS* mutation. This finding is important for therapeutic and prognostic considerations, and emphasizes the importance of *KRAS* testing in younger patients with CRC.

854 Immunohistochemical and Molecular Evaluation of BRAF Mutations in Tumors of the Serrated Neoplastic Pathway

A-S Weidner, NC Panarelli, RK Yantiss, CP Vaughn, WS Samowitz, Y-T Chen. Weill Cornell Medical College, New York, NY; University of Utah, Salt Lake City, UT.

Background: Sessile serrated polyps (SSPs) frequently harbor *BRAF* mutations and are potential precursors to colonic adenocarcinomas with MSI-H phenotype. Our previous sequencing analysis of SSPs revealed that *BRAF*^{V600E} mutations often involved a minority of cells within mutation-positive polyps, but the distribution of cells harboring these mutations within the lesion is unknown. In this study, we evaluated *BRAF*^{V600E} mutational status by sequencing and immunohistochemistry in invasive adenocarcinomas and SSPs with and without cytologic dysplasia in order to determine the correlation between molecular and immunohistochemical testing for *BRAF*^{V600E} mutations and assess the distribution of *BRAF*^{V600E} mutated cells in preinvasive lesions.

Design: Sequencing assays for *BRAF*^{V600E} mutations were performed on 26 selected invasive adenocarcinomas, 39 SSPs, and 7 SSPs with dysplasia. All cases were stained with an antibody against mutated *BRAF* (Spring Bioscience, clone VE1) and reviewed in a blinded fashion. Cytoplasmic staining of neoplastic cells was considered a positive result. Staining was scored as either focal (\leq 50% of cells) or diffuse ($>$ 50% of cells) and intensity was scored from 0 to 4+.

Results: There were 16 *BRAF* mutated (100% MSI-H) and 10 *BRAF* wild-type (80% MSS, 20% MSI-H) invasive adenocarcinomas in the study group. Immunostains for *BRAF*^{V600E} were positive in 15 (94%) *BRAF* mutated carcinomas. Of these, 14 showed a 2+/4+ staining reaction in a diffuse ($n=13$) or focal ($n=1$) distribution and one displayed diffuse 1+/4+ staining. All *BRAF* wild-type tumors were negative for this marker (sensitivity: 94%, specificity: 100%). Sequencing assays detected *BRAF* mutations in 37 (95%) SSPs and 6 (86%) SSPs with dysplasia. Immunohistochemistry revealed 1+/4+ focal cytoplasmic staining for *BRAF*^{V600E} in only 3 of 43 cases, all without dysplasia. The staining was too focal in these cases to assess the distribution of positive cells in these lesions.

Conclusions: Immunohistochemical analysis of *BRAF*^{V600E} has a high correlation with sequencing assays in invasive colonic adenocarcinomas. However, the level of mutated *BRAF* protein in SSPs was below the detection threshold of this *BRAF*^{V600E} antibody in our analysis. Immunostaining with the currently available antibody is not a sensitive marker of *BRAF*^{V600E} mutations in serrated colonic polyps.

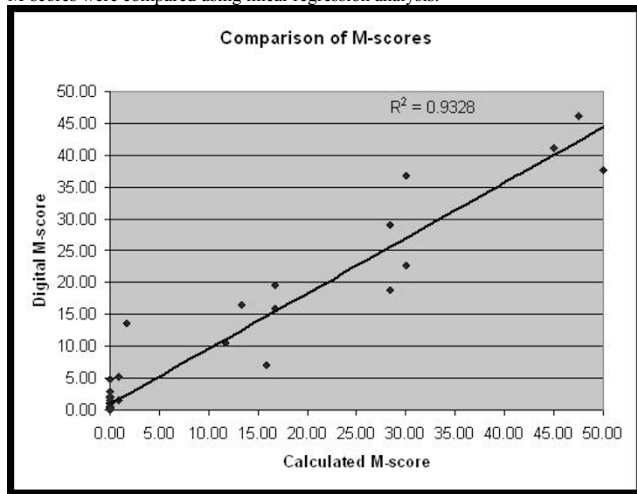
855 HER2 M-Scores in Gastric/Gastroesophageal Junction Adenocarcinomas: Comparison of Digital Image Analysis and Pathologist Interpretation

CL Whitney-Miller, BR Koltz, C Slusznny, DG Hicks, AR Huber. University of Rochester Medical Center, Rochester, NY; Rochester General Hospital, Rochester, NY; Applied Spectral Imaging, Ltd, Carlsbad, CA.

Background: Approximately 20% of gastric and gastroesophageal junction (GEJ) adenocarcinomas are HER2 positive (3+ overexpression by immunohistochemistry [IHC] or gene amplification by in situ hybridization [ISH]). In the ToGA trial, the addition of trastuzumab was shown to prolong survival in patients with advanced gastric and GEJ carcinomas. Prior studies have examined HER2 IHC scoring using digital image analysis (DIA) and some have implemented H-scores in their evaluation. The M-score is a quantitative measure of membrane staining with a calculated range of 0 to 50. We investigated the potential utility of a commercially available image analysis platform (IAP) in determining M-scores for HER2 expression in gastric/GEJ adenocarcinomas.

Design: 46 cases (29 biopsies and 17 resections) were reviewed from which 65 blocks were selected for IHC staining using the commercially available Hercep Test (DAKO). One pathologist estimated the M-score. Targeted DIA was then performed on fields selected by a second pathologist using Go-Path GenASIs (Applied Spectral Imaging)

which generated a separate M-score. DIA was performed by an independent third party familiar with the instrument and software; the pathologists were uninformed and blinded during DIA. When the pathologist derived and IAP derived M-scores were compared there were 9 very disparate cases. Review of those slides showed non-specific staining within tumor or crush artifact. These 9 cases were removed from the analysis. The M-scores were compared using linear regression analysis.



Results: The semiquantitative M-score obtained by the pathologist showed good agreement with the M-score determined by digital image analysis (CC 0.9328).

Conclusions: The M-score calculated by the pathologist is comparable to that done by digital image analysis. Areas of crush artifact and non-specific staining contributed to disparate results between image analysis and the pathologist interpretation and therefore careful selection of fields for analysis is important to help ensure the accuracy of the computer-assisted scoring.

856 Traditional Serrated Adenomas: A Morphologic, Immunohistochemical, and Molecular Assessment

H Wiland, D Allende, J Goldblum, X Liu, D Patil, B Shadrach, L Rybicki, R Pai. Cleveland Clinic, Cleveland, OH.

Background: Traditional serrated adenomas (TSAs) are rare colorectal polyps with malignant potential. Previous studies have suggested that TSAs may arise via a non-dysplastic serrated precursor lesion, and can harbor either BRAF or KRAS mutations. **Design:** We studied 56 left-sided TSAs diagnosed at a single institution between 2009-2013. Five subspecialty GI pathologists assessed each polyp for the following features: cytoplasmic eosinophilia, ectopic crypt foci, a non-dysplastic serrated precursor, and conventional dysplasia. Interobserver agreement was measured using kappa statistics. A subset of polyps were assessed for BRAF/KRAS mutations, CpG island methylation (CIMP), and annexin A10 (ANXA10) expression (a protein highly expressed in sessile serrated polyps (SSPs)).

Results: Upon review, 55/56 (98%) polyps had a consensus diagnosis of TSA. All polyps had cytoplasmic eosinophilia while 34/56 (61%) had ectopic crypts. Non-dysplastic serrated precursors were identified in 13 polyps (21%; 6 HP, 3 SSP, 4 unclassified) with a moderate level of interobserver agreement (kappa: 0.47). Conventional dysplasia was identified in 17 polyps (30%; 15 low grade, 1 carcinoma, 1 indeterminate grade) with a moderate level of interobserver agreement (kappa: 0.46). Only 2 polyps had ANXA10 expression in greater than 50% of serrated crypts. Twenty-five (25/53; 47%) polyps harbored a BRAF mutation, 23/53 (43%) harbored a KRAS mutation, and 5/53 (9%) polyps were wild type for both. CIMP was tested in 33 polyps and 7 (21%) were CIMP-high, 13 (39%) were CIMP-low, and 13 (39%) were CIMP negative. Upon multivariate analysis, there were no significant associations between clinical and morphologic features of TSAs and their molecular features. However, all 3 TSAs which harbored a precursor SSP demonstrated a BRAF mutation. Additionally, BRAF mutated TSAs and KRAS mutated TSAs showed different methylation patterns at the RUNX3 locus upon CIMP analysis ($p=0.018$).

Conclusions: TSAs appear to arise in the left colon via a non-dysplastic serrated precursor, and have potential to progress to conventional dysplasia and carcinoma. We found a moderate level of agreement in the recognition of precursor lesions and conventional dysplasia in TSAs. Although TSAs may harbor BRAF or KRAS mutations, these mutations are not associated with clinical or morphologic features; however, patterns of CpG methylation are different.

857 Expression and Clinical Significance of EGFR, IGF-1R and HER-2 in Patients with Ampullary Adenocarcinoma

MD Xia, MJ Overman, A Rashid, H Wang, MH Katz, JB Fleming, R Wolff, H Wang. University of Texas Medical Branch, Galveston, TX; University of Texas MD Anderson Cancer Center, Houston, TX.

Background: EGFR, IGF-1R and HER2 have been shown to play an important role in the pathogenesis of human malignancies and have been used as markers for targeted therapies for cancers. However their expression and role in ampullary adenocarcinoma (AA) has not been examined in detail.

Design: We retrospectively reviewed 106 cases of AA at our institution. Tissue microarrays were constructed using the formalin fixed paraffin embedded tissue with

three 1.0 mm cores from representative areas of each tumor. Immunohistochemical stains for EGFR, IGF-1R and HER-2 were performed on 4.0 μ m unstained slides from tissue microarrays. The staining results were evaluated for membranous staining using the modified HercepTest for gastrointestinal cancers independently by two pathologists. The results were correlated with the clinicopathologic parameters and survival.

Results: Strong (3+) expression of EGFR, IGF1R and Her2 was detected in 18 (17%), 26 (25%) and 0 (0%) AAs respectively. Overexpression of EGFR correlated with poorer overall survival (mean survival: 109.8 \pm 22.3 months in EGFR high group vs 164.2 \pm 10.6 months in EGFR low group, $P=0.04$). In multivariate analysis, EGFR overexpression is an independent prognostic factor for overall survival ($P=0.03$). However, no significant correlation between EGFR expression and other clinicopathologic factors were identified ($P>0.05$). No correlation between IGF-1R or Her-2 expression and survival or other clinicopathologic factors were observed in our patient population.

Conclusions: Our study showed that EGFR and IGF1R, but not Her2 are overexpressed in a subset of AAs. Strong membranous expression of EGFR is an independent predictor for overall survival in patients with AA.

858 Clinical Significance of Beta-Catenin and E-Cadherin Expression in a Large Cohort of Patients with Gastric Cancer

MD Xia, Y Xie, S Lee, D Tan. University of Texas Medical Branch, Galveston, TX; University of Texas MD Anderson Cancer Center, Houston, TX.

Background: Gastric cancer is a major health issue and is the second leading cause of death worldwide. Both beta-catenin and e-cadherin are adhesion molecules that have been shown to promote metastatic potential through epithelial-mesenchymal transition (EMT). The goal of this study is to explore relationship between the immunohistochemical expressions of these EMT markers with clinicopathologic parameters in patients with gastric cancer.

Design: We retrospectively reviewed 205 cases of gastric cancer that were previously diagnosed at University of Texas MD Anderson Cancer Center. Tissue microarrays were constructed using the formalin fixed paraffin embedded tissue with three 1.0 mm cores from representative areas of each tumor. The slides were stained with beta-catenin and e-cadherin and evaluated for membranous staining by H-score (intensity multiplied by percentage of tumor cells stained), modified HercepTest for gastric cancer and percentage of loss of membranous (LOM) staining. The results were analyzed using Chi-square, general linear model, and logistic regression model.

Results: Decreased membranous expression of e-cadherin and beta-catenin is correlated with worse overall survival ($p < 0.05$). In addition, loss of membranous staining of beta-catenin is also correlated with poorer overall survival ($p = 0.04$). Loss or decreased membranous staining for both e-cadherin and beta-catenin is significantly correlated with poorly differentiated tumors ($p < 0.05$). Loss of membranous staining in beta-catenin was associated with a diffuse Lauren-type (versus intestinal, $p=0.016$) whereas a strong membranous staining (3+) with beta-catenin had a significant lower rate of lymphovascular invasion ($p=0.011$). Moreover, strong (3+) membranous staining of both e-cadherin and beta-catenin is associated with H.pylori infection ($p < 0.05$).

Conclusions: Loss or decreased membranous expression of both e-cadherin and beta-catenin show poorer overall survival and also correlate with clinicopathologic parameters that indicate a more aggressive clinical behavior. Beta-catenin appears to be a better marker than e-cadherin since it shows significant correlation with more clinical parameters and may be a useful immunohistochemical prognostic marker for patients with gastric cancer.

859 Ethnic Differences in the Prevalence of Helicobacter pylori Infection and Gastric Pre-Neoplastic Lesions in US Veterans

Z Yan, C McPhaul, C Park, E Coss, N Rogers, B Cryer, RM Genta. UT Southwestern, Dallas, TX; Dalla VAMC, Dallas, TX; Miraca Life Sciences Research Institute, Irving, TX.

Background: In any community, differences in prevalence and manifestations of *H. pylori* infection are believed to be more related to socioeconomic status than to ethnic characteristics. We hypothesized that in US Veterans, a population of relatively uniform socioeconomic status, the prevalence of both *H. pylori* infection and intestinal metaplasia (IM) would show only minor variations amongst White, African-American, and Hispanic subjects.

Design: Topographically defined gastric biopsy specimens (2 each from corpus and antrum and 1 from the *incisura angularis*) were obtained from patients recruited into a trial designed to test a novel therapy for *H. pylori*. Two blinded pathologists used the Updated Sydney System to evaluate the biopsies. For this study arm, endpoints included: presence of *H. pylori* (detected by hematoxylin and eosin and anti-*Helicobacter* immunohistochemical staining, as needed); and presence and location of IM.

Results: We recruited 310 Veterans: 185 White (median age 63 years; 92% men), 97 African-American (median age 58 years; 86% men) and 28 Hispanic (median age 57 years; 82% men). The prevalence of *H. pylori* gastritis and IM in each group are summarized in Table 1. Intestinal metaplasia was found in the corpus of 2 (15.4%) of 13 Whites who had this lesion, in contrast to 9 (42.9%) of 21 African Americans (OR 4.12 95%CI 0.72 – 23.4).

Table 1. The prevalence of *H. pylori* gastritis and of intestinal metaplasia in the three ethnic groups

Ethnic group	Hp (+) (%)	IM (%)	IM in corpus (%)
White (n = 185)	64 (34.6)	13 (7.0)	2 (15.4) - 1 in Hp (+)
African American (n = 97)	67 (69.1)	21 (21.6)	9 (42.9) - 6 in Hp (+)
Hispanic (n = 28)	18 (64.3)	5 (17.9)	0

Conclusions: In spite of broadly similar socioeconomic backgrounds, both African-American and Hispanic Veterans had a much greater prevalence of *H. pylori* infection (combined OR 4.02; 95%CI 2.48 – 6.51; $p < .0001$) and IM (combined OR 3.47; 95%CI 1.71 – 7.07; $p < .001$) than White patients. Neither age nor sex differences amongst the

groups helped explain these differences. Particularly alarming was the higher prevalence of corpus IM, a powerful predictor of gastric cancer risk, in African-Americans; its absence amongst Hispanics, although surprising, may be due to the relatively small sample of these subjects included. If confirmed in larger studies, these data suggest that providers caring for minorities must have a high level of awareness regarding both *H. pylori* infection and gastric preneoplastic lesions.

860 Pre-Pouch Ileitis Following Proctocolectomy for Ulcerative Colitis: What Does It Mean?

S Yasir, LE Raffals, TC Smyrk. Mayo Clinic, Rochester, MN.

Background: Pouchitis is a known complication following proctocolectomy with ileal pouch-anal anastomosis. It can usually be managed with antibiotics. Inflammation of the ileum proximal to the pouch is less common and less well-understood, often raising consideration for Crohn's disease (CD). We documented the spectrum of pre-pouch pathology in a series of patients, then looked at clinical outcomes and attempted to establish clinicopathologic correlations.

Design: We searched the electronic pathology base for all biopsies submitted as "pre-pouch ileum" during the years 2008-2012. Among the 1183 cases meeting that criterion, we reviewed slides from a random selection of 100, categorizing both the pre-pouch and pouch as normal, active ileitis or active chronic ileitis, and noting the presence of erosion, ulcer, pyloric metaplasia or granuloma. We reviewed clinical records to see the current diagnosis (UC or CD) and document any perianal disease, fistula, stricture or upper GI pathology. Finally, we did a longitudinal histologic review for all patients currently classified as CD and a subset of those still called UC, categorizing all pouch and pre-pouch biopsies obtained from those patients.

Results: Among the initial set of 100 pre-pouch biopsies, 34 were normal, 13 had acute ileitis and 53 had active chronic ileitis. Erosions were seen in 14 biopsies, ulcers in 19, pyloric metaplasia in 10 and granulomas in 1. Only 4 pouch biopsies were normal, while 88 had active chronic pouchitis. The 100 biopsies came from 89 individual patients; among those, 23 had been given a new diagnosis of CD. Longitudinal review of all pre-pouch biopsies showed that the 23 CD patients differed from the UC group in having more pre-pouch biopsies (114 vs 64), more biopsies with active chronic ileitis (58 vs 19), more pyloric metaplasia (2 vs 0) and more granulomas (5 vs 0). Clinically, the CD group had more perianal disease (7 vs 1) and more stricturing/fistulizing disease (10 vs 2) than the UC group.

Conclusions: Pre-pouch inflammation can accompany chronic pouchitis; we found active chronic ileitis in 53% of pre-pouch biopsies. While granulomas and pyloric metaplasia are relatively uncommon and should raise consideration for CD, we suggest that no single histologic finding or set of findings in a single biopsy is diagnostic of CD. Pathologists should apply descriptive diagnoses to pre-pouch biopsies and histology should be one criterion for clinicians considering a change in diagnosis from UC to CD.

861 The Membranous Staining of N-Acetyltransferase 10 Reflects the Activation of Wnt-Signaling and Aggressive Phenotype of Sporadic Colorectal Cancers

B Zhang, H Zhang, H Liu, L Hou, T Li. Peking University Third Hospital, Beijing, China; Peking University First Hospital, Beijing, China.

Background: The crucial role of Wnt/ β -catenin signaling in progression of colorectal cancer (CRC) has been extensively documented in the latest decades, but the molecular details are still under exploration. Here, we demonstrated that membranous redistribution of NAT10 (N-acetyltransferase 10) protein from nucleolus correlated with Wnt-signaling activation and an aggressive phenotype of colorectal cancers.

Design: Paraffin-embedded specimens from 248 surgically resected colorectal carcinomas, all of which was confirmed to express mis-match repair genes (MMRs), were selected. Immunohistochemical staining of NAT10 and β -catenin was performed, respectively. And the correlations between NAT10 and β -catenin and clinicopathologic parameters were statistically analyzed.

Results: The staining of NAT10 was mainly stained in nucleoli of non-neoplastic gland cells, but for colorectal carcinomas, almost half of these cases (47.6%, 118/248) presented membranous staining of NAT10 in cancer cells. In addition, the membrane staining of NAT10 was also closely correlated with nuclear accumulation of β -catenin ($P < 0.001$), a hallmark of Wnt-signaling activation. Moreover, both of membranous staining of NAT10 and nuclear accumulation of β -catenin was frequent at the invasive front of cancer cells. The membrane staining of NAT10 was 106 out of 198 cases (53.5%) of advanced carcinomas while early carcinomas limited to submucosa was just 12/50 (24%), with a statistic difference ($P = 0.008$). About 69.8% (74/106) with lymphatic or distant organ metastasis at diagnosis showed membrane staining of NAT10, while in cases without metastasis, the proportion was only 31% (44/142) ($P < 0.001$). A linear positive correlation between membrane positive of NAT10 and the Dukes' stage was revealed ($P = 0.001$). Kaplan-Meier single-factor analysis and log-rank test showed a statistically significant survival disadvantage of patients' disease-free survival (DFS) in CRC with NAT10 membranous staining.

Conclusions: The data indicated that membrane redistribution of NAT10 should represent the progression of CRC, correlating with activation of Wnt-signaling, and could be predictive in evaluation of the potential of metastasis and prognosis of patients.

862 Delayed Specimen Collection May Artificially Damage the Mucosal Surface in Barrett's EMR Specimens

X Zhang, L Zhao, CD Guy, SJ McCall, DM Cardona, RA Burbridge, KS Garman, MS Branch, U Siddiqui, S-Y Xiao, I Waxman, J Hart. Duke University, Durham, NC; The University of Chicago, Chicago, IL.

Background: For Barrett's esophagus associated early neoplasia, endoscopic mucosal resection (EMR) is usually performed for visible lesions, both for treatment and for

accurate histological diagnosis. EMR specimens are free of many of the artifacts often present in small biopsy specimens. However, there has been increasing awareness among pathologists of the not uncommon presence of surface damage/artifact in EMR specimens. Because surface maturation is an important morphologic consideration when analyzing dysplasia, this artifact can be quite problematic in selected cases. The exact cause of this mucosal surface damage has not been clearly delineated. We hypothesize that delayed specimen retrieval may be the culprit for much of the mucosal surface damage observed in Barrett's EMR specimens.

Design: From the pathology archives of 2 institutions, 46 EMR specimens for Barrett's dysplasia were retrieved. In 26 cases, the endoscopists immediately removed each portion of resected mucosa and placed them in fixative. In 20 other cases, the resected mucosa was allowed to fall into the stomach and not retrieved until the end of the procedure. The slides from every case were reviewed by at least 2 GI pathologists. Two parameters (both indicating ex vivo damage) were scored in a semi-quantitative manner and analyzed with chi square method.

A. Surface detachment (assessing mechanical injury related to the cap resection device; defined as surface epithelial detachment devoid of inflammatory response):

Scores: 0, none; 1, focal surface epithelium detachment; 2, large areas of surface detachment.

B. Surface necrosis (assessing chemical/enzymatic injury from immersion in gastric contents, defined as mucosal necrosis devoid of inflammatory response):

Scores: 0, none; 1, necrosis limited to surface epithelium; 2, necrosis involving lamina propria

Areas of ulceration or erosion where an inflammatory exudate was present were not scored for either parameter.

Results: The specimens that were collected immediately demonstrated significantly less surface necrosis (acid/enzymatic damage) compared to those with delayed collection ($p = 0.001$). The degree of mechanical detachment was similar between the 2 groups ($p = 0.2$).

Table 1

Score	Surface Detachment		Surface Necrosis	
	Immediate	Delayed	Immediate	Delayed
0	9	5	21	6
1	12	14	4	7
2	5	1	1	7

Conclusions: Delayed specimen collection may cause significant mucosal surface damage and artifact in Barrett's EMR specimens. It is important to raise awareness of this avoidable pitfall among both endoscopists and pathologists.

863 High ALDH1 Expression in Malignant Colorectal Polyps Associates with High Risk of Tumor Metastasis

D Zhang, Q Si, P Macias, H Zhu. The Icahn School of Medicine at Mount Sinai, New York, NY.

Background: Malignant colorectal polyps are adenomatous polyps with invasive carcinoma. The management of such malignant colorectal polyps, i.e. polypectomy vs segmental resection, is often challenging and requires clinico-pathological correlation. Aldehyde dehydrogenase isoform 1 (ALDH1), a functional marker of stem cell and progenitor cell, is associated with tumor aggressiveness and poor survival in variety of human malignant tumors. The aim of the study is to determine the prognostic significance of various putative morphological features and the expression levels of ALDH1 in malignant polyps.

Design: We collected 74 cases of endoscopically-removed colorectal polyps from the pathology archive with histologically confirmed early (T1) invasive carcinoma. Adverse histological features including poorly differentiation, lymphatic invasion, margin of excision either positive, or less than 1 mm or indeterminate due to artifact are recorded. Clinical follow-up studies were carried out for an average length of 55.9 months. In addition, immunohistochemical study of ALDH1 was performed on randomly selected 20 cases of malignant polyps.

Results: In 45 out of 74 cases with colorectal polyps with adverse features, 13 (28.9%) had residual tumor or metastasis on subsequent follow up or resection; while only 1 out of 29 (3.4%) patients without adverse features had residual tumor ($P = 0.0062$, Fisher's exact test). In addition, 3 of 13 (23.1%) patients who had polyps with adverse features, but followed by negative results of rebiopsies at prior biopsy site, was later found to have residual tumor or metastasis. ALDH1 expression is much stronger in invasive carcinoma than adenoma or normal colonic mucosa. Furthermore, 4 out of 9 (44.4%) cases with positive ALDH1 expression in invasive carcinoma had either lung metastasis ($n = 2$) or lymph node metastasis ($n = 2$); while none of 11 cases with negative ALDH1 expression had metastasis (0/11, $P = 0.026$, Fisher's exact test).

Conclusions: Our study has demonstrated that malignant polyps without adverse features can be managed conservatively. In patients who had malignant polyps with adverse features, even after a negative set of rebiopsies, the risk of residual tumor or metastasis remains clinically significant. In addition, expression of ALDH1 in malignant polyps is associated with lymph node or distant metastasis and can be further used to predict prognosis and guide management of malignant polyps.

864 Sub-Classification of Colorectal Carcinoma: A Single Institution Evaluation of 204 Resections by MMR IHC, MSI PCR and BRAF V600E IHC (VE1)

G Zhang, C Lanigan, R Tubbs, TA Bal, B LaFleur, S Singh. Cleveland Clinic Foundation, Cleveland, OH; Ventana Medical Systems, Inc, Tucson, AZ.

Background: There is growing recognition that sub-classifying colorectal carcinoma is an essential aid for informing clinical decisions. Approaches for subclassification include MSI PCR, MMR IHC, and BRAF V600E (IHC/molecular). The study goals

were to determine the: (1) agreement between MSI and MMR status (2) percent BRAF V600E IHC positivity (3) percent of MLH1 deficiency and (4) percent MLH1 deficient, BRAF V600E positivity.

Design: This study evaluated 204 consecutive colorectal cancer resections at single academic institution using FFPE tissues. The antibodies MLH-1 (M1), PMS2 (EPR3947), MSH2 (G219-1129) and CONFIRM MSH6 (44), and the mutation specific BRAF V600E (VE1) were run on the BenchMark XT automated platform (Ventana Medical Systems Inc. Tucson, Arizona). MSI status was determined by the MSI Analysis System (Version 1.2, Promega, Madison, WI), and BRAF V600E molecular status by the ABI 3730 (Life Technologies, Grand Island, NY).

Results: In this cohort, 83% (169/204) were MSS, 17% (35/204) were MSI-H, 84% (172/204) were MMR proficient, 16% (32/204) were MMR deficient, and 12% (26/204) were MLH1 deficient. Average positive and negative agreement between MMR and MSI status (method of Cicchetti and Feinstein) was 95.5% and 99.1%. Overall agreement was 98.5%. Among BRAF IHC samples, 13.2% (27/204) were positive, 85.2% (174/204) were wildtype, and were 3 indeterminate. On repeat analysis, 2/3 were reclassified as positive. Among MLH1 deficient samples, 54% (14/26) were positive and 46% (12/26) were negative for BRAF V600E (VE1) IHC. Among the cases with both BRAF V600E IHC and sequencing results, 30/31 were in agreement: 13/13 negative agreement and 17/18 positive agreement (1 was IHC positive, sequence negative).

Conclusions: This study demonstrated high overall agreement between MMR IHC and MSI, and the predominance of MLH1 deficiency. The BRAF V600E (VE1) IHC positivity rate (13.2%) is comparable to the published mutation rate. As demonstrated in larger studies, there was a high overall agreement (30/31) for BRAF V600E status between Sanger sequencing and the VE1 antibody. Studies have also demonstrated a higher level of sensitivity for detection of BRAF V600E mutation by the BRAF V600E (VE1) antibody in comparison to some molecular methods including Sanger sequencing and PCR. A combination of the MMR and BRAF V600E (VE1) antibodies can be used effectively to aid sub-classification of colorectal carcinoma in the pathology laboratory.

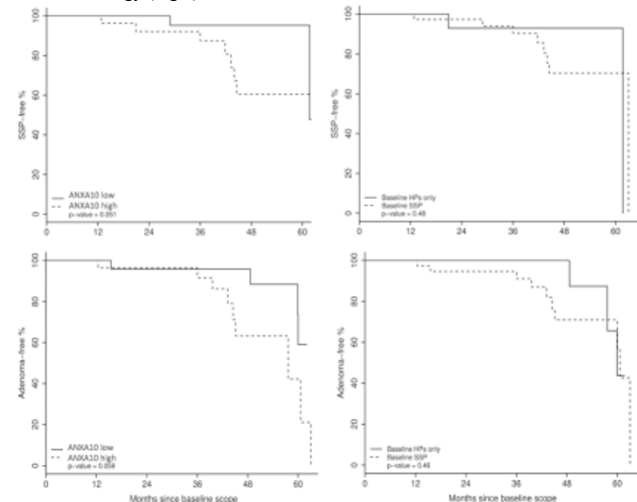
865 Expression of Annexin A10 in Serrated Polyps Predicts the Development of Metachronous Neoplasia

G Zhang, M Carole, R Lopez, P Carver, C Burke, R Pai. Cleveland Clinic, Cleveland, OH.

Background: Sessile serrated adenomas/polyps (SSA/Ps) are precursors to colorectal carcinoma (CRC) whereas small distal hyperplastic polyps (HPs) are considered innocuous. Guidelines recommend a shorter screening interval for patients with SSA/Ps compared to diminutive distal HPs. Distinguishing SSA/Ps from HPs can be challenging. Previously we showed increased annexin A10 (ANXA10) expression in SSA/Ps compared to HPs suggesting that ANXA10 may be a marker of the serrated pathway to CRC. In this study we evaluate the ability of ANXA10 expression in baseline serrated polyps to predict the development of metachronous polyps.

Design: 52 patients undergoing a baseline colonoscopy with only serrated polyps were selected (38 patients with SSA/P and 14 patients with HP). Immunohistochemistry for ANXA10 (Novus biologicals 1:100) was performed on baseline polyps. Polyps were scored as having high (positive in >50% of serrated crypts) or low expression (positive in <50% of serrated crypts). Patients were divided into two groups: ANXA10 high and ANXA10 low. The development of metachronous SSA/Ps and adenomas on follow-up colonoscopy was assessed. Time of follow up was months from baseline colonoscopy to either first follow-up colonoscopy showing neoplasia or last available scope. ANOVA and univariable Cox regression were performed.

Results: 24 patients were in the ANXA10 low group (12 patients with SSA/Ps and 12 with HPs) and 28 patients in the ANXA10 high group (26 patients with SSA/Ps and 2 with HPs). Compared with the ANXA10 low group, the ANXA10 high group had a higher risk of developing SSA/Ps (25% vs. 4.2%, $p=0.068$) and proximal adenomas (28.6% vs. 8.3%, $p=0.075$) within 5 years. Importantly, high ANXA10 expression at baseline may be a better predictor of the development of SSA/Ps and adenomas than baseline histology (Fig 1).



Conclusions: Our study suggests that ANXA10 expression in serrated polyps is a better predictor of the development of metachronous polyps than baseline polyp histology.

If confirmed in larger studies, this finding may impact surveillance for patients with serrated colorectal polyps.

866 MicroRNA Biomarker Differentiates Inflammatory Bowel Disease and Microscopic Colitis

Z Zhao, H Osman, R Watson, I Nalbantoglu, M Bronner, J Lin. Indiana University School of Medicine, Indianapolis, IN; Washington University, St Louis, MO; University of Utah and ARUP Laboratories, Salt Lake City, UT.

Background: Idiopathic inflammatory bowel disease (IBD) and microscopic colitis (MC) are distinct entities. However, patients with intermittent episodes of IBD and MC that are encountered clinically puzzle clinicians and pathologists. Differential microRNA expression pattern has been reported in IBD. This study examines whether microRNA markers assist in the classification of patients with alternating episodes of IBD and MC.

Design: MicroRNA was extracted from formalin-fixed, paraffin-embedded colon tissue and qRT-PCR was performed from cohorts of normal controls ($n=38$), ulcerative colitis ($n=36$), Crohn disease ($n=26$), collagenous colitis ($n=36$), lymphocytic colitis ($n=30$), and the study group with intermittent features of IBD and MC ($n=5$).

Results: Differential expression of miRNA-31 distinguished IBD (ulcerative colitis and Crohn disease) and MC (collagenous colitis and lymphocytic colitis), confirming the specificity of miRNA-31 in IBD ($P<0.05$). In the study group, one patient had matching miRNA-31 expression pattern at different phases (lymphocytic colitis to ulcerative colitis, then back to collagenous colitis). The other 4 patients had MC-like expression patterns at both MC and IBD episodes.

Conclusions: In summary, miRNA-31 is a specific biomarker that differentiates between IBD and MC in formalin-fixed, paraffin-embedded colon tissue. The expression patterns of miRNA-31 in patients with intermittent IBD and MC are diverse. Although the underlying mechanisms remain unknown, microRNA biomarkers could be useful to characterize the individual patient with alternating episodes of IBD and MC.

Genitourinary Pathology

867 Prognostic Significance of RICTOR Protein Expression in Prostatic Adenocarcinomas (PACs): Nuclear Immunoreactivity Independently Predicts Disease Recurrence

KF Afaneh, OR Elkadi, JS Ross, GM Sheehan, CE Sheehan, HAG Fisher, RP Kaufman, BVS Kallakury. Albany Medical College, Albany, NY; Georgetown University Hospital, Washington, DC.

Background: RICTOR is a core protein of the mTOR (mammalian target of rapamycin) pathway complex which plays a major role in cancer development and progression. Although RICTOR expression has been associated with breast cancer metastasis, its prognostic significance in prostate cancer has not been extensively studied.

Design: Formalin-fixed paraffin-embedded tissue sections from 114 PACs were immunostained by a manual method (DAKO LSAB+ System-HRP) using mouse monoclonal RICTOR (ab56578; Abcam, Cambridge, MA). Cytoplasmic and/or nuclear immunoreactivity was scored based on intensity and percentage of positive cells in both the tumor and adjacent benign epithelium in each case. Cases were assessed as tumor>benign (T>B), tumor=benign (T=B), and negative (N). Results were correlated with clinicopathologic variables.

Results: Either cytoplasmic (cRICTOR) and/or nuclear (nRICTOR) immunoreactivity was noted for the tumor and adjacent benign glands in all cases. nRICTOR was increased in tumors as compared to benign glands [T>B 45%, T=B 5%, N 50%], and correlated with tumor stage [T>B 59% adv vs 33% early, T=B 8% adv vs 3% early, N 33% adv vs 64% early; $p=0.006$] and biochemical disease recurrence [T>B 56% recur vs 34% non, T=B 6% recur vs 5% non, N 38% recur vs 61% non; $p=0.045$]. cRICTOR was also increased in tumors versus benign glands [T>B 61%, T=B 19%, N 20%], and correlated with tumor grade [T>B 70% HG vs 53% LG, T=B 8% HG vs 28% LG, N 22% HG vs 19% LG; $p=0.025$] and tumor stage [T>B 63% adv vs 59% early, T=B 10% adv vs 27% early, N 27% adv vs 14% early; $p=0.033$]. On multivariate analysis, nRICTOR independently predicted biochemical disease recurrence ($p=0.03$).

Conclusions: Both nuclear and cytoplasmic RICTOR expression are significant biomarkers of adverse prognosis in prostate cancer. Nuclear RICTOR expression is an independent predictor of biochemical disease recurrence. Further study of RICTOR expression and its potential role in prostate cancer appears warranted.

868 Inverted/Endophytic Growth Pattern of Papillary Urothelial Neoplasms of the Bladder: Clinicopathological Study in 225 Transurethral Resection Specimens

AS Akki, K Richards, ND Smith, GD Steinberg, GP Paner. University of Chicago, Chicago, IL.

Background: Inverted growth in papillary urothelial neoplasm (PUN) is a well-recognized morphologic variation that may mimic invasive urothelial carcinoma. The clinical significance of inverted growth in PUN is unclear, and to date, no large clinicopathological study has investigated PUNs with inverted growth pattern.

Design: A histopathological review of 259 bladder transurethral resection (TUR) specimens (from 115 patients) from a single tertiary institution was conducted. Of these, 225 TURs contained PUNs that were included in the study. 34 TURs with CIS, urothelial papilloma or other benign lesions (from 14 patients) were excluded. Inverted growth was defined as non-invasive intrusion of PUN into the lamina propria. The inverted component within a PUN was quantified after delineating the surface and exophytic papillary components (i.e. non-inverted parts). Patients were followed for recurrence from first presentation (initial TUR, 1 month to 7 years follow-up). Correlation analysis was performed by Fischer's exact test.