Diagnosis | **Severe prognathic malocclusion**

Laboratory mice are characterized by monophyodont dentition, meaning that they possess only one set of teeth throughout their entire lives. Rodent incisors and molars are examples of rootless teeth, in which the root canal remains open and the tooth continues to grow indefinitely. Mice have four incisors, two maxillary (upper) incisors, and two mandibular (lower) incisors. Canine teeth and anterior premolars are absent—the toothless space between the incisors and molar (cheek) teeth is known as the diastema. The incisor teeth of mice (**Fig. 2**) grow continually throughout life and are modified to form chisel-like cutting structures that remain permanently sharp. There are no nerves in the incisors except at the base of the tooth where growth occurs. The incisors are curved and continuously pushed out of the jaw, compensating for the portion that is worn away through normal use. The outer (or front) surface of the incisors is coated in hard enamel and the inner (or back) surface coated in softer dentin. As enamel is harder than dentin, the outer surface wears down more slowly and the incisors remain sharp. The incisor crowns wear away and are completely replaced every forty to fifty days[2].

Through uneven wear of the teeth or misalignment of the jaw, a malocclusion may become evident[3]. A malocclusion is generally defined as an irregular alignment of the teeth. Dental malocclusion is a common abnormality in laboratory mice and has been characterized extensively both physiologically and genetically[4]. Usually the lower incisors project in front of the upper incisors because the mandible sticks out markedly (*i.e.*, prognathism). Synonyms for prognathic malocclusion include mandibular prognathism, brachygnathia, hypognathia, malocclusion, walrus teeth, and buck teeth. As a potentially heritable trait, the severity of malocclusion is dependent upon a number of environmental and genetic factors[3,5]. If left untreated, malocclusion may lead to malnourishment and eventual premature death as feed prehension becomes more difficult. In extreme cases, the upper and lower incisors do not meet, resulting in rapid overgrowth of the incisors. With severe overgrowth, the mandibular incisors grow into the nares and the maxillary incisors grow into the soft tissue of the jaw.

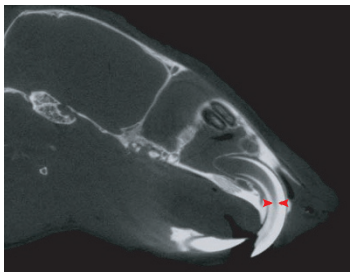

FIGURE 2 | Computed tomographic image of a normal 10-week-old juvenile mouse showing a sagittal cross-section of the maxillary open-rooted incisor. Red arrowheads indicate the boundaries of the open incisor root.

In this runted mouse, we characterized the incisor malocclusion using computed tomography (CT) imaging techniques. To visually characterize the severity of the malocclusion and growth patterns of the occluded teeth, high resolution volumetric CT scans were performed posthumously on both mutant and control mice at 27 μm^3 isometric voxel resolution using an eXplore Locus RS microCT small animal scanner (GE Healthcare, London, Ontario, Canada). This volumetric scanner employs a 3,500 × 1,750 CCD detector, uses the Feldkamp cone-beam reconstruction, and is similar in design to other commercially available *in-vivo* scanners. In this study, the platform-independent parameters of current, voltage, and exposure time were kept constant at 450 µA, 80 kVP, and 2,000 ms, respectively. The scan comprised 720 evenly spaced views with an average of 10 frames per view. Each scan took approximately six hours. The images were reconstructed with the manufacturer's proprietary EVSBeam software, and preliminary visualizations (not shown) and cross-sections were generated with the open-source MicroView program. Visual renderings of the digitized image were created using *Nenners*[6], a direct volume rendering software package, as previously described.

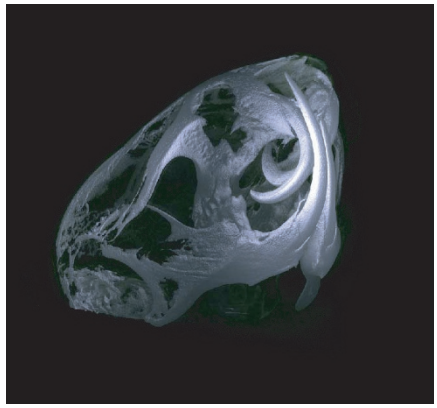

FIGURE 3 | Volumetric digital rendering of dental malocclusion in a 3-month-old mouse (same mouse as **Figure 1**). For orientation purposes, the rostrad skull is up and to the right and caudad is down and to the left. This orientation was chosen to allow the observer to appreciate the degree of dental malformation. The elongation of the right mandibular incisor and the extreme curvature of both maxillary incisors highlight the severity of the malocclusion. The tip of the left maxillary incisor penetrates the hard palate near the right anterior palatine foramen. The gross misalignment of the maxillary and mandibular molars is also evident from this scan.

The resulting image depicted the grossly overgrown lower incisors misaligned rostrad relative to the maxillary incisors (**Fig. 3**). Remarkably, both upper incisors curved inward and upard as they grew, with the left maxillary incisor penetrating the hard or bony palate near the right anterior palatine foramen. This is indicative of a helical pattern suggested in hypothetical unrestrained growth of rodent incisor dentition due to asymmetrical *Notch2*

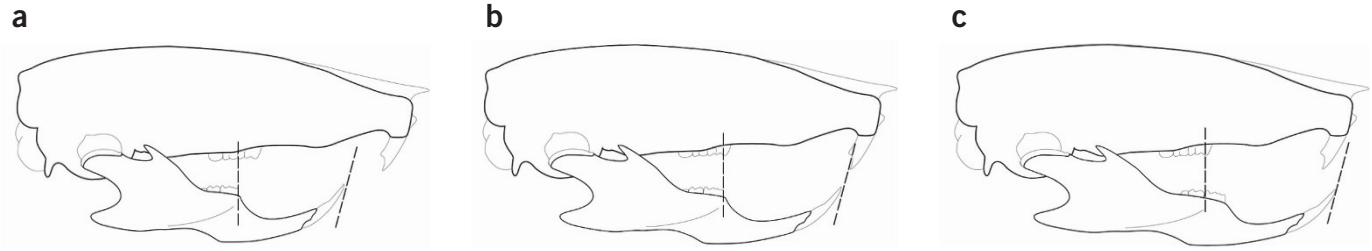

FIGURE 4 | Classification of dental misalignments: (**a**) type II malocclusion ('overbite'); (**b**) normal occlusion; and (**c**) type III malocclusion ('underbite').

gene expression in basal tooth epithelium[7]. Mandibular molars were also misaligned rostrad to the maxillary molars, which suggested a diagnosis of a class III malocclusion, commonly referred to in humans as an 'underbite' (**Fig. 4**). Lastly, and as a point of note, both infraorbital foramina of the runted mouse were misshaped and bilaterally asymmetrical, suggesting phenotypic abnormalities of the overall skull and not just of the dentition.

In mice with incisor malocclusion, treatment consists of trimming the elongated incisors to a length slightly shorter than normal. Trimming the incisors too short may cause pulp cavity exposure, with potential for infection of the tooth root canal. The ideal instrument for trimming is a high-speed water-cooled dental burr (not a regular high-speed burr, as it becomes very hot). Trimming with a dental burr should be done under anesthesia. Small Mueller rongeurs can also be used. When using Mueller rongeurs do not cut the tooth in one movement, but slowly snip off small fragments of the tooth until a suitable length is reached. Most mice will tolerate this procedure without anesthesia or sedation.

Mice with incisor malocclusion need regular trimming for life, as clipping of the overgrown portion of the incisors only provides temporary remediation of the condition. In a valuable transgenic animal, surgical removal of all the upper and lower incisors could be attempted. This is a common procedure in pet rodents and rabbits with incisor malocclusion. The roots of the maxillary and mandibular incisors are long, and the maxillary incisors are curved in a half-moon shape. The entire tooth must be removed to prevent regrowth or abscessation of root remnants. A mouse without incisors can eat by prehending feed with its lips and chewing the ingested feed with its molars. However, softened or mashed rodent blocks must be placed on the cage floor, as a mouse without incisors cannot gnaw rodent feed blocks placed in the feeder part of the wire cage lid.

1. Keller, C., Hansen, M.S., Coffin, C.M. & Capecchi, M.R. Pax3:Fkhr interferes with embryonic Pax3 and Pax7 function: Implications for alveolar rhabdomyosarcoma cell of origin. *Genes Dev.* **18(21)**, 2608–2613 (2004).
2. Crossley, D. Clinical aspects of rodent dental anatomy. *J. Vet. Dent.* **12(4)**, 131–135 (1995).
3. Millar, S.E. *et al.* Over- and ectopic expression of Wnt3 causes progressive loss of ameloblasts in postnatal mouse incisor teeth. *Connect. Tissue Res.* **44(Suppl 1)**, 124–129 (2003).
4. Peterkova, R., Peterka, M. & Lesot, H. The developing mouse dentition: a new tool for apoptosis study. *Ann. NY Acad. Sci.* **1010**, 453–466 (2003).
5. Townsend, G.C., Aldred, M.J. & Bartold, P.M. Genetic aspects of dental disorders. *Aust. Dental J.* **43(4)**, 269–286 (1998).
6. Johnson, J.T. *et al.* Virtual histology of transgenic mouse embryos for high-throughput phenotyping. *PLoS Genet.* **2(4)**, e61 (2006).
7. Mucchielli, M-L. & Mitsiadis, T.A. Correlation of asymmetric *Notch2* expression and mouse incisor rotation. *Mech. Dev.* **91(1–2)**, 379–382 (2000).

LAB ANIMAL welcomes reader contributions to "What's Your Diagnosis" in case history/diagnosis format. Submissions should include two to five illustrations or photos. Please email manuscripts to editors@labanimal.com. Selections are made on the basis of relevance and interest to readers. Please refer to the Guide to Authors for information on submission of digital figures.