Journal of Human Genetics (2016) 61, 765–769

www.nature.com/jhg

SHORT COMMUNICATION

Beckwith–Wiedemann syndrome and pseudohypoparathyroidism type Ib in a patient with multilocus imprinting disturbance: a female-dominant phenomenon?

Shinichiro Sano[1,2], Keiko Matsubara[1], Keisuke Nagasaki[3], Toru Kikuchi[4], Kazuhiko Nakabayashi[5], Kenichiro Hata[5], Maki Fukami[1], Masayo Kagami[1] and Tsutomu Ogata[1,2]

Although recent studies have often revealed the presence of multilocus imprinting disturbance (MLID) at differentially methylated regions (DMRs) in patients with imprinting disorders (IDs), most patients exhibit clinical features of the original ID only. Here we report a Japanese female patient with Beckwith–Wiedemann syndrome and pseudohypoparathyroidism type Ib. Molecular studies revealed marked methylation defects (MDs) at the *Kv*-DMR and the *GNAS*-DMRs and variable MDs at four additional DMRs, in the absence of a mutation in *ZFP57*, *NLRP2*, *NLRP7*, *KHDC3L* and *NLRP5*. It is likely that the MDs at the *Kv*-DMR and the *GNAS*-DMRs were sufficient to cause clinically recognizable IDs, whereas the remaining MDs were insufficient to result in clinical consequences or took place at DMRs with no disease-causing imprinted gene(s). The development of MLID and the two IDs of this patient may be due to a mutation in a hitherto unknown gene for MLID, or to a reduced amount of DNA methyltransferase-1 (DNMT1) available for the methylation maintenance of DMRs because of the consumption of DNMT1 by the maintenance of X-inactivation. In support of the latter possibility, such co-existence of two IDs has primarily been identified in female patients, and MLID has predominantly been identified as loss of methylations.
Journal of Human Genetics (2016) **61,** 765–769; doi:10.1038/jhg.2016.45; published online 28 April 2016

INTRODUCTION

Recent studies have indicated the presence of multilocus imprinting disturbance (MLID) at differentially methylated regions (DMRs) in a subset of patients with imprinting disorders (IDs).[1] The underlying factor(s) for MLID remains elusive, although mutations of *ZFP57*, *NLRP2*, *NLRP7*, *KHDC3L* and *NLRP5* have been reported in several patients with MLID.[2–6] Although most patients with MLID exhibit clinical features of the original IDs alone, several patients manifest clinical features of two different IDs in the presence of MLID.[2,6–10] Of note, such patients are primarily females and have loss of methylations (LOMs) rather than gain of methylations (GOMs) at disease-specific DMRs.

Here we report a Japanese female patient with Beckwith–Wiedemann syndrome (BWS) and pseudohypoparathyroidism type Ib (PHP-Ib) phenotypes and LOM-dominant MLID, and discuss the underlying factor(s) leading to the development of two IDs and LOM-dominant MLID in a female-dominant manner.

CASE REPORT

This Japanese female patient was born to healthy non-consanguineous parents at 35 weeks of gestation, after natural conception. Her birth length was 50.0 cm (+2.1 s.d. for her gestational age), and her birth weight 3.1 kg (+2.1 s.d.). She had BWS-compatible phenotypes such as macroglossia, umbilical hernia, right hemihyperplasia and transient neonatal hypoglycemia. Subsequent clinical follow-up confirmed BWS phenotype including postnatal overgrowth (Figure 1). Annual routine laboratory tests indicated gradually decreasing serum calcium value from ~ 9 years of age. At 14 years of age, while there was no episode of tetany or convulsion, she was found to have obvious hypocalcemia (1.9 mmol l^{-1}) (normal range, 2.2–2.7 mmol l^{-1}) and hyperphosphatemia (1.9 mmol l^{-1}) (0.95–1.75 mmol l^{-1}), in the presence of elevated serum intact parathyroid hormone value (20.6 pmol l^{-1}) (0.95–6.80 pmol l^{-1}). She had no Albright's hereditary osteodystrophy. Thus, she was diagnosed as having PHP-Ib, and was placed on vitamin D supplementation therapy. There was no other clinically

[1]Department of Molecular Endocrinology, National Research Institute for Child Health and Development, Tokyo, Japan; [2]Department of Pediatrics, Hamamatsu University School of Medicine, Hamamatsu, Japan; [3]Division of Pediatrics, Department of Homeostatic Regulation and Development, Niigata University Graduate School of Medical and Dental Sciences, Niigata, Japan; [4]Department of Pediatrics, Faculty of Medicine, Saitama Medical University, Saitama, Japan and [5]Department of Maternal-Fetal Biology, National Research Institute for Child Health and Development, Tokyo, Japan
Correspondence: Professor T Ogata, Department of Pediatrics, Hamamatsu University School of Medicine, 1-20-1, Handayama, Higashi-ku, Hamamatsu, Shizuoka 431-3192 Japan.
E-mail: tomogata@hama-med.ac.jp
Received 17 December 2015; revised 16 February 2016; accepted 5 April 2016; published online 28 April 2016

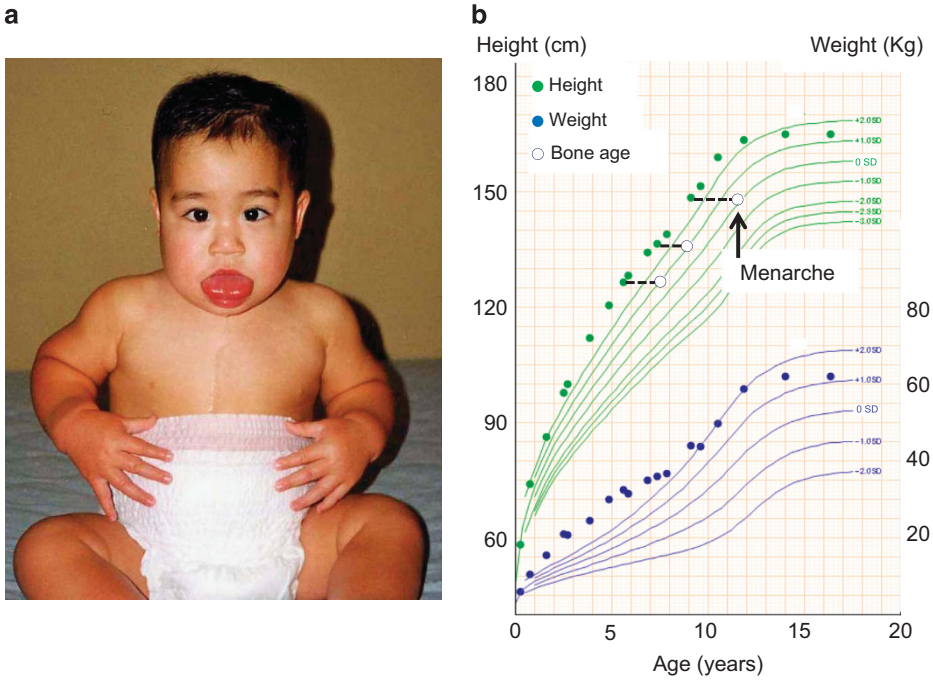

Figure 1 Clinical findings of this patient. (**a**) Photograph at 1 year of age. (**b**) Growth chart.

discernible feature. At present, she is 16 years old, and has normal serum calcium values.

MOLECULAR STUDIES

This study was approved by the Institutional Review Board Committee at National Center for Child Health and Development, and performed using leukocyte genomic DNA samples after obtaining written informed consent.

Methylation analysis was carried out for 12 DMRs (75 CpG sites) involved in the development of previously known IDs by pyrosequencing with PyroMark Q24 (Qiagen, Hilden, Germany), and for 49 DMRs (761 CpG sites) distributed widely in the genome by HumanMethylation450 BeadChip (Illumina, San Diego, CA, USA) (Supplementary Methods). Genomewide array comparative genomic hybridization (aCGH) and SNP array were performed using a catalog array (SurePrint G3 Human CGH+SNP 4×180 K & CGH 1×1 M formats) (Agilent Technologies, Palo Alto, CA, USA). Microsatellite genotyping and Sanger sequencing were performed on ABI 3130xl Genetic Analyzer (Life Technologies, Carlsbad, CA, USA), and whole exome sequencing on HiSeq sequencer (Illumina) using SureSelect Human All Exon V4 kit. Primers utilized are shown in Supplementary Table 1.

Methylation analysis showed marked LOM at the *Kv*-DMR and severe methylation defects (MDs) at the *GNAS*-DMRs (that is, LOMs at the *AS*-DMR, the *XLas*-DMR, and the *A/B*-DMR, and GOM at the *NESP55*-DMR) as the causative factors for the development of BWS and PHP-Ib, respectively (Figure 2a; Supplementary Figure 1).[11,12] There was no GOM at the *H19*-DMR as an underlying factor for the occurrence of BWS. Copy-number alteration and uniparental disomy involving these DMRs were excluded by aCGH, SNP array and microsatellite analyses (Figures 2b and c; Supplementary Table 2). Direct sequencing identified no mutation in *CDKN1C* (NM_000076) for BWS and *GNAS* (NM_000516) for PHP-Ia.[11,12]

Methylation analysis also revealed mild LOMs at the *PEG1/MEST*-DMR and the *RB1*-DMR, and severe LOMs at the *DIRAS3*-DMR and the *FAM50B*-DMR (Figure 2a; Supplementary Figure 1). aCGH and SNP analyses for chromosomes harboring such DMRs showed normal findings (Supplementary Figure 2). No mutation was found in *ZFP57* (NM_001109809), *NLRP2* (NM_001174081), *NLRP7* (NM_206828), *KHDC3L* (NM_001017361) and *NLRP5* (NM_153447) by exome sequencing.

DISCUSSION

This patient had overt BWS and PHP-Ib phenotypes and marked MDs at the *Kv*-DMR and the *GNAS*-DMRs. Clinical course of this patient is consistent with BWS being usually recognizable from infancy and PHP-Ib being usually discernible from childhood,[11,13] and molecular data indicate the occurrence of epimutations. To our knowledge, this is the second case with obvious BWS and PHP-Ib phenotypes in the presence of marked MDs at the corresponding disease-specific DMRs.[10] In this regard, while several BWS patients with LOMs at the *Kv*-DMR have MDs at the *GNAS*-DMRs, they are free from PHP-Ib phenotype.[1,6,14] This may be explained by assuming that the degree of MDs at the critical CpG sites within the *GNAS*-DMRs remained at a subclinical level in the target tissues for PHP-Ib.

This patient also had variable degrees of MDs at additional four DMRs. The mild LOM at the *PEG1/MEST*-DMR might have had a certain role in overgrowth, because overgrowth has been described in patients with PHP-Ib accompanied by LOM at the *PEG1/MEST*-DMR.[1,15] By contrast, as there was no other abnormal phenotype, it appears that the remaining three MDs were insufficient to result in clinical consequences or took place at DMRs with no disease-causing imprinted gene(s).

To our knowledge, co-existence of two clinically recognizable IDs has been reported in nine cases including this patient (case 1) (Table 1). Cases 2–9 were identified by a thorough literature search. Actually, ~230 patients of both sexes were found to have MLID (the precise patient number is uncertain, because several patients appear to have been reported repeatedly in plural papers) (Supplementary References). Although most of them had clinical features of a single original ID alone, eight of them (cases 2–9) exhibited two clinically

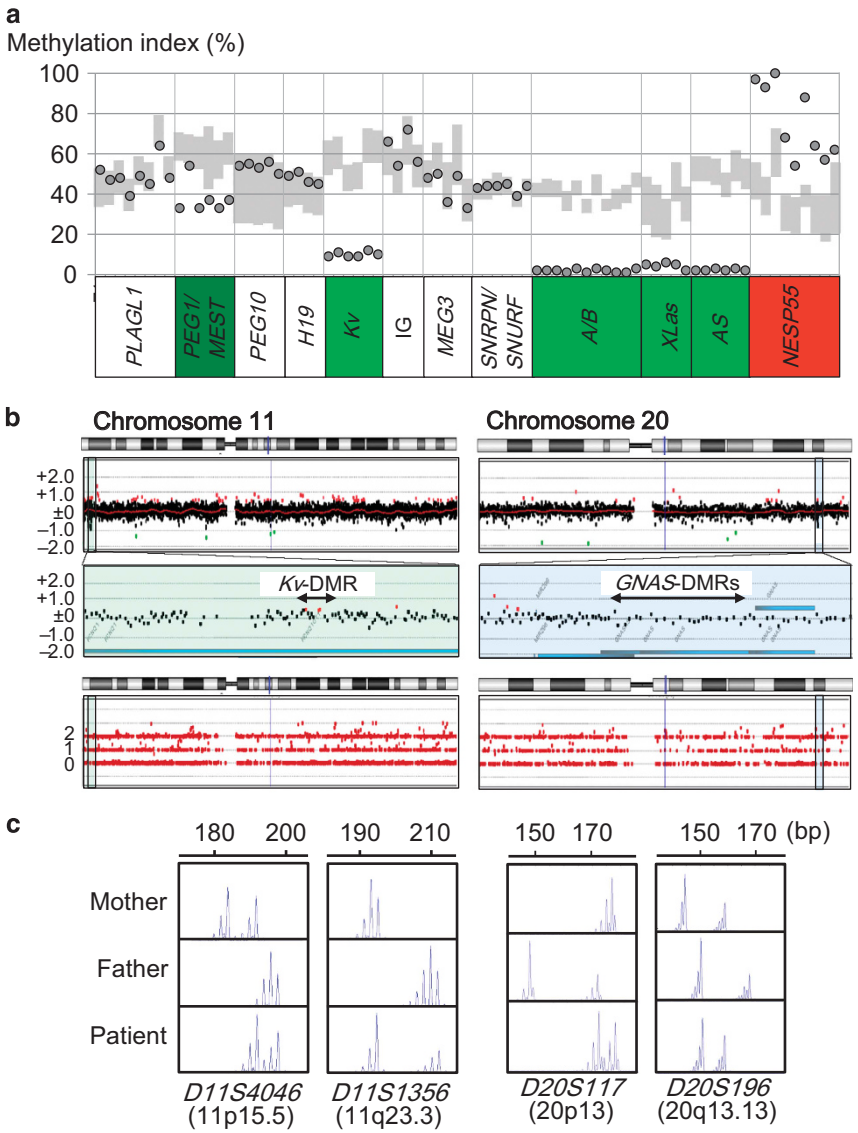

Figure 2 Molecular findings. (**a**) Methylation indices obtained by pyrosequencing for 12 DMRs. Gray vertical bars indicate the reference ranges (minimum–maximum) in 50 control subjects. (**b**) aCGH and SHP array findings for chromosomes 11 and 20. In aCGH, the black, the red and the green dots denote signals indicative of the normal, the increased ($\log_2$ signal ratio $>+0.4$) and the decreased ($\log_2$ signal ratio <-0.8) copy numbers, respectively. In SNP array, the dots for $\log_2$ signal ratios of '0 or 2' and '1' denote homozygous and heterozygous regions, respectively. (**c**) Microsatellite analysis indicating biparental origin of the examined loci.

discernible IDs. In particular, cases 1–3 and 6–8 have two overt IDs in the presence of MDs at the corresponding disease-specific DMRs, although the clinical diagnosis is not definitive in cases 4, 5 and 9, and a simple epigenotype–phenotype correlation is difficult in case 4. Notably, all the affected DMRs exhibit LOMs except for the *NESP55*-DMR that manifests GOM. Furthermore, cases 1–6 are females and born after natural conception, although such information is not available in cases 7–9.

Two possibilities are considered for the development of MLID and $\geqslant 2$ IDs. One possibility is a mutation of genes involved in the occurrence of MLID. Indeed, cases 2 and 3 have a homozygous *ZFP57* mutation, and case 4 has a heterozygous *NLRP5* mutation.[2,6] It is postulated that $\geqslant 2$ IDs can take place when a mutation has caused profound MDs at the corresponding disease-specific DMRs. For the *NLRP5* mutation, however, the mother homozygous for the mutation is clinically normal, and no clinical information is available for three brothers who are also predicted to be heterozygous for this mutation. Thus, while maternal homozygosity (and compound heterozygosity as well) has been suggested as a critical factor for the occurrence of MLID, further studies would be necessary to clarify underlying mechanism(s). In this regard, while this patient (case 1) had no mutation in *ZFP57*, *NLRP2*, *NLRP7*, *KHDC3L* and *NLRP5*, this does not exclude the possible relevance of a hitherto unknown gene(s) to MLID. Unfortunately, such a mutation analysis remained incomplete in cases 5 and 9, and has not been performed in cases 6–8.

The other possibility is a reduced amount of DNA methyltransferase-1 (DNMT1) available for the methylation maintenance of DMRs because of the consumption of DNMT1 by the maintenance of X-inactivation from the blastocyst stage.[16] Indeed, cases 1–6 are invariably females, and MLIDs are predominantly exhibited as LOMs. It is assumed that a few severe and widely distributed LOMs at the disease-specific DMRs, which would be generated at the early developmental stage, can lead to

Table 1 Summary of patients with definitive or possible co-existence of two imprinting disorders

	Case 1	*Case 2*[a]	*Case 3*[a]	*Case 4*	*Case 5*	*Case 6*	*Case 7*	*Case 8*	*Case 9*
Age (year)	16	$5\frac{7}{12}$	$0\frac{11}{12}$	$3\frac{6}{12}$	17	$12\frac{5}{12}$	Unknown	Unknown	Unknown
Sex	Female	Female	Female	Female	Female	Female	Unknown	Unknown	Unknown
Phenotype	BWS (typical)	TNDM (confirmed)	TNDM (confirmed)	PWS? (developmental delay, obesity)	SRS (typical)	BWS (typical)	TNDM (confirmed)	TNDM (confirmed)	TNDM? (hyperglycemia)
	PHP-Ib (confirmed)	BWS (macroglossia, postnatal overgrowth)	BWS (macroglossia, umbilical hernia, ear lobe creases)	BWS? (macroglossia, single palmer creases)	BWS? (umbilical hernia)	PHP-Ib (confirmed)	BWS (macroglossia, umbilical hernia)	BWS (macroglossia, umbilical hernia)	BWS (macroglossia, abdominal abnormality, overgrowth)
Phenotype-related DMRs with methylation defects[b]	*Kv*, *A/B*[c], *XLas*[c], *AS*[c], *NESP55*[c]	*PLAGL1*, *Kv*	*PLAGL1*, *Kv*	*SNRPN*[d], *Kv*	*H19*, *Kv*	*Kv*, *A/B*[c], *XLas*[c], *AS*[c], *NESP55*[c]	*PLAGL1*, *Kv*	*PLAGL1*, *Kv*	*PLAGL1*, *Kv*
Other associated DMRs with methylation defects[b]	*DIRAS3*, *FAM50B*, *PEG1/MEST*, *RB1*	*GRB10*, *PEG1/MEST*, *PEG3*, *AS*[c]	*GRB10*, *PEG1/MEST*, *PEG3*	*H19*, *PEG3*, *PEG1/MEST*, *A/B*[c], *XLas*[c], *AS*[c], *WRB*, *IGF1R*	Not identified	Not examined	Not examined	*PEG1/MEST*	*IGF2R*, *PEG1/MEST*
Conception	Natural	Natural	Natural	Natural	Natural	Natural	Unknown	Unknown	Unknown
Maternal/paternal age at childbirth (years)	33/34	18/25	22/29	34/42	Unknown	Unknown	Unknown	Unknown	Unknown
Mutation of a gene for MLID	Not identified	*ZFP57* (p.C241X) Homozygous[e]	*ZFP57* (p.C241X) Homozygous[e]	*NLRP5* (p.M567V) Heterozygous[f]	Not identified	Not examined	Not examined	Not examined	Not identified
Remarks		Normocalcemia	Deceased	Normocalcemia	…	…	…	IUGR no overgrowth	Cardiac anomaly, duplex kidneys, scoliosis, osteoporosis
Reference (Supplementary reference)[g]	This report …	2,7 (26,27)	2,7 (26, 27)	6,8 (2, 20)	9 (19)	10 (3)	… (31)	… (28, 29[h])	… (11)

[a]Siblings born to consanguineous parents.
[b]Evaluated for leukocyte DNA samples. All DMRs exhibit hypomethylations except for the *NESP55*-DMR that manifests hypermethylation.
[c]These DMRs reside at the *GNAS* region.
[d]The *SNRPN*-DMR is hypomethylated in case 3 as in Angelman syndrome patients; while it is usually hypermethylated in PWS patients, hypomethylated *SNRPN*-DMR has been reported in exceptional patients with PWS phenotype.[20]
[e]The parents and the third child heterozygous for this mutation are clinically normal.
[f]This mutation has been inherited from her healthy mother homozygous for the mutation; no clinical information is available for three brothers who are also predicted to be heterozygous for this mutation.
[g]See Supplementary References.
[h]Probably reported as patient 4 in Supplementary Ref. 28 and as patient 1 in Supplementary Ref. 29.

clinically recognizable IDs. Importantly, this notion is consistent with the co-existence of two IDs being observed in an apparently female-dominant manner. Such relevance of a reduced amount of DNMT1 to the development of ID has also been postulated for the female dominance of monozygotic twins discordant for BWS with LOM at the *Kv*-DMR.[16]

LOMs have predominantly occurred at the maternally inherited DMRs. This would be explained as a simple stochastic event, because most methylated DMRs are of maternal origin.[17] In addition, it is possible that the sex difference in the establishment and maintenance of methylation during gametogenesis is relevant to this finding,[18] and that the maternally inherited DMRs are more susceptible to LOMs than paternally derived DMRs.[14]

Several patients with MLID and $\geqslant 2$ IDs may remain unrecognized. In particular, the diagnosis of PHP-Ib and transient neonatal diabetes mellitus (TNDM) requires the identification of hypocalcemia and hyperglycemia respectively, and subsequent pertinent molecular studies.[13,19] Thus, PHP-Ib and TNDM may have been overlooked in a certain fraction of patients with MLID. By contrast, as the diagnosis of BWS can be made clinically because of its pathognomonic malformations,[11] this would explain why BWS is observed as one of the two IDs in cases 1–9. In addition, the high prevalence of BWS may suggest that LOM-type epimutations are prone to occur at the *Kv*-DMR.

In summary, we observed BWS and PHP-Ib phenotypes in a patient with MLID. Notably, the two possibilities described here are not mutually exclusive, and both may be relevant to the development of MLID and two IDs. Further studies will permit to identify patients with MLID and $\geqslant 2$ IDs, and to elucidate underlying factor(s) for the occurrence of MLID and $\geqslant 2$ IDs.

CONFLICT OF INTEREST

The authors declare no conflict of interest.

ACKNOWLEDGEMENTS

We thank Dr Hiromi Kamura (Department of Maternal-Fetal Biology, National Research Institute for Child Health and Development, Japan) for her technological assistance. This work was supported by Grants-in-Aid for Scientific Research (A) (25253023), Grants-in-Aid for Scientific Research (C) (26461537) and Grants-in-Aid for Challenging Exploratory Research (15K15096) from the Japan Society for the Promotion of Science (JSPS), by Grants from the National Center for Child Health and Development (25-10), and by Grant from Takeda Science Foundation.

1 Court, F., Martin-Trujillo, A., Romanelli, V., Garin, I., Iglesias-Platas, I., Salafsky, I. *et al.* Genome-wide allelic methylation analysis reveals disease-specific susceptibility to multiple methylation defects in imprinting syndromes. *Hum. Mutat.* **34**, 595–602 (2013).
2 Mackay, D. J., Callaway, J. L., Marks, S. M., White, H. E., Acerini, C. L., Boonen, S. E. *et al.* Hypomethylation of multiple imprinted loci in individuals with transient neonatal diabetes is associated with mutations in ZFP57. *Nat. Genet.* **40**, 949–951 (2008).
3 Meyer, E., Lim, D., Pasha, S., Tee, L. J., Rahman, F., Yates, J. R. *et al.* Germline mutation in NLRP2 (NALP2) in a familial imprinting disorder (Beckwith-Wiedemann Syndrome). *PLoS Genet.* **5**, e1000423 (2009).
4 Murdoch, S., Djuric, U., Mazhar, B., Seoud, M., Khan, R., Kuick, R. *et al.* Mutations in NALP7 cause recurrent hydatidiform moles and reproductive wastage in humans. *Nat. Genet.* **38**, 300–302 (2006).
5 Parry, D. A., Logan, C. V., Hayward, B. E., Shires, M., Landolsi, H., Diggle, C. *et al.* Mutations causing familial biparental hydatidiform mole implicate c6orf221 as a possible regulator of genomic imprinting in the human oocyte. *Am. J. Hum. Genet.* **89**, 451–458 (2011).
6 Docherty, L. E., Rezwan, F. I., Poole, R. L., Turner, C. L., Kivuva, E., Maher, E. R. *et al.* Mutations in NLRP5 are associated with reproductive wastage and multilocus imprinting disorders in humans. *Nat. Commun.* **6**, 8086 (2015).
7 Boonen, S. E., Porksen, S., Mackay, D. J., Oestergaard, E., Olsen, B., Brondum-Nielsen, K. *et al.* Clinical characterisation of the multiple maternal hypomethylation syndrome in siblings. *Eur. J. Hum. Genet.* **16**, 453–461 (2008).
8 Baple, E. L., Poole, R. L., Mansour, S., Willoughby, C., Temple, I. K., Docherty, E. L. *et al.* An atypical case of hypomethylation at multiple imprinted loci. *Eur. J. Hum. Genet.* **19**, 360–362 (2011).
9 Begemann, M., Spengler, S., Kanber, D., Haake, A., Baudis, M., Leisten, I. *et al.* Silver-Russell patients showing a broad range of ICR1 and ICR2 hypomethylation in different tissues. *Clin. Genet.* **80**, 83–88 (2011).
10 Bakker, B., Sonneveld, L. J., Woltering, M. C., Bikker, H. & Kant, S.G. A girl with beckwith-wiedemann syndrome and pseudohypoparathyroidism type 1B due to multiple imprinting defects. *J. Clin. Endocrinol. Metab.* **100**, 3963–3966 (2015).
11 Weksberg, R., Shuman, C. & Beckwith, J. B. Beckwith-Wiedemann syndrome. *Eur. J. Hum. Genet.* **18**, 8–14 (2010).
12 Mantovani, G., Linglart, A., Garin, I., Silve, C., Elli, F. M. & de Nanclares, G. P. Clinical utility gene card for: pseudohypoparathyroidism. *Eur. J. Hum. Genet.* **21** (2013).
13 Fernandez-Rebollo, E., Lecumberri, B., Gaztambide, S., Martinez-Indart, L., de Nanclares, G. P. & Castano, L. Endocrine profile and phenotype-(epi)genotype correlation in Spanish patients with pseudohypoparathyroidism. *J. Clin. Endocrinol. Metab.* **98**, E996–1006 (2013).
14 Maeda, T., Higashimoto, K., Jozaki, K., Yatsuki, H., Nakabayahsi, K., Makita, Y. *et al.* Comprehensive and quantitative multilocus methylation analysis reveals the susceptibility of specific imprinted differentially methylated regions to aberrant methylation in Beckwith-Wiedemann syndrome with epimutations. *Genet. Med.* **16**, 903–912 (2014).
15 Maupetit-Mehouas, S., Azzi, S., Steunou, V., Sakakini, N., Silve, C., Reynes, C. *et al.* Simultaneous hyper- and hypomethylation at imprinted loci in a subset of patients with GNAS epimutations underlies a complex and different mechanism of multilocus methylation defect in pseudohypoparathyroidism Type 1b. *Hum. Mutat.* **34**, 1172–1180 (2013).
16 Bestor, T. H. Imprinting errors and developmental asymmetry. *Philos. Trans. R. Soc. Lond. B. Biol. Sci* **358**, 1411–1415 (2003).
17 Court, F., Tayama, C., Romanelli, V., Martin-Trujillo, A., Iglesias-Platas, I., Okamura, K. *et al.* Genome-wide parent-of-origin DNA methylation analysis reveals the intricacies of human imprinting and suggests a germline methylation-independent mechanism of establishment. *Genome. Res.* **24**, 554–569 (2014).
18 Kaneda, M., Okano, M., Hata, K., Sado, T., Tsujimoto, N., Li, E. *et al.* Essential role for *de novo* DNA methyltransferase Dnmt3a in paternal and maternal imprinting. *Nature* **429**, 900–903 (2004).
19 Mackay, D., Bens, S., de Nanclares, G. P., Siebert, R. & Temple, I. K. Clinical utility gene card for: transient neonatal diabetes mellitus, 6q24-related. *Eur. J. Hum. Genet.* **22** (2014).
20 Gillessen-Kaesbach, G., Demuth, S., Thiele, H., Theile, U., Lich, C. & Horsthemke, B. A previously unrecognised phenotype characterised by obesity, muscular hypotonia, and ability to speak in patients with Angelman syndrome caused by an imprinting defect. *Eur J. Hum. Genet.* **7**, 638–644 (1999).

Supplementary Information accompanies the paper on Journal of Human Genetics website (http://www.nature.com/jhg)