Journal of Human Genetics (2015) 60, 561–564

www.nature.com/jhg

ORIGINAL ARTICLE

Calcification of joints and arteries: second report with novel NT5E mutations and expansion of the phenotype

Zeng Zhang[1,2], Jin-Wei He[1], Wen-Zhen Fu[1], Chang-Qing Zhang[2] and Zhen-Lin Zhang[1]

Calcification of joints and arteries (CALJA; MIM 211800) is an extremely rare mendelian disorder of isolated calcification that is characterized by late onset calcification of the extremity arteries and hand and foot joint capsules. Mutations of *NT5E*, encoding cluster of differentiation 73, have been implicated in CALJA. Here we report on a Chinese family with CALJA and novel compound heterozygous mutations (c.1360G>A (p.Gly454Arg) and c.1387C>T (p.Arg463X)) in *NT5E*. Our study represents the second report on patients with CALJA associated with NT5E mutations. The clinical features expand the previously reported phenotype of *NT5E* mutations. The propositus has calcification of the lower extremity arteries and hand and foot joint capsules similar to those previously reported patients. However, he also has calcification of the upper extremity arteries. By protein structural modeling, we found the mutation p.Gly454Arg may disrupt the folding of β-pleated sheet and destabilize the protein structure. Our findings will provide clues to the phenotype–genotype relations and may assist not only in the clinical diagnosis but also in the interpretation of genetic information used for prenatal diagnosis and genetic counseling.
Journal of Human Genetics (2015) **60,** 561–564; doi:10.1038/jhg.2015.85; published online 16 July 2015

INTRODUCTION

Heterotopic calcification is a deposition of calcium-containing mineral outside the physiologically mineralized tissues such as the bone and teeth. The severity of mineral deposition may range from the minimal and inconsequential to massive and clinically significant.[1] Extracellular calcification is a default biochemical pathway and requires the constant stimulation of inhibitory systems to prevent its occurrence.[2] Genetic defects of inhibitory systems lead to heterotopic calcification in various tissues, such as the skin, subcutaneous tissue, skeletal muscle, ligament and occasionally in the wall of blood vessels.[2] Calcification of joints and arteries (CALJA; OMIM#211800) is an extremely rare, autosomal recessive disorder, which represents only the second mendelian disorder of vascular calcification;[3] the other one is generalized arterial calcification of infancy (OMIM#208000) caused by mutations in either *ENPP1* or *ABCC6*.[4,5] To our best knowledge, only 16 cases with CALJA from 9 families were previously reported in the literature worldwide.[3,6,7]

CALJA is characterized by late onset calcification of the lower extremity arteries and hand and foot joint capsules. In 2011, St Hilaire *et al.*[3] discovered that mutations in *NT5E*, encoding cluster of differentiation 73 (CD73), are implicated in CALJA. In normal conditions, extracellular calcification depends critically on levels of inorganic pyrophosphate, a strong inhibitor of calcification, and tissue non-specific alkaline phosphatase, which degrades inorganic pyrophosphate.[8] CD73 participates in the extracellular pathway that converts ATP to adenosine on the surface of various types of cells.[9] In the condition of CALJA, the consequent reduction in extracellular adenosine levels due to *NT5E* mutations can enhances tissue non-specific alkaline phosphatase activity. However, an exact understanding of pathogenesis of CALJA remains unclear.

Here we report on a Chinese family with CALJA and novel compound heterozygous mutations (c.1360G>A (p.Gly454Arg) and c.1387C>T (p.Arg463X)) in *NT5E*. Our study represents the second report on patients with CALJA associated with *NT5E* mutations, thus confirming the important role of *NT5E* in this disease. Furthermore, the clinical features in the present study expand the previously reported phenotype of *NT5E* mutations by St Hilaire *et al.*[3] At last, by protein structural modeling, we found the mutation p.Gly454Arg may disrupt the folding of β-pleated sheet and destabilize the protein structure.

MATERIALS AND METHODS

Ethics statement

This study was approved by the Ethics Committee of the Shanghai Jiao Tong University Affiliated Sixth People's Hospital. All the adult participants and the parents of children participants signed informed consent documents before entering the study. All participants were of Han ethnicity. The pedigrees of the family are shown in Figure 1. All these cases are previously unreported.

[1]Metabolic Bone Disease and Genetic Research Unit, Department of Osteoporosis and Bone Diseases, Shanghai Key Clinical Center for Metabolic Disease, Shanghai Jiao Tong University Affiliated the Sixth People's Hospital, Shanghai, PR China and [2]Department of Orthopedic Surgery, Shanghai Jiao Tong University Affiliated the Sixth People's Hospital, Shanghai, PR China
Correspondence: Professor Z-L Zhang, Metabolic Bone Disease and Genetic Research Unit, Department of Osteoporosis and Bone Diseases, Shan, Shanghai Jiao Tong University Affiliated the Sixth People's Hospital, 600 Yi-Shan Road, Shanghai 200233, PR China.
E-mail: zzl2002@medmail.com.cn
Received 1 March 2015; revised 9 June 2015; accepted 18 June 2015; published online 16 July 2015

Mutation analysis

Informed consent was obtained from the family and from 250 healthy volunteers before blood sampling and DNA analysis. The DNA was extracted from peripheral white blood cells using conventional methods. The DNA sequence for the *NT5E* gene was obtained from the available online database (GenBank accession No. NC_000006). Primers of the two genes were designed using the Primer 3 software (http://frodo.wi.mit.edu/cgi-bin/primer3/primer3_www.cgi). All exons and their exon–intron boundaries in the *NT5E* gene were amplified via PCR. Direct sequencing was performed using the BigDye Terminator Cycle Sequencing Ready Reaction Kit, version 3.1 (Applied Biosystems, Foster, CA, USA), and the sequencing was analyzed using an ABI Prism 3130 automated sequencer (Applied Biosystems, Foster City, CA, USA). The sequencing was performed in two directions.

Mutation prediction

The possible impact of amino-acid substitution on the function of CD73 was predicted using online tools including PolyPhen-2 (Polymorphism Phenotyping v2; http://genetics.bwh.harvard.edu/pph2),[10] SIFT (Sorting Intolerant From Tolerant; http://sift.jcvi.org)[11] and PROVEAN (Protein Variation Effect Analyzer; http://provean.jcvi.org/index.php).[12]

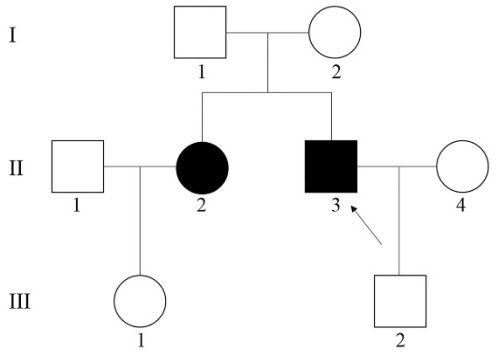

Figure 1 Pedigrees of a Chinese family. Patients with were shown by filled symbols. Arrow indicates the propositus.

Protein structural modeling

To illustrate the effects of the proband's exonic missense mutation p.Gly454Arg, we incorporated the mutation into the crystal structure of CD73. A molecular model of CD73 and its substrate AMP was constructed using the SWISS-MODEL server and Swiss-PdbViewer.[13,14] The construction of the structural graphics and the visualization were both based on PyMOL (Schrödinger, New York, NY, USA) and the Swiss-PdbViewer.

RESULTS

Human subjects

The 26-year-old propositus (II3) was born to a healthy nonconsanguineous couple. His birth and growth were normal. He presented with linear hard subcutaneous masses in his elbows (Figure 2a) that had begun 10 years earlier. These masses were growing very slowly. He was otherwise healthy and active. He had neither joint pain in his hands nor disabling intermittent claudication. Plain radiography of the upper extremities revealed marked calcification with areas of arteriomegaly (Figure 2b); radiography of the lower extremities also revealed heavy calcification (Figures 2c and d); and chest radiography revealed no vascular calcifications above the diaphragm (Figure 2e). Radiography also revealed juxta-articular joint-capsule calcifications of the fingers (indicated by arrows in Figure 2f). Vascular ultrasound in the left elbow showed that the arterial intima was smooth. Dual-energy X-ray absorptiometry examination showed normal bone density of lumbar spine (Z score: −0.6) and osteopenia of femoral neck (Z score: −1.9). Laboratory examinations revealed normal hematological parameters, biochemistry (including serum calcium, phosphorus and alkaline phosphatase), routine metabolic investigations and immune function parameters (Table 1).

The propositus' elder sister (II2), 30 years of age, reported having recurrent joint pain in her hands. Physical examination did not reveal subcutaneous masses in her inner aspect of the thighs and the upper arms. However, she refused radiographic examination. Other family members were healthy without similar features.

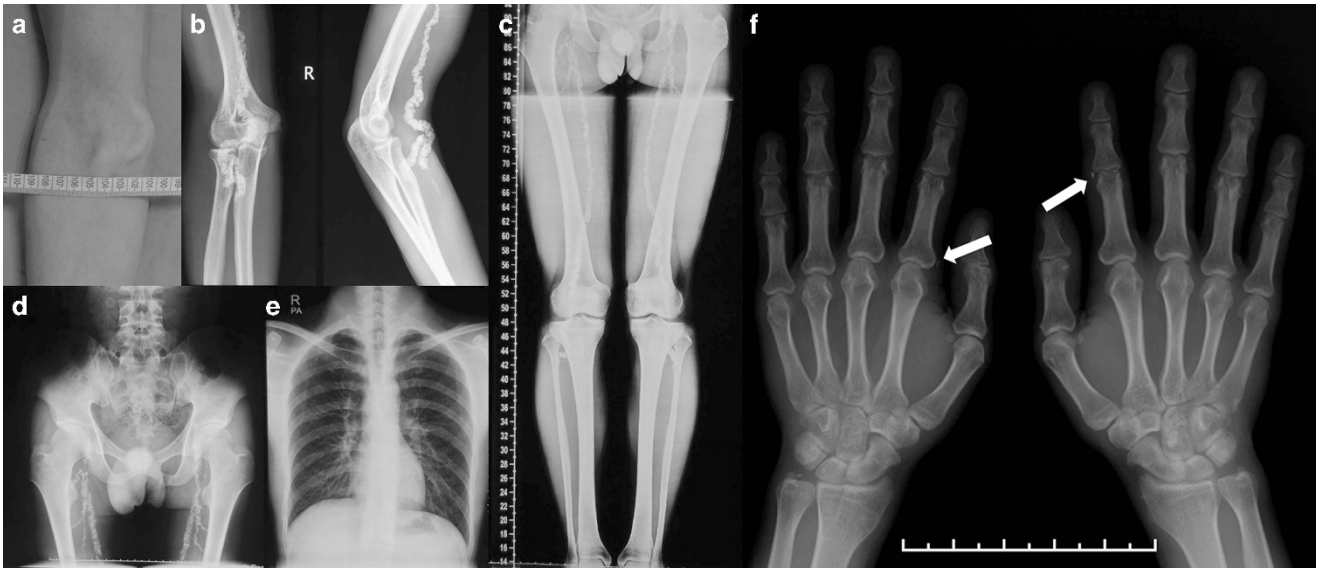

Figure 2 The propositus. (**a**) Cord-like hard subcutaneous masses in the elbow. (**b**–**d**) Plain radiography of the upper and lower extremities revealed heavy calcification with the areas of arteriomegaly. (**e**) Chest radiography revealed no vascular calcifications above the diaphragm. (**f**) Radiography also revealed juxta-articular joint-capsule calcifications of the fingers (indicated by arrows). A full color version of this figure is available at the *Journal of Human Genetics* journal online.

Mutation analysis and protein structural modeling

We screened for the *NT5E* mutation in the family using PCR followed by direct sequence analysis. In both the propositus and his sister (II2), the sequencing revealed compound heterozygous mutations that consisted of a heterozygous missense mutation c.1360G>A (p.Gly454Arg) in exon 7 and a heterozygous nonsense mutation c.1387C>T (p.Arg463X) in exon 8 (Figure 3a and b). Both mutations were novel. On the basis of DNA sequence analysis, the c.1360G>A and c.1387C>T mutations were found to be inherited from the propositus' unaffected mother (I2) and father (I1), respectively, and the propositus' son (III2) carried c.1360G>A. The c.1360G>A and c.1387C>T mutations were not found in DNA samples from 250 healthy volunteers with the same ethnic background. Nucleotide and amino-acid positions are written according to Refseq NM_002526.3 and NP_002517.1, respectively.

Table 1 Laboratory examinations of the propositus

Laboratory parameters	*Results*	*Normal range*
Serum alkaline phosphatase	107 U l^{-1}	15–112 U l^{-1}
Serum calcium	2.28 mmol l^{-1}	2.08–2.60 mmol l^{-1}
Serum phosphorus	0.87 mmol l^{-1}	0.80–1.60 mmol l^{-1}
Serum parathyroid hormone	44.1 pg ml^{-1}	12.0–88.0 pg ml^{-1}
Erythrocyte sedimentation rate	3 mm h^{-1}	0–21 mm h^{-1}
IgG	11.30 g l^{-1}	7.00–16.00 g l^{-1}
IgA	1.75 g l^{-1}	0.70–4.00 g l^{-1}
IgM	1.12 g l^{-1}	0.40–2.30 g l^{-1}
C3	0.80 g l^{-1} ↓	0.90–1.80 g l^{-1}
C4	0.16 g l^{-1}	0.10–0.40 g l^{-1}
IgE	26 IU ml^{-1}	0–100 IU ml^{-1}
κ light chain	2.77 g l^{-1}	1.70–3.70 g l^{-1}
λ light chain	1.73 g l^{-1}	0.90–2.10 g l^{-1}
κ/λ ratio	1.60	1.35–2.65
CH50	40.00 U ml^{-1}	23.00–46.00 U ml^{-1}

p.Gly454Arg is non-conservative, affects evolutionarily highly conserved amino acids from fish to mammals (Figure 3c) and was predicted *in silico* by all bioinformatic tools used to be of pathogenic relevance (PolyPhen-2 score of 1.000, SIFT score of 0 and PROVEAN score of −7.657). To illustrate the effect of p.Gly454Arg, a molecular model of CD73 and its substrate AMP was constructed (Figure 3d). According to the predicted structure, the mutant p.Gly454Arg (solid arrow) is located at the turn of β-pleated sheet, and is far away from the binding site of substrate AMP (hollow arrow). Therefore, p.Gly454Arg may not have a direct impact on the enzyme–substrate binding. However, the larger side chain of arginine could influence the folding of β-pleated sheet and make the protein unstable. The energy analysis also supported that the effect of p.Gly454Arg mutation is destabilizing.

DISCUSSION

Vascular calcification was previously considered to be a purely degenerative, passive process, without biological regulation.[15] The current view, however, is that vascular calcification is a biologically regulated process that—such as osteogenesis—involves both activators and inhibitors.[16] In the present study, we reported a Chinese family with CALJA and identified two novel mutations (c.1360G>A and c.1387C>T) in the *NT5E* gene. It is the second report on CALJA cases with confirmed *NT5E* mutations.

In 2011, St Hilaire *et al.*[3] reported on three families with CALJA and revealed that mutations of *NT5E* cause CALJA. In their study, patients had intermittent claudication of the calves, thighs and buttocks, and intense joint pain in their hands. Plain radiography revealed extensive calcification of the lower extremities and juxta-articular joint-capsule calcifications of the fingers, wrists, ankles and feet, with sparing of the carotid arteries, aorta and coronary arteries. They summarized that CALJA is characterized as medial arterial calcification of the lower extremities with periarticular calcification and supposed that selective involvement of lower extremity arteries may be related to the

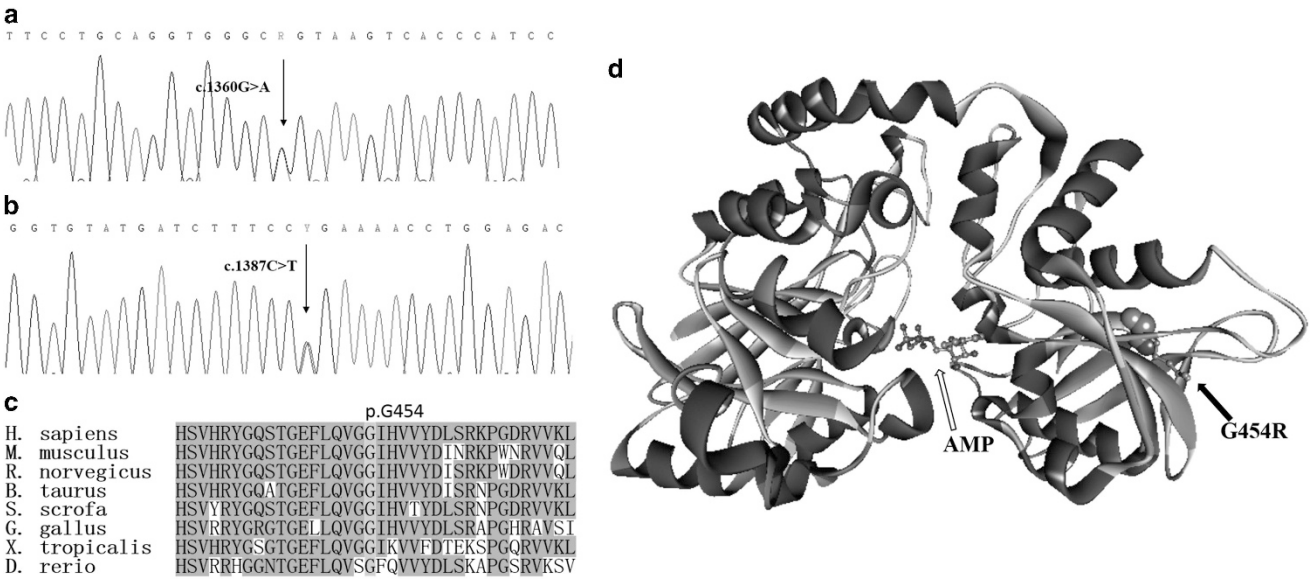

Figure 3 (**a**, **b**) Genetic analyses of the *NT5E* gene revealed compound heterozygous mutations that consisted of a heterozygous missense mutation c.1360G>A (p.Gly454Arg) in exon 7 and a heterozygous nonsense mutation c.1387C>T (p.Arg463X) in exon 8. (**c**) p.Gly454Arg affects evolutionarily highly conserved amino acids from fish to mammals. (**d**) According to the predicted structure, the mutant p.Gly454Arg (solid arrow) is located at the turn of β-pleated sheet, and is far away from the binding site of substrate AMP (hollow arrow). A full color version of this figure is available at the *Journal of Human Genetics* journal online.

particular distribution of adenosine receptors in these tissues. However, the propositus in the present study presented with extensive arterial calcification of the upper extremities in addition to that of the lower extremities, indicating that arterial calcification is not restricted in the lower extremities. Indeed in 1992, Mori *et al.*[7] reported on a 29-year-old man with generalized arterial calcification. The radiogram showed extensive calcification bilaterally in the facial, brachial, renal, external iliac, femoral and popliteal arteries. There was also calcification around the joints of the fingers, toes, elbows and shoulders. So, the range of the vascular calcification of CALJA may be not confined to extremities. However, *NT5E* gene was not sequenced at that time. In the contrary, the physical examination on the propositus' elder sister (II2) did not reveal subcutaneous masses in her inner aspect of the thighs and the upper arms. It is likely that she only had calcification of hand joint capsules, or the calcification of the extremity arteries was mild. It suggests that there is great variability in the clinical presentation of NT5E deficiency even in the same family.

NT5E encodes CD73. CD73 is a membrane-bound ecto-5′-nucleotidase that catalyzes the conversion of AMP to adenosine.[9] One of the many functions of adenosine is to suppress the activity of tissue non-specific alkaline phosphatase, an enzyme important in regulating extracellular matrix calcification.[17] p.Arg463X is a nonsense mutation, so it will cause a truncated, and often nonfunctional protein product. By protein structural modeling, we showed that p.Gly454Arg in our family may influence the folding of β-pleated sheet and make the protein unstable, thus leading to an impaired CD73 enzymatic activity. Both the mutations deserve further experimental confirmation. Recently, Fausther *et al.*[18] performed functional studies on *NT5E* mutations identified by St Hilaire *et al.*,[3] and showed that these mutations result in a protein with significantly reduced trafficking to the plasma membrane and reduced endoplasmic reticulum retention as compared with wild-type protein. They suggested that the syndrome of premature arterial calcification due to *NT5E* mutations may also involve a novel 'trafficking-opathy'. It is worth mentioning that Tsukamoto *et al.*[19] reported deficiency of CD73/ecto-5′-nucleotidase in mice enhances acute graft-versus-host disease, which is a common complication following an allogeneic tissue transplant. However, arterial calcification was not mentioned in their study.

In conclusion, we report on a Chinese family with CALJA and novel compound heterozygous mutations (c.1360G>A (p.Gly454Arg) and c.1387C>T (p.Arg463X)) in *NT5E*. Our study represents the second report on patients with CALJA associated with *NT5E* mutations. The clinical features expand the previously reported phenotype of *NT5E* mutations. Our findings may assist not only in the clinical diagnosis but also in the interpretation of genetic information used for prenatal diagnosis and genetic counseling.

CONFLICT OF INTEREST

The authors declare no conflict of interest.

ACKNOWLEDGEMENTS

The study was supported by the National '973' Program of China (2014CB942903), the National Natural Science Foundation of China (81401764 and 81370978), Academic Leaders in Health Sciences in Shanghai (XBR2011014), Science and Technology Commission of Shanghai Municipality (14JC1405000) and Chongqing Research Program of Basic Research and Frontier Technology (CSCT2013jcyjC00009).

1 McCarthy, E. F. & Sundaram, M. Heterotopic ossification: a review. *Skeletal Radiol.* **34**, 609–619 (2005).
2 Shore, E. M. & Kaplan, F. S. Inherited human diseases of heterotopic bone formation. *Nat. Rev. Rheumatol.* **6**, 518–527 (2010).
3 St Hilaire, C., Ziegler, S. G., Markello, T. C., Brusco, A., Groden, C., Gill, F. *et al.* NT5E mutations and arterial calcifications. *N. Engl. J. Med.* **364**, 432–442 (2011).
4 Lorenz-Depiereux, B., Schnabel, D., Tiosano, D., Hausler, G. & Strom, T. M. Loss-of-function ENPP1 mutations cause both generalized arterial calcification of infancy and autosomal-recessive hypophosphatemic rickets. *Am. J. Hum. Genet.* **86**, 267–272 (2010).
5 Nitschke, Y., Baujat, G., Botschen, U., Wittkampf, T., du Moulin, M., Stella, J. *et al.* Generalized arterial calcification of infancy and pseudoxanthoma elasticum can be caused by mutations in either ENPP1 or ABCC6. *Am. J. Hum. Genet.* **90**, 25–39 (2012).
6 Sharp, J. Heredo-familial vascular and articular calcification. *Ann. Rheum. Dis.* **13**, 15–27 (1954).
7 Mori, H., Yamaguchi, K., Fukushima, H., Oribe, Y., Kato, N., Wakamatsu, T. *et al.* Extensive arterial calcification of unknown etiology in a 29-year-old male. *Heart Vessels* **7**, 211–214 (1992).
8 Hessle, L., Johnson, K. A., Anderson, H. C., Narisawa, S., Sali, A., Goding, J. W. *et al.* Tissue-nonspecific alkaline phosphatase and plasma cell membrane glycoprotein-1 are central antagonistic regulators of bone mineralization. *Proc. Natl Acad. Sci. USA* **99**, 9445–9449 (2002).
9 Colgan, S. P., Eltzschig, H. K., Eckle, T. & Thompson, L. F. Physiological roles for ecto-5'-nucleotidase (CD73). *Purinergic Signal.* **2**, 351–360 (2006).
10 Adzhubei, I. A., Schmidt, S., Peshkin, L., Ramensky, V. E., Gerasimova, A., Bork, P. *et al.* A method and server for predicting damaging missense mutations. *Nat. Methods* **7**, 248–249 (2010).
11 Kumar, P., Henikoff, S. & Ng, P. C. Predicting the effects of coding non-synonymous variants on protein function using the SIFT algorithm. *Nat. Protoc.* **4**, 1073–1081 (2009).
12 Choi, Y., Sims, G. E., Murphy, S., Miller, J. R. & Chan, A. P. Predicting the functional effect of amino acid substitutions and indels. *PLoS One* **7**, e46688 (2012).
13 Arnold, K., Bordoli, L., Kopp, J. & Schwede, T. The SWISS-MODEL workspace: a web-based environment for protein structure homology modelling. *Bioinformatics* **22**, 195–201 (2006).
14 Schwede, T., Kopp, J., Guex, N. & Peitsch, M. C. SWISS-MODEL: An automated protein homology-modeling server. *Nucleic Acids Res.* **31**, 3381–3385 (2003).
15 Demer, L. L. & Tintut, Y. Vascular calcification: pathobiology of a multifaceted disease. *Circulation* **117**, 2938–2948 (2008).
16 Sage, A. P., Tintut, Y. & Demer, L. L. Regulatory mechanisms in vascular calcification. *Nat. Rev. Cardiol.* **7**, 528–536 (2010).
17 Gan, X. T., Taniai, S., Zhao, G., Huang, C. X., Velenosi, T. J., Xue, J. *et al.* CD73-TNAP crosstalk regulates the hypertrophic response and cardiomyocyte calcification due to alpha1 adrenoceptor activation. *Mol. Cell. Biochem.* **394**, 237–246 (2014).
18 Fausther, M., Lavoie, E. G., Goree, J. R., Baldini, G. & Dranoff, J. A. NT5E mutations that cause human disease are associated with intracellular mistrafficking of NT5E protein. *PLoS One* **9**, e98568 (2014).
19 Tsukamoto, H., Chernogorova, P., Ayata, K., Gerlach, U. V., Rughani, A., Ritchey, J. W. *et al.* Deficiency of CD73/ecto-5'-nucleotidase in mice enhances acute graft-versus-host disease. *Blood* **119**, 4554–4564 (2012).