

SHORT COMMUNICATION

Cerebral hemorrhage in Fabry's disease

Katsuya Nakamura¹, Yoshiki Sekijima^{1,2}, Kimitoshi Nakamura³, Kiyoko Hattori³, Kiyoshiro Nagamatsu¹, Yusaku Shimizu⁴, Takuji Yasude^{1,4,5}, Masao Ushiyama⁶, Fumio Endo³, Yoshimitsu Fukushima² and Shu-ichi Ikeda¹

Fabry's disease is an X-linked lysosomal storage disorder resulting from α -galactosidase A deficiency. Although ischemic stroke is recognized as an important manifestation of Fabry's disease, hemorrhagic stroke is considered to be rare. Here, we report our recent clinical experience with three hemizygous male patients with Fabry's disease who developed cerebral hemorrhage. One patient had classic type Fabry's disease with p.Ala37Val mutation and others had cerebrovascular variant with p.Glu66Gln mutation. Degeneration of the cerebral small arteries secondary to deposition of glycosphingolipids and aging, in addition to hypertension and antiplatelet/anticoagulant agents, are considered to be contributing factors for hemorrhage. Fabry's disease is frequently associated with not only ischemic but also hemorrhagic stroke, especially in elderly patients.

Journal of Human Genetics (2010) 55, 259–261; doi:10.1038/jhg.2010.18; published online 19 March 2010

Keywords: α -galactosidase A; Fabry's disease; cerebral hemorrhage; cerebral infarction; stroke

INTRODUCTION

Fabry's disease is an X-linked lysosomal storage disorder in which the deficiency of α -galactosidase A (α -Gal A) leads to progressive accumulation of globotriaosylceramide and related glycosphingolipids in vascular endothelial lysosomes of the kidneys, heart, skin and brain.¹ Stroke is one of the major complications of Fabry's disease² and has been described in $\geq 25\%$ of patients.^{3–6} In patients with the classic phenotype, levels of α -Gal A activity are very low or undetectable, and progressive glycosphingolipids accumulation leads to renal, cardiac and cerebrovascular manifestations and early death.¹ On the other hand, patients with substantial levels of residual α -Gal A activity have milder phenotypes, including renal⁷ and cardiac⁸ variant. Another atypical variant of Fabry's disease has been reported, with manifestations limited to the cerebrovascular system.^{9,10} Although cerebral infarction is recognized as an important manifestation of Fabry's disease,^{2,9,11} cerebral hemorrhage seems to be underrecognized in this disorder. Here, we report our recent clinical experience with three hemizygous male patients with Fabry's disease suffering from cerebral hemorrhage.

MATERIALS AND METHODS

α -Gal A activity was determined using a fluorescent substrate as described earlier.¹² Briefly, 40 μ l of McIlvan buffer (0.1 M citrate, 0.2 M NaH₂PO₄, 36.8:63.2, pH 6.0) were added to 96-microwell plates; 3 mm punch of dried blood spots were added into the buffers and processed for extraction at room temperature for 2 h; 30 μ l of blood extract were transferred into another 96-microwell plate and 100 μ l of the reaction mixture (3.5 mM 4-MU galactosylpyranoside, 100 mM citrate, 200 mM phosphate, 100 mM N-acetylgalactosamine) were added into each well of the microplates and incubated at 37°C for 24 h. The reaction was

terminated with 150 μ l of termination solution (300 mM glycine, NaOH, pH10.6) immediately after the reaction. Fluorescent intensity from the 4-methylumbelliferones in the wells was measured with fluorescent plate reader (BIO-TEK) at 450 nm. One unit (AgalU) of enzymatic activity was equal to 0.34 pmol of 4-methylumbelliferyl-D-galactopyranoside cleaved per hour per disc. For DNA analysis, total genomic DNA was extracted from leukocytes of patients. All seven exons of the *GLA* gene were amplified by polymerase chain reaction (PCR), and the amplification products were analyzed by a direct sequencing method. This study was approved by the Ethical Committee of Shinshu University School of Medicine and informed consent was obtained from each patient.

Case reports

Patient 1. The patient was a 49-year-old Japanese man. His mother developed cryptogenic cerebral infarction at age 52 and his younger brother was diagnosed as having Fabry's disease based on renal failure and decreased α -Gal A activity. He developed proteinuria at age 25 with progressively deteriorated renal function and became dependent on hemodialysis at age 46. At age 44, a diagnosis of Fabry's disease was made based on clinical findings, family history and decreased α -Gal A activity. Enzyme replacement therapy was started with biweekly infusions of agalsidase- β at age 47. At age 49, he developed acute onset of right-sided weakness and aphasia and was admitted to a local hospital. CT scan revealed a left thalamic hemorrhage with ventricular perforation (Figures 1a and b). He was referred to our hospital for biochemical and molecular diagnosis. Measurement of α -Gal A activity in the whole blood revealed 4.6 AgalU (normal > 17.0), and direct DNA sequencing of the *GLA* gene revealed a single base sequence change (c.110C>T) causing substitution of an alanine residue with valine at codon 37 (p.Ala37Val) (Figure 2a).

Patient 2. The patient was an 83-year-old Japanese man. There was no family history suggesting Fabry's disease. He had been well until 76 years old, when he

¹Department of Medicine (Neurology and Rheumatology), Shinshu University School of Medicine, Matsumoto, Japan; ²Division of Clinical and Molecular Genetics, Shinshu University Hospital, Matsumoto, Japan; ³Department of Pediatrics, Graduate School of Medical Science, Kumamoto University, Kumamoto, Japan; ⁴Department of Neurology, Ina Central Hospital, Japan; ⁵Department of Neurology, Hokushin General Hospital, Nakano, Japan and ⁶Department of Neurology, Kenwakai Hospital, Iida, Japan
Correspondence: Dr Y Sekijima, Department of Medicine (Neurology and Rheumatology), Shinshu University School of Medicine, 3–1–1 Asahi, Matsumoto 390-8621, Japan. E-mail sekijima@shinshu-u.ac.jp

Received 26 November 2009; revised 15 February 2010; accepted 17 February 2010; published online 19 March 2010

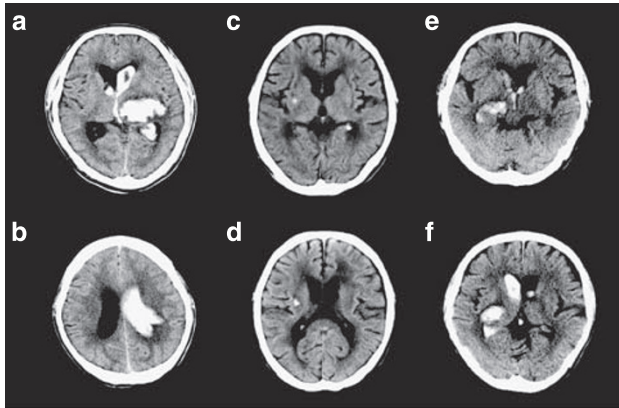


Figure 1 Brain CT scans of patients with Fabry's disease. (a, b) Brain CT of patient 1 showed large left thalamic hematoma with rapture into the lateral, third and fourth ventricles and associated hydrocephalus. (c, d) Brain CT of patient 2 showed minor left putaminal hemorrhage and diffuse ischemic change in bilateral cerebral white matter. (e, f) Brain CT of patient 3 showed right thalamic bleeding with extension into the lateral and third ventricles.

developed hypertension. At age 81, he developed aphasia and was admitted to a local hospital. Brain MRI showed cerebral infarction in the left temporal lobe, and antiplatelet therapy (aspirin 100 mg per day) was started. Two months later, he suddenly developed dysarthria and a diagnosis of left putaminal hemorrhage was made (Figures 1c and d). Antiplatelet therapy was discontinued after this episode. At age 83, he noticed weakness in the right arm and was diagnosed with recurrence of cerebral infarction. He was referred to our hospital to determine the pathogenesis of recurrent cerebrovascular events. Measurement of α -Gal A activity in the whole blood revealed 11.6 AgalU (normal > 17.0), and direct DNA sequencing of the *GLA* gene revealed a single base sequence change (c.196G>C) causing substitution of a glutamate residue with glutamine at codon 66 (p.Glu66Gln), suggesting that his recurrent episodes of stroke were caused by Fabry's disease (Figure 2b).

Patient 3. The patient was a 74-year-old Japanese man, who had been in good health except a history of compression fracture of the lumbar spine. There was no family history suggesting Fabry's disease. At age 73, he suddenly noticed vertigo and nausea, and was admitted to a local hospital. Brain MRI showed lacunar infarctions in the left pons and right cerebellar hemisphere. He was diagnosed as having cryptogenic cerebral infarction and treated with aspirin (100 mg per day). At age 74, he was admitted to our hospital to investigate the pathogenesis of cerebral infarction. Measurement of α -Gal A activity in whole blood revealed 12.3 AgalU (normal > 17.0), and direct DNA sequencing of the *GLA* gene showed c.196G>C (p.Glu66Gln) mutation (Figure 2c). On the basis of these findings, he was diagnosed with Fabry's disease and enzyme replacement therapy with agalsidase- β was started. A month later, he developed consciousness disturbance and a diagnosis of right thalamic hemorrhage with ventricular perforation was made (Figures 1e and f).

DISCUSSION

Clinical information is available for only four patients with Fabry's disease who developed cerebral hemorrhage (Table 1).^{8,13–15} Three patients were hemizygous males with classic type^{8,13,14} and one was a heterozygous female.¹⁵ All four patients had renal dysfunction and three had uncontrolled hypertension. None of the patients received enzyme replacement therapy. The patients presented here were all hemizygous males (Table 1). Patient 1 had classic type Fabry's disease with p.Ala37Val mutation, and patients 2 and 3 had cerebrovascular variant phenotype with p.Glu66Gln mutation.^{7,16} Although only four patients have been reported earlier, our recent clinical experience with three patients suggests that cerebral hemorrhage is a relatively com-

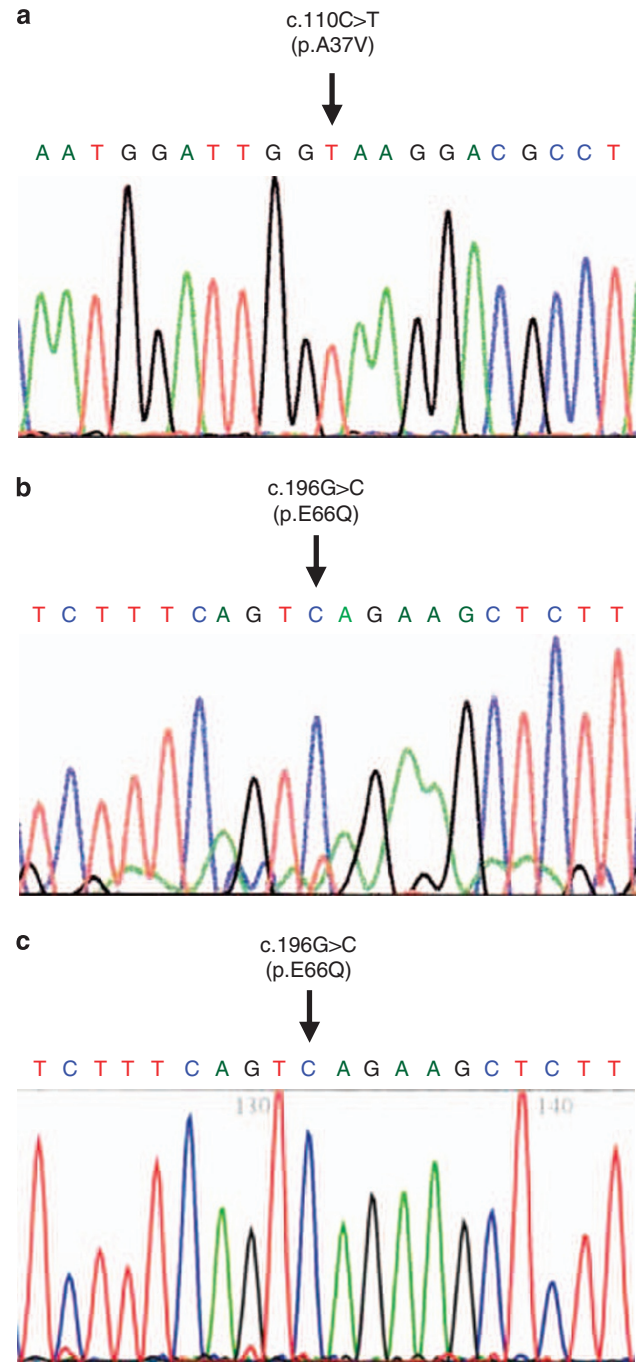


Figure 2 Direct nucleotide sequencing of the PCR-amplified DNA of the *GLA* gene. (a) The sense strand of the DNA from patient 1. Vertical arrow indicates nucleotide 110 (exon 1), where a hemizygous C→T transversion resulted in an amino-acid substitution p.Ala37Val. (b, c) The sense strand of the DNA from patient 2 (b) and patient 3 (c). Vertical arrow indicates nucleotide 196 (exon 2), where a hemizygous G→C transversion resulted in an amino-acid substitution p.Glu66Gln.

mon underrecognized complication of Fabry's disease.¹⁷ Indeed, the incidence rate of cerebral hemorrhage was reported to be about threefold higher in Fabry's stroke group (14.3%) than non-Fabry's stroke group (5.0%),⁹ although detailed information regarding hemorrhage was not described.

The pathophysiological mechanism of cerebral hemorrhage in Fabry's disease remains to be elucidated, but may be attributable to

Table 1 Clinical features of Fabry's disease patients with cerebral hemorrhage

Patient (reference number)	Age (years)	Sex	Renal dysfunction	Cardio- myopathy	Cerebral infarction	Other complications	Hypertension	ERT	Antiplatelet/ anticoagulant	GLA gene mutation
1 ^a	49	M	+ (HD)	+	–	Hypohidrosis	+ (Good control)	+	–	A37V
2 ^a	83	M	–	–	+	–	+ (Good control)	–	Aspirin	E66Q
3 ^a	74	M	–	–	+	–	–	+	Aspirin	E66Q
4 (8)	62	M	+	+	–	–	+ (Poor control)	–	ND	M296I
5 (13)	38	M	+	ND	ND	Angiokeratoma	+ (Poor control)	–	ND	ND
6 (14)	42	M	+	ND	ND	Angiokeratoma	–	–	–	–
						Acroparesthesia	+ (Poor control)	–	ND	ND
7 (15)	57	F	+	+	ND	Dementia	ND	–	ND	ND

Abbreviations: ERT, enzyme replacement therapy; HD, hemodialysis; ND., not described.

^aPatients described in this paper.

several factors. Most likely, the hemorrhage is a consequence of uncontrolled hypertension secondary to renal dysfunction. In fact, our patient 1 was treated with chronic hemodialysis and patients 1 and 2 had hypertension, although their blood pressures were well controlled by antihypertensive drugs. On the other hand, our patient 3 had neither hypertension nor renal dysfunction, suggesting that there should be other contributing factors for cerebral hemorrhage. In Fabry's disease, deposition of glycosphingolipids occurs predominantly in the lysosomes of endothelial, perithelial and smooth-muscle cells of blood vessels. Glycosphingolipids deposition in cerebral large arteries leads to the development of the dolichoectasia, which is commonly seen in Fabry's patients. Cerebral aneurysm of large arteries^{18,19} and subsequent subarachnoid hemorrhage¹⁹ are also reported in some patients. Recently, it is reported that cerebral small artery disease, which is known to be associated with lacunar infarction, white matter lesions (leukoaraiosis) and cerebral hemorrhage, rather than large artery stroke, is frequently observed in Fabry's disease.^{5,6,20} These findings suggest that the underlying degeneration of the cerebral small arteries, secondary to the deposition of glycosphingolipids in the vessel wall, could be a strong contributing factor for cerebral hemorrhage in Fabry's disease. Aging is thought to be another important contributing factor,⁶ as our patients, especially patients 2 (83 years old) and 3 (74 years old), were elderly compared with average Fabry's patients. Finally, there is no doubt that antiplatelet and anticoagulation therapies were partially responsible for cerebral hemorrhage.

Enzyme replacement therapy can clear microvascular endothelial deposits of glycosphingolipids from the kidneys, heart and skin in patients with Fabry's disease, reversing the pathogenesis of the chief clinical manifestations of this disease. Although a tendency to normalization of cerebral vessel compliance and regional cerebral hyperperfusion has been shown in patients with the disease after enzyme replacement therapy,²¹ beneficial effects of this treatment on the incidence of stroke in Fabry's disease have not yet been shown. Reasons for the failure of enzyme replacement therapy yet to affect stroke incidence in the disease include the irreversible damage done by the time patients develop such late complications. Thus, such treatment should be started earlier in the natural history of the disease.

In conclusion, Fabry's disease is frequently associated with cerebrovascular complications, including not only ischemic but also hemorrhagic stroke. Antiplatelet and/or anticoagulation therapies are necessary for most patients with Fabry's disease. However, care

should be taken in the administration of such therapies considering the increased risk of cerebral hemorrhage.

- Brady, R. O. & Schiffmann, R. Clinical features of and recent advances in therapy for Fabry disease. *JAMA* **284**, 2771–2775 (2000).
- Mitsias, P. & Levine, S. R. Cerebrovascular complications of Fabry's disease. *Ann. Neurol.* **40**, 8–17 (1996).
- MacDermot, K. D., Holmes, A. & Miners, A. H. Anderson-Fabry disease: clinical manifestations and impact of disease in a cohort of 98 hemizygous males. *JAMA* **38**, 750–760 (2001).
- Grewal, R. P. Stroke in Fabry's disease. *J. Neurol.* **241**, 153–156 (1994).
- Buechner, S., Moretti, M., Burlina, A. P., Cei, G., Manara, R., Ricci, R. *et al.* Central nervous system involvement in Anderson Fabry disease: a clinical and MRI retrospective study. *J. Neurol. Neurosurg. Psychiatry.* **79**, 1249–1254 (2008).
- Crutchfield, K. E., Patronas, N. J., Dambrosia, J. M., Frei, K. P., Banerjee, T. K., Barton, N. W. *et al.* Quantitative analysis of cerebral vasculopathy in patients with Fabry disease. *Neurology.* **50**, 1746–1749 (1998).
- Nakao, S., Kodama, C., Takenaka, T., Tanaka, A., Yasumoto, Y., Yoshida, A. *et al.* Fabry disease: detection of undiagnosed hemodialysis patients and identification of a 'renal variant' phenotype. *Kidney Int.* **64**, 801–807 (2003).
- Nakao, S., Takenaka, T., Maeda, M., Kodama, C., Tanaka, A., Tahara, M. *et al.* An atypical variant of Fabry's disease in men with left ventricular hypertrophy. *N. Engl. J. Med.* **333**, 288–293 (1995).
- Rofls, A., Bottcher, T., Zschiesche, M., Morris, P., Winchester, B. & Bauer, P. *et al.* Prevalence of Fabry disease in patients with cryptogenic stroke: a prospective study. *Lancet.* **366**, 1794–1796 (2005).
- Schiffmann, R. & Ries, M. Fabry's disease—an important risk factor for stroke. *Lancet.* **366**, 1754–1756 (2005).
- Moore, D. F., Ye, F., Schiffmann, R. & Butman, J. A. Increased signal intensity in the pulvinar on T1-weighted images: a pathognomonic MR imaging sign of Fabry disease. *AJNR Am. J. Neuroradiol.* **24**, 1096–1101 (2003).
- Chamoles, N. A., Blanco, M. & Gaggioli, D. Fabry disease: enzymatic diagnosis in dried blood spots on filter paper. *Clin. Chim. Acta.* **308**, 195–196 (2001).
- Bass, B. H. Angiokeratoma corporis diffusum. *Br. Med. J.* **1**, 1418 (1958).
- Wise, D., Jellinek, E. H. & Wallace, H. J. Angiokeratoma corporis diffusum. A clinical study of eight affected families. *Q. J. Med.* **31**, 177–206 (1962).
- Steward, V. W. & Hitchcock, C. Fabry's disease (angiokeratoma corporis diffusum). A report of 5 cases with pain in the extremities as the chief symptom. *Pathol. Eur.* **3**, 377–388 (1968).
- Yoshitama, T., Nakao, S., Takenaka, T., Teraguchi, H., Sasaki, T., Kodama, C. *et al.* Molecular genetic, biochemical, and clinical studies in three families with cardiac Fabry's disease. *Am. J. Cardiol.* **87**, 71–75 (2001).
- Sims, K., Politei, J., Banikazemi, M. & Lee, P. Stroke in Fabry disease frequently occurs before diagnosis and in the absence of other clinical events: natural history data from the Fabry Registry. *Stroke.* **40**, 788–794 (2009).
- Maisey, D. N. & Cosh, J. A. Basilar artery aneurysm and Anderson-Fabry disease. *J. Neurol. Neurosurg. Psychiatry.* **43**, 85–87 (1980).
- Sakuishi, K., Hashimoto, A., Ugawa, Y. & Tuji, S. An experience of enzyme therapy on adult-onset atypical Fabry's disease. *Shinkeinaika.* **62**, 62–69 (2005). (in Japanese).
- Moore, D. F., Kaneski, C. R., Askari, H. & Schiffmann, R. The cerebral vasculopathy of Fabry disease. *J. Neurol. Sci.* **257**, 258–263 (2007).
- Moore, D. F., Altarescu, G., Ling, G. S. F., Jeffries, N., Frei, K. P., Weibel, T. *et al.* Elevated cerebral blood flow velocities in Fabry disease with reversal after enzyme replacement. *Stroke.* **33**, 525–531 (2002).