

A CASE OF PARTIAL TRISOMY 2p (REGION 2p21→2pter) DERIVED FROM A MATERNAL t(2;15)(p21;q26)¹

Kunikazu KISHI,² Yukio MATSUTANI,³ Tetsuya IWATSUBO,³
KOZO NISHIMURA,³ and Akira TONOMURA²

²*Department of Cytogenetics, Medical Research Institute, Tokyo Medical and Dental
University, Yushima, Bunkyo-ku, Tokyo 113, Japan*

³*Department of Pediatrics, St. Luke's International Hospital,
Akashicho, Chuo-ku, Tokyo 104, Japan*

Summary A further case of partial trisomy 2p inherited from a maternal balanced translocation with a karyotype of 46,XX,t(2;15)(p21;q26) is reported. The female patient had an unbalanced karyotype with duplication of the distal part of the short arm of chromosome 2 (region 2p21→2pter). On the basis of the cytogenetic finding, clinical features of this patient were compared with those of the reported two cases with the similar duplication of region 2p21→2pter. The clinical features common to the three cases were hypertelorism, triangular face, large abnormal ears, congenital heart defect and long fingers, but microcephaly, prominent nasal bridge and long toes noted in the reported cases were replaced with hydrocephalus, wide, flat nasal bridge and short toes in the present case.

INTRODUCTION

Since the discovery of the first case with partial trisomy 2p due to a familial t(2;3) translocation by Lee *et al.* (1964), at least 17 cases with similar phenotypic and karyotypic findings have been reported (Bender *et al.*, 1969; Stoll *et al.*, 1974; Magenis *et al.*, 1975; Franke and Jones, 1976; Buyse *et al.*, 1977; Cassidy *et al.*, 1977; Armendares and Salamanca-Gómez, 1978; Mayer *et al.*, 1978; Sekhon *et al.*, 1978; Nagano *et al.*, 1979; Yunis *et al.*, 1979). In 1976, Franke and Jones delineated this disorder as the "2p partial trisomy syndrome," which involved partial trisomy of the short arm of chromosome 2 (region 2p23→2pter). On the basis of the cytogenetic findings, however, the cases so far reported can be subdivided into five groups according to the trisomic regions of the short arm of chromosome 2.

Received January 17, 1980

¹ Detailed clinical report was presented at the 81st Annual Meeting of the Societas Paediatrica Japonica (Iwatsubo *et al.*, 1978).

In this paper we report a further case of duplication of region 2p21→2pter inherited from a maternal $t(2;15)(p21;q26)$.

CASE REPORT

The patient was a female infant, born at the St. Luke's International Hospital after a 42-week gestation. She was the first-born of non-consanguineous parents. The paternal and maternal ages at the time of her birth were 28 and 27 years respectively. Her birth weight was 1,165 g, body length was 33.0 cm, head circumference was 28.5 cm and chest circumference was 21.1 cm. She showed prominent occiput, hypertelorism, epicanthus, downward sloping palpebral fissures and eyebrow, long eyelid, wide, flat nasal bridge, anteverted nostrils, micrognathia and low set ears. Her skin was loose, and subcutaneous fatty tissue was hypoplastic. She had long digits, short hallux, rocker-bottom feet, the right valgus foot and the left calcaneovarus foot. Her pelvis was a rather small and her external genitalia showed hypoplasia of labia majora (Fig. 1).

Developmental retardation was severe and athetoid movement was observed. No abnormalities were visible in Moro's reaction and grasp reflex. She died of congenital multiple abnormalities at 5 months of age. Dermatoglyphic study was tried but failed of success.

CYTOGENETIC STUDIES

Chromosom epreparations were made from peripheral blood cultures and G-banding technique was performed according to the method of Seabright (1971).

Karyotype analysis of the patient showed an unusually long chromosome in one member of chromosome 15 (Fig. 2). Karyotype of the mother revealed a balanced reciprocal translocation involving between the distal part of the short arm of chromosome 2 and the long arm of chromosome 15 (Fig. 3). The break-points for this rearrangement are 2p21 and 15q26, as shown in Fig. 4. Therefore, the karyotype of the mother is $46,XX,t(2;15)(p21;q26)$ and that of the patient is $46,XX,der(15), t(2;15)(p21;q26)mat$.

Based on a comparison with other reported cases, the present case is concluded to be an additional type of the 2p partial trisomy syndrome, trisomic for region 2p21→2pter and monosomic for a very small terminal region of the long arm of chromosome 15.

The father and her brother had normal karyotypes.

FAMILY STUDY

The pedigree of this family is shown in Fig. 5. The mother (II-5) of the propositus (III-11) had five phenotypically normal sibships, one male and four females,

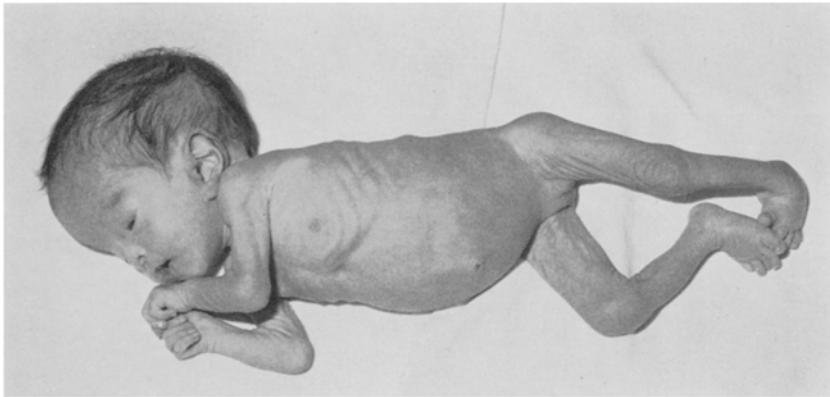


Fig. 1. The propositus at 5 months. Note hydrocephalus, low set ears and the abnormal feet.

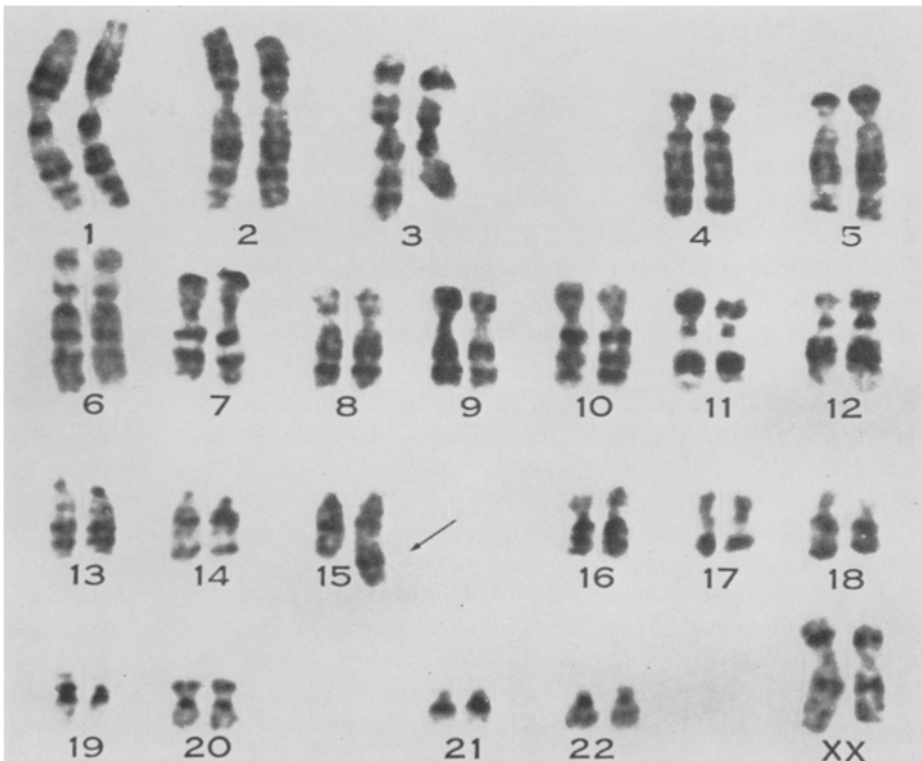

Fig. 2. Karyotype of the propositus. Arrow indicates der(15) chromosome.

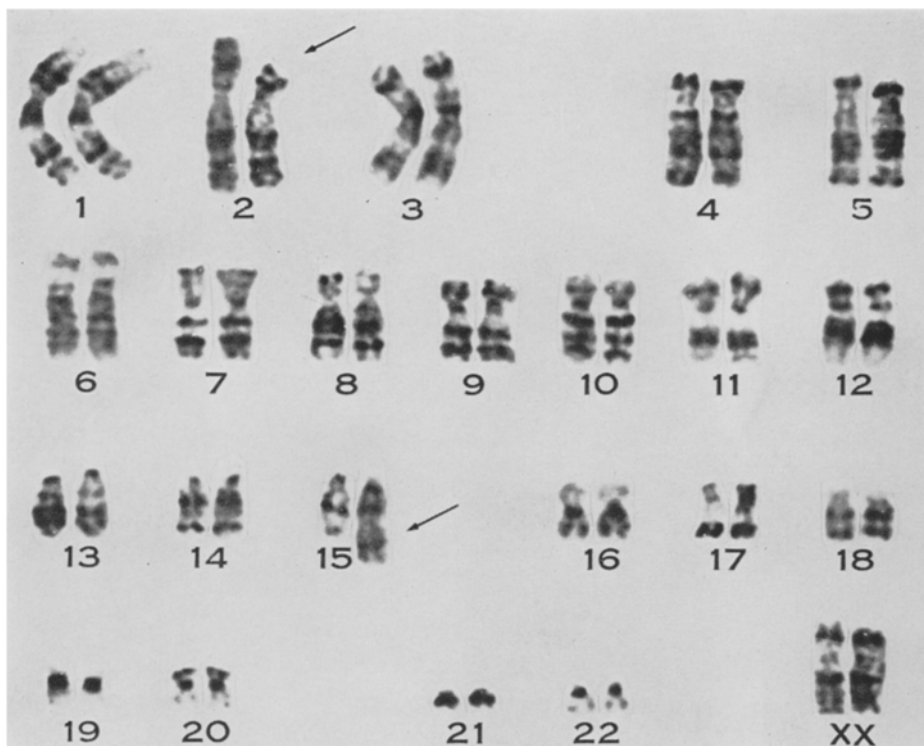


Fig. 3. Karyotype of the mother. Arrows indicate balanced reciprocal translocation between chromosomes 2 and 15.

and karyotype analyses revealed that all of them were balanced $t(2;15)$ translocation carriers. The grandmother (I-2) showed a normal karyotype. Among her cousins, two were translocation carriers (III-2, 3) and six were normal karyotypes (III-1, 4, 7, 8, 9, 10). The other two cousins were phenotypically normal (III-5, 6), but we had no opportunity to perform their chromosome examination.

There were 10 spontaneous abortions and two perinatal deaths in generations II and III.

DISCUSSION

There have been at least 18 reported cases of partial trisomy 2p including the present case, in which 17 cases were inherited from a parental reciprocal translocation and only one case was due to a *de novo* duplication. The trisomic regions of these cases have been identified by means of banding techniques except for the earliest two patients (Lee *et al.*, 1964; Bender *et al.*, 1969). According to the trisomic regions of the short arm of chromosome 2, the patients reported can be subdivided into five groups; 2 cases were trisomic for $2p13 \rightarrow 2p$ (Buyse *et al.*, 1977;

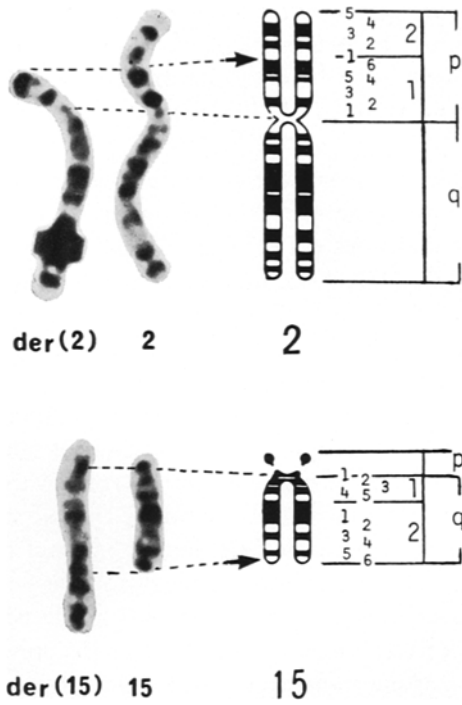

Fig. 4. Partial karyotype of the mother and diagrammatic representation of chromosomes 2 and 15. Arrows indicate points of breakage and reunion in this reciprocal translocation.

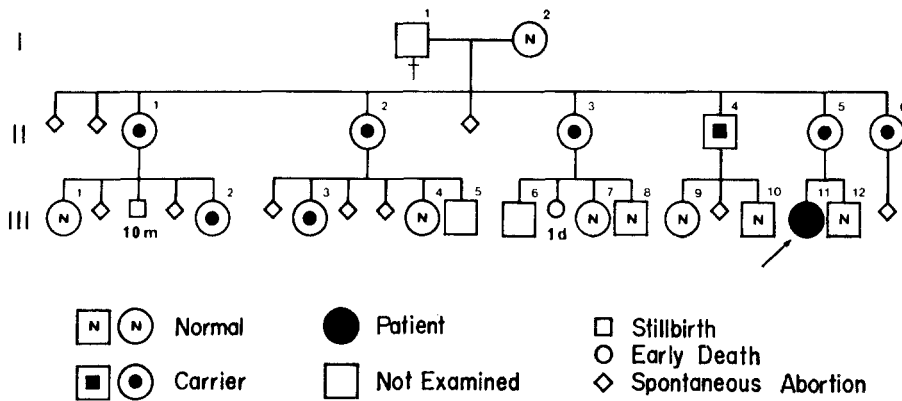


Fig. 5. The pedigree of the family.

Nagano *et al.*, 1979), 5 were trisomic for 2p21→2pter (Armendares and Salamanca-Gómez, 1978; Mayer *et al.*, 1978; Sekhon *et al.*, 1978), 2 were trisomic for 2p22→2pter (Stoll *et al.*, 1974), 6 were trisomic for 2p23→2pter (Magenis *et al.*, 1975; Franke and Jones, 1976; Cassidy *et al.*, 1977) and one was trisomic for 2p14→2p23 (Yunis *et al.*, 1979).

Similar abnormalities such as developmental and psychomotor retardations, frontal bossing, epicanthus, micrognathia, vertebral anomalies, long digits and hypoplastic external genitalia were frequently found in most cases (Franke and Jones, 1976; Cassidy *et al.*, 1977; Armendares and Salamanca-Gómez, 1978; Sekhon *et al.*, 1978). Hypertelorism, low-set and malformed ears, cardiac defects and cryptorchidism were more often found in patients trisomic for 2p21→2pter, as compared with those trisomic for 2p23→2pter.

On the other hand, some of the discordances were found between the present patient and two affected cases reported by Armendares and Salamanca-Gómez (1978); they showed a similar partial trisomy 2p (region 2p21→2pter) inherited from the parent with t(2;15)(p21;q26). Common clinical features included low birth weight, hypertelorism, triangular face, large abnormal ears, congenital heart defect and long fingers. However, microcephaly, prominent nasal bridge and long toes represented in the reported cases were replaced in the opposite direction with hydrocephalus, wide, flat nasal bridge and short toes in the present case. Strabismus and abnormal curvature of the spine were observed in the reported cases but not in the present case, while valgus and varus feet and hypoplastic external genitalia in the present case were not found in the reported two cases. Examination of more cases is required before conclusion can be regarding the presence of distinct clinical features in patients trisomic for a longer region of the short arm of chromosome 2.

Chromosome investigations of this family revealed that all the six siblings including the mother of the propositus were balanced t(2;15) translocation carriers. Since the grandmother showed a normal karyotype, it appears reasonable to assume that the translocation chromosome were derived from the deceased grandfather. This segregation in phenotypically normal persons seems to be of very rare occurrence according to the theoretical 1 : 1 ratio of a reciprocal translocation. In generation III, however, out of 10 members examined 7 showed normal karyotypes, 2 were translocation carriers and one was the case due to an adjacent segregation. Therefore, as a whole, the segregation ratio of the karyologically normal individuals and translocation carriers is about 1 : 1 in this family.

REFERENCES

- Armendares, S., and Salamanca-Gómez, F. 1978. Partial 2p trisomy (p21→pter) in two siblings of a family with a 2p- : 15q+ translocation. *Clin. Genet.* **13**: 17-24.
- Bender, K., Reinwein, H., Gorman, L.Z., und Wolf, U. 1969. Familiäre 2/C-Translocation: 46,XYt(2p-;Cp+) und 46,XX Cp+. *Humangenetik* **8**: 94-104.

- Buyse, M., Bull, M.J., and Atkins, L. 1977. Prenatal diagnosis of partial trisomy 2p. *Am. J. Hum. Genet.* **29**: 26A.
- Cassidy, S.B., Heller, R.M., Chanzen, E.M., and Engel, E. 1977. The chromosome 2 distal short arm trisomy syndrome. *J. Pediat.* **91**: 934-938.
- Franke, U., and Jones, K.L. 1976. The 2p partial trisomy syndrome. *Am. J. Dis. Child.* **130**: 1244-1249.
- Iwatsubo T., Matsutani, Y., Kawaguchi, H., Eiraku, K., Nakajima, K., and Nishimura, K., 1978. An autopsy case of partial trisomy 2p (region 2p21-2pter) derived from a material t(2;15)(p21;q26). *Acta Paediat. Japon.* **82**: 1234.
- Lee, C.S.N., Bowen, P., Rosenblum, H., and Linsao, L. 1964. Familial chromosome-2,3 translocation ascertained through an infant with multiple malformations. *N. Engl. J. Med.* **271**: 12-16.
- Mayer, U., Schwanitz, G., Grosse, K.P., and Etzolt, R. 1978. Trisomie partielle 2p par translocation familiale 2/6. *Ann. Génét.* **23**: 172-176.
- Magenis, R.E., Koler, R.D., Lovrien, E., Bigley, R.H., DuVal, M.C., and Overton, K.M. 1975. Gene dosage: Evidence for assignment of erythrocyte acid phosphatase locus to chromosome 2. *Proc. Natl. Acad. Sci. USA* **72**: 4526-4530.
- Nagano, H., Kano, Y., Kobuchi, S., and Kajitani, T. 1979. A case of 2p partial trisomy syndrome with neuroblastoma. *Jpn. J. Hum. Genet.* **24**: 161.
- Seabright, M. 1971. A rapid banding technique for human chromosomes. *Lancet* **ii**: 971-972.
- Sekhon, G.S., Taysi, K., and Rath, R. 1978. Partial trisomy for the short arm of chromosome 2 due to familial balanced translocation. *Hum. Genet.* **44**: 99-103.
- Stoll, C., Messer, J., and Vors, J. 1974. Translocation t(2;14) équilibrée chez une mère et trisomie partielle d'une partie du bras court d'un chromosome N° 2 chez deux de ses enfants. *Ann. Génét.* **17**: 193-196.
- Yunis, E., González, J., Zūniga, R., Torres de Caballero, O.M., and Mondragon, A. 1979. Direct duplication 2p14→2p23. *Hum. Genet.* **48**: 241-244.