

Fixed Bicortical Screw and Blade Implants as a Non-Standard Solution to an Edentulous (Toothless) Mandible

Juraj Strecha^{1*}, Richard Jurkovic², Tomas Siebert³, Patrik Prachar⁴, Sonia Bartakova⁴

¹Eurodent Medima Ltd., Priehradka 20, 036 01 Martin, Slovak Republic

²Deimperio Ltd., Liscie Nivy 6, 821 08 Bratislava, Slovak Republic

³Dental Centre Ltd., Jeruzalemska 19, 91701 Trnava, Slovak Republic

⁴Clinic of Dentistry, Faculty of Medicine, Masaryk University and St. Anne's University Hospital, Pekarska 53, 65691 Brno, Czech Republic

Abstract

Aim This paper deals with the treatment of an atrophied toothless mandible with a fixing bridge carried by two non-standard implant systems.

Methodology Four bicortical screws were implanted into the frontal part of the mandible and one implant on each side was placed into the distal area of the mandible as a support for a fixing bridge.

Results During the years 2002 – 2007 the authors placed a total of 256 bicortical screw and 84 blade implants. During this

period only four bicortical screws and one blade implant failed. The primary and secondary surgical success rate was therefore above 98%, while the prosthetic success rate was 100%. (Bridges which had to be re-fabricated due to implant failure were not taken into account.)

Conclusion This approach is recommended as a highly successful and affordable option for a wide range of patients.

Keywords bicortical implant, blade implant, circular bridge, edentulous (toothless) mandible

Received Dec.17, 2009; Revision accepted Mar. 5, 2010

Introduction

A dental implant is a suitable substitution for one tooth or a group of teeth. After placing an implant into the alveolar bone of the mandible or the maxilla, the process of healing (osteointegration or osseointegration) begins. The length of healing varies, depending on anatomic conditions and the type of implant. Generally, in the first days after implantation, a phase of angiogenesis starts, followed by the formation of new osseous tissue in the bone around the implant. After two or three weeks, bone recovery accompanied by osteoclastic and osteoplastic phases takes place. An active osteointegration is said to begin approximately four weeks after implant placement. Good osteointegration requires choosing an appropriate atraumatic surgical procedure, sharp preservative tools,

and a stable position for the implant. Nowadays, implantologists attempt to accelerate the process of osteointegration by developing new implants with bioactive surfaces. Good primary stability of the implant is the most important requirement for osteointegration.

Good mandible bone is essential for successful application of various types of implants in different diagnoses. In spite of frequent and significant atrophy of the alveolar ridge of the mandible, the success rate of implantation is higher in the mandible than in the maxilla. A relatively wide interforaminal area offers sufficient osseous tissue for placement of enoseal implants. The most significant advantage of this procedure is that we can use the whole bone in the interforaminal area, especially the firm cortical layer of the mandible. The anatomy of this area provides an excellent

primary stability for implants and greatly encourages undisturbed and smooth osteointegration. Strain can be placed on the bicortical self-taping screws very soon or immediately after their placement. This area is also used for fixed as well as for removable partial dentures.

Materials and Methods

A bicortical implant is a one-phase self-taping screw which can be placed into both cortical layers of the mandible in the interforaminal area (Figure 1). The upper cortical layer can sometimes be a problem due to the destructive periodontal process and necessary correction of the alveolar ridge during implant placement. The bicortical implant is mainly applied to the lower cortical layer of the mandibular edge, where it is firmly fixed. The screwing part penetrates through the whole depth of the mandible, the polished part passing through a gingival layer and only an implant abutment protrudes into the oral cavity (Figure 2). Implant abutments can be of various shapes for bond or screw crowns. The number of bicortical implants that can be placed into the interforaminal area depends on the mass and quality of the bone. In our experience three implants are the minimum; four implants are ideal n. A very important requirement is to place bicortical implants as parallel as possible which is not a technical problem (Figure 2).



Figure 1 Bicortical implants

(Photo: Eurodent medima)

Lateral sections of an atrophied mandibular bone are often very problematic for placement of screw implants of an appropriate length. Lack of

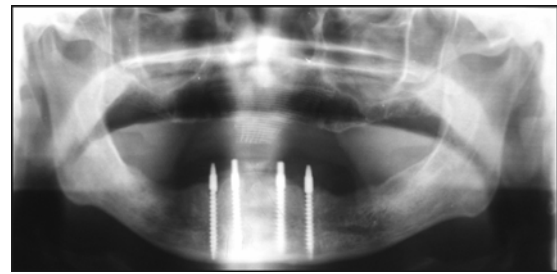


Figure 2 Bicortical implants in X-ray image

(Photo: Eurodent medima)




Figure 3 Blade implant

(Photo: Eurodent medima)

bone mass above the mandibular canal and a narrow and sharp edge disable even simple surgeries during screw implantation. Complicated surgical procedures in reconstruction of the alveolar ridge and subsequent placement of numerous screw implants have no place in common implantological practice. The anatomical shape of the mandible enables the surgeon to place blade implants by means of an atraumatic operative procedure (Figure 3). Application of blade implants requires surgical skills and adequate training.

Surgery

The surgical procedure begins with a crestal incision along the length of ten frontal teeth (from tooth 20 to tooth 29) and an auxiliary incision in the median plane towards the vestibule of the mouth. Subsequently a mucoperiosteal flap is made. This flap should be large enough to enable a good view into the operation field and provide enough space for modification of the alveolar ridge if necessary. In the area of the 22nd, 23rd, 26th and 27th tooth, holes are drilled into the lower edge of the mandible. When the drill reaches the corticalis

of the lower edge of the mandible, we continue drilling for about one more millimeter. The drilled holes have to be parallel to each other. Parallelism of drilling is controlled with metal probes placed into the drilled holes. The bone mash we obtain from drilling is stored for later use. The depth of the drilled holes is the same or slightly greater than the length of the thread of the chosen bicortical implants. We carefully place bicortical implants one by one into the holes (Figure 4). At this point it is necessary to emphasize that the implants have to be placed very slowly – by quarter-revolutions – because the cutting thread of an implant can produce significant friction during placement, overheating the surrounding bone and causing irreversible damage to it. When the implant reaches the bottom, it is tightened to 35 N-cm. Bicortical implants implanted in this fashion are very firm. We rinse the wound with a physiological solution and suture the mucoperiost with an atraumatic stitching material. We cut off the excessive margin of the mucoperiost flap, which remains from previous correction of the alveolar ridge, into a suitable width so that the suture remains without tension. The spaces between individual implants are sutured with vertical mattress stitches. In the neck area of the implants, we suture the mucoperiost from both sides with individual stitches very close to each implant.

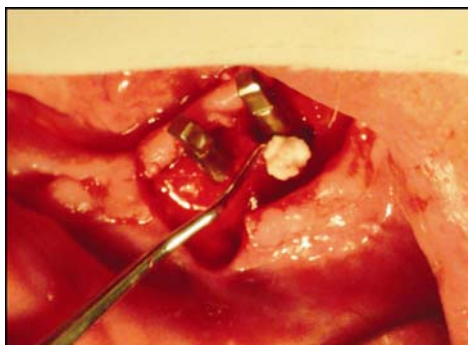


Figure 4 Bicortical implants with periimplant augmentation

(Photo: Eurodent medima)

In the second phase of the operation, we extend the original crestal incision distally up to section 8. Mucoperiost is lifted and the top of the alveolar ridge is cleared of scar tissues and slightly corrected. In section 6, we drill three holes with a fissure drill into the corticalis at a distance of 1–2 mm. We

interconnect these holes by means of the fissure drill to form a slot. Then we place a circular cutter (delivered by the producer of the blade implants) onto the slot and cut a groove into the corticalis the length of the body of the blade implant. Wherever necessary, we modify the required depth of the groove with the fissure drill. The entire procedure can also be done atraumatically using a more time-consuming surgical technique called piezosurgery (Sivolella *et al.*, 2007).

The blade implant is inserted into the prepared groove and softly knocked with an inserting tool and hammer to the bottom so that the implant body is placed approximately 1 mm below the alveolar ridge peak (Figure 5). A blade implant placed in this way is very stable. Then we fill the part of the groove over the implant body with the bone mash obtained in the first stage of operation. Finally, we suture the mucoperiost with mattress stitches in combination with individual stitches applied on both sides of the implant abutments (with slight bending it is possible to achieve parallel alignment of the abutments of blade implants on both sides). After the operation, the patient is given suitable analgesics and broad-spectrum antibiotics.

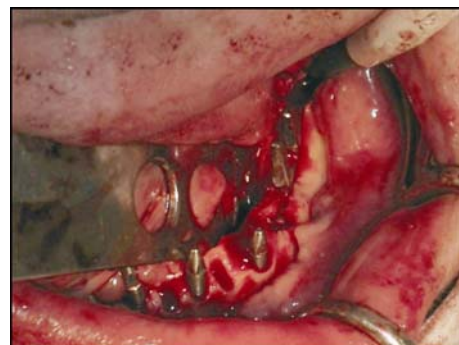

Figure 5 Preoperative image of bicortical implants and blade implant placed into the left lateral area of the mandible

(Photo: Eurodent medima)

Prosthetic Phase

Approximately ten days after operation, when the mucoperiost has healed, we remove the stitches and make a double imprint into a silicone imprint substance (Figure 6). With the first imprint we check the alignment of implants. Slight irregularities could be removed with a cutter before the

second imprint. The second imprint registers the occlusion of the opposite teeth. Then the prosthetic phase continues in a dental laboratory with a dental technician preparing a metal construction. Later we tested this construction by placing it onto the abutments (Figure 7). We checked its stability and the state of the individual abutments, connecting members and occlusion. It is advisable to check the bite occlusion once more with the silicone imprint and if necessary, the dental technician can re-plaster the models in an articulator, and finish the work by putting a ceramic layer on it. We test the prepared bridge by setting it on the abutments. When it was stable and causes no problems with articulation, we fix it with glass ionomer cement (Figure 8).

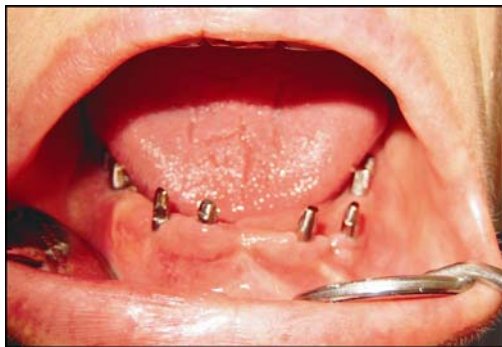

Figure 6 The state 10 days after placement of bicortical and blade implants

(Photo: Eurodent medima)

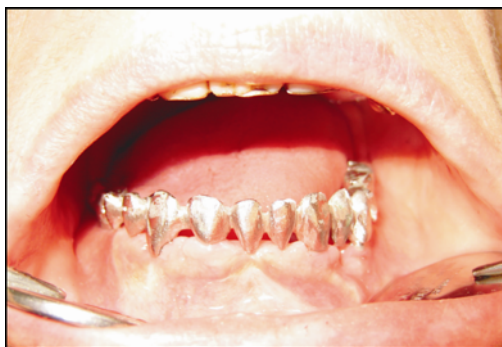

Figure 7 Test of a metal supra-construction

(Photo: Eurodent medima)

If the wound has not healed properly or there are complications, we postponed fabrication of a permanent bridge for three months, and the patient uses a temporary resin splint bridge.

As we have often used this procedure in elderly (toothless) patients, the shape of the fixing bridge

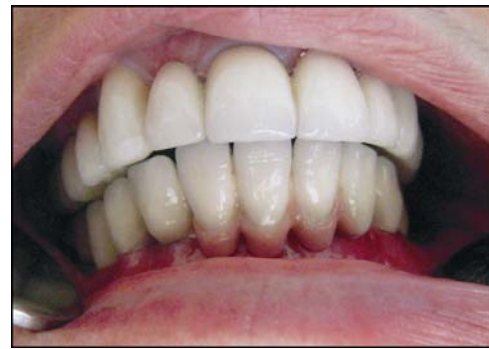

Figure 8 Fixed bridge

(Photo: Eurodent medima)

is modelled so that hygiene around the implants does not problems. This is easily achieved because, in the mandible, we focus more on function and hygiene than on “red-white” aesthetics. After completing the prosthetic phase, we instruct the patient on how to brush their “new teeth”. The first check-up is two weeks after the operation and depending on the result of the oral cavity examination; we then plan a further recall. Three months after implant load, we check the state of implants by X-ray, and then repeat this each successive year (Figure 9).

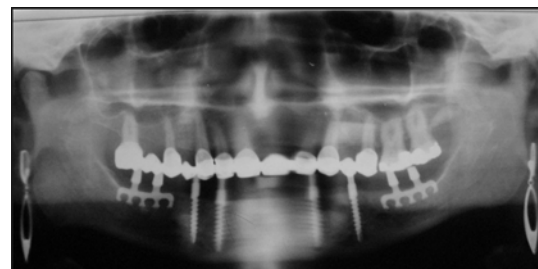


Figure 9 X-ray examination after 2 years

(Photo: Eurodent medima)

Results

From 2002 to 2007 we placed 256 bicortical implants into the mandible. We applied 84 blade implants into the lateral area of the mandible. We made 29 supported removable dentures and 32 fixed circular bridges. During this period only one blade implant broke. Four bicortical implants healed with fibrous integration and had to be removed. Out of these four, two bicortical implants were replaced with new implants into the neigh-

Table 1 Review of bicortical and blade implants use in the years 2002–2007

	Number of bicortical implants	Number of blade implants	Number of supported dentures	Number of circular bridges
Total number of implants	256	84	29	32
Failure of bicortical implants	4			
Failure of blade implants		1		
Success rate	98.4%	98.8%		
Men			8	15
Women			21	17
Mean age		58 years		

bouring area and the prosthesis was re-fabricated (Table 1).

In our experience, a successful implant placement depends on good primary healing of the mucoperiost above the implant body. This can be achieved with precise surgery of the mucoperiosteal lobe and application of atraumatic sutures. The success rate of bicortical implants is generally very high and can be further ensured by precise drilling into the tooth bed with a sharp drill and careful and slow insertion of the implants into the bone. The shape and exact length of bicortical implants (mainly the screw part) are ordered at a manufacturer according to data taken from the patient's orthopantomographic image or CT scan or an analysis of study models.

Discussion

The described method is a non-standard therapeutic treatment of an atrophied toothless mandible. Therapy by means of a Brånemark's bridge, which has up to now been modified by development of new implant surfaces, is still considered to be the "gold standard" in implantology (Brånemark *et al.*, 1987). This method is perfectly elaborated and described in many scientific studies; however, the costs are quite high for the patient. The procedure we have suggested in this paper is less expensive. This is a non-standard alternative to a fixed denture and the patients prefer it to a totally removable denture.

In screw implants, the heaviest strain is placed on the cervical area of the implant, on the site where the implant enters the crestal bone (Pierrisnard *et al.*, 2003). For implantologists – as well as

for us – this means that it is necessary to anchor the implants bicortically (if anatomy allows). This is the basis of this implant system (Payne *et al.*, 2001; Tawse-Smith *et al.*, 2001). The difference in this system is determining which cortical layer (besides corticalis of the crestal bone) is used for stabilization of the bicortically anchored implant. Joeng *et al.* tried a model anchored into the lingual cortical layer of bone, but their evaluations did not confirm the advantages of this option (Jeong *et al.*, 2003). We anchored implants into the inner part of the lower edge of the frontal body of the mandible because it provides better stability than the lingual cortical bone.

In modern dental implantology, the history of blade implants was started by Professor Linkow in the USA (Linkow, 1968). Blade implants are not considered a standard implant system. Despite this, they are successfully used in Slovakia as well as in other countries, although less often than other types of screw implants (Roberts, 2002). However, there are many papers describing the blade implants (Commissionat *et al.*, 1996; Roberts, 1996; Veron *et al.*, 1997; Roberts, 2002). In our practice, we have used two-abutment blade implants placed into the distal area of the alveolar ridge of the mandible for stabilization of fixing bridges in connection with bicortical screws inserted interforaminally. We consider this method a stable and suitable therapeutic method for a group of elderly patients who either have anatomical problems with their alveolar ridge or do not have enough money to pay for a standard fixed denture, Brånemark's bridge, or other type of circular bridge.

Other authors have reported on the use of transmandibular implants in the extremely atrophied mandible. These implants have excellent primary

stability but this treatment is much more traumatic than the use of bicortical screws (Stellingsma *et al.*, 2004).

Conclusion

Our five-year experience with this non-standard implant system confirms its functionality, stability and ease of home care. The method is appropriate for reconstruction of an atrophied toothless mandible in elderly patients and in patients who choose this alternative for financial reasons. It is important to emphasize that non-standard implant systems require an experienced and skilful surgeon. We stress that the success rate of healed blade implants depends very much on atraumatic work with bone and mucoperiost. Only then is it possible to guarantee good long-term results.

In the study we used bicortical and blade implants made by VNI fy. Frank-Kreisler from the Czech Republic (www.dentalniimplantaty.cz), and by fy. Martikan from the Slovak Republic (www.martikan.eu). Both implant systems are made of biocompatible material (titanium).

The materials have been tested and their production is approved by certificate no. 080092QS/NB, certificate 080093T/NB and EC certificate no. 44133/101/1/2007/CE valid in the European Union.

References

- Brånemark PB, Zarb, GA, Albrektson, T (1987). *Tissue-integrated protheses: osseointegration in clinical dentistry*. Special edition for Nobelpharma Chicago. Illinois: Quintessence Publishing, p350.
- Commissionat Y, Poulmaire F (1996). Blade implants: new ideas. *Rev Stomatol Chir Maxillofac*, 97(5): 283–287.
- Jeong CM, Caputo AA, Wylie RS, Son SC, Jeon YC (2003). Bicortically stabilized implant load transfer. *Int J Oral Maxillofac Implants*, 18(1): 59–65.
- Linkow LI (1968). The blade vent – a new dimension in endosseous implantology. *Dent Concepts*, 11(2): 3–12.
- Payne AG, Tawse-Smith A, Kumara R, Thomson WM (2001). One-year prospective evaluation of the early loading of unsplinted conical Brånemark fixtures with mandibular overdentures immediately following surgery. *Clin Implant Dent Relat Res*, 3(1): 9–19.
- Pierrisnard L, Renouard F, Renault P, Barquins M (2003). Influence of implant length and bicortical anchorage on implant stress distribution. *Clin Implant Dent Relat Res*, 5(4): 254–262.
- Roberts R (2002). Placement of plate-form implants using osteotomes. *J Oral Implantol*, 28(6): 283–289.
- Roberts RA (1996). Types, uses, and evaluation of the plate-form implant. *J Oral Implantol*, 22(2): 111–118.
- Sivolella S, Berengo M, Fiorot M, Mazzuchin M (2007). Retrieval of blade implants with piezosurgery: two clinical cases. *Minerva Stomatol*, 56(1/2): 53–61.
- Shen TC (1999). The use of different implant modalities in the atrophied ridge. *J Oral Implantol*, 25(2): 109–113.
- Stellingsma K, Raghoebar GM, Meijer HJ, Stegenga B (2004). The extremely resorbed mandible: a comparative prospective study of 2-year results with 3 treatment strategies. *Int J Oral Maxillofac Implants*, 19(4): 563–577.
- Tawse-Smith A, Perio C, Payne AG, Kumara R, Thomson WM (2001). One-stage operative procedure using two different implant systems: a prospective study on implant overdentures in the edentulous mandible. *Clin Implant Dent Relat Res*, 3(4): 185–193.
- Veron C, Chanavaz M (1997). Implant rehabilitation of distal mandibular atrophy using a blade implant. *Rev Stomatol Chir Maxillofac*, 98(Suppl 1): 17–22.

*Corresponding author: Juraj Strecha

Address: Eurodent Medima s.r.o., Priehradka 20, 036 01 Martin, the Slovak Republic

E-mail: strecha@medima.sk
