

Depth evaluation of intended vs actual intacs intrastromal ring segments using optical coherence tomography

R Barbara¹, A Barbara² and M Naftali³

Abstract

Purpose Evaluation of actual vs intended intrastromal corneal ring segments (ICRS) implantation depth as measured by anterior segment optical coherence tomography (OCT)
Methods Prospective study evaluating 30 Intacs segments implanted manually in 19 eyes of 15 patients suffering from keratoconus. Segment depth evaluation was performed using anterior segment OCT. Measurements were performed above and below the segment at 3 points in relation to the incision site. Statistical analysis was performed using the SAS software for ANOVA, matched *t*-test, and GLIMMIX procedure.

Results Intacs segment depth was 153- μ m shallower than intended (58% vs 80%). Segment layout demonstrated the proximal and distal portions to be 13- μ m shallower and 12- μ m deeper (on average), respectively. Intacs segment thickness does not influence implantation depth. Intacs segments implanted in the same eye do not share similar implantation depths. Stromal compression is likely to occur.

Conclusion Intacs are implanted at a shallower depth than intended. The 'pocketing' stage prior to implantation most likely has a stronger effect on the segment's final implantation depth than does the incisions' depth.

Eye (2016) 30, 102–110; doi:10.1038/eye.2015.202; published online 23 October 2015

Introduction

Keratoconus (KC) is a relatively common ectatic degenerative corneal disease.^{1,2} FDA-approved³ intrastromal corneal ring segments (ICRS) have been found beneficial for the treatment of

KC and corneal ectasia following refractive surgery^{4–6} as they flatten and regularize the cornea by means of an arc shortening effect.⁷

The most common types of ICRS used in clinical practice are Intacs (Addition Technology, Inc., Sunnyvale, CA, USA) and Ferrara rings (Ferrara Ophthalmics, Brazil).⁸ Although both are made of polymethylmethacrylate (PMMA), they vary in their radius of curvature and cross-sectional shape. The original Intacs segments had 6.77 mm internal radius, 8.10 mm outer radius, 250–450 μ m thicknesses, 150 degrees arc length, and a hexagonal cross-section,⁹ vs 4.4 mm, 5.60 mm, 200–350 μ m, 160 degrees, and a triangular cross-section respectively for Ferrara rings.⁸ Ferrara rings are hence implanted closer to the centre of the cornea and presumably have a stronger flattening effect.¹⁰ Intacs SK are a new segment design by Addition Technology, intended for the treatment of moderate to severe keratoconus. They are 6 mm oval-shaped segments, available in 400 and 450 μ m thicknesses.² Although it is recommended for ICRS to be implanted at a depth of 66–75% of the total corneal thickness at the incision site, it is common practice to aim for depths of 70% for Intacs and 80% for Ferrara.¹¹

There are two methods of implanting ICRS: either femtosecond laser-assisted, or with a mechanical approach.¹¹ Shallow implantation is associated with complications such as implant exposure due to corneal thinning over the implant,¹² implant extrusion,¹¹ anterior stromal compression,¹³ compromised diffusion of nutrients to the corneal epithelium,¹³ and segment superficialization.⁸

Assessing ICRS depth may help predict future complications. Slit lamp examination, Pentacam imaging (Oculus Optikgerate GmbH), and anterior segment optical coherence tomography

¹Department of Ophthalmology, Bnai Zion Medical Centre, Haifa, Israel

²Hadassah Optimal Private Medical Centre, Affiliated to Hadassah Medical Centre, Haifa, Israel

³Ophthalmology Unit, Baruch Padeh Medical Centre, Poriya, Israel

Correspondence: R Barbara, Department of Ophthalmology, Bnai Zion Medical Centre, 29 Tchernikhovski Street, Haifa 35701, Israel
 Tel: +972 052 444 8687.
 E-mail: ramezborbara@gmail.com

Received: 29 January 2015
 Accepted in revised form: 24 August 2015
 Published online: 23 October 2015

(OCT) are common methods for assessing ICRS implantation depth, with the latter two techniques providing the most precise assessment.^{8,11,14}

Patients and methods

This is a prospective study approved by the Helsinki Board at Padeh Medical Centre, Poriya, Israel. All applicable institutional and governmental regulations concerning the ethical use of human volunteers were followed during this research. All patients underwent Intacs ICRS implantation in at least one eye for the treatment of keratoconus. Data collected were segment size, expected segment depth, and actual postoperative ICRS depth as measured by OCT (OPKO Spectral OCT/SLO) at 3 points for each segment. Thirty intrastromal ring segments implanted in 19 eyes of 15 patients were measured using OCT (OPKO Spectral OCT/SLO). Relevant data including demographics were collected from patients' charts.

Surgical technique

The surgical procedure was performed by the same surgeon (AB) according to the company's manual and instructional course,⁹ under topical anesthesia. Briefly—standard prepping and draping were performed. The cornea was marked with the special Intacs marker provided by Addition Technology (Lombard, IL, USA). A 1.2-mm radial incision was made along the steep axis at a depth of 80% of corneal thickness as measured by a pachymeter in the operating room. Pachymetry was done at the incision site and on the hypothetical channels as marked by the special Intacs marker. After applying a semiautomated suction ring and high vacuum by the vacuum system, dissection was performed using a channel guide in clockwise and counterclockwise directions. The Intacs segments were inserted as planned in the created corneal channels. The procedure was sutureless and post operative treatment with topical antibiotics and steroid eye drops were used for 4 weeks.

OCT features

Three scans were performed for each segment in relation to the incision site. The first, second, and third measurements were at the proximal, central, and distal portions of the segment, respectively. The meridian of the incision and the scan location differed for each patient, as for each eye, the incision was made in the steepest meridian in reference to the corneal topography. The reported variables were calculated as follows:

- Three measurements above the segment were obtained at the proximal, central, and distal portions. Each measurement was performed from the outer corneal surface to the shallow edge of the segment (Figure 1a).
- Three measurements below the segment were obtained at the proximal, central, and distal portions. Each measurement was performed from the inner corneal surface to the inner deep edge of the segment (Figure 1a).
- The averages of the 3 measurements (proximal, central, and distal) above and below the segment were calculated.
- The deepest and shallowest measurements were recorded for each segment. The difference between the maximal and minimal depths for each segment were calculated.
- The percentage depth of segment was calculated by dividing the average reading of the 3 measurements

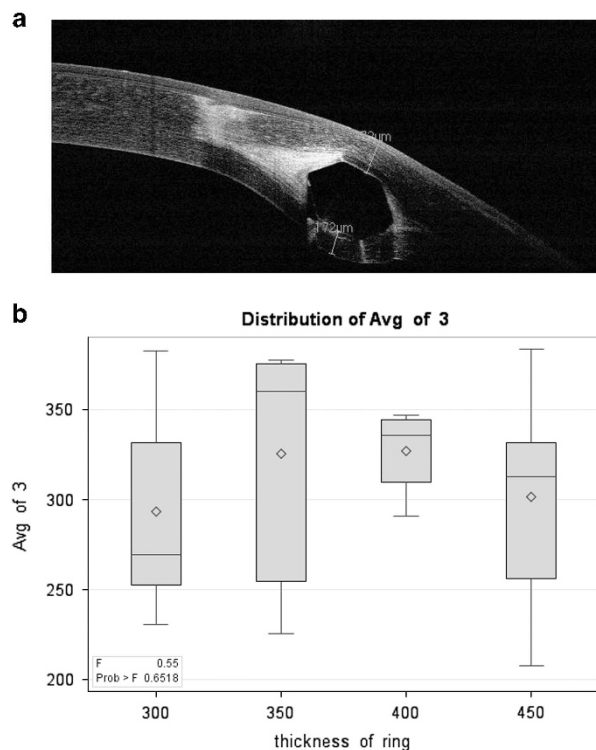


Figure 1 (a) OCT scan of a cornea with ICRS demonstrating 2 measurements, above the segment (outer corneal surface to the superficial edge of the segment), and below it (inner corneal surface to the inner deep edge of the segment). (b) Distribution of the average depth values (averages taken of patients' eyes), as a function of segment thickness. These distributions' respective averages are denoted as diamonds, and their medians as horizontal lines. No significant differences were found between the four averages ($F=0.55$, $P>0.65$). The graph elucidates the differences in the variances with a relatively small variability when thickness was 400 μm .

above the segment by corneal thickness at the thinnest point along the tract (referred to as Method 1):

$$\left(\frac{\text{Avg (Proximal + Central + Distal)}}{\text{Thinnest point along the tract}} \right) \times 100$$

- The percentage depth of segment (at each of the 3 points) was calculated by measuring the corneal thickness above the segment (TA) in relation to the corneal thickness above (TA) plus the corneal thickness below the segment (TB) as measured by OCT using the formula (referred to as Method 2):

$$\left(\frac{TA}{TA + TB} \right) \times 100$$

Statistical methods

We applied ANOVA (Analysis of Variance) to compare the means for independent samples, and used the matched *t*-test to estimate and test the differences between the target and the actual values. We applied a mixed model to estimate the intraclass correlation for continuous measurements as the dependent variable, taking into account the data's repeated-measure structure. We applied the GLIMMIX procedure to fit the logistic model with repeated measures. We used the SAS software (SAS Institute, Cary, NC, USA) to perform all the statistical analyses.

Results

We evaluated 30 segments of 19 eyes of 15 patients. Table 1 contains all data collected for each segment. Table 2 summarizes the data.

Patients had one or two segments implanted in each eye depending on clinical need, as judged by the surgeon. Table 3 shows the distribution of the 30 segments. Fifteen segments were 450 μm in thickness, four were 400 μm , six were 350 μm , and five were 300 μm (Table 4).

The thinnest point along the tract was between 504–658 μm , with an average of 563 μm (SD – 59 to +95). Incision depth was dependent on corneal thickness at the intended incision site, aiming at 80% depth and ranging between 420–500 μm , with an average of 461 μm (SD – 41 to +39). Corneal thickness at the incision site ranged from 568–687 μm , with an average of 607 μm (SD – 39 to +80). Average CCT was 440 μm (SD – 97 to +110; range 343–550 μm). Average depth of the segments was 295 μm (SD – 120 to +83), 309 μm (SD – 114 to +96), and 321 μm (SD – 108 to +125) in the proximal (closest to the incision site), central, and distal portions respectively. Average thickness of the three readings above the segments (proximal, central, and distal) was 308 μm (SD – 100 to +70; range 208–378 μm). The difference between the highest and lowest readings for segment depth was 51 μm (SD – 31 to 89, range 20–140 μm).

Average segment depth calculated using Method 2 was 57%, 58%, and 60% for the proximal, central, and distal portions respectively; the shallowest being 36%, 37%, and 40% respectively; and the deepest being 75%, 75%, and 82% respectively. Average corneal thickness below the segment was 227 μm (SD – 99 to +109), 221 μm (SD – 100 to +147), and 215 μm (SD – 114 to 112) for the proximal, central, and distal portions, respectively. Using Method 1 to evaluate segment depth revealed an average of 55%, ranging from 39–69%, which is comparable to the results of Method 2.

As part of our analysis, we aimed to answer the following questions, which might aid in future planning and performing the surgery:

1. What is the probability of two segments implanted in the same eye having similar depths when compared with segments implanted in all eyes?

To answer this question, we fitted a mixed model with the average of the proximal, central, and distal measurements as the dependent variables, taking into account the data's repeated-measures structure. The model indicated a slightly larger variance (1746.54) between the eyes of one patient compared with the variance between the eyes of different patients (1628.92), which yields an intraclass correlation of only 0.48. Thus we cannot assume that two segments in the same eye will be at closer implanted depths when compared with the segments in other patients' eyes.

2. Is there a correlation between a segment's thickness and its depth of implantation?

Although the segments were of differing thicknesses, we still aimed to implant them at 80% of corneal depth in that area. No correlation was observed between the segment's depth and depth of implantation ($r = -0.03$, $P = 0.87$; Figure 1b).

3. What is the statistical significance between a segment's intended and actual depths?

The mean deviation of the observed compared with the target value is – 152.9 μm (0.95 confidence interval (–132.7, – 173.1)), which differs significantly from zero ($P < 0.0001$). This indicates that there is a significantly high probability that the implanted segment will not be as deep as planned (with 0.95 confidence, it will be shallower by more than 132 μm).

4. What is the significance of the difference between each measurement above the segment (proximal, central, and distal) and their average?

We performed calculations for each parameter and compared them to the average readings using the

Table 1 Patients' data showing collected and calculated figures

Patient	Age (years)	Eye	Thickness of corneal ring segment	Thinnest point along the tract	Incision depth	Corneal thickness at incision site	Intended depth/corneal incision ^a	Corneal thickness above ring segment						Corneal thickness below ring segment						$\left(\frac{TA}{TA+TB}\right) \times 100^b$	% Depth of ring ^c			
								High—Low ^d			Average ^d			Proximal			Central					Distal		
								Proximal	Central	Distal	Proximal	Central	Distal	Proximal	Central	Distal	Proximal	Central	Distal			Proximal	Central	Distal
1	29	LE	450	594	480	604	79%	302	326	329	319	27	284	288	286	286	286	286	286	52%	53%	53%	54%	
2	32	RE	450	567	450	574	78%	265	331	343	313	78	165	166	183	171	183	171	183	62%	67%	65%	55%	
3	31	RE	450	639	500	662	76%	378	379	355	371	24	238	231	283	251	283	251	283	61%	62%	56%	58%	
		RE	300	639	500	662	76%	278	254	226	253	52	247	275	280	267	280	267	280	53%	48%	45%	40%	
		LE	450	658	500	654	76%	255	244	270	256	26	307	281	308	299	308	299	308	45%	46%	47%	39%	
		LE	400	658	500	654	76%	344	369	327	347	42	214	206	232	217	232	217	232	62%	64%	58%	53%	
4	31	LE	450	634	460	593	78%	260	300	359	306	99	230	251	231	237	251	231	237	53%	54%	61%	48%	
5	26	RE	400	545	500	687	73%	325	346	356	342	31	336	309	321	322	322	322	322	49%	53%	53%	63%	
6	41	LE	450	579	450	583	77%	331	405	415	384	84	206	206	187	200	206	187	200	62%	66%	69%	66%	
7	29	RE	450	504	460	607	76%	220	218	213	217	7	289	251	276	272	272	272	272	43%	46%	44%	43%	
8	31	RE	450	505	430	594	72%	184	195	244	208	60	219	266	195	227	227	227	227	46%	42%	56%	41%	
		RE	450	505	430	594	72%	276	307	311	298	25	203	174	203	193	203	193	203	59%	64%	59%	59%	
9	22	RE	400	571	450	569	79%	320	326	340	329	20	218	182	184	195	184	195	184	59%	64%	65%	58%	
		RE	300	571	450	569	79%	294	277	238	270	56	194	201	210	202	210	202	210	60%	58%	53%	47%	
		LE	450	576	450	596	76%	340	338	317	332	23	130	160	146	145	146	145	146	72%	68%	68%	58%	
10	27	LE	450	573	450	628	72%	275	294	375	315	100	185	165	118	156	165	118	156	60%	64%	76%	55%	
		LE	350	573	450	628	72%	377	359	374	370	18	128	121	107	119	121	107	119	75%	75%	78%	65%	
11	49	RE	350	506	440	572	77%	175	235	267	226	92	306	221	202	243	262	226	243	36%	52%	57%	45%	
		RE	450	506	440	572	77%	216	214	214	233	54	327	368	327	341	368	327	341	45%	37%	40%	46%	
		LE	400	552	450	584	77%	286	278	309	291	31	301	262	226	263	262	226	263	49%	51%	58%	53%	
		LE	300	552	450	584	77%	218	239	235	231	21	264	302	231	266	302	231	266	45%	44%	50%	42%	
12	49	RE	300	562	420	568	74%	274	339	382	332	108	209	199	208	205	208	205	208	57%	63%	65%	59%	
		LE	300	601	450	609	74%	306	396	446	383	140	179	129	101	136	129	101	136	63%	75%	82%	64%	
13	24	LE	450	544	480	605	79%	272	333	390	332	118	172	140	134	149	140	134	149	61%	70%	74%	61%	
		LE	350	544	480	605	79%	360	392	381	378	32	140	200	189	176	200	189	176	72%	66%	67%	69%	
14	41	RE	350	538	480	672	71%	364	352	334	350	30	280	275	274	276	275	274	276	57%	56%	55%	65%	
		RE	350	538	480	672	71%	401	358	368	376	43	270	249	278	266	249	278	266	60%	59%	57%	70%	
15	26	RE	450	530	450	568	79%	348	324	358	343	34	139	155	158	151	155	158	151	71%	68%	69%	65%	
		RE	350	530	450	568	79%	265	240	259	255	25	236	227	228	230	227	228	230	53%	51%	53%	48%	
Average	32.5			563	461	607	76%	295	309	321	308	51	227	221	215	221	221	215	221	57%	58%	60%	55%	

^aIntended incision depth in relation to corneal depth at incision site. ^b%Segment depth calculated using $\left(\frac{TA}{TA+TB}\right) \times 100$ formula. TA = corneal thickness above segment; TB = corneal thickness below segment. ^cDepth of ring segment calculated using $\left(\frac{\text{corneal thickness above segment}}{\text{thinnest point along the tract}}\right) \times 100$ formula. ^dAverage of the 3 readings of corneal thickness above ring segment. ^eDifference between highest and lowest readings of corneal thickness above ring segment. ^fAverage of the 3 readings of corneal thickness below ring segment.

Table 2 Figures and averages of results

	Range μm	Average μm	%	SD
Thinnest point along the tract	504–658	563		–59 to +95
Depth of incision	420–500	461		–41 to +39
Corneal thickness at incision site	568–687	607		–39 to +80
Central Corneal Thickness	343–500	440		–97 to +110
Difference between attempted and actual segments depth	66–252	153		–87 to +99
Difference between highest & lowest readings for segments depth	7–140	51		–44 to +89
<i>CTA</i>				
Proximal	175–401	295		–120 to +83
Central	195–405	309		–114 to +96
Distal	213–446	321		–108 to +125
Average of CTA (proximal, central & distal)	208–384	308		–100 to +76
<i>CTB</i>				
Proximal	130–327	227		–99 to +109
Central	121–309	221		–100 to +147
Distal	101–327	215		–114 to +112
Average of CTB (proximal, central & distal)	119–322	221		–102 to +101
$\frac{CTA}{CTA+CTB}$				
Proximal	36–72%		57	
Central	37–75%		58	
Distal	40–82%		60	

Abbreviations: CTA, corneal thickness above segment; CTB, corneal thickness below segment.

Table 3 Distribution of the 30 implanted segments in the 19 eyes of 15 patients

Number of patients	Number of treated eyes in each patient	Total number of eyes	Number of Intacs segments in each eye	Total number of Intacs segments
2	2	4	2	8
6	1	6	2	12
5	1	5	1	5
1	2	2	1 and 2	3
1	2	2	1	2
15 patients		19 eyes		30 Segments

Table 4 The number of each segment thickness used

Number of segments used	Thickness of segments μm
15	450
4	400
6	350
5	300

Univariate procedure. The estimated expected value of the deviation between the proximal above, and the average is –13.31 (0.95 confidence interval (–24.20, –2.41)), which differs significantly from zero ($P=0.0184$). The estimated expected value of the deviation between the central above and the average is 0.98 (0.95 confidence interval (–3.73, 5.71)), which does not significantly differ from zero ($P=0.67$). The estimated expected value of the deviation between the distal above and the average is

12.32 (0.95 confidence interval (2.17, 22.47)), which differs significantly from zero ($P=0.019$).

5. What is the significance of the difference between each measurement below the segment (proximal, central, and distal) and their average?

We performed calculations for each parameter and compared them with the average readings using the Univariate procedure. The estimated expected value of the deviation below the proximal segment and the average was 5.67 (0.95 confidence interval (–1.9, –13.24)), which does not significantly differ from zero ($P=0.137$). The estimated expected value of the deviation between the below the central segment and the average was 0.33 (0.95 confidence interval (–5.8, 6.47)), which does not significantly differ from zero ($P=0.91$). The estimated expected value of the

deviation below the distal segment and the average was -6.0 (0.95 confidence interval $(-13.3, 1.13)$), which does not significantly differ from zero ($P = 0.096$).

6. Comparison between intended and actual measurement at the 3 points (proximal, central, and distal portion of the segment) and their mean

Univariate procedure was used. The estimated expected value of the deviation between the target value and the proximal depth was 0.195 (0.95 confidence interval $(0.16, 0.23)$), which differs significantly from zero ($P < 0.0001$). The estimated expected value of the deviation between the target value and the central depth was 0.176 (0.95 confidence interval $(0.13, 0.21)$), which differs significantly from zero ($P < 0.0001$). The estimated expected value of the deviation between the target value and the distal depth was 0.16 (0.95 confidence interval $(0.12, 0.20)$), which differs significantly from zero ($P < 0.0001$). The estimated expected value of the deviation between the target value and the mean depth of the 3 measurements was 0.18 (0.95 confidence interval $(0.14, 0.21)$), which differs significantly from zero ($P < 0.0001$). Thus, for all measurements, actual depth was significantly shallower than intended.

7. We hypothesize that when a segment is inserted into the cornea, it results in compression of the superior or inferior corneal lamella

This hypothesis was tested by adding the corneal thicknesses above (TA) and below (TB) the segment and comparing it to the thinnest point measured along the tract (TT) prior to inserting the segment. If subtracting TA + TB from TT results in a positive value, then one could assume that compression has resulted, while a zero or negative value rejects this hypothesis. In our data, 22 values were positive and 8 were negative. In order to test our hypothesis, we defined a binary variable obtaining the value '1' if the difference was positive, and '0' otherwise. We used the GLIMMIX procedure of SAS to fit the logistic model with repeated measures, as there was more than one observation per patient. Among the 30 differences, 8 were negative and 22 positive. According to the fitted model, the estimated probability of a positive difference is 0.73 with a 0.95 confidence interval $(0.45, 0.90)$.

The estimated odds ratio for an equal chance of positive vs negative difference differs from 1, but does not attain statistical significance at the 0.05 level. Thus, we cannot reject the hypothesis that there is an equal chance of a positive vs negative difference. Moreover, owing to the repeated measure data structure, the effective sample size was not 30 though we measured 30 differences. If those differences were measured on 30 different patients rather

than 15, then a proportion of $22/30$ compared with $8/30$ would lead to a highly significant conclusion that supports our hypothesis ($P < 0.01$).

Discussion

ICRSs are an established, approved surgical management option for keratoconus. Although designed for corneal implantation at a depth of 70–80%, this is rarely achieved, as proven by our study and others.^{8,13,14}

Various methods of assessing segment depth using OCT and Pentacam¹⁴ are referred to in the literature,^{8,13,15,16} including measuring from the anterior corneal surface to the apex of the segment;⁸ and from the anterior corneal surface to the inner ring of the segment.¹³ The method of quantifying segment depth common to all mentioned studies is measurement of the anterior corneal thickness only. This study is unique, as we were also able to measure the corneal thickness below the segment, and hence precisely measure ICRS depth in relation to corneal thickness in that area.

Our study demonstrates that the average measured depth of the implanted segments was $153 \mu\text{m}$ shallower than planned ($308 \mu\text{m}$ instead of the expected $461 \mu\text{m}$; $P < 0.0001$). The average ICRS depth was 58% instead of the planned 76%. Comparing the intended vs actual depth at the three points yields a shallower implantation than intended ($P < 0.0001$ for all three measurements). This is also true when comparing the mean of the three measurements to the intended depth ($P < 0.0001$).

Results in the study by Naftali *et al*⁸ are consistent with ours, showing a shallower implantation than intended by $120 \mu\text{m}$. Segment depth was $360 \mu\text{m}$, about $50 \mu\text{m}$ deeper than our results and corresponding to 60% of corneal thickness, vs 55% depth in our study using Method 1 and 58% using Method 2.

Koussai *et al* compared Intacs implantation using manual and femtosecond laser-assisted implantation, demonstrating shallower implantations than intended in both groups— $76 \mu\text{m}$ in the manual, and $86 \mu\text{m}$ in the laser-assisted—concluding that there was no difference between the two techniques with regard to segment depth. Gorgun *et al*¹⁶ measured anterior stromal thickness from the apex of the Ferrara segment following femtosecond laser-assisted implantation using OCT. On average, the segments were implanted $97\text{-}\mu\text{m}$ shallower than intended.

Lai *et al*¹³ suggested that shallow implantation can cause anterior stromal compression. Based thereon, ICRSs in our study were implanted deeper than 58% of corneal thickness due to anterior stromal compression. While we cannot be certain whether ICRSs cause anterior stromal compression only. Our statistical analysis can neither reject nor prove this hypothesis, due to the small sample size.

Although ICRSs implanted in the same eye shared the same initial incision depth, they tended not to be at similar depths to each other compared with all segments in the study (Intraclass correlation of only 0.48). This fact emphasizes the importance of the 'pocketing' stage—and not incision depth—as a determinant of segments' depth of implantation.

The segment's proximal portion was statistically significantly shallower than average ($13\ \mu\text{m}$; $P=0.0184$), the distal portion was statistically significantly deeper than average ($12\ \mu\text{m}$; $P=0.019$). This suggests that as we create the tunnel using the dissector, the pockets' proximal portions are shallow; and as we keep on dissecting, we move deeper into the cornea. This result contrasts with those reported by Lai *et al*, which show the distal portion of the segment's shallower location.¹³ Naftali *et al*⁸ demonstrated no significant difference between the proximal, central and distal portions of the segments when using Ferrara rings. When evaluating corneal thickness below the segment, this uneven depth was also apparent. However, this difference did not reach statistical significance.

Assessing segment depth could help predict complications associated with superficial implantation, that is, less than 70–80% which is rarely achieved. Ferrer *et al* reported that extrusion was related to shallow implantation and positioning the segment close to the incision site. Shallow implantation has been associated with epithelial breakdown owing to reduced diffusion of nutrients to the epithelium.¹⁷ When shallow implantation occurs, no surgical intervention is needed as long as the anterior corneal surface is intact. Regular follow up and educating the patient of the potential symptoms of extrusion are important. Even shallow implantation results in improved keratometric and visual outcomes, so usually no other surgical measures are needed to improve visual outcome. If extrusion occurs, removal of the segment can be performed safely through the main incision site, followed by topical antibiotics. Visual and refractive benefits are likely to remain following segment removal due to stromal scarring that occurs while the segment is *in situ*.

Although this was not the objective of this study, most patients enrolled demonstrated improved visual and refractive outcomes. To date (5 years on) none of the patients had complications associated with shallow implantation, raising the question of how shallow the segment has to be before being prone to complications. It may be that other factors such as eye rubbing have to be present to thin the overlying cornea or promote extrusion of an already superficial segment.

This study proves the importance of pocket dissection as a determinant of segment depth rather than merely incision depth. Therefore, adjustment of the way the

dissector is inserted could help achieve deeper dissection. However, this is not crucial to improve visual and refractive outcomes.

There are potential practical learning points for surgeons who perform, or who are considering performing ICRS implantation. Aiming for 80% incision depth does not guarantee 80% depth of implantation as the pocket-making stage is the main determinant; this applies to thick and thin corneas. This has also been demonstrated when implanting two segments that share same incision site. Most segments in this study had shallower implantation than planned. Thin corneas at the site of incision and along the tract can result in even shallower implantation, probably due to shallow pocketing. This is likely to be related to the surgeon consciously trying to avoid perforation in a thin cornea. Knowing the above results could encourage surgeons to adjust their technique to enable deeper dissection at the pocket-making stage.

Photorefractive keratectomy has been performed post-ICRS implantation to correct residual refractive error,¹⁸ which will result in an even 'shallower' segment. When concern about progression of keratoconus exists, the above can be combined with corneal collagen cross linking.

Limitations of this study include its small sample size. A larger sample size is needed to assess for anterior stromal compression, and provide definitive answers to some of the questions raised in this study. The use of different devices to measure corneal thickness is another potential source of confounding; ultrasonic (US) pachymetry was used intraoperatively while anterior segment OCT was used postoperatively. We are limited by what instruments are available for intraoperative use and while the patient is supine. US pachymetry is the easiest way to measure corneal thickness over the hypothetical channels. A potential preoperative measurement using anterior segment OCT could have been performed, but it would be difficult to correlate that to the exact hypothetical channels.

There is a potential bias in the preoperative pachymetry measurements as we attempted to measure the thinnest point along the tract. Other areas along the tract may have been thicker and therefore in those areas, the measured segment depth would have been different. We have attempted to tackle this issue by measuring corneal thickness at three different zones of the segment. Furthermore, inter- and intraobserver variability are recognized problems with caliper measurements on OCT imaging.

All procedures were performed by a single surgeon and although most published studies report shallow implantation of segments, the outcomes reported

in the present study are specific for one surgeon. It could have been of value to compare two surgeons' results. While we found incidentally that shallow implantation did not appear to affect visual or refractive outcomes, further work could involve investigating more specifically the correlation between these variables.

Conclusion

This study is unique because we were able to measure corneal thickness below the implanted segment, and hence precisely measure ICRS depth in relation to corneal thickness in that area. Although shallow implantations are present in our study as in other studies, novel methods of calculating segment depth have been implemented. On the basis of these results, it may be assumed with 95% confidence that an ICRS segment will be implanted ~130 μm shallower than its intended depth. Segment thickness does not influence implantation depth. The pocketing stage has the strongest influence on segment depth, more so than the initial incision depth, while the thinnest point and corneal thickness along the tract have a role in segment depth. We could not determine whether corneal lamellar compression is present and at what level in relation to the ICRS segment.

Summary

What was known before

- Intacs Depth: it is recommended for Intacs intra-corneal ring segments to be implanted at 70% depth of the cornea. Shallower implantation than intended does occur in most cases. Superficial implantation Superficial implantation increases the risk of implant exposure due to corneal thinning over the implant, implant extrusion, anterior stromal compression, compromised diffusion of nutrients to the corneal epithelium, and segment superficialization.
- Anterior segment OCT: Anterior segment OCT is accurate method to assess segments depth of implantation.

What this study adds

- Depth of implantation: we were able to establish the depth of implantation by measuring corneal thickness above and below the segment. this method has not been described before. Shallower depth of implantation is to be expected (58%).
- Pocket making stage: pocket making stage is the most crucial step in determining segments depth of implantation and not corneal thickness, incision depth or segments' thickness. two segments implanted in the same eye and share the same incision site and incision depth do not share similar implantation depths. This supports the aforementioned statement. Anterior stromal corneal compression is likely to occur when implanting Intacs segment.

Conflict of interest

The authors declare no conflict of interest.

Acknowledgements

We thank Professor Ayala Cohen and Dr Nadia Bordo for their contribution in the statistical analysis and Miriam Erez and Dr Andrew Turnbull for the language editing. This paper was presented at the annual congress of the European Society of Cataract and Refractive Surgeons, London, 2014.

References

- 1 Salgado-Borges JM, Costa-Ferreira C, Monteiro M, Guilherme-Monteiro J, Torquestti L, Ferrara P AR JR. Refractive, tomographic and biomechanical outcomes after implantation of Ferrara ICRS in keratoconus patients. *Int J Kerat Ect Cor Dis* 2012; **1**(1): 16–21.
- 2 Borbara R, Garzozzi H BA. Combined intacs SK and corneal collagen cross-linking for the treatment of keratoconus. *Int J Kerat Ect Cor Dis* 2012; **1**(2): 109–116.
- 3 Schanzlin DJ, Asbell PA, Burris TE, Durrie DS. The intrastromal corneal ring segments. Phase II results for the correction of myopia. *Ophthalmology* 1997; **104**(7): 1067.
- 4 Colin J. European clinical evaluation: use of Intacs for the treatment of keratoconus. *J Cataract Refract Surg* 2006; **32**(5): 747–755.
- 5 Alio J, Salem T, Artola A, Osman A. Intracorneal rings to correct corneal ectasia after laser in situ keratomileusis. *J Cataract Refract Surg* 2002; **28**(9): 1568.
- 6 Ertan A, Colin J. Intracorneal rings for keratoconus and keratectasia. *J Cataract Refract Surg* 2007; **33**(7): 1303–1314.
- 7 Kymionis GD, Siganos CS, Kounis G, Astyrakakis N, Kalyvianaki MI, Pallikaris IG. Management of post-LASIK corneal ectasia with Intacs inserts: one-year results. *Arch Ophthalmol* 2003; **121**(3): 322.
- 8 Naftali M, Jabaly-Habib H. Depth of intrastromal corneal ring segments by OCT. *Eur J Ophthalmol* 2013; **23**(2): 171–176.
- 9 Addition Technology Intacs corneal ring segments for the treatment of keratoconus. *International Surgeon Training Manual* 2007; 3.1-1–3.1-8.
- 10 Ertan A, Karacal H, Kamburoğlu G. Refractive and topographic results of transepithelial cross-linking treatment in eyes with intacs. *Cornea* 2009; **28**(7): 719–723.
- 11 Barbara R, Barbara A. *Textbook on Keratoconus - New Insights* 2012; 126–162.
- 12 Kanellopoulos AJ, Lawrence HP, Perry HD, Donnenfeld ED. Modified intracorneal ring segment implantations (INTACS) for the management of moderate to advanced keratoconus: efficacy and complications. *Cornea* 2006; **25**(1): 29–33.
- 13 Lai MM, Tang M, Andrade EMM, Li Y, Khurana RN, Song JC et al. Optical coherence tomography to assess intrastromal corneal ring segment depth in keratoconic eyes. *J Cataract Refract Surg* 2006; **32**(11): 1860–1865.
- 14 Kamburoglu G, Ertan A, Saraçbasi O. Measurement of depth of Intacs implanted via femtosecond laser using Pentacam. *J Refract Surg* 2009; **25**(4): 377–382.
- 15 Kouassi FX, Buestel C, Raman B, Melinte D, Touboul D, Gallois A CJ. Comparison of the depth predictability of intra

- corneal ring segment implantation by mechanical versus femtosecond laser-assisted techniques using optical coherence tomography (OCT Visante). *J Fr Ophthalmol* 2012; **35**(2): 94–99.
- 16 Gorgun E, Kucumen RB, Yenerel NM, Ciftci F. Assessment of intrastromal corneal ring segment position with anterior segment optical coherence tomography. *Ophthalmic Surg Lasers Imaging* 2012; **43**(3): 214–221.
- 17 Ferrer C, Alió JL, Montañés AU, Pérez-Santonja JJ, del Rio MA, de Toledo JA *et al*. Causes of intrastromal corneal ring segment explantation: clinicopathologic correlation analysis. *J Cataract Refract Surg* 2010; **36**(6): 970–977.
- 18 Tan BU, Purcell TL, Nalgirkar A, Ehrenhaus MP, Torres LF, Schanzlin DJ. Photorefractive keratectomy for the correction of residual refractive error with Intacs intrastromal corneal ring segments in place. *J Cataract Refract Surg* 2008; **34**(6): 909–915.