

# Pattern strabismus and torsion needs special surgical attention

R Kekunnaya<sup>1</sup>, T Mendonca<sup>1</sup> and V Sachdeva<sup>2</sup>

## Abstract

**Pattern strabismus is relatively common in strabismus practice. Although it is classically used to include A and V patterns, the term has been expanded to include additional vertically incomitant horizontal strabismus. This article reviews the clinical features, etiopathogenesis, and surgical options for the patients with pattern strabismus.**

*Eye* (2015) 29, 184–190; doi:10.1038/eye.2014.270; published online 21 November 2014

## Introduction

The term pattern strabismus denotes a significant difference in the size of horizontal deviations in defined positions of upgaze and downgaze. Classically, it includes A and V patterns, where by convention the difference between upgaze and downgaze must be > 10 prism diopters (PD) and 15 PD for A and V patterns, respectively. However, in recent years, this term has been expanded to include the other patterns with significant differences in the primary gaze and up/downgaze such as Y, X, arrow, and lambda patterns. A lesser degree of difference is accepted for A pattern, because convergence is more essential in downgaze. The exact mechanism of pattern strabismus is poorly understood even today. Cyclotorsion is a common feature of pattern strabismus and is also proposed to be one of the etiological factors for A and V patterns. Various surgical options for pattern strabismus include procedures on superior/inferior oblique muscles if there is associated oblique dysfunction or transposition procedures on the rectus muscles in its absence.

## Clinical features

Presence of pattern strabismus may result in an abnormal head posture (AHP) to maintain fusion. For example, a patient with V pattern exotropia may adopt a chin elevation (Table 1) to keep the eye in downgaze where the

deviation is minimal. However, AHP may be absent if there is a large deviation in primary position. Patients often complain of asthenopia and double vision, especially if the deviation is more in downgaze.

Clinical workup of patients with pattern strabismus includes: (1) measurement of deviation in nine gaze with accommodation being controlled; (2) measurement of deviation in 25° of upgaze (chin depression) and 35° of downgaze (chin elevation); (3) careful assessment of overelevation and overdepression in adduction; and (4) objective assessment of fundus torsion with indirect ophthalmoscopy or fundus photography.

## Uncommon subtypes of pattern strabismus

Y pattern exists when the change in deviation is minimal between primary and downgaze, and occurs only in upgaze. It is highly characteristic of bilateral inferior oblique overaction seen in congenital esotropia or exotropia. It can also be seen in Duane retraction syndrome (DRS) and Brown syndrome (Figures 1a and b).<sup>1</sup> This pattern of strabismus offers advantage for binocular vision, especially if the primary position deviation is minimal.

X pattern is seen in long-standing exotropia and type 3 DRS patients. In both situations, a tight lateral rectus muscle causes a leash effect and leads to increased divergence in both up and downgaze. Overaction of all four oblique muscles was shown to be the cause for X pattern by Brandner *et al*<sup>2</sup> using computer-based simulation model.

Arrow pattern occurs when maximum convergence occurs in between the primary and downgaze. This is seen in cases of bilateral superior oblique palsy.

Lambda pattern is the opposite of Y pattern wherein, maximum divergence occurs between primary and downgaze. Such a pattern is seen with bilateral superior oblique overaction<sup>3</sup> or inferior rectus underaction (over-recessed or slipped muscle).

<sup>1</sup>Jasti V Ramanamma  
 Children's Eye Care Center,  
 LV Prasad Eye Institute, KAR  
 campus, Hyderabad, India

<sup>2</sup>Nimmagadda Prasad  
 Children's Eye Care Center,  
 LV Prasad Eye Institute,  
 GMRV Campus,  
 Visakhapatnam, India

Correspondence:  
 R Kekunnaya, Head, Jasti V  
 Ramanamma Children's Eye  
 Care Center, Consultant,  
 Pediatric Ophthalmology,  
 Strabismus and  
 Neuroophthalmology,  
 LV Prasad Eye Institute,  
 Kallam Anji Reddy Campus,  
 LV Prasad Marg, Banjara  
 Hills, Hyderabad 500034,  
 India  
 Tel: +91 40 3061 2632;  
 Fax: +91 40 2354 8271.  
 E-mail: rameshak@lvpei.org  
 or drrk123@gmail.com

Received: 1 October 2014  
 Accepted: 6 October 2014  
 Published online: 21  
 November 2014

### Etiopathogenesis

In 1897, Duane described V pattern in a patient with bilateral superior oblique palsy.<sup>4</sup> Measurements of deviation in up and downgaze was popularised by Urrrets-Zavalía<sup>5</sup> in 1948. The worldwide accepted term of A and V patterns was coined by Urist.<sup>6</sup> The role of oblique muscle dysfunction was described by Knapp<sup>7</sup> in 1959. He also recommended surgeries on oblique muscles to treat A and V patterns.

About 12.5–50% of the patients with horizontal strabismus may have coexisting A and V patterns.<sup>3–5</sup> Spina bifida was associated with A pattern in 31% of the cases.<sup>8</sup>

Etiology of pattern strabismus has evolved through many theories. Though there are various schools of thought, there is no unanimity regarding the exact pathophysiology of pattern strabismus. Proposed etiological mechanisms can be mechanical (peripheral) and neural (central).<sup>9</sup>

### Mechanical factors

According to the theory of horizontal muscle overaction,<sup>6</sup> an imbalance between the actions of the rectus muscles leads to pattern strabismus, for example the medial rectus muscles overact in downgaze and lateral rectus muscles overact in upgaze giving rise to a V esotropia. Conversely, an A pattern arises when the medial rectus muscle underacts in downgaze and lateral rectus muscle underacts in upgaze. However, this theory has been disproved by electromyographic studies that showed that electrical activity of horizontal rectus is similar in pattern strabismus and other incomitant strabismus.

**Table 1** Showing AHP in A and V pattern

Chin up posture	A esotropia, V exotropia
Chin down posture	A exotropia, V esotropia

An imbalance of the cyclovertical muscles was also proposed to be one of the mechanisms for pattern strabismus. It was thought that, while an A pattern occurs when inferior rectus underacts and yoke superior oblique overacts, a V pattern is noted when superior rectus underacts and yoke inferior oblique overacts.<sup>10</sup> This theory has also been abandoned due to lack of adequate evidence.

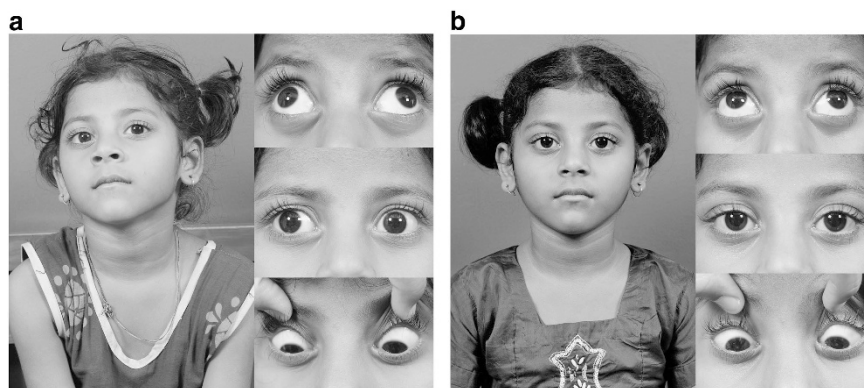
### Oblique muscle overaction or underaction

This theory is most popular and widely accepted and was put forward by Knapp<sup>7</sup> in 1959. It is based on the fact that abduction is the tertiary action of oblique muscles. Thus a primary or secondary overaction of the inferior oblique muscle leads to increased abduction, especially when the eye is in elevation. This leads to a V pattern. Vice versa is seen when the superior oblique muscles are overacting. In clinical practice, usually this type of oblique muscle dysfunction is observed to be associated with pattern strabismus.

Classification of eye movement abnormalities and strabismus (CEMAS)—a national Eye Institute sponsored workshop referred superior oblique overaction as overdepression in adduction and inferior oblique overaction as overelevation in adduction. Therefore, 'overelevation/overdepression in adduction' is a generalized term where oblique dysfunction is one of the causes for the same.

### Anomalies of orbital structures

Anatomical factors like craniofacial anomalies, hydrocephalus, and heterotopy of muscle pulleys demonstrate pattern strabismus owing to abnormal vector force. Patients with mongoloid slant are seen to



**Figure 1** Preoperative (a) and postoperative (b) photographs of a patient who had Y pattern due to Brown syndrome, who underwent superior oblique tenotomy.

have A esotropia and V exotropia, whereas patients with antimongoloid slant have V esotropia and A exotropia.<sup>11</sup>

The 'theory of sagittalisation of oblique muscles' as a cause of pattern strabismus was put forward by Gobin<sup>12</sup> According to this theory, reduction in angle between visual axis and muscle axis results in cyclophoria that is compensated by contraction of respective cyclovertical muscles, thereby resulting in overelevation or overdepression in adduction.

Pseudoparalysis of superior oblique and V pattern may be seen in plagioccephaly owing to shallow orbit on affected side.<sup>13</sup> Similarly pseudo A pattern may be seen in patients with hydrocephalus.<sup>8</sup>

#### *Abnormalities of extraocular muscle (EOM) pulleys*

EOM pulleys are condensations of posterior tenon's capsule composed of collagen, elastin, and smooth muscles, which act as the functional origin of EOMs. Muscle pulleys are thought to minimize sideslip relative to orbit during globe rotations. Clark *et al*<sup>14</sup> have studied EOM pulley positions using high-resolution MRI. They have shown that small mislocations (<2 mm) of rectus muscle pulleys can result in incomitance in vertical gaze. They found inferior displacement of the lateral rectus pulley is associated with apparent overelevation in adduction, whereas superior displacement of the same causing apparent overdepression in adduction. They concluded that pulley heterotopy can itself cause incomitance without dysfunctional oblique muscles, hence resulting in A or V pattern strabismus.

#### **Neural mechanisms**

Several neural mechanisms have been proposed to explain pattern strabismus. Miller and Guyton<sup>15</sup> studied pre- and postoperative courses of patients who were overcorrected after surgery for intermittent exotropia. About 43% patients with consecutive esotropia, *vs* only 5% controls, developed A or V pattern strabismus at 28 months after surgery. The authors say that loss of fusional control leads to torsional drift, which is similar to exotropic drift seen in sensory strabismus. Torsional drift may cause altered vector forces of vertical rectus muscles, which may lead to pattern strabismus.

Abnormal supranuclear circuits have been postulated as one of the neural causes for pattern strabismus. In an animal study, Das and Mustari<sup>16</sup> have studied burst neuron activity from oculomotor nucleus in three juvenile rhesus monkeys with A pattern exotropia as they performed horizontal or vertical smooth pursuit during monocular viewing. The authors concluded that in animal models with sensory-induced strabismus, innervation to EOMs from motor nuclei produce the inappropriate cross-axis eye movements, resulting in

pattern strabismus and dissociated vertical deviation (DVD).

#### *Could A pattern strabismus be a special form of skew deviation?*

Donahue and Itharat<sup>17</sup> reported 13 cases of A pattern strabismus with neurologic abnormalities like hydrocephalus, spina bifida, perinatal stroke, and global developmental delay. In all, 11 out of 13 patients had no difference in vertical misalignment during right and left head tilts. Hence, they proposed that in A pattern strabismus, damage to utricular pathways resulted in decrease in anterior semicircular canal input and increase in posterior semicircular canal input that causes increased bilateral depressor tonus of superior oblique and inferior rectus muscles. However, the superior oblique muscle is an incyclotorter and the inferior rectus muscle is an excyclotorter, which should nullify the torsion effects of each other when there is an increase in bilateral depressor tonus.

#### **Ocular torsion as a cause of pattern strabismus**

Association of excyclotorsion with V pattern and incyclotorsion with A pattern was first reported by Piper<sup>18</sup> in 1963. Weiss<sup>19</sup> used campimetric measurements of position of blind spot to confirm ocular torsion. He postulated that apparent rotation of insertion of rectus muscles due to excyclotorsion of the globe is the etiological factor for pattern strabismus. For example, if a patient has a V pattern with inferior oblique muscle overaction, each eye will be extorted. This will rotate the insertions of the rectus muscles counterclockwise in the right eye and clockwise in the left eye. An abducting force will be created from superior rectus in upgaze and adducting force from inferior oblique in downgaze, which will result in a V pattern. In addition, the medial rectus muscle acts like a partial elevator and lateral rectus muscle acts like a partial depressor in abduction, which will exacerbate the V pattern. This complex action of all EOMs was also supported by an investigation conducted by Kushner<sup>20</sup>

Guyton<sup>21</sup> proposed that loss of fusion predisposes the oculomotor system to cyclodeviations of the eyes, which in turn causes A and V patterns according to the mechanism proposed by Weiss. Ocular torsion has been attributed as a major etiological factor for pattern strabismus by the author. He also introduced the term sensory torsion.<sup>22</sup> Similarly, Miller and Guyton<sup>15</sup> showed occurrence of sensory torsion in patients with subnormal binocularity resulting in alteration of vector forces of horizontal rectus muscles, which in turn results in pattern strabismus.

Fundus torsion is also described as a marker for subsequent development of inferior oblique overaction in cases of infantile esotropia by Eustis and Nussdorf.<sup>23</sup> The authors say that inferior oblique overaction developed in every child who showed fundus extorsion and it is suggestive of a 100% positive predictive value for the same.

Good correlations were found between fundus intorsion, superior oblique muscle overaction, and A patterns; and between fundus extorsion, inferior oblique muscle overaction, and V patterns in a study conducted by Deng *et al.*<sup>24</sup> The authors also say that correlations increased in the absence of stereopsis.

Early onset strabismus may lead to sensorial adaptations such as suppression, cyclofusion, or anomalous retinal correspondence that may not reveal any torsion on subjective methods of assessment. Correlation between subjective and objective torsion was studied by Kushner and Hariharan<sup>25</sup> and the authors claim that better correlation exists in patients with late onset strabismus or with good stereopsis. They also observed that patients with early onset strabismus with absent binocularity may not experience subjective torsion.<sup>25</sup>

An experimental study published by Kushner<sup>26</sup> evaluated whether ocular torsion is a primary factor for the development of pattern strabismus, or is just a contributing factor. He studied trajectory of eye movements in five patients with oblique muscle overaction and found that for all five patients elevation or depression of the eye was curvilinear as the eye was moved from abduction to adduction owing to primary oblique muscle overaction. The second investigation was on two patients with unilateral superior oblique palsy who underwent Harada-Ito procedure for torsional diplopia, which was abolished after surgery. However, patients persisted to have significant inferior oblique overaction. The third investigation quantified increase in fundus torsion after horizontal muscle transposition for pattern strabismus in five patients whereas the pattern collapsed after surgery. The mean increase in fundus torsion was 6.4° with a range of 5–7°. Hence the authors concluded that ocular torsion may not be the primary etiological factor for pattern strabismus.

Sharma *et al.*<sup>27</sup> studied pre- and postoperative torsion subjectively by synoptophore and objectively by fundus photography in 21 patients who underwent monocular surgery with horizontal rectus transposition for pattern strabismus. They also demonstrated worsening of torsion as well as occurrence of new onset torsion after horizontal muscle surgery.

It has been argued that ocular torsion may lead to heterotopy of orbital pulleys and displacement of pulleys may result in altered vector forces in the presence of cyclotorsion.<sup>22</sup> Upward displacement of medial rectus pulley alone was found in patients with superior oblique

palsy and extorsion in a study conducted by Clark *et al.*<sup>28</sup> However, there was no displacement of other EOM pulleys that suggests torsion may not be the primary cause of pulley heterotopy.<sup>28</sup>

### Surgical implications

It is important to correct pattern deviations along with correction of horizontal deviations if it is clinically significant.

Apart from measurement of deviation in all diagnostic positions of gazes, workup of patient should also include measurement of vertical deviation (hyper/hypotropia in adduction) and careful search for the muscle insertion during slit lamp examination. Accomodative esotropia and increased AC/A ratio may simulate pseudo V pattern. Imaging of the orbit may be considered in selected cases where pattern cannot be attributed to any of the ocular motility findings and also in unusual cases. The most popular surgical modalities to treat pattern strabismus include weakening of oblique muscles and vertical transpositions of horizontal muscles. Other surgical modalities described in literature are insertion slanting procedures and horizontal transposition of vertical rectus muscles. Intraoperatively, one may inspect the course of horizontal rectus muscle course, which may provide additional clues for the surgical management.

### Oblique muscle surgery

When vertical deviation is greatest in adduction (overelevation in adduction), primary oblique muscle overaction could be the commonest cause. Primary inferior oblique overaction is usually associated with V pattern and extorsion. Similarly, primary superior oblique muscle overaction is associated with A pattern and intorsion. The amount of anatomic torsion usually correlates with the amount of oblique muscle overaction. Ocular torsion is said to be a more reliable indicator of oblique muscle overaction than versions.<sup>29</sup>

Oblique muscle weakening is appropriate in cases of pattern deviations with oblique muscle overaction as it decreases torsion, which may contribute to the pattern.<sup>29</sup> Primary position deviation does not get affected by surgery on oblique muscle. Hence, horizontal muscle surgery should be planned according to horizontal deviation in primary position. Thus, V esotropia or exotropia with overelevation in adduction requires inferior oblique weakening with horizontal muscle surgery. Similarly, horizontal muscle surgery with posterior tenotomy of superior oblique can be done for A pattern with overdepression in abduction. The decision of posterior tenotomy can be titrated based on forced traction test for superior oblique.



The various weakening procedures available for inferior oblique are recession, myectomy and anterior transposition. Anterior transposition is preferred in the presence of a DVD or in very severe overaction. The choice between myectomy and recession varies between surgeons. Most of these procedures reduce the exotropia and increase esotropia in upgaze to an extent of 15–25 PD.

Many surgeons prefer posterior tenotomy of superior oblique muscle as it preserves the anterior fibers that are responsible for intorsion and thereby prevents unwanted postoperative cyclotorsion, especially in patients with good fusion.


A study by Yu *et al*<sup>30</sup> compared fundus extorsion before and after inferior oblique myectomy using fundus photography combined with horizontal muscle surgery for horizontal deviations. They found significant reduction in excyclotorsion after inferior oblique myectomy. Similarly, Wu *et al*<sup>31</sup> showed significant reduction in intorsion after weakening of superior oblique.

**Vertical offset of horizontal rectus muscles**

In cases where the oblique muscles are not overacting, transposition of horizontal rectus muscles is another effective surgery to collapse pattern strabismus. When a

horizontal muscle is transposed, its primary action is decreased while it gains a new action in the direction of transposition. Thus when a medial rectus muscle is shifted downwards it gains a depressor action, which is maximum in the downgaze and less in the upgaze (Figures 2a and b). The anticipated decrease in the horizontal action of the muscle determines the direction of the transposition of the muscle. Thus, the insertion of a muscle should be moved in the direction in which it is desirable to most decrease its horizontal action and in the direction opposite that in which one wishes its horizontal action to be more effective. Hence in the case of a V esotropia, an inferior transposition of the medial rectus corrects increase in the horizontal deviation in downgaze. Table 2 shows various types of pattern strabismus and possible combination of surgeries for the treatment and Figure 3 shows direction of transposition of horizontal rectus muscles.

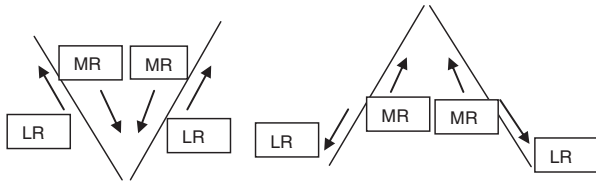
Kushner,<sup>32</sup> in a retrospective case series, illustrated occurrence of ocular torsion after transposition of horizontal muscles for pattern strabismus in three patients and development of pattern strabismus after vertical rectus transposition for ocular torsion in five patients. Hence, he states that horizontal muscle transposition surgery can have adverse effect on torsion



**Figure 2** Preoperative (a) and postoperative (b) photographs of a patient who had A esotropia, who underwent bilateral medial rectus recession with superior transposition.

**Table 2** Shows various types of pattern strabismus and possible surgeries

Pattern	Surgery
V esotropia/exotropia with inferior oblique overaction	Horizontal muscle surgery with inferior oblique weakening
A esotropia/exotropia with superior oblique overaction	Horizontal muscle surgery with Superior oblique weakening
V esotropia without oblique muscle overaction	Bimedial recession with downshift
V exotropia without oblique muscle overaction	Bilateral lateral rectus recession with upshift
A esotropia without oblique muscle overaction	Bimedial recession with upshift
A exotropia without oblique muscle overaction	Bilateral lateral rectus recession with downshift



**Figure 3** Direction of transposition of horizontal rectus muscles.

if it is done for pattern and vice versa. As five out of eight patients had Grave's orbitopathy, the author hypothesizes that torsion or alphabet pattern could have been more owing to tight muscles. Also, patients who underwent surgery for torsion had bilateral surgery, which could be having an added effect on the development of torsion.

A monocular recession/resection procedure with vertical transposition is also commonly practiced for pattern strabismus. Worsening of existing torsion or occurrence of new torsional changes has been studied by Sharma *et al.*<sup>27</sup> They compared pre- and postoperative torsional changes after recession/resection procedure. They observed worsening of intorsion in five out of eight cases and occurrence of new onset intorsion in three patients. The pattern collapsed effectively in all cases.

Although horizontal muscle transposition surgery has an adverse effect on torsion, it has been observed for the past few decades that successful outcomes can be achieved in terms of reduction in pattern. We have satisfactory results from this surgery and no subjective complaints from patients.

Insertion slanting procedures have been advocated by many authors where selective slanting of superior and inferior poles of recessed muscles cause effect of supra- or infrapalcement. Many of the authors have stated that insertion slanting procedures do not have significant adverse effect on torsion.<sup>33,34</sup>

Horizontal transposition of vertical rectus muscles have also been implicated in treatment of pattern strabismus based on the principle that vector forces are produced in the direction in which the muscle is moved. This method also theoretically should worsen existing torsion. As additional muscles are required to be operated, this technique has not gained much popularity.

## Conclusions

In conclusion, pattern strabismus is a relatively common condition. The exact pathophysiology behind occurrence of pattern strabismus is still an enigma. In most cases where an associated oblique overaction can be clinically determined, it may be believed to be causative. Careful attention should be paid to associated craniofacial abnormality or orbital asymmetry, which may be contributory in specific cases. Table 2 summarizes the possible surgical options. Although many options are described, surgical management depends on presence or absence of oblique overaction. However, in the author's experience, weakening of oblique muscles usually gives satisfactory results in cases of oblique muscle overaction with pattern strabismus.

## Conflict of interest

The authors declare no conflict of interest.

## References

- Kushner BJ. Pseudo inferior oblique overaction associated with Y and V patterns. *Ophthalmology* 1991; **98**: 1500–1505.
- Brandner M, Buchberger M, Kaltofen T *et al*. Biomechanical analysis of x-pattern exotropia. *Am J Ophthalmol* 2011; **152**: 141–146.
- Rubin SE, Nelson LB, Harley RD. A complication in weakening the superior oblique muscle in A-pattern exotropia. *Ophthalmic Surg* 1984; **15**: 134–135.
- Duane A. Isolated paralysis of extraocular muscles. *Arch Ophthalmol* 1897; **26**: 317–334.
- Urrets-zavalía A. Abduction en la elevación. *Arch Ophthalmol* 1948; **23**: 124–134.
- Urist MJ. The etiology of the so-called 'A' & 'V' syndromes. *Am J Ophthalmol* 1958; **46**: 835–844.
- Knapp P. Vertically incomitant horizontal strabismus: the so-called 'A' & 'V' syndromes. *Trans Am Ophthalmol Soc* 1959; **57**: 666–699.
- France TD. Strabismus in hydrocephalus. *Am Orthopt J*. 1975; **25**: 101–105.
- Ghasia FF, Shaikh AG. Pattern strabismus: where does the brain's role end and the muscle's begin? *J Ophthalmol* 2013; **2013**: 301256
- Brown HW. Vertical deviations. In symposium, strabismus. *Trans Am Acad Ophthalmol Otolaryngol* 1953; **57**: 157–162.

- 11 Urrets-Zavalía A, Solares-Zamora J, Olmos HR. Anthropological studies on the nature of cyclovertical squint. *Br J Ophthalmol* 1961; **45**: 578–596.
- 12 Gobin MH. Sagittalization of the oblique muscles as a possible cause for the 'A', 'V', and 'X' phenomena. *Br J Ophthalmol* 1968; **52**: 13–18.
- 13 Bagolini B, Campos EC, Chiesi C. Plagiocephaly causing superior oblique deficiency and ocular torticollis. A new clinical entity. *Arch Ophthalmol* 1982; **100**: 1093–1096.
- 14 Clark RA, Miller JM, Rosenbaum AL, Demer JL. Heterotopic muscle pulleys or oblique muscle dysfunction? *J AAPOS* 1998; **2**: 17–25.
- 15 Miller MM, Guyton DL. Loss of fusion and the development of A or V patterns. *J Pediatr Ophthalmol Strabismus* 1994; **31**: 220–224.
- 16 Das VE, Mustari MJ. Correlation of cross-axis eye movements and motor neuron activity in non-human primates with "A" pattern strabismus. *Invest Ophthalmol Vis Sci* 2007; **48**: 665–674.
- 17 Donahue SP, Itharat P. A-pattern strabismus with overdepression in adduction: A special type of bilateral skew deviation? *J AAPOS* 2010; **14**: 42–46.
- 18 Piper HF. Über die Bedeutung des V- und A-Phänomens beim Schielen. *Sitzungsbericht 107, Versammlung Rheinland Westfalen Augenärzte* 1963; p 63.
- 19 Weiss JB. Ectopies et pseudoectopies maculaires par rotation. *Bull Mem Soc Fr Ophthalmol* 1966; **79**: 329–349.
- 20 Kushner BJ. The role of ocular torsion on the etiology of A and V patterns. *J Pediatr Ophthalmol Strabismus* 1985; **22**: 171–179.
- 21 Guyton DL. Ocular torsion: Sensorimotor principles. *Graefes Arch Clin Exp Ophthalmol* 1988; **266**: 241–245.
- 22 Guyton DL, Weingarten PE. Sensory torsion as the cause of primary oblique muscle overaction/underaction and A and V-pattern strabismus. *Binocular Vision Eye Muscle Surg Q* 1992; **9**: 209–236.
- 23 Eustis HS, Nussdorf JD. Inferior oblique overaction in infantile esotropia: fundus extorsion as a predictive sign. *J Pediatr Ophthalmol Strabismus* 1996; **33**: 85–88.
- 24 Deng H, Irsch K, Gutmark R, Phamonvaechavan P, Foo FY, Anwar DS *et al*. Fusion can mask the relationships between fundus torsion, oblique muscle overaction/underaction, and A- and V-pattern strabismus. *J AAPOS* 2013; **17**: 177–183.
- 25 Kushner BJ, Hariharan L. Observations about objective and subjective ocular torsion. *Ophthalmology* 2009; **116**: 2001–2010.
- 26 Kushner BJ. Effect of ocular torsion on A and V patterns and apparent oblique muscle overaction. *Arch Ophthalmol* 2010; **128**: 712–718.
- 27 Sharma P, Halder M, Prakash P. Torsional changes in surgery for A-V phenomena. *Indian J Ophthalmol* 1997; **45**: 31–35.
- 28 Clark RA, Miller JM, Demer JL. Displacement of the medial rectus pulley in superior oblique palsy. *Invest Ophthalmol Vis Sci* 1998; **39**: 207–212.
- 29 Phillips PH, Hunter DG. Evaluation of ocular torsion and principles of management. In: Rosenbaum AL, Santiago AP (eds) *Clinical Strabismus Management, Principles and Surgical Techniques*. WB Saunders: Philadelphia, 1999; p 52–72.
- 30 Yu X, Mai G, Yu H, Deng D, Lin X, Chen J *et al*. Study on ocular torsion of V patterns strabismus. *Yan Ke Xue Bao* 2003; **19**: 160–164.
- 31 Wu HP, Mai GH, Deng DM, Lin XM, Yu XP, Chen JC. The effect of weakening the overaction superior oblique muscles on the status of ocular torsion. *Zhonghua Yan Ke Za Zhi* 2006; **42**: 883–887.
- 32 Kushner BJ. Torsion and pattern strabismus: potential conflicts in treatment. *JAMA Ophthalmol* 2013; **131**: 190–193.
- 33 Mostafa AM, Kassem RR. A comparative study of medial rectus slanting recession versus recession with downward transposition for correction of V-pattern esotropia. *J AAPOS* 2010; **14**: 127–131.
- 34 Biedner B, Rothkoff L. Treatment for 'A' or 'V' pattern esotropia by slanting muscle insertion. *Br J Ophthalmol* 1995; **79**: 807–808.