

25th RCOphth Congress, President's Session paper: 25 years of progress in medical retina

JM Gibson

Abstract

The quarter century since the foundation of the Royal College of Ophthalmologists has coincided with immense change in the subspecialty of medical retina, which has moved from being the province of a few dedicated enthusiasts to being an integral, core part of ophthalmology in every eye department. In age-related macular degeneration, there has been a move away from targeted, destructive laser therapy, dependent on fluorescein angiography to intravitreal injection therapy of anti-growth factor agents, largely guided by optical coherence tomography. As a result of these changes, ophthalmologists have witnessed a marked improvement in visual outcomes for their patients with wet age-related macular degeneration (AMD), while at the same time developing and enacting entirely novel ways of delivering care. In the field of diabetic retinopathy, this period also saw advances in laser technology and a move away from highly destructive laser photocoagulation treatment to gentler retinal laser treatments. The introduction of intravitreal therapies, both steroids and anti-growth factor agents, has further advanced the treatment of diabetic macular oedema. This era has also seen in the United Kingdom the introduction of a coordinated national diabetic retinopathy screening programme, which offers an increasing hope that the burden of blindness from diabetic eye disease can be lessened. Exciting future advances in retinal imaging, genetics, and pharmacology will allow us to further improve outcomes for our patients and for ophthalmologists specialising in medical retina, the future looks very exciting but increasingly busy.

Eye (2014) 28, 1041–1052; doi:10.1038/eye.2014.141; published online 4 July 2014

Introduction

It could reasonably be argued that in the field of ophthalmology, the subspecialty of medical

retina has undergone the most extensive developments in practice over the past quarter of a century. It is a period that has seen major progress in ophthalmic imaging of the ocular fundus, and huge progress in the management of the major retinal conditions, namely age-related macular degeneration (AMD), diabetic retinopathy, and retino-vascular disorders. This period has encompassed a move away from the destructive, targeted laser treatments of retinal lesions with inevitable unwanted collateral retinal damage, to pharmacological interventions with improved visual outcomes. I was appointed as a NHS consultant ophthalmologist in Birmingham in 1986, and therefore I have experienced at first hand many of the changes that have occurred in medical retina within the last 25 years.

In 1988, the ophthalmic world in the United Kingdom was very different from now, and Birmingham was probably fairly typical of large city services, with a 'hub and spoke' configuration of its services. In 1988, there were only 10 ophthalmic consultants providing services to the greater Birmingham Area, 9 of whom had sessions at the 'hub', the Birmingham and Midland Eye Hospital, which provided regional and subregional eye services, and subspecialty services. The same consultants also provided general ophthalmology services at the district general 'spoke' hospitals within Birmingham. In contrast in 2013, there are over 50 consultants providing ophthalmic services to the same geographic area, with well-developed ophthalmic units in all the major hospitals within the Birmingham conurbation.

In 1988, subspecialist training in the United Kingdom was in its infancy, and apart from those consultants working in larger centres, the vast majority of consultants were generalists, providing care for a wide range of disorders.

School of Life and Health Sciences, Aston University, Birmingham, UK

Correspondence: JM Gibson, School of Life and Health Science, Aston University, Birmingham, West Midlands B4 7ET, UK
Tel: +44 (0)121 204 3848; Fax: +44 (0)121 204 3696. E-mail: j.m.gibson@aston.ac.uk

Received: 23 September 2013
Accepted: 3 October 2013
Published online: 4 July 2014

At this time, medical retina was an embryonic subspecialty and for many patients laser photocoagulation and fundus fluorescein angiography (FFA) services were not provided at the local district general hospital, necessitating referral and travel to a larger centre with inevitable delays.

In the context of these major changes in the provision of ophthalmic services in the United Kingdom, I will now consider the major advances that have occurred in the management of medical retina disorders.

Age-related macular degeneration

For patients with wet AMD in 1988, the outlook was fairly bleak. It had been known for some years that choroidal neovascular (CNV) membranes were aggressive and grew quickly under the fovea, and that there was a high risk of fellow-eye involvement.¹ The Macular Photocoagulation Study had shown that 73% of untreated extrafoveal CNV became subfoveal within 1 year² and it had also been shown that CNV edge growth rates were 5–10 μm per day.³ It had also been shown in randomised clinical trials by the Macular Photocoagulation Study Group⁴ and by the Moorfields Macular Study Group⁵ that laser photocoagulation with argon blue-green laser could reduce vision loss by >60% in patients with CNV >200 μm from the centre of the foveal avascular zone.

Laser photocoagulation for wet AMD

The technique of laser treatment of CNV required high energy laser with 0.1 to 0.2-s duration, to create an intense white laser burn that covered and overlapped the CNV as visualised on the FFA. For well defined, extrafoveal lesions, the treatment was relatively straightforward, but even in these cases failure did occur when there was recurrence and regrowth of the lesion, which occurred in close to half of cases followed up for 3 years.⁶ An important part of the treatment was to overlap the CNV edge by at least 100 μm , which in juxtafoveal cases on the foveal side was not for the faint-hearted ophthalmologist!

In most cases this treatment required a retro-bulbar local anaesthesia injection, to minimise pain for the patient but more importantly to reduce inadvertent ocular movement during laser, and it required immediate post-laser FFA to check that the entire CNV was covered. It can be seen that this treatment was probably best left to specialist macular services of which there were at this time very few.

The choice of laser wavelength was probably not as important as the proper placement and correct intensity of the burns, but it soon became apparent that argon

blue-green was best avoided for juxtafoveal CNV due to inner retinal damage caused by xanthophyll pigment absorption. Argon green therefore became the commonest option although at the Birmingham and Midland Eye Hospital we also used multiple wavelength lasers and later on the infrared diode laser, all of which had been shown to be effective.^{7,8}

Generally patients with retinal pigment epithelial detachments (PEDs) were not treated with laser after the Moorfields Macular Study Group had failed to show any benefit of treatment for avascular PED, although the situation for vascularised PED was less clear.⁹ Retinal pigment epithelial tears, which had been first described at Moorfields Eye Hospital in 1981,¹⁰ became a recognisable complication of this type of laser.

A longer-term problem with laser treatment for CNV is the longer-term enlargement and creepage of the scar toward the fovea over time. This is demonstrated in Figure 1, which shows the effect of successful photocoagulation in a young patient with idiopathic CNV and subsequent enlargement of the scar over a 10-year period.

Treatment of subfoveal CNV

The difficult scenario of treating patients with wet AMD where some part of the lesion was under the fovea remained a problem. The Macular Photocoagulation Study Group carried out a subfoveal laser therapy trial, which treated patients at an early stage. The results showed that over a 2-year period the treated group did marginally better than the untreated, in terms of lines of visual acuity and contrast sensitivity, but the trade off was a large decrease in the vision immediately after treatment. As a result, this treatment did not prove popular with patients or ophthalmologists.¹¹

Scatter laser therapy to the lesion in subfoveal CNV was not found to be beneficial,¹² and systemic interferon therapy, which had shown benefit in a very small initial case series,¹³ was shown to be ineffective when tested in proper clinical trials.^{14,15} Ionising radiation, which can inactivate rapidly proliferating cells, such as occurs in CNV, was used in several trials in subfoveal CNV. Overall, the results of these trials were disappointing and it was not used in widespread clinical practice at that time,^{16,17} although subsequently it is now being re-evaluated in the light of new developments.

The introduction of indocyanine green (ICG) video angiography led to much interest in the possibility of identifying and treating feeder vessels to CNV, thus avoiding potentially damaging collateral laser damage to the fovea. It also led to renewed interest in the possibility of treating poorly defined, occult CNV with laser photocoagulation, which had recognisable

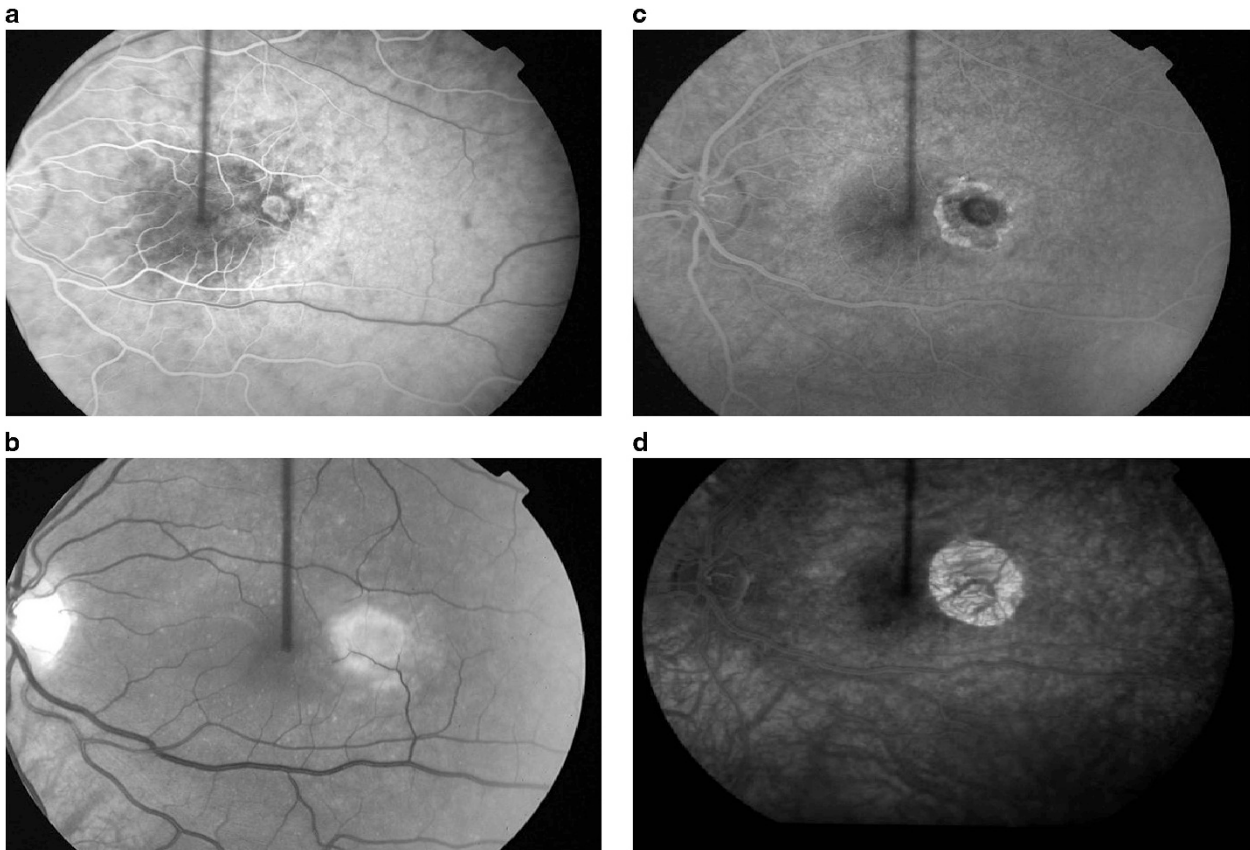


Figure 1 Small extrafoveal CNV treated with argon green laser photocoagulation in 1989. (a) FFA pre-laser. (b) Red-free photograph immediately post-laser showing overlapping, confluent burns. (c) Fluorescein angiography 1-week post-laser treatment. (d) Late phase fluorescein angiography in 1999 showing laser creep and scar extension toward fovea.

hot spots on ICG.^{18,19} Ultimately, however, ICG probably did not fully live up to its initial promise as an adjunct for laser photocoagulation, although it did allow some cases to be treated with ICG dye enhanced laser, as a form of early photodynamic therapy (PDT).²⁰ ICG did, however, transform our understanding of the choroid and CNV and as we shall see, has today become a key investigation for several retinal and choroidal conditions.

Photodynamic laser therapy with verteporfin

PDT was a major breakthrough because it allowed for the first time subfoveal CNV to be successfully treated, and was shown in large-scale randomised clinical trials to reduce the risk of vision loss in selected cases of AMD with CNV.²¹ PDT is a two-stage procedure performed as an outpatient basis: the first step is a 10-min intravenous infusion of a light-sensitising drug, verteporfin, a benzoporphyrin derivative, which is lipophilic and taken up by plasma membrane cells, within the CNV. The second stage is the activation of the verteporfin dye by irradiation of the CNV with a non-thermal diode laser of

wavelength 689 nm, which delivers a dose of 50 J/cm^2 over a period of 83 s.²²

The treatment of AMD with PDT (TAP) Trial, was a large randomised controlled trial that investigated the effectiveness of PDT compared with placebo in patients with subfoveal CNV. The key eligibility criteria was best-corrected visual acuity of 20/40–20/200, subfoveal CNV secondary to AMD with evidence of classic CNV and a greatest linear dimension of the entire lesion of $5400 \mu\text{m}$ or less. Categorisation of the CNV lesion on FFA was of major importance, the identification of the proportion of the lesion that was ‘classic’ and ‘occult’ relied on meticulous analysis of the FFA images. The treatment spot size was determined by measuring the entire lesion on FFA and adding $1000 \mu\text{m}$, to achieve a $500 \mu\text{m}$ margin of overlap at the margin of the lesion to ensure that the entire lesion was covered.

Patient selection criteria include the following: (1) in cases due to AMD, lesion composition of (a) predominantly classic CNV, (b) occult with no classic CNV with presumed recent disease progression, or (c) relatively small minimally classic lesions.

In the TAP Study, the benefits of PDT were most clearly seen in 'predominant classic' lesions with no occult component, where 23% of verteporfin-treated eyes had at least moderate vision loss at 12 months, compared with 73% of placebo-treated eyes.²¹ This study and others showed that PDT with verteporfin in AMD cases with subfoveal CNV showed that therapy was safe²³ and reduced the risk of moderate and severe vision loss in patients with subfoveal lesions that are predominantly classic CNV secondary to AMD.²⁴ In time, this and other studies enabled guidelines regarding PDT in AMD for medical retina specialists to be created.^{25,26}

Photodynamic combination therapy and use in other conditions

PDT with verteporfin was shown to be effective in younger patients with idiopathic CNV²⁷ and the VIP Study showed that PDT was better than placebo in cases of CNV secondary to pathological myopia.²⁸ However, studies with ICG angiography had shown in some AMD cases that collateral damage of the healthy choroidal vasculature had occurred, with repeated PDT treatments and this raised concerns about the side effects of reducing normal choroidal perfusion, and the influence of this on the visual outcome of the treatment.²⁹ These observations lead to an acceptance that PDT was not entirely without risk and that where possible reduced light doses should be used.³⁰

PDT combined with intravitreal triamcinolone for AMD was shown to be effective and initial reports were encouraging, with better visual outcomes and less laser treatments being required.^{31,32} Attention also turned to combining full or reduced fluence verteporfin, with ranibizumab or bevacizumab, powerful anti-angiogenic agents. Although combination therapy appears to be safe and effective, comparative studies have not shown any improvement or reduction in vision when compared with anti-angiogenic monotherapy with ranibizumab or bevacizumab alone.^{33–35} The vaso-occlusive effects of PDT may excite some deleterious inflammatory effects in the surrounding tissues and therefore some ophthalmologists have recommended so-called triple therapy—namely intravitreal anti-vascular growth factor (VEGF) agent, PDT with verteporfin and intravitreal steroid. This technique has been shown to be effective in certain cases of CNV but is not currently in widespread use.³⁶

PDT has also been used and shown to be effective in the treatment of choroidal haemangioma,³⁷ chronic central serous retinopathy,³⁸ and in polypoidal vasculopathy, where it has been shown to be superior to ranibizumab.³⁹

Anti-angiogenic agents in AMD

Anti-angiogenic therapy has transformed the treatment in wet AMD, with improved visual outcomes over PDT monotherapy, and ranibizumab and bevacizumab are currently the gold-standard care. ANCHOR and MARINA, large, multicentre, randomised clinical trials showed that a fixed monthly dosing regime of ranibizumab gave extremely good visual outcomes in all subtypes of wet AMD.^{40,41} However, monthly injections place a huge burden on both patients and health providers and this lead to other treatment regimes being investigated.

The PIER study showed that close monitoring and retreatment are still necessary to maintain the optimal visual results.⁴² The PrONTO Study, using an OCT-guided variable-dosing regimen with intravitreal ranibizumab resulted in VA outcomes comparable to the outcomes from the phase III clinical studies, but fewer intravitreal injections were required.^{43,44} Despite being a small study of 40 patients, the protocol of this study has formed the basis for guidance TA 155 issued by the National Institute for Health and Care Excellence (NICE) in 2008 for the treatment of wet AMD in the NHS.⁴⁵ In this guidance, pegaptanib a selective anti-VEGF agent was compared with ranibizumab and found not to be cost effective.

The clear benefits of intravitreal anti-VEGF drugs over PDT laser therapy led to a rapid transition from PDT to the introduction of ranibizumab in the United Kingdom. This can be seen in my personal experience at the Birmingham and Midland Eye Centre where the number of PDT laser treatments declined from 160 per month or more to less than 5 per month in the period 2007–2010, and it has now declined even further. PDT is mainly now only being used for polypoidal vasculopathy and chronic central serous chorioretinopathy.

The provision of AMD services in the NHS accordingly underwent a reformation at this time, and it was recognised that the 'PDT model' was no longer going to be viable. For PDT services in the United Kingdom, treatment and assessment had been limited to 40 or so larger ophthalmic units who had access to medical retina expertise. For anti-VEGF services, it was realised that greater numbers of patients would be eligible for treatment, with more frequent monitoring and treatment visits, and a new service delivery model was required. This led to considerable debate within the Royal College of Ophthalmologists about the configuration of the new services and in July 2007, the publication of guidelines for ophthalmologists and health-care commissioners.⁴⁶

Diabetic retinopathy

The quarter century from 1988 to 2013 witnessed important progress in the management of diabetic retinopathy, with

developments in laser technology, ophthalmic imaging, and drugs targeted to the retina. However, possibly the greatest impact in the United Kingdom was the introduction of a national diabetic retinopathy screening programme in the four devolved nations.

The provision of diabetic eye services in the United Kingdom in 1988 was patchy, and access to laser photocoagulation services and expertise was often difficult for patients outside the larger centres. As early as 1978, Professor Eva Kohner had outlined a blue-print of optimal care, which had emphasised the need for close collaboration between ophthalmologists and diabetic physicians, the provision of regional centres for assessment and treatment of diabetic retinopathy, and the importance of screening and diabetic control.⁴⁷ Professor Kohner had commented in this paper that 'if physicians and ophthalmologists work together, blindness may indeed be prevented in diabetic patients' and at East Birmingham Hospital, (subsequently Birmingham Heartlands) where I was based, we took this advice to heart by setting up a combined diabetic eye clinic, which was led by myself an ophthalmologist and Professor Paul Dodson, a diabetic physician. Although for us this worked exceptionally well in improving patient care, facilitating teaching, training, and research, it was not unfortunately a model that was copied elsewhere to my knowledge, but it was certainly beneficial in improving our clinical service.⁴⁸⁻⁵²

Laser photocoagulation

The success of laser photocoagulation in preventing blindness in diabetic retinopathy had been demonstrated in a number of earlier, landmark clinic trials. The Diabetic Retinopathy Study (DRS) had clearly shown that timely pan-retinal argon laser photocoagulation could reduce the risk of severe visual loss by at least half and had far less harmful side effects than xenon light coagulation.⁵³ In addition, it had also introduced the concept of 'high-risk' characteristics for proliferative diabetic retinopathy (PDR), which enabled ophthalmologists to identify and treat patients appropriately.⁵⁴ The Early Treatment Diabetic Retinopathy Study (ETDRS) further refined our knowledge of when to treat patients with PDR, and showed that scatter argon laser photocoagulation was not beneficial in mild and moderate non-proliferative (pre-proliferative phase), if careful monitoring in these cases can be maintained.⁵⁵

Until the 1980s, the importance of macular oedema as a cause of visual loss in diabetic patients was underestimated by most ophthalmologists and diabetic physicians. However, the reports from the Wisconsin Epidemiological Study provided the best data on the epidemiology of diabetic macular oedema, and raised the

awareness of this condition.⁵⁶⁻⁵⁸ The ETDRS further defined and classified diabetic macular oedema, and produced important information about the treatment of this condition^{59,60} and appropriate photocoagulation and laser settings.⁶¹ The concept of 'clinically significant macular oedema' was introduced by the ETDRS because it was shown that laser treatment was beneficial if this was present, and could reduce the risk of significant visual loss by about 50%.

Following these landmark studies, it was recognised that laser photocoagulation services should be provided in most ophthalmology departments, which would enable patients to receive early and timely laser photocoagulation locally. Most ophthalmologists at this time also switched away from using argon blue-green laser because of the perceived risk to the operator and increased collateral damage to the patient when treating near the macula. In fact for a short period, a monitoring system was introduced as part of a research project, to screen the colour vision of ophthalmologists performing laser, to detect laser-induced colour vision damage, on a volunteer basis.⁶²

With improvements in laser technology, and the introduction of solid state laser machines, it has been recognised that heavy laser burns in diabetic retinopathy are unnecessary for effective treatment and collateral damage to the retina can be minimised, by reducing laser exposure times^{63,64} (Figure 2).

This in turn has led to effective strategies to reduce patient's discomfort during pan-retinal laser photocoagulation by deliberately choosing shorter exposure times, while still providing effective treatment.⁶⁵ More recent advances have continued to improve the experience of patients undergoing retinal laser photocoagulation by using pattern scanning laser machines, which allow ophthalmologists to perform the treatment much quicker and with less discomfort.⁶⁶

Intravitreal therapy for diabetic maculopathy

Although laser photocoagulation had been the mainstay of treatment for diabetic maculopathy since the early 1980s, it was recognised that not all patients responded well to treatment. In particular, patients with diffuse macular thickening and with ischaemic changes did poorly with laser treatment. Other treatment options were therefore investigated and the IDRCR.Net performed a randomised controlled trial comparing modified EDTRS laser photocoagulation with either 1 or 4 mg of preservative free intravitreal triamcinolone. Despite an initial improvement in vision and retinal thickness in the 4 mg triamcinolone group, overall the laser group did better at 1 and 2 years, even when the effect of cataract formation with triamcinolone was considered.⁶⁷

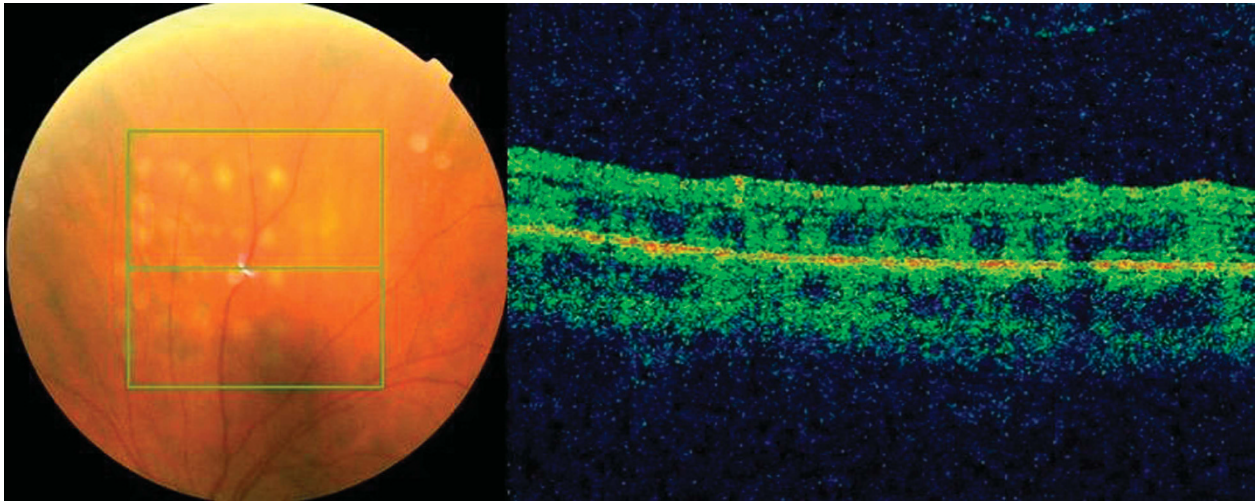


Figure 2 Fundus photograph and OCT image of diabetic patient with threshold laser photocoagulation burns, showing how OCT can facilitate subthreshold and threshold laser treatment.

However, increasing evidence from trials of intravitreal VEGF inhibitors is accumulating, which suggests that the outcome in patients with diffuse macular oedema is much improved. The BOLT Study, which compared bevacizumab with laser⁶⁸ and the landmark DRCR.Net study, which compared ranibizumab, laser, and triamcinolone, have shown that anti-VEGF therapy has become the new gold standard treatment for diabetic macular oedema.⁶⁹

Screening for diabetic retinopathy

In 1988, diabetic retinopathy screening for diabetic retinopathy was mostly opportunistic, performed by a few dedicated enthusiasts, but with no co-ordinated central organisation or guidelines, and with pupil dilatation being optional. In addition, there was considerable debate as to how screening should be delivered, whether by fundus photography or direct ophthalmoscopy, with and without mydriasis, and who should be trained to perform it.⁷⁰⁻⁷⁵ Many of these aspects were discussed at the Cambridge Ophthalmic Symposium in 1992, which was chaired by Dr Angus MacCuish a diabetic physician from Glasgow, who emphasised the needs for pupillary dilatation, for recruitment and training of personnel, and the importance of having quality control.⁷⁶

The development of DR screening in Europe had been accelerated by the St Vincent Declaration, in 1989, which set a target for reduction of new blindness by one-third, in the following 5 years.⁷⁷ In addition, several authors had shown that DR screening was cost effective as a means of preventing blindness from DR.⁷⁸

In 1999, a national workshop was convened in Glasgow by the National Screening Committee (NSC) of the Department of Health and the Royal College of Ophthalmologists (RCOphth), to consider the introduction of national screening programmes in the four devolved nations of the United Kingdom. Subgroups were set up to consider technology, training and education, grading, and quality assurance. The key mantra of co-chairs of this landmark meeting, Dr Muir Gray of the NSC and Dr Jeffrey Jay, President of the RCOphth, was 'simplify, simplify, simplify!'

The introduction of digital cameras for fundus photography enabled quality control to be obtained, and was rapidly adopted as the gold standard by the national screening programme.⁷⁹ The final parts of the photographic jigsaw was the validation that two field fundus photography was just as good, and much easier for photographer and patient, than seven standard field fundus photography, which was the then gold standard for clinical trials but impractical for large scale screening.^{80,81}

For grading, a subgroup of ophthalmologists, diabetic physicians, and photographers was convened to develop a simplified grading protocol⁸² for England and Wales, which was based on the following principles:

- To detect any retinopathy
- To detect the presence of sight threatening retinopathy (STDR)
- To allow precise quality assurance at all steps
- To minimise false-positive referrals to the hospital eye service.

This led to the novel 'R and M grades', which were introduced as a simple but accurate grading system, which could be easily validated. In 2011–2012, in England over 1.9 million persons with diabetes underwent retinopathy screening, representing a coverage of 73.9% of the population identified to have diabetes⁸³ (Figure 3).

Retinal vascular disease

For the management of retinal vein occlusions for much of the last 25 years, the best evidence has come from two important clinical trials: the Branch Vein Occlusion Study (BVOS) and the Central Vein Occlusion Study (CVOS). The BVOS conclusively demonstrated the effectiveness of argon laser photocoagulation for macular oedema⁸⁴ and retinal neovascularisation.⁸⁵ However, the CVOS showed that macular grid photocoagulation had no effect on the visual prognosis in patients with macular oedema,⁸⁶ but in ischaemic cases, iris neovascularisation quickly resolved after pan-retinal photocoagulation.⁸⁷ In general terms, therefore, there was not much ophthalmologists had to offer patients who developed macular oedema following central retinal vein occlusions.

However, the advent of intravitreal drug therapy has markedly changed the options available in the last few years. Intravitreal triamcinolone is effective in reducing

macular oedema but high rates of cataract formation and raised intra-ocular pressure were of concern in the SCORE Study.⁸⁸ However, more recently a slow release, dexamethasone intravitreal implant has been shown to be effective with a better safety profile.⁸⁹ Intravitreal ranibizumab and bevacizumab have also been shown to be highly effective in treating macular oedema in CVO.⁹⁰

Imaging advances in medical retina service

The past 25 years have seen major advances in retinal imaging. In the 1980s, we were almost entirely reliant on film-based fluorescein angiography, for guiding laser treatment, which in the case of wet AMD had to be performed on an urgent basis. This required an in-house medical photographer who would carry out the fundus photography, undertake immediate film development, and printing, and return it to the ophthalmologist with patient to perform laser—all within the time confines of a clinic (Figures 4 and 5).

This laborious process could be accelerated by using Polaroid film,⁹¹ or by using video analysis, but did not really improve until the advent of digital fundus photography. Later on the use of ICG angiography transformed our understanding of choroidal disorders⁹² and continues to be an important investigation in certain




Figure 3 Map of constituent parts of the Birmingham and Black Country Diabetic Retinopathy Screening Service. By 2010, when this schematic map was created, there were 125 000 annual screens being performed, at 106 screening sites, referring into 7 hospital ophthalmology departments.

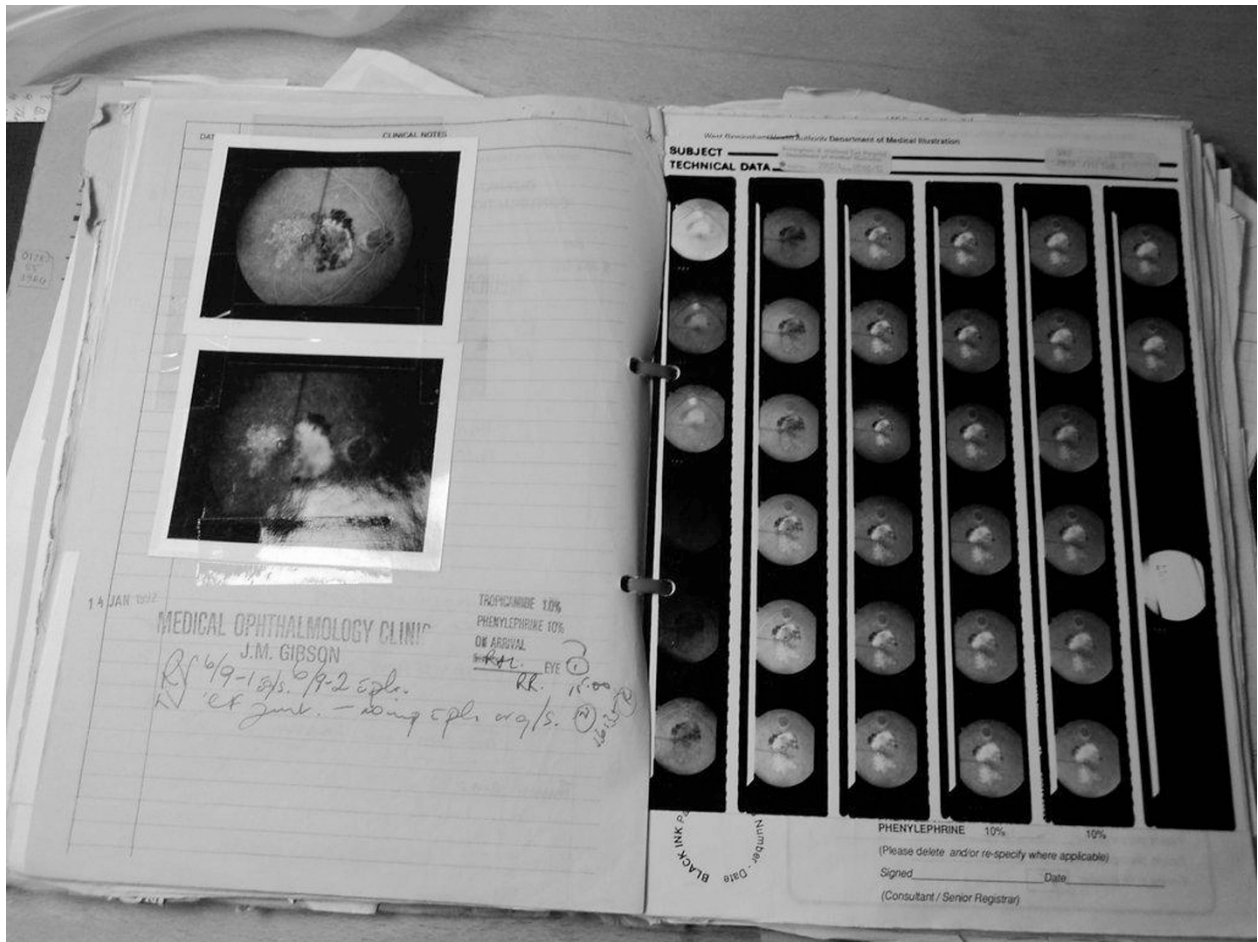


Figure 4 Photograph of case notes of patient in pre-digital era of 1992, showing Polaroid prints and fluorescein angiography prints performed to guide laser treatment.

conditions,^{93,94} although probably less influential in medical retina disease that was first expected.

By far the major imaging advance in the field of medical retina has been optical coherence tomography (OCT), which rapidly went from being a research investigation, first reported in the early 1990s,⁹⁵ to being an essential part of the medical retina clinic in 2013. Today OCT is an integral part of the assessment of all macular diseases, and has become a key part of treatment protocols for AMD, diabetic retinopathy, and retinovascular disorders. To meet the increasing workload of busy clinics, ophthalmologists are increasingly turning to their non-medical staff clinics to support in the provision of services, such as by 'virtual clinics', whereby large numbers of patients results can be quickly reviewed.⁹⁶

Conclusion

Over the past 25 years enormous advances have taken place in the way we manage the major medical retina conditions. There has been a move away from targeted,

destructive, laser therapy to intravitreal pharmacological interventions, blocking VEGF, and other growth factors. The forthcoming challenge will be how ophthalmologists deal with the ever increasing workload in medical retina disease, while being able to incorporate the exciting concepts of individualised health care that are promised by recent advances in genetics.⁹⁷

Conflict of interest

The author has received travel re-imbursement and honoraria for attending advisory boards and conferences from Novartis Pharmaceuticals UK Ltd, Bayer PLC, Alimera Sciences, and Allergan Limited. He has received research funding from Novartis Pharmaceuticals UK Ltd and Bayer PLC.

Acknowledgements

The author acknowledges the large number of medical, nursing, and technical staff that he had the privilege of

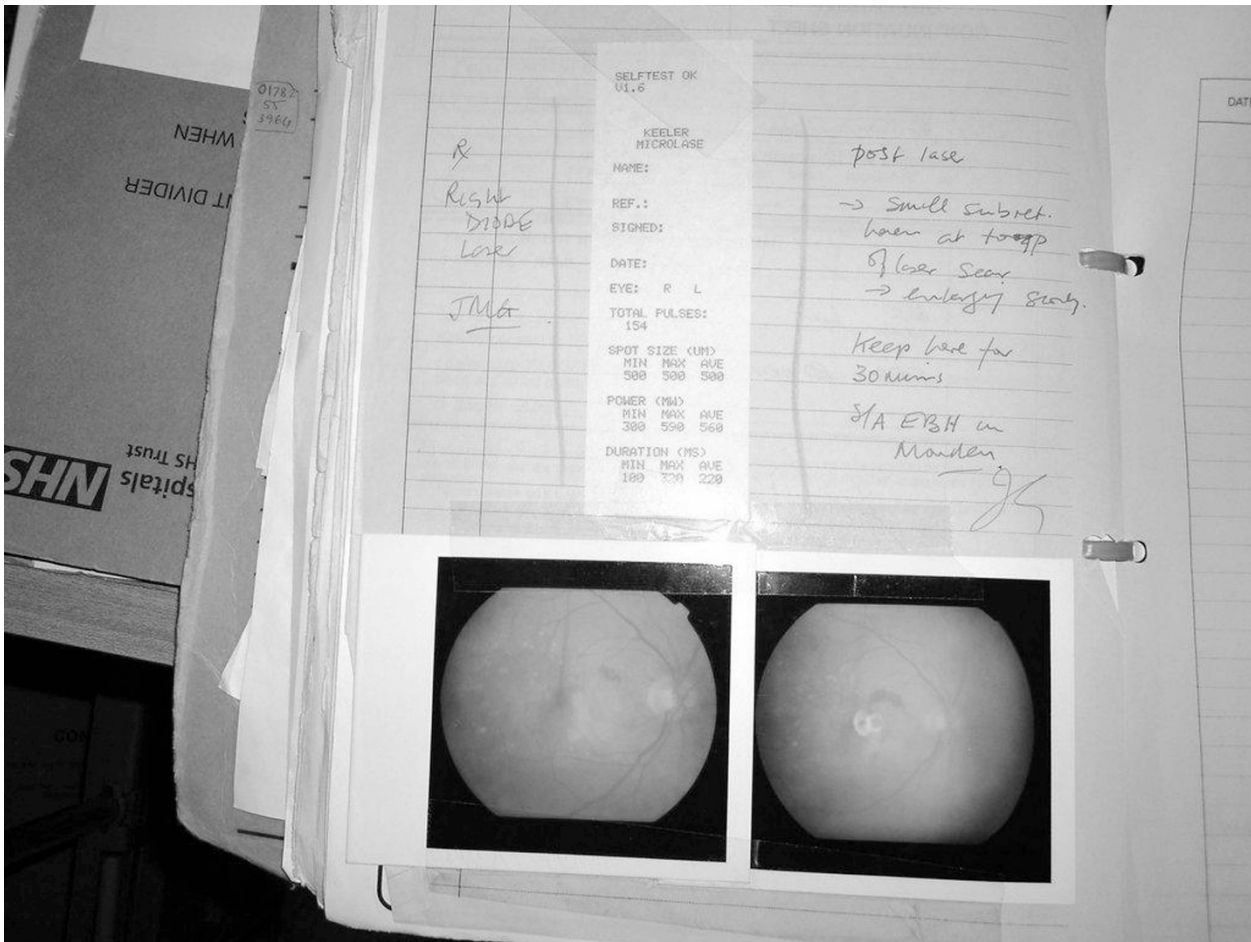


Figure 5 Post-laser treatment notes and photographs of same case as in Figure 2, showing successful laser treatment of large classic, extrafoveal CNV. The patient went on to retain good vision for 20 years.

working with over the past 25 years in the medical retina clinics at the Birmingham and Midland Eye Centre and Heart of England NHS Foundation Trust. He knows his patients have appreciated the efforts of the whole team involved in their eye care and it has been a personal pleasure to be involved in this service.

References

- 1 Gregor Z, Bird AC, Chisholm IH. Senile disciform macular degeneration in the second eye. *Br J Ophthalmol* 1977; **61**(2): 141–147.
- 2 Macular Photocoagulation Study Group. Argon laser photocoagulation for senile macular degeneration. Results of a randomized clinical trial. *Arch Ophthalmol* 1982; **100**(6): 912–918.
- 3 Klein ML, Jorizzo PA, Watzke RC. Growth features of choroidal neovascular membranes in age-related macular degeneration. *Ophthalmology* 1989; **96**(9): 1416–1419; discussion 20–21.
- 4 Fine SL, Murphy RP. Photocoagulation for choroidal neovascularization. *Ophthalmology* 1983; **90**(5): 531–533.
- 5 The Moorfields Macular Study Group. Treatment of senile disciform macular degeneration: a single-blind randomised trial by argon laser photocoagulation. *Br J Ophthalmol* 1982; **66**(12): 745–753.
- 6 Macular Photocoagulation Study Group. Persistent and recurrent neovascularization after laser photocoagulation for subfoveal choroidal neovascularization of age-related macular degeneration. *Arch Ophthalmol* 1994; **112**(4): 489–499.
- 7 Singerman LJ, Kalski RS. Tunable dye laser photocoagulation for choroidal neovascularization complicating age-related macular degeneration. *Retina* 1989; **9**(4): 247–257.
- 8 Ulbig MW, McHugh DA, Hamilton AM. Photocoagulation of choroidal neovascular membranes with a diode laser. *Br J Ophthalmol* 1993; **77**(4): 218–221.
- 9 Barondes MJ, Pagliarini S, Chisholm IH, Hamilton AM, Bird AC. Controlled trial of laser photocoagulation of pigment epithelial detachments in the elderly: 4 year review. *Br J Ophthalmol* 1992; **76**(1): 5–7.
- 10 Hoskin A, Bird AC, Sehmi K. Tears of detached retinal pigment epithelium. *Br J Ophthalmol* 1981; **65**(6): 417–422.
- 11 Macular Photocoagulation Study Group. Laser photocoagulation of subfoveal neovascular lesions in age-related macular degeneration. Results of a randomized clinical trial. *Arch Ophthalmol* 1991; **109**(9): 1220–1231.

- 12 Tornambe PE, Poliner LS, Hovey LJ, Taren D. Scatter macular photocoagulation for subfoveal neovascular membranes in age-related macular degeneration. A pilot study. *Retina* 1992; **12**(4): 305–314.
- 13 Fung WE. Interferon alpha 2a for treatment of age-related macular degeneration. *Am J Ophthalmol* 1991; **112**(3): 349–350.
- 14 Gillies MC, Sarks JP, Beaumont PE, Hunyor AB, McKay D, Kearns M *et al.* Treatment of choroidal neovascularisation in age-related macular degeneration with interferon alfa-2a and alfa-2b. *Br J Ophthalmol* 1993; **77**(12): 759–765.
- 15 Kirkpatrick JN, Dick AD, Forrester JV. Clinical experience with interferon alfa-2a for exudative age-related macular degeneration. *Br J Ophthalmol* 1993; **77**(12): 766–770.
- 16 Hart PM, Chakravarthy U, Mackenzie G, Chisholm IH, Bird AC, Stevenson MR *et al.* Visual outcomes in the subfoveal radiotherapy study: a randomized controlled trial of teletherapy for age-related macular degeneration. *Arch Ophthalmol* 2002; **120**(8): 1029–1038.
- 17 Evans JR, Sivagnanavel V, Chong V. Radiotherapy for neovascular age-related macular degeneration. *Cochrane Database Syst Rev* 2010; (5): CD004004.
- 18 Yannuzzi LA, Slakter JS, Sorenson JA, Guyer DR, Orlock DA. Digital indocyanine green videoangiography and choroidal neovascularization. *Retina* 1992; **12**(3): 191–223.
- 19 Slakter JS, Yannuzzi LA, Sorenson JA, Guyer DR, Ho AC, Orlock DA. A pilot study of indocyanine green videoangiography-guided laser photocoagulation of occult choroidal neovascularization in age-related macular degeneration. *Arch Ophthalmol* 1994; **112**(4): 465–472.
- 20 Hope-Ross MW, Gibson JM, Chell PB, Corridan PG, Kritzinger EE. Dye enhanced laser photocoagulation in the treatment of a peripapillary subretinal neovascular membrane. *Acta ophthalmologica* 1994; **72**(1): 134–137.
- 21 Treatment of age-related macular degeneration with photodynamic therapy (TAP) Study Group. Photodynamic therapy of subfoveal choroidal neovascularization in age-related macular degeneration with verteporfin: one-year results of 2 randomized clinical trials—TAP report. *Arch Ophthalmol* 1999; **117**(10): 1329–1345.
- 22 Soubrane G, Bressler NM. Treatment of subfoveal choroidal neovascularisation in age related macular degeneration: focus on clinical application of verteporfin photodynamic therapy. *Br J Ophthalmol* 2001; **85**(4): 483–495.
- 23 Azab M, Benchaboune M, Blinder KJ, Bressler NM, Bressler SB, Gragoudas ES *et al.* Verteporfin therapy of subfoveal choroidal neovascularization in age-related macular degeneration: meta-analysis of 2-year safety results in three randomized clinical trials: Treatment of Age-Related Macular Degeneration with Photodynamic Therapy and Verteporfin in Photodynamic Therapy Study Report no. 4. *Retina* 2004; **24**(1): 1–12.
- 24 Bressler NM, Arnold J, Benchaboune M, Blumenkranz MS, Fish GE, Gragoudas ES *et al.* Verteporfin therapy of subfoveal choroidal neovascularization in patients with age-related macular degeneration: additional information regarding baseline lesion composition's impact on vision outcomes-TAP report No. 3. *Arch Ophthalmol* 2002; **120**(11): 1443–1454.
- 25 Verteporfin R, participants, treatment of age-related macular degeneration with photodynamic therapy study group principal i, Verteporfin in photodynamic therapy study group principal i. Guidelines for using verteporfin (visudyne) in photodynamic therapy to treat choroidal neovascularization due to age-related macular degeneration and other causes. *Retina* 2002; **22**(1): 6–18.
- 26 Verteporfin Roundtable P. Guidelines for using verteporfin (Visudyne) in photodynamic therapy for choroidal neovascularization due to age-related macular degeneration and other causes: update. *Retina* 2005; **25**(2): 119–134.
- 27 Spaide RF, Martin ML, Slakter J, Yannuzzi LA, Sorenson J, Guyer DR *et al.* Treatment of idiopathic subfoveal choroidal neovascular lesions using photodynamic therapy with verteporfin. *Am J Ophthalmol* 2002; **134**(1): 62–68.
- 28 Blinder KJ, Blumenkranz MS, Bressler NM, Bressler SB, Donato G, Lewis H *et al.* Verteporfin therapy of subfoveal choroidal neovascularization in pathologic myopia: 2-year results of a randomized clinical trial—VIP report no. 3. *Ophthalmology* 2003; **110**(4): 667–673.
- 29 Schmidt-Erfurth UM, Michels S. Changes in confocal indocyanine green angiography through two years after photodynamic therapy with verteporfin. *Ophthalmology* 2003; **110**(7): 1306–1314.
- 30 Michels S, Hansmann F, Geitzenauer W, Schmidt-Erfurth U. Influence of treatment parameters on selectivity of verteporfin therapy. *Invest Ophthalmol Vis Sci* 2006; **47**(1): 371–376.
- 31 Spaide RF, Sorenson J, Maranan L. Combined photodynamic therapy with verteporfin and intravitreal triamcinolone acetate for choroidal neovascularization. *Ophthalmology* 2003; **110**(8): 1517–1525.
- 32 Augustin AJ, Schmidt-Erfurth U. Verteporfin therapy combined with intravitreal triamcinolone in all types of choroidal neovascularization due to age-related macular degeneration. *Ophthalmology* 2006; **113**(1): 14–22.
- 33 Kaiser PK. Registry of Visudyne AMDTWCBoyer DS, Garcia R, Hao Y, Hughes MS *et al.* Verteporfin photodynamic therapy combined with intravitreal bevacizumab for neovascular age-related macular degeneration. *Ophthalmology* 2009; **116**: 747–755; 55e1.
- 34 Rudnisky CJ, Liu C, Ng M, Weis E, Tennant MT. Intravitreal bevacizumab alone versus combined verteporfin photodynamic therapy and intravitreal bevacizumab for choroidal neovascularization in age-related macular degeneration: visual acuity after 1 year of follow-up. *Retina* 2010; **30**(4): 548–554.
- 35 Smith BT, Dhalla MS, Shah GK, Blinder KJ, Ryan Jr EH, Mitra RA. Intravitreal injection of bevacizumab combined with verteporfin photodynamic therapy for choroidal neovascularization in age-related macular degeneration. *Retina* 2008; **28**(5): 675–681.
- 36 Augustin A. Triple therapy for age-related macular degeneration. *Retina* 2009; **29**(6 Suppl): S8–S11.
- 37 Michels S, Michels R, Simader C, Schmidt-Erfurth U. Verteporfin therapy for choroidal hemangioma: a long-term follow-up. *Retina* 2005; **25**(6): 697–703.
- 38 Ergun E, Tittl M, Stur M. Photodynamic therapy with verteporfin in subfoveal choroidal neovascularization secondary to central serous chorioretinopathy. *Arch Ophthalmol* 2004; **122**(1): 37–41.
- 39 Koh A, Lee WK, Chen LJ, Chen SJ, Hashad Y, Kim H *et al.* EVEREST study: efficacy and safety of verteporfin photodynamic therapy in combination with ranibizumab or alone versus ranibizumab monotherapy in patients with symptomatic macular polypoidal choroidal vasculopathy. *Retina* 2012; **32**(8): 1453–1464.
- 40 Brown DM, Kaiser PK, Michels M, Soubrane G, Heier JS, Kim RY *et al.* Ranibizumab versus verteporfin for

- neovascular age-related macular degeneration. *N Engl J Med* 2006; **355**(14): 1432–1444.
- 41 Rosenfeld PJ, Brown DM, Heier JS, Boyer DS, Kaiser PK, Chung CY *et al.* Ranibizumab for neovascular age-related macular degeneration. *N Engl J Med* 2006; **355**(14): 1419–1431.
- 42 Regillo CD, Brown DM, Abraham P, Yue H, Ianchulev T, Schneider S *et al.* Randomized, double-masked, sham-controlled trial of ranibizumab for neovascular age-related macular degeneration: PIER Study year 1. *Am J Ophthalmol* 2008; **145**(2): 239–248.
- 43 Fung AE, Lalwani GA, Rosenfeld PJ, Dubovy SR, Michels S, Feuer WJ *et al.* An optical coherence tomography-guided, variable dosing regimen with intravitreal ranibizumab (Lucentis) for neovascular age-related macular degeneration. *Am J Ophthalmol* 2007; **143**(4): 566–583.
- 44 Lalwani GA, Rosenfeld PJ, Fung AE, Dubovy SR, Michels S, Feuer W *et al.* A variable-dosing regimen with intravitreal ranibizumab for neovascular age-related macular degeneration: year 2 of the PrONTO Study. *Am J Ophthalmol* 2009; **148**(1): 43–58 e1.
- 45 Excellence NifHaCTA 155 Ranibizumab and pegaptanib for the treatment of age-related macular degeneration. London, 2008.
- 46 Ophthalmologists RCoCommissioning contemporary AMD services: a guide for commissioners and clinicians 2007, Contract No.: version 3.
- 47 Kohner EM. The solution of the problem. *Transactions of the Ophthalmological Societies of the United Kingdom* 1978; **98**(2): 299–302.
- 48 Dodson PM, Gibson JM. The National Diabetic Retinopathy Laser Treatment Audit: implications for clinical practice in 1998. *Eye* 1998; **12**(Pt 1): 1.
- 49 Jude EB, Ryan B, O’Leary BM, Gibson JM, Dodson PM. Pupillary dilatation and driving in diabetic patients. *Diabet Med* 1998; **15**(2): 143–147.
- 50 Gillow JT, Gibson JM, Dodson PM. Hypertension and diabetic retinopathy—what’s the story? *Br J Ophthalmol* 1999; **83**(9): 1083–1087
- 51 Al-Husainy S, Farmer J, Gibson JM, Dodson PM. Is measurement of blood pressure worthwhile in the diabetic eye clinic? *Eye* 2005; **19**(3): 312–316
- 52 Denniston AK, Banerjee S, Gibson JM, Dodson PM. Cardiovascular therapies and their role in diabetic eye disease. *Diabet Med* 2005; **22**(5): 665–666.
- 53 The Diabetic Retinopathy Study Research Group. Photocoagulation treatment of proliferative diabetic retinopathy. Clinical application of Diabetic Retinopathy Study (DRS) findings, DRS Report Number 8. *Ophthalmology* 1981; **88**(7): 583–600.
- 54 The Diabetic Retinopathy Study Research Group. Indications for photocoagulation treatment of diabetic retinopathy: Diabetic Retinopathy Study Report no. 14. *Int Ophthalmol Clinics* 1987; **27**(4): 239–253.
- 55 Early Treatment Diabetic Retinopathy Study Research Group. Early photocoagulation for diabetic retinopathy. ETDRS report number 9. *Ophthalmology* 1991; **98**(5 Suppl): 766–785.
- 56 Klein R, Klein BE, Moss SE, Davis MD, DeMets DL. The Wisconsin epidemiologic study of diabetic retinopathy. IV. Diabetic macular edema. *Ophthalmology* 1984; **91**(12): 1464–1474.
- 57 Klein R, Moss SE, Klein BE, Davis MD, DeMets DL. The Wisconsin epidemiologic study of diabetic retinopathy. XI. The incidence of macular edema. *Ophthalmology* 1989; **96**(10): 1501–1510.
- 58 Klein R, Klein BE, Moss SE, Cruickshanks KJ. The Wisconsin Epidemiologic Study of Diabetic Retinopathy. XV. The long-term incidence of macular edema. *Ophthalmology* 1995; **102**(1): 7–16.
- 59 Early Treatment Diabetic Retinopathy Study research group. Photocoagulation for diabetic macular edema. Early Treatment Diabetic Retinopathy Study report number 1. *Arch Ophthalmol* 1985; **103**(12): 1796–1806.
- 60 The Early Treatment Diabetic Retinopathy Study Research Group. Photocoagulation for diabetic macular edema: Early Treatment Diabetic Retinopathy Study Report no. 4. *Int Ophthalmol Clinics* 1987; **27**(4): 265–272.
- 61 Early Treatment Diabetic Retinopathy Study Research Group. Treatment techniques and clinical guidelines for photocoagulation of diabetic macular edema. Early Treatment Diabetic Retinopathy Study Report Number 2. *Ophthalmology* 1987; **94**(7): 761–774.
- 62 Arden GB, Hall MJ. Does occupational exposure to argon laser radiation decrease colour contrast sensitivity in UK ophthalmologists? *Eye* 1995; **9**(Pt 6): 686–696
- 63 Jain A, Blumenkranz MS, Paulus Y, Wiltberger MW, Andersen DE, Huie P *et al.* Effect of pulse duration on size and character of the lesion in retinal photocoagulation. *Arch Ophthalmol* 2008; **126**(1): 78–85.
- 64 Bhatnagar A, Gibson JM, Elsherbiny S. Spectral domain optical coherence tomography can detect visible and subthreshold laser burns using 532-nm laser. *Ophthalmic Surg Lasers Imaging* 2010; **41** Online: e1–e3.
- 65 Al-Hussainy S, Dodson PM, Gibson JM. Pain response and follow-up of patients undergoing panretinal laser photocoagulation with reduced exposure times. *Eye* 2008; **22**(1): 96–99.
- 66 Muqit MM, Marcellino GR, Henson DB, Young LB, Patton N, Charles SJ *et al.* Single-session vs multiple-session pattern scanning laser panretinal photocoagulation in proliferative diabetic retinopathy: the Manchester Pascal Study. *Arch Ophthalmol* 2010; **128**(5): 525–533.
- 67 Diabetic Retinopathy Clinical Research NBeck RW, Edwards AR, Aiello LP, Bressler NM, Ferris F *et al.* Three-year follow-up of a randomized trial comparing focal/grid photocoagulation and intravitreal triamcinolone for diabetic macular edema. *Arch Ophthalmol* 2009; **127**(3): 245–251.
- 68 Michaelides M, Kaines A, Hamilton RD, Fraser-Bell S, Rajendram R, Quhill F *et al.* A prospective randomized trial of intravitreal bevacizumab or laser therapy in the management of diabetic macular edema (BOLT study) 12-month data: report 2. *Ophthalmology* 2010; **117**(6): 1078–86 e2.
- 69 Diabetic Retinopathy Clinical Research NELman MJ, Aiello LP, Beck RW, Bressler NM, Bressler SB *et al.* Randomized trial evaluating ranibizumab plus prompt or deferred laser or triamcinolone plus prompt laser for diabetic macular edema. *Ophthalmology* 2010; **117**(6): 1064–1077; e35.
- 70 Foulds WS, McCuish A, Barrie T, Green F, Scobie IN, Ghafour IM *et al.* Diabetic retinopathy in the West of Scotland: its detection and prevalence, and the cost-effectiveness of a proposed screening programme. *Health Bull* 1983; **41**(6): 318–326.
- 71 Taylor R, Lovelock L, Tunbridge WM, Alberti KG, Brackenridge RG, Stephenson P *et al.* Comparison of non-mydriatic retinal photography with ophthalmoscopy in

- 2159 patients: mobile retinal camera study. *BMJ* 1990; **301**(6763): 1243–1247.
- 72 Harding SP, Broadbent DM, Neoh C, White MC, Vora J. Sensitivity and specificity of photography and direct ophthalmoscopy in screening for sight threatening eye disease: the Liverpool Diabetic Eye Study. *BMJ* 1995; **311**(7013): 1131–1135.
- 73 Ryder RE, Vora JP, Atiea JA, Owens DR, Hayes TM, Young S. Possible new method to improve detection of diabetic retinopathy: polaroid non-mydratric retinal photography. *Br Med J* 1985; **291**(6504): 1256–1257.
- 74 Owens DR, Dolben J, Young S, Ryder RE, Jones IR, Vora J *et al*. Screening for diabetic retinopathy. *Diabet Med* 1991; **8**, Spec No S4–10.
- 75 Burns-Cox CJ, Hart JC. Screening of diabetics for retinopathy by ophthalmic opticians. *Br Med J* 1985; **290**(6474): 1052–1054.
- 76 MacCuish AC. Early detection and screening for diabetic retinopathy. *Eye* 1993; **7**(Pt 2): 254–259.
- 77 St. Vincent Declaration Workshop Report. Diabetes care and research in Europe: the Saint Vincent declaration. *Diabet Med* 1990; **7**(4): 360.
- 78 James M, Turner DA, Broadbent DM, Vora J, Harding SP. Cost effectiveness analysis of screening for sight threatening diabetic eye disease. *BMJ* 2000; **320**(7250): 1627–1631.
- 79 Scanlon PH, Malhotra R, Thomas G, Foy C, Kirkpatrick JN, Lewis-Barned N *et al*. The effectiveness of screening for diabetic retinopathy by digital imaging photography and technician ophthalmoscopy. *Diabet Med* 2003; **20**(6): 467–474.
- 80 Moss SE, Meuer SM, Klein R, Hubbard LD, Brothers RJ, Klein BE. Are seven standard photographic fields necessary for classification of diabetic retinopathy? *Invest Ophthalmol Visual Sci* 1989; **30**(5): 823–828.
- 81 Scanlon PH, Malhotra R, Greenwood RH, Aldington SJ, Foy C, Flatman M *et al*. Comparison of two reference standards in validating two field mydratric digital photography as a method of screening for diabetic retinopathy. *Br J Ophthalmol* 2003; **87**(10): 1258–1263.
- 82 Harding S, Greenwood R, Aldington S, Gibson J, Owens D, Taylor R *et al*. Grading and disease management in national screening for diabetic retinopathy in England and Wales. *Diabet Med* 2003; **20**(12): 965–971.
- 83 Programme NDES2011-2012 Summary 2013.
- 84 The Branch Vein Occlusion Study Group. Argon laser photocoagulation for macular edema in branch vein occlusion. *Am J Ophthalmol* 1984; **98**(3): 271–282.
- 85 Branch Vein Occlusion Study Group. Argon laser scatter photocoagulation for prevention of neovascularization and vitreous hemorrhage in branch vein occlusion. A randomized clinical trial. *Arch Ophthalmol* 1986; **104**(1): 34–41.
- 86 The Central Vein Occlusion Study Group M report. Evaluation of grid pattern photocoagulation for macular edema in central vein occlusion. *Ophthalmology* 1995; **102**(10): 1425–1433.
- 87 The Central Vein Occlusion Study Group N report. A randomized clinical trial of early panretinal photocoagulation for ischemic central vein occlusion. *Ophthalmology* 1995; **102**(10): 1434–1444.
- 88 Ip MS, Scott IU, VanVeldhuisen PC, Oden NL, Blodi BA, Fisher M *et al*. A randomized trial comparing the efficacy and safety of intravitreal triamcinolone with observation to treat vision loss associated with macular edema secondary to central retinal vein occlusion: the Standard Care *vs* Corticosteroid for Retinal Vein Occlusion (SCORE) study report 5. *Arch Ophthalmol* 2009; **127**(9): 1101–1114.
- 89 Haller JA, Bandello F, Belfort Jr R, Blumenkranz MS, Gillies M, Heier J *et al*. Randomized, sham-controlled trial of dexamethasone intravitreal implant in patients with macular edema due to retinal vein occlusion. *Ophthalmology* 2010; **117**(6): 1134–1146 e3.
- 90 Brown DM, Campochiaro PA, Singh RP, Li Z, Gray S, Saroj N *et al*. Ranibizumab for macular edema following central retinal vein occlusion: six-month primary end point results of a phase III study. *Ophthalmology* 2010; **117**(6): 1124–1133; e1.
- 91 Gibson JM, Bradley I. Polaroid print film for fluorescein angiography. *Br J Ophthalmol* 1989; **73**(8): 687.
- 92 Guyer DR, Yannuzzi LA, Slakter JS, Sorenson JA, Orlock S. The status of indocyanine-green videoangiography. *Curr Opin Ophthalmol* 1993; **4**(3): 3–6.
- 93 Spaide RF, Donsoff I, Lam DL, Yannuzzi LA, Jampol LM, Slakter J *et al*. Treatment of polypoidal choroidal vasculopathy with photodynamic therapy. *Retina* 2002; **22**(5): 529–535.
- 94 Yannuzzi LA. Central serous chorioretinopathy: a personal perspective. *Am J Ophthalmol* 2010; **149**(3): 361–363.
- 95 Puliafito CA, Hee MR, Lin CP, Reichel E, Schuman JS, Duker JS *et al*. Imaging of macular diseases with optical coherence tomography. *Ophthalmology* 1995; **102**(2): 217–229.
- 96 Mookhtiar M, Downey L. Combined OCT and colour fundus photography in virtual clinic assessments of wet AMD patients. *Eye* 2012; **26**(4): 619 author reply 20.
- 97 Fritsche LG, Chen W, Schu M, Yaspan BL, Yu Y, Thorleifsson G *et al*. Seven new loci associated with age-related macular degeneration. *Nat Genet* 2013; **45**(4): 433–439; 9e1–2.