

Surgical management of corneal limbal dermoids: retrospective study of different techniques and use of Mitomycin C

SJ Lang, D Böhlinger and T Reinhard

CLINICAL STUDY

Abstract

Purpose We retrospectively studied the efficacy and safety of different surgical approaches to treating pediatric limbal dermoids with regard to intra and postoperative complications.

Methods The data of 12 consecutive patients (14 eyes), who underwent monocentric surgery of a limbal demoid in the past 9 years, were retrospectively analyzed for intra and postoperative complications. Group one consists of eleven eyes: seven eyes with a bare-sclera deep lamellar excision of the dermoid and four eyes with an additional amniotic membrane transplantation subsequent to excision. Group two consists of three eyes: two eyes treated with Mitomycin C 0.02% over 2 min following the excision, and one eye treated with Mitomycin C and amniotic membrane transplantation after removal of the dermoid. Follow-up ranged from 2 to 53 months (median 17 months).

Results Intraoperative complications did not occur in any of the patients. Postoperatively, all patients showed corneal reepithelialization within a week. Limbal stem cell deficiency with a pseudopterygium developed in four eyes, one treated with bare-sclera excision and the others with amniotic membrane transplantation. One pseudopterygium had to be removed surgically because of visual acuity deterioration. Not a single eye treated with Mitomycin C developed a pseudopterygium.

Conclusions The transplantation of amniotic membrane following removal of a limbal

dermoid cannot prevent the occurrence of a pseudopterygium. However, the use of Mitomycin C seems to have a protective effect. *Eye* (2014) 28, 857–862; doi:10.1038/eye.2014.112; published online 23 May 2014

Introduction

Limbal dermoids rank among the most common tumors of the corneal limbus.¹ They are ocular choristomas and can occur in a variety of sizes ranging from only small lesions to larger masses in the epibulbar region.² Epibulbar dermoids are classified into three grades. Grade I limbal or epibulbar dermoid are lesions with a superficial tumor measuring <5 mm. Grade II limbal dermoids are of larger size and extend into the corneal stroma down to Descemet's membrane. Grade III limbal dermoids involve the whole cornea and structures of the anterior chamber. The most common location for epibulbar dermoids is the temporal inferior quadrant of the limbus.³ Though being a benign tumor, the removal of a limbal dermoid is not only performed to improve the cosmetic appearance of the eye but more importantly to prevent loss of visual acuity. Vision is often impaired from astigmatic refractive errors caused by corneal astigmatism. This may lead to irreversible anisometropic amblyopia in children.^{4,5} Large dermoids can also lead to surface irritation and discomfort or even central corneal opacification.

The appropriate time of intervention and the best surgical technique for removal of the pediatric limbal dermoids are subject to

Department of Ophthalmology, University Eye Hospital Freiburg, Freiburg im Breisgau, Germany

Correspondence: SJ Lang, Department of Ophthalmology, University Eye Hospital Freiburg, Killianstr. 5, Freiburg im Breisgau 79106, Germany
Tel: +49 761 270 40010;
Fax: +49 761 270 41271.
E-mail: Stefan.lang@uniklinik-freiburg.de

Received: 13 May 2013
Accepted in revised form: 14 April 2014
Published online: 23 May 2014

discussion. In the past, several different surgical techniques for the removal of dermoids have been described.⁶ These techniques include bare excision, amniotic membrane transplantation, and even lamellar and penetrating keratoplasty. The adequate choice depends on the location and size of the lesion.

Major risks of the excision of the limbal dermoid are intraoperative perforation, postoperative epithelial defects and peripheral vascularization of the cornea.⁷ Lamellar keratoplasty is reported to result in the improvement of visual acuity, but may also lead to an increased corneal astigmatism.^{8,9} In order to avoid scarring and conjunctivalization of the cornea, two different possibilities are described.

(1) Covering of the defect: several reports describe the possibility to combine the excision of the dermoid with placement of different kinds of tissue on the ocular surface. Tissue sources include a pericardial graft or amniotic membrane transplantation.¹⁰⁻¹² The fibrin-glued multilayered amniotic membrane transplantation was discussed to improve postoperative reepithelialization, prevent post-operative scarring, and protect the limbal stem cells.^{11,12}

(2) The use of Mitomycin C: Mitomycin C as an antitumor antibiotic was first isolated from *Streptomyces caespitosus* in 1958.¹³ It is used in pterygium surgery since 1963 in order to reduce the recurrence rates.¹⁴ This seems to be achieved by the inhibition of fibroblast proliferation at the level of the episclera.^{15,16} Therefore, in our opinion the use of Mitomycin C can be beneficial in

the treatment of limbal dermoids in matters of postoperative complications.

The goal of our study was to compare the efficacy of Mitomycin C in surgical treatment of limbal dermoids.

Patients and methods

The data with respect to efficacy and intra and postoperative safety of the removal of limbal dermoids were assessed in a monocentric, retrospective trial. All patients had been treated consecutively in the past 9 years. We included a total of 14 eyes of 12 consecutive patients who had undergone a removal of a limbal dermoid.

Seven patients were male and five were female (Table 1). Three patients had a diagnosis of Goldenhar syndrome. Thirteen limbal dermoids were located in the temporal inferior quadrant of the eye (Figures 1a and 2a), one was in the upper quadrant. All limbal dermoids were classified as grade one.

The indication for the surgery was an increase in the size of the dermoid in three patients. In two patients, the indication for excision was an increasing astigmatism and visual deterioration. Seven patients were afflicted with discomfort of the affected eye. Three patients suffered from strabism associated with amblyopia. One of these patients also had a central opacification of the cornea.

Preoperative evaluation of the limbal dermoid included measurement of best corrected visual acuity,

Table 1 Patients and surgical techniques

<i>Surgical technique</i>	<i>BCVA preOP</i>	<i>BCVA postOP</i>	<i>Complications</i>	<i>Follow-up postOP</i>	<i>Miscellaneous</i>
<i>Group one: plain removal</i>					
Patient 1	0.3	0.5	None	20 months	
Patient 2	0.9	0.8	Pseudopterygium	4 months	Goldenhar syndrome
Patient 3	1	0.8	Corneal opacification	3 months	
Patient 4	0.05	0.05	None	3 days	
Patient 5	1.25	0.9	None	1 day	
Patient 6	0.3	0.1	None	1 day	
Patient 7	0.8	k.A.	None	1 day	
<i>Removal and amniotic membrane</i>					
Patient 8 OD	0.6	0.5	Pseudopterygium	27 months	Removal of pseudopterygium with MMC 17 months after first surgery
Patient 8 OS	0.8	0.63	Pseudopterygium	26 months	Goldenhar syndrome
Patient 9	0.4	0.6	Pseudopterygium	2 months	
Patient 10	NA	NA	None	28 days	
<i>Group two: removal and mitomycin C</i>					
Patient 11 OD	0.5	0.4	None	53 months	Goldenhar syndrome
Patinet 11 OS	0.8	1	None	45 months	Goldenhar syndrome
Patient 12	1.25	1	None	17 months	Additional amniotic membrane transplantation

The table contains all patients; only patients with a follow-up of >2 months were included in the analysis of postoperative complications.

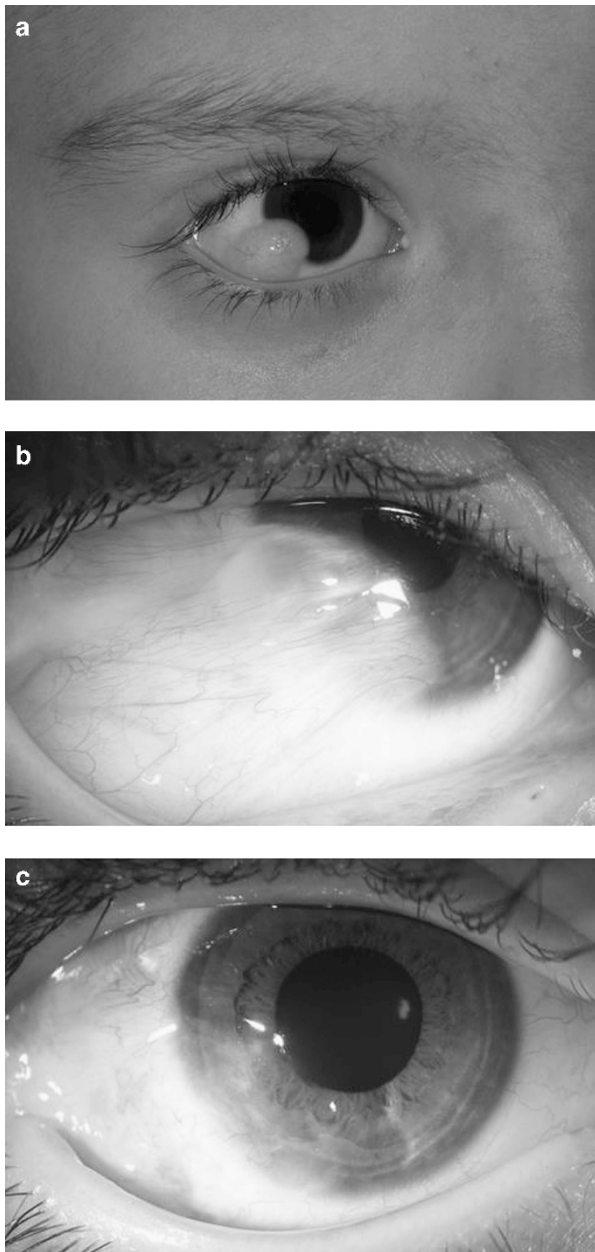


Figure 1 (a) Limbal dermoid before surgery (Patient 8). (b) Pseudoepithelioma 4 months after initial surgery with amniotic membrane (Patient 8). (c) After removal of the pseudoepithelioma (Patient 8).

slit-lamp examination and ophthalmoscopy. Ultrasound biomicroscopy (SonoMed VuMax 35 mHz; SonoMed Escalon, Lake Success, NY, USA) (Figure 3) could be obtained in six of the patients (seven eyes). However, the depth of the dermoid could not be definitely measured with this technique. All surgeries were performed by the same surgeon.

The surgical techniques were divided in two groups:

Group one included eleven eyes. The mean age at the time of the surgery was 4.4 years (lower quartile: 3.8;

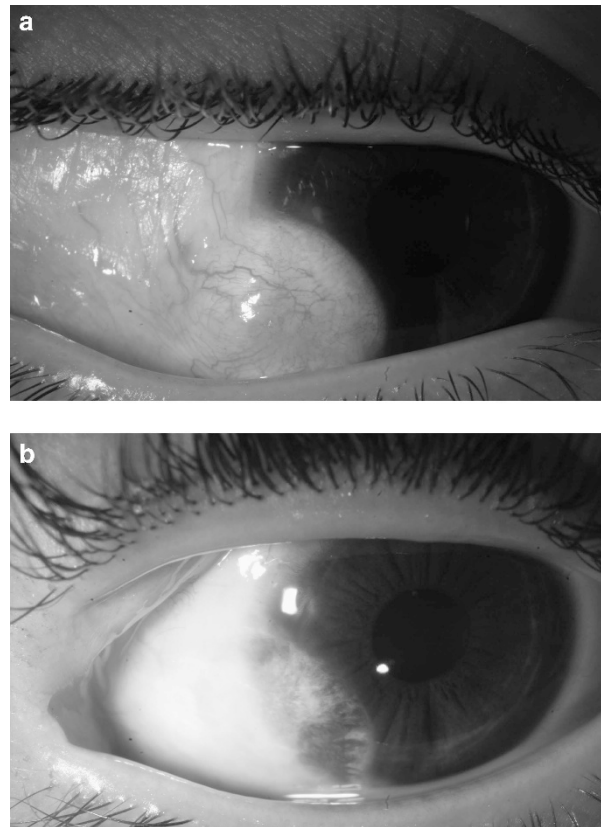


Figure 2 (a) Limbal dermoid before surgery (Patient 11). (b) After removal of the limbal dermoid with use of Mitomycin C (Patient 11).

upper quartile: 8.9). Seven eyes were treated by removal of the limbal dermoid by lamellar excision without further procedures. At first, the border of the limbal dermoid was marked using a trepan or a diamond blade. Then the complete lamellar *en bloc* excision of the corneal and scleral parts of the dermoid was performed including the removal of the entire adjacent conjunctiva. Finally a smoothing of the corneal surface was performed if necessary.

Amniotic membrane transplantation was carried out in four eyes. The amniotic membrane was prepared at our hospital, stored at -80°C on a Sartolon Polyamid Filter by Sartorius Stedim biotech (Sartorius AG, Göttingen, Germany) in a culture medium containing Glycerol, Streptomycin, penicillin, L-Glutamin, Amphotericin B, HEPES Buffer, NaHCO_3 , and MEM-Earles's. The amniotic membrane was grafted as single layer and fixed with multiple sutures of Vicryl 7.0 after the removal of the dermoid. Amniotic membrane only covered the sclera and the cornea at area of the excision. All sutures were removed within 2 weeks after surgery.

Group two consisted of three eyes that had been additionally treated with Mitomycin C 0.02% (Medac GmbH, Wedel, Germany). The mean age at the time of the surgery was 4.4 years (lower quartile: 3.8; upper

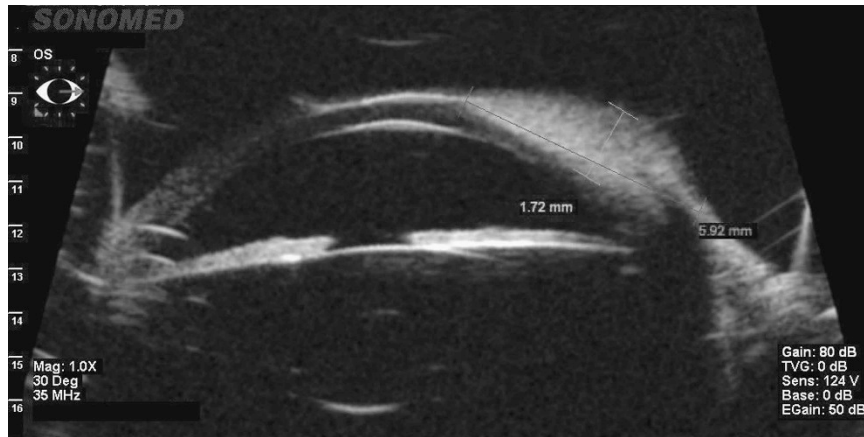


Figure 3 Ultrasound biomicroscopy (Frequency 35 mHz) of a limbal dermoid: Difficult evaluation of the depth (Patient 8).

quartile: 8.9). We exposed the bare sclera for 2 min after the complete removal of the dermoid. One of these eyes with treatment with Mitomycin C 0.02% over 2 min had supplemental amniotic membrane transplantation.

Postoperative treatment included antibiotic eye drops and artificial tear eye drops until reepithelialization occurred. Sutures were removed within 2 weeks. Pre and postoperative photographical data were available for all patients (Figures 1a and b, and 2a and b). When applicable, we assessed the best corrected visual acuity at each follow-up. All excised limbal dermoids underwent histological examination.

For the evaluation of postoperative complications, only the patients with a follow-up of >2 months were included. We estimated the rate of pseudoptygium formation with the Kaplan–Meier method. We also tested the difference in pseudoptygium formation between the Mitomycin C-treated and the conventional group for statistical significance by means of the log-rank test. This test was intended to be interpreted in a descriptive sense owing to the lack of an *a priori* statistical power calculation.

Results

There was no statistical difference between the groups concerning age ($P = 0.344$). We observed no intraoperative complications. A complete removal of the dermoid was achieved in all but one of the operated eyes.

Reepithelialization was complete after 1 week the latest in all eyes.

The histopathological examination confirmed the diagnosis of a solid limbal dermoid in all cases. Squamous epithelium, hair follicles, and sebaceous glands were unanimously present in the specimen.

For the evaluation of postoperative complications, the assessed patients had a postoperative follow-up from 2 to 53 months. Median follow-up was 17 months.

A total of four eyes from group one developed a limbal stem cell deficiency within 2–16 months, resulting in a pseudoptygium formation (Figure 1b). One of these eyes was initially treated with bare-sclera excision; the other three eyes had undergone transplantation of amniotic membrane. One eye had to undergo surgery of the pseudoptygium because of visual loss due to an increasing astigmatism. A removal of the pseudoptygium with the intraoperative use of Mitomycin C 0.02% for 2 min and the transplantation of amniotic membrane were performed (Figure 1c). No eye treated with Mitomycin C developed a postoperative pseudoptygium (Figure 4). The difference between the groups was not statistically different in the log-rank test ($P = 0.053$). Temporary signs of ischemia after treatment with Mitomycin C (Figure 2b) resolved completely and did not pose any further complications.

Mean visual acuity was 0.21 logMAR in group one and 0.0 logMAR in group two. There was no statistical difference ($P = 0.18$). Postoperative astigmatism showed -0.25 D in group one and -4.25 D in group two. This also did not show statistical significance ($P = 0.56$).

Discussion

The method of choice to treat a limbal dermoid is surgical excision.^{1–7}

The use of amniotic membrane transplantation in the removal of a limbal dermoid has recently been described by others.^{10,12,13} The main reasons for using amniotic membrane transplantation on conjunctival defects are the positive effects on reepithelialization and inhibition of postoperative inflammation, neovascularisation, and fibrosis.¹⁷

Pirouzian *et al*¹¹ reported that the purpose of amniotic membrane transplantation was primarily to achieve a volumetric filling of the stromal and epithelial defect after the removal of a limbal dermoid. They also

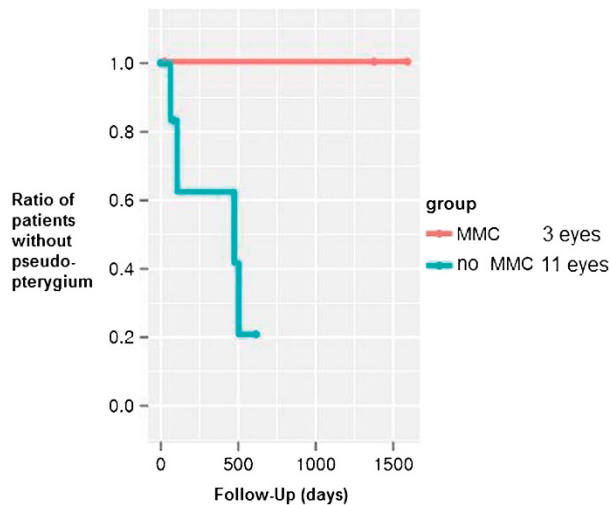


Figure 4 Ratio of patients without pseudoepithelium in the groups with or without MMC.

anticipated reduced scarring due to faster reepithelialization. Reduced inflammation with consecutive protection of the limbal stem cells is another commonly assumed mechanism of action.^{11,12} A removal of a limbal dermoid alone can lead to a limbal stem cell deficiency and pseudoepithelium formation.¹⁸ Therefore, stem cell transplantation may be a more beneficial approach.^{19,20} However, we decided to choose a less invasive technique, namely intraoperative application of Mitomycin C with or without amniotic membrane transplantation. Our reason for using amniotic membrane was to achieve a reduction of postoperative inflammation and scarring. The use of Mitomycin C in our patients was based on the positive results from limbokeratoplasty in limbal stem cell deficiency.¹⁹ We hypothesize that Mitomycin C inhibits fibroblast growth and consequently the occurrence of a pseudoepithelium or corneal neovascularization. The inhibition of fibroblast growth by Mitomycin C is also reported in the treatment of a primary pterygium, a recurrent pterygium, and in filtering bleb surgery.^{14–16} Regarding our data, three out of four limbal stem cell deficiencies occurred in eyes, which had amniotic membrane transplantation after removal of the limbal dermoid. Therefore, we did not observe a protective effect of amniotic membrane transplantation regarding the limbal stem cells or the growth of a postoperative pseudoepithelium. The poor outcome of amniotic membrane transplantation in our study stands in contrast to the previous reports.^{10,12,13} All eyes treated with Mitomycin C, however, showed no development of a pseudoepithelium during the follow-up. Therefore, a beneficial effect of Mitomycin C on postoperative pseudoepithelium formation has to be considered likely.

The main limitation of our trial is the small number of cases that forecloses adequate statistical reasoning from our results. In addition, the patients need a longer postoperative follow-up until a final evaluation is possible. This is especially true for our five patients with short follow-up, which could either not be contacted owing to unknown address or were not available for another examination. Therefore, the use of Mitomycin C in the removal of limbal dermoids and the transplantation of amniotic membrane should be evaluated in a larger, prospective and controlled clinical trial. Nevertheless, our preliminary results are promising, and we believe that Mitomycin C is a viable option in limbal dermoid surgery.

Summary

What was known before

- Tumors of the corneal limbus are extremely rare. Limbal dermoids rank among the most common of them. They are treated mostly by bare-sclera excision. Pseudoepithelium due to limbal stem cell deficiency is a possible postoperative complication. The transplantation of amniotic membrane has been recently described in order to prevent postoperative complications. The transplantation of amniotic membrane has been recently described in order to prevent postoperative complications.

What this study adds

- The use of amniotic membrane transplantation cannot prevent the occurrence of a pseudoepithelium. The intraoperative additional treatment with Mitomycin C is a new approach not described in the literature yet. First results indicate that it might have a protective effect relating to the occurrence of postoperative pseudoepithelium.

Conflict of interest

The authors declare no conflict of interest.

References

- 1 Sunderraj PP, Viswanathan RK, Balachander R. Neoplasms of the limbus. *Indian J Ophthalmol* 1991; **39**: 168–169.
- 2 Mansour AM, Barber JC, Reinecke RD, Wang FM. Ocular choristomas. *Review Surv Ophthalmol* 1989; **33**: 339–358.
- 3 Sommer F, Pillunat LE. Epibulbäre Dermoiden. *Klin Monatsbl Augenheilkd* 2004; **221**: 872–877.
- 4 Burillon C, Durand L. Solid dermoids of the limbus and the cornea. *Ophthalmologica* 1997; **211**: 367–372.
- 5 Robb RM. Astigmatic refractive errors associated with limbal dermoids. *J Pediatr Ophthalmol Strabismus* 1996; **33**: 241–243.
- 6 Stergiopoulos P, Link B, Naumann GO, Seitz B. Solid corneal dermoids and subconjunctival lipodermoids: impact of differentiated surgical therapy on the functional long-term outcome. *Cornea* 2009; **28**(6): 644–651.

- 7 Panton RW, Sugar J. Excision of limbal dermoids. *Ophthalmic Surg* 1991; **22**: 85–89.
- 8 Scott JA, Tan DT. Therapeutic lamellar keratoplasty for limbal dermoids. *Ophthalmology* 2001; **108**: 185818–185867.
- 9 Watts P, Michaeli-Cohen A, Abdolell M, Rootman D. Outcome of lamellar keratoplasty for limbal dermoids in children. *J AAPOS* 2002; **6**: 209–215.
- 10 Lazzaro DR, Coe R. Repair of limbal dermoid with excision and placement of a circumlimbal pericardial graft. *Eye Contact Lens* 2010; **36**: 228–229.
- 11 Pirouzian A, Holz H, Merrill K, Sudesh R, Karlen K. Surgical management of pediatric limbal dermoids with sutureless amniotic membrane transplantation and augmentation. *J Pediatr Ophthalmol Strabismus* 2011; **30**: 1–6.
- 12 Pirouzian A, Ly H, Holz H, Sudesh R, Chuck R. Fibrin-glue assisted multilayered amniotic membrane transplantation in surgical management of pediatric corneal limbal dermoid: a novel approach. *Graefes Arch Clin Exp Ophthalmol* 2011; **249**: 261–265.
- 13 Wakaki S, Marumo H, Tomioka K. Isolation of new fractions of antitumor mitomycins. *Antibiot Chemother* 1958; **8**: 228–240.
- 14 Cheng HC, Tseng SH, Kao PL, Chen FK. Low-dose intraoperative mitomycin C as chemoadjuvant for pterygium surgery. *Cornea* 2001; **20**: 24–29.
- 15 Hutchinson Amy K, Grossniklaus Hans E, Brown Reay H, McManus Paul E, Bradley Charles K. Clinicopathologic features of excised mitomycin filtering blebs. *Arch Ophthalmol* 1994; **112**: 74–79.
- 16 Fakhry MA. The use of mitomycin C with autologous limbal-conjunctival autograft transplantation for management of recurrent pterygium. *Clin Ophthalmol* 2011; **26**: 123–127.
- 17 Gomes JA, Romano A, Santos MS, Dua HS. Amniotic membrane use in ophthalmology. *Curr Opin Ophthalmol* 2005; **16**: 233–240.
- 18 Mohan M, Mukherjee G, Panda A. Clinical evaluation and surgical intervention of limbal dermoid. *Indian J Ophthalmol* 1981; **29**: 69–73.
- 19 Eberwein P, Böhringer D, Schwartzkopff J, Birnbaum F, Reinhard T. Allogenic limbo-keratoplasty with conjunctivoplasty, mitomycin c, and amniotic membrane for bilateral limbal stem cell deficiency. *Ophthalmology* 2012; **119**(5): 930–937.
- 20 Reinhard T, Spelsberg H, Henke L, Kontopoulos T, Enczmann J, Wernet P et al. Long-term results of allogenic penetrating limbo-keratoplasty in total limbal stem cell deficiency. *Ophthalmology* 2004; **111**(4): 775–782.