Eye (2013) 27, 1388–1390

www.nature.com/eye

CLINICAL STUDY

Bimanual anterior segment revision surgery for anterior capsule contraction syndrome associated with anterior flexion of intraocular lens haptics

M Zinkernagel[1], A Papazoglou and CK Patel

Abstract

Purpose **To report the incidence of anterior capsule contraction syndrome (ACCS) and to present a novel minimally invasive bimanual technique for anterior segment revision surgery associated with ACCS with anterior flexion of the intraocular lens haptics.**
Methods **A consecutive cohort of 268 eyes of 161 patients undergoing phacoemulsification and implantation of the same type of hydrophilic acrylic aspheric intraocular lens cohort were analysed and a novel technique of minimally invasive bimanual technique for anterior segment revision surgery is described.**
Results **We identified four eyes (1.5%) of three patients with advanced ACCS. Successful restoration of a clear visual axis with minimal induction of astigmatism and rapid visual rehabilitation was achieved in all four cases.**
Conclusion **This technique is a safe and minimally invasive alternative to laser or vitrector-cut capsulotomy to restore a clear visual axis. In cases of advanced ACCS, it offers the option for haptic reposition or amputation.**

Eye (2013) **27,** 1388–1390; doi:10.1038/eye.2013.206; published online 13 September 2013

Keywords: anterior capsule of the lens; phacoemulsification; capsulotomy

Oxford Eye Hospital, Oxford University Hospitals, Oxford, UK

Correspondence:
M Zinkernagel, Department of Ophthalmology, University Hospital Bern, 3010 Bern, Switzerland
Tel: +41316322501;
Fax: +41316320114.
E-mail: m.zinkernagel@gmail.com

[1]Current address: Department of Ophthalmology, University Hospital Bern, Bern, Switzerland

Received: 7 November 2012
Accepted in revised form: 19 August 2013
Published online: 13 September 2013

Introduction

After continuous curvilinear capsulorrhexis in uneventful phacoemulsification cataract surgery, the anterior capsule opening often contracts to some degree.[1,2] In rare cases the contraction can be severe, leading to anterior capsule contraction syndrome (ACCS). ACCS consists of opacification, fibrosis, and contraction of the anterior capsule. When the constriction affects the visual axis, visual acuity decreases. In advanced cases, intraocular lens decentration and flexion of the haptics onto the anterior surface of the optic can occur.[3] Once formed, removal of fibrosis often needs surgical removal.[4] Nd:YAG opening frequently requires excessive laser energy with complications such as IOL pitting, cystoid macular oedema, or residual fibrotic material in the anterior chamber that may lead to inflammation and secondary glaucoma. Surgical treatment options for ACCS include the use of a capsulorrhexis forceps to peel the fibrotic capsule,[5] microscissors[4] or vitrector-cut capsulotomy.[6] The latter carries the risk IOL damage or severe iris damage, as the tip of the vitrector needs to be pushed towards the IOL to engage the opening of the vitrector with the anterior capsule. We report here a novel, minimally invasive and safe technique of bimanual anterior capsulotomy and haptic reposition or amputation in a small case series to restore a clear visual axis.

Materials and methods

This retrospective clinical study included patients who received phacoemulsification and IOL implantation between November 2010 and December 2011. Informed consent was obtained from all patients prior to surgical procedures. In

all cases a hydrophilic one-piece acrylic IOL (Quatrix IOL, Corneal Laboratories, La Rochelle, France) was used. Inclusion criteria included successful creation of a complete and appropriately sized CCC and IOL fixation in the capsular bag. Patients with pseudoexfoliation syndrome or a history of uveitis and intra-operative complications were excluded. A standard technique (2.75 mm clear corneal incision, Duovisc, phaco-chop, bimannual irrigation-aspiration(I/A), 1 mg intracameral Cefuroxime) and platform (Infinity, Alcon, Fort Worth, TX, USA) was used in all cases. Out of this cohort the rate of ACCS was determined and a novel technique for revision of ACCS is described.

Results and report of technique

The retrospective study included 268 eyes (109 left and 159 right). Four (1.5%) eyes of this cohort developed a ACCS grade 2 according to Toto *et al*,[7] requiring surgical intervention (Figure 1). Subtenons anaesthesia (Lidocaine 2%/Mepivacaine 0.5% 50:50 (4–6 ml)) was used in all four cases. After surgical disinfection with 2.5% povidone iodine and draping the anterior chamber was entered obliquely at 6 o'clock with a 20-gauge MVR blade and an anterior chamber maintainer was inserted. Two additional 20-gauge paracenteses were made in the 10 and 2 o'clock positions. The anterior capsule was opened with the MVR blade and a small amount of viscoleastic material was placed underneath the anterior capsule. Grieshaber 23-gauge endgrasping forceps and standard curved scissors were used for bimanual surgical anterior capsulectomy. Briefly, the edge of the anterior capsulotomy was lifted with the forceps for stablization and the anterior capsule opening was enlarged by tangential cuts with the scissors (Supplementary Video 1).

In two cases, amputation of the IOL haptics to achieve a free optical axis (clip 1) was necessary. The cut capsule and haptics were removed from the anterior chamber using the endgrasping forceps. At the end of surgery, viscoelastic was removed with a Simcoe cannula and 1 mg intracameral Cefuroxime was given prior to hydration of the paracentesis. Postoperative G dexamethasone 0.1% and G Ofloxacin 0.3% q.i.d. were prescribed for 7 days. One day after capsulectomy, the visual acuity improved objectively and subjectively in all patients (Table 1).

Discussion

The incidence of ACCS with the Quatrix IOL (Croma-Pharma GmbH, Leobendorf, Austria), a single-piece hydrophilic acrylic aspheric IOL, has been reported previously to be about 5%.[8] We report here a lower incidence of ACCS with the Quatrix IOL of 1.5% in a large cohort undergoing standard phacoemulsification cataract extraction, although only cases with visually significant ACCS were included. All of our cases with ACCS were treated surgically using a novel minimally invasive technique. Several factors promote capsular contraction syndrome. Apart from capsulorhexis technique, risk

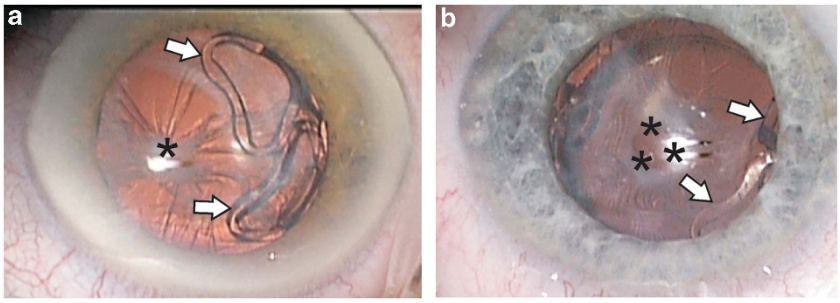

Figure 1 (a) Anterior capsule contraction syndrome with complete obliteration of the visual axis. Arrows define the dislocated haptics. Asterisks show anterior capsule opening. (b) Anterior capsule contraction syndrome with IOL decentration and haptic dislocation. Arrows point to haptics. Asterisks show anterior capsule opening.

Table 1 Patient data

Patient	*Eye*	*Age*	*Pre-op BCVA*	*Post-op BCVA (3 m)*	*ACCS Grade*[7]	*Amputation required (y/n)*	*Pre-op refraction*	*Post-op refraction (1 m)*
MR	*OD*	*60*	*6/18*	*6/9*	*2*	*n*	*−0.75Dpt*	*−0.75Dpt*
MR	*OS*	*60*	*6/24*	*6/12*	*2*	*y*	*−0.5Dpt*	*−0.5Dpt*
JM	*OD*	*77*	*6/60*	*6/6*	*2*	*y*	*plano/−1.00@86°*	*+0.25/−125@90°*
SO	*OD*	*64*	*6/7.4*	*6/6*	*2*	*n*	*+0.50/−0.50@180°*	*plano*

factors for the development of ACCS include pseudoexfoliation syndrome,[9] diabetes mellitus,[10,11] and retinitis pigmentosa.[12] IOL design and IOL composition are significant factors in the development of ACCS as well.[13,14] Treatment of ACCS depends on the degree of visual disability due to whitening of the capsule over the IOL optic. We report here a minimally invasive technique using standard 23-gauge vitreoretinal forceps and horizontal scissors to bimanually remove the fibrotic anterior capsule, and in some cases to perform haptic amputation. Although we describe this technique exclusively in ACCS associated with the Quatrix IOL, it is likely to be useful in ACCS associated with other types of acrylic one-piece IOLs. Potential sequelae of haptic amputation may be iris chafing with development of microhyphema or bag IOL complex dislocation because of further contracture of the bag. This technique has the advantage over other forms of surgical removal that only small paracenteses are required to gain access and maintain stability of the anterior chamber. This results in minimal induction of astigmatism and rapid postoperative visual rehabilitation. The use of an anterior chamber maintainer makes this procedure very safe and cost efficient. Using the bimanual technique also offers more control and minimal risk of damaging the IOL than with laser capsulotomy while being able to remove even tenacious membranes.

Summary

What was known before

- Anterior capsule contraction syndrome (ACCS) can lead to significant reduction in visual acuity due to central opacification of the visual axis.
- Severe ACCS has been reported to develop in 1.6–6% depending on IOL material and design.
- Therapies for ACCS with Nd:YAG capsulotomy or capsulotomy with a vitrector have a risk of IOL damage or iris damage.

What this study adds

- We describe a novel minimally invasive technique using standard 23-gauge vitreoretinal instruments to perform a controlled capsulotomy of the anterior capsule.
- We report the incidence of severe ACCS after implantation of the Quatrix IOL in a large cohort.

References

1 Park TK, Chung SK, Baek NH. Changes in the area of the anterior capsule opening after intraocular lens implantation. *J Cataract Refract Surg* 2002; **28**: 1613–1617.
2 Ursell PG, Spalton DJ, Pande MV. Anterior capsule stability in eyes with intraocular lenses made of poly(methyl methacrylate), silicone, and AcrySof. *J Cataract Refract Surg* 1997; **23**: 1532–1538.
3 Michael K, O'Colmain U, Vallance JH, Cormack TG. Capsule contraction syndrome with haptic deformation and flexion. *J Cataract Refract Surg* **36**: 686–689.
4 Arleo RJCA, Arar HH, Hoffman RS. Anterior capsular contraction syndrome and PXF. *Cataract Refract Surg Today* 2007.
5 Reyntjens B, Tassignon MJ, Van Marck E. Capsular peeling in anterior capsule contraction syndrome: surgical approach and histopathological aspects. *J Cataract Refract Surg* 2004; **30**: 908–912.
6 Yeh PC, Goins KM, Lai WW. Managing anterior capsule contraction by mechanical widening with vitrector-cut capsulotomy. *J Cataract Refract Surg* 2002; **28**: 217–220.
7 Toto L, Falconio G, Vecchiarino L, Scorcia V, Di Nicola M, Ballone E *et al*. Visual performance and biocompatibility of 2 multifocal diffractive IOLs: six-month comparative study. *J Cataract Refract Surg* 2007; **33**: 1419–1425.
8 Tsinopoulos IT, Tsaousis KT, Kymionis GD, Symeonidis C, Grentzelos MA, Diakonis VF *et al*. Comparison of anterior capsule contraction between hydrophobic and hydrophilic intraocular lens models. *Graefes Arch Clin Exp Ophthalmol* 2010; **248**: 1155–1158.
9 Hayashi H, Hayashi K, Nakao F, Hayashi F. Anterior capsule contraction and intraocular lens dislocation in eyes with pseudoexfoliation syndrome. *Br J Ophthalmol* 1998; **82**: 1429–1432.
10 Kato S, Suzuki T, Hayashi Y, Numaga J, Hattori T, Yuguchi T *et al*. Risk factors for contraction of the anterior capsule opening after cataract surgery. *J Cataract Refract Surg* 2002; **28**: 109–112.
11 Kato S, Oshika T, Numaga J, Hayashi Y, Oshiro M, Yuguchi T *et al*. Anterior capsular contraction after cataract surgery in eyes of diabetic patients. *Br J Ophthalmol* 2001; **85**: 21–23.
12 Sudhir RR, Rao SK. Capsulorhexis phimosis in retinitis pigmentosa despite capsular tension ring implantation. *J Cataract Refract Surg* 2001; **27**: 1691–1694.
13 Schaumberg DA, Dana MR, Christen WG, Glynn RJ. A systematic overview of the incidence of posterior capsule opacification. *Ophthalmology* 1998; **105**: 1213–1221.
14 Sacu S, Menapace R, Buehl W, Rainer G, Findl O. Effect of intraocular lens optic edge design and material on fibrotic capsule opacification and capsulorhexis contraction. *J Cataract Refract Surg* 2004; **30**: 1875–1882.

Supplementary Information accompanies this paper on Eye website (http://www.nature.com/eye)