Eye (2013) 27, 1169–1173

www.nature.com/eye

CLINICAL STUDY

Influence of seasonal sunlight intensity and iris color on the anti-VEGF therapy for neovascular age-related macular degeneration

C Brockmann[1], T Brockmann[1] and J Dawczynski[2]

Abstract

Purpose **To investigate the influence of seasonal light intensity and patients' iris color on the visual recovery after anti-vascular endothelial growth factor (VEGF) therapy with ranibizumab or bevacizumab for neovascular age-related macular degeneration (AMD).**

Methods **The visual acuity of 555 eyes (529 patients) with neovascular AMD was evaluated after intravitreal injections of either ranibizumab or bevacizumab in respect to global radiation intensity and iris color.**

Results **The functional results during anti-VEGF therapy revealed a seasonal oscillation with a negative correlation between visual recovery and global radiation intensity ($R^2 = -0.756$, $P = 0.004$). Although the influence of the sunlight intensity on the visual recovery was significant after the first injection, this effect vanished within the continuous course of treatment. Regarding the improvement of functional recovery depending on iris color, dark-colored eyes (16.0%) gained 8.5 ± 10.0 letters after the first injection and 9.9 ± 12.8 letters after the second injection, compared with 3.4 ± 8.6 letters and 4.4 ± 11.0 letters in light-colored eyes (84.0%), respectively ($P = 0.005$ and $P = 0.019$).**

Conclusions **Our results indicate that seasonal sunlight intensity and iris color might influence the visual recovery of neovascular AMD patients undergoing anti-VEGF therapy. Our findings may be used as suggestions to refine individual anti-VEGF therapy regimens, especially in patients with light-colored eyes.**

Eye (2013) **27,** 1169–1173; doi:10.1038/eye.2013.159; published online 2 August 2013

Keywords: age-related macular degeneration; anti-VEGF therapy; ranibizumab; bevacizumab; iris color; sunlight

Introduction

Today's first-line therapy for neovascular age-related macular degeneration (AMD) is the inhibition of the vascular endothelial growth factor (VEGF) by the intravitreal application of monoclonal anti-VEGF antibodies such as ranibizumab (Lucentis, Genentech (San Francisco, CA, USA) and Novartis (Basel, Switzerland)) and bevacizumab (Avastin, Genentech and Roche (Basel, Switzerland)), and recently the anti-VEGF fusion protein aflibercept (Eylea, Regeneron Pharmaceuticals (Tarrytown, NY, USA) and Bayer HealthCare (Berlin, Germany)).[1–3] Ranibizumab and bevacizumab were proven to be equivalent[4,5] and demonstrated a superior effectiveness compared with former therapy options.[6–10] Nevertheless, patients benefit from this treatment to different degrees.[11–13] In this context, predictive baseline characteristics such as visual acuity, central retinal thickness, lesion size, choroidal neovascularization type, duration of symptoms, genotype, and coincidental systemic factors were identified.[14–17] However, taking known influencing parameters

[1]Department of Ophthalmology, Charité - University Medicine Berlin, Berlin, Germany

[2]Faculty of Medicine, Department of Ophthalmology and Eye Hospital, University of Leipzig, Leipzig, Germany

Correspondence: J Dawczynski, Faculty of Medicine, Department of Ophthalmology and Eye Hospital, University of Leipzig, Liebigstraße 10-14, 04103 Leipzig, Germany
Tel: +49 341 97 21650; Fax: +49 341 97 21659.
E-mail: Jens.Dawczynski@medizin.uni-leipzig.de

Received: 3 September 2012
Accepted in revised form: 27 June 2013
Published online: 2 August 2013

into account by adapting therapy regimes individually, the diversity of the outcome after anti-VEGF therapy is still remarkable.[18,19]

Accordingly, the purpose of this study was to investigate the influence of seasonal sunlight intensity and patients' iris color on the visual recovery after initial anti-VEGF therapy with ranibizumab or bevacizumab for neovascular AMD.

Materials and methods

Five hundred and fifty-five consecutive eyes of 529 Caucasian patients from Central Germany who were treated the first time for neovascular AMD by a series of three intravitreal injections of either 0.5 mg in 0.05 ml ranibizumab (363 eyes) or 1.25 mg in 0.05 ml bevacizumab (192 eyes) between July 2006 and December 2009 at the Department of Ophthalmology, University Hospital Jena were analyzed retrospectively. The study was realized agreeable to the rules of the local institutional review board and ethics committee. Benefits and risks were explained in detail to the patients and the procedure was performed after written informed consent. At the beginning of treatment and 4 weeks after each injection, patients underwent an ophthalmic examination including determination of the best-corrected visual acuity (BCVA), slit lamp examination, and optical coherence tomography (Cirrus and Stratus OCT; Carl Zeiss Meditec, Dublin, CA, USA). Relevant exclusion criteria such as retinal vascular diseases other than neovascular AMD, age <50 years, previous intravitreal injection of anti-VEGF agents, previous photodynamic therapy, and previous argon laser treatment were taken into account.

In an additional approach, iris colors of 179 eyes (175 patients) undergoing anti-VEGF therapy for neovascular AMD were documented in non-mydriasis between January and December 2009. A trained physician categorized the appearance of the irides into blue, gray, green, hazel, and brown using The Iris Color Classification System.[20] Simultaneously, the distrubution of iris colors of 174 eyes (174 patients) with atrophic AMD and 221 eyes of 221 cataract patients without retinal pathologies were reviewed likewise as controls.

No significant differences of the baseline characteristics between the study groups were observed (see Supplementary Data). All statistical evaluations were accomplished by using SPSS version 19.0 (SPSS, Chicago, IL, USA). A P-value <0.05 was considered as statistically significant.

Results

A total of 555 eyes (529 patients; 61.1% females) were treated between July 2006 and December 2009. The mean age was 76.2 ± 7.9 years, ranging from 50 to 95 years, the initial BCVA was 60.0 ± 20.4 letters. Ranibizumab was applied in 65.4% (363/555 eyes) and bevacizumab in 34.6% (192/555 eyes) of cases. The BCVA increased by 2.6 ± 10.6 letters after the first injection and 3.9 ± 12.9 letters after the second injection ($P = 0.001$ and $P = 0.001$, Student's t-test). Comparing the responsiveness to ranibizumab and bevacizumab after the first and second injection, no significant differences were observed ($P = 0.267$ and $P = 0.606$; Student's t-test).

Seasonal light intensity

Regarding the functional results after the intravitreal injection of the used VEGF inhibitors depending on the annual course, a seasonal oscillation becomes evident. Therefore, we investigated the association of seasonal sunlight intensities onto the visual outcome. Correlating the mean change of BCVA after anti-VEGF therapy to global radiation intensity, a negative association was found ($R^2 = -0.756$, $P = 0.004$, Pearson's correlation). According to the global radiation intensity, we split the year into months of high exposure from April to September and low exposure from October to March. Although the mean global radiation was 139.6 kWh/m^2 per month from April to September, the intensity declined to 40.4 kWh/m^2 per month from October to March. Correspondingly, eyes in the high-exposure group (53.3%, $n = 296$) gained 1.7 ± 9.9 letters, whereas eyes in the low-exposure group (46.7%, $n = 259$) improved by 3.6 ± 11.2 letters after the first injection ($P = 0.031$, Student's t-test). In the continous course of treatment, the effect of global radiation intensity on the functional recovery declines (Figure 1). On this account, the mean gain of visual acuity after the second injection was 3.7 ± 13.0 letters in the high-exposure group (57.3%, $n = 259$) compared with 4.2 ± 13.0 letters in the low-exposure group (42.7%, $n = 193$; $P = 0.650$, Student's t-test).

Iris color

Iris color has a geographical and demographical distribution.[21,22] On this account, we reviewed cataract patients as controls, of whom 64.3% (142/221 eyes) were light colored. AMD patients were light colored in 84.0% (147/175 patients) within the neovascular group and in 77.6% (135/174 eyes) of cases within the atrophic group. Thereby, light-colored eyes were significantly more frequent within neovascular ($P = 0.001$, χ^2-test) and atrophic AMD patients ($P = 0.004$, χ^2 test) compared with the controls. Patients with light-colored eyes had an odds ratio of 2.92 (95% confidence interval (CI), 1.79–4.76; $P = 0.001$) for neovascular and 1.93 (95% CI, 1.23–3.02; $P = 0.004$) for atrophic AMD. The control group was age and gender matched.

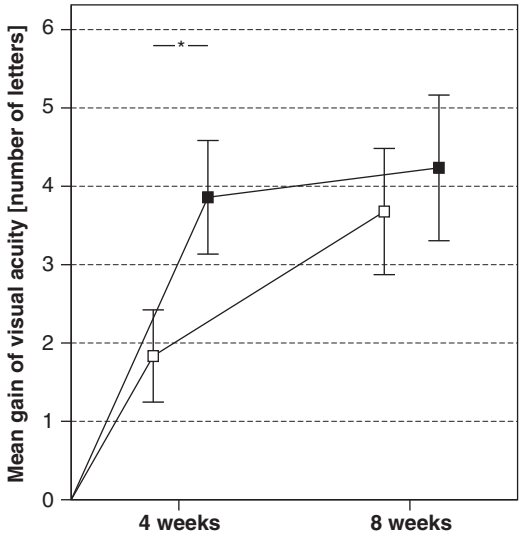

Figure 1 Mean gain of visual acuity after the first (4 weeks) and second injection (8 weeks) of eyes treated in month of high- (empty squares) and low-light exposure (solid squares). Although a significant difference was found after the first injection (*$P = 0.031$), disparities dissolved after the second injection. Bars represent the SE.

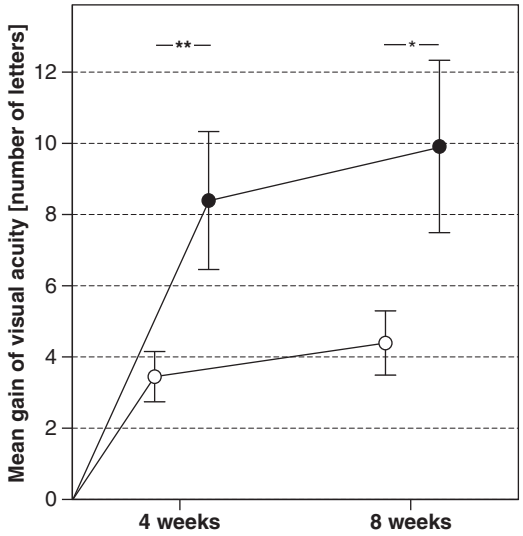

Figure 2 Mean gain of visual acuity after the first (4 weeks) and second injection (8 weeks) of light- (empty circles) and dark-colored (solid circles) eyes. A significant difference was found after the first (**$P = 0.005$) and second injection (*$P = 0.019$). Bars represent the SE.

To investigate the influence of iris color on the improvement of BCVA during anti-VEGF therapy, 179 eyes with neovascular AMD (175 patients) were analyzed, as shown in Figure 2. After the first injection, dark-colored eyes gained 8.5 ± 10.0 letters compared with 3.4 ± 8.6 letters within light-colored eyes ($P = 0.005$; Student's *t*-test). After two injections, dark-colored eyes gained 9.9 ± 12.8 letters compared with 4.4 ± 11.0 letters within light-colored eyes ($P = 0.019$; Student's *t*-test). Thus, the gain of functional recovery under anti-VEGF therapy was significantly higher in dark-colored eyes. Baseline characteristis of neovascular AMD patients including age, gender, visual acuity, central retinal thickness, and coincidential ocular and systemic pathologies did not differ between patients with light- and dark-colored eyes.

Discussion

Our overall results were comparable to previous studies analyzing visual outcome after anti-VEGF therapy, such as the MARINA and CATT study.[4,6] Disparities between ranibizumab and bevacizumab were not observed.

On analyzing the visual recovery after the first injection, depending on global radiation intensities, a significant reluctance was observed during months with a high sunlight exposure from April to September. However, this effect vanishes within the continuous course of treatment.

As AMD is a multifactorial disease, numerous reasons for a seasonal variation are possible. Among others, cardiovascular diseases and hypertension are risk factors for AMD and are subject to seasonal fluctuation.[23–25] So far, the influence of sunlight on the pathogenesis of AMD is still unsufficiently understood. The Beaver Dam Eye Study has revealed an increased incidence of AMD in patients spending above-average time at sunlight.[26,27] A current meta-analysis reviewing 14 studies could confirm extended sunlight exposure as a risk factor for AMD.[28] Especially, UV light contributes to the retinal destruction due to reactive oxygen species and thereby contributes to the development of AMD.[29,30] Raman *et al*[31] have shown that elevated UV exposure led to a reduction of the macular pigment optical density. In this respect, we hypothesize that the progression of neovascular AMD is accelerated in months with a high sunlight intensity likewise. Grisanti and Tura[32] demonstrated that the binding affinity of ranibizumab was decreased by 25% after sunlight exposure. In combination, the reduced effectiveness of anti-VEGF agents in a progressive condition of neovascular AMD might explain our results.

Iris color has been discussed as a risk factor for AMD.[33–36] Hammond *et al*[37] have shown that light irides are associated with less-pigmented retinal pigment epithelium. Thereby, the retinal pigment epithelium is of central importance to prevent cellular damage from reactive oxygen species by the reduction of radicals. In this context, light-colored eyes are more likely to develop AMD[34,38] and present a rapid progression.[33] Accordingly, we found a higher proportion of light irides within AMD patients compared with controls. Considering iris color on the visual recovery during anti-VEGF therapy,

dark-colored eyes were significantly more responsive than light-colored eyes after the first and second injection.

So far, genetic association studies investigating the responsiveness to anti-VEGF therapy were accomplished. Thereby, gene polymophisms of the VEGF-A (rs3025000), complement factor H (rs1061170), age-related macular susceptibility 2 (rs10490924), and high-temperature requirement A-1 (rs11200638) were determined to influence the therapeutic outcome.[16,39–41] Likewise, the gene polymorphisms rs12913832 and rs1129038 were identified to influence the iris color.[42] The interaction of gene polymorphisms associated to iris color and the anti-VEGF responsiveness has not been investigated yet.

We are aware that our study has several limitations, particularly because of the retrospective nature. Clinical data after the third injection have been omitted in our study because follow-up care was provided by local ophthalmologists and a negative selection took place in patients returning for futher visits. We decided to investigate the dynamic phase of the anti-VEGF therapy; therefore, we concentrated on the initial injections and did not rely on long-term data.

In summary, our observations indicate that seasonal light intensity and iris color might influence the visual recovery of neovascular AMD patients undergoing anti-VEGF therapy. We believe that the findings of our study might be used as suggestions to refine individual anti-VEGF therapy regimens.

Summary

What was known before

- Known predictive parameters for the responsiveness of the anti-VEGF therapy are the visual acuity, central retinal thickness, lesion size, choroidal neovascularization type, duration of symptoms, and genetic conditions.

What this study adds

- This study adds new evidence that sunlight intensity and iris color influence the course of visual recovery during anti-VEGF therapy.

Conflict of interest

The authors declare no conflict of interest.

Acknowledgements

We would like to thank Bernhard Kühn from the University of Applied Sciences Jena for providing meteorological data.

References

1 Chong V. Biological, preclinical and clinical characteristics of inhibitors of vascular endothelial growth factors. *Ophthalmologica* 2012; **227**(Suppl 1): 2–10.
2 Heier JS, Brown DM, Chong V, Korobelnik JF, Kaiser PK, Nguyen QD *et al*. Intravitreal aflibercept (VEGF trap-eye) in wet age-related macular degeneration. *Ophthalmology* 2012; **119**(12): 2537–2548.
3 Browning DJ, Kaiser PK, Rosenfeld PJ, Stewart MW. Aflibercept for age-related macular degeneration: a game-changer or quiet addition? *Am J Ophthalmol* 2012; **154**(2): 222–226.
4 Martin DF, Maguire MG, Ying GS, Grunwald JE, Fine SL, Jaffe GJ *et al*. Ranibizumab and bevacizumab for neovascular age-related macular degeneration. *N Engl J Med* 2011; **364**(20): 1897–1908.
5 Chakravarthy U, Harding SP, Rogers CA, Downes SM, Lotery AJ, Wordsworth S *et al*. Ranibizumab versus bevacizumab to treat neovascular age-related macular degeneration: one-year findings from the IVAN randomized trial. *Ophthalmology* 2012; **119**(7): 1399–1411.
6 Rosenfeld P, Brown D, Heier J, Boyer D, Kaiser P, Chung C *et al*. Ranibizumab for neovascular age-related macular degeneration. *N Engl J Med* 2006; **355**(14): 1419–1431.
7 Brown D, Kaiser P, Michels M, Soubrane G, Heier J, Kim R *et al*. Ranibizumab versus verteporfin for neovascular age-related macular degeneration. *N Engl J Med* 2006; **355**(14): 1432–1444.
8 Regillo C, Brown D, Abraham P, Yue H, Ianchulev T, Schneider S *et al*. Randomized, double-masked, sham-controlled trial of ranibizumab for neovascular age-related macular degeneration: PIER Study year 1. *Am J Ophthalmol* 2008; **145**(2): 239–248.
9 Monés J. A review of ranibizumab clinical trial data in exudative age-related macular degeneration and how to translate it into daily practice. *Ophthalmologica* 2011; **225**(2): 112–119.
10 Ladas ID, Chatziralli IP, Kotsolis AI, Douvali M, Georgalas I, Theodossiadis PG *et al*. Intravitreal ranibizumab versus thermal laser photocoagulation in the treatment of extrafoveal classic choroidal neovascularization secondary to age-related macular degeneration. *Ophthalmologica* 2012; **228**(2): 93–101.
11 Boyer DS, Antoszyk AN, Awh CC, Bhisitkul RB, Shapiro H, Acharya NR *et al*. Subgroup analysis of the MARINA study of ranibizumab in neovascular age-related macular degeneration. *Ophthalmology* 2007; **114**(2): 246–252.
12 Lux A, Llacer H, Heussen FM, Joussen AM. Non-responders to bevacizumab (Avastin) therapy of choroidal neovascular lesions. *Br J Ophthalmol* 2007; **91**(10): 1318–1322.
13 Veritti D, Sarao V, Lanzetta P. Neovascular age-related macular degeneration. *Ophthalmologica* 2012; **227**(Suppl 1): 11–20.
14 Brantley MA, Fang AM, King JM, Tewari A, Kymes SM, Shiels A. Association of complement factor H and LOC387715 genotypes with response of exudative age-related macular degeneration to intravitreal bevacizumab. *Ophthalmology* 2007; **114**(12): 2168–2173.
15 Francis PJ. The influence of genetics on response to treatment with ranibizumab (Lucentis) for age-related macular degeneration: the Lucentis Genotype Study (an American Ophthalmological Society thesis). *Trans Am Ophthalmol Soc* 2011; **109**: 115–156.

16 McKibbin M, Ali M, Bansal S, Baxter PD, West K, Williams G *et al.* CFH, VEGF and HTRA1 promoter genotype may influence the response to intravitreal ranibizumab therapy for neovascular age-related macular degeneration. *Br J Ophthalmol* 2012; **96**(2): 208–212.
17 Kaiser PK, Brown DM, Zhang K, Hudson HL, Holz FG, Shapiro H *et al.* Ranibizumab for predominantly classic neovascular age-related macular degeneration: subgroup analysis of first-year ANCHOR results. *Am J Ophthalmol* 2007; **144**(6): 850–857.
18 Kloeckener-Gruissem B, Barthelmes D, Labs S, Schindler C, Kurz-Levin M, Michels S *et al.* Genetic association with response to intravitreal ranibizumab in patients with neovascular AMD. *Invest Ophthalmol Vis Sci* 2011; **52**(7): 4694–4702.
19 Menghini M, Kurz-Levin MM, Amstutz C, Michels S, Windisch R, Barthelmes D *et al.* Response to ranibizumab therapy in neovascular AMD—an evaluation of good and bad responders. *Klin Monbl Augenheilkd* 2010; **227**(4): 244–248.
20 Seddon J, Sahagian C, Glynn R, Sperduto R, Gragoudas E. Evaluation of an iris color classification system. The Eye Disorders Case-Control Study Group. *Invest Ophthalmol Vis Sci* 1990; **31**(8): 1592–1598.
21 Holz F, Piguet B, Minassian D, Bird A, Weale R. Decreasing stromal iris pigmentation as a risk factor for age-related macular degeneration. *Am J Ophthalmol* 1994; **117**(1): 19–23.
22 Bito LZ, Matheny A, Cruickshanks KJ, Nondahl DM, Carino OB. Eye color changes past early childhood. The Louisville Twin Study. *Arch Ophthalmol* 1997; **115**(5): 659–663.
23 Sun C, Klein R, Wong TY. Age-related macular degeneration and risk of coronary heart disease and stroke: the Cardiovascular Health Study. *Ophthalmology* 2009; **116**(10): 1913–1919.
24 Jakovljević D, Salomaa V, Sivenius J, Tamminen M, Sarti C, Salmi K *et al.* Seasonal variation in the occurrence of stroke in a Finnish adult population. The FINMONICA Stroke Register. Finnish Monitoring Trends and Determinants in Cardiovascular Disease. *Stroke* 1996; **27**(10): 1774–1779.
25 Alpérovitch A, Lacombe JM, Hanon O, Dartigues JF, Ritchie K, Ducimetière P *et al.* Relationship between blood pressure and outdoor temperature in a large sample of elderly individuals: the Three-City study. *Arch Intern Med* 2009; **169**(1): 75–80.
26 Cruickshanks K, Klein R, Klein B, Nondahl D. Sunlight and the 5-year incidence of early age-related maculopathy: the beaver dam eye study. *Arch Ophthalmol* 2001; **119**(2): 246–250.
27 Tomany S, Cruickshanks K, Klein R, Klein B, Knudtson M. Sunlight and the 10-year incidence of age-related maculopathy: the Beaver Dam Eye Study. *Arch Ophthalmol* 2004; **122**(5): 750–757.
28 Sui GY, Liu GC, Liu GY, Gao YY, Deng Y, Wang WY *et al.* Is sunlight exposure a risk factor for age-related macular degeneration? A systematic review and meta-analysis. *Br J Ophthalmol* 2013; **97**(4): 389–394.
29 Remé C. The dark side of light: rhodopsin and the silent death of vision the proctor lecture. *Invest Ophthalmol Vis Sci* 2005; **46**(8): 2671–2682.
30 Margrain T, Boulton M, Marshall J, Sliney D. Do blue light filters confer protection against age-related macular degeneration? *Prog Retin Eye Res* 2004; **23**(5): 523–531
31 Raman R, Biswas S, Gupta A, Kulothungan V, Sharma T. Association of macular pigment optical density with risk factors for wet age-related macular degeneration in the Indian population. *Eye* 2012; **26**(7): 950–957.
32 Grisanti S, Tura A. [Qualitative differences between ranibizumab from original and ready to use syringes]. *Ophthalmologe* 2010; **107**(12): 1123–1132.
33 Sandberg M, Gaudio A, Miller S, Weiner A. Iris pigmentation and extent of disease in patients with neovascular age-related macular degeneration. *Invest Ophthalmol Vis Sci* 1994; **35**(6): 2734–2740.
34 Mitchell P, Smith W, Wang J. Iris color, skin sun sensitivity, and age-related maculopathy. The Blue Mountains Eye Study. *Ophthalmology* 1998; **105**(8): 1359–1363.
35 Wang J, Jakobsen K, Smith W, Mitchell P. Five-year incidence of age-related maculopathy in relation to iris, skin or hair colour, and skin sun sensitivity: the Blue Mountains Eye Study. *Clin Experiment Ophthalmol* 2003; **31**(4): 317–321.
36 Khan J, Shahid H, Thurlby D, Bradley M, Clayton D, Moore A *et al.* Age related macular degeneration and sun exposure, iris colour, and skin sensitivity to sunlight. *Br J Ophthalmol* 2006; **90**(1): 29–32.
37 Hammond BJ, Fuld K, Snodderly D. Iris color and macular pigment optical density. *Exp Eye Res* 1996; **62**(3): 293–297.
38 Fraser-Bell S, Choudhury F, Klein R, Azen S, Varma R. Group LALES. Ocular risk factors for age-related macular degeneration: the Los Angeles Latino Eye Study. *Am J Ophthalmol* 2010; **149**(5): 735–740.
39 Abedi F, Wickremasinghe S, Richardson AJ, Makalic E, Schmidt DF, Sandhu SS *et al.* Variants in the VEGFA gene and treatment outcome after anti-VEGF treatment for neovascular age-related macular degeneration. *Ophthalmology* 2013; **120**(1): 115–121.
40 Teper SJ, Nowinska A, Pilat J, Palucha A, Wylegala E. Involvement of genetic factors in the response to a variable-dosing ranibizumab treatment regimen for age-related macular degeneration. *Mol Vis* 2010; **16**: 2598–2604.
41 Nischler C, Oberkofler H, Ortner C, Paikl D, Riha W, Lang N *et al.* Complement factor H Y402H gene polymorphism and response to intravitreal bevacizumab in exudative age-related macular degeneration. *Acta Ophthalmol* 2011; **89**(4): e344–e349.
42 Ruiz Y, Phillips C, Gomez-Tato A, Alvarez-Dios J, Casares de Cal M, Cruz R *et al.* Further development of forensic eye color predictive tests. *Forensic Sci Int Genet* 2013; **7**(1): 28–40.

Supplementary Information accompanies this paper on Eye website (http://www.nature.com/eye)