

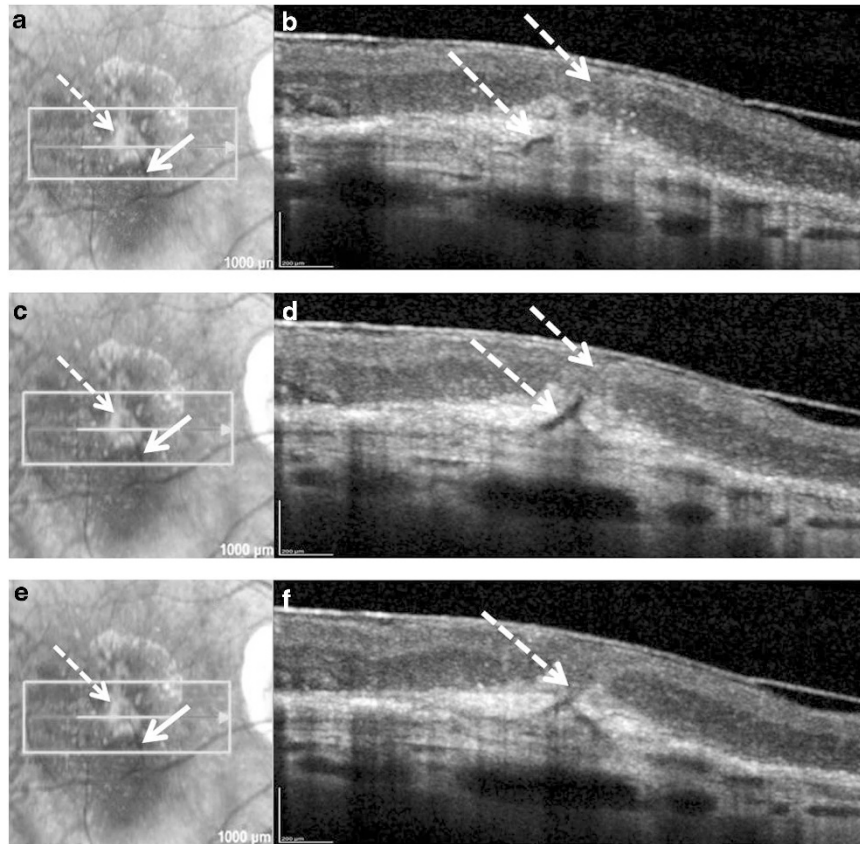Figure 3 The serial near-infrared and SD-OCT B-scan images (23 to 25/49) show an enlarged view of the area of interest. On near-infrared images (a, c, and e), the white dashed arrow points toward the scar tissue (white, bright lesion) and the white solid arrow points to the branch retinal arteriole that is seen penetrating the scar tissue. The white dashed arrows on the B-scans (b, d, and f) identify a retinochoroidal anastomotic vessel.

References

- 1 Yannuzzi LA, Negrão S, Iida T, Carvalho C, Rodriguez-Coleman H, Slakter J *et al*. Retinal angiomatous proliferation in age-related macular degeneration. *Retina* 2001; **21**(5): 416–434.
- 2 Troung SN, Alam S, Zawadzki RJ, Choi SS, Telander DG, Park SS *et al*. High resolution fourier-domain optical coherence tomography of retinal angiomatous proliferation. *Retina* 2007; **27**(7): 915–925.
- 3 Freund KB, Zweifel SA, Engelbert M. Do we need a new classification for choroidal neovascularization in age-related macular degeneration? *Retina* 2010; **30**(9): 1333–1349
- 4 Green WR, Gass JDM. Senile disciform degeneration of the macula. *Arch Ophthalmol* 1971; **86**: 487–494.

S Pilli¹, C O'Brien¹ and AJ Lotery^{1,2}

¹Department of Ophthalmology, University Hospital Southampton NHS Foundation Trust, Southampton, UK

²Academic Unit of Clinical and Experimental Sciences, Faculty of Medicine, University of Southampton, Southampton, UK

E-mail: a.j.lotery@soton.ac.uk

Meeting presentation: Amsler Club Meeting, London, 29 September 2012.

Eye (2013) **27**, 1105–1107; doi:10.1038/eye.2013.121; published online 21 June 2013

Sir, Congenital ptosis associated with combined superior rectus, lateral rectus, and levator palpebrae synkinesis: the first reported case

Superior rectus (SR) to levator palpebrae superioris (LPS) synkinesis has recently been described in patients with congenital or longstanding ptosis.^{1,2} However, aberrant innervation between lateral rectus (LR) and LPS has not been previously reported. We report a combined SR and LR to LPS synkinesis in a patient with congenital ptosis.

Case report

A 22-year-old man presented for ptosis assessment in his left eye. The ophthalmic history referred to a previous unsuccessful operation for correction of his unilateral, congenital ptosis. No history of squint or trauma was reported. His medical history was unremarkable.

The patient displayed a marked ptosis, more noticeable in the temporal half of upper lid. Ptosis assessment measurements were palpebral aperture (PA) = 7 mm, levator function (LF) (two-phase procedure as suggested by Jones and colleagues³): on primary position: phase 1 = 4 mm, phase 2 = 8 mm (total = 12 mm), abduction: phase 1 = 4 mm, phase 2 = 8 mm, while on adduction: phase 1 = 4 mm and phase 2 = 4 mm (total 8 mm). Skin crease height (SC) = 8 mm, symmetrical to contralateral eyelid. Bell's phenomenon was moderately weak, while 1–2 mm lagophthalmos was apparent. Cover test and eye movements were normal.

A complete resolve of ptosis was noted on up-gaze (PA = 11 mm) as well as on abduction (PA = 11.5 mm; Figure 1). Slit lamp examination was normal, while patient's visual acuity was 6/6 OU.

The patient underwent a large levator resection, as indicated in cases with simple SR to LPS synkinesis, with satisfactory results. The surgery resulted in 4 mm lagophthalmos, which progressively improved to 2–3 mm. At 4 weeks post-op, PA was 10.5 mm on primary, 14 mm on up-gaze, and 11.5 mm on abduction, while symmetry between fellow eyes was achieved. (Figure 2).

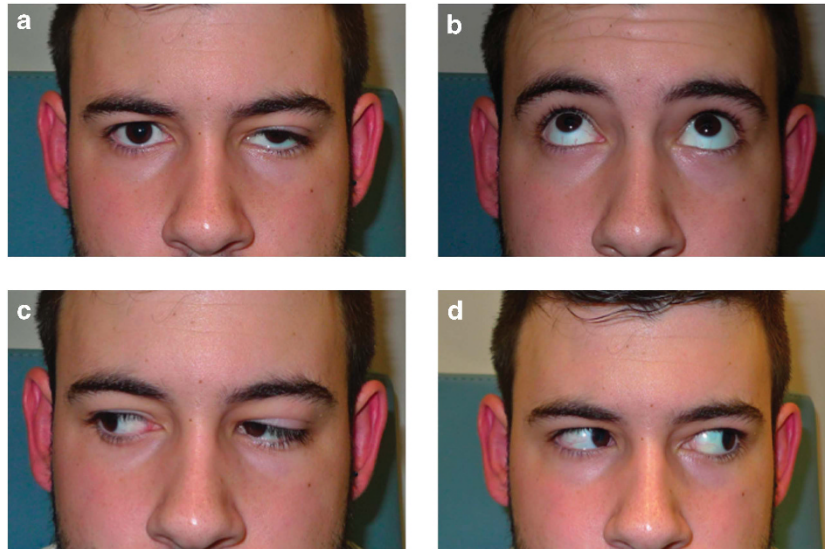


Figure 1 Pre-operative photographs depicting the eyelids on four positions of gaze: (a) primary: note the marked ptosis on left side, (b) up-gaze: complete resolve of ptosis is noted, (c) adduction: ptosis becomes apparent, and (d) abduction: complete resolve of ptosis.

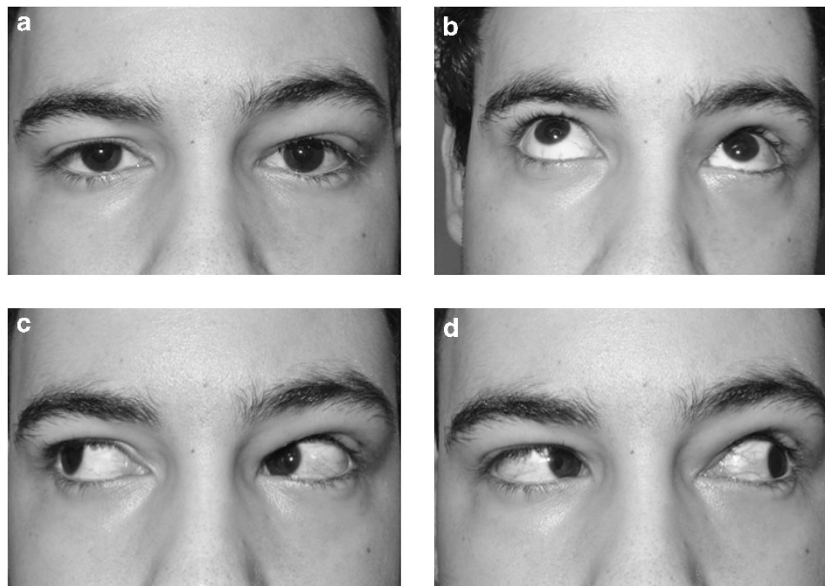


Figure 2 Early post-operative photographs on same four positions of gaze: (a) primary: successful ptosis correction is shown despite the post-op tissue oedema, (b) up-gaze: slight overcorrection of ptosis compared to fellow eye, (c) adduction: symmetrical elevation is noted, and (d) abduction: mild overcorrection is apparent.

Comment

Synkinetic innervation between muscles nerved by 3rd cranial nerve has been described as a result of acquired or congenital palsies. SR to LSP synkinesis is considered a poor prognostic factor affecting ptosis surgery and therefore a new method of ptosis assessment has been proposed.³ As the neurogenic dysfunction along the course of 3rd nerve seems to play a major role in LPS weakness, the phenomenon should always be sought in this group of patients and if apparent, a larger than usual LPS resection is recommended.¹

However, and to our knowledge, synkinesis between SR, LSP, and LR has never been reported. This pattern of aberrant innervation involves 3rd and 6th nerve simultaneously and represents an addition to the range of congenital cranial dysinnervation disorders.⁴

Conflict of interest

The authors declare no conflict of interest.

References

- 1 Harrad RA, Shuttleworth GN. Superior rectus-levator synkinesis: a previously unrecognized cause of failure of ptosis surgery. *Ophthalmology* 2000; **107**(11): 1975–1981.
- 2 McMullan TFW, Robinson DO, Tyers AG. Towards an understanding of congenital ptosis. *Orbit* 2006; **25**(3): 179–184.
- 3 Jones CA, Lee EJ, Sparrow JM, Harrad RA. Levator function revisited: a two-phase assessment of lid movement to better identify levator-superior rectus synkinesis. *Br J Ophthalmol* 2010; **94**(2): 229–232.
- 4 Oystrek DT, Engle E, Bosley TM. Recent progress in understanding congenital cranial dysinnervation disorders. *J Neuroophthalmol* 2011; **31**(1): 69–77.

NT Chalvatzis^{1,2}, AK Tzamalīs¹, N Ziakas³, G Kalantzis⁴, SA Dimitrakos¹ and RA Harrad²

¹Second Department of Ophthalmology, Aristotle University of Thessaloniki, Thessaloniki, Greece

²Bristol Eye Hospital, Bristol, UK

³First Department of Ophthalmology, Aristotle University of Thessaloniki, Thessaloniki, Greece

⁴Department of Ophthalmology, St. James University Hospital, Leeds, UK
E-mail: nikocha@hotmail.com

Eye (2013) **27**, 1107–1109; doi:10.1038/eye.2013.138;
published online 21 June 2013

Sir,
Subconjunctival anaesthesia for intravitreal injections

We read with interest the paper by Lyall *et al.*¹ who report the results of an observational study of infective endophthalmitis in the United Kingdom following intravitreal anti-VEGF injection.

Using 200 patients selected from 10 control centres, the authors identified 3 endophthalmitis patients, compared

to 1 control patient, who had received subconjunctival anaesthesia prior to intravitreal injection. Their conclusion that subconjunctival anaesthesia is a significant risk factor for developing infectious endophthalmitis, with an odds ratio of 13.7, was surprising to us. A subconjunctival fluid bleb serves to act as a mechanical barrier between the outside world and the vitreous cavity, and would thereby be expected to reduce the risk of a vitreous wick being exposed to conjunctival flora. To our knowledge, subconjunctival anaesthesia has not been identified as a risk factor for endophthalmitis by any other study. Furthermore, we note the very large confidence interval for the odds ratio (1.07–728.9); however, we recognise that this is a result of studying a rare complication such as post-injection endophthalmitis. We would be interested to know whether subconjunctival anaesthetic was the standard of care in the centres that treated the three patients who developed endophthalmitis, and whether these three patients had any other risk factors for endophthalmitis.

In the Medical Retina Unit in Southampton, subconjunctival anaesthesia with 2% lidocaine is standard practice for all patients receiving intravitreal injections. Of the 6000 anti-VEGF injections performed in our unit between January 2012 and December 2012, there have been four instances of post-injection endophthalmitis, representing an incidence of 0.07%, which is not significantly dissimilar from the overall incidence in this or other large studies.^{2,3} We are reluctant to change our clinical practice unless there is firm evidence against the use of subconjunctival anaesthesia.

Conflict of interest

The authors declare no conflict of interest.

References

- 1 Lyall DA, Tey A, Foot B, Roxburgh ST, Viridi M, Robertson C *et al.* Post-intravitreal anti-VEGF endophthalmitis in the United Kingdom: incidence, features, risk factors, and outcomes. *Eye (London, England)* 2012; **26**(12): 1517–1526.
- 2 Day S, Acquah K, Mruthyunjaya P, Grossman DS, Lee PP, Sloan FA. Ocular complications after anti-vascular endothelial growth factor therapy in Medicare patients with age-related macular degeneration. *Am J Ophthalmol* 2011; **152**(2): 266–272.
- 3 McCannel CA. Meta-analysis of endophthalmitis after intravitreal injection of anti-vascular endothelial growth factor agents: causative organisms and possible prevention strategies. *Retina (Philadelphia, PA)* 2011; **31**(4): 654–661.

P Alexander^{1,2}, D Sahu² and AJ Lotery^{1,2}

¹Faculty of Medicine, University of Southampton, Southampton, UK

²Department of Ophthalmology, University Hospital Southampton, Southampton, UK
E-mail: a.j.lotery@soton.ac.uk

Eye (2013) **27**, 1109; doi:10.1038/eye.2013.132;
published online 28 June 2013