

Comment

Madelung's disease is characterized by multiple non-encapsulated lipomas, which can enlarge significantly, resulting in dyspnea and dysphagia.² The etiology of the disease remains unknown, but an abnormal lipogenesis induced by catecholamines has been observed and is often associated with liver dysfunction due to alcoholism.³

Bilateral late-onset lipomatosis of the orbits also occurs in Graves' disease and has also been reported following prolonged administration of oral corticosteroids.⁴ Interestingly, the phenotype of orbital fibroblasts is distinct from pre-adipocyte fibroblasts elsewhere, and it is this characteristic that is thought to contribute to the selective involvement of the orbit in Graves' disease; yet, in Madelung's disease the orbit also appears to be a feature.⁵ Treatment is surgical removal of excess adipose tissue where it is affecting the aerodigestive tract, causing psychological distress and may now be extended to include compromising optic nerve function.

Conflict of interest

The authors declare no conflict of interest.

References

- 1 Parmar C, Blackburn C. Madelung's disease: an uncommon disorder of unknown aetiology? *Br J Oral Maxillofac Surg* 1996; **34**: 467–470.
- 2 Fonseca VA, Alves C, Marques H, Camacho E, Saraiva AP. Madelung's disease as a rare cause of obstructive sleep apnea. *J Bras Pneum* 2009; **35**: 1053–1056.
- 3 González-García R, Rodríguez-Campo FJ, Sastre-Pérez J, Muñoz-Guerra MF. Benign symmetric lipomatosis (Madelung's disease): case reports and current management. *Aesthetic Plast Surg*. 2004; **28**: 108–112.
- 4 Humblot S, Weber JC, Korganow AS, Hammann B, Pasquali JL, Martin T. Lipomatosis induced by corticosteroid therapy. *Rev Med Interne* 1997; **18**: 396–401.
- 5 Smith TJ, Koumas L, Gagnon A, Bell A, Sempowski GD, Phipps RP *et al*. Orbital fibroblast heterogeneity may determine the clinical presentation of thyroid-associated ophthalmopathy. *J Clin Endocrinol Metab* 2002; **87**: 385–392.

M Subash, A Aziz, M O'Doherty and JM Olver

¹Ophthalmology Department, Charing Cross Hospital, Fulham Palace Road, London, UK

²Adnexal Department, Western Eye Hospital, London, UK.

E-mail: Malavika.subash01@gmail.com

Eye (2012) **26**, 894–895; doi:10.1038/eye.2012.56; published online 13 April 2012

Sir,

Recurrent giant orbital apocrine hidrocystoma

We report a case of recurrent giant hidrocystoma that demonstrates the importance of intact excision of these lesions.

Case report

A healthy 46-year-old woman with a few months history of painless swelling of the right lower lid. There was no history of impaired vision, diplopia, watering, discharge, or prior trauma. Ophthalmological examination revealed a soft, non-reducible, medial lower-lid swelling with normal overlying skin. The eye was displaced superiorly and laterally. Valsalva test was negative and ocular motility was full. An orbital CT scan showed a large, cystic mass of about 18-mm diameter occupying the infero-nasal orbital quadrant. Surgical excision via conjunctival approach revealed a very thin-walled cystic mass that ruptured during the procedure with the release of clear fluid. The histopathological examination of remnants of cyst wall was inconclusive.

The patient represented 2 years later with a recurrence of the cyst, width 17.5-mm diameter on MRI scan (Figure 1), abutting the globe in the right inferior medial orbit similarly to that seen previously. The cyst was excised intact. Histopathological analysis revealed a benign apocrine hidrocystoma. No further recurrence of the lesion was seen on repeat MRI at 6-months follow-up.

Comment

Hidrocystomas are benign sweat-gland tumours that are usually small and are typically found in the head and neck region, especially the eyelid, but other locations including the chest, axilla, palms, and penis have been described.¹ Histologically, two types of hidrocystoma, eccrine, and apocrine are recognised reflecting the cells of origin. Spontaneous orbital apocrine hidrocystoma has been reported only once,² a 10-mm cyst located beneath the orbital roof. Giant hidrocystomas are very unusual, the largest reported by Laktaoui *et al.*³ being a 2-cm eccrine cyst on the eyelid.

The pathophysiology of hidrocystomas is uncertain. It has been hypothesised that sequestration of epithelial cells at the embryonic stage could lead to the condition.⁴ Bone remodelling or orbital enlargement is often present in long-standing lesions of the orbit but these features were absent in our patient. Traumatic implantation of epithelial cells into deeper tissues, including the orbit,⁵ has also been described but a history of trauma was absent in our patient.

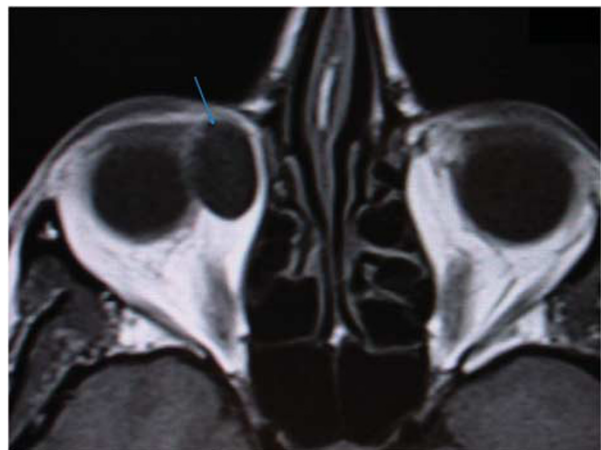


Figure 1 Orbital MRI Scan. Arrow shows a giant hidrocystoma (17.5-mm diameter) abutting the eyeball medially in the orbit.

As this case demonstrates, intact excision may be challenging due to the very thin cyst wall but is necessary to avoid recurrence.

Conflict of interest

The authors declare no conflict of interest.

References

- 1 Obaidat NA, Ghazarian DM. Bilateral multiple axillary apocrine hidrocystomas associated with benign apocrine hyperplasia. *J Clin Pathol* 2006; **59**(7): 779.
- 2 Vignes JR, Franco-Vidal V, Eimer S, Liguoro D. Intraorbital apocrine hidrocystoma. *Clin Neurol Neurosurg* 2007; **109**(7): 631–633.
- 3 Laktaoui A, Kriet M, Bouia Y, Louaya S, Zrara I, Fiqhi A *et al.* Giant apocrine hidrocystoma of the internal canthus. *J Fr Ophthalmol* 2011; **34**(2): 91–94.
- 4 Haider E, Saigal G, Gill D, Brown E, Daniel S. Congenital orbital sudoriferous cyst: radiological findings. *Pediatr Radiol* 2005; **35**(11): 1142–1144.
- 5 Mehta A, Rao A, Khanna A. Sudoriferous cyst of the orbit of adult origin after trauma. *Indian J Ophthalmol* 2008; **56**(3): 235–237.

IC Ssi-Yan-Kai¹ and AR Pearson^{1,2}

¹Department of Eye, Royal Berkshire Hospital, NHS Foundation Trust, Reading, UK

²Prince Charles Eye Unit, King Edward VII Hospital, Windsor, UK

E-mail: isabellessiyankai@yahoo.fr

Eye (2012) **26**, 895–896; doi:10.1038/eye.2012.57;
published online 13 April 2012