Eye (2012) 26, 1585–1601

www.nature.com/eye

Sir,

Characteristics of segmental optic nerve hypoplasia

The optic disc is prone to various congenital anomalies, among which, segmental optic disc anomaly can be shown in superior segmental optic hypoplasia, an optic pit, and an optic coloboma. Here, we present a case of segmental optic nerve hypoplasia with detail descriptions.

Case report

A 32-year-old woman presented with an inferior visual field defect. Her best-corrected visual acuity was 0.8 in the right eye and 0.3 in the left eye. Manifest refraction was sph. -0.75 cyl $+0.50$ axis 5 in the right eye and sph. -0.75 cyl $+0.25$ axis 180 in the left eye. Intraocular pressure in both the eyes was 15 mmHg. Anterior segments, including the cornea, iris, and lens, were normal in both eyes, and the right optic disc showed normal findings. Fundus photography revealed a segmental defect in the superotemporal quadrant of the left optic disc (Figure 1a). Fluorescein angiography revealed no leakage around the optic disc and showed normal vasculature, except for the absence of microvasculature around the segmental optic disc defect (Figure 1b). Optical coherence tomography (Cirrus HD-OCT, Carl Zeiss, Jena, Germany) showed that the retinal nerve fiber layer in the right eye was normal; however, the thickness of RNFL was decreased in the 10 o'clock to 2 o'clock region in the left eye. Humphrey's visual field analysis showed an inferior altitudinal defect, which corresponded well with RNFL loss (Figures 2a and b).

Comment

Skarf and Hoyt[1] classified optic nerve hypoplasia (ONH) into three groups. Group 1 consisted of patients with bilateral ONH, poor vision, and nystagmus. Group 2 comprised patients with bilateral segmental ONH and moderate to good vision. Recently, patients with superior segmental ONH with bilateral 'topless' discs were included in Group 2; inferior field cuts and normal visual acuity are detected in a unique form of segmental ONH that is distinguishable because of its association with maternal diabetes.[2] Group 3 comprised patients with isolated unilateral ONH, as in the present case. Hoyt *et al*[3] reported another case of typical ONH, in which chiasmal hemioptic hypoplasia produced focal loss of the nasal and temporal nerve fiber layer; the chiasmal hemioptic hypoplasia was distinguishable owing to its association with unilateral lesions of the optic radiations. In conclusion, the present case is the rare form of ONH, presenting as unilateral segmental ONH with decreased visual acuity.

Conflict of interest

The authors declare no conflict of interest.

References

1 Skarf B, Hoyt CS. Optic nerve hypoplasia in children. *Arch Ophthalmol* 1984; **102**: 62–67.
2 Kim RY, Hoyt WF, Lessell S, Narahara MH. Superior segmental optic hypoplasia. A sign of maternal diabetes. *Arch Ophthalmol* 1989; **107**: 1312–1315.
3 Hoyt WF, Rios-Montenegro EN, Behrens MM, Eckelhoff RJ. Homonymous hemioptic hypoplasia. Fundoscopic features in standard and red-free illumination in three patients with congenital hemiplegia. *Br J Ophthalmol* 1972; **56**: 537–545.

US Kim[1], S-H Baek[1] and JH Lee[2]

[1]Department of Ophthalmology, Kim's Eye Hospital, Konyang University College of Medicine, Seoul, Korea
[2]Myung-Gok Eye Research Institute, Konyang University College of Medicine, Seoul, Korea
E-mail: ungsookim@kimeye.com

Eye (2012) **26,** 1585–1586; doi:10.1038/eye.2012.208; published online 12 October 2012

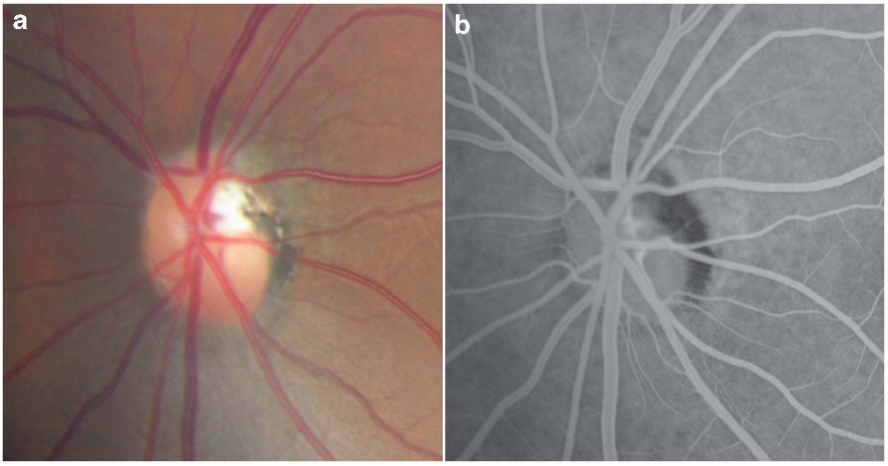

Figure 1 Optic disc photography. (a) A quarter of the segmental defect is shown in the superotemporal quadrant of the left optic disc. Peripapillary pigmentation is noted and retinal vasculature emerges from the center of the disc. (b) Fluorescein angiography revealed no leakage and no vasculature around the disc defect area.

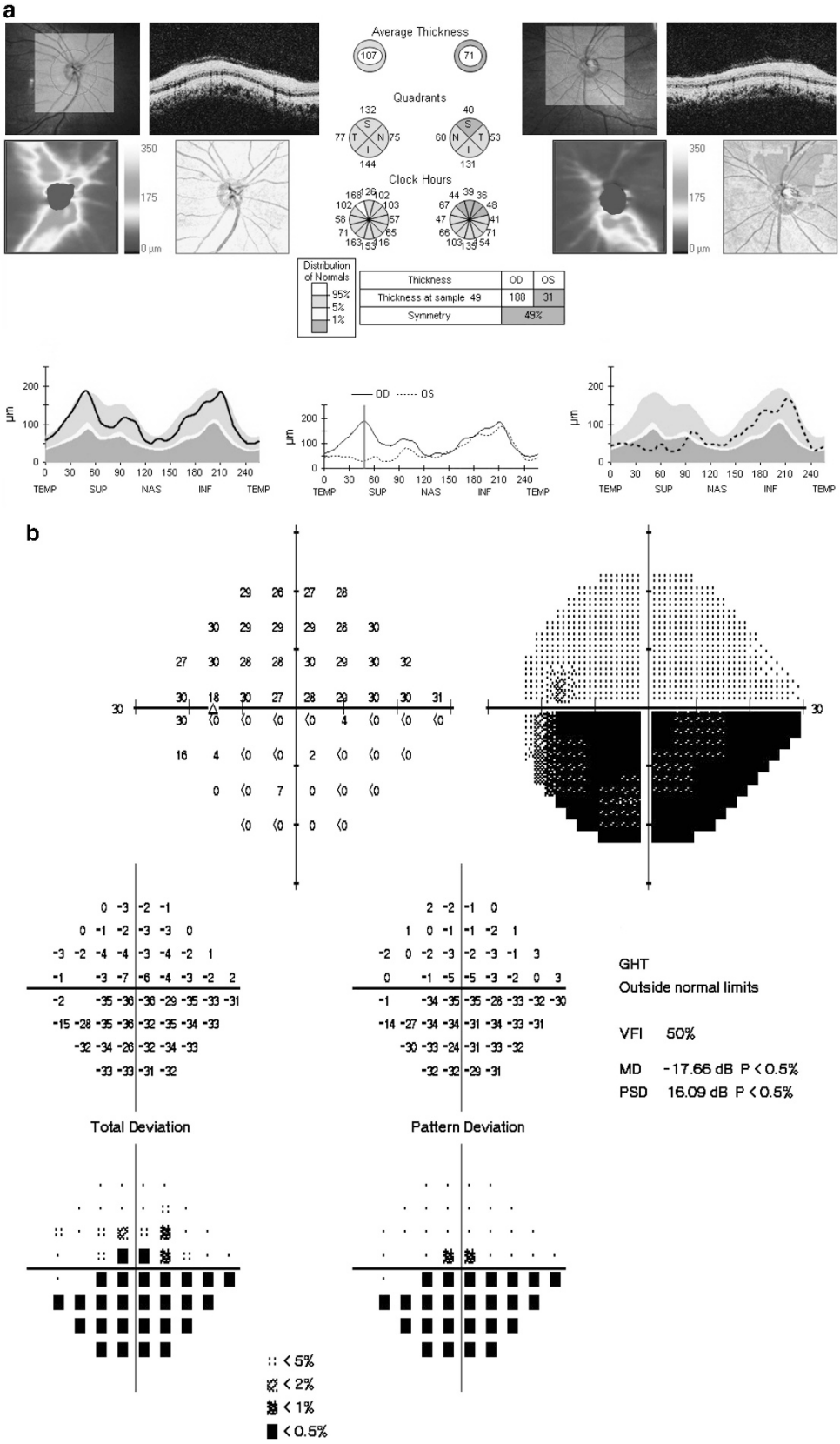

Figure 2 (a) Using optical coherence tomography, the RNFL defect is noted from 10 to 2 o'clock in the left optic disc. (b) A visual field test shows that the altitudinal inferior visual field defect corresponds well with the RNFL defect in the left eye.