

after pars plana vitrectomy (PPV) that included ILM peeling using a diamond scraper. The diamond particles had no effect on visual acuity or the visual field on short-term follow-up.

We performed a PPV with ILM peeling to treat a patient with full-thickness macular hole. A Tano Diamond-Dusted Membrane Scraper (Synergetics Inc., O'Fallon, MO, USA) was used to create an ILM edge before peeling. No complications were experienced during surgery. After 1 month, two highly reflective diamond particles were observed in the macular area. Best-corrected visual acuity (logMAR) was 0.1 and this was maintained until 1 year of follow-up. The diamond particles were still evident, but no morphological change of the macula was noted. Time domain (TD) optical coherence tomography (Stratus OCT, Carl Zeiss Meditec Inc., Dublin, CA, USA) did not detect the diamond particles, but spectral domain (SD) OCT (Spectralis OCT, Heidelberg Engineering, Carlsbad, CA, USA) revealed intraretinal particles, which were thus not on the retinal surface (Figure 1).

Thus, SD OCT could detect the highly reflective diamond particles, and their locations were confirmed by high-resolution imaging. TD OCT could not detect the particles because images were of low resolution. Diamond particles released during surgery should certainly be removed, but this may be difficult because of their small size. Although the particles remained within the retina, no effect on any of visual acuity, visual field, or retinal structure was evident up to 1 postoperative year. To the best of our knowledge, no SD OCT images of diamond particles or long-term follow-up data from a patient carrying such particles have been reported. In conclusion, SD OCT could detect small diamond particles in the retina, but no visual problem was noted at the 1-year follow-up.

#### Conflict of interest

The authors declare no conflict of interest.

#### References

- 1 Khun F, Mester V, Berta A. The Tano diamond dusted membrane scraper: indications and contraindications. *Acta Ophthalmol Scand* 1998; **76**: 754–759.
- 2 Tolentino F, Wu G. Diamond-dusted microspatula tips for vitreoretinal surgery. *Arch Ophthalmol* 1987; **105**: 1732–1733.
- 3 Gupta D, Goldsmith C. Iatrogenic retina diamond deposits: an unusual complication of using the diamond-dusted membrane scraper. *Eye* 2009; **23**: 1751–1752.

SW Bae, DK Choi and JB Chae

Department of Ophthalmology, College of Medicine, Chungbuk National University, Cheongju, Korea  
E-mail: jbachae@chungbuk.ac.kr

*Eye* (2011) **25**, 1518–1519; doi:10.1038/eye.2011.204;  
published online 19 August 2011

#### Sir, Tuberculoma of the choroid masquerading as a choroidal melanoma

We read with great interest the paper by Sanghvi *et al*<sup>1</sup> and would like to commend the authors for a well-presented case series of presumed tuberculous uveitis. However, in their series of 27 patients, no cases of choroidal tuberculoma were presented. All cases of tuberculosis-related uveitis seen in the Ocular Oncology Service are associated with choroidal tuberculoma as it masquerades as choroidal melanoma<sup>2</sup> We present one such case.

#### Case report

A 24-year-old Indian man with active miliary tuberculosis presented with a hyperemic amblyopic right eye. He had started standard quadruple anti-tuberculosis therapy (ATT),<sup>3</sup> but could not tolerate pyrazinamide. After 10 days, he stopped all treatment.

Best-corrected visual acuity was 6/24 OD. The anterior chamber had 4+ cells and fine keratic precipitates. Intraocular pressures were normal. An amelanotic choroidal mass with associated bullous retinal detachment was seen superotemporally to the fovea (Figure 1a and b). B-mode ultrasound scan revealed a lesion of low internal reflectivity with internal blood flow, measuring 11.5 × 18.2 mm with a height of 7.6 mm (Figure 1c).

Two hourly g. Maxidex and g Cyclopentolate bd were commenced. A contrast-enhanced MRI of the brain and spinal cord indicated the presence of tuberculomas in the right parietal and occipital lobes. The patient was immediately started on ATT CNS protocol treatment, ethambutol, rifampicin, isoniazide, and prothionamide for a year.<sup>3</sup> After 2 months, the choroidal mass height reduced to 1.9 mm (Figure 1d). A repeated MRI indicated regression of the occipital lesion, and no new infiltrations.

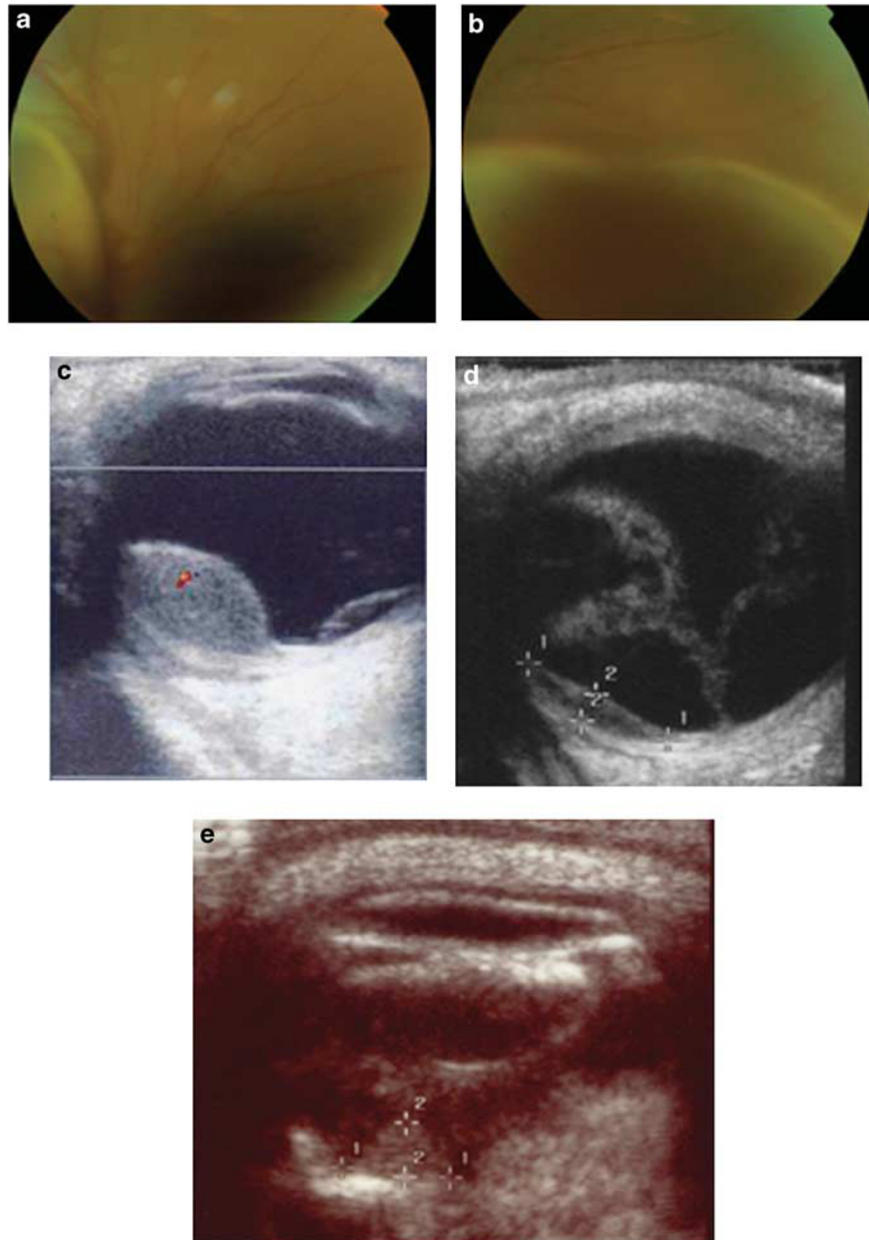
One year later, visual acuity was hand motions due to a white cataract. Intraocular inflammation had resolved, but the eye was hypotonic. The cerebral and choroidal tuberculomas were not active. B-mode ultrasound showed extension of the retinal detachment; however, the tuberculoma was inert, calcified with no change in height (Figure 1e). No systemic toxicity developed.

#### Comment

There is a very strong association with choroidal tuberculoma and CNS tuberculosis. These patients require an urgent MRI of the brain and spine to search for a neurologically debilitating or life threatening mass lesion. Miliary TB is typically treated with only 6 months of anti-TB medication, whereas the CNS treatment protocol is for 12 months.<sup>3</sup>

#### Conflict of interest

The authors declare no conflict of interest.



**Figure 1** Fundus photographs and B mode ultrasound scans. (a–c) Initial presentation. Extensive bullous retinal detachment extending temporally and inferonasally (a, b). Elevated lesion (7.6 mm) with low internal reflectivity and associated retinal detachment (c). Two months after ATT treatment (d). Height of lesion reduced to 1.9 mm and extensive retinal detachment. One year after ATT treatment: lesion height at 1.9 mm with associated calcification (e).

**References**

- 1 Sanghvi C, Bell C, Woodhead M, Hardy C, Jones N. Presumed tuberculous uveitis: diagnosis, management, and outcome. *Eye (Lond)* 2011; **25**(4): 475–480.
- 2 Demirci H, Shields CL, Shields JA, Eagle Jr RC. Ocular tuberculosis masquerading as ocular tumors. *Surv Ophthalmol* 2004; **49**(1): 78–89.
- 3 NICE guidelines. CG117 Tuberculosis. Available at <http://guidance.nice.org.uk/CG117>.

VP Papastefanou<sup>1,2</sup> and VM Cohen<sup>1,2</sup>

<sup>1</sup>Ocular Oncology Service, Moorfields Eye Hospital, London, UK

<sup>2</sup>Ocular Oncology Service, St Bartholomew's Hospital, London, UK

E-mail: [Vasilios.Papastefanou@moorfields.nhs.uk](mailto:Vasilios.Papastefanou@moorfields.nhs.uk)

*Eye* (2011) **25**, 1519–1520; doi:10.1038/eye.2011.205;

published online 19 August 2011