Eye (2011) 25, 331–341

www.nature.com/eye

RCOphth EPONYMOUS LECTURE

The Optic UK Lecture: bench-to-bedside adventures of a diabetes researcher: results past, results present

RN Frank

Abstract

This presentation covers two topics. First is a basic laboratory study, designed to explore the mechanism for the phenomenon of 'early worsening,' in which individuals with type 1 diabetes and early to moderate retinopathy are rapidly placed on 'tight' blood glucose control, after which about 10% of these individuals develop a worsening of retinopathy with the appearance of multiple 'cotton wool' spots. Our studies on cultured retinal cells used vascular endothelial growth factor (VEGF) production as an index of cellular ischaemia. VEGF production increases substantially when cells are cultured in low oxygen, but VEGF production in these hypoxic cultures decreases when the medium contains a fivefold excess glucose concentration. Cultures with no medium glucose also show increased VEGF production. In the clinical situation, we infer from these results that retinas with early retinopathy have a reduced blood supply and are therefore relatively ischaemic, thus increasing their VEGF production. Adding glucose provides an alternative energy supply, thus reducing the demand for VEGF and hence, reducing the likelihood of 'early worsening.' However, reducing the glucose supply to these already compromised retinas further increases their ischaemia and, therefore, the stimulus to produce more VEGF. The second part of this presentation is a clinical exploration of possible reasons for the frequent, wide discrepancy between measured central macular thickness by optical coherence tomography (OCT) and visual acuity in eyes with diabetic macular oedema. I explore the influence of different diseases in which macular oedema appears, the presence or absence, and size, of cystoid cavities; duration of the oedema; age of the subject, different anatomic derangements including epiretinal membranes and disruptions of the photoreceptor layer, and various biochemical and physiological mechanisms.
Eye (2011) **25,** 331–341; doi:10.1038/eye.2010.195; published online 7 January 2011

Keywords: diabetic retinopathy; vascular endothelial growth factor; macular oedema; retinal cell culture; optical coherence tomography; visual acuity

My professional career has been somewhat bifurcated, between basic laboratory investigations and clinical practice combined with clinical research. My interest in retinal and choroidal vascular disease, and in particular, diabetic retinopathy has been longstanding. In this presentation, I will discuss a basic laboratory study that was performed several years ago, but has only recently been published in the peer-reviewed literature, as well as some currently ongoing clinical investigations. Each of these studies deal with attempts to explain clinical observations that seem paradoxical, and which struck me as true mysteries. The first of these was the observation that 'tight control' of blood sugar in type 1 diabetes in an effort to prevent development or worsening of diabetic retinopathy may, instead, pardoxically lead to worsening in a small percentage of cases.[1] Second, that although swelling of the macular retina in disease would seem most likely to make visual acuity worse and reduction of that swelling would make the vision better, this has proved true only in the broadest sense, as plots of visual acuity *vs* central macular thickness, measured by spectral domain optical coherence tomography (SD-OCT) showed a very wide

The Kresge Eye Institute, Wayne State University School of Medicine, Detroit, MI, USA

Correspondence: RN Frank, Kresge Eye Institute, Wayne State University School of Medicine, 4717 Saint Antoine Street, Detroit, MI 48201, USA
Tel: +1 313 577 7613; Fax: +1 313 577 8884.
E-mail: rnfrank@med.wayne.edu

Received: 4 November 2010
Accepted in revised form: 15 November 2010
Published online: 7 January 2011

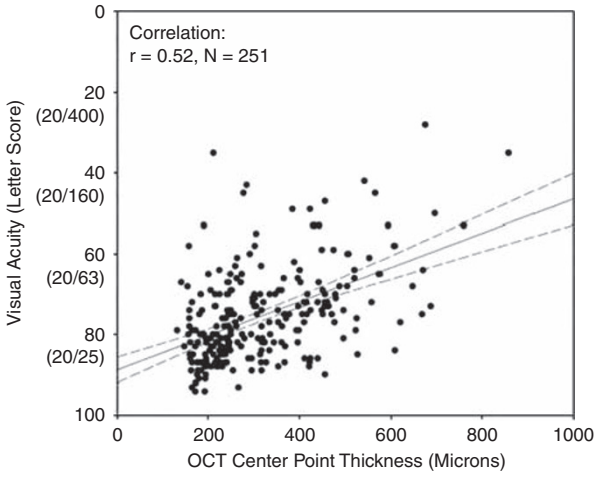

Figure 1 Macular center point thickness, measured by time-domain optical coherence tomography, against best-corrected visual acuity (number of letters read on the Early Treatment Diabetic Retinopathy Study, or ETDRS, chart; five letters equal one chart line with comparable Snellen visual acuity in parentheses). The best-fitting linear plot is shown, with 95% confidence interval shown by the surrounding dashed lines. Although the r-value indicates a significant linear relationship, note the wide scatter of the points. From the Diabetic Retinopathy Clinical Research Network.[2] With permission from the Editor of *Ophthalmology* and the DRCR.net Coordinating Center.

scatter of the data points around the best fitting straight line (Figure 1).[2]

The mystery of 'Early worsening'

During the Diabetes Control and Complications Trial (DCCT), a large, randomized, controlled clinical trial to determine the potential benefit of 'tight' blood glucose control on the development and progression of retinopathy, and other complications in individuals with type 1 diabetes, it was unexpectedly noted that about 10% of subjects who had early to moderate retinopathy at the outset and were randomized to the 'tight' glucose control arm developed worsening of their retinopathy compared with individuals in the 'standard' glucose control arm.[1,3] This 'early worsening' consisted primarily of a marked increase in 'cotton wool' spots, indicating retinal ischaemia, and it resolved within 2–3 years, after which retinopathy in the subjects in the 'tight' control group did consistently better than the 'standard' control subjects. Similar 'early worsening' had been noted in two earlier and smaller clinical trials.[4,5]

Several explanations have been offered for 'early worsening.' The most prominent has been that rapid imposition of 'tight' blood glucose control in type 1 diabetics initiates an outpouring of insulin-like growth factor-1 (IGF-1), which can initiate the 'worsening.'[6] However, extensive studies show that IGF-1 is a molecule that simply facilitates retinal neovascularization, but does not itself cause it,[7] and, moreover, IGF-1 most certainly doesn't increase retinal ischaemia, which may result in a multitude of 'cotton wool spots,' but not retinal neovascularization. A clinical trial that used exogenous doses of IGF-1, along with insulin, in an effort to improve blood glucose control and eliminate large blood glucose fluctuations in type 1 diabetic subjects, resulted in several cases of 'diabetic papillopathy,' with swelling of the optic nerve head and dilated vessels on the nerve head, which resembled new blood vessels, but regressed when the IGF-1 dosing was stopped.[8,9]

Working with various types of cultured cells from human and bovine retinas, we made a series of observations that we believe provide a more cogent explanation for this clinical observation. A detailed presentation of these experiments is forthcoming,[10] and I present them here, in summary form.

Vascular endothelial growth factor (VEGF) A appears to be the major agent producing neovascularization as well as breakdown of the blood-retinal barrier in retinal and choroidal diseases, including diabetic retinopathy.[11,12] Although there are many potential stimuli for increased secretion of VEGF, a major such stimulus in the retina appears to be hypoxia[13] in this metabolically highly active neural tissue. We chose, therefore, to measure VEGF production in our cultured retinal cells as a measure of the hypoxic, or more broadly, the metabolic stimulus to which the cells were exposed.

When we cultured a variety of retinal cell types in medium containing a glucose concentration that is normal in human blood (100 mg/dl or 5 mM) and then put them in a very low (1%) oxygen atmosphere, we observed, as have numerous investigators, that VEGF protein or, as shown (Figure 2), VEGF mRNA production increased greatly. When we cultured cells in room air (20% O_2), but with a fivefold excess of glucose (500 mg/dl, that is, 25 mM), VEGF production was unchanged from that in normal glucose medium, but the hypoxic stimulus to VEGF production was greatly reduced. Substituting galactose, another hexose that is metabolized by cells incompletely and through a different pathway than glycolysis and the citric acid cycle, did not abolish the hypoxic stimulus to VEGF production (Figure 2). Finally, when we cultured the cells in room air, but with no glucose in the medium, VEGF production increased greatly compared with that in 5 mM glucose medium, but there was minimal further increment when culture with no glucose was carried out in a 1% O_2 atmosphere (Figure 3).

These results explain 'early worsening' as follows. The retinas of type 1 diabetic subjects with mild to moderate retinopathy have clearly suffered vascular damage, with

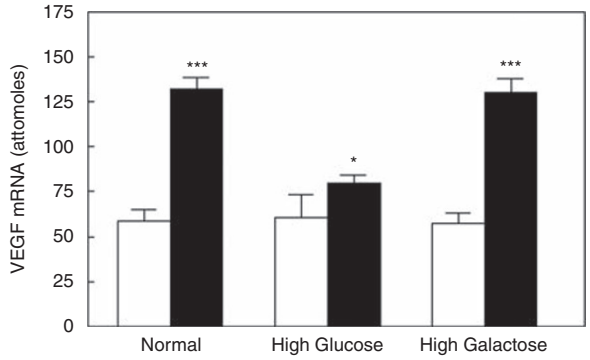

Figure 2 Measurement of VEGF mRNA levels in cultures of bovine retinal pigment epithelial cells in normoxia (room air) or low (1%) oxygen, and in culture medium containing either normal (5 mM) or high (25 mM) D-glucose, or 5 mM D-glucose together with 20 mM D-galactose. Note that in medium containing normal glucose levels, either with or without high galactose, culture in an hypoxic atmosphere stimulates substantially greater production of VEGF, but in the presence of a fivefold excess of glucose, VEGF production in hypoxia is much less. The plots show means ± 1 SD of four determinations, each averaged from duplicate cultures. The open bars indicate cells cultured in room air (normoxia). The filled bars indicate cells cultured in 1% oxygen (hypoxia). * = differs from normoxic cultures, $P<0.05$. *** = differs from normoxic cultures, $P<0.0001$. From Kennedy and Frank.[10] By permission of the editor and publisher.

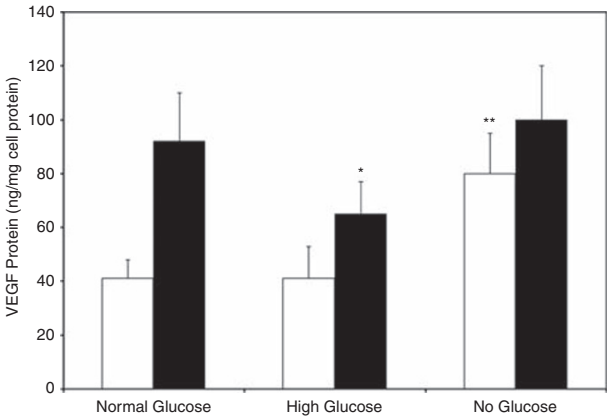

Figure 3 VEGF protein production in cultures of human retinal pigment epithelial cells in room air (normoxia) or in 1% oxygen (hypoxia), with the culture medium containing either normal (5 mM) glucose, high (25 mM) glucose, or no glucose. As in Figure 2, the hypoxic stimulus to VEGF production is reduced in the presence of a fivefold excess of glucose, although VEGF production in normoxia increases substantially when no glucose is present, with only a much smaller increment added in hypoxia. The plots show means ± 1 SD of four determinations, each averaged from duplicate cultures. The open bars represent cultures in room air (normoxia). The filled bars represent cultures in 1% oxygen (hypoxia). *$P<0.05$ compared to other hypoxic cultures. **$P<0.05$ compared to other normoxic cultures. From Kennedy and Frank.[10] By permission of the editor and publishers.

Table 1 Some possible reasons for the divergence between visual acuity and macular thickness in macular oedema from diverse causes

1. Cystoid *vs* non-cystoid macular oedema
2. Different diseases = different pathophysiology for the oedema
3. Differences in disease duration
4. Differences in patient age
5. Anatomic disturbances
6. Physiological and biochemical abnormalities

reduced blood flow and resultant hypoxia, at least in certain regions of the retina. However, severe tissue damage is delayed by the chronic hyperglycemic state, with the elevated glucose level serving as a major energy source partially offsetting the hypoxia. This is analogous to our cultures in low oxygen atmospheres, but high glucose media. In the diabetic retina in this situation, a sudden, drastic decrease in blood glucose through the imposition of a 'tight control' regimen, removes this metabolic 'safety cushion' and leads to hypoxic tissue damage.

The mystery of macular oedema

Macular oedema, which occurs in many diseases, is a mystery because, although a principal goal of all treatment paradigms has been to reduce the macular thickening, this does not always produce the visual improvement that one would hope. Accurate, quantitative measurement of macular thickening has been achieved in recent years by OCT. A notable result was reported very recently by the Diabetic Retinopathy Clinical Research Network (DRCR.net), a large consortium of academic and private practice retinal specialty groups in the United States, supported by the US National Eye Institute. In an early trial of two different protocols for applying argon laser treatment for diabetic macular oedema, the DRCR.net used OCT-determined macular thickness as one measure of efficacy.[2] A plot of baseline macular thickness, measured using the earlier, time-domain OCT machine against logMAR visual acuity (Figure 1) demonstrates the mystery. Although a trend is evident, indicated by the best-fitting straight line, showing a linear correlation between visual acuity and macular thickness, it is also clear that the data points show a very large degree of scatter. Visual acuity and macular thickness correlate roughly, but far from precisely. What factors account for the wide divergence from perfect linearity? In Table 1, I have listed some possibilities, which I will now discuss in more detail.

Cystoid vs non-cystoid macular oedema

A priori, one would think that the presence of cystoid spaces within the cellular layers of the neural retina

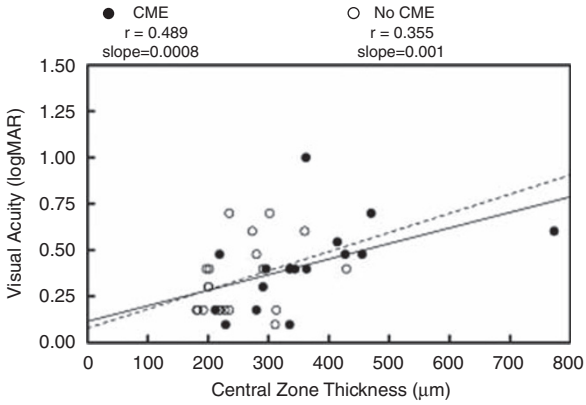

Figure 4 A plot, similar to Figure 1, but indicating the relationship of average thickness of the 1-mm diameter central zone of time-domain OCT measurements *vs* logMAR visual acuity from a series of patients with diabetic macular oedema at our own institution, in which cystoid spaces either were (filled circles) or were not (open circles) present. The best fitting straight lines through each set of points have very nearly the same slopes, and do not differ significantly from each other.

would substantially compromise visual acuity, because the presence of cystoid oedema is an indicator of more serious physiologic disturbance within the retinal neurons, or simply because these spaces can produce optical distortion of the image. In a recent paper, Deak *et al*[14] reported that in a series of 26 patients with diabetic macular oedema, large intraretinal cystoid spaces and subretinal fluid were the major contributors to visual dysfunction, whereas smaller cystoid spaces were not. However, in a retrospective analysis of a series of patients with diabetic macular oedema who were followed by my colleagues and I at the Kresge Eye Institute and whose retinal imaging records had been collected between 2002 and 2007, Drs Ahmad Aref, Michael Mequio and I found that plots of best-corrected logMAR visual acuity against average thickness of the central 1 mm macular zone measured with the Zeiss-Humphrey Stratus (Carl Zeiss Meditec, Dublin, CA, USA) time-domain optic coherence tomograph (OCT) showed virtually no difference in the linear plots that best fit the data points for patients who had cystoid changes on OCT compared with those who did not (Figure 4).

Different diseases mean different mechanisms for cystoid macular oedema

In another retrospective analysis of patients from the same image set, Drs Aref, Mequio and I compared best-corrected visual acuity (here, given as a decimal fraction rather than as the logMAR figure) with the mean thickness of the macular center 1 mm zone using time-domain OCT, in patients with diabetic macular

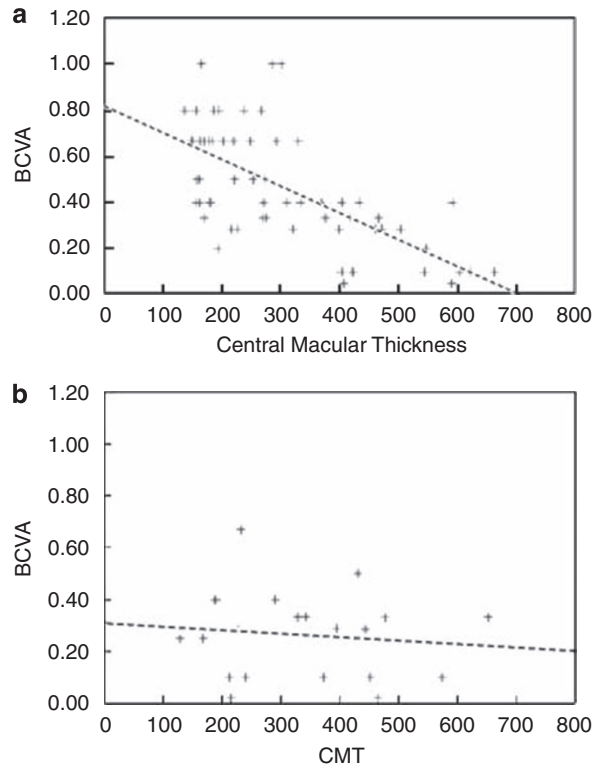

Figure 5 (a) Best-corrected visual acuity (BCVA), plotted here as a decimal fraction (for example, $20/40 = 0.5$) *vs* central macular 1 mm zone thickness (CMT), determined by time-domain OCT, for patients with diabetic macular oedema. (b) A similar plot for non-diabetic patients with pseudophakic cystoid macular oedema. The slopes of the best-corrected straight line through the data points (by least-squares analysis) differ significantly for the disease entities depicted in the two parts of this figure.

oedema and in those with pseudophakic cystoid macular oedema, the so-called Irvine–Gass syndrome (Figures 5a and b). Listed on these plots are the r-values for the best-fitting straight lines, and the *P*-values denoting the significance of the difference between that line and a line of zero slope. The best-fitting straight line for the diabetic macular oedema patients shows a steep slope that differs significantly from zero, whereas the line for the patients with pseudophakic cystoid macular oedema has a shallow slope that does not differ significantly from zero. The processes that produce macular oedema in these two entities, therefore, have different effects on visual function.

Duration of macular oedema

It is reasonable to expect that the persistence of a pathological process that causes macular oedema would eventually lead to deterioration of visual function. For different entities that produce macular oedema, this might not be so easy to determine. Certainly, for

pseudophakic cystoid macular oedema, where the date of cataract surgery is known, or for macular oedema following a retinal vein occlusion, where the onset is acute, the duration is relatively easy to determine. However, for diabetic macular oedema, whose onset may be gradual, determination of the onset by the duration of symptoms alone may be very difficult. Gangnon *et al*[15] and Davis *et al*[16] determined duration of macular oedema in diabetic patients with very long follow up and careful photographic documentation and suggested that macular oedema of longer duration does have a deleterious effect on visual function. We determined duration more crudely, by simple history taking of the onset of loss of vision in a series of diabetic patients. Although these histories could be considered only approximate, we could estimate fairly well the effect of macular oedema duration on the relationship of visual acuity to macular thickness by dividing our duration data into quartiles (Figures 6a–d). All of these plots showed the same wide scatter of the individual data points, but all were fit by straight lines whose slopes differed highly significantly from a line of zero slope, but did not differ significantly from each other. To a fair approximation, these plots suggest that the relationship of visual acuity to central 1-mm diameter zone macular thickness and vision does not vary significantly with oedema duration. Although our estimation of the duration of macular oedema is less precise than that of Gangnon *et al*,[15] our determination of the quantitative degree of the oedema is more exact than theirs, as we used OCT measurements, whereas theirs used estimates from stereoscopic photographic pairs.

Effect of patient age

Macular oedema may occur in patients of different ages throughout adult life. Age alters many body tissues and biological processes. Might it also change the effect of macular oedema on visual function? Again, our data indicate that this may not be the case (Figure 7), as the slopes of the central macular thickness *vs* visual acuity curves do not differ significantly from one another, although all differ significantly from a line of zero slope.

Anatomic disturbances

A variety of abnormalities of the macular anatomy, well seen by OCT, may produce decreases of visual acuity.

Epiretinal membranes producing traction on the central retina may worsen macular oedema and may prevent its regression when laser therapy or, more recently, intravitreal injection of anti-VEGF pharmaceutical agents or steroids are used therapeutically. Although the traction from the epiretinal membrane may itself result in retinal elevation (Figure 8a), it may also produce wrinkling of the inner

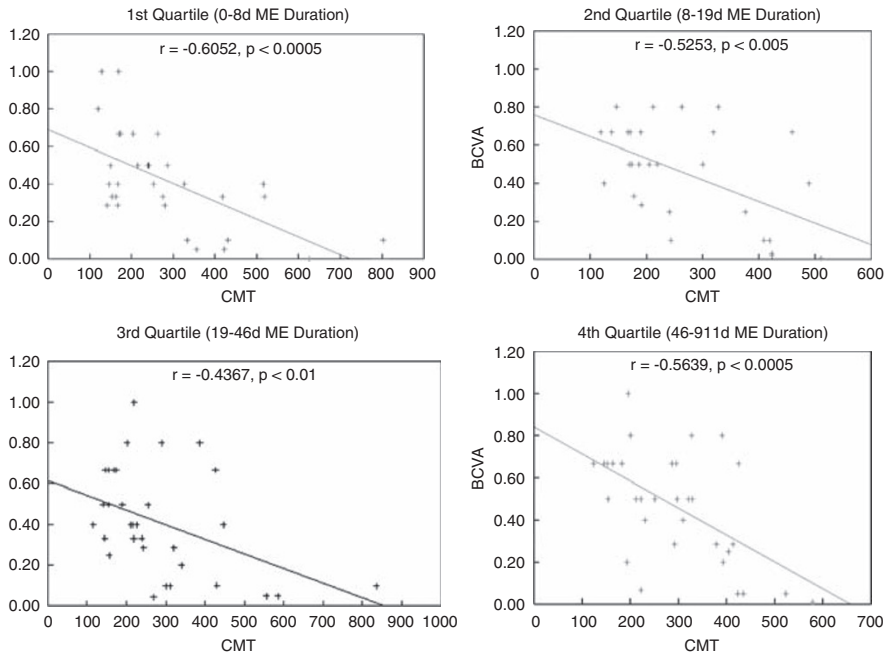

Figure 6 Best-corrected visual acuity (BCVA), plotted as a decimal fraction, *vs* central macular 1 mm zone thickness (CMT), as in Figure 5. Plots are by duration of macular oedema (ME) divided into quartiles. The x-axes here differ, but the slopes of the plots are similar and do not differ significantly from one another. *P*-values listed here are for significance of the differences between the slope of each plot and a line of zero slope.

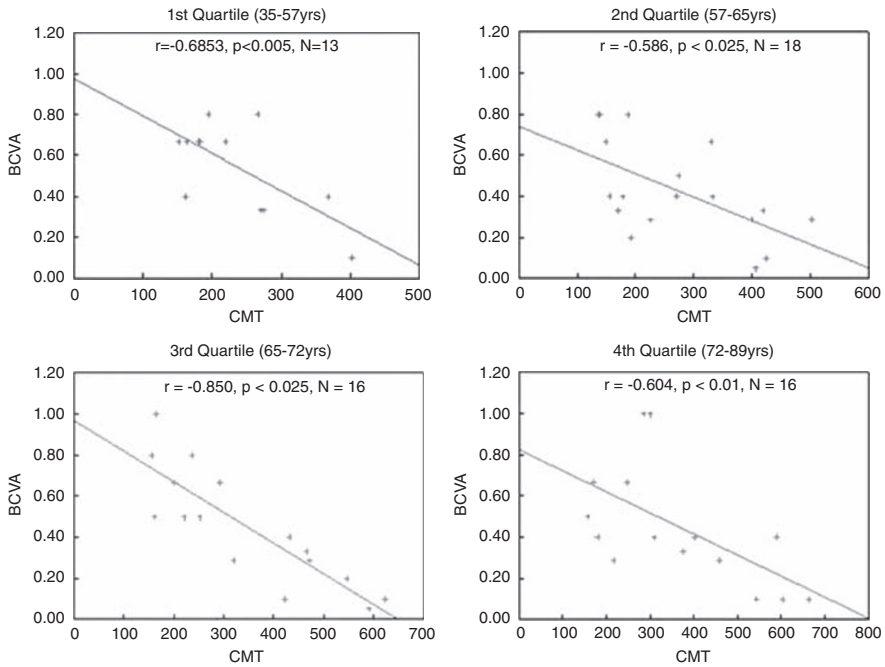

Figure 7 Best-corrected visual acuity (BCVA), here plotted as a decimal fraction, *vs* central macular 1 mm zone thickness (CMT). Plots are by age of the patient, divided into quartiles. Once again, the x-axes differ, but the slopes of the best-fitting straight line plots are quite similar and do not differ significantly from one another. *P*-values are for significance of the differences between the slope of each plot and a line of zero slope.

retinal surface (Figure 8b), producing an optical disturbance of light passing through to the photoreceptor layer, or may disturb neuronal function out of proportion to the effect of the membrane on the actual thickness of the macular neuronal layers.

The photoreceptor layer of the retina may also be damaged by macular oedema, especially if the oedema is relatively chronic or if there is serous elevation of the neurosensory retina with separation from the retinal pigment epithelium. Some abnormalities of the photoreceptor layer can be demonstrated with the high resolution afforded by spectral domain OCT, which can optimally demonstrate photoreceptor layer integrity by displaying both the outer limiting membrane of the photoreceptors as well as the outer segment-inner segment junction. The patient shown in Figure 9 had diabetic macular oedema with a cystoid cavity in the right eye, but an intact photoreceptor layer (Figure 9a, arrows). The vision was 20/40. In the left eye, there was no oedema, but there was photoreceptor loss centrally (Figure 9b, arrows). Vision in that eye was reduced to 20/70.

Photoreceptor layer disruption is not the only reason why visual acuity may not be predictable on the basis of macular thickness. The 80-year-old diabetic man whose OCT image of his left eye is shown in Figure 10 had type 2 diabetes, but no detectable retinopathy on the basis of retinal examination or fluorescein angiography. However, there was cystoid macular oedema that did not improve despite three bevacizumab injections, and the visual acuity was no better than 20/60. The OCT image shows a vitreomacular traction membrane and prominent cystoid oedema, but a completely intact photoreceptor layer, with a normal appearance both of the outer limiting membrane (solid, white arrows) and of the inner segment-outer segment junctions (dashed black arrow).

A final case bearing on this point is illustrated in Figures 11a–d. This 62-year-old woman had cataract surgery in her right eye in April 2009, during which the lens capsule ruptured, with nuclear and cortical fragments dispersed in the vitreous. The patient came to us on 7 August 2009 with vision reduced to 20/400 in that eye. Examination by spectral domain OCT showed extensive subretinal fluid and cystoid macular oedema (Figure 11a). An intravitreal injection of 1.25 mg bevacizumab produced little change in the appearance of the macula. Ultrasound biomicroscopy of the anterior segment demonstrated extensive deposition of lens fragments posterior to the iris. Vitrectomy surgery was performed in October 2009, followed by modest reduction in the subretinal fluid and macular thickness. Subsequently, over the next several months, the patient had two more intravitreal injections of bevacizumab.

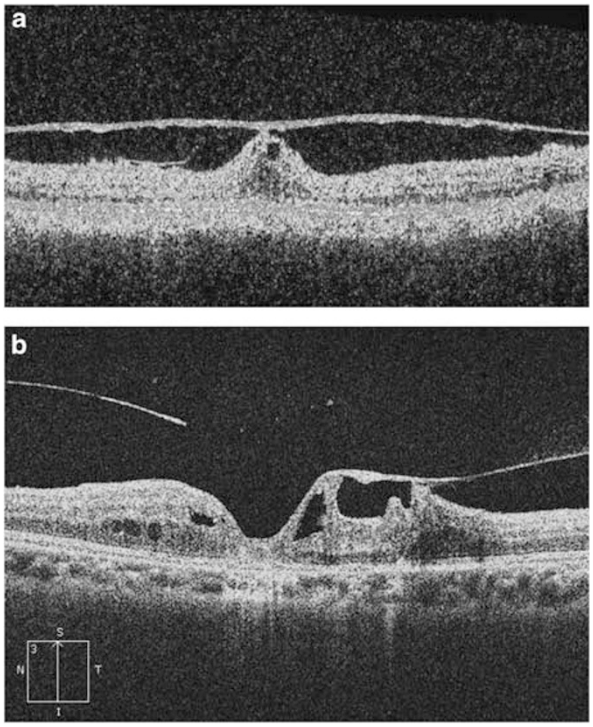

Figure 8 (a) Grayscale rendering of a spectral domain optical tomographic image (this, and all other OCT images in this presentation were carried out using the Zeiss Cirrus tomograph) of the right eye of a 65-year-old man who had received extensive laser photocoagulation for proliferative diabetic retinopathy. There is now a heavy epiretinal traction membrane elevating the center of the macula. The cellular layers of the neural retina are markedly thinned, in particular the outer nuclear layer. The photoreceptor inner and outer segments are not visible. Vision was 20/200. (b) Grayscale rendering of an OCT image of the macula of the right eye of a 56-year-old woman with long-standing diabetes. She had undergone extensive laser photocoagulation bilaterally for proliferative retinopathy and macular oedema, and is now receiving bevacizumab injections in her left eye with partial resolution of the oedema in that eye. The right eye, however, has an epiretinal membrane with traction and distortion of the inner retinal layers. The fovea is thin, but loss of photoreceptors reduces her vision in the eye to 20/200.

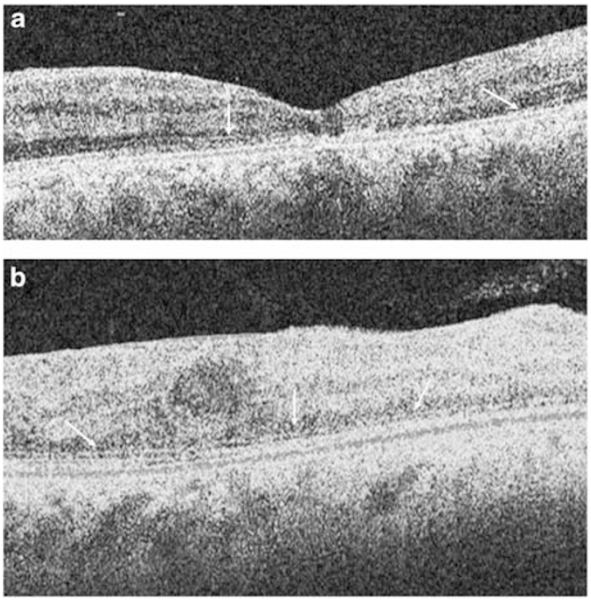

Figure 9 (a) This 52-year-old man with type 2 diabetes had laser-treated macular oedema in both eyes. In the left eye, the oedema has resolved as shown in this OCT image, but the photoreceptor layer is partially lost (arrows) and his vision is 20/70. (b) The right eye has remaining cystoid macular oedema, but the photoreceptor layer is intact (arrows) and his vision is 20/40.

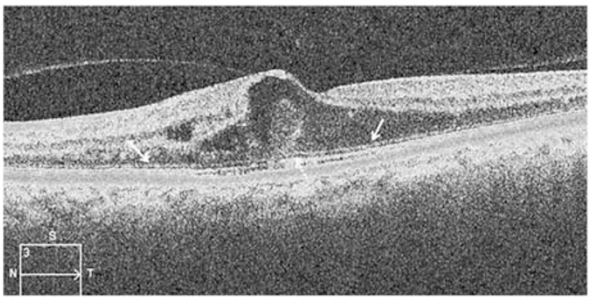

Figure 10 This 80-year-old man with diabetes, but no demonstrable retinopathy has vision of 20/60 in the eye depicted in this image. There is a vitreomacular membrane with traction, probably responsible for his cystoid macular oedema. The vision is reduced although the photoreceptor layer in his macula is intact, as demonstrated by the outer limiting membrane (solid arrows) and the intact inner segment-outer segment junction (dashed arrow).

On 30 April 2010 there was still moderate cystoid macular oedema (Figure 11b), and 2 mg triamcinolone was injected intravitreally. After 2 weeks, the macular oedema and subretinal fluid had disappeared entirely, but the visual acuity remained 20/80 and remained at this level 2 months later. Comparison with the fellow eye (Figures 11c and d) showed thinning of the outer nuclear layer, with preservation of the outer limiting membrane of the retina, but loss of the outer segment-inner segment boundary with the typical upward concavity at the fovea. Such subtle anatomic abnormalities, which would not have been visible before the introduction of techniques like spectral domain OCT, lead to a number of interesting questions. Which cases have permanent loss of photoreceptor cells that cannot be repaired, and in which ones can there simply be a reorientation of photoreceptor outer segments over time after the resolution of subretinal fluid, or even a replacement of lost photoreceptor outer segments by normally operative physiologic processes, with ultimate restoration of vision? Some years ago, Enoch *et al*[17] reported slow recovery of visual acuity over about 1 year in patients who had had successful anatomic repair of macula-off

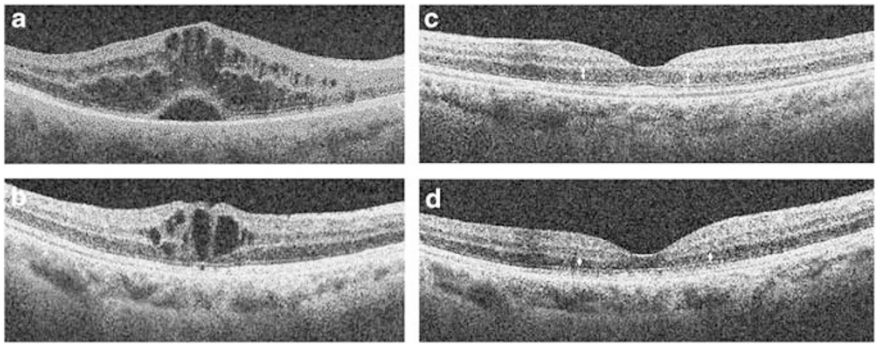

Figure 11 (a) This 62-year-old woman had cataract surgery in her right eye with a ruptured lens capsule and lens nuclear and cortical fragments scattered throughout the vitreous. When she was initially seen on 7 August 2009, there was massive cystoid macular oedema and subretinal fluid. Visual acuity was 20/400. (b) A single intravitreal injection of 1.25 mg bevacizumab had little effect and in October 2009 she underwent vitrectomy, which was followed by two more injections of bevacizumab. This figure shows the appearance of her macula on 30 April 2010. At that time, she received an intravitreal injection of 2 mg triamcinolone. A few weeks later, a scan of the normal left eye (c) shows an intact photoreceptor layer with a normal outer nuclear layer (double-headed arrows), outer limiting membrane and inner-outer segment junctions. However, in the right eye (d), the outer nuclear layer is thinned (double-headed arrows) and the inner-outer segment junctions are less evident.

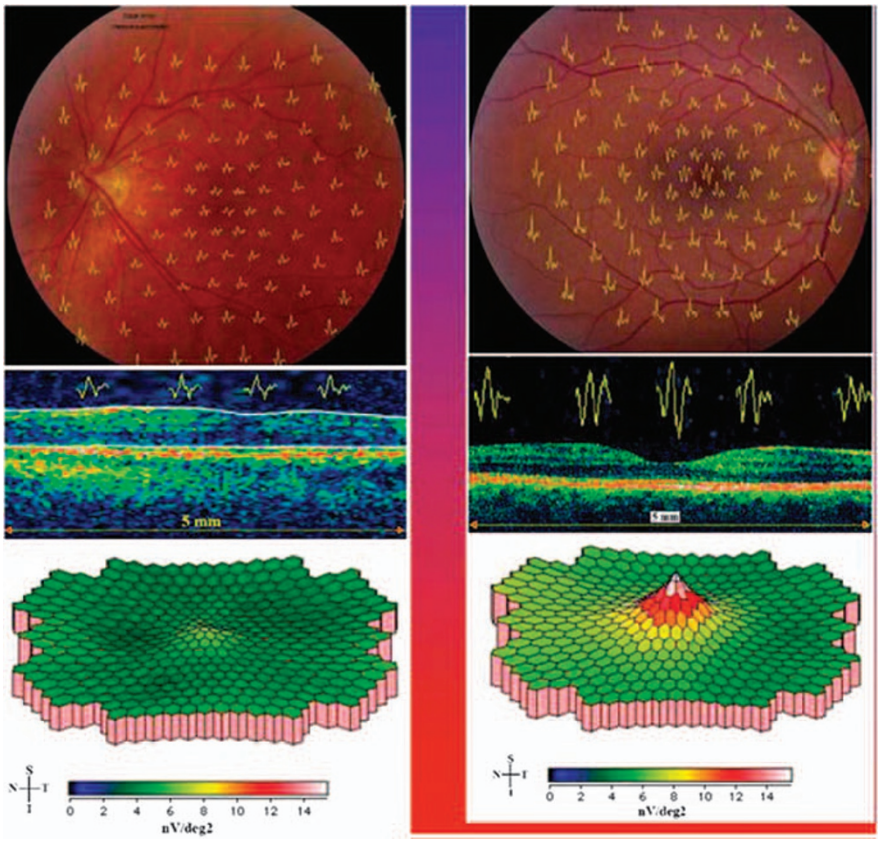

Figure 12 Multifocal electroretinographic (mfERG) potentials of the left eye (left-hand images) and of the right eye (right-hand column of images) of a patient with diffuse diabetic macular oedema in the left eye, but not the right. In the topmost images, the mfERG potentials overlay photographic images of each macula. In the middle panels, the potentials in the 180-degree meridians of each eye overlay the 180-degree scan of a time-domain OCT (Zeiss Stratus, Carl Zeiss Meditec, Dublin, CA, USA). Note that potentials from the eye with macular oedema are markedly diminished. This is further shown in the lower two images, which present three-dimensional plots of the scan amplitudes (summing the initial negative, or N1, wave and the later positive, or P1 wave of each potential; these are analogous to the a-wave and the b-wave of a conventional electroretinogram). From Frank *et al*,[31] by permission of the editors and publisher.

rhegmatogenous retinal detachments, which recovery coincided with recovery of the Stiles–Crawford effect in these eyes. They interpreted this result to indicate that a possible cause of the relatively poor vision initially after surgical repair of the macular detachment was loss of the normal foveal cone photoreceptor orientation, producing loss of directional sensitivity. Over time in these reattached retinas, they suggested that the cone outer segments reoriented themselves, although of course, their experiments could not determine whether their result was due to simple foveal cone outer segment reorientation, or actual replacement. Further use of newer methodologies like high resolution OCT, adaptive optics,[18] and confocal scanning laser ophthalmoscopy[19] viewing of the photoreceptor layer and other retinal structures will help us to resolve some of these questions non-invasively in living eyes over time that, therefore, could only be observed in histologic sections of enucleated globes, where correlation with visual function was not possible.

Physiological and biochemical abnormalities

In many cases, these have been more difficult to study because, to a very large extent, sampling of retinal tissue *in vivo* for biochemical analysis cannot be done. As experimental animals, other than primate species, do not have maculas, there is no satisfactory animal model of macular oedema that can be studied. The success of certain therapeutic interventions, for example, the introduction of intravitreal anti-VEGF agents[20–22] and corticosteroids[23,24] has indicated at least some important cellular mechanisms that can produce macular oedema. A very small scale clinical trial indicated that diabetic patients with macular oedema who were given nasal oxygen therapy over a brief period of time had improvement in their macular oedema, and visual function, over that experimental duration.[25] One study that involved both human vitrectomy specimens and an animal model of diffuse retinal oedema suggested that the CA-I isoform of carbonic anydrase may have a role in the production of macular oedema.[26] Unfortunately, this isoform is not substantially inhibited by the carbonic anhydrase inhibitors that are used clinically in humans, which are effective primarily against the CA-II, IV, and XII isoforms.[27] However, interestingly, Genead and Fishman have reported that clinically available, topical carbonic anhydrase inhibitors do reduce cystoid macular oedema in some patients with retinitis pigmentosa syndromes.[28] However, the treatment in some of these cases is only effective for a relatively brief period, apparently because tachyphylaxis occurs. Neither topical nor systemic carbonic anhydrase inhibitors have been uniformly effective in macular oedema in other diseases, and their relatively specific effect on the cystoid macular oedema that occurs in some patients with retinitis pigmentosa syndromes is curious.

The above treatments have been useful in many cases of macular oedema, but they are general treatments for resolving the macular thickening rather than specific

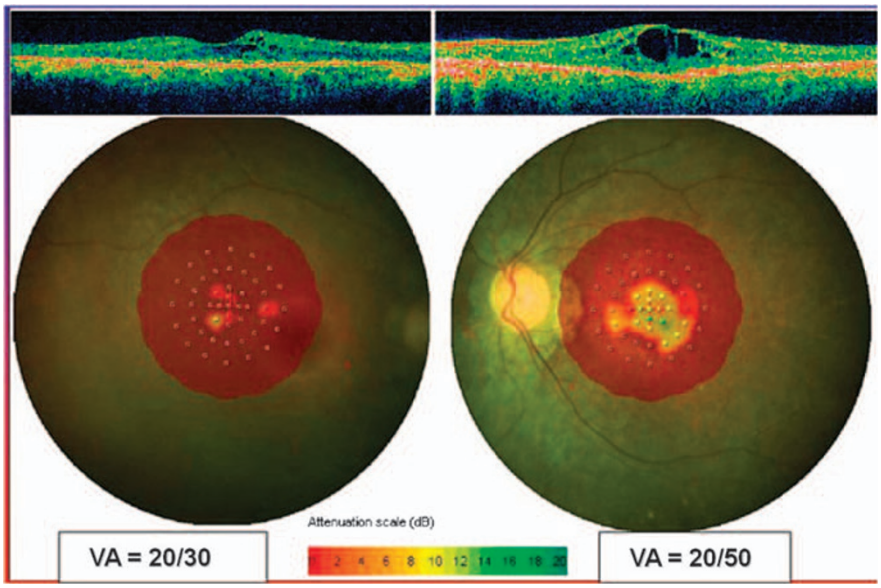

Figure 13 Microperimetric scans (Nidek MP-1), showing both eyes of a patient with bilateral diabetic cystoid macular oedema. The scan on the left shows smaller cystoid cavities and vision of 20/30 in the right eye. Areas of decreased sensitivity (central yellow zones) are much smaller than those in the left eye, shown in the right of the figure, where the vision is 20/50. However, as other figures in this presentation show, the size of the cystoid cavities does not always correspond to the visual acuity. From Frank *et al*,[31] by permission of the editors and publisher.

mechanisms facilitating neural function. Ways to study such specific mechanisms are few. Although it does not facilitate our understanding of the biochemical pathways involved, the technique of multifocal electroretinography (mfERG) does show very tiny, focal regions of retinal dysfunction, allowing the investigator to evaluate the effect of specific lesions in or near these regions on the electrophysiological function of those regions (Figure 12). The topic has been reviewed extensively by Bearse.[29] Detailed visual field evaluations of very tiny regions of retina, which can be mapped precisely to photographs of those regions, can be conducted by microperimetry (Figure 13). A method for evaluating biochemical pathways in living human eyes, in particular the redox state of pyridine nucleotides, has been proposed by Field and colleagues.[30] This method is being evaluated specifically in diabetic subjects, with the goal of predicting which eyes will be more susceptible to the development or progression of retinopathy. Although much of this work is still at an early stage, it holds a great deal of promise.

Conflict of interest

The author declares no conflict of interest.

Acknowledgements

All of the work described in this paper was conducted with funding from a departmental unrestricted Grant from Research to Prevent Blindness, New York, NY, USA. The experiments described in 'The Mystery of Early Worsening' were conducted several years ago with funding from the Juvenile Diabetes Research Foundation, also in New York. I am indebted for assistance in the experiments in this section from Alexander Kennedy, BS and for assistance in the studies of the second section of this manuscript, 'The Mystery of Macular Oedema,' from Ahmad Aref, M.D. and Michael Mequio, M.D.

References

1 The Diabetes Control and Complications Trial Research Group. Early worsening of diabetic retinopathy in the diabetes control and complications trial. *Arch Ophthalmol* 1998; **116**: 874–886.
2 Diabetic Retinopathy Clinical Research Network, Browning DJ, Glassman AR, Aiello LP, Beck RW, Brown DM, Fong DS *et al.* Relationship between optical coherence tomography-measured central retinal thickness and visual acuity in diabetic macular edema. *Ophthalmology* 2007; **114**: 525–536.
3 The Diabetes Control and Complications Trial Research Group. The effect of intensive treatment of diabetes on the development and progression of long-term complications in insulin-dependent diabetes mellitus. *N Engl J Med* 1993; **329**: 977–986.
4 Lauritzen T, Frost-Larsen K, Larsen HW, Deckert T. Two-year experience with continuous subcutaneous insulin infusion in relation to retinopathy and neuropathy. *Diabetes* 1985; **34**(Suppl. 3): 74–79.
5 Kroc Collaborative Study Group. Blood glucose control and the evolution of diabetic retinopathy and albuminuria. *N Engl J Med* 1984; **311**: 365–372.
6 Chantelau E, Kohner EM. Why some cases of retinopathy worsen when diabetic control improves. *Br Med J* 1997; **315**: 1105–1106.
7 Smith LEH, Kopchick JJ, Chen W, Knapp J, Kinose F, Daley D *et al.* Essential role of growth hormone in ischemia-induced retinal neovascularization. *Science* 1997; **276**: 1706–1709.
8 Thrailkill KM, Quattrin T, Baker L, Kuntze JE, Compton PG, Martha Jr PM. Cotherapy with recombinant human insulin-like growth factor I and insulin improves glycemic control in type 1 diabetes. RhIGF-I in IDDM Study Group. *Diabetes Care* 1999; **22**: 585–592.
9 Frank RN. Etiologic mechanisms in diabetic retinopathy. Chapter 66 In: SJ Ryan, AP Schachat, CP Wilkinson, D Hinton (eds). *Retina*, 4th ed. Elsevier: London, 2006, pp 1240–1270.
10 Kennedy A, Frank RN. The influence of glucose concentration and hypoxia on VEGF secretion by cultured retinal cells. *Curr Eye Res*, epub ahead of print 15 December 2010; doi:10.3109/02713683.2010.521968.
11 Aiello LP, Avery RL, Arrigg PG, Keyt BA, Jampel HD, Shah ST *et al.* Vascular endothelial growth factor in ocular fluid of patients with diabetic retinopathy and other retinal disorders. *N Engl J Med* 1994; **331**: 1480–1487.
12 Aiello LP, Bursell SE, Clermont A, Duh E, Ishii H, Takagi C *et al.* Vascular endothelial growth factor-induced retinal permeability is mediated by protein kinase C *in vivo* and suppressed by an orally effective beta-isoform-selective inhibitor. *Diabetes* 1997; **46**: 1473–1480.
13 Shweiki D, Itin A, Soffer D, Keshet E. Vascular endothelial growth factor induced by hypoxia may mediate hypoxia-initiated angiogenesis. *Nature* 1992; **359**: 843–845.
14 Deak GG, Bolz M, Ritter M, Prager SG, Benesch T, Schmidt-Erfurth U. A systematic correlation of morphology and functional alterations in diabetic macular Edema. *Invest Ophthalmol Vis Sci* 2010; **51**: 6710–6714.
15 Gangnon RE, Davis MD, Hubbard LD, Aiello LM, Chew EY, Ferris III FL *et al.* A severity scale for diabetic macular edema developed from ETDRS data. *Invest Ophthalmol Vis Sci* 2008; **49**: 5041–5047.
16 Davis MD, Sheetz MJ, Aiello LP, Milton RC, Danis RP, Zhi X *et al.* Effect of ruboxistaurin on the visual acuity decline associated with long-standing diabetic macular edema. *Invest Ophthalmol Vis Sci* 2009; **50**: 1–4.
17 Enoch JM, Van Loo Jr JA, Okun E. Realignment of photoreceptors disturbed in orientation secondary to retinal detachment. *Invest Ophthalmol* 1973; **12**: 849–853.
18 Hofer H, Carroll J, Neitz J, Neitz M, Williams DR. Organization of the human trichromatic cone mosaic. *J Neurosci* 2005; **25**: 9669–9679.
19 Schmitz-Valckenberg S, Steinberg JS, Fleckenstein M, Visvalingam S, Brinkmann CK, Holz FG. Combined confocal scanning laser ophthalmoscopy and spectral-domain optical coherence tomography imaging of reticular drusen associated with age-related macular degeneration. *Ophthalmology* 2010; **117**: 1169–1176.

20 The Diabetic Retinopathy Clinical Research Network. Randomized trial evaluating ranibizumab plus prompt or deferred laser or triamcinolone plus prompt laser for diabetic macular edema. *Ophthalmology* 2010; **117**: 1064–1077.
21 Campochiaro PA, Heier JS, Feiner L, Gray S, Saroj N, Rundle AC *et al.* Ranibizumab for macular edema following branch retinal vein occlusin: six-month primary end point results of a phase III study. *Ophthalmology* 2010; **117**: 1102–1112.
22 Brown DM, Campochiaro PA, Singh RP, Li Z, Gray S, Saroj N *et al.* Ranibizumab for macular edema following central retinal vein occlusion: six-month primary end point results of a phase III study. *Ophthalmology* 2010; **117**: 1124–1133.
23 Scott IU, Ip MS, VanVeldhuisen PC, Oden NL, Blodi BA, Fisher M *et al.* A randomized trial comparing the efficacy and safety of intravitreal triamcinolone with standard care to treat vision loss associated with macular edema secondary to branch retinal vein occlusion: the Standard Care vs Corticosteroid for Retinal Vein Occlusion (SCORE) study report 6. *Arch Ophthalmol* 2009; **127**(9): 1115–1128.
24 Ip MS, Scott IU, VanVeldhuisen PC, Oden NL, Blodi BA, Fisher M *et al.* A randomized trial comparing the efficacy and safety of intravitreal triamcinolone with observation to treat vision loss associated with macular edema secondary to central retinal vein occlusion: the Standard Care vs Corticosteroid for Retinal Vein Occlusion (SCORE) study report 5. *Arch Ophthalmol* 2009; **12**: 1101–1114.
25 Nguyen QD, Shah SM, Van Anden E, Sung JU, Vitale S, Campochiaro PA. Supplemental oxygen improves diabetic macular edema: a pilot study. *Invest Ophthalmol Vis Sci* 2004; **45**: 617–624.
26 Gao BB, Clermont A, Rook S, Fonda SJ, Srinivasan VJ, Wojtkowski M *et al.* Extracellular carbonic anhydrase mediates hemorrhagic retinal and cerebral vascular permeability through prekallikrein activation. *Nat Med* 2007; **13**: 181–188.
27 Mincione F, Scozzafava A, Supuran CT. The development of topically acting carbonic anhydrase inhibitors as anti-glaucoma agents. *Curr Top Med Chem* 2007; **7**: 849–854.
28 Genead MA, Fishman GA. Efficacy of sustained topical dorzolamide therapy for cystic macular lesions in patients with retinitis pigmentosa and usher syndrome. *Arch Ophthalmol* 2010; **128**: 1146–1150.
29 Bearse Jr MA, Adams AJ, Han Y, Schneck ME, Ng J, Bronson-Castain K *et al.* A multifocal electroretinogram model predicting the development of diabetic retinopathy. *Prog Retin Eye Res* 2006; **25**: 425–448.
30 Field MG, Elner VM, Puro DG, Feuerman JM, Musch DC, Pop-Busui R *et al.* Rapid, noninvasive detection of diabetes-induced retinal metabolic stress. *Arch Ophthalmol* 2008; **126**: 934–938.
31 Frank RN, Glybina I. Macular oedema. In: Dartt D, Besharse JC, Dana MR (eds). *Encyclopedia of the Eye*, Vol. 3 Oxford, Academic Press: Elsevier, 2010, pp 1–12.