infestation. Early stages show unilateral vitritis, papillitis, and recurrent grey-white retinal lesions. The later stages have diffuse pigment epithelium degeneration, optic atrophy, vascular attenuation and vision loss.[1,2] DUSN presents as a diagnostic dilemma and leads to severe visual loss.

We present the first report of the high-definition spectral domain OCT (HD-OCT) features of an eye with DUSN and the use of this imaging modality to possibly localize the worm and follow it after laser treatment.

Case report

We saw a 45-year-old Haitian woman with a 1week history of severe vision loss in the left eye. Her best-corrected visual acuities were 20/30 right eye (RE) and Hand motions left eye (LE). Examination of the RE was unremarkable. Anterior segment evaluation of the LE was unremarkable, posterior segment examination showed vitritis, optic nerve oedema, midperipheral pigmentary degeneration, macular oedema, and a motile 2000 μ subretinal worm above the superior arcade (Figure 1a). The worm migrated to the inferior arcade (Figure 1b) over the next half hour. Argon laser photocoagulation of the worm was done (365 spots, 200–400 mW, 200–500 μ, 0.15 s). At 1 week post-laser the worm could not be identified; however, intense focal inflammation was seen at the site of the laser (Figure 1c). HD-OCT (Cirrus HD-OCT, Carl Zeiss Meditech Inc., Jena, Germany) of this area revealed a round hypoechogenic structure under the inflammation conforming to the size and shape of the worm. This was surrounded by a hyperechogenic inflammatory response (Figure 1d). Serial HD-OCT evaluations of these structures were carried out at weeks 8 and 12. At 12 weeks ocular inflammation in the patient resolved, the retina showed classic subretinal fibrosis (Figure 1e) and HD-OCT showed a hyperechogenic scar and the absence of a round hypoechogenic structure (Figure 1f).

Comment

The nematode in our patient was large and rapidly motile so we believe that it likely was *Baylisascaris procyonis*.[3,4] We show that HD-OCT can potentially visualize the nematode even through hazy vitreoretinal inflammation. This report shows that HD-OCT offers a valuable noninvasive technique to image eyes with DUSN.

References

1 Gass JDM, Gilbert Jr WR, Guerry RK, Scelfo R. Diffuse unilateral subacute neuroretinitis. *Ophthalmology* 1978; **85**: 521–545.
2 Gass JD, Braunstein RA. Further observations concerning the diffuse unilateral subacute neuroretinitis syndrome. *Arch Ophthalmol* 1983; **101**: 1689–1697.
3 Goldberg MA, Kazacos KR, Boyce WM, Ai E, Katz B. Diffuse unilateral subacute neuro- retinitis. Morphometric, serologic, and epidemiologic support for *Baylisascaris* as a causative agent. *Ophthalmology* 1993; **100**: 1695–1701.
4 Garcia CA, Sabrosa NA, Gomes AB, Segundo Pde S, Garcia Filho CA, Sabrosa AS. Diffuse unilateral subacute neuroretinitis-DUSN. *Int Ophthalmol Clin* 2008; **48**: 119–129.

E Ahmed, MA Houston and D Husain

Retina Service, Department of Ophthalmology, Boston University School of Medicine, Boston, MA, USA
E-mail: deeba.husain@bmc.org

None of the authors have any financial or propriety interest in the presented work

Eye (2010) **24,** 393–394; doi:10.1038/eye.2009.110; published online 15 May 2009

Sir,

Spontaneous regression of a retinal fold a year after scleral buckling and intravitreal injection of gas

Posterior retinal folds have been rarely reported after the use of intravitreal gas combined with scleral buckling.[1,2] We report a case where a symptomatic retinal fold developed after scleral buckling and intravitreal gas injection and spontaneously regressed a year later.

Case report

A 43-year-old woman, presented with a superotemporal bullous retinal detachment (RD) sparing the macula, with a U-tear at 1 o'clock hours. Best-corrected visual acuity (BCVA) was 20/20. The patient underwent uncomplicated scleral buckling (SB) procedure during which preplacement of scleral sutures, drainage of subretinal fluid (SRF), and placement and tightening of a circumferential solid (276) silicone tire extending from 12 to 3 h were carried out; additionally, as the eye was still hypotonous, 1 ml of air was injected intravitreally. In the first postoperative day, the retina was attached; however, a retinal fold extending from the area of the buckle towards the posterior pole, involving the superior arcade and distorting the macular area (Figure 1a and b) was noted. The patient complained for disturbing metamorphopsia and VA could not improve more than 20/80. After a discussion on underlining

Figure 1 (a) Colour fundus photograph showing nematode superior to disk crossing the superior retinal vein. (b) Redfree photograph showing the worm moved to the inferonasal retina. (c) Colour fundus photograph 1 week post-laser showing white inflammation nasal to disk. (d) HD-OCT cross-section at 1 week post-laser through the area of inflammation showing the round hypoechogenic presumed worm body surrounded by inflammation. (e) Colour fundus photograph at 12 weeks post-laser showing hyperpigmented area consistent with area of photocoagulation inferonasal to disk and white area of fibrosis. Subretinal fibrosis tracks are also visible in the macula. (f) HD-OCT cross-section at 12 weeks post-laser showing hyperechogenic subretinal scar.

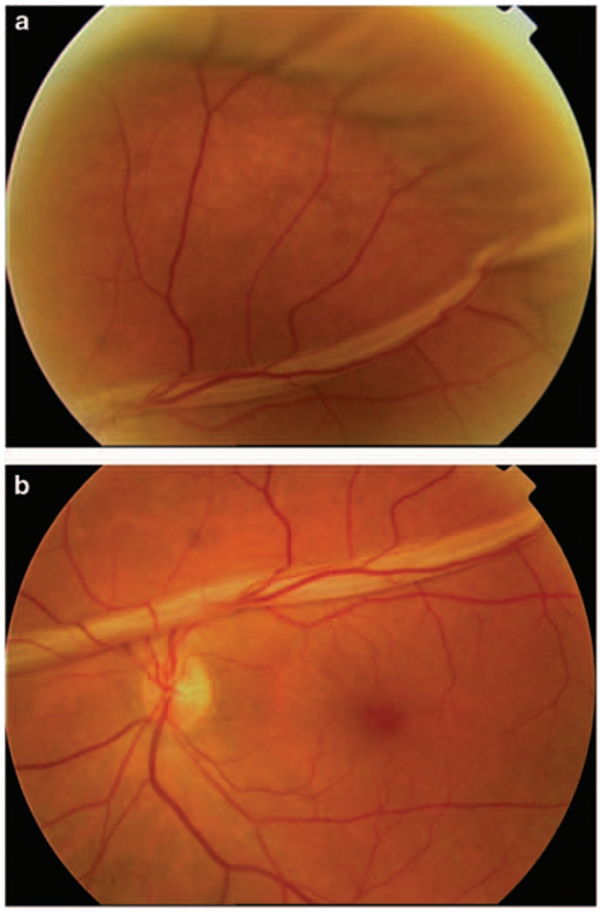

Figure 1 The first postoperative day; although the retina is flat, a retinal fold is formed extending from the indentation of the buckle (a) towards the posterior pole and the nasal side of the optic disc (b).

benefits and risks of possible treatment options, the patient denied further surgery.

Six months later, BCVA was 20/30 and the retinal fold less was prominent (Figure 2). Twelve months postoperatively, as the indentation of the buckle had completely flatten (Figure 3a), the retinal fold regressed (Figure 3b) and BCVA was 20/20.

Comment

Posterior retinal folds have been rarely reported after the use of intravitreal gas combined with SB.[1,2] A circumferential SB occupies a substantial part of the intraocular volume and thereby makes retinal tissue relatively redundant. Retinal folds have been considered to form by the combined action of gravity and intravitreal gas bubble to the redundant retina, which is pushed posteriorly.[3] If the SRF is then absorbed, an arcuate retinal fold could remain, and if the macula is involved, vision could be impaired.[1–4] Surgical treatment of symptomatic retinal folds with vitrectomy, induction of an RD with injection of saline subretinally, and relocation of the retina with gas[5] or with perfluoro-hexy-loctane(F_6H_8)[6] have been reported in the literature.

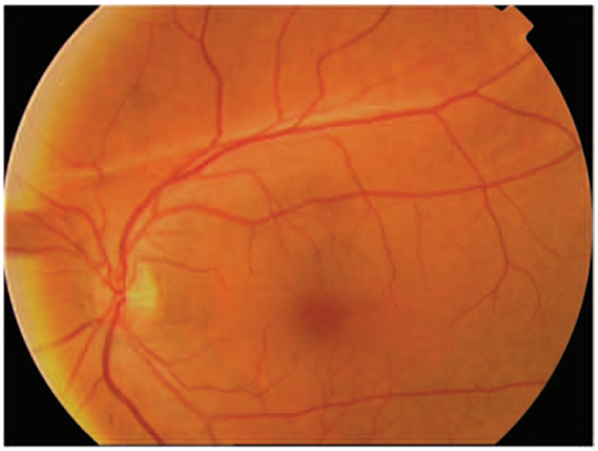

Figure 2 Six months after surgery, the retinal fold has partially 'ironed out' corresponding with an improvement in the visual acuity.

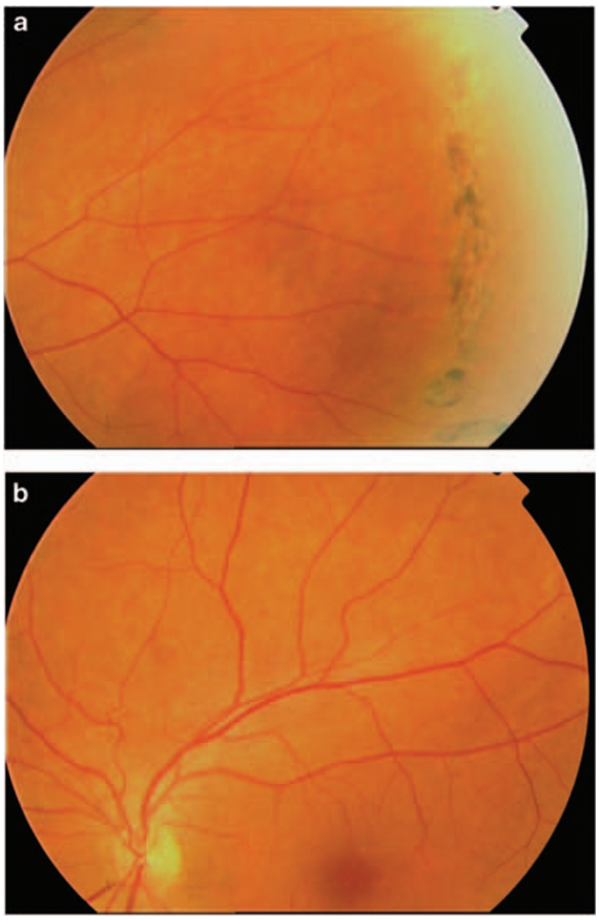

Figure 3 An year after surgery, as the indentation of the buckle has diminished in height (a), the retinal fold has completely flatten (b), and visual acuity has restored to 20/20.

In our patient, the retinal fold did not involve the fovea; however, it distorted the macular (Figure 1) area causing metamorphopsia and decreased VA. As the indentation of the buckle diminished in height within the next months, the retina gradually unfolded and VA was completely restored.

Our case illustrates the rare but possible occurrence of arcuate retinal folds, which could compromise the results of successful retinal reattachment surgery. We postulate that in our case, the formation of the retinal fold might have been prevented if the air was injected after the drainage of SRF and a gentler buckle was placed when the retina was more or less completely reattached. It could be also postulated that in cases where permanent indentation is not necessary, the removal of the circumferential buckle might be an option for the treatment of symptomatic arcuate retinal folds, as in our patient, the retinal fold regressed when the buckle indentation diminished in height.

References

1 Larrison WI, Frederick Jr AR, Peterson TJ, Topping TM. Posterior retinal folds following vitreoretinal surgery. *Arch Ophthalmol* 1993; **111**: 621–625.
2 Pavan PR. Arcuate retinal folds after intraocular gas injection. *Arch Ophthalmol* 1988; **106**: 164–165.
3 Lewen RM, Lyon CE, Diamond JG. Scleral buckling with intraocular air injection complicated by arcuate retinal folds. *Arch Ophthalmol* 1987; **105**: 1212–1214.
4 van Meurs JC, Humalda D, Mertens DA, Peperkamp E. Retinal folds through the macula. *Doc Ophthalmol* 1991; **78**: 335–340.
5 El-Amir AN, Every S, Patel CK. Repair of macular fold following retinal reattachment surgery. *Clin Experiment Ophthalmol* 2007; **35**: 791–792.
6 Herbert EN, Groenewald C, Wong D. Treatment of retinal folds using a modified macula relocation technique with perfluoro-hexyloctane tamponade. *Br J Ophthalmol* 2003; **87**: 921–922.

E Gotzaridis[1], I Georgalas[2] and I Ladas[2]

[1]Retinal Center, Athens, Greece
[2]Department of Ophthalmology, G Gennimatas Hospital of Athens, NHS, Athens, Greece
E-mail: igeorgalas@yahoo.com

The authors declare no conflict of interest

Eye (2010) **24,** 394–396; doi:10.1038/eye.2009.90; published online 24 April 2009

Sir,

Retinal artery occlusion associated with a patent foramen ovale

Systemic disease is usually responsible for retinal ischaemic events in patients under 30 years of age. We report the case of a young man with retinal artery occlusion (RAO) secondary to patent foramen ovale (PFO).

Case report

A healthy 17-year-old African-American male presented with sudden, painless loss of vision in his right eye while playing basketball. He denied associated symptoms of headache, pain, or visual disturbance, as well as a history of sickle cell disease or trait, or recreational drug abuse. An examination revealed a visual acuity of hand motions in the affected eye. The fundus had macular pallor and a cherry-red spot in the fovea (Figure 1). Fluorescein angiography was consistent with a RAO (Figures 2 and 3). An optical coherence tomography showed macular edema of 503 μm. The haemotological/infectious work-up, including transthoracic echocardiogram (TTE), was negative. However, a trans-oesophageal echocardiogram (TEE) showed a PFO. The patient underwent a successful percutaneous femoral catheterization to close the defect.

Comment

A PFO has been a reported finding in young patients presenting with RAO without risk factors for such an event.[1] Autopsy studies report the incidence of PFO to be 17–35% in the general population.[2] The association between PFO and embolism has been reported in young adults.[3] The source for the emboli is often not found, but is usually attributed to occult thrombosis. Nakagawa *et al*[4] reported a case of RAO in a patient with PFO and deep venous thrombosis. Our patient's history is significant for engagement in the basketball game at the onset of symptoms. This exertion, coupled with a sub-clinical thrombosis, may have resulted in the paradoxical RAO.

Chen *et al*[2] reported a fourfold increased incidence of PFO in patients with ischaemic events compared with that in controls, and a greatly increased sensitivity for

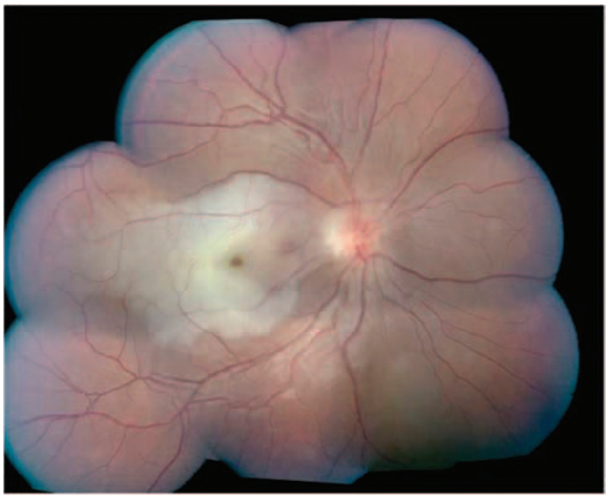

Figure 1 Right eye with inner retinal ischaemic whitening in the area supplied by the temporal retinal artery.