Eye (2009) 23, 2263–2272

www.nature.com/eye

Sir,

Mid-term outcomes of penetrating keratoplasty (PK) and deep anterior lamellar keratoplasty (DALK)

Since our publication in 2006,[1] we have revisited our keratoconic cohort and retrospectively collected refraction and best (spectacle)-corrected visual acuities (BCVAs) at 2 and 4 years post-PK or post-DALK plus the incidence of rejection and graft failure. Data analyses were undertaken via independent *t*-tests or the Mann–Whitney test.

At 2 years, there were visual acuity data for 17 eyes with PK and 10 with DALK, and refractive data for 16 eyes with PK and 12 with DALK; at four years, there were visual acuity data for 17 eyes with PK and 9 with DALK, and refractive data for 14 eyes with PK and 9 with DALK (Table 1). The refractive outcomes were similar except that the DALK group had significantly less astigmatism at 2 years compared with those that had undergone PK. A BCVA of 6/6 or better was achieved 4 years postoperatively by more than three-quarters of the PK group, but only a third of the DALK group (Figure 1). Two of the PK patients (10%) underwent a second PK: one had secondary graft failure following infective keratitis at 9 months and another developed large, fluctuating astigmatism following suture removal at 32 months. None of the DALKs required repeat corneal transplantation. Both groups had graft rejection episodes; three in the PK group had endothelial rejections and two in the DALK group suffered epithelial or stromal rejection, all of which resolved with the appropriate treatment.

This report confirms both PK and DALK as successful surgical options for keratoconus. A constant significant finding was the attainment of better visual acuity via PK than following DALK with improvement in both sets over time (Figure 1). The two groupings experienced similar rates of graft rejection episodes, yet none of the DALKs required regrafting; these outcomes are similar to earlier studies.[2,4] Furthermore, we too observed that the DALK patients had a shorter post-op rehabilitation period than PK patients.[3,5] Consequently, we propose that DALK offers faster rehabilitation plus an improved chance of long-term graft survival, but at the expense of reduced BCVA compared with PK.

Table 1 Summary of the findings at 2 and 4 years after PK and DALK

	Mean BCVA	*Mean SE*	*Mean Cyl*
2-year post-graft			
PK	*6/7.5^{+} ($P=0.03$)	−2.75DS (SD 2.99)	*4.22DC (SD 2.64) ($P=0.01$)
DALK	*6/9.5^{-}	−4.29DS (SD 3.00)	*2.21DC (SD 1.19)
4-year post-graft			
PK	*6/6^{+} ($P=0.01$)	−2.69DS (SD 3.62)	4.34DC (SD 4.34)
DALK	*6/7.5^{-}	−4.64DS (SD 3.85)	3.28DC (SD 1.75)

BCVA = best-corrected visual acuity; S.E = spherical equivalent; Cyl = refractive cylinder; Group comparisons were analysed with independent *t*-tests apart from the SE at 2 years and the BCVA at 4 years that were analysed with the Mann–Whitney test, as these data were not normally distributed; all distributions were assessed for normality using the Shapiro–Wilk test.
*Outcomes (between PK and DALK) were statistically significant, that is, $P<0.05$.

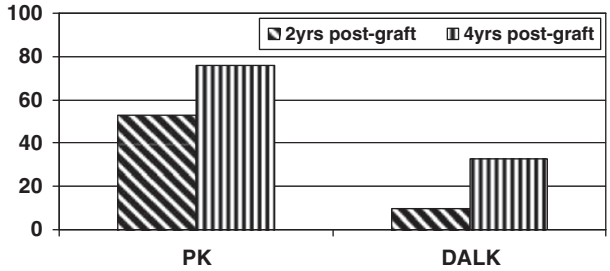

Figure 1 Percentage of eyes that achieved a BCVA of 6/6 or better following PK or DALK at 2- and at 4-years post-graft.

References

1 Funnell CL, Ball J, Noble BA. Comparative cohort study of the outcomes of deep lamellar keratoplasty and penetrating keratoplasty for keratoconus. *Eye* 2006; **20**: 527–532.
2 Shimazaki J, Shimmura S, Ishioka M, Tsubota K. Randomized clinical trial of deep lamellar keratoplasty vs penetrating keratoplasty. *Am J Ophthalmol* 2002; **134**: 159–165.
3 Watson SL, Ramsay A, Dart JK, Bunce C, Craig E. Comparison of deep lamellar keratoplasty and penetrating keratoplasty in patients with keratoconus. *Ophthalmology* 2004; **111**: 1676–1682.
4 Noble BA, Agrawal A, Collins C, Saldana M, Brogden PR, Zuberbuhler B. Deep anterior lamellar keratoplasty (DALK): visual outcome and complications for a heterogeneous group of corneal pathologies. *Cornea* 2007; **26**: 59–64.
5 Panda A, Bageshwar LM, Ray M, Singh JP, Kumar A. Deep lamellar keratoplasty versus penetrating keratoplasty for corneal lesions. *Cornea* 1999; **18**: 172–175.

A Rice[1,2], CL Funnell[2], K Pesudovs[3], BA Noble[4] and JL Ball[2]

[1]Section of Ophthalmology and Neuroscience, LIMM, University of Leeds, Leeds, UK;
[2]Eye Department, St James's University Hospital, Leeds, UK;
[3]Department of Ophthalmology, NHMRC Centre for Clinical Eye Research, Flinders University of South Australia, Bedford Park, Australia
[4]Yorkshire Eye Hospital, Apperley Bridge, UK
E-mail: a.rice@leeds.ac.uk

This study was supported by a Leeds Teaching Hospitals Charitable Foundation Fellowship and funding from Yorkshire Eye Research (Grant numbers 011 and 011B).

Eye (2009) **23,** 2263; doi:10.1038/eye.2009.9; published online 6 February 2009