

Sir,
Anterior segment optical coherence tomography imaging and histopathologic findings of an overhanging filtering bleb

An overhanging bleb, a rare complication of trabeculectomy, can cause discomfort and decreased visual acuity in which case surgical removal is necessary.

But, surgical removal is not free of possible risks such as leakage. We present a case in which a dissecting portion of bleb was successfully removed without leaking, with an aid of preoperative anterior segment optical coherence tomography (AS-OCT).

Case report

A 47-year-old woman visited our clinic due to visual disturbance (10/200 without correction) on her left eye. She received trabeculectomy 13 years ago. On slit-lamp examination, an overhanging filtration bleb was noted (Figure 1a). Before the surgery, AS-OCT (SL-OCT™, Heidelberg Engineering GmbH, Germany) was taken (Figure 2). The dissecting portion of the bleb over the cornea was removed with forceps and scissors. The histopathologic image of removed bleb was consistent with the imaging of AS-OCT, multiloculated cystic structures (Figure 3). One day after operation, there was

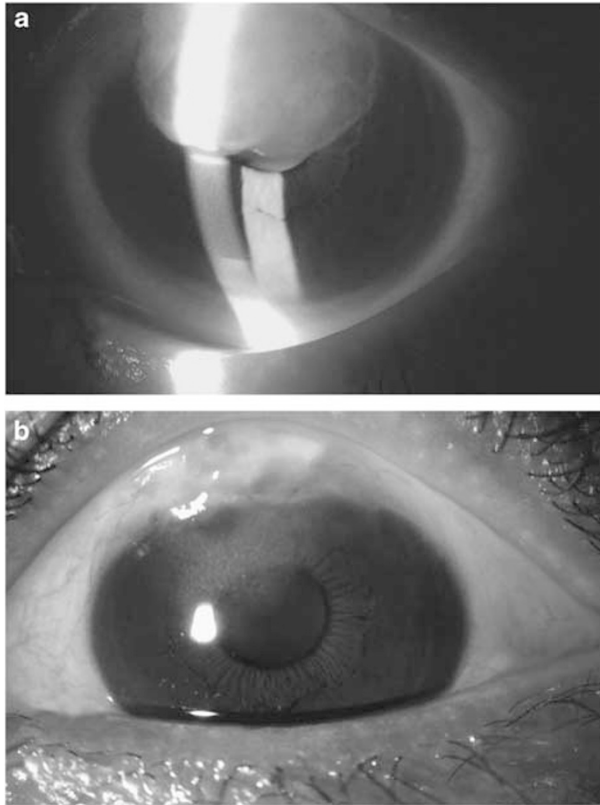


Figure 1 Preoperative slit-lamp photograph of overhanging filtering bleb (a), Slit-lamp photograph at 6 months after surgery (b).

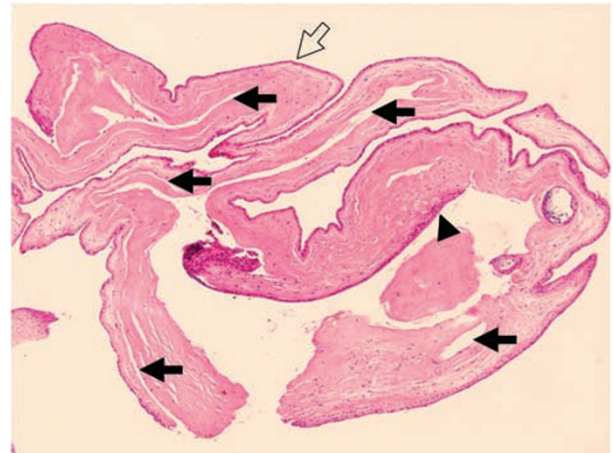


Figure 3 Histopathology of excised corneal overhanging filtering bleb shows a multiloculated cystic structure (arrow) covered with flattened corneal epithelium (open arrow) and conjunctival epithelium (arrow head; original magnification $\times 40$).

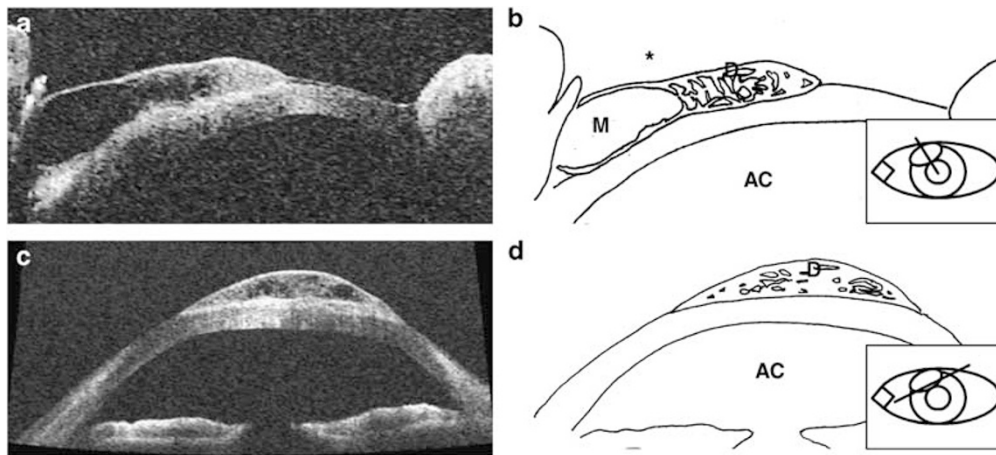


Figure 2 Anterior chamber OCT images of axial view (a), schematic axial view (b), horizontal view (c), and schematic horizontal view (d) of dissecting filtering bleb. In the axial view (a and b), coarse and multiloculated cystic structure in the dissecting portion of the bleb and uniloculated main cystic bleb in the conjunctival portion of the bleb are noted, whose boundary lies at corneoscleral limbus. AC = anterior chamber; D = dissecting portion of overhanging bleb; M = main original bleb; the symbol "*" signifies corneoscleral limbus.

no leakage around excision margin. Until 6 months after surgery (Figure 1b), the patient showed good visual acuity (20/40–20/50) and IOP (14–18 mmHg) without leaking.

Comment

Surgeons generally find it uncomfortable to manipulate trabeculectomy bleb due to the risk of leaking. Obtaining preoperative knowledge of bleb structures appears feasible in planning safe surgery beforehand to reduce the risk of complications from manipulation.

Noninvasive approaches to examine bleb include ultrasound biomicroscopy and AS-OCT.^{1,2} In our case, multiloculated bleb structure of dissecting portion apart from the main cystic bleb was confirmed by preoperative AS-OCT imaging and histological study. Previous reports of overhanging bleb^{3–5} stated that leaking was not a common complication even without the safety measure or suture. No leakage of aqueous humour or fast healing might be due to multicystic structures of the overhanging bleb in which the exchange of aqueous humour is suppressed.

We believe our experience with this case help readers understand the physical characteristics of overhanging blebs, as well as the feasibility of AS-OCT in planning safe surgery before bleb manipulation. However, more research and experiences should be carried out to bring up a general conclusion, which can be applied in all overhanging bleb cases.

References

- 1 Konstantopoulos A, Hossain P, Anderson DF. Recent advances in ophthalmic anterior segment imaging: a new era for ophthalmic diagnosis? *Br J Ophthalmol* 2007; **91**: 551–557.
- 2 Singh M, Chew PT, Friedman DS, Nolan WP, See JL, Smith SD *et al.* Imaging of trabeculectomy blebs using anterior segment optical coherence tomography. *Ophthalmology* 2007; **114**: 47–53.
- 3 Grostern RJ, Torczynski E, Brown SV. Surgical repair and histopathologic features of a dissecting glaucoma filtration bleb. *Arch Ophthalmol* 1999; **117**: 1566–1567.
- 4 Anis S, Ritch R, Shihadeh W, Liebmann J. Sutureless revision of overhanging filtering blebs. *Arch Ophthalmol* 2006; **124**: 1317–1320.
- 5 Ito K, Miura K, Sugimoto K, Malsunaga K, Susoh M, Uji Y. Use of indocyanine green during excision of an overhanging filtering bleb. *Jpn J Ophthalmol* 2007; **51**: 57–59.

WK Kim, GJ Seong, CS Lee, YG Kim and CY Kim

Department of Ophthalmology, Institute of Vision Research, Yonsei University College of Medicine, Seoul, Korea
E-mail: kcyeye@yuhs.ac

The authors have no proprietary interests in any of the products mentioned in the manuscript.

Eye (2008) **22**, 1520–1521; doi:10.1038/eye.2008.166; published online 6 June 2008

Sir,
Surgical outcomes of intermittent exotropia associated with concomitant hypertropia including simulated superior oblique palsy after horizontal muscles surgery only by YA Cho and S-H Kim

We have read the article with the title ‘Surgical outcomes of intermittent exotropia associated with concomitant hypertropia including simulated superior oblique palsy after horizontal muscles surgery only’ by YA Cho and S-H Kim.

We have a few questions about the article.

The Bielschowsky test is one of the adaptation tests to get rid of diplopia because of superior oblique paralysis. According to the Bielschowsky head tilt test, it is known that hyperdeviation increases when the head deviates towards the side of SO paralysis and hyperdeviation decreases or disappears when the head deviates towards the other side of SO paralysis. Therefore, hyperdeviation should be the highest when the head deviates towards the side of SO paralysis, the least when the head deviates towards the other side of SO paralysis, and in between in primary position. It was written in this article that the mean amount of hypertropia was 3.5–1.60 (2–14) PD in primary position, average hypertropia on the hypertropic side was 8.8–4.63 (3–18) PD, and on the nonhyperdeviating side 4.0–4.77 (0–16) PD. How do the authors explain that mean hyperdeviation in primary position is lower than the deviation on the nonparalytic side?

According to our experience, we also observed that hyperdeviation disappears when exodeviation is corrected surgically, as written in this article. But in some of our cases without fusion and with low visual acuity, the deviation recurred a few years after the operation. On the other hand, both horizontal and vertical deviations were controlled with strong fusional convergences in some of our patients.

What were the sensory states of the patients in this article who were tested with Titmus Fly stereotest, Randot stereotest, etc. as mentioned in the Materials and methods section? Have the authors observed any effect of fusional status on the correction of deviation for long-term results? Therefore, can the disappearance of vertical deviation spontaneously after correction of horizontal deviation only be explained by an anatomical or mechanical point of view?

AG Altintas and S Raza

SB Ataturk Research and Training Hospital, Bilkent, Ankara, Turkey
E-mail: sabri_raza@hotmail.com

Eye (2008) **22**, 1521; doi:10.1038/eye.2008.228; published online 1 August 2008

Sir,
Response to Dr Raza

Thank you for showing interest in our study. Our explanations are as follows:

Your point regarding the Bieschowsky test is all right. There are several possible explanations for our results.