6. Berry AC, et al. Monozygotic twins discordant for Wiedeman–Beckwith syndrome and the implications for genetic counselling. J Med Genet 1980;17:136–8.
7. Olney AH, et al. Beckwith–Wiedeman syndrome in discordant monozygotic twins. Am J Med Genet 1988; 29:491–9.
8. Lubinsky MS, Hall J. Genomic imprinting, monozygous twinning and X inactivation. Lancet 1991;237:1288.
9. Jinno Y, et al. Mosaic and polymorphic imprinting of the WT1 gene in humans. Nature Genet 1994;6:305–7.

Sir,

Cystoid Macular Oedema in Chronic Myeloid Leukaemia: Treatment with Acetazolamide and Response to Bone Marrow Transplantation

We report the first described case of cystoid macular oedema (CMO) occurring in a patient with chronic leukaemia. An initial resolution followed treatment with acetazolamide, previously thought useful only in ocular disease with blood–retinal barrier disruption and breaches in the retinal pigment epithelium. Complete resolution of CMO followed bone marrow transplantation, the unique relevance of which is discussed.

Case Report

A 50-year-old Caucasian man presented to his general practitioner with a 6 month history of malaise, weight loss and splenomegaly. More lately he had noticed deteriorating visual acuity in his left eye, although vision in the other eye seemed unaffected. Investigation revealed chronic myeloid leukaemia (CML) with confirmation of the BCR-ABL gene rearrangement. Treatment was commenced with hydroxyurea and immediate haematological improvement was noted at 11 days. After a further 2 weeks he was in remission and the dose of hydroxyurea was reduced. At no time did the patient show features of diabetes.

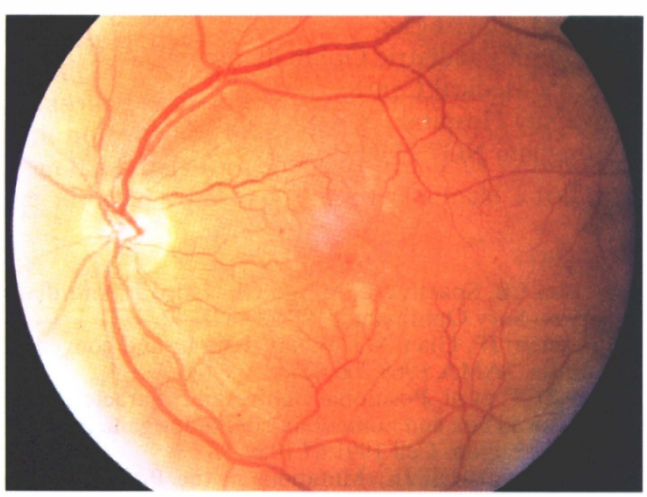

Fig. 1. *Appearance of left macula at presentation. Note the cystic changes at the fovea and scattered microaneurysms. There is an area of retinal thickening just below the fovea.*

Three months after diagnosis he presented to us with visual acuities of 6/5 right 6/60 left and no refractive improvement. Pupillary reflexes and anterior segment appearances were normal, and each retina contained a few small blot haemorrhages in its periphery. The right macula was normal but the left showed cystic changes at the fovea and several microaneurysms (Fig. 1). There were no cotton wool spots or signs of vascular occlusion. Fundus fluorescein angiography confirmed CMO in the left eye (Fig. 2), and several hyperfluorescent points corresponding to the microaneurysms seen on ophthalmoscopy.

We treated the CMO with acetazolamide slow release 250 mg twice daily. There was rapid visual improvement and after 4 weeks acuity had improved to 6/5 right OS left. The CMO appeared less marked on fluorescein angiography, as were the other points of hyperfluorescence (Fig. 3). Treatment was stopped after 7 weeks and within 5 days acuity had fallen to 6/36, with no pinhole improvement. Acetazolamide was restarted with rapid improvement to 6/5 right 6/6 left, and visual symptoms were subsequently controlled with acetazolamide 250 mg daily.

Eight months after presentation the patient underwent sibling allogeneic bone marrow transplant (BMT) from his HLA identical sister and achieved neutrophil engraftment after 27 days.

His vision was remained stable and acetazolamide was withdrawn 4 months after BMT. After a further 6 months visual acuity still measured 6/5 in each eye, with normal colour vision and retinal appearances. Fluorescein angiography at this time showed a marked decrease in hyperfluorescence both at the fovea and at the other macular locations previously exhibiting leakage (Fig. 4).

Discussion

Fundal abnormalities are well-recognised signs of leukaemia at its presentation,[1] and prior to the

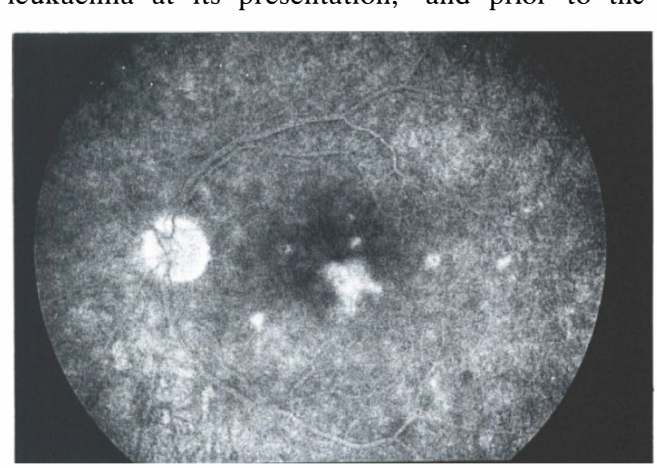

Fig. 2. *Fluorescein angiogram at presentation, showing hyperfluorescence corresponding to macular oedema and scattered microaneurysms.*

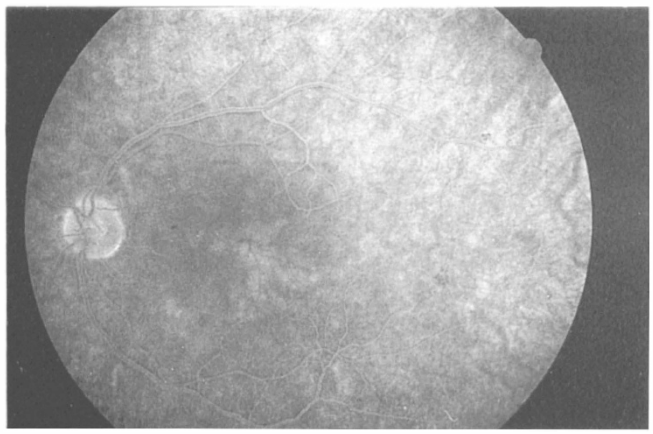

Fig. 3. *Fluorescein angiogram after 4 weeks of acetazolamide treatment. Hyperfluorescence is less marked, suggesting improvement in CMO.*

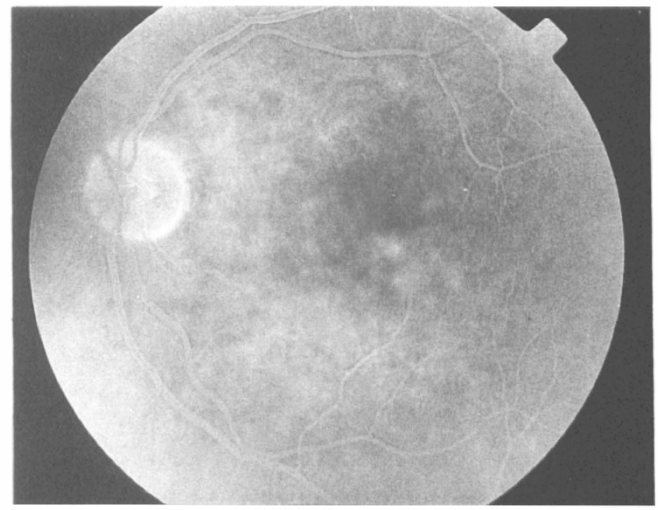

Fig. 4. *Fluorescein angiogram 6 months after bone marrow transplant. Further improvement in CMO appearances are evident.*

advent of bone marrow biopsy, ophthalmologists were routinely consulted for confirmation of the diagnosis. Abnormalities are seen more commonly in the acute than chronic leukaemias.[2] Commonest are retinal haemorrhages, sometimes having a white component (leukaemic cells and platelet aggregates), abnormal retinal vein calibre, vessel sheathing and cotton wool spots.[1] Other features seen in chronic leukaemia are microaneurysms[3] and neovascularisation.[4] Retinal features reflect the combined effects of anaemia and hyperviscosity (capillary closure, microaneurysms and neovascularisation), supporting the concept of retinal vascular stasis and hypoxia.

Choroidal infiltration can be found histopathologically in 59% of eyes with chronic leukaemia.[1] The infiltration tends to be perivascular and the overlying retinal pigment epithelium (RPE) shows varied changes, sometimes accompanied by serous detachment. Fluorescein angiography in such instances shows RPE window defects during the early phase.[5] Kincaid and Green[1] reviewed histopathology for 768 post-mortem eyes from leukaemic patients. They found an 80% incidence of ocular infiltration but no cases of CMO. The literature contains no reference to CMO in a proven case of leukaemia.

Regardless of aetiology, a similar pathology is recognised in all cases of CMO.[6] Serous fluid accumulates and spreads posteriorly within the inner nuclear and outer plexiform layers. At this level interconnecting horizontal processes are rare, which allows the formation of large cystic expansions. The exudate is homogeneous and does not contain cellular remnants. There is no evidence of photoreceptor degeneration, intracellular oedema or obvious capillary endothelial damage, although authors comment on the possibility of degraded endothelial junctional complexes which are too small to be visualised by their technique.[6]

CMO is a recognised feature of several retinal angiopathies,[7] notably diabetic retinopathy, venous occlusive disease and retinal telangiectasia. In 1988 Bird and associates[7] assessed the response of CMO to treatment with acetazolamide, comparing it in their cross-over trial with cyclopenthiazide (which does not inhibit carbonic anhydrase). They observed patients with CMO due to various conditions but found no detectable effect on macular oedema due to primary retinal vascular disease. In contrast, however, patients with inflammatory or aphakic oedema, or inherited outer retinal disease, responded reproducibly to acetazolamide.

Leakage of fluid through the RPE has been noted in both retinitis pigmentosa[8] and primate models for CMO.[9] In experimental models of CMO associated with lens extraction, the blood–retinal barrier at the pigment epithelium was broken, with transudation into extracellular spaces and disruption of the capillary endothelial barrier.[10]

As the response to acetazolamide appeared to be restricted to CMO in patients with pigment epithelial disease, Bird speculates on the possible therapeutic mechanisms.[7] Possibilities include a changing RPE polarity and altered retinal capillary behaviour, with effective maintenance doses of acetazolamide much smaller than those used to control intraocular pressure. Systemic acetazolamide has been shown to affect fluid dynamics across the blood–retinal barrier.[11] This effect is seen in vitrectomised and normal eyes, and in eyes with rhegmatogenous retinal detachment.[12]

Our case exhibited a functional response to acetazolamide and marked improvement in CMO as demonstrated angiographically, and with further improvement following BMT. This raises some interesting points. Early in the course of CML there was CMO despite haematological remission induced by hydroxyurea. This may imply that the cause of CMO was not related to haemodynamic or

hypoxic factors prevailing within the retina. Some modification of fluid dynamics relating to inner retinal and pigment epithelial function was achieved using acetazolamide, and BMT consolidated this benefit. This suggests that definitive treatment of the leukaemia has removed the stimulus for CMO and allowed recovery of vision, despite persisting features of blood–retinal barrier disruption.

S. E. Horgan[1]
S. G. Fraser[2]
P. F. Ferrante[1]
A. Spencer[3]
M. Beaconsfield[1]

[1]Department of Ophthalmology
Oldchurch Hospital
Romford
Essex, UK
[2]Department of Ophthalmology
Whipps Cross Hospital
London, UK
[3]LRF Adult Leukaemia Unit
Hammersmith Hospital
London, UK

Correspondence to:
Mr Simon Horgan, FRCOphth
Moorfields Eye Hospital
City Road
London EC1V 2PD, UK

References

1. Kincaid MC, Green WR. Ocular and orbital involvement in leukaemia. Surv Ophthalmol 1983;27:211–32.
2. Holt JM, Gordon-Smith EC. Retinal abnormalities in diseases of the blood. Br J Ophthalmol 1969;53:145–60.
3. Duke JR, Wilkinson CP, Sigelman S. Retinal microaneurysms in leukaemia. Br J Ophthalmol 1968;52: 368–74.
4. Morse PH, McCready JL. Peripheral retinal neovascularisation with chronic myelocytic leukaemia. Am J Ophthalmol 1971;72:975–8.
5. Kincaid MC, Green WR, Kelley JS. Acute ocular leukaemia. Am J Ophthalmol 1979;87:698–702.
6. Gass JD, Anderson DR, Davis EB. A clinical, fluorescein angiographic, and electron microscopic correlation of cystoid macular edema. Am J Ophthalmol 1985;100:82–6.
7. Cox SN, Hay EH, Bird AC. Treatment of chronic macular oedema with acetazolamide. Arch Ophthalmol 1988;106:1190–5.
8. Spalton DJ, Bird AC, Cleary PE. Retinitis pigmentosa and retinal oedema. Br J Ophthalmol 1978;62:174–82.
9. Tso M. Animal modelling of human cystoid macular edema. Surv Ophthalmol 1984;28(Suppl):512–9.
10. Tso M. Pathology of cystoid macular edema. Ophthalmology 1982;89:902–14.
11. Tsuboi S. Fluid movement across the blood–retinal barrier: a review of studies by vitreous flourophotometry. Jpn J Ophthalmol 1990;34:133–41.
12. Tsuboi S, Pederson JE. Acetazolamide effect on the inward permeability of the blood–retinal barrier. Invest Ophthalmol Vis Sci 1987;28:92–5.

Sir,

Solitary Fibrous Tumour: An Atypical Presentation Within the Orbit

Solitary fibrous tumour is a rare neoplasm which more commonly arises in the pleura.[1–7] Extrapleural sites are recognised including mediastinum,[5,8,9] pericardium,[4] upper respiratory tract, nasal cavities,[10–12] lung parenchyma,[13] peritoneum[4,14] tunica vaginalis of the testis,[15] liver, thyroid and parotid glands.[16] Recently, orbital involvement has been recognised.[17,18]

Case Report

A 23-year-old woman, who gave a 2 year history of a watery left eye, presented with a painless swelling over the left medial canthus which had slowly enlarged over 6 months. Clinical examination revealed a large, rubbery mass with no evidence of proptosis. Ultrasonography of the orbit demonstrated a well-circumscribed lesion medially, of fairly low reflectivity. This was confirmed on CT scanning (Fig. 1).

Exploration and surgical excision of the lesion was performed under general anaesthesia. The upper pole of the lesion was visible just below the medial palpebral ligament, and was adherent to the periosteum and the lacrimal sac. Probes were placed in the upper and lower canaliculus, and the tumour was carefully dissected. Anterior and posterior dacryocystorhinostomy flaps were fashioned, O'Donoghue tubes were inserted, and the wound closed.

Pathology. A bosselated, smooth, grey-brown mass measuring 2.2 × 1.3 × 1 cm was removed from the left orbit. It was firm and showed a whorled, pale grey cut surface. Microscopically, it was composed of

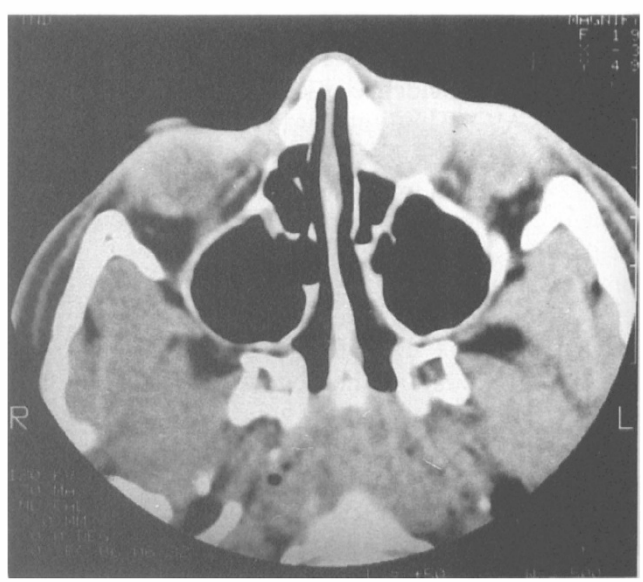

Fig. 1. *CT scan showing lesion in left medial canthal region.*