

diagnosis of enlarged extraocular muscles in computed tomography. *Am J Ophthalmol* 1979;87:503–12.

4. Bermann M, Magee M, Koenig RJ, Kaplan MM, Arscott P, Maastricht J, *et al.* Differential autoantibody responses to thyroid peroxidase in patients with Graves' disease and Hashimoto's thyroiditis. *J Clin Endocrinol Metab* 1993;77:1098–101.
5. Patrinely JR, Osborn AG, Anderson RL, Whiting AS. Computed tomographic features of nonthyroid extraocular muscle enlargement. *Ophthalmology* 1989;96:1038–47.

Sir,

We read with interest King and colleagues' article on *in situ* degradation of 11–0 polyester Mersilene suture, but question their conclusion that whilst there is no clinical evidence of biodegradation, electron microscopic evidence of slow biodegradation of the suture material is seen from 22 months post-operatively.¹

Both the electron micrographs in their article show circumferential marks on the suture material adjacent to the knot, from buried sites, that should therefore be least subject to biodegradation. Clinically evident biodegradation of nylon corneal sutures occurs mostly on the surface of the globe. What do these marks represent?

It is likely that these are compression marks due to sharp angulation of suture materials adjacent to knots. These marks are present immediately after knot-tying using Mersilene material, but not nylon. Fig. 1 shows a 2/1/1 reef knot tied with 10–0 Mersilene removed immediately after tying and turning on a porcine corneal cataract section. Compression marks occur where the suture material has to turn sharply.

Mersilene corneal sutures are undoubtedly much safer to leave unremoved compared with nylon ones,² but King's data confirm that even Mersilene may not be safe if left unremoved. Eighteen sets of sutures in 231 eyes (7.8%) had become loose prior to

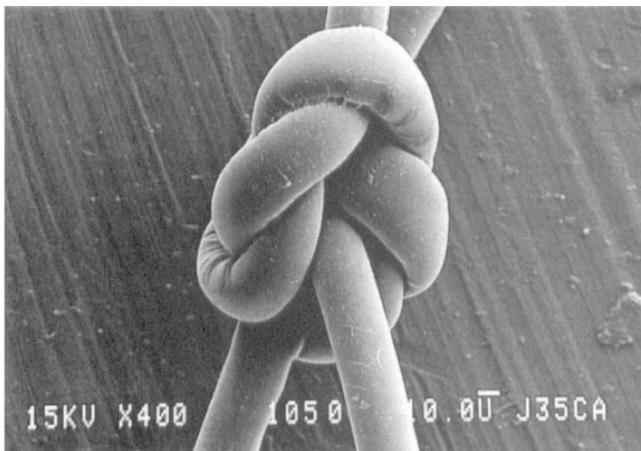


Fig. 1. Electron micrograph of a 2/1/1 reef knot tied with 10–0 Mersilene removed immediately after tying and turning on a porcine corneal cataract section. Compression marks occur where the suture material has to turn sharply.

discharge from clinic, necessitating removal (follow-up 2–20 months). In addition, of 107 eyes of patients invited for examination, 7 sutures (6.5%) had to be removed because of loosening. Six of the 7 eyes (85.7%) were asymptomatic, which is comforting to the patient, but provides less warning that they are at risk of infective keratitis. Data on infection would be welcome.

The natural history of extracapsular cataract extraction is a trend towards against-the-rule surgically induced astigmatism,³ which may be enhanced by early removal of sutures. The longevity of Mersilene will allow *later* removal of sutures, but this should be performed routinely none-the-less. Currently, only sutureless and scleral section surgery with sutures covered by conjunctiva allow early safe discharge of cataract patients within days.

Christopher Liu
Christopher Hammond
Richard Bowman
Anthanasios Vakalis
Wood Yee Chan

Cambridge and Hong Kong

Correspondence to:
Christopher Liu
West Norwich Hospital
Bowthorpe Road
Norwich NR2 3TU
UK

References

1. King AJ, Deane J, Sandford-Smith J. *In situ* degradation of 11/0 polyester (Mersilene) suture material following cataract surgery. *Eye* 1994;8:676–9.
2. Smith LF, Hugkulstone CE. Long-term survival of corneal sutures: Mersilene vs nylon. *Eur J Implant Refract Surg* 1994;6:348–50.
3. Drews RC. Astigmatism after cataract surgery: nylon versus Mersilene. *J Cataract Refract Surg* 1995;21:70–2.

Sir,

We are pleased to have the opportunity to clarify some of the points raised by Liu and colleagues in their letter. We agree that compression marks occur immediately on tying Mersilene (polyester) sutures as demonstrated by their electron micrograph. However, our comments in the original article were directed at the grooves highlighted in the magnified image. These show lamination of the suture structure rather than compression in the inferior limb leaving the knot and are distinct from the compression grooves. This form of surface change has been reported by other authors, notably Dvorak,¹ who describes surface degradation with lamination of polyester sutures left in dog muscle for 210 days. He found, as we also did, that these changes were more common around areas of mechanical stress and