

ARTICLE

The lymphatic phenotype in Turner syndrome: an evaluation of nineteen patients and literature review

Giles Atton¹, Kristiana Gordon², Glen Brice^{1,2}, Vaughan Keeley³, Katie Riches³, Pia Ostergaard⁴, Peter Mortimer⁴ and Sahar Mansour^{*,1}

Turner syndrome is a complex disorder caused by an absent or abnormal sex chromosome. It affects 1/2000–1/3000 live-born females. Congenital lymphoedema of the hands, feet and neck region (present in over 60% of patients) is a common and key diagnostic indicator, although is poorly described in the literature. The aim of this study was to analyse the medical records of a cohort of 19 Turner syndrome patients attending three specialist primary lymphoedema clinics, to elucidate the key features of the lymphatic phenotype and provide vital insights into its diagnosis, natural history and management. The majority of patients presented at birth with four-limb lymphoedema, which often resolved in early childhood, but frequently recurred in later life. The swelling was confined to the legs and hands with no facial or genital swelling. There was only one case of suspected systemic involvement (intestinal lymphangiectasia). The lymphoscintigraphy results suggest that the lymphatic phenotype of Turner syndrome may be due to a failure of initial lymphatic (capillary) function.

European Journal of Human Genetics (2015) 23, 1634–1639; doi:10.1038/ejhg.2015.41; published online 25 March 2015

INTRODUCTION

Turner syndrome is one of the most common forms of chromosomal aneuploidy. The majority of cases (~45%) are characterised by sex chromosome monosomy (45,X),¹ with the remaining cases caused by a structurally abnormal X-chromosome or mosaicism. Turner syndrome is associated with prenatal lethality, with ~98% of 45,X conceptuses spontaneously aborting.² The clinical phenotype is variable and can be subtle, although it most commonly presents with short stature and primary amenorrhoea (60–90% cases).³ More variable features include congenital lymphoedema of the hands and feet (see Figure 1), distinct craniofacial features (including a low posterior hairline and low-set ears), physical malformations (including a webbed neck (see Figure 1) and widely spaced nipples), cardiovascular (~50% of patients⁴), thyroid and renal complications (~39% patients⁵), socio-behavioural difficulties and gonadal dysgenesis (from which amenorrhoea and infertility often result).^{3,5–8}

Lymphoedema is a chronic, debilitating and incurable condition. It is characterised by the accumulation of lymph and other elements (commonly proteins) in the interstitial spaces. This is due to a failure of the lymph-conducting system. A compromised lymphatic system results in lymphatic insufficiency, with swelling and fluid retention in one or more limbs or body segment (eg, head, neck or genitalia) or systemically with gut, pericardial or respiratory involvement. Primary lymphoedema has many genetic causes.⁹ Like Turner syndrome, Milroy disease may present with congenital pedal oedema; however, hand swelling is rarely noted in Milroy disease and this condition affects males and females equally.¹⁰ Lymphoscintigraphy (imaging of peripheral lymph drainage through interstitial injection of a radiolabelled colloid and gamma camera detection) is the gold-standard

investigation for lymphoedema, but it is not routinely performed in all centres.¹¹

Lymphoedema of the hands and feet is thought to be present in >60% of infants with Turner syndrome. This facilitates an early diagnosis in an approximately one-third of patients.² Swollen hands and feet in a female neonate always suggest a diagnosis of Turner syndrome.² Lymphoedema is thought to result from lymphatic hypoplasia or aplasia of the lymphatic tracts, which results in stasis of lymph fluid and swelling.^{2,8,12} Many phenotypic features of Turner syndrome are believed to result from *in utero* oedema.² Cervical lymphatic system distension manifests as a webbed neck and a low posterior hairline² (observable as increased nuchal translucency on ultrasound scanning (USS) at 10–14 weeks^{8,12}). *In utero* facial oedema manifests as epicanthic folds and peripheral lymphoedema manifests as swollen hands and feet, deep digital skin fold creases and small dysplastic toenails. Prenatal lethality in Turner syndrome may also be due to an underlying lymphatic abnormality, resulting in fluid imbalance and hydrops fetalis.¹³

There is a lack of detailed medical literature regarding the lymphatic phenotype of Turner syndrome. The literature that is available reports that lymphoedema is most commonly found in Turner syndrome patients with a non-mosaic 45,X karyotype and usually resolves by 2 years of age, although it can persist throughout life and recur.^{2,14,15} One key study, a retrospective questionnaire study focusing on the progression of lymphoedema in 42 Turner syndrome patients, found that 76% patients had swelling at birth and 55% had hand and feet swelling. Swelling resolved in 19% (87% of these by 2 years), improved in 31%, worsened in 10% and was unchanged in 40%.¹⁶ One lymphoscintigraphic study of Turner syndrome patients has demonstrated various lymphatic pathological features and identified

¹South West Thames Regional Genetics Service, St George's Healthcare NHS Trust, London, UK; ²Department of Dermatology, St. George's Hospital NHS Trust, London, UK; ³Lymphoedema Clinic, Derby Hospitals Foundation NHS Trust, Derby, UK; ⁴Lymphovascular Research Unit, Division of Cardiovascular and Cell Sciences, St George's, University of London, London, UK

*Correspondence: Dr S Mansour, South West Thames Regional Genetics Service, St George's Healthcare NHS Trust, Tooting, London SW17 0RE, UK. Tel: +44 20 8725 0957; Fax: +44 20 8725 3444; E-mail: smansour@sgul.ac.uk

Received 21 September 2014; revised 19 December 2014; accepted 6 January 2015; published online 25 March 2015

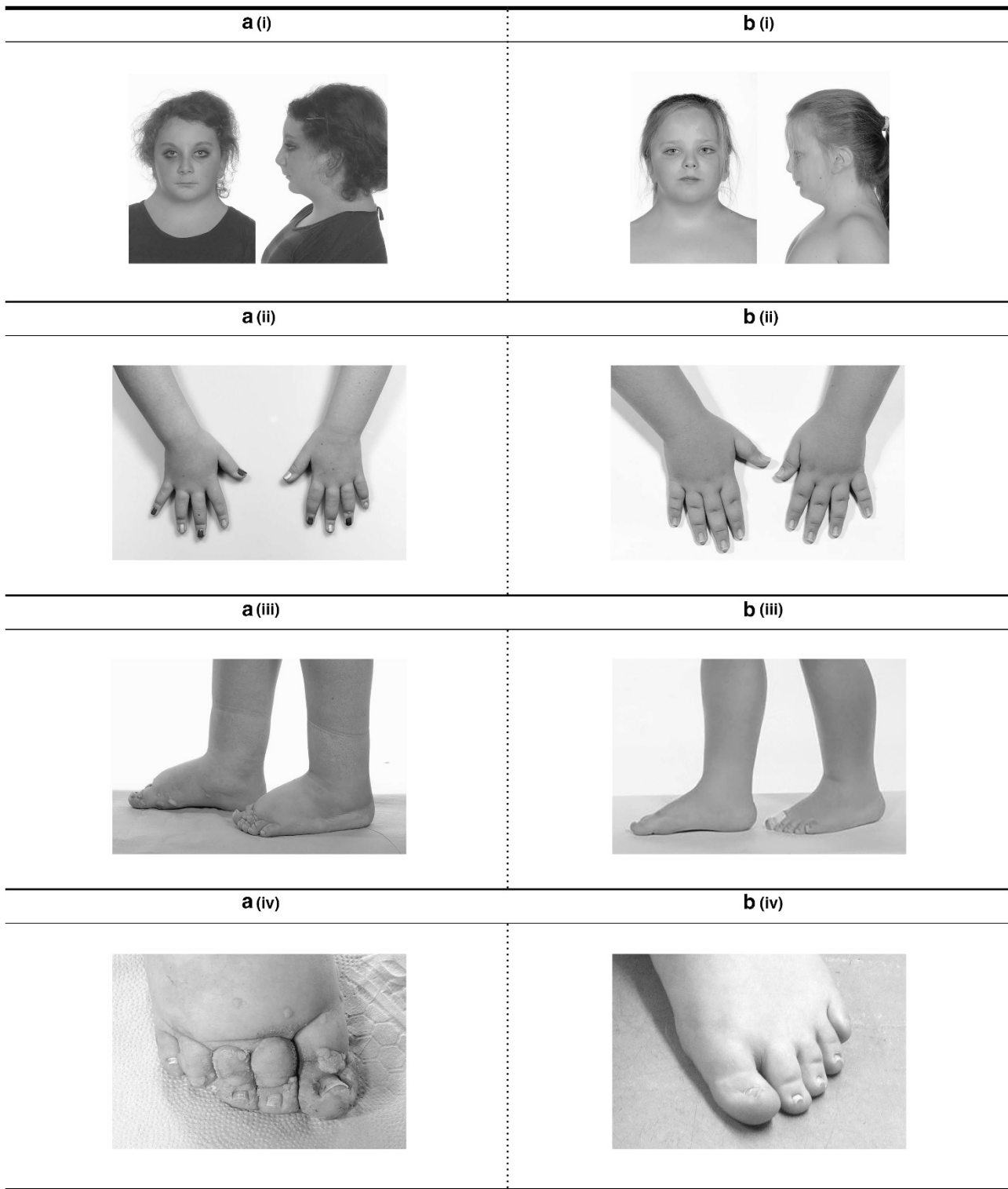


Figure 1 Clinical images of patient 7 (a(i–iv)) and patient 6 (b(i–iv)). (a(i), b(i)) Anterior and lateral view of the head and neck demonstrating some of the following features of Turner syndrome: a webbed neck, a low posterior hairline, low-set posteriorly rotated ears and a broad chest. (a(ii), b(ii)) Hands: Bilateral swelling of the hands and fingers. (a(iii), b(iii)) Below-knee: Bilateral swelling of the legs and feet. a(iv) Toes: Swelling with papillomatosis, small dysplastic toenails and deep digital skin fold creases. B(iv) Toes: Swelling with small dysplastic toenails.

aplasia, hypoplasia and hyperplasia of the peripheral lymphatics in Turner syndrome patients.¹⁷

Identification of causative genes for the lymphatic phenotype in Turner syndrome has proven difficult. To date, only one gene, short-

stature homeobox gene (*SHOX*), has been confirmed to cause phenotypic features of Turner syndrome, specifically short stature and skeletal abnormalities.^{18,19} The lymphatic phenotype in Turner syndrome is thought to be due to haploinsufficiency of an *X/Y*

Table 1 A summary of the clinical reports from the 19 Turner syndrome patients

Demographics		Turner syndrome			Lymphoedema			Management	
Patient	Age	Age of diagnosis	Karyotype	Initial onset	Initial site/ current site	Progression	Complications	Management	
1	4	Prenatal at 12 weeks	45,X	Birth	4 limbs/4 limbs	Persistent	None	Skin and nail care	
2	43	19 years	45,X	Birth	4 limbs/4 limbs	Persistent	Cellulitis-1 infection	Skin and nail care	
3	10	Infancy	45,X	Birth	4 limbs/4 limbs	Persistent	↓IgA, diarrhoea (suspected Intestinal lymphangiectasia)	Finger and toe gloves	
4	2	Prenatal at 16 weeks	45,X	Birth	4 limbs/4 limbs	Improving slowly	None	Medium-chain triglyceride diet (for suspected intestinal lymphangiectasia)	
5	13	Prenatal	45,X	Birth	Bilateral LL/bilateral LL	Persistent	Cellulitis-1 infection	Skin and nail care	
6	12	Infancy	45,X	10yrs	4 limbs/4 limbs	Exacerbated since age 1.1 years	None	Custom footwear	
7	13	Infancy	45,X	Birth	4 limbs/4 limbs	Progressively worse – particularly the left LL	None	Compression garments	
8	12	Infancy	45,X	Birth	4 limbs/4 limbs	Persistent	None	Compression garments	
9	2	Infancy	45,X	Birth	4 limbs/4 limbs	LL worse since birth	None	Skin and nail care	
10	26	Infancy	UA	Birth	4 limbs/right LL	UL improving slowly	None	Compression garments	
11	10	Infancy	45,X	Birth	4 limbs/bilateral LL	Exacerbated in all limbs - particularly LL	None	Simple lymph drainage	
12	7	Infancy	45,X	Birth	4 limbs/left LL	Variable severity	None	Compression garments	
13	19	14 years	45,X	Birth	4 limbs/bilateral LL	Resolved in 3-limbs (by 2 years)	None	Manual lymph drainage	
14	4	Prenatal	45,X	Birth	4 limbs/left LL	Persistent right foot swelling	None	Compression garments	
15	12	Infancy	45,X	Birth	4 limbs/bilateral LL	Resolved in UL (3 years)	None	Manual lymph drainage	
16	10	Infancy	45,X	Birth	4 limbs/left LL	Persistent in LL	None	Toe gloves. Bandaging	
17	23	Infancy	45,X	Birth	4 limbs/bilateral LL	Resolved in left foot	None	Compression garments	
18	37	Infancy	Mosaic	Birth	4 limbs/right LL	Resolved in UL	None	Compression garments	
19	45	Infancy	45,X	Birth	4 limbs/4-limb	Resolved in LL	None	Simple lymph drainage	
					4 limbs/4 limbs	Resolved aged 18 months	None	Compression garments	
					4 limbs/left LL	Recurrent in UL and left LL aged 10 years	Cellulitis-1 infection	Skin and nail care	
					4 limbs/right LL	Resolved aged 4yrs	Cellulitis-4 infections	Compression garments	
					4 limbs/4-limb	Recurrent in left LL aged 18 years	Recurrent cellulitis-2-3 infections a year	Decongestive lymphatic therapy	
					4 limbs/4-limb	Recurrent in right LL aged 37 years		Toe gloves	
					4 limbs/4-limb	Resolved in infancy		Compression garments	
					4 limbs/4-limb	Recurrent in UL and LL aged 40 years		Decongestive lymphatic therapy	
					4 limbs/4-limb	Recurrent in UL and LL aged 40 years		Penicillin prophylaxis for cellulitis	

Abbreviations: LL, lower limb; UA, Unattainable; UL, upper limb.

homologous putative lymphogenic gene, other than the *SHOX* gene, that escapes X inactivation.^{18,19} Two 'critical regions' for the lymphogenic gene have been proposed at chromosomal regions Xp11.4¹⁸ and Yp11.2,²⁰ but no specific genes have been confirmed.

The diagnosis and treatment of lymphoedema are as it is for any primary lymphoedema, namely Decongestive Lymphatic Therapy (DLT),²¹ but the lymphatic phenotype in Turner syndrome has specific idiosyncrasies, which are not widely reported in the literature. This study aims to elucidate the key features of the lymphatic phenotype in Turner syndrome and provide vital insights into its diagnosis, natural history and management.

MATERIALS AND METHODS

Study subjects

Patients were recruited and seen at three specialist primary lymphoedema clinics at St George's Hospital (London), the Royal Derby Hospital (Derby) and Queen's Medical Centre (Nottingham). The study cohort consisted of 19 female patients all of whom had confirmed Turner syndrome: 18 had a karyotype report available and one did not have a formal karyotype report available but their medical records clearly and consistently document a diagnosis of Turner syndrome. All 19 patients had lymphoedema on clinical inspection at their corresponding clinics. The study sample was ascertained at each clinic by identifying all patients with Turner syndrome and lymphoedema from hospital databases.

Clinical data

Clinical data were collected from patient notes, genetic notes, electronic records and imaging records (specifically lymphoscintigraphy reports) and located by the use of patient-specific numerical identifiers. All notes were thoroughly analysed and examined and any important information was inserted into a spreadsheet pro forma. A thorough documentation of each patient's demographics, history of Turner syndrome and history of lymphoedema was performed. All patients were examined by at least one of the authors (PM, VK, KG, SM and GWB). Ethical approval was covered by the 'Analysis of genes and their functions in patients with primary lymphoedema' study, REC Reference: 05/Q0803/267.

Lymphoscintigraphy

Lymphoscintigraphy scan images or reports were obtained for those patients who had undergone the investigation. Scan images were reported blind with no knowledge of clinical details. An attempt was made to interpret the lymphatic fault to determine whether there was a consistent mechanism to explain the lymphoedema.

RESULTS

Demographics

The mean age and age range of the study cohort were 16.0 years (SD \pm 13.13 years) and 2–45 years, respectively (see Table 1). The ethnic origin of 16 patients was classed as 'White British', 2 as 'any other white background (white)' and 1 as 'any other mixed background (black)'.

Clinical data

Table 1 provides summary information for the age, karyotype, age of onset, natural history, systemic involvement and the complications from lymphoedema for each patient.

Turner syndrome history

Seventy-nine percent (15/19) of patients were diagnosed with Turner syndrome postnatally. The majority of these patients had suspected Turner syndrome at birth owing to swollen hands and feet, although two patients were diagnosed at a later age (14 and 19 years). The remaining 21% (4/19) were diagnosed prenatally, initially suspected owing to an increased nuchal translucency on USS and confirmed by

amniocentesis. Eighty-nine percent (17/19) of patients had a 45,X karyotype, 5% (1/19) of patients had mosaic Turner syndrome and one karyotype was unattainable.

Natural history of lymphoedema

Ninety-five percent (18/19) of the patients presented with four-limb swelling at birth. Lymphoedema was persistent for most individuals throughout life with 15 of the 19 patients (79%) having persistent lymphoedema in at least one limb. In 63% (12/19) of patients, the swelling improved over time and of these, 33% (4/12) had swelling that completely resolved at a young age (<4 years) but later recurred in at least one limb. One patient (5%) developed lymphoedema for the first time at the age of 10 years old. One patient (5%) presented with suspected systemic disease, intestinal lymphangiectasia, but this was not confirmed. There was no evidence of any facial or genital swelling. Five of the patients (26%) suffered from cellulitis (two of them had recurrent infections), a common complication of lymphoedema. The lymphatic phenotype of two patients is shown in Figure 1.

Lymphoscintigraphy results

Lymphoscintigraphy had been performed on six patients with clinically identifiable lymphoedema. Written lymphoscintigraphy reports were available for all six patients. The lymphoscintigram images for one patient were unavailable and our own interpretation of these images was, therefore, not possible in this case. The available lymphoscintigram images for five patients showed similarities, namely a failure of tracer uptake and absorption into the lymph system with retention of the bulk of tracer at the site of injection after 2 h. Figure 2 documents the quantitative lymphoscintigraphy values. As a result of poor uptake of tracer into the lymphatic system, there was reduced imaging of downstream drainage channels and lymph nodes in most cases (see Figure 2). These features suggest a failure of initial lymphatic (capillary) function.

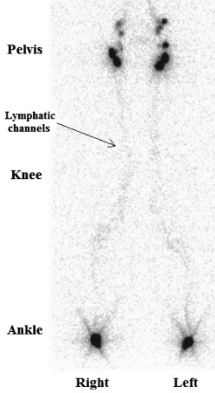
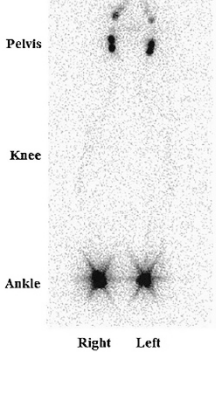
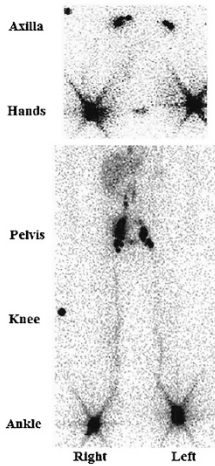
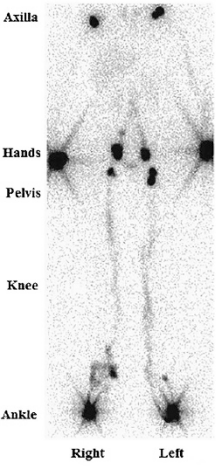
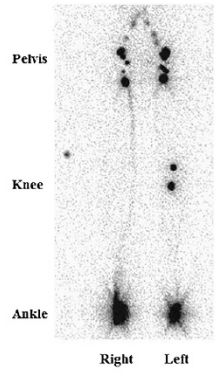
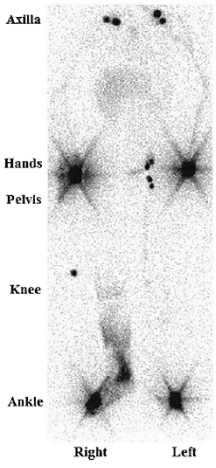
Management

Table 1 summarises the management for each patient. The treatment given was largely proportional to the severity of lymphoedema: from skin and nail care in less severe cases to compression stockings, manual lymph drainage and DLT in more severe cases. Compression garments were the mainstay of treatment for this cohort of patients.

DISCUSSION

Almost all patients in this study presented with four-limb swelling at birth. The majority had lymphoedema persisting throughout life. This corroborates what is already well documented in the literature. In four patients, the swelling completely resolved but recurred in at least one limb. This recurrence has been described in Turner syndrome patients before,^{2,14,15} but it is a phenomenon that is poorly documented and described. In two of these four patients, the lymphoedema resolved in early infancy. In the remaining two patients it resolved in early childhood. The timescale of recurrence was variable, ranging from 8.5 to ~40 years between the initial resolution and recurrence. The site of recurrence was also variable (see Table 1). The results of this study also indicate that systemic lymphatic involvement is a rare feature of the Turner phenotype with only one patient presenting with suspected (but not proven) intestinal lymphangiectasia. Interestingly, only one of the patients had a mosaic form of Turner syndrome. The majority had 45,X in all cells examined.

The most significant discovery from this study was the consistent abnormality observed on the lymphoscintigraphy images. The images suggested that the lymphatic abnormality in Turner syndrome is due

Qualitative Lymphoscintigraphy	Quantitative Lymphoscintigraphy	Qualitative Lymphoscintigraphy	Quantitative Lymphoscintigraphy																		
a Normal Control Individual		b Patient 2																			
 <p>Pelvis Lymphatic channels Knee Ankle Right Left</p>	<p>Average quantification data for normal limbs:</p> <p><80% retention at depot</p> <p>>8% uptake in regional lymph nodes</p>	 <p>Pelvis Knee Ankle Right Left</p>	<p>Lower Limb</p> <table border="1"> <thead> <tr> <th></th> <th>Left</th> <th>Right</th> </tr> </thead> <tbody> <tr> <td>Depot Retention</td> <td>100%</td> <td>97.4%</td> </tr> <tr> <td>Ilio-inguinal Nodal Uptake</td> <td>4.6%</td> <td>3.7%</td> </tr> </tbody> </table>		Left	Right	Depot Retention	100%	97.4%	Ilio-inguinal Nodal Uptake	4.6%	3.7%									
				Left	Right																
Depot Retention	100%	97.4%																			
Ilio-inguinal Nodal Uptake	4.6%	3.7%																			
c Patient 6		d Patient 8																			
 <p>Axilla Hands Pelvis Knee Ankle Right Left</p>	<p>Upper Limb</p> <table border="1"> <thead> <tr> <th></th> <th>Left</th> <th>Right</th> </tr> </thead> <tbody> <tr> <td>Depot Retention</td> <td>96.1%</td> <td>92.3%</td> </tr> <tr> <td>Axillary Nodal Uptake</td> <td>1.1%</td> <td>2.7%</td> </tr> </tbody> </table>		Left	Right	Depot Retention	96.1%	92.3%	Axillary Nodal Uptake	1.1%	2.7%	 <p>Axilla Hands Pelvis Knee Ankle Right Left</p>	<p>Upper Limb</p> <table border="1"> <thead> <tr> <th></th> <th>Left</th> <th>Right</th> </tr> </thead> <tbody> <tr> <td>Depot Retention</td> <td>93.6%</td> <td>92.5%</td> </tr> <tr> <td>Axillary Nodal Uptake</td> <td>3.7%</td> <td>3.0%</td> </tr> </tbody> </table>		Left	Right	Depot Retention	93.6%	92.5%	Axillary Nodal Uptake	3.7%	3.0%
		Left	Right																		
Depot Retention	96.1%	92.3%																			
Axillary Nodal Uptake	1.1%	2.7%																			
	Left	Right																			
Depot Retention	93.6%	92.5%																			
Axillary Nodal Uptake	3.7%	3.0%																			
<p>Lower Limb</p> <table border="1"> <thead> <tr> <th></th> <th>Left</th> <th>Right</th> </tr> </thead> <tbody> <tr> <td>Depot Retention</td> <td>95.2%</td> <td>72.7%</td> </tr> <tr> <td>Ilio-inguinal Nodal Uptake</td> <td>2.8%</td> <td>14.8%</td> </tr> </tbody> </table>		Left	Right	Depot Retention	95.2%	72.7%	Ilio-inguinal Nodal Uptake	2.8%	14.8%	<p>Lower Limb</p> <table border="1"> <thead> <tr> <th></th> <th>Left</th> <th>Right</th> </tr> </thead> <tbody> <tr> <td>Depot Retention</td> <td>80.1%</td> <td>82.5%</td> </tr> <tr> <td>Ilio-inguinal Nodal Uptake</td> <td>7.6%</td> <td>5.4%</td> </tr> </tbody> </table>		Left	Right	Depot Retention	80.1%	82.5%	Ilio-inguinal Nodal Uptake	7.6%	5.4%		
		Left	Right																		
Depot Retention	95.2%	72.7%																			
Ilio-inguinal Nodal Uptake	2.8%	14.8%																			
	Left	Right																			
Depot Retention	80.1%	82.5%																			
Ilio-inguinal Nodal Uptake	7.6%	5.4%																			
e Patient 18		f Patient 19																			
 <p>Pelvis Knee Ankle Right Left</p>	<p>Lower Limb</p> <table border="1"> <thead> <tr> <th></th> <th>Left</th> <th>Right</th> </tr> </thead> <tbody> <tr> <td>Depot Retention</td> <td>72.4%</td> <td>80.9%</td> </tr> <tr> <td>Ilio-inguinal Nodal Uptake</td> <td>14.3%</td> <td>9.1%</td> </tr> </tbody> </table>		Left	Right	Depot Retention	72.4%	80.9%	Ilio-inguinal Nodal Uptake	14.3%	9.1%	 <p>Axilla Hands Pelvis Knee Ankle Right Left</p>	<p>Upper Limb</p> <table border="1"> <thead> <tr> <th></th> <th>Left</th> <th>Right</th> </tr> </thead> <tbody> <tr> <td>Depot Retention</td> <td>93.9%</td> <td>92.6%</td> </tr> <tr> <td>Axillary Nodal Uptake</td> <td>2.3%</td> <td>2.2%</td> </tr> </tbody> </table>		Left	Right	Depot Retention	93.9%	92.6%	Axillary Nodal Uptake	2.3%	2.2%
		Left	Right																		
Depot Retention	72.4%	80.9%																			
Ilio-inguinal Nodal Uptake	14.3%	9.1%																			
	Left	Right																			
Depot Retention	93.9%	92.6%																			
Axillary Nodal Uptake	2.3%	2.2%																			
<p>Lower Limb</p> <table border="1"> <thead> <tr> <th></th> <th>Left</th> <th>Right</th> </tr> </thead> <tbody> <tr> <td>Depot Retention</td> <td>91.4%</td> <td>77.8%</td> </tr> <tr> <td>Ilio-inguinal Nodal Uptake</td> <td>1.3%</td> <td>0.1%</td> </tr> </tbody> </table>		Left	Right	Depot Retention	91.4%	77.8%	Ilio-inguinal Nodal Uptake	1.3%	0.1%	<p>Lower Limb</p> <table border="1"> <thead> <tr> <th></th> <th>Left</th> <th>Right</th> </tr> </thead> <tbody> <tr> <td>Depot Retention</td> <td>91.4%</td> <td>77.8%</td> </tr> <tr> <td>Ilio-inguinal Nodal Uptake</td> <td>1.3%</td> <td>0.1%</td> </tr> </tbody> </table>		Left	Right	Depot Retention	91.4%	77.8%	Ilio-inguinal Nodal Uptake	1.3%	0.1%		
		Left	Right																		
Depot Retention	91.4%	77.8%																			
Ilio-inguinal Nodal Uptake	1.3%	0.1%																			
	Left	Right																			
Depot Retention	91.4%	77.8%																			
Ilio-inguinal Nodal Uptake	1.3%	0.1%																			

to a failure of lymph absorption by the initial lymphatic capillaries. Biopsy studies would be required to determine whether there is an anatomical reduction in the number of initial lymphatic vessels or whether these initial vessels are present in normal numbers but are dysfunctional. The fact that lymphoedema can resolve would suggest a functional rather than a structural mechanism. A functional failure of

lymph uptake and transport by initial lymphatics is the proven mechanism in Milroy disease where the causal mutation is in *FLT4* (the gene for vascular endothelial growth factor receptor 3, VEGFR3²²). The upper limbs are rarely involved in Milroy disease.²³ The lymphoscintigraphic manifestation of Turner syndrome has been described once before in a study of 18 Turner syndrome patients,¹⁷

Figure 2 Anteroposterior lymphoscintigrams at 2 h following an interstitial injection of a radiolabelled colloid tracer (Technetium (99mTc)). **(a)** Normal control individual: Lower limb lymphoscintigram. Patent lymphatic channels and inguinal nodes imaged. Average quantification data for normal limbs demonstrate <80% retention at depot and >8% uptake in regional lymph nodes. **(b)** Patient 2, lower limb lymphoscintigram: Symmetrical drainage to inguinal lymph nodes with reduced imaging of the lymphatic channels bilaterally. Quantitative lymphoscintigraphy demonstrates a significant bilateral retention of tracer in the feet after 2 h of 100% (left) and 97.4% (right). **(c)** Patient 6, four-limb lymphoscintigram: Upper limbs: Quantitative lymphoscintigraphy demonstrates a retention of tracer in the hands after 2 h of 96.1% (left) and 92.3% (right) with a concurrent markedly reduced axillary uptake of 1.1% (left) and 2.7% (right). Lower limb: Quantitative lymphoscintigraphy demonstrates a retention of tracer in the left foot (95.2%) but not the right (72.7%). Bilateral lower limb swelling that is worse on the left is commensurate with these lymphoscintigraphy findings. **(d)** Patient 8, four-limb lymphoscintigram: Upper limbs: Quantitative lymphoscintigraphy demonstrates a retention of tracer in the hands after 2 h of 93.6% (left) and 92.5% (right). Lower limb: Evidence of rerouting in the right lower limb. Quantitative lymphoscintigraphy demonstrates that the percentage retention of tracer in the feet after 2 h is 80.1% (left) and 82.5% (right). Abnormalities are observed in the imaged drainage routes rather than drainage function. **(e)** Patient 18, lower limb lymphoscintigram: Bilateral drainage to the inguinal lymph nodes. Reduced imaging of lymphatic channels on the left. Imaging of popliteal lymph nodes on the left suggests deep rerouting. Quantitative lymphoscintigraphy demonstrates an adequate percentage drainage of tracer to the ilioinguinal lymph nodes after 2 h of 14.3% (left) and 9.1% (right). Reduced drainage on the right is consistent with clinical lymphoedema of the right lower limb. **(f)** Patient 19, four-limb lymphoscintigram: Upper limb: Quantitative lymphoscintigraphy demonstrates a retention of tracer in the hands after 2 h of 93.9% (left) and 92.6% (right). Lower limb: Asymmetrical drainage to inguinal lymph nodes with no main lymphatic tracts imaged and significant dermal rerouting. Quantitative lymphoscintigraphy determined that the percentage retention of tracer in the feet after 2 h is 91.4% (left) and 77.8% (right). Ilioinguinal nodal uptake was markedly reduced at 1.3% (left) and 0.1% (right).

where 15 showed an abnormal lymphoscintigraphic pattern, but there was no quantification relating to initial lymphatic function. Furthermore, only four of the 15 patients had clinically identifiable lymphoedema at some stage in their lives. Hypoplasia was the dominant lymphatic impairment demonstrated in their cohort. Our study identified initial lymphatic failure as the dominant pattern of lymphatic system impairment in all five patients with clinically identifiable lymphoedema and available lymphoscintigrams.

There is ascertainment bias in this observational study, as only patients being followed up in the lymphoedema clinics were considered.

We can conclude that Turner syndrome frequently presents at birth with four-limb lymphoedema, which often resolves to a certain degree in early childhood but may recur at any age. There is rarely systemic involvement or swelling of the face, trunk or genitalia. The lymphoscintigraphy results suggest that the mechanism for lymphoedema in Turner syndrome is a failure of initial lymphatic function.

Future work could involve a prospective study of patients with Turner syndrome presenting at birth to look at the natural history of lymphoedema with further investigation of Turner syndrome patients with and without lymphoedema.

CONFLICT OF INTEREST

The authors declare no conflict of interest.

ACKNOWLEDGEMENTS

We extend our thanks to the patients and their families and the British Heart Foundation for funding the work of Dr Kristiana Gordon (FS/11/40/28739) and Dr Pia Ostergaard (PG/10/58/28477).

- 1 Wolff DJ, Van Dyke DL, Powell CM: Working Group of the ACMG Laboratory Quality Assurance Committee Laboratory guideline for Turner syndrome. *Genet Med* 2010; **12**: 52–55.
- 2 Gunther DF, Sybert VP: Lymphatic, tooth and skin manifestations in Turner syndrome. *Int Congr Ser* 2006; **1298**: 58–62.

- 3 Zhong Q, Layman LC: Genetic considerations in the patient with Turner syndrome - 45, X with or without mosaicism. *Fertil Steril* 2012; **98**: 775–779.
- 4 Matura LA, Ho VB, Rosing DR, Bondy CA: Aortic dilatation and dissection in Turner syndrome. *Circulation* 2007; **116**: 1663–1670.
- 5 Sybert VP, McCauley E: Turner's Syndrome. *N Engl J Med* 2004; **351**: 1227–1238.
- 6 Morgan T: Turner syndrome: diagnosis and management. *Am Fam Physician* 2007; **76**: 405–410.
- 7 Oliveira RM, Verreschi IT, Lipay MV, Eça LP, Guedes AD, Bianco B: Y chromosome in Turner syndrome: review of the literature. *Sao Paulo Med J* 2009; **127**: 373–378.
- 8 Rizell S: Dentofacial morphology in Turner syndrome karyotypes. *Swed Dent J Suppl* 2012; **225**: 7–98.
- 9 Connell FC, Gordon K, Brice G *et al*: The classification and diagnostic algorithm for primary lymphatic dysplasia: an update from 2010 to include molecular findings. *Clin Genet* 2013; **84**: 303–314.
- 10 Gordon K, Spiden SL, Connell FC *et al*: FLT4/VEGFR3 and Milroy disease: novel mutations, a review of published variants and database update. *Hum Mutat* 2013; **34**: 23–31.
- 11 Keeley V: The use of lymphoscintigraphy in the management of chronic oedema. *J Lymphoedema* 2006; **1**: 42–57.
- 12 von Kaisenberg CS, Wiltling J, Dörk T *et al*: Lymphatic capillary hypoplasia in the skin of fetuses with increased nuchal translucency and Turner's syndrome: comparison with trisomies and controls. *Mol Hum Reprod* 2010; **16**: 778–789.
- 13 Canki N, Warburton D, Byrne J: Morphological characteristics of monosomy X in spontaneous abortions. *Ann Genet* 1988; **31**: 4–13.
- 14 Elsheikh M, Dunger DB, Conway GS, Wass JA: Turner's syndrome in adulthood. *Endocr Rev* 2002; **23**: 120–140.
- 15 Lowenstein EJ, Kim KH, Glick SA: Turner's syndrome in dermatology. *J Am Acad Dermatol* 2004; **50**: 767–776.
- 16 Welsh J, Todd M: Incidence and Characteristics of lymphedema in Turner's Syndrome. *Lymphology* 2006; **39**: 152–153.
- 17 Bellini C, Di Battista E, Boccardo F *et al*: The role of Lymphoscintigraphy in the Diagnosis of Lymphedema in Turner Syndrome. *Lymphology* 2009; **42**: 123–129.
- 18 Boucher CA, Sargent CA, Ogata T, Affara NA: Breakpoint analysis of Turner patients with partial Xp deletions: implications for the lymphoedema gene location. *J Med Genet* 2001; **38**: 591–598.
- 19 Ogata T, Muroya K, Matsuo N *et al*: Turner syndrome and Xp deletions: clinical and molecular studies in 47 patients. *J Clin Endocrinol Metab* 2001; **86**: 5498–5508.
- 20 Ogata T, Tyler-Smith C, Purvis-Smith S, Turner G: Chromosomal localisation of a gene (s) for Turner stigmata on Yp. *J Med Genet* 1993; **30**: 918–922.
- 21 Lymphoedema Framework. Best Practice for the Management of Lymphoedema. International consensus. London: MEP Ltd 2006. Available at http://www.lympho.org/mod_turbolead/upload/file/Lympho/Best_practice_20_July.pdf.
- 22 Mellor RH, Hubert CE, Stanton AW *et al*: Lymphatic dysfunction, not aplasia, underlies Milroy disease. *Microcirculation* 2010; **17**: 281–296.
- 23 Brice G, Child AH, Evans A *et al*: Milroy disease and the VEGFR-3 mutation phenotype. *J Med Genet* 2005; **42**: 98–102.