

PRACTICAL GENETICS

In association with orphanet

Hereditary haemorrhagic telangiectasia: a clinical and scientific review

The autosomal-dominant trait hereditary haemorrhagic telangiectasia (HHT) affects 1 in 5–8000 people. Genes mutated in HHT (most commonly for endoglin or activin receptor-like kinase (ALK1)) encode proteins that modulate transforming growth factor (TGF)- β superfamily signalling in vascular endothelial cells; mutations lead to the development of fragile telangiectatic vessels and arteriovenous malformations. In this article, we review the underlying molecular, cellular and circulatory pathobiology; explore HHT clinical and genetic diagnostic strategies; present detailed considerations regarding screening for asymptomatic visceral involvement; and provide overviews of management strategies.

In brief

- Autosomal dominant.
- Commonly results from mutations in *endoglin* (HHT1) or *ACVRL1* (HHT2).
- Rarely due to mutations in *Smad4*, or other genes.
- Known disease genes involved in TGF- β superfamily signalling.
- Marked intrafamilial variation.
- Many patients experience only nosebleeds and telangiectasia, and have a normal life span.
- Approximately one-third of patients have chronic anaemia, with gastrointestinal bleeding increasing with age.
- Asymptomatic arteriovenous malformations occur in pulmonary (~50%), hepatic (~30%), cerebral (~10%) and spinal (~1%) circulations.
- Common AVM complications include stroke (ischaemic and haemorrhagic) and brain abscess.
- Rarer HHT complications include deep venous thromboses; symptomatic liver disease requiring liver transplantation; severe pulmonary hypertension; pregnancy-related death; and spinovascular accidents.

Introduction

The vascular disorder hereditary haemorrhagic telangiectasia (HHT) affects 1 in 5–8000,^{1,2} and is inherited as an autosomal-dominant trait. HHT disease-causing genes encode proteins that modulate transforming growth factor (TGF)- β superfamily signalling in vascular endothelial cells.

Genetic testing for endoglin (HHT type 1), activin receptor-like kinase (ALK1) (HHT type 2) and *Smad4* (HHT in association with juvenile polyposis (JPHT)) is available; further genes are predicted at loci identified by linkage analyses on chromosomes 5 (*HHT3*) and 7 (*HHT4*) (Table 1). Although HHT predominantly manifests as a heterozygous condition, several studies investigating children with two affected parents support *in utero* or infantile homozygous lethality in HHT.^{3–5}

HHT gene mutations lead to the development of abnormal vascular structures, which range from dilated microvessels to large arteriovenous malformations (AVMs) measuring several centimeters in diameter (Figure 1). These occur at specific sites in systemic and pulmonary circulations (Figure 2). Fragile walls and turbulent blood flow render these vessels more prone to haemorrhage than normal vessels. However, for pulmonary and hepatic AVMs, it is the consequences of arteriovenous shunting that lead to most clinical features (Table 2). Complications commonly occur from previously silent AVMs, and complications can be prevented if AVMs are recognised and treated. Asymptomatic screening and treatment programmes

Fatima S Govani¹ and Claire L Shovlin^{*1,2}

¹NHLI Cardiovascular Sciences, Imperial College London, London, UK;

²Department of Respiratory Medicine, Hammersmith Hospital, Imperial College Healthcare NHS Trust, London, UK

European Journal of Human Genetics (2009) 17, 860–871; doi:10.1038/ejhg.2009.35; published online 1 April 2009

Keywords: nosebleeds; anaemia; AVMs; stroke; endothelial; TGF- β

*Correspondence: Dr CL Shovlin, Respiratory Medicine, Hammersmith Hospital, Du Cane Road, London W12 0NN, UK.

Tel: +44 208 383 4831; Fax: +44 208 383 3260;

E-mail: c.shovlin@imperial.ac.uk

Received 28 October 2008; revised 20 January 2009; accepted 11 February 2009; published online 1 April 2009

Table 1 HHT genes

HHT	OMIM	HHT type	Chromosome	Approved gene symbol	Protein	Sequence accession IDs	Earlier symbols	Aliases
HHT1	#187300	Type 1	9	<i>ENG</i>	Endoglin	AF035753	ORW1, ORW	HHT1, END, CD105
HHT2	#600376	Type 2	12	<i>ACVRL1</i>	Activin receptor-like kinase ALK-1	L17075	ACVRLK1, ORW2	HHT2, ALK1
HTJP	#175050	HTJP	18	<i>SMAD4</i>	Smad 4	NM 005359	MADH4	DPC4
HHT3	%601101	Type 3	5					
HHT4	%610655	Type 4	7					

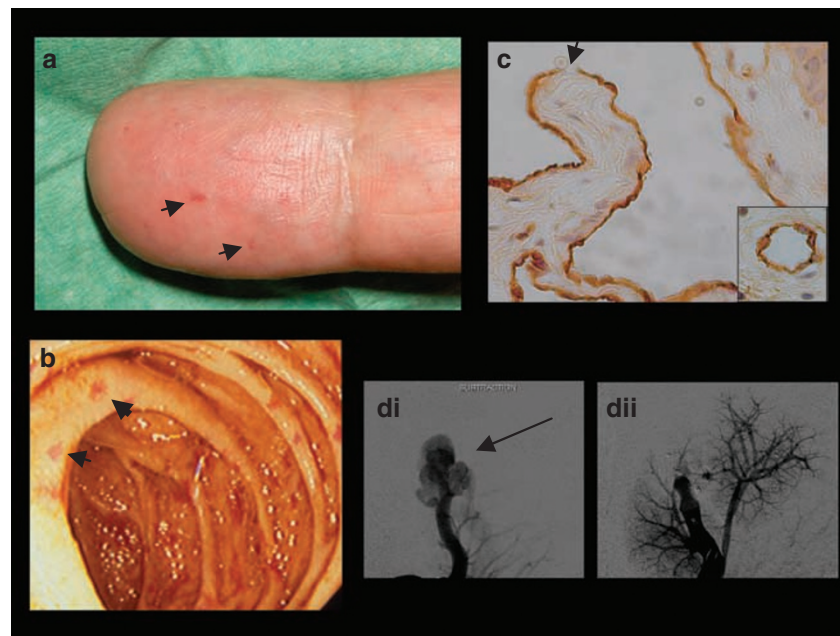


Figure 1 HHT images. (a) Fingertip and (b) gastrointestinal telangiectasia (largest examples arrowed). (c) $\times 40$ magnification of oral telangiectasia in an individual with HHT compared with control (inset). Note ruptured wall denoted by arrow. (d) Pulmonary AVM (arrowed) pre (i) and post (ii) embolisation: Angiograms are presented courtesy of Dr James Jackson.

form major components of HHT management. Useful recent reviews include those by Abdalla *et al.*,¹² Bayrak-Toydemir *et al.*,¹³ Begbie *et al.*¹⁴ and by Sabba *et al.*¹⁵

Clinical overview

HHT was first described as a familial disease characterised by anaemia, severe recurrent nosebleeds and gastrointestinal blood loss.^{16,17} There was early recognition of HHT-affected individuals developing abnormal vascular structures at other sites, particularly AVMs of the pulmonary,¹⁸ hepatic¹⁹ and cerebral²⁰ circulations. The majority of HHT patients will be affected by AVMs in at least one of these sites, with AVMs usually remaining silent.²¹ More recently, the HHT disease spectrum has expanded further to encompass pulmonary hypertension (two forms pre-

dominate in HHT), juvenile polyposis, a prothrombotic state and potential immune dysfunction (see Table 2 for references).

HHT presentation patterns are highly variable even within families. Spontaneous recurrent nosebleeds are the most common and usually earliest clinical manifestation of HHT, often commencing before school age. Telangiectases of the skin and buccal mucosa typically present from about the third decade of life, and increase with age. Recurrent haemorrhage from the gastrointestinal tract is a feature of later years in 15–20% of individuals.²² Major complications of HHT include severe anaemia from chronic nasal and gastrointestinal haemorrhage; stroke (ischaemic and brain abscess from pulmonary AVMs; haemorrhagic from cerebral AVMs); deep venous thromboses, and in rarer cases, symptomatic liver disease requiring liver transplantation; severe pulmonary hyper-

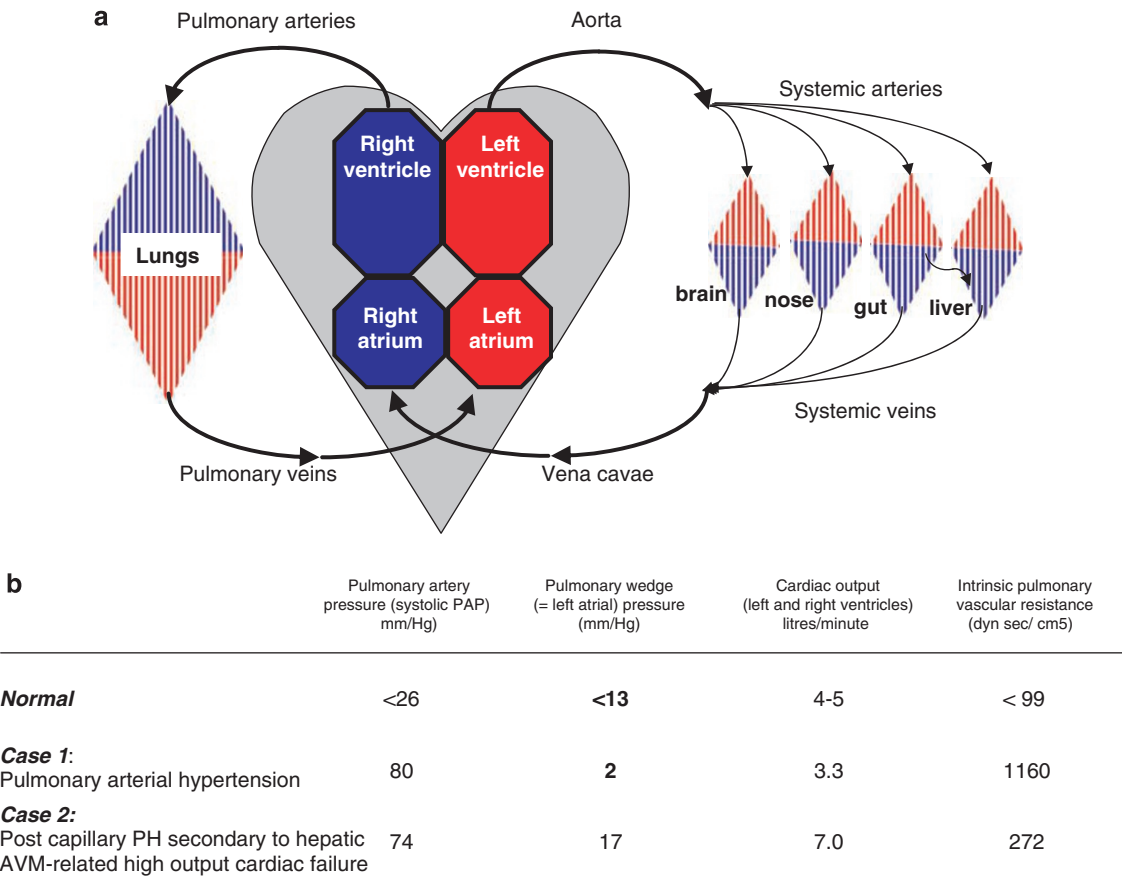


Figure 2 Circulatory explanation of HHT phenotypes. (a) Schematic of systemic and pulmonary circulations showing capillary beds in which HHT telangiectasia and AVMs occur. Note the pulmonary post capillary veins are in direct communication with the left atrium, and the portal vein which drains from the gastrointestinal tract to liver acinus. (b) Illustration of two separate pathologies resulting in severe pulmonary hypertension in two women with HHT (reported in Shovlin *et al*⁶). Note case 1 has markedly elevated intrinsic pulmonary vascular resistance, whereas this is near-normal in case 2, who has hepatic AVM-associated high output cardiac failure characterised by elevated cardiac output, cardiac index (not shown), and left atrial pressure.

tension; pregnancy-related death, and spinovascular accidents (see Table 2). Most HHT-affected individuals, however, will not have life-limiting consequences from their HHT.²³ Presymptomatic AVM screening programmes highlight the fact that before screening, the majority of affected individuals are unaware of their HHT diagnosis.²⁴

The goal of HHT management is to optimise the overall outcome of affected individuals, without raising excessive alarm regarding vascular lesions that may be of little consequence. Symptomatic patients with active medical problems because of their HHT deserve review by informed specialised services. For people with HHT who are well, the focus is on education (including recently published recommendations regarding dental care and pregnancy management) and presymptomatic screening programmes. Exact clinical management regimes differ between countries, predominantly because of differing healthcare practices (see Acknowledgements section tab (^)).

Molecular and genetic basis of the disease
Mutated genes and new loci

Three HHT disease-causing genes have been identified to date (Table 1). HHT type 1 results from mutations in *ENG* encoding endoglin²⁵ (Figure 3a); HHT type 2 results from mutations in *ACVRL1* encoding ALK1²⁸ (Figure 3b), and HHT in association with juvenile polyposis (JPHT) results from mutations in *MADH4*.²⁹ There are at least two further unidentified genes that can cause classical HHT, *HHT3* mapped to chromosome 5q between *D5S2011* and *D5S2490* (Figure 3c) and *HHT4* on chromosome 7p between *D7S2252* and *D7S510* (Figure 3d).^{26,27}

Distribution and frequency of gene mutations

The majority of HHT patients (>80%) will have mutations in either *ENG* or *ACVRL1*, *ENG* mutations being more common (61%) than *ACVRL1* mutations (37%) or *MADH4* (2%).³⁰ There is a geographical variation, with both North

Table 2 HHT Clinical features and management overview

Feature	%	Haem.	Other complications	Management if symptomatic
<i>Curaçao criteria</i>				
Nasal telangiectasia	90	++++ Nosebleeds	Iron deficiency anaemia	Iron +/- transfusions for anaemia. Nasal humidification; packing in emergencies. ENT: laser; surgery; embolisation; Systemic: oestrogen-progesterone, antifibrinolytics*
Mucocutaneous telangiectasia	80	++		Laser or other ablation therapies
Gastrointestinal telangiectasia	20	+++ (chronic)	Iron deficiency anaemia	Iron +/- transfusions for anaemia. Gastroenterology: Repeated laser therapy; surgery or embolisation for emergency control
Pulmonary AVMs	50	+	<i>Right-to-left shunt</i> : dyspnoea, stroke/TIA; brain abscess; migraine; decompression illness	Embolisation Dental hygiene and prophylactic antibiotics Caution against scuba diving
Cerebral AVMs	10	++	<i>Space occupying lesion +/- vascular steal</i> : headache, fit	Cerebral MRI. Refer to neurology for multidisciplinary evaluation of risk-benefits of treatment in an experienced centre
Hepatic AVMs	≥ 30		<i>Left to right shunt</i> : high output cardiac heart failure; pulmonary hypertension. <i>Hepato-portal shunt</i> : portal hypertension. <i>Porto-hepatic shunt</i> : biliary ischaemia, encephalopathy	Refer to specialized hepatology services for intensive medical management: liver transplantation is the treatment of choice if symptoms fail to respond to medical treatment ⁷
Spinal AVMs	< 1	++	Pain, asymmetric growth	Spinal MRI. Refer to neurology for multidisciplinary evaluation of risk-benefits of treatment in an experienced centre
<i>Non-criterion manifestations</i>				
Juvenile polyposis (Smad4)	< 1		Haemorrhage, malignancy	Refer to gastroenterology, and follow national surveillance guidelines such as ⁸
Pulmonary hypertension	< 2		Dyspnoea, right heart failure	Refer to cardiorespiratory; Exclude hepatic AVMs; if present, consider liver transplant
Prothrombotic state ⁹			Deep venous thrombosis, pulmonary emboli	As per national guidelines, eg, 10
Immune dysfunction ¹¹			Uncertain	

%, Estimated prevalence across all age groups. Haem., haemorrhage frequency scale 0 to +++. *Ensure not prothrombotic first.⁹ Further agents are undergoing clinical evaluation, particularly, in the setting of severe gastrointestinal and nasal haemorrhage. Shunt anatomy: right-to-left: pulmonary artery to pulmonary vein, left-to-right: hepatic artery to hepatic vein, Hepato-portal: hepatic artery to portal vein; Porto-hepatic: portal vein to hepatic vein.

American and European series showing either *ACVRL1* predominance (USA;³¹ European^{32,33}) or an *ENG* bias (USA,³⁴ European^{35,36}). It is therefore not clear whether this reflects the referral practice of HHT centres or genuine geographical variation.

More than 600 different mutations have been found in *ENG* or *ACVR* in HHT families (see <http://www.hhtmutilation.org>). Neither gene displays a common mutation, and the majority of mutations have been reported only once. All types of mutations are found in *ENG* and *ACVRL1*, including deletions, insertions, missense, nonsense and splice site (Figure 3). The JPHT mutations found to date are

in the last four exons of *Smad4* (exons 8–11); mutation types include missense, nonsense and frameshift, with a high incidence of *de novo* mutations.^{29,30}

Genotype-phenotype relationships

Recent large series support early observations, finding pulmonary and cerebral AVMs more common in HHT1 (*ENG* mutations), and hepatic AVMs more common in HHT2 (*ACVRL1* mutations).^{31–36} Although there was an initial suggestion that overall severity of disease is greater in HHT1 than in HHT2,³⁷ this study predated the

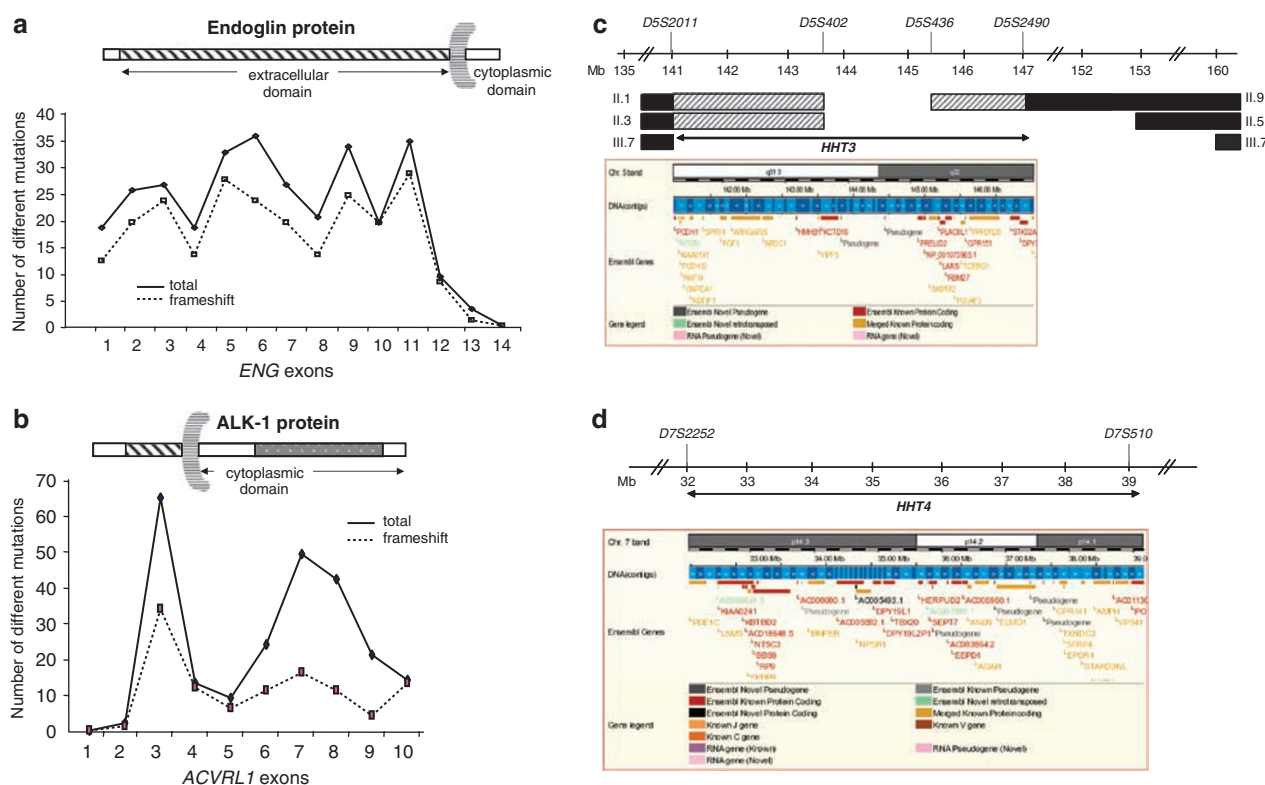


Figure 3 Schematic representations of HHT1-4. (a) HHT1: Summary of 311 *ENG* mutations reported to <http://www.hhtmut.org>. Note high proportion of frameshift mutations. (b) HHT2: Summary of 250 *ACVRL1* mutations reported to <http://www.hhtmut.org>. Note higher frequency in exons 3, 7 and 8, and lower proportion of frameshift mutations. (c) HHT3: 6 Mb *HHT3* interval defined by key recombinants (black bars) between *D5S2011* and *D5S2490*. Uninformative regions are shown by shaded bars.²⁶ Ensembl predicts 29 genes in this interval. (d) HHT4: 7 Mb *HHT4* interval between *D7S2252* and *D7S510*²⁷. Ensembl predicts 57 genes in this interval. Mb, mega base.

recognition of pulmonary hypertension, and there was no difference in the 90-month mortality in a later series.³⁶

Pulmonary hypertension³⁸ and juvenile polyposis²⁹ are recognised as part of the spectrum of HHT for particular families. As illustrated in Figure 2b, pulmonary hypertension is not a single disease entity and can result from multiple secondary causes in HHT. The pure pulmonary arterial hypertension (PAH) phenotype seen in patients with HHT is indistinguishable from PAH in the general population due to mutations in the related *BMPRII* (Figure 4). Juvenile polyposis (JP) seen in HHT patients with *Smad4* mutations is indistinguishable from JP in the general population most commonly due to mutations in *BMPRI1A*, which encodes another related protein (ALK3 in Figure 4). In HHT, pulmonary artery hypertension and JP were initially considered attributable solely to *ACVRL1* and *Smad4* mutations, respectively. There are rare reports of both pulmonary artery hypertension and JP associated with *ENG* missense mutations. Further evaluation is needed to determine whether these *ENG* sequence variations are HHT disease-causing or benign variants.

These genotype–phenotype correlation studies suggest that, although normal function of the gene products

of *ENG*, *ACVRL1* and *MADH4* are required to prevent the development of an HHT-like phenotype, there are likely to be differences in the normal requirements for the three proteins in different vascular beds and cell types.

Biology of the disease

Phenotypic considerations, expression analysis of mutant endoglin and ALK1 proteins, and HHT-like phenotypes in heterozygous mice implicate haploinsufficiency of the respective protein as the cause of *HHT1* and *HHT2*.¹² Dominant negative mutations in endoglin can be generated, but may cause different phenotypes; for example, truncated soluble endoglin is associated with the non-HHT phenotype of pre-eclampsia.³⁹

The genes mutated in HHT encode proteins involved in TGF- β superfamily signalling; perturbation of these signalling pathways is therefore implicated in the pathogenesis of HHT. Superfamily ligands such as TGF- β s, BMPs, activins, nodals, GDFs and inhibins normally regulate diverse cellular functions, such as cellular survival, proliferation and differentiation, by binding to a heteromeric complex of type I and type II transmembrane serine/

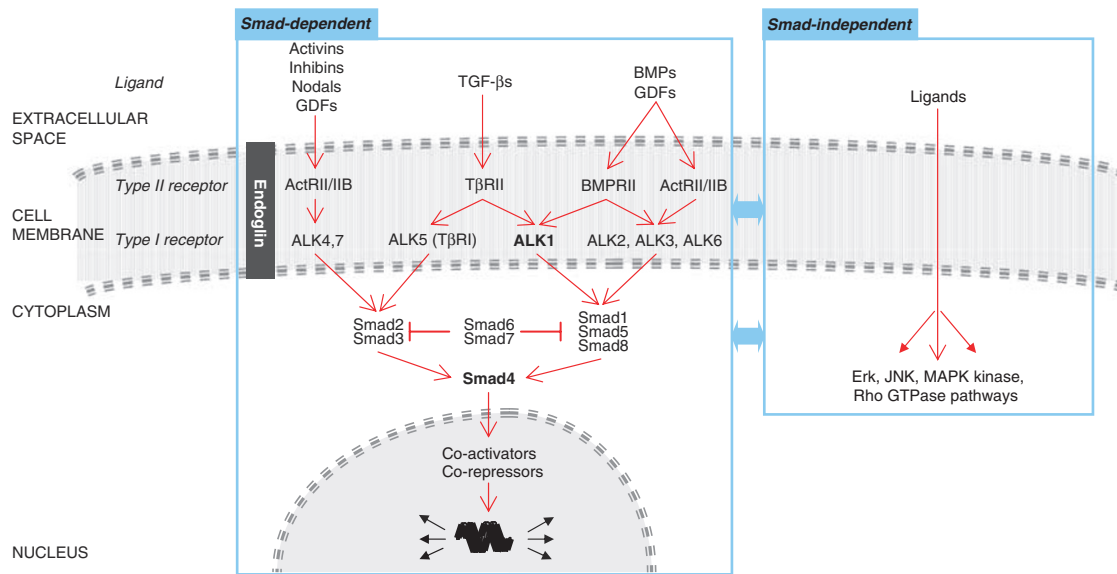


Figure 4 TGF- β superfamily signalling pathways. Endoglin can interact with type I and type II receptors. The genes mutated in HHT are highlighted in bold.

threonine kinase receptors (Figure 4). Signalling can be propagated through Smad-dependent and Smad-independent pathways.^{40,41} In Smad-dependent pathways, in which all three known HHT gene products function, ligand binding activates a TGF- β type II receptor, which in turn phosphorylates and activates a type I receptor. The type I receptor subsequently phosphorylates and activates receptor associated (R)-Smads (Smads 1, 2, 3, 5 and/or 8), which bind to *Smad4* and translocate to the nucleus, where they influence transcriptional activation with co-activators and co-repressors. Inhibitory Smads (Smad6/7) target R-Smads for degradation and provide a negative feedback loop for this pathway. In most cell types, T β RII signalling transmits through ALK5 (T β RI) via Smad2/3 pathways. In endothelial cells, however, T β RII signalling can also be propagated through ALK1 via Smad1/5/8 pathways. The ALK1 ligand has been unknown for a long time, but recently it was shown that BMP9 and BMP10 are specific ALK1 ligands that can also bind endoglin (Figure 4).^{42,43}

Several series of HHT animal models are now described. Null mice for *Eng* and *Acvr11* die between E10.5–11.5 because of gross vascular and cardiac defects comparable with multiple other null mice, potentially reflecting aberrant placental vascular development. Heterozygous mice develop variable, but more HHT-specific, features including nosebleeds, telangiectasia, dilated vessels and AVMs.^{12,41} Conditional LoxP knockout alleles have been generated for all three HHT genes and for ALK1, result in a model in which HHT-like vascular malformations occurred in a consistent and predictable manner.⁴⁴ These and other models are under active study.

Current HHT models

What causes the pathogenesis of HHT? This has been a controversial topic for many years and remains unresolved, in part because of the non-uniformity of the disease process in affected vascular beds. The precise sequence of events remains to be determined, but most likely involves aberrant endothelial cell responses to TGF- β /BMP signalling in specific settings.

A favoured model has been generated from data focussing on the two T β RII-associated type I receptors (ALK5 and ALK1), suggesting that the endothelial state depends on the predominant type I receptor used, and that abnormal vasculature in HHT resulted from a perturbation of this balance.^{45–47} This balance model has been both challenged⁴⁴ and supported⁴⁸ by recent data, and remains a helpful tool in clarifying signalling pathway interrelationships.

For example, endoglin and ALK1 are involved in angiogenesis, the process in which new blood vessels are formed from pre-existing ones. During angiogenesis, mural cells (smooth muscle cells, pericytes) detach, and brief periods of endothelial cell activation, proliferation and migration are co-ordinated with controlled proteolytic remodelling of the basement membrane and extracellular matrix, expression of endothelial cell survival factors, and recruitment of mural cells to stabilise the nascent blood vessels. There are complex context-dependent biological activities of the HHT gene products in these processes such that over-expression of constitutively active ALK1 or under-expression of endoglin can each either promote or inhibit specific endothelial cell responses according to the experimental conditions. However, evidence suggests that

endoglin and ALK1 responses promote opposing endothelial cell responses (such as proliferation, migration) to ALK5, and that the ratio of ALK5 and ALK1 activation by TGF- β superfamily ligands can influence whether pro- or anti-angiogenic genes are predominantly expressed.⁴⁹

Management

Diagnostic approaches

Clinical diagnosis of HHT The Curacao criteria, published in 2000,⁵⁰ remain the mainstay of HHT clinical diagnosis. A definite diagnosis of HHT is made in the presence of at least three separate manifestations:

- spontaneous recurrent nosebleeds;
- mucocutaneous telangiectasia (multiple at characteristic sites: fingertip pulps, lips, oral mucosa or tongue);
- visceral involvement (gastrointestinal, pulmonary, hepatic, cerebral or spinal AVM);
- family history: a first-degree relative affected according to these criteria

Family history plus one criterion When reviewing individuals from HHT families, clinicians are often faced with individuals with only one additional diagnostic criterion. In clinical practice, if the non-familial criterion is a visceral AVM, which would be very rare in the general population, the diagnosis of HHT is essentially confirmed. This is not the case for nosebleeds, which are common in the general population, or non-florid telangiectasia, which can be readily confused with non-HHT pathologies. For research and epidemiological studies, the labels of possible or suspected HHT should be used for all individuals with only two diagnostic criteria.⁵⁰

Family history only Although HHT is likely to present with nosebleeds during childhood, the condition cannot be excluded on clinical grounds even at the age of 30–40 years. For an apparently unaffected child of an HHT-affected parent, clinical data on age-related penetrance in European HHT populations allow estimations of the probability of HHT-affected status ranging from 0.5 at 0 years; 0.22 at 16 years; 0.05 at 40 years and 0.01 at 60 years.^{22,51,52} ‘Possible HHT’ can be added to the medical records of such individuals.

Molecular diagnosis Genetic testing for *endoglin*, *ALK1/ACVRL1* and *Smad4* is available and can confirm the diagnosis for the family, and confirm or refute the diagnosis in family members. Strategies to use genetic tests vary between units.

For patients with definite clinical HHT, molecular testing is not required to confirm their diagnosis, but may assist management of other family members. Mutations

are not found in about 20% of HHT families; hence, failure to detect a causative HHT mutation in a family does not exclude HHT. Not all *ENG/ACVRL1/Smad4* gene sequence variations in HHT families are disease-causing (<http://www.hhtmutilation.org>); in those cases in which it is difficult to distinguish from incidental polymorphisms, assessment of co-segregation in a distant affected relative may be helpful.

Genetic testing is most helpful in the settings of

- a potentially unaffected family member in whom the diagnosis of HHT cannot be excluded clinically;
- a patient with suggestive, but not confirmatory, clinical features of HHT, in whom a positive test would be diagnostic.

Other genetic counselling issues

- The hallmark of clinical HHT is the variability between different affected members of the same HHT family. Nevertheless, there are genotype–phenotype correlations related to the causative *HHT* gene mutation, and as-yet unidentified genetic modifiers
- Prenatal diagnosis is technically feasible and chosen by some families. Generally, however, there has been little interest in, or use of, prenatal molecular diagnosis for HHT in view of the longevity and paucisymptomatic state of most HHT patients (^).
- At present, a positive molecular diagnosis does not modify recommended screening or management, except in the setting of HHT-affected individuals with a family history of gastrointestinal polyps/malignancy; identification of a *Smad4* mutation would lead to institution of gastrointestinal screening programmes.

Clinical work-up

The basic work-up approach for suspected HHT patients is illustrated in Figure 5. After a clinical evaluation, including a detailed family history, emphasis is placed on:

- ensuring that patients with a particular problem are reviewed by an organ-specific specialist aware of HHT issues (details of management are beyond the scope of this text, but outlined within Table 2);
- screening for asymptomatic AVMs according to local or regional practice (see below);
- formalizing the diagnosis of HHT, which may require molecular testing;
- providing information and opportunity for follow-up and family screens.

Screening

The medical justification for screening regimes in asymptomatic individuals from the HHT population

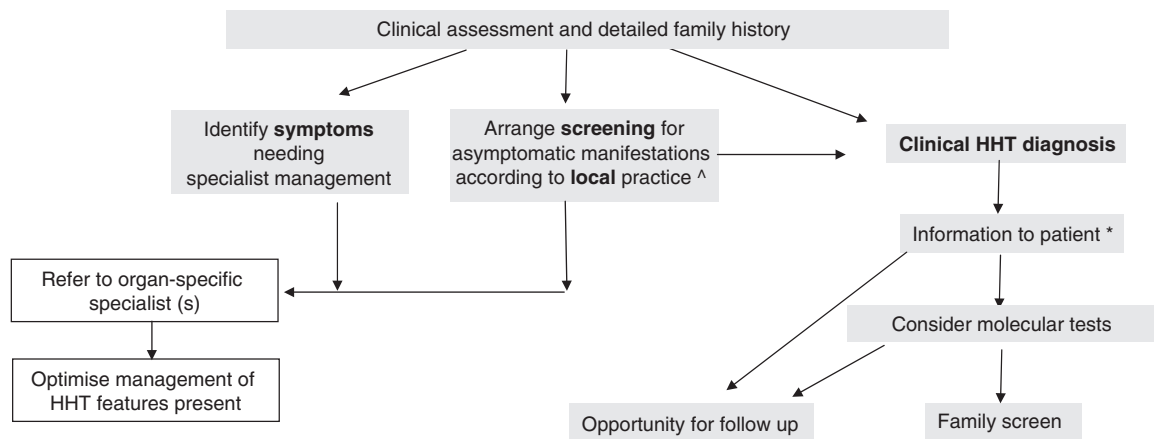


Figure 5 Schematic of management approaches. Similar principles operate throughout most HHT specialised services. (^*): Further details are provided in the text.

centres on the degree of danger posed by silent AVMs (as opposed to symptomatic AVMs), the safety/tolerability of the diagnostic tool, the advantages offered by the correct diagnosis in terms of patient management and follow-up, and the safety of effective treatments. Risk–benefit evaluations are then performed to determine whether the detection and treatment of the asymptomatic AVM is likely to carry overall positive health benefits for the patient.

Where risk–benefit considerations are less clear cut, different interpretations are observed, and generally reflect the overall healthcare practices of particular countries and cultures. To reflect these differing practices and the evolving nature of recommendations as new data regarding natural history and treatment safety/efficacy become available, Figure 5 presents only limited data regarding specific particular screening and management regimes. Detailed considerations are presented below.

Pulmonary AVMs

Pulmonary AVMs are usually silent at the time of PAVM-induced strokes and brain abscess, can be diagnosed at low risk and have an effective and safe treatment with embolisation shown to reduce or abolish neurological risks.²⁴ Hence, detection and treatment of asymptomatic pulmonary AVMs is recommended worldwide for adults.

For highly sensitive screening tests, the choice lies between thoracic CT scans and contrast echocardiography (CE). Use of either test means that very few pulmonary PAVMs will be missed out in an HHT population, whereas chest x-rays, blood oxygen levels and right-to-left shunt measurements are insufficiently sensitive to exclude pulmonary AVMs. Both CT and CE also allow for the detection of severe pulmonary hypertension, which is a relative contraindication to embolisation.⁵³

Many specialised units use a multistep-screening programme using CE as a first line screen. After intravenous

injection of contrast or microbubbles, which should be removed by the normal pulmonary capillary bed, right-to-left shunting through pulmonary AVMs results in the appearance of microbubbles on the left side of the circulation. Arrival is usually delayed compared with intracardiac shunts, with bubbles arriving after 3–10 cardiac cycles associated with pulmonary AVMs.⁵⁴ Shunt severity may be graded by the number of microbubbles appearing on a single frame. Higher grade shunts (>20–30 microbubbles per frame) have higher positive predictive values.^{54–56} After a positive study, patients proceed to thoracic CT scans to determine anatomical features and suitability for embolisation treatment.

Other institutions, including our own, do not use CE routinely, as the majority of studies are positive and there are substantial time and resource implications. The new generations of CT scanners mean that a diagnosis of pulmonary AVMs can be made efficiently and quickly using a single thoracic CT scan, which carries a radiation burden, but has the benefit of identifying additional pathology and embolisation contraindications, such as severe pulmonary hypertension.

Discussion continues regarding the degree to which a negative screen (by CT or CE) can be used to rule out small PAVMs, which may nevertheless carry risks of dental bacteraemias and decompression illness during scuba diving. The current practice at our institution is to provide recommendations regarding dental hygiene to all HHT patients, and to refer divers for specialist advice and evaluation.

Cerebral AVMs

Screening of asymptomatic patients for cerebral AVMs is recommended in many countries, but remains controversial in others (^): Cerebral haemorrhages in HHT patients are usually life-changing and may be fatal. Conversely, most HHT-related cerebral AVMs will never bleed, and

investigation and treatments carry risks. Both sets of considerations differ with the precise anatomy and location of the AVM. Other important considerations are that cerebral AVMs are more common in HHT1 families^{31–36}, and that the lifelong risk of haemorrhage is higher for younger patients because of their longer predicted lifespan.

In the UK, we have followed the interpretation articulated by the late Pierre Lasjaunias that risk–benefit considerations for asymptomatic cerebral AVMs are usually not interpreted in favour of treatment because the risks of intervention are too high for the low risk of haemorrhage⁵⁷. Thus, up to 10% of screened individuals would be faced with the identification of cerebral AVMs for which no treatment or management options would be currently recommended. At our institution, we discuss these considerations openly with the patient and, generally, cerebral MRI is not performed. However, for any individual with a family member who has had a cerebral haemorrhage, or in whom there is any concern regarding cerebral symptoms, a cerebral MRI is recommended to rule out a chance inheritance of familial aneurysms (which carry a higher risk of haemorrhage⁵⁸) or presence of an unstable, symptomatic cerebral AVM.

Hepatic AVMs

Screening considerations for hepatic AVMs in asymptomatic individuals differ from those for cerebral and pulmonary AVMs, as hepatic AVM management is directed towards symptomatic patients who receive intensive medical treatment, with liver transplantation (which is effective in HHT⁵⁹) reserved for non-responders.⁷ However, as there is a totally non-invasive and effective screening tool (Doppler US), and because a correct diagnosis can help to clarify the diagnosis of HHT and improve subsequent patient management, screening of asymptomatic individuals for hepatic AVMs has been recommended.⁷

Special considerations in pregnancy

The overwhelming majority of pregnancies in women with HHT proceed normally, but there are small risks of life-threatening maternal complications; in a recent series of 484 pregnancies, 1.02% (95% confidence intervals 0.13, 1.92%) resulted in a major PAVM bleed; 1.24% (0.25, 2.23%) in stroke (not all were HHT-related); and 1.00% (0.13, 1.92%) in maternal death.⁵⁸ In British obstetric terminology, this renders HHT pregnancies high risk for greater obstetric medical review than recommended for low-risk pregnancies.

The data for and against screening asymptomatic women during pregnancy for pulmonary, cerebral or spinal AVMs were discussed in detail in the paper.⁵⁸ The Anglo-French authors' recommendations for their obstetric healthcare systems were, in the absence of symptoms, to defer pulmonary AVM screens, only perform cerebral imaging if warranted by family history and to consider spinal MRI

in those cases in which the possibility of spinal AVMs would lead obstetric anaesthetists to withhold epidural analgesia. There are strong opinions in other countries that asymptomatic women should be screened and treated for pulmonary AVMs during pregnancy. As a result, there are different practices among countries.

Children

Occasionally, children from HHT families have major complications from HHT, but the majority have healthy childhoods, with or without nosebleeds, and usually without anaemia. AVMs may be present (cerebral AVMs usually develop perinatally and can bleed in childhood; pulmonary AVMs may develop in the pre-pubertal period, but complications in asymptomatic children are extremely rare²⁴). There are few data regarding dedicated risk–benefit considerations for the paediatric population, particularly regarding their increased susceptibility to diagnostic radiation-induced morbidity from CT scans^{60–61} and angiography.⁶² The ethics of screening an asymptomatic child, who is too young to give consent and will likely not understand the implications of testing, also need to be carefully considered before proceeding. Institutions therefore differ in their screening regimes. Practice ranges from screening for all manifestations of HHT to deferring screening in most asymptomatic children until post-puberty, unless dictated otherwise by family history.

Treatment and care

Brief details of medical management are given in Table 2 for clinicians. Additional information is warranted for several points for clinicians and patients alike. Our practice is to provide this general advice for the whole family, with particular focus on individual patients according to the aspects of HHT known to affect them. This is particularly important when the presence of HHT would modify general clinical protocols for management of common conditions such as stroke, and prophylaxis against deep venous thrombosis (see below).

Anaemia

It is unusual to be able to abolish nasal and gastrointestinal bleeding. Prevention and management of anaemia becomes paramount in at least one-third of HHT patients. Dietary advice for foods containing iron, and identification of oral iron preparations that suit the individual are important steps to reduce the need or frequency of transfusions or iron infusions required for severely affected individuals.

Pulmonary AVMs

Irrespective of size or symptoms, these carry risks of paradoxical embolic stroke and brain abscess, which can be reduced or abolished by embolisation.⁴² Owing to brain

abscess links with dental microorganisms, scrupulous dental hygiene and antibiotic prophylaxis at the time of dental procedures have been recommended, and this advice has been recently confirmed by senior British dentists, recognizing the differences between HHT/PAVM patients, and individuals at risk of infective endocarditis, for whom prophylaxis was withdrawn.⁶³

Stroke advice

HHT-affected families should be aware that in the event of stroke-like features, their doctors may need to be alerted to their three potential stroke types (haemorrhagic, ischaemic and brain abscess), leading to modification of local stroke-management protocols.

Liver evaluations

Hepatic AVMs commonly lead to asymptomatic abnormalities in biochemical markers of cholestasis, and the benign condition of focal nodular hyperplasia. These are of little clinical importance, but could potentially result in unnecessary diagnostic tests.⁷ HHT patients should be advised to exclude liver biopsy, unless imaging has excluded hepatic AVMs.⁷

Deep venous thrombosis prophylaxis

Prophylaxis against deep venous thromboses is often modified or withheld for patients with haemorrhagic conditions such as HHT. Recent data highlight that HHT-affected individuals are at risk for thrombotic events, and should be considered for full prophylaxis at appropriate times, particularly in periods after a pulmonary AVM-induced brain abscess.⁹

Pregnancy

Irrespective of earlier screening and treatment, obstetricians should be alerted to the presence of HHT for all women with HHT. Any haemoptysis or sudden severe dyspnoea should be considered a potential emergency, prompting immediate hospital admission.⁵⁷

Conclusion

The diagnosis of HHT has been facilitated with the identification of several disease-causing genes, but management of both symptomatic and asymptomatic individuals remains highly challenging for experienced specialists. Discussion of risks and complex risk-benefit analyses need to be handled sensitively and appropriately for age, family, cultural and national background. Major clinical and research hurdles remain if we are to more closely predict and prevent likely pathology in a condition in which the majority of individuals will not have major complications.

Self-help websites for HHT families

Country and language-specific information for HHT patients and families is available through a number of websites. The EuroHHT consortium plans an umbrella entry European website for 2009.

Denmark	http://www.osler.dk
France	http://www.amro-france.org
Germany	http://www.morbus-osler.de
Ireland	http://www.Gracenolan.com
Italy	http://www.hht.it
Netherlands	http://www.renduoslerweber.nl
Norway	http://http://ssss.oslonett.no/side.php?mid=18&k=morbus_osler
Spain	http://www.asociacionhht.org
UK	http://www.telangiectasia.co.uk
USA and international	http://www.hht.org

Acknowledgements

We thank Jamie McDonald (US), Elisabetta Buscarini (Italy), Kees Westermann (Netherlands) and Roberto Zarrabeitia (Spain) for reviewing and commenting on the paper; medical members of the EuroHHT consortium for helpful discussions including approval of the highlighted (^) statements by Gregor Bachmann-Harildstad (Norway), Elisabetta Buscarini (Italy), Sophie Dupuis-Girod (France), Anette Kjeldsen (Denmark), Pascal Lacombe (France), Henri Plauchu (France), Carlo Sabba (Italy), Kees Westermann (Netherlands) and Roberto Zarrabeitia (Spain); for specific pulmonary and neurovascular discussions, James Jackson (UK) and Pierre Lasjaunias (France); and for approval of paediatric statements, Nicky Coote (UK) and Andrew Bush (UK). FSG is supported by a British Heart Foundation PhD studentship. CLS is grateful for support from the NIHR Biomedical Research Centre Funding Scheme, and thanks the British HHT families, whose donations have supported HHT clinical research at the Hammersmith Hospital.

References

- 1 Bideau A, Brunet G, Heyer E *et al*: An abnormal concentration of cases of Rendu-Osler disease in the Valserine valley of the French Jura: a geneological and demographic study. *Ann Hum Biol* 1992; **19**: 233–247.
- 2 Kjeldsen AD, Vase P, Green A: Hereditary haemorrhagic telangiectasia: a population-based study of prevalence and mortality in Danish patients. *J Intern Med* 1999; **245**: 31–39.
- 3 Snyder LH, Doan CA: Clinical and experimental studies in human inheritance: is the homozygous form of multiple telangiectasia lethal? *J Lab Clin Med* 1944; **29**: 1211–1216.
- 4 Karabegovic A, Shinawi M, Cymerman U *et al*: No live individual homozygous for a novel endoglin mutation was found in a consanguineous Arab family with hereditary haemorrhagic telangiectasia. *J Med Genet* 2004; **41**: e119.
- 5 El-Harith HA, Kuhnau W, Schmidtke J *et al*: Hereditary hemorrhagic telangiectasia is caused by the Q490X mutation of the ACVRL1 gene in a large Arab family: support of homozygous lethality. *Eur J Med Genet* 2006; **49**: 323–330.

- 6 Shovlin CL, Tighe HC, Davies RJ *et al*: Embolisation of pulmonary arteriovenous malformations (PAVMs): no consistent effect on pulmonary artery pressure. *Eur Resp J* 2008; **32**: 162–169.
- 7 Buscarini E, Plauchu H, Garcia Tsao G *et al*: Liver involvement in hereditary hemorrhagic telangiectasia: consensus recommendations. *Liver Int* 2006; **26**: 1040–1046.
- 8 Dunlop MG: British Society of Gastroenterology. Guidance on gastrointestinal surveillance for hereditary non-polyposis colorectal cancer, familial adenomatous polyposis, juvenile polyposis and Peutz-Jeghers syndrome. *Gut* 2002; **51**: v21–v27.
- 9 Shovlin CL, Sulainam NL, Govani FS *et al*: Elevated factor VIII in hereditary haemorrhagic telangiectasia (HHT): association with venous thromboembolism. *Thromb Haemost* 2007; **98**: 1031–1039.
- 10 British Thoracic Society Standards of Care Committee Pulmonary Embolism Guideline Development Group: British Thoracic Society guidelines for the management of suspected acute pulmonary embolism. *Thorax* 2003; **58**: 470–484.
- 11 Cirulli A, Loria MP, Dambra P *et al*: Patients with hereditary hemorrhagic telangiectasia (HHT) exhibit a deficit of polymorphonuclear cell and monocyte oxidative burst and phagocytosis: a possible correlation with altered adaptive immune responsiveness in HHT. *Curr Pharm Des* 2006; **12**: 1209–1215.
- 12 Abdalla SA, Letarte M: Hereditary haemorrhagic telangiectasia: current views on genetics and mechanisms of disease. *J Med Genet* 2006; **43**: 97–110.
- 13 Bayrak-Toydemir P, Mao R, Lewin S, McDonald J: Hereditary hemorrhagic telangiectasia: an overview of diagnosis and management in the molecular era for clinicians. *Genet Med* 2004; **6**: 175–191.
- 14 Begbie ME, Wallace GMF, Shovlin CL: Hereditary haemorrhagic telangiectasia (Osler-Weber-Rendu syndrome): a view from the 21st century. *Postgrad Med J* 2003; **79**: 18–24.
- 15 Sabbà C: A rare and misdiagnosed bleeding disorder: hereditary hemorrhagic telangiectasia. *J Thromb Haemost* 2005; **3**: 2201–2210.
- 16 Rendu H: Épistaxis répétées chez un sujet porteur de petits angiomes cutanés et muqueux. *Gazette des Hôpitaux (Paris)* 1896; **135**: 1322–1323.
- 17 Legg W: A case of haemophilia complicated with multiple naevi. *Lancet* 1876; **2**: 856–857.
- 18 Rundles RW: Hemorrhagic telangiectasia with pulmonary artery aneurysm: case report. *Am J Med Sci* 1945; **210**: 76–81.
- 19 Smith JL, Lineback MI: Hereditary hemorrhagic telangiectasia, nine cases in one Negro family with special reference to hepatic lesions. *Am J Med* 1954; **17**: 41–49.
- 20 Román G, Fisher M, Perl DP *et al*: Neurological manifestations of hereditary hemorrhagic telangiectasia (Rendu-Osler-Weber Disease): report of 2 cases and review of the literature. *Ann Neurol* 1978; **4**: 130–144.
- 21 Guttmacher AE, Marchuk DA, White RI: Hereditary hemorrhagic telangiectasia. *New Engl J Med* 1995; **333**: 918–924.
- 22 Plauchu H, de Chadarevian J-P, Bideau A *et al*: Age-related clinical profile of hereditary hemorrhagic telangiectasia in an epidemiologically recruited population. *Am J Med Genet* 1989; **32**: 291–297.
- 23 Kjeldsen AD, Vase P, Green A: Hereditary haemorrhagic telangiectasia: a population-based study of prevalence and mortality in Danish patients. *J Intern Med* 1999; **245**: 31–39.
- 24 Shovlin CL, Jackson JE, Bamford KB *et al*: Primary determinants of ischaemic stroke/brain abscess risks are independent of severity of pulmonary arteriovenous malformations in hereditary haemorrhagic telangiectasia. *Thorax* 2008; **63**: 259–266.
- 25 McAllister KA, Grogg KM, Johnson DW *et al*: Endoglin, a TGF-beta binding protein of endothelial cells, is the gene for hereditary haemorrhagic telangiectasia type 1. *Nat Genet* 1994; **8**: 345–351.
- 26 Cole SG, Begbie ME, Wallace GMF, Shovlin CL: A new locus for hereditary haemorrhagic telangiectasia (HHT3) maps to chromosome 5. *J Med Genet* 2005; **42**: 577–582.
- 27 Bayrak-Toydemir P, McDonald J, Akarsu N *et al*: A fourth locus for hereditary hemorrhagic telangiectasia maps to chromosome 7. *Am J Med Genet A* 2006; **140**: 2155–2162.
- 28 Johnson DW, Berg JN, Baldwin MA *et al*: Mutations in the activin receptor-like kinase 1 gene in hereditary haemorrhagic telangiectasia type 2. *Nat Genet* 1996; **13**: 189–195.
- 29 Gallione CJ, Repetto GM, Legius E *et al*: A combined syndrome of juvenile polyposis and hereditary haemorrhagic telangiectasia associated with mutations in MADH4 (SMAD4). *Lancet* 2004; **363**: 852–859.
- 30 Gallione CJ, Richards JA, Letteboer TG *et al*: SMAD4 mutations found in unselected HHT patients. *J Med Genet* 2006; **43**: 793–797.
- 31 Bayrak-Toydemir P, McDonald J, Markewitz B *et al*: Genotype-phenotype correlation in hereditary hemorrhagic telangiectasia. *Am J Med Genet* 2006A; **140**: 463–470.
- 32 Sabbà C, Pasculli G, Lenato GM *et al*: Hereditary hemorrhagic telangiectasia: clinical features in ENG and ALK1 mutation carriers. *J Thromb Haemost* 2007; **5**: 1149–1157.
- 33 Lesca G, Olivieri C, Burnichon N *et al*: Genotype-phenotype correlations in hereditary hemorrhagic telangiectasia: data from the French-Italian HHT network. *Genet Med* 2007; **9**: 14–22.
- 34 Bossler AD, Richards J, George C *et al*: Novel mutations in ENG and ACVRL1 identified in a series of 200 individuals undergoing clinical genetic testing for hereditary hemorrhagic telangiectasia (HHT): correlation of genotype with phenotype. *Hum Mutat* 2006; **27**: 667–675.
- 35 Letteboer TG, Mager JJ, Snijder RJ *et al*: Genotype-phenotype relationship in hereditary haemorrhagic telangiectasia. *J Med Genet* 2006; **43**: 371–377.
- 36 Kjeldsen AD, Møller TR, Brusgaard K *et al*: Clinical symptoms according to genotype amongst patients with hereditary haemorrhagic telangiectasia. *J Int Med* 2005; **258**: 349–355.
- 37 Berg JN, Porteous MEM, Reinhardt D *et al*: Hereditary haemorrhagic telangiectasia: a questionnaire based study to delineate the different phenotypes caused by endoglin and ALK 1 mutations. *J Med Genet* 2003; **40**: 585–590.
- 38 Trembath R, Thomson J, Machado R *et al*: Clinical and molecular features of pulmonary hypertension in hereditary hemorrhagic telangiectasia. *New Engl J Med* 2001; **345**: 325–334.
- 39 Venkatesha S, Toporsian M, Lam C *et al*: Soluble endoglin contributes to the pathogenesis of preeclampsia. *Nat Med* 2006; **12**: 642–649.
- 40 Derynck R, Zhang YE: Smad-dependent and Smad-independent pathways in TGF-beta family signalling. *Nature* 2003; **425**: 577–584.
- 41 ten Dijke P, Arthur HM: Extracellular control of TGF-beta signalling in vascular development and disease. *Nat Rev Mol Cell Biol* 2007; **8**: 857–869.
- 42 David L, Mallet C, Mazerbourg S *et al*: Identification of BMP9 and BMP10 as functional activators of the orphan activin receptor-like kinase 1 (ALK1) in endothelial cells. *Blood* 2007; **109**: 1953–1961.
- 43 Scharpfenecker M, van Dinther M, Liu Z *et al*: BMP-9 signals via ALK1 and inhibits bFGF-induced endothelial cell proliferation and VEGF-stimulated angiogenesis. *J Cell Sci* 2007; **120**: 964–972.
- 44 Park SO, Lee YJ, Seki T *et al*: ALK5- and TGFBR2-independent role of ALK1 in the pathogenesis of hereditary hemorrhagic telangiectasia type 2. *Blood* 2008; **111**: 633–642.
- 45 Blanco FJ, Santibanez JF, Guerrero-Esteo M *et al*: Interactions and functional interplay between endoglin and ALK-1, two components of the endothelial transforming growth factor-beta receptor complex. *J Cell Physiol* 2005; **204**: 574–584.
- 46 Lebrin F, Goumans MJ, Jonker L *et al*: Endoglin promotes endothelial cell proliferation and TGF-beta/ALK1 signal transduction. *EMBO J* 2004; **23**: 4018–4028.
- 47 Pece-Barbara N, Vear S, Kathirakamathamby K *et al*: Endoglin null endothelial cells proliferate faster and are more responsive to transforming growth factor beta 1 with higher affinity receptors and an activated Alk1 pathway. *J Biol Chem* 2005; **280**: 27800–27808.
- 48 Daly AC, Randall RA, Hill CS: Transforming growth factor beta-induced Smad1/5 phosphorylation in epithelial cells is mediated

- by novel receptor complexes and is essential for anchorage-independent growth. *Mol Cell Biol* 2008; **28**: 6889–6902.
- 49 Goumans M-J, Valdimarsdottir G, Itoh S *et al*: Activin receptor-like kinase (ALK)1 is an antagonistic mediator of lateral TGF- β /ALK5 signaling. *Mol Cell* 2003; **12**: 817–828.
- 50 Shovlin CL, Guttmacher AE, Buscarini E *et al*: Diagnostic criteria for hereditary hemorrhagic telangiectasia (Rendu-Osler-Weber syndrome). *Am J Med Genet* 2000; **91**: 66–67.
- 51 Porteous MEM, Burn J, Proctor SJ: Hereditary haemorrhagic telangiectasia: a clinical analysis. *J Med Genet* 1992; **29**: 527–530.
- 52 Shovlin CL, Hughes JM, Tuddenham EG *et al*: A gene for hereditary haemorrhagic telangiectasia maps to chromosome 9q3. *Nat Genet* 1994; **6**: 205–209.
- 53 Shovlin CL, Gibbs JSR, Jackson JE: Management of pulmonary arteriovenous malformations in pulmonary hypertensive patients. A pressure to embolise? *Eur Respir Rev* 2008; **18**: 111; 4–6.
- 54 Zukotynski K, Chan RP, Chow CM *et al*: Contrast echocardiography grading predicts pulmonary arteriovenous malformations on CT. *Chest* 2007; **132**: 18–23.
- 55 van Gent MW, Post MC, Luermans JG *et al*: Screening for pulmonary arteriovenous malformations using transthoracic contrast echocardiography: a prospective study. *Eur Respir J* 2009; **33**: 85–91.
- 56 Gazzaniga P, Buscarini E, Leandro G *et al*: Contrast echocardiography for pulmonary arteriovenous malformations (PAVMs) screening: does any bubble matter? *Eur J Echocardiogr* 2008; e-pub ahead of print 17 December 2008; PMID: 19091794.
- 57 Lasjaunias P: Cerebro medullary arteriovenous locations in children and adults with HHT. *Hematology Meeting Reports* 2007; **1**: 43.
- 58 Shovlin CL, Sodhi V, McCarthy A *et al*: Estimates of maternal risks of pregnancy for women with hereditary haemorrhagic telangiectasia: suggested approach for obstetrics services. *BJOG* 2008; **115**: 1108–1115.
- 59 Lerut J, Orlando G, Adam R *et al*, European Liver Transplant Association: Liver transplantation for hereditary hemorrhagic telangiectasia: report of the European liver transplant registry. *Ann Surg* 2006; **244**: 854–862.
- 60 Brenner D, Elliston C, Hall E, Berdon W: Estimated risks of radiation-induced fatal cancer from pediatric CT. *AJR Am J Roentgenol* 2001; **176**: 289–296.
- 61 Chodick G, Ronckers CM, Shalev V, Ron E: Excess lifetime cancer mortality risk attributable to radiation exposure from computed tomography examinations in children. *Isr Med Assoc J* 2007; **9**: 584–587.
- 62 Thierry-Chef I, Simon SL, Land CE, Miller DL: Radiation dose to the brain and subsequent risk of developing brain tumors in pediatric patients undergoing interventional neuroradiology procedures. *Radiation Res* 2008; **170**: 553–565.
- 63 Shovlin CL, Bamford KB, Wray D: Post NICE 2008: antibiotic prophylaxis prior to dental procedures for patients with pulmonary arteriovenous malformations (PAVMs) and hereditary haemorrhagic telangiectasia. *Br Dent J* 2008; **205**: 531–533.