

Correspondence

Prions and neuronal death

G Di Guardo*¹ and G Marruchella¹

Cell Death and Disease (2010) 1, e6; doi:10.1038/cddis.2009.9; published online 14 January 2010

Subject Category: Neuroscience

This is an open-access article distributed under the terms of the Creative Commons Attribution License, which permits distribution and reproduction in any medium, provided the original author and source are credited. This license does not permit commercial exploitation without specific permission.

Dear Editor,

It is widely accepted that a prominent neuron cell loss occurs in the brain in the course of prion diseases (PDs) or transmissible spongiform encephalopathies (TSEs),¹ which are a group of slowly progressive and invariably fatal neurological disorders affecting man and animals.² Despite this, the inner mechanisms underlying prion-induced neuronal death at the central nervous system (CNS) level are still largely unclear.³ A number of peripheral tissues of the host are colonized by the infectious

agent during the preclinical phase of sheep scrapie, the TSE 'prototype'. These include several lymphoreticular system districts, such as palatine tonsils, ileal Peyer's patches (PPs), and enteric nervous system (ENS) plexuses, from which 'neuroinvasion' – the long journey of prions to the CNS – is believed to take place.¹ In this respect, calbindin (CALB)-immunoreactive (IR), neuronal nitric oxide synthase (nNOS)-IR (Figure 1), and somatostatin-IR neurons have been recently

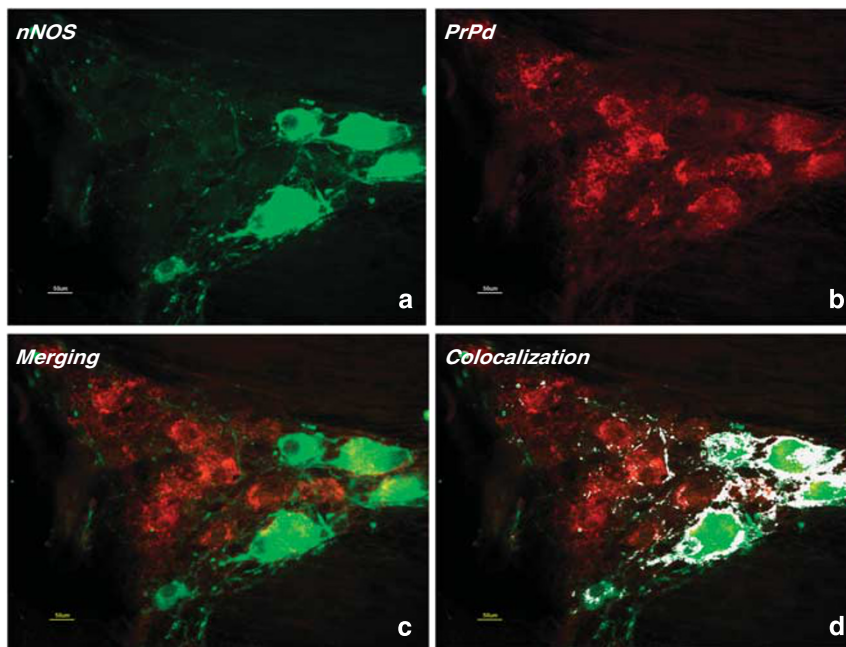


Figure 1 Sheep. Tangential histological sections from an ileal myenteric plexus (MP) of a natural scrapie-affected Sarda breed sheep carrying the homozygous (scrapie-susceptible) ARQ/ARQ PrP genotype. Specific anti-nNOS (neuronal nitric oxide synthase) (a) and anti-PrPd ('disease-specific PrP' or 'pathological PrP') (b) immunolabelling are shown within neuronal perykaria and nerve fibres. Merging (c) and colocalization (d) of the two signals are shown in yellow-orange and in white colour, respectively, with a strong colocalization of nNOS and PrPd immunostaining being detected (d). Double-labelling indirect immunofluorescence with anti-nNOS (rabbit polyclonal) and anti-PrP (mouse monoclonal) commercial antibodies. Fluorescein avidin DCS (D cell sorter) (green colour) and Texas Red avidin DCS (red colour) were used as fluorochromes. Merging and colocalization analyses were carried out by means of *ImageJ* software. Bars = 50 microns

¹Faculty of Veterinary Medicine, Department of Comparative Biomedical Sciences, University of Teramo, Piazza Aldo Moro, 45, Teramo 64100, Italy

*Corresponding author: G Di Guardo, Faculty of Veterinary Medicine, Department of Comparative Biomedical Sciences, University of Teramo, Piazza Aldo Moro, 45, Teramo 64100, Italy. Tel: +39 0861 266 933; Fax: +39 0861 266 865; E-mail: gdiguardo@unite.it

identified as three distinct cell populations residing within ileal ENS plexuses that are selectively targeted during natural and oral experimental sheep scrapie infection.^{4,5} However, differently from that reported at the CNS level,¹ we did not observe significant differences in total (HuC/D-IR) as well as in CALB-IR and nNOS-IR neuron cell counts between the ileal ENS plexuses from scrapie-affected sheep and those from uninfected control sheep carrying an identical 'susceptible' (ARQ/ARQ) PrP genotype.⁴ Furthermore, no evidence of gut dysfunction and/or functional loss was found in these scrapie-affected sheep, which is also in open contrast with that constantly observed in the brain of any PD-affected individual.¹⁻³

These striking results may argue in favour of an 'interaction pattern' between the sheep scrapie agent (and, presumably, also between other TSE agents), on one side, and the host's neurons, on the other, which is different when dealing with either CNS or ENS neurons. Alternatively, a regenerative activity allowing damaged ENS neuronal cells to be numerically restored (at least in part) should not be ruled out.

In conclusion, there is no doubt that this highly fascinating and still largely 'mysterious' topic will continue to be a real

challenge for neuropathologists and neuroscientists in the years to come.

Conflict of interest

The authors declare no conflict of interest.

Acknowledgements. We thank Professor Adriano Aguzzi for his critical revision and his very useful comments on this manuscript.

1. Aguzzi A, Bawmann F, Bremer J. *Annu Rev Neurosci* 2008; **31**: 439-477.
2. Prusiner SB. *Proc Natl Acad Sci USA* 1998; **95**: 13363-13383.
3. Radford HE, Mallucci GR. *Curr Issues Mol Biol* 2009; **12**: 119-128.
4. Marruchella G *et al.* *J Gen Virol* 2007; **88**: 2899-2904.
5. Schneider DA *et al.* *Acta Neuropathol* 2008; **115**: 651-661.



Cell Death and Disease is an open-access journal published by *Nature Publishing Group*. This article is licensed under a **Creative Commons Attribution-NonCommercial-No Derivative Works 3.0 License**. To view a copy of this license, visit <http://creativecommons.org/licenses/by-nc-nd/3.0/>