

On traditional dental extraction: case reports from Dinka and Nuer *en route* to restoration

M. S. Willis,¹ L. E. Harris² and P. J. Hergenrader³

IN BRIEF

- Chronicles memories of a traditional childhood extraction process in Dinka and Nuer refugees from Sudan.
- Describes canine/incisor root retention in three males who experienced ritual extraction during childhood in Sudan.
- Describes dental practice and care systems among Dinka and Nuer in Sudan.
- Provides information about dental status among refugees that might be useful to dentists in western host countries.

Ritual dental extraction among Sub-Saharan African populations has been practised for centuries, yet little is known about the removal process for any ethnic group. Dinka and Nuer refugees to the US requested replacements for missing anterior teeth removed during childhood. Among 36 Sudanese refugees, 238 individual extractions had been performed. Three retained canine/incisor root fragments; their cases are presented, including memories of the tooth-extraction ritual.

The ritual removal of anterior teeth among Sub-Saharan African populations is an ancient practice, at least 1,500 years old,¹ and may have originated when tetanus incidence rates were high and lockjaw prevented normal food intake.²⁻¹² Located in the eastern region of the African continent and north of the equator, Sudan is divided by the Sahara desert. It is in the sub-Saharan region of Sudan, as in much of Sub-Saharan Africa, where anterior tooth extraction occurs just after permanent tooth eruption and has been associated with adulthood, beauty, tribal identity, sound production, and soft food consumption.¹³⁻²⁰ Historically, as many as nine cultures of Southern Sudan removed anterior teeth during their recent history and specific extraction patterns have become inextricably linked to tribal identity.^{15,16,18} Nilotic pastoralists traditionally extracted two

to eight maxillary/mandibular incisors and/or canines.

Presently, it is unclear whether anterior tooth extraction is still performed in Southern Sudan among Nilotic pastoralists such as the Dinka or Nuer. Despite the fact that the Sudanese People's Liberation Army (SPLA) had outlawed dental extraction in late 1986 or early 1987 to eliminate ethnic identification and associated genocide by the Northern Sudanese Government, recent media coverage suggests that extraction practices may still exist in at least some remote Southern Sudanese communities.²¹⁻²³ By contrast, all of the Dinka and Nuer interviewed within this project stated that dental extraction is no longer performed in their respective communities and none of those interviewed expressed a desire for their children now in the US to undergo the removal procedure. Nevertheless, although historic notations can be located, no single study of dental practices for either ethnic group has ever been conducted. Little is known about past or present ritual extractions and dental hygiene practices in Southern Sudan. From the late twentieth century, refugees from the Dinka and Nuer tribes have resettled in the US and requested restoration of missing teeth. A collaborative dental restorative-project, funded by the Jacob and Valeria Langeloth Foundation of New York, provided support to restore the ritually extracted teeth and to study Dinka and Nuer dental

practices and traditions. Contrary to historical accounts, anterior dental extraction is not restricted to males; rather anterior tooth extraction was also performed on females and was essential for the transition to adulthood.^{24,25} Among the Nuer, it was not just the mandibular incisors but also the mandibular canines that were extracted. Furthermore, although not previously described, the permanent maxillary canines were also removed among the Nuer.^{24,25} The following three case reports are of individuals who have retained incisor/canine root fragments. The description of these cases and the memories of extraction procedures provide insight into Dinka and Nuer dental practices. These cases also illustrate the role that Western dentistry can play in the enculturation of refugees to a new context.

CASE REPORT 1

A 34-year-old Nuer male reported that when his teeth were removed, four other boys also had their six mandibular incisors and canines extracted. The extractor or *naak* was a highly respected adult male. The only dental procedure he performed was to remove teeth and he was not paid for this work. The child lay prone with arms and legs restrained. The *naak* knelt and placed the child's head between his knees. With his hand beneath the child's chin, he pulled the child's mouth up and back and used his other hand to place a small knife-like

¹Associate Professor, Department of Anthropology, 928 Oldfather Hall, University of Nebraska Lincoln, Lincoln, Nebraska, 68588-0368, USA; ²Periodontal Resident, Department of Surgical Specialties, College of Dentistry, University of Nebraska Medical Center, Lincoln, Nebraska, 68588-0757, USA; ³Coordinator, Certified Dental Assistant, College of Dentistry, University of Nebraska Medical Center, Lincoln, Nebraska, 68588-0757, USA

*Correspondence to: M. S. Willis
Email: mwillis2@unl.edu

Refereed Paper

Accepted 21 November 2007

DOI: 10.1038/bdj.2008.46

©British Dental Journal 2007; 204: 121-124

instrument between the central incisors. He moved the instrument from side-to-side, luxating the teeth at the midline. The sharp-edged knife was moved to the lingual side of the incisors; the gingival tissues were separated from the root surfaces, the instrument was forced apically along the root's surface, and with an upward motion, the tooth was 'plucked' out. The entire process was done 'quickly' although the time frame could not be recalled. No anaesthetic was provided; still the patient did not cry. The absence of tears was important to one's reputation. Hot milk was provided after removal but nothing else was placed on the surgical site. The patient remembers a headache, that the procedure was 'very painful', but has no recall related to the removal of the tooth that left the residual root (Fig. 1). Within two weeks, the site had healed and he had no further pain.

Within two months of his 2001 arrival in the US, this Nuer male wanted replacements for his mandibular anterior teeth, absent for more than two decades. He was often asked whether he was born without teeth. He thought those in the US with teeth looked 'healthier.' He tried a partial denture, but had trouble biting into dense food items. During the clinical examination, the residual root of the mandibular left lateral incisor or left canine was palpable (Fig. 1); however, a panoramic radiograph revealed no pathology. Prior to implant surgery, the residual root was removed and the height of the alveolar ridge was reduced until an adequate width was obtained for implant placement – in this case to the level of the apices of the adjacent left and right premolars. Three titanium implants were placed. These supported a prosthesis that successfully replaced the missing anterior teeth and restored the anterior aesthetics of the refugee in line with Western constructs.

CASE REPORT 2

This 23-year-old Dinka (Bor subtribe) male had his mandibular anterior teeth removed with three other boys. He estimated that he was seven years old at the time of the tooth extractions. He too did not cry; he escaped teasing from others and confirmed his manhood.

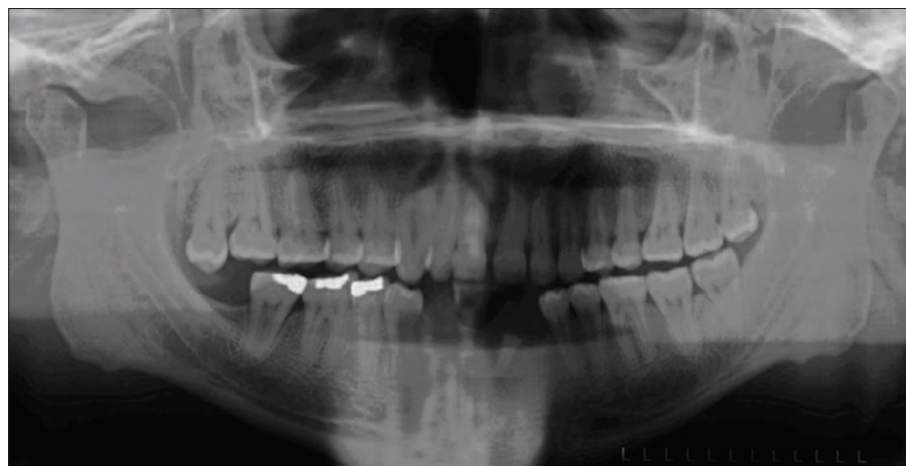


Fig. 1 Presurgical panoramic radiograph for adult Nuer male showing root retention of left mandibular canine or left lateral incisor

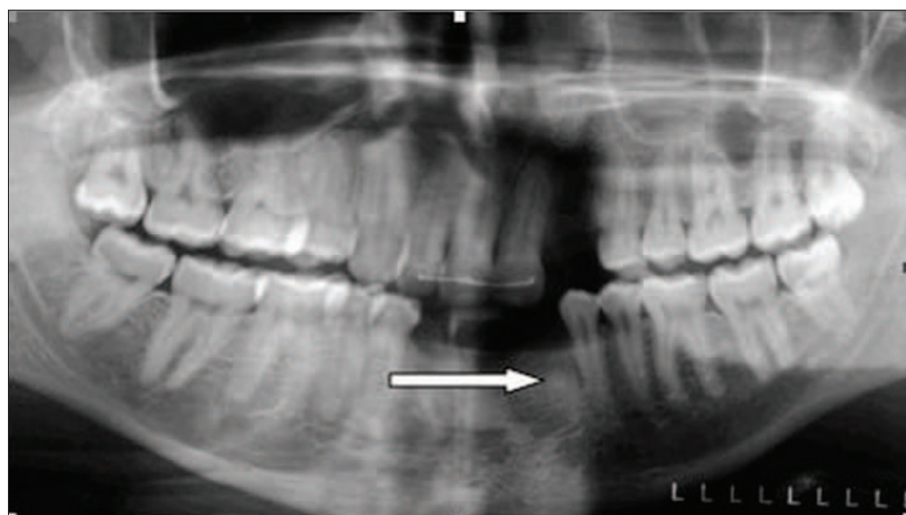

Fig. 2 Presurgical panoramic radiograph of adult Dinka male showing tip of retained left mandibular canine

Emitting neither tears nor sounds, he was not restrained. He sat upright, his head 'squeezed' between the knees of the well-known village extractor or *raan de hoth*. Using a procedure similar to that described above, the mandibular incisors were luxated at the midline using a finger-sized spear, narrow and sharp at the end. Once the teeth were loosened, the extractor 'dug' on the lingual side of the child's gingival tissue and the teeth were 'popped' out. The boy rinsed with boiled hot water and used his tongue to clean the wound 'so that it would be smooth'. Later he was given boiled hot milk.

Arriving in the US during 2001, he immediately sought permanent replacements for his missing mandibular teeth. Because of the uneven resorption of the alveolar ridge (over a ten-plus year period), an osteoplasty was

performed. During the osteoplasty, the root tip of the left mandibular canine was discovered (Fig. 2) and extracted. Three titanium implants were surgically placed and allowed to integrate. The implant-supported prosthesis was seated approximately three months later. This patient also wished to replace missing upper teeth. His right premolar had been extracted in the US and he thought this was because of periodontal disease. The resulting space was closed orthodontically. The left lateral incisor was fractured while playing soccer in Kakuma, Kenya and subsequently extracted in a camp clinic. Finally, it appeared that the left maxillary canine tooth bud had been damaged and subsequently avulsed as the result of a traditional procedure to remedy diarrhoea (Fig. 3). Prior to implant surgery, a bone graft was required to replace missing

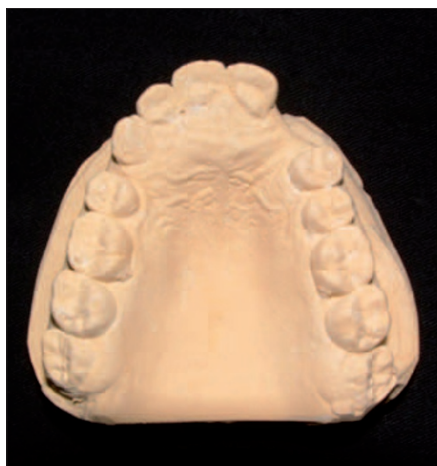

Fig. 3 Occlusal view of dental cast showing presurgical placement of maxillary teeth with missing right lateral premolar, left lateral incisor, and left canine

alveolar bone in this area. The forthcoming dental restoration will restore the dental aesthetics of this patient to a Western standard.

CASE REPORT 3

This 40-year-old Nuer male underwent two childhood extraction procedures, separated in time by one or more years. When he misbehaved as a child, his parents threatened to call the extractor; he then quickly did as he was told. But no warning was issued when his mother arranged for the *naak* to extract his four permanent mandibular incisors. He was the only one to have extractions that day and three adults held him on the ground, arms crossing his chest. Everyone watched and he cried for about an hour. Hot water and milk, boiled on the fire, were provided after the extractions had been performed. He does not remember the uneventful healing period but a few years later, he and his younger male cousin had all of their canines extracted. The maxillary teeth were removed to bring about a cherished midline diastema, *yaari*, while the mandibular ones were removed 'according to the culture.' If the mandibular teeth were not extracted, he could not talk to older boys or any of the girls; he would be considered immature.

From the time he arrived in the US in 1998, he wanted implant surgery. Because the cost was 'high', he felt this was not feasible. He did not consider dentures, noting that, 'If you are

not careful, they can fall down'. Once accepted into the restorative study, a panoramic radiograph revealed canine roots in the mandible and maxilla with no associated pathologies. An osteoplastic procedure was performed on the mandibular alveolar ridge in preparation for placing implants; two retained roots were extracted. The implant-retained prosthesis successfully restored the refugee's anterior aesthetics to US standards.

COMMENT

Missing anterior teeth in 23 of 36 Dinka and Nuer refugees were replaced with implant-supported prostheses to achieve Western aesthetic standards and facilitate enculturation. In each case, refugees sought restoration within the first few months after arrival to the US and attributed their strong desire for restoration to limiting embarrassment about their dental condition and becoming 'American'. Results of an early pilot study indicated that Dinka and Nuer refugees seeking restoration wished to eliminate negative comments and queries about their missing teeth and to eat, speak, and look like Americans in the host community.²⁴ An initial examination of the pre- and post-restoration mental health assessments for the population described here suggests that a similar outcome has been obtained in this subsequent study. Dinka and Nuer refugees feel more confident about the way they look and report functional changes related to sound production in English and the ability to nip or incise food in a manner similar to that of other Americans.²⁴

Three of the 36 restoration candidates examined had root fragments retained within the mandibular alveolar bone. One of these candidates also had a canine root retained within the maxilla. Out of 238 tooth extractions from the maxilla and mandible, all performed by traditional 'extractors' in Sudan, just 2% resulted in residual roots or fragments remaining in the jaw. No Western technologies, eg radiographs, pharmaceuticals, nor surgical instruments, were available. In all but one instance, it was the canine teeth whose remnants were retained. Thus as one refugee stated, 'they [the extractors] were very good at

it', performing extractions rapidly on all children just after their permanent teeth had erupted.

In addition to the mandibular extractions, the Dinka patient explained that treatment for diarrhoea included the cutting of gingival tissue, providing 'relief' to swollen gingival tissue where the maxillary canines were erupting. This appears to have been a common practice in Southern Sudan, as well as in other East African countries, although the reasons for performing 'germectomy' on infants and the specific tooth buds affected have varied within and between countries and populations. For example, removal can be undertaken for medical or religious reasons and can involve not just tooth buds of the maxillary and mandibular canines, but also the maxillary and mandibular incisors.²⁶⁻³⁰

Traditional post-operative techniques included use of boiled water after surgery, cleaning with sticks of *Salvador persica* (the toothbrush tree), and the use by both Dinka and Nuer of cow dung ash as a dentifrice. The toothbrush tree has been shown to be effective against periodontal disease³¹ and cow dung ash, according to the refugees, maintains bright white enamel and effectively removes food particles from the occlusal surface. Once in the US, successful restoration of ritually extracted teeth facilitated enculturation to a new context. Refugees reported changes that they considered important to successful resettlement – the ability to eat, speak, and look like members of the host community.

1. Morris A G. Human remains from the early Iron Age sites of Nanda and KwaGandaganda, Mngeni Valley, Natal, South Africa. *Natal Mus J Hum* 1993; **5**: 83-98.
2. Chindia M L. Traditional dental practices. *East Afr Med J* 1995; **72**: 205-206.
3. Goose D H. Tooth-mutilation in West Africans. *Man* 1963; **63**: 91-93.
4. Halestrap D J. Indigenous dental practice in Uganda. *Br Dent J* 1971; **131**: 463-466.
5. Hassanali J, Amwayi P. Report on two aspects of Maasai dentition. *East Afr Med J* 1988; **65**: 798-803.
6. Hinde S L, Hinde H B. *The Last of the Masai*. London: W Heinemann, 1901.
7. Hollis A C. *The Nandi: their language and folklore*. Oxford: The Clarendon Press, 1909.
8. Humphreys C E. Dental operations practised in primitive communities. *Proc Royal Soc Med* 1954; **47**: 313-316.
9. Moshia H J. Dental mutilation and associated abnormalities in Tanzania. *Odontostomatol Trop* 1983; **4**: 215-219.
10. Singer R. Artificial deformation of teeth: a preliminary report. *S Afr J Sci* 1953; **December**: 116-121.

11. Townend B R. The non-therapeutic extraction of teeth and its relation to the ritual disposal of shed deciduous teeth. *Br Dent J* 1963; **115**: 354-357.
12. Van Rippen B. Practices and customs of the African natives involving dental procedures. *J Allied Dent Soc* 1918; **13**: 1-22.
13. Briedenham S J, Van Reenen J F. Tooth mutilating practices amongst the Ovambo and the West Caprivi Bushmen of South West Africa (Namibia). *J Dent Assoc S Africa* 1978; **33**: 665-671.
14. Briedenham S J. Kaokoland and its people. *J Dent Assoc S Africa* 1987; **42**: 457-460.
15. Deng F M. *The Dinka of the Sudan*. Prospect Heights: Waveland Press, Inc., 1972.
16. Domville-Fife C W. *Savage life in the Black Sudan*. Philadelphia: J. B. Lippincott Company, 1927.
17. Evans-Pritchard E E. The Nuer: a description of the modes of livelihood and political institutions of a Nilotic people. Oxford: Oxford University Press, 1940.
18. Seligman C G, Seligman B Z. *Pagan tribes of the Nilotic Sudan*. London: George Routledge & Sons, Ltd., 1932.
19. Van Reenen J F. Tooth mutilation amongst the peoples of Kavango and Bushmanland, South West Africa (Namibia). *J Dent Assoc S Africa* 1978; **33**: 205-218.
20. Van Reenen J F, Briedenhahn S J. Tooth mutilating practices amongst the Damara of South West Africa (Namibia). *J Dent Assoc S Africa* 1985; **40**: 537-539.
21. Currington M. Tribal secrets: the Dinka. Documentary film. *National Geographic* (USA) 2006. Original air date: 22 June 2007.
22. Gettleman J. Poolcooch Journal: in Southern Sudan, peace alters a way of life. *The New York Times* 2007; September 13.
23. Hutchinson S E. *Nuer dilemmas: coping with money, war, and the state*. Los Angeles: University of California Press, 1996.
24. Willis M S, Schacht R N, Toothaker R. Anterior dental extractions among Dinka and Nuer refugees in the United States: a case series. *Spec Care Dentist* 2005; **25**: 193-198.
25. Willis M S, Swindler D R, Toothaker R W. A description of Nuer and Dinka anterior tooth extractions, practices and a preliminary odontometric analysis of the remaining permanent dentition. In ZadZinska E (ed). *Current trends in dental morphology research*. pp 177-189. Lodz, Poland: University of Lodz Press, 2005.
26. Baba S P, Kay E J. The mythology of the killer deciduous canine tooth in Southern Sudan. *J Pedod* 1989; **14**: 48-49.
27. Hassanali J, Amwayi P, Muriithi A. Removal of deciduous canine tooth buds in Kenyan rural Maasai. *East Afr Med J* 1995; **72**: 207-209.
28. Abusinna I M. Lugbara teeth germectomy of canines for newborn babies; a magico-religious phenomena in some African tribes. *Egypt Dent J* 1979; **25**: 209-214.
29. Johnston N L, Riordan P J. Tooth follicle extirpation and uvulectomy. *Aus Dent J* 2005; **50**: 267-272.
30. Mogensen H O. False teeth and real suffering: the social course of 'Germectomy' in Eastern Uganda. *Cult Med Psychiatry* 2000; **24**: 331-351.
31. Darout I A, Albandar J M, Skaug N. Periodontal status of adult Sudanese habitual users of miswak chewing sticks or toothbrushes. *Acta Odontol Scand* 2000; **58**: 25-30.