

## LETTER TO THE EDITOR

# Paroxysmal nocturnal hemoglobinuria and concurrent $JAK2^{V617F}$ mutation

*Blood Cancer Journal* (2012) **2**, e63; doi:10.1038/bcj.2012.7; published online 23 March 2012

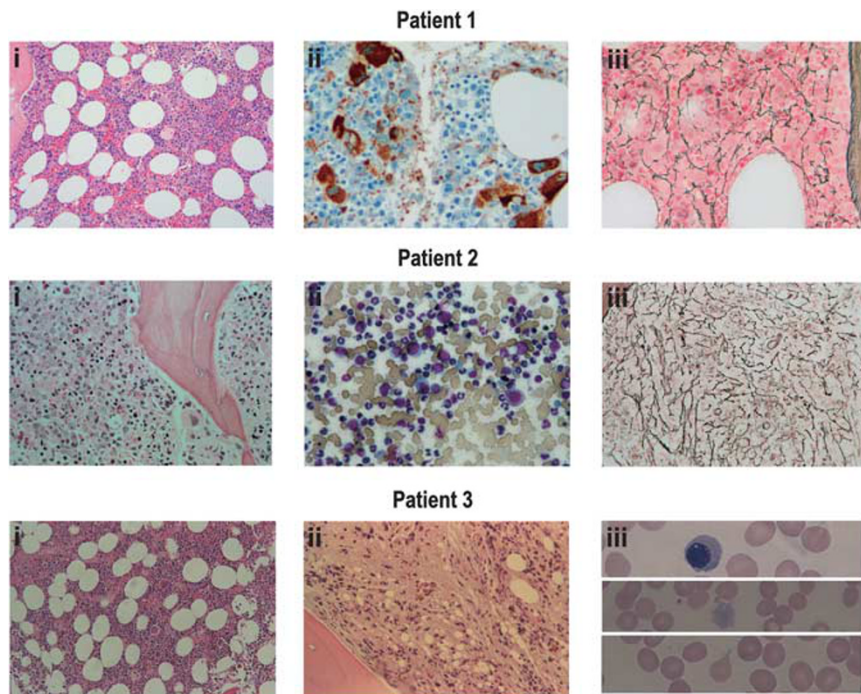
Paroxysmal nocturnal hemoglobinuria (PNH) is a hemolytic and pro-thrombotic disorder associated with the clonal expansion of hematopoietic stem cells harboring somatic mutations in the *PIG-A* gene.<sup>1</sup> Mutations in *PIG-A* result in a lack of surface expression of all glycosylphosphatidylinositol (GPI)-anchored proteins, including the complement inhibitors CD55 and CD59,<sup>2</sup> which is responsible for the hemolytic (and probably also the pro-thrombotic) phenotype.<sup>3,4</sup> However, long-term colony-forming assays and *in vivo* murine models have failed to show that *PIG-A* mutations are alone sufficient to drive clonal expansion.<sup>5,6</sup>

There are two leading hypotheses to account for clonal expansion of *PIG-A*-null stem cells: (i) clonal selection and (ii) second mutations. The first model posits that aplastic anemia—which is epidemiologically associated with PNH—results in an immune-mediated marrow injury that selectively spares PNH stem cells.<sup>7</sup> The second hypothesis is borrowed from models of

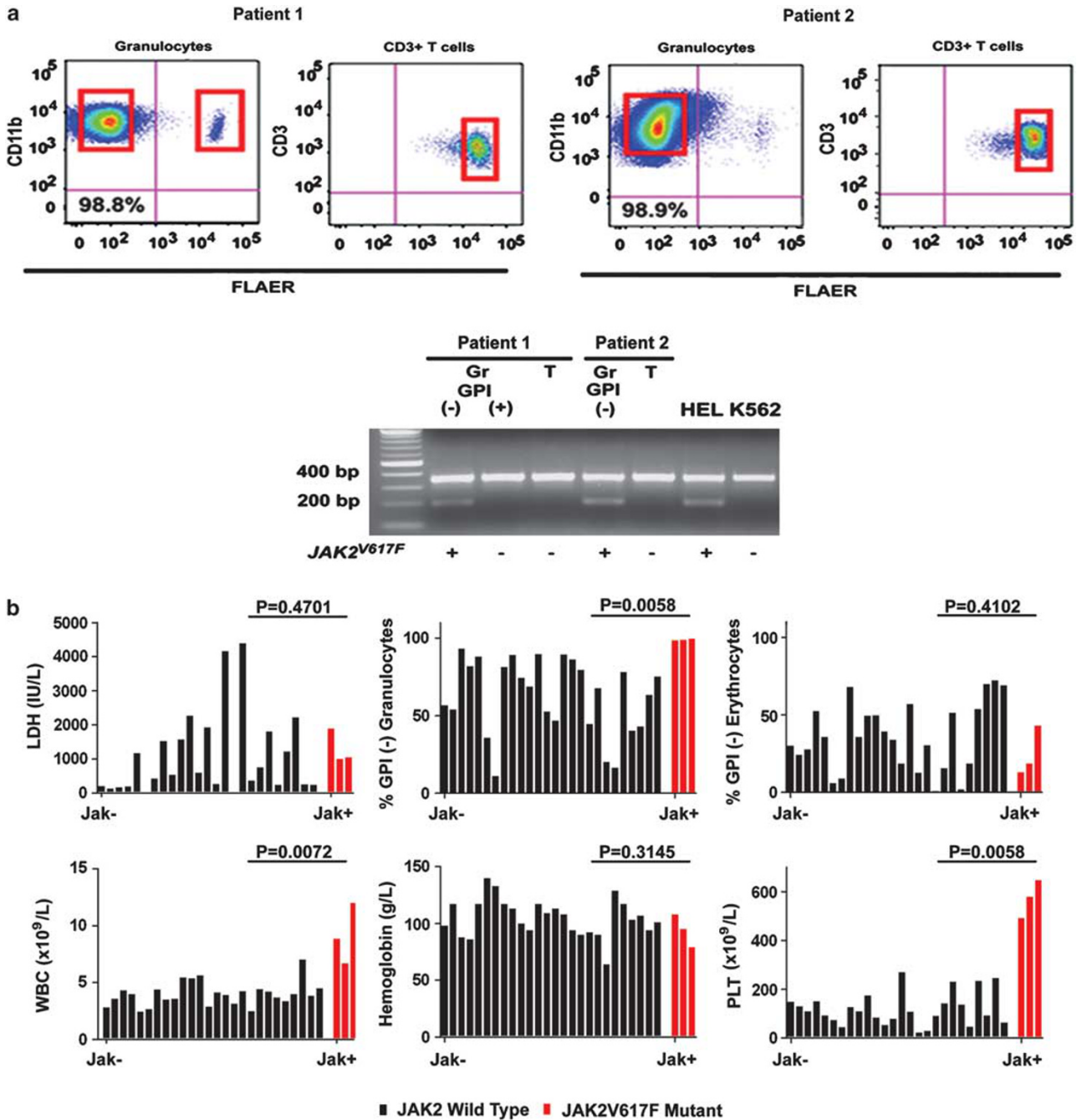
oncogenesis and may be supported by the observation that patients with PNH can harbor clonal cytogenetic abnormalities.<sup>8</sup> However, no specific gene mutations other than *PIG-A* have been reported in patients with PNH—with one exception. In two patients, a rearrangement of chromosome 12 with a break in the 3'-untranslated region of the *HMG2* gene has been reported.<sup>9</sup> Overexpression of an *HMG2* truncated protein recapitulates an myeloproliferative neoplasms (MPN)-like phenotype in a murine model and could theoretically contribute to clonal expansion in PNH.<sup>10</sup>

Interestingly, literature from the 1970's has reported several cases of PNH in association with myelofibrosis and other MPNs.<sup>11,12</sup> Here we report on three index cases of PNH with myeloproliferative features harboring a  $JAK2^{V617F}$  mutation, which is now understood to drive clonal expansion in many MPNs.<sup>13</sup>

The first case is a 51-year-old male, presenting with right hemiparesis and dysarthria secondary to a stroke, followed by multiple thrombotic events, including the Budd Chiari Syndrome (BCS). A hypercoagulable workup revealed the presence of the  $JAK2^{V617F}$  mutation in the peripheral blood. Upon referral to us, a complete



**Figure 1.** Morphological features of the bone marrow in patients with PNH and the  $JAK2^{V617F}$  mutation. Patient 1: (i) hematoxylin–eosin-stained section showing hyperplasia and mild dysplasia. (ii) Anti-factor VIII section showing increased number of megakaryocytes (stained in brown) with mild dysplasia. (iii) Reticulin stain showing moderately increased reticulin staining (grade 2), indicative of mild fibrosis. Patient 2: (i) hematoxylin–eosin-stained section, showing hypercellularity and an increase in small hypolobated megakaryocytes. The myeloperoxidase stain (data not shown) is strongly positive in most of the cells. (ii) Wright stain. There were no spicules present, but the aspirate is richly cellular and demonstrates predominance of myeloid cells with an M:E ratio of ~8:1. (iii) Reticulin stain showing diffuse increase in reticulin. Trichrome stain was negative. Patient 3: (i) hematoxylin–eosin-stained section, 2006, showing normocellularity; megakaryocytes were present but not increased; (ii) repeat marrow examination in 2010, demonstrating marked distortion of the architecture by fibrosis; reticulin stain was 4+ positive at this time. (iii) peripheral smear findings in 2011 typical of a myeloproliferative syndrome: nucleated red blood cells, giant PLTs and occasional teardrops.



**Figure 2.** Cellular origin of PNH and *JAK2*<sup>V617F</sup> mutation. (a) To clarify the cellular origin of *JAK2*<sup>V617F</sup> mutation, GPI (-) cells and GPI (+) cells were isolated with fluorescence-activated cell-sorting method using a FACSria (BD Biosciences, San Jose, CA, USA). CD11b<sup>+</sup>FLAER<sup>+</sup> (GPI+) granulocytes, CD11b<sup>+</sup>FLAER<sup>-</sup> (GPI-) granulocytes and CD3<sup>+</sup>FLAER<sup>+</sup> (GPI+) lymphocytes were isolated from patient no.1, whereas CD11b<sup>+</sup>FLAER<sup>-</sup> (GPI-) granulocytes and CD3<sup>+</sup>FLAER<sup>+</sup> (GPI+) lymphocytes were isolated from patient no. 2. Purity of sorted CD11b<sup>+</sup>FLAER<sup>-</sup> (GPI-) granulocytes from patient no.1 exceeded 99%. CD11b<sup>+</sup>FLAER<sup>+</sup> (GPI+) granulocytes were 83% pure. From each population, genomic DNA was isolated using the PureLink DNA Mini Kit (Invitrogen, Carlsbad, CA, USA). The DNA tetra-primer ARMS was performed to detect the *JAK2*<sup>V617F</sup> mutation using a mutant and a specific forward primer with a common reverse primer. Presence of the mutation resulted in the amplification of a 203-bp DNA product; wild-type primers generated a 364-bp product. HEL and K562 cells were included as positive and negative controls for the *JAK2*<sup>V617F</sup> mutation, respectively. This analysis was non-quantitative, but demonstrated the presence and absence of *JAK2*<sup>V617F</sup> as shown (+ vs -) in different cell populations. (b) Waterfall plot displaying clinical characteristics of *JAK2*<sup>V617F</sup>-positive mutants PNH patients (red) compared with *JAK2*<sup>V617F</sup>-negative mutants (black). LDH (IU/l), % GPI (+) granulocytes, % GPI (-) erythrocytes, WBC, (cells × 10<sup>9</sup>/l), hemoglobin (g/l) and PLT (cells × 10<sup>9</sup>/l) count. The percentage of GPI (-) granulocytes, WBC and PLT are all statistically higher (Mann-Whitney) in *JAK2* mutant patients compared with controls, whereas LDH and GPI (-) erythrocytes are not. Analyses were performed on samples obtained from patients after provision of informed consent as per institutional protocols.

blood count noted an Hgb of 5 g/dl, platelets (PLTs) of  $492 \times 10^9/l$  and a white blood cell (WBC)  $8.90 \times 10^9/l$ . Bone marrow biopsy revealed a hypercellular marrow (80–100%), dysmegakaryopoiesis,

a 4% myeloblast population and normal cytogenetics (Figure 1). The patient later presented with an elevated lactate dehydrogenase (LDH) and undetectable haptoglobin. Flow cytometry

revealed that 99% of the granulocytes and 13% of the erythrocytes were GPI (–), confirming the diagnosis of PNH, and the patient was initiated on eculizumab. Although he has been transfusion independent for 3 years with this therapy, he has had multiple complications of BCS, including esophageal variceal hemorrhage.

The second patient, a 65-year-old male, presented with darkened urine and transfusion-dependent anemia, and was found to have 40% PNH red cells. At that time, hematological parameters were: WBC  $6.7 \times 10^9/l$ , 76.7% granulocytes Hgb 95 g/l and PLTs  $580 \times 10^9/l$ . His LDH was nine-fold the upper limit of normal. Two years later, despite prophylactic anticoagulation with coumadin, he developed a splenic infarction, prompting a splenectomy. His WBC then rose to over  $100\,000 \times 10^9/l$  and his PLT count to over  $1\,000\,000 \times 10^9/l$ , and the  $JAK2^{V617F}$  mutation was identified. He developed a post-operative portal vein thrombosis, and he was treated at that time with hydroxyurea, oral anticoagulation and eculizumab. Ten months later, he developed BCS in the setting of a therapeutic international normalized ratio, but low trough eculizumab levels; BCS completely resolved with intravenous tissue plasminogen activator, and he was started on aspirin, fondaparinux and hydroxyurea—and a shorter eculizumab-dosing interval. He then developed a progressively increasing WBC, and the marrow demonstrated hypercellularity, granulocytic hyperplasia and moderate reticulin fibrosis (Figure 1), and a 46, XY, del (17) (p11) (18/24) karyotype. Three additional metaphases demonstrated the del17 abnormality with a non-clonal additional abnormality in each case. He was given decitabine, but expired 4 years after the diagnosis of PNH secondary to progressive liver failure due to iron overload.

The third patient is a 78-year-old male with a history of prostate cancer in 2004, treated with brachytherapy. He also had a history of arthritis, pulmonary hypertension and cutaneous melanoma. In 2003, he was mildly anemic, and in 2006, a marrow examination revealed hypercellularity without excess blasts. In 2009, he noticed dark urine; the Hgb was 102 g/l with 4.5% reticulocytes, PLTs  $648 \times 10^9/l$ , WBC  $10.1 \times 10^9/l$ , 77% polys, 15% lymphocytes and 7% monocytes. The LDH was 1367 IU/L (normal < 243), and flow cytometry demonstrated 73% CD59-negative granulocytes and 53% CD59-negative red cells. Repeat marrow examination in 2010 was notable for hypercellularity and severe fibrosis (Figure 1). The karyotype was normal (20/20), and the  $JAK2^{V617F}$  mutation was identified. The patient developed transfusion-dependent anemia not responding to eculizumab, steroids or danazol. At the time of referral in 2011, the WBC was  $12.1 \times 10^9/l$  with 71% polys, 3% metamyelocytes, 2% myelocytes, 1% blasts, 10% lymphocytes, 8% monocytes, 3% basophils and 1% nucleated red blood cells; Hgb was 79 g/l and the absolute reticulocyte count was 97 500/ $\mu$ l. The peripheral blood smear demonstrated poikilocytosis, rare teardrops, some giant PLTs and giant early myeloid precursors. LDH was 1047 IU/l (normal < 180) and ferritin was 2908 ng/ml. The spleen was not palpable. Repeat analysis demonstrated 43% CD59-negative red cells and 99.7% FLAER-negative, CD24-negative granulocytes. Molecular testing again revealed the  $JAK2^{V617F}$  mutation, and he was treated with eculizumab, aspirin and fondaparinux. The patient had several bouts of pneumonia and eventually succumbed in September 2011 to a severe *Clostridium difficile* infection.

A total of 26 subsequent patients (mean age, 36 years; range, 15–65) with PNH were tested for the  $JAK2^{V617F}$  mutation by the DNA tetra-primer amplification refractory mutation system (ARMS). All patients had intravascular hemolysis and were considered to have classic PNH. A total of 23 cases (77%) were *de novo* and 7 (23%) had antecedent aplastic anemia. The percentage of GPI (–) granulocytes ranged from 22 to 99% (median 71.6%) and GPI (–) erythrocytes ranged from 0.86 to 72.3% (median 32.4%) by FLAER staining and flow cytometry. Serum LDH levels were elevated in most patients (mean 1204 IU/l,

range 129–4393 IU/l, normal < 618 IU/l). The median WBC was  $4.48 \times 10^9/l$  (range, 2.44–8.90), median Hgb level was 117 g/l (range, 6.4–14.0) and median PLT count was  $108 \times 10^9/l$  (range, 28–648). Hepatic, cerebral or mesenteric thrombosis was found in 6 of the 29 patients (21%), and 3 had BCS. On the basis of the ARMS analysis, the  $JAK2^{V617F}$  mutation was not detected in any of these 26 patients.

In both case 1 and 2, the molecular lesion in the *PIG-A* gene was identified to be a 500-kb deletion at Xp22.2 by single-nucleotide polymorphism array, as we have published previously.<sup>14</sup> To determine the cellular origin of the  $JAK2^{V617F}$  mutation in these two patients, DNA was extracted from GPI (–) CD11b<sup>+</sup> granulocytes, GPI (+) CD11b<sup>+</sup> granulocytes and CD3<sup>+</sup> T cells after FLAER staining and flow cytometry sorting.  $JAK2^{V617F}$  was selectively detected in GPI (–) granulocytes, but not in GPI (+) granulocytes or T cells, clearly showing that the  $JAK2^{V617F}$  mutation is not in the germline and that it co-exists within in the PNH clone (Figure 2).

The occurrence of PNH clones in MDS and aplastic anemia is well documented and routinely evaluated in clinical practice. This series now documents the coexistence of PNH and  $JAK2^{V617F}$ -associated MPNs in three index cases with a higher PLT count and WBC compared with PNH patients overall (Figure 2b). Two of the three cases were shown to harbor the  $JAK2^{V617F}$  mutation within the PNH clone. In the third patient, 99% of the granulocytes were GPI (–), suggesting that  $JAK2^{V617F}$  mutation also occurred within the PNH clone. Apart from *HMG2A*, this now represents the second mutation coexisting with PNH that could explain clonal expansion. The prevalence of PNH clones among MPN patients is unknown, because these three index patients were ascertained by referral. In rare patients, even before the era of flow cytometry and molecular testing, a MPN/PNH overlap syndrome was identified.<sup>11,13,14</sup> Of note, no  $JAK2^{V617F}$  mutations were detected in 26 subsequently screened PNH patients, suggesting that the prevalence of this mutation is not high in classic PNH, consistent with an earlier report.<sup>15</sup>

On the basis of these findings, we believe that JAK2 mutation testing should be performed on patients with PNH, who have elevated peripheral blood counts. Considering that most patients with PNH are mildly cytopenic (Figure 2b), this recommendation might extend to those with blood counts towards the upper limit of normal. Unexplained splenomegaly or a fibrotic marrow would also represent an indication for JAK2 mutation analysis. Conversely, patients with an MPN and signs of hemolysis should be tested for PNH by flow cytometry.

## CONFLICT OF INTEREST

Dr Epling-Burnette received a grant from Genzyme Corporation for the development of the PNH test. Dr Araten is on the Scientific Advisory Board of Alexion, Inc. Dr Lee has attended advisory meetings for Alexion, Millenium and Novartis. All other authors have no potential conflicts of interest.

## ACKNOWLEDGEMENTS

This study was supported by the NIH Grant CA129952-02, VA Merit Review 11018X-000670 and Genzyme Corporation. We thank the Flow Cytometry Core Facility for their assistance with sorting cells for this project, and the Malignant Hematology Program and Bridget Lane, RN for assistance with patient sample collection. We thank Dr Katherine Waters for her assistance in reviewing pathology slides.

C Sugimori<sup>1,7</sup>, E Padron<sup>2,7</sup>, G Caceres<sup>2,7</sup>, K Shain<sup>2</sup>, L Sokol<sup>2</sup>, L Zhang<sup>3</sup>, R Tiu<sup>4</sup>, CL O'Keefe<sup>4</sup>, M Afable<sup>4</sup>, M Clemente<sup>4</sup>, JM Lee<sup>5</sup>, JP Maciejewski<sup>4</sup>, AF List<sup>2</sup>, PK Epling-Burnette<sup>1,8</sup> and DJ Araten<sup>6,8</sup>

<sup>1</sup>Department of Immunology, H Lee Moffitt Cancer Center and Research Institute, Tampa, FL, USA;

<sup>2</sup>Malignant Hematology Division, H Lee Moffitt Cancer Center and Research Institute, Tampa, FL, USA;

<sup>3</sup>Department of Pathology, H Lee Moffitt Cancer Center and Research Institute, Tampa, FL, USA;

<sup>4</sup>Department of Translational Hematology and Hematopoiesis, Taussig Cancer Institute, Cleveland Clinic, Cleveland, OH, USA;

<sup>5</sup>Division of Hematology/Oncology, Maine VA Medical Center, Augusta, ME, USA and

<sup>6</sup>Division of Hematology NYU Langone Cancer Center and the New York VA Medical Center, New York, NY, USA

E-mail: [Pearlie.Burnette@moffitt.org](mailto:Pearlie.Burnette@moffitt.org)

<sup>7</sup>Shared first authorship.

<sup>8</sup>Shared senior authorship.

## REFERENCES

- Bessler M, Mason PJ, Hillmen P, Miyata T, Yamada N, Takenda J *et al.* Paroxysmal nocturnal haemoglobinuria (PNH) is caused by somatic mutations in the PIG-A gene. *EMBO J* 1994; **13**: 110-117.
- Miyata T, Takeda J, Iida Y, Yamada N, Inoue N, Takahashi *et al.* The cloning of PIG-A, a component in the early step of GPI-anchor biosynthesis. *Science* 1993; **259**: 1318-1320.
- Medof ME, Kinoshita T, Nussenzweig V. Inhibition of complement activation on the surface of cells after incorporation of decay-accelerating factor (DAF) into their membranes. *J Exp Med* 1984; **160**: 1558-1578.
- Venneker GT, Asghar SS. CD59: a molecule involved in antigen presentation as well as downregulation of membrane attack complex. *Exp Clin Immunogenet* 1992; **9**: 33-47.
- Rosti V, Tremml G, Soares V, Pandolfi PP, Luzzatto L, Bessler M. Murine embryonic stem cells without pig-a gene activity are competent for hematopoiesis with the PNH phenotype but not for clonal expansion. *J Clin Invest* 1997; **100**: 1028-1036.
- Moore JG, Humphries RK, Frank MM, Young N. Characterization of the hematopoietic defect in paroxysmal nocturnal hemoglobinuria. *Exp Hematol* 1986; **14**: 222-229.
- Rotoli B, Luzzatto L. Paroxysmal nocturnal haemoglobinuria. *Baillieres Clin Haematol* 1989; **2**: 113-138.
- Araten DJ, Swirsky D, Karadimitris A, Notaro R, Nafa K, Bessler M *et al.* Cytogenetic and morphological abnormalities in paroxysmal nocturnal haemoglobinuria. *Br J Haematol* 2001; **115**: 360-368.
- Inoue N, Izui-Sarumaru T, Murakami Y, Endo Y, Nishimura J, Kurokawa K *et al.* Molecular basis of clonal expansion of hematopoiesis in 2 patients with paroxysmal nocturnal hemoglobinuria (PNH). *Blood* 2006; **108**: 4232-4236.
- Ikeda K, Mason PJ, Bessler M. 3' UTR-truncated Hmga2 cDNA causes MPN-like hematopoiesis by conferring a clonal growth advantage at the level of HSC in mice. *Blood* 2011; **117**: 5860-5869.
- Hansen NE, Killmann SA. Paroxysmal nocturnal hemoglobinuria in myelofibrosis. *Blood* 1970; **36**: 428-431.
- Luzzatto L, Familusi JB, Williams CK, Junaid TA, Rotoli B, Alfinito F. The PNH abnormality in myeloproliferative disorders: association of PNH and acute erythremic myelosis in two children. *Haematologica* 1979; **64**: 13-30.
- Levine RL, Wadleigh M, Cools J, Ebert BL, Werning G, Huntly BJ *et al.* Activating mutation in the tyrosine kinase JAK2 in polycythemia vera, essential thrombocythemia, and myeloid metaplasia with myelofibrosis. *Cancer Cell* 2005; **7**: 387-397.
- O'Keefe CL, Sugimori C, Afable M, Clemente M, Shain K, Araten DJ *et al.* Deletions of Xp22.2 including PIG-A locus lead to paroxysmal nocturnal hemoglobinuria. *Leukemia* 2011; **25**: 379-382.
- Fouassier M, Girodon F, Cleyrat C, Robillard N, Garand R, Hermouet S. Absence of JAK2-V617F in paroxysmal nocturnal haemoglobinuria-associated thrombosis. *Thromb Haemost* 2009; **102**: 180-182.



This work is licensed under the Creative Commons Attribution-NonCommercial-No Derivative Works 3.0 Unported License. To view a copy of this license, visit <http://creativecommons.org/licenses/by-nc-nd/3.0/>