

Erratum

Persistence of *Plasmodium falciparum* in the Placenta After Apparently Effective Quinidine/Clindamycin Therapy

Procop GW, Jessen R, Hyde SR, Scheck DN. *J Perinatol* 2001;21:128–130.

Since publication of the above paper, the authors have identified that Figure 2 was omitted from the paper. The missing figure is reproduced below.

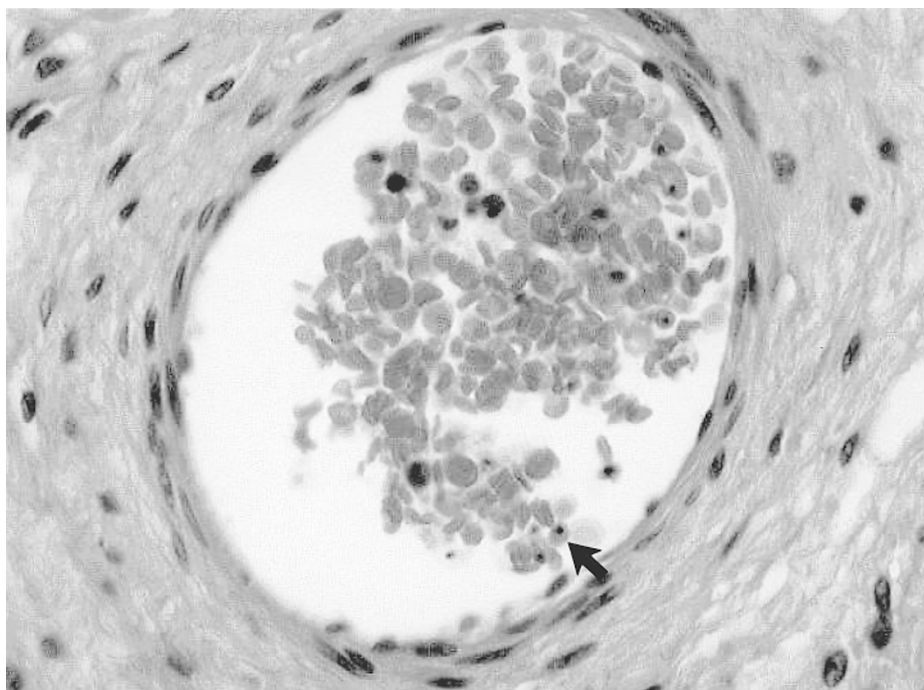


Figure 2. Rare *P. falciparum*-infected erythrocytes in the fetal circulation of this patient's placenta. 600 \times magnification.

Clinical Microbiology/L40, Cleveland Clinic Foundation, 9500 Euclid Avenue, Cleveland, OH.

Address correspondence and reprint requests to Gary Procop, Clinical Microbiology/L40, Cleveland Clinic Foundation, 9500 Euclid Ave., Cleveland, OH 44195.

Journal of Perinatology 2001; 21:347

© 2001 Nature Publishing Group All rights reserved. 0743-8346/01 \$17

www.nature.com/jp