Sir,

Injecting an air bubble at the end of sutureless cataract surgery to prevent inflow of ocular surface fluid

The overall UK incidence of postoperative endophthalmitis is approximately one in 700,[1] with an increase in incidence observed recently.[2] Inflow of ocular surface fluid through sutureless-cataract surgery wounds has been observed in both laboratory[3] and human studies.[4] Contamination of aqueous by ocular surface bacteria can cause low-grade endophthalmitis[5] and might have a role in the aetiology of endophthalmitis post-cataract surgery.

We demonstrate how introducing a small air bubble in the anterior chamber, at the end of sutureless cataract surgery, can prevent inflow of ocular surface fluid.

Case report

Digital video recording of 14 serial patients, showing bleeding from the limbal capillary bed were included. All wounds were 2.8-mm limbal incisions sealed by stromal hydration. Patient manipulation was simulated by external pressure and release of the speculum before and after injection of a 0.1 ml air bubble.

Spontaneous inflow of blood-tinged ocular surface fluid into the anterior chamber through the wound was observed in 2 out of 14 eyes (14.3%) (Figures 1–4). A further four patients (28.5%) demonstrated inflow with light speculum manipulation. In all six patients, inflow immediately stopped after the air bubble had been injected into the anterior chamber. The bubble disappeared after 24 h in all patients without complications.

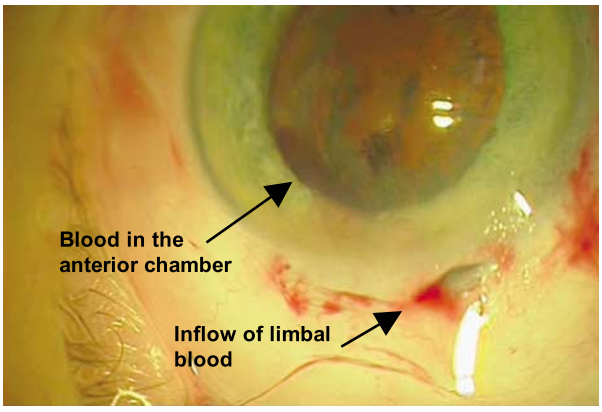

Figure 1 Patient 1—Spontaneous inflow of limbal blood.

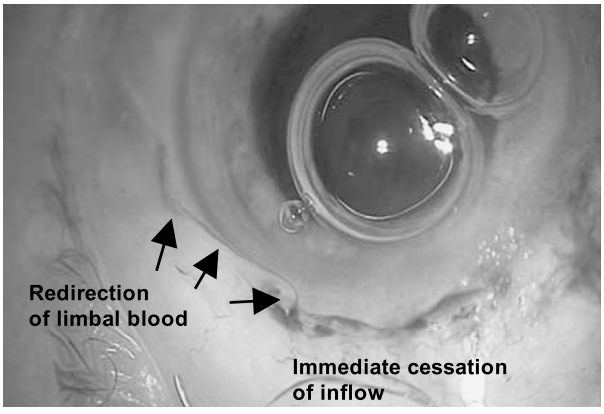

Figure 2 Patient 1—Immediate cessation of inflow—blood is redirected around the limbus on air bubble introduction.

Comment

Inflow of ocular surface fluid can occur with speculum removal at the end of surgery, and excessive squeezing or manipulation by the patient. We observe that the air bubble, which is compressible, allows the anterior chamber more compliance. This prevents wound leak and suction/inflow with positive and negative pressures created by external forces. This is especially crucial during the first 24 h after intraocular surgery.

Other advantages of the air bubble include: unrolling a Descemet's scroll, confirming the eye is not leaking (bubble does not get bigger), defocusing light after IOL implantation and so preventing macula phototoxicity,

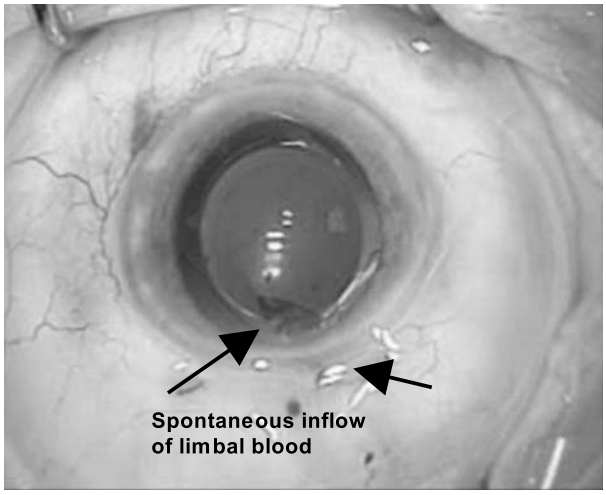

Figure 3 Patient 2—Spontaneous inflow into anterior chamber.

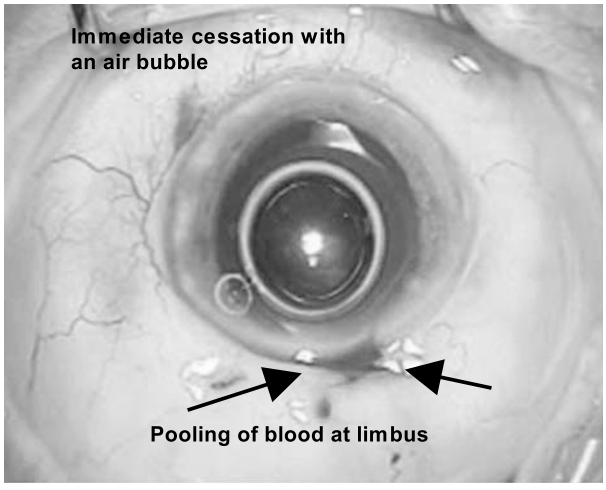

Figure 4 Patient 2—Cessation of inflow with air bubble—pooling of blood at limbus after air bubble introduction.

and buffering against postoperative intraocular pressure spikes. Pupil block, toxicity to the endothelium, and associated visual phenomenon were not observed in our study. The air bubble disappeared within 24 h minimizing such risks.This simple procedure may reduce intraocular contamination and rate of postoperative endophthalmitis.

Acknowledgements

This work was presented at ESCRS London 2006, as a video, and at Asia ARVO Singapore 2007, as an oral presentation. It has not been previously published.

References

1 Kamalarajah S, Silvestri G, Sharma N, Khan A, Foot B, Ling R *et al*. Surveillance of endophthalmitis following cataract surgery in the UK. *Eye* 2004; **18**: 580–587.
2 Taban M, Behrens A, Newcomb RL, Nobe MY, Saedi G, Sweet PM *et al*. Acute endophthalmitis following cataract surgery: a systematic review of the literature. *Arch Ophthalmol* 2005; **123**: 613–620.
3 Sarayba MA, Taban M, Almeda TI, Behrens A, Mc Donnell PJ. Inflow of ocular surface fluid through clear corneal cataract incisions: a laboratory model. *Am J Ophthalmol* 2004; **138**: 206–210.
4 Herretes S, Stark WJ, Pirouzmanesh A, Reyes JMG, Mc Donnell PJ, Behrens A. Inflow of ocular surface fluid into the anterior chamber after phacoemulsification through sutureless corneal cataract wounds. *Am J Ophthalmol* 2005; **140**: 737–740.
5 Suzuki T, Uno T, Kawamura Y, Joko T, Ohashi Y. Postoperative low-grade endophthalmitis caused by biofilm-producing coccus bacteria attached to posterior surface of intraocular lens. *J Cataract Refract Surg* 2005; **31**(10): 2019–2020.

DA Sim[1], R Wong[1] and MFP Griffiths[2]

[1]Department Ophthalmology, Moorfields Eye Hospital, London, UK
[2]Department of Ophthalmology, Frimley Park Hospital, London, UK
E-mail: dawnsim@doctors.org.uk

The authors have no any proprietary interests or research funding

Eye (2007) **21,** 1444–1445; doi:10.1038/sj.eye.6702974; published online 31 August 2007

Sir,

Sulcus-based 25-gauge vitrectomy with transscleral intraocular lens fixation

After creating fornix-based peritomies in the 1:30 and 7:30 O'clock meridian and a partial thickness 7 mm superior limbal incision, the trocars of the 25-gauge system are passed 1.5 mm posterior to the limbus, approximately 180° apart, into the sulcus (Figure 1a–f). These are passed parallel to the iris rather than perpendicular to the sclera, and should avoid penetration of the ciliary body. A third trocar may be placed through the sulcus or pars plana. Removal of a cataractous or dislocated lens may be attempted either via the limbal incision or with the vitrectomy instruments. As the 25-gauge vitrector is inadequate to remove nuclear material, enlarging the sulcus sclerostomy to accommodate a 20-gauge vitrector or phacofragmentation device might be required. Once the indicated lens removal and vitreous procedures have been performed, the limbal incision is opened to its full extent. Infusion through one of the ports should be continued in order to maintain globe inflation. Transscleral lens fixation sutures are created by first passing one end of 10-0 polypropylene suture material into the bore of a 27-gauge needle. The needle is then passed through the sclera and into the sulcus, approximately 3 mm from the 1:30 and 7:30 o'clock trocars. The suture is retrieved from inside the eye via the limbal wound with a hook or forceps, and then passed through the eyelet on the intraocular lens (IOL) haptic (Alcon CZ-70BD). If having difficulty threading the needle, one may leave the 10-0 polypropylene suture attached to a straight needle, which could be threaded backwards into the eye through the first port and the suture then retrieved as described. The suture end is then fed back into the anterior chamber and retrieved through the adjacent trocar using 25 g forceps. An alternative method for suture placement, particularly for the transscleral suture more distal to the wound, would be to make the initial pass with the suture through the limbal wound then externally through the sulcus. After removing the trocars, the lens is placed into the eye and rotated into position. The 10-0 suture is tied externally using four to five knots. Finally, the knot is rotated into the eye through the sclerostomy. When rotated properly, it is our experience that suture erosion is not a problem. Although we have not encountered postoperative hypotony through the scleral channels, in cases of concern, it may be reasonable to use fibrin glue placed beneath the conjunctiva to promote adhesion. If not already watertight, the sclerostomy may be closed with absorbable suture, taking care not to cut the transscleral 10-0 suture in the process. The limbal wound and peritomies are closed in a standard manner. It is important that the conjunctiva completely covers the transscleral polypropylene suture in order to minimize the risk of late endophthalmitis.

Case 1

A 68-year-old man was referred for combined vitrectomy and lensectomy after blunt trauma to his right eye from a projectile spring while repairing a lawn mower. Visual acuity was 20/80 and vitreous was present in the anterior chamber. The iris sphincter had a rupture at the 2:00 meridian, and the lens was cataractous with the nasal aspect subluxed posteriorly. A cystic traction tuft, an operculated hole, and a flap tear were found on funduscopic examination. We performed a 25-guage vitrectomy using the described technique, which