Eye (2007) 21, 1516–1523

www.nature.com/eye

LABORATORY STUDY

The new malononitrilamide immunosuppressant FK778 prolongs corneal allograft survival in the rat keratoplasty model

F Birnbaum, J Schwartzkopff, C Scholz, A Reis and T Reinhard

Abstract

Purpose **Aim of this study was to prove the efficacy and safety of the new malononitrilamide immunosuppressive FK778 in prolonging clear graft survival following allogeneic orthotopic keratoplasty in rats.**
Methods **Sixty-seven penetrating keratoplasties were performed using Fisher and Lewis rats as donors and recipients, respectively: group 1 ($n=11$), allogeneic control without therapy; group 2 ($n=12$), syngeneic control; group 3 ($n=11$), mycophenolate mofetil (MMF) 40 mg/kg bodyweight; group 4 ($n=12$), FK778 5 mg/kg bodyweight; group 5 ($n=12$), FK778 10 mg/kg bodyweight; and group 6 ($n=9$), FK778 20 mg/kg bodyweight. Four animals in each group were killed for immunohistological evaluation on day 14. Therapy was administered orally for 18 days. The grafts were evaluated every three days by means of a scoring system including opacity, oedema, and vascularization. Time to rejection was analysed with the Kaplan–Meier survival analysis and compared with the log-rank test. The densities of infiltrating immune cells were compared statistically using the non-parametric Mann–Whitney test.**
Results **Mean rejection-free graft survival was 11.4 days in group 1 (allogeneic control), 100 days (total follow-up time) in group 2 (syngeneic control), 24.0 days in group 3 (MMF 40 mg/kg), 15.7 days in group 4 (FK778 5 mg/kg), 19.1 days in group 5 (FK778 10 mg/kg), and 25.4 days in group 6 (FK778 20 mg/kg) ($P<0.005$).**
Conclusions **Systemic immunosuppression with FK778 prolongs graft survival in the rat keratoplasty model. FK778's efficacy is comparable with that of MMF in preventing immunologic graft rejection.**

Eye (2007) **21**, 1516–1523; doi:10.1038/sj.eye.6702727; published online 30 March 2007

Keywords: high-risk keratoplasty; immunosuppression; FK778; mycophenolate mofetil

Eye Hospital, Albert-Ludwigs University, Killianstr. 5, Freiburg, Germany

Correspondence: F Birnbaum, Eye Hospital, Albert-Ludwigs University, Killianstr. 5, D-79106 Freiburg, Germany
Tel: +49-761-270-4001; Fax: +49-761-270-4063.
E-mail: florian.birnbaum@uniklinik-freiburg.de

Received: 23 August 2006
Accepted in revised form: 28 December 2006
Published online: 30 March 2007

The authors thank *Astellas Pharma GmbH* for the supply of FK778

Introduction

The promising new immunosuppressive drug FK778, a malononitrilamide, is a derivative of the active metabolite of leflunomide A77 1726. Its main mechanism of action is the inhibition of the dehydroorotate dehydrogenase. The resulting reduced capacity of de novo pyrimidine synthesis leads to inhibition of T- and B-cell proliferation.

Efficacy of FK778 in preventing graft rejection in solid organ transplantation has been shown in several animal models.[1–6] The substance has been found to be effective and safe in a phase II study in renal transplantation in humans.[7]

As the mechanism of graft rejection in solid organ transplantation differs considerably from those in corneal transplantation, it is necessary to evaluate the efficacy of FK778 in preventing corneal graft rejection in an animal model.

The purpose of this study was to prove the efficacy of the new immunosuppressive drug FK778 in preventing immunologic graft rejection in allogeneic orthotopic keratoplasty in rats. Results were compared with the efficacy of mycophenolate mofetil (MMF). MMF is the bioavailability-enhanced morpholino ethyl ester of the active substance mycophenolic acid (MPA), which interferes with the *de novo*

synthesis of guanosine nucleotides by reversibly inhibiting the enzyme inosine monophosphate dehydrogenase.[8] MMF has proven its potency in preventing corneal allograft rejection in the rat keratoplasty model,[9,10] as well as in human corneal transplantation.[11,12]

Materials and methods

Animals

Sixty-seven orthotopic penetrating keratoplasties were performed using Fisher rats (Rtl-l^{vl}) as donors in the allogeneic groups and Lewis rats (Rtl-l^{le}) as donors in the syngeneic control group. Lewis rats were used as recipients in all groups. All animals were female, weighing 150–200 g. They were approximately 12 weeks old. Animals were obtained from Charles River Deutschland GmbH, (Sulzfeld, Germany). They were obtained and cared for in accordance with the Directives of the European Community as well as with the recommendations of the National Institutes of Health's Guide for the Care and Use of Laboratory Animals, NIH Publication Number 85–23 (revised 1985).

Surgery

Orthotopic penetrating keratoplasties were performed according to the technique of Herbort *et al*.[13]

Before surgery (in donors and recipients), mydriasis was achieved by local application of phenylephrine (Neosynephrin-POS 10%; Ursapharm, Saarbrücken, Germany) and tropicamid eyedrops (Mydriatikum Stulln, Pharma Stulln GmbH, Stulln, Germany). Eyedrops were administered three times at intervals of about 5–10 min before the operation. Corneal grafts were obtained using a 3.5 mm trephine after donors were killed by means of CO_2 inhalation. The grafts were stored at room temperature in a conservation medium for corneas (Medium 2, Biochrom AG, Berlin, Germany) until transplantation (maximum 2 h).

Recipients underwent short inhalation anaesthesia with isofluran (Forene, ABBOTT GmbH&Co., KG, Wiesbaden, Germany) and were then injected intraperitoneally with a mixture of ketaminhydrochloride 60 mg/kg bodyweight (Ketamin 10%, Essex Tierarznei, Munich, Germany), xylazinhydrochloride 4 mg/kg bodyweight (Rompun 2%, Bayer Vital GmbH, Leverkusen, Germany), and atropinsulphat 0.2 mg/kg bodyweight (Atropinsulfat B.Braun 0.5 mg/ml, B.Braun Melsungen AG, Melsungen, Germany). The recipients were fixed in a dextral lateral position. Central 3.0 mm trephination was performed at the left cornea and the 3.5 mm donor corneal button was transplanted. The graft was fixed with 8–10 interrupted sutures (11.0 Ethilon, Ethicon GmbH, Norderstedt, Germany). The sutures were left in place for the complete follow-up to enhance vascularization and graft rejection. The anterior chamber of the eye was restored at the end of the operation by injection of balanced salt solution. Gentamicin ointment (Refobacin, Merck, Darmstadt, Germany) was applied and a blepharorraphy, which remained in place for 3 days, was performed with one interrupted suture (6.0 Vicryl, Ethicon GmbH, Norderstedt, Germany) to protect the corneal graft.

Groups

The groups were divided as follows:

Group 1 ($n=11$): Fisher/Lewis (allogeneic control)
Group 2 ($n=12$): Lewis/Lewis (syngeneic control)
Group 3 ($n=11$): Fisher/Lewis (MMF, 40 mg/kg bodyweight /day)
Group 4 ($n=12$): Fisher/Lewis (FK778, 5 mg/kg bodyweight /day)
Group 5 ($n=12$): Fisher/Lewis (FK778, 10 mg/kg bodyweight /day)
Group 6 ($n=9$): Fisher/Lewis (FK778, 20 mg/kg bodyweight /day)

We applied the same dosages of FK778 as used in previous animal models, for example the rat cardiac transplantation model.[1,2]

The dosage of 40 mg/kg bodyweight/day MMF has shown a strong immunosuppressive effect in several previous studies and is therefore used as control for the high-dosage FK778 group in this study.[2,10,14,15]

Medication in the therapy groups 3–6 was given orally with a stomach tube, starting on the day of operation and continuing daily for 18 days. MMF was given as a suspension in water and FK778 was dissolved in 1% of carboxymethylcellulosis.

Clinical evaluation

Fourty-three rats (group 1 ($n=7$), group 2 ($n=8$), group 3 ($n=7$), group 4 ($n=8$), group 5 ($n=8$), group 6 ($n=5$) were subjected to clinical examination for a maximum of 100 days.

Examination was perfomed with the surgery-microscope following brief inhalation anaesthesia with isofluran (Forene, ABBOTT GmbH&Co, KG, Wiesbaden, Germany).

The grafts were evaluated every three days by means of a scoring system including opacity, oedema, and vascularisation. Graft rejection was defined as total opacity of the graft. Between days 9 and 12, grafts were

evaluated daily to determine the exact day of rejection. To enhance accuracy of graft evaluation, each animal was evaluated by two examiners (FB and CS).

We scored opacity as follows: 0 = no opacity; 1 = slight opacity (details of iris clearly visible); 2 = some details of iris no longer visible; 3 = pronounced opacity (pupil still recognizable); 4 = total opacity.

Not all of the grafts experienced total opacification in the groups with oral immunosuppression. Some of them reached only opacity level 3 and cleared up afterwards to opacity level 2 or even 1. In such cases, we defined the day of reaching opacity level 3 as the day of rejection.

After 100 days, or following clinically diagnosed, complete opacification of the corneal graft, the recipient animals were killed by CO_2 inhalation. The operated eye was enucleated and fixed in a buffered formalin solution (4%). For histological assessment, the formalin-fixed eyes were cut into 4-μm-thick preparations and subjected to hematoxylin–eosin staining.

The animals were closely monitored for signs of toxic side effects (e.g., weight loss) during the entire follow-up.

Immunohistology

Four rats from each group were killed for immunohistological evaluation on day 14. Using a cryostat, 7-μm-thick sections of each frozen eye were prepared. Specimens were allowed to dry 2 h on silanised slides, then fixed in 100% acetone at -20°C for 1 min. Once the acetone had evaporated, the slides were stored in plastic film at -20°C for further use. For staining, the slides were fixed in acetone at -20°C for 30 min under addition of 0.1 ml 30% H_2O_2 every 10 min. Then the slides were immersed in Tris buffer with calf serum. The primary antibodies were applied to the sections for 1 h at room temperature. Monoclonal mouse anti-rat antibodies to T-helper cells (cluster of differentiation (CD) 4, W3/25, 1:200), cytotoxic T cells (CD8, MRC OX-8, 1:200), interleukin (IL)2-receptor (CD25, MRC OX-39, 1:100), B cells (CD45RA, MRC OX-33, 1:100), natural killer cells (CD161, 10/78, 1:200), macrophages (CD163, ED2, 1 : 500) and dendritic cells (DC, MRC OX-62) were used. CD4, CD8, CD25, and CD161 were purchased from Biozol Diagnostica GmbH (Eching, Germany), CD45RA from Oxford Biotechnology Ltd 2000 (Oxford, UK), CD163 from RDI Research Diagnostics Inc. (Flanders, NJ, USA) and DC from Cedarlane Laboratories Limited (Ontario, Canada). After washing in Tris buffer, we applied the biotinylated rabbit anti-mouse second antibody (Anti-Mouse Immunoglobulins/Biotinylated, Polyclonal Rabbit, Dako Cytomation GmbH, Hamburg, Germany) for 45 min. The slides were washed in Tris buffer and incubated with horseradish peroxidase 1:500 (HRP, Dako A/S, Denmark). 3-Amino-9-ethyl-carbazole was then applied for 10 min to the tissue, followed by counterstaining with hematoxylin for 2 min. One digital photograph was taken for every slide in the central zone of each graft. Cells were counted on the photographs on an area of 1/100 mm^2 to quantify the degree of graft infiltration by each cell type. Immunohistological staining was controlled with staining of rat spleen specimens as positive control and corneal grafts without primary antibodies as negative control.

Statistical analysis

Time to rejection was analysed with the Kaplan–Meier survival analysis[16] and compared with the log-rank test. The densities of infiltrating immune cells were compared statistically using the non-parametric Mann–Whitney test.

All statistical evaluation was performed using SPSS Windows 12.0 (Microsoft Corp., Redmond, USA).

Results

Clinical evaluation

In the allogeneic control group (group 1) mean graft survival was 11.4 days. We found complete opacification combined with total vascularization and pronounced oedema. Graft rejection was confirmed as cause of graft failure by means of histological examination of the enucleated, formalin-fixed eyes (haematoxylin–eosin staining).

Grafts remained clear during the total follow-up time of 100 days in the syngeneic control group (group 2).

In all grafts of the allogeneic groups, vascularization reached the center of the corneal button. There was no statistically significant difference regarding vascularization between the allogeneic groups. Even in the syngeneic group, we observed a suture-induced vessel ingrowth in the graft, which stopped in the periphery of the grafts.

In group 3 (MMF 40 mg/kg), the mean time from transplantation to complete opacification of the graft was 24.0 days.

In the FK778-treated animals, we observed a dose-related, differential effect: mean survival was 15.7 days in group 4 (FK778 5 mg/kg), 19.1 days in group 5 (FK778 10 mg/kg) and 25.4 days in group 6 (FK778 20 mg/kg).

The pair-wise log-rank test showed a *P*value smaller than 0.05 for all groups except groups 3 against 6.

Figure 1 shows a Kaplan–Meier survival plot of rejection-free graft survival.

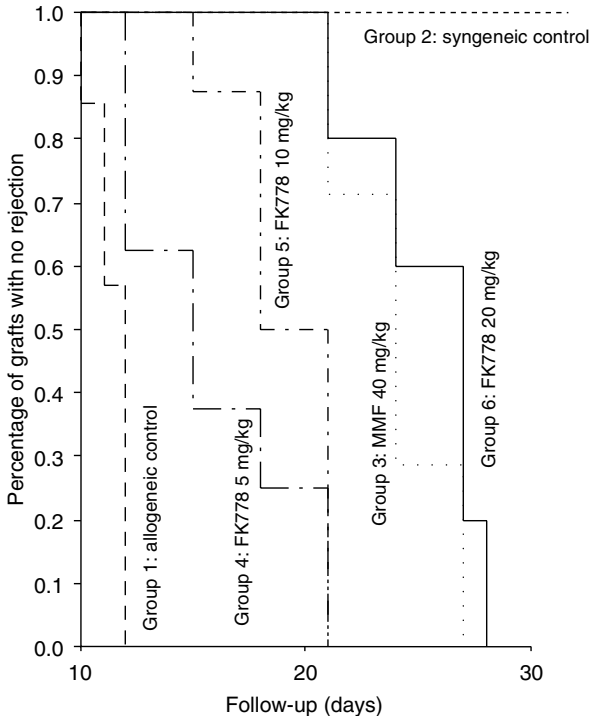

Figure 1 Kaplan–Meier survival plot of rejection-free graft survival; MMF: mycophenolate mofetil; pair-wise log-rank test: $P<0.05$ for all groups except group 3 against group 6.

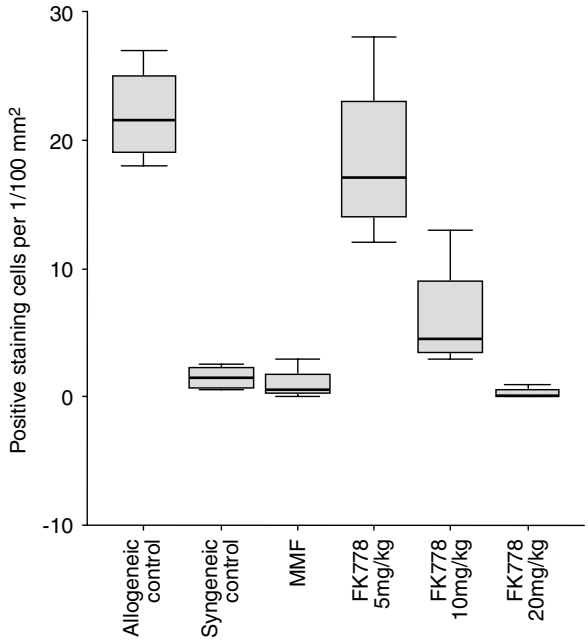

Figure 2 Immunohistology of corneal grafts. Density of infiltrating CD4+ cells; $P<0.0001$, ANOVA.

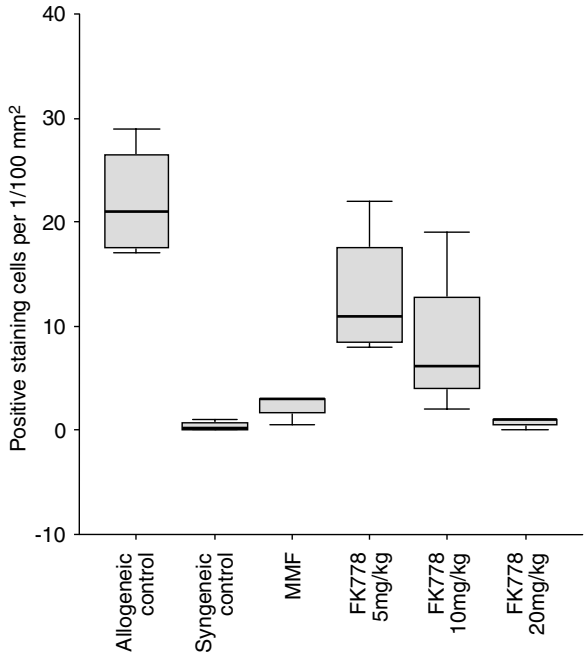

Figure 3 Immunohistology of corneal grafts. Density of infiltrating CD8+ cells; $P<0.0001$, ANOVA.

Immunohistology

We found dense cell infiltration in the allogeneic grafts in group 1 with CD4+ (T-helper cells; mean 22 cells per 1/100 mm^2), CD8+ (cytotoxic T cells; mean 22 cells per 1/100 mm^2), CD25+ (IL2-receptor; mean 12 cells per 1/100 mm^2), CD161+ (natural killer cells; mean 7 cells per 1/100 mm^2) and CD163+ (macrophages; mean 29 cells per 1/100 mm^2) cells (Figures 2–7).

The syngeneic grafts were nearly free of immunologic cell infiltration.

Grafts from Group 3 (MMF) showed a statistically significantly decreased infiltration of CD4+, CD8+, CD25+, CD161+, and CD163+ cells ($P<0.002$, anlysis of variance (ANOVA)).

We found a dose-related reduction in immunologic cell infiltration in all FK778-treated groups, which reached statistical significance in group 6 when compared with the allogeneic control group ($P<0.002$ ANOVA). Reduction in immune-cell infiltration in the grafts showed no statistically significant difference between treatment groups 3 and 6. Four from eight grafts in the follow-up group 4 were already rejected at day 14 (Figure 1), the remaining a few days later. The four grafts of the immunohistology group 4 were all rejected at day 14.

Only very few DCs (mean 0.5–2 cells per 1/100 mm^2) were found in group 1, 3, 4, and 5, and no DCs were found in groups 2 and 6. Owing to the low cell count, this difference is not statistically significant.

No CD45RA+ (B cells) were detected in any of the grafts.

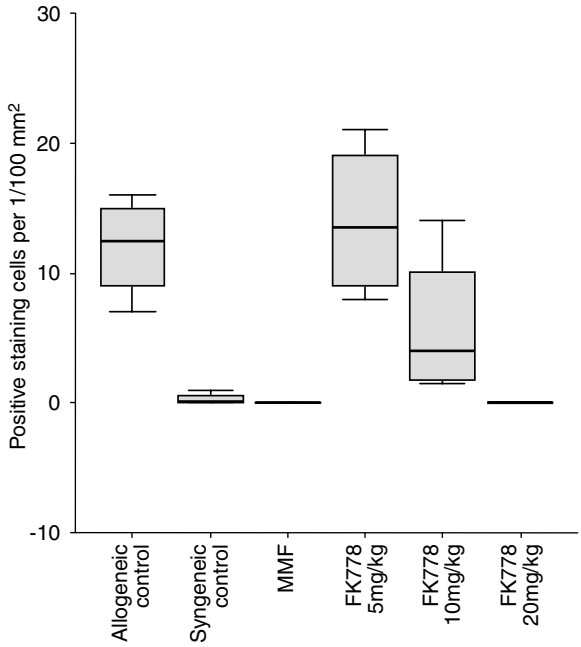

Figure 4 Immunohistology of corneal grafts. Density of infiltrating CD25+ cells; $P = 0.001$, ANOVA.

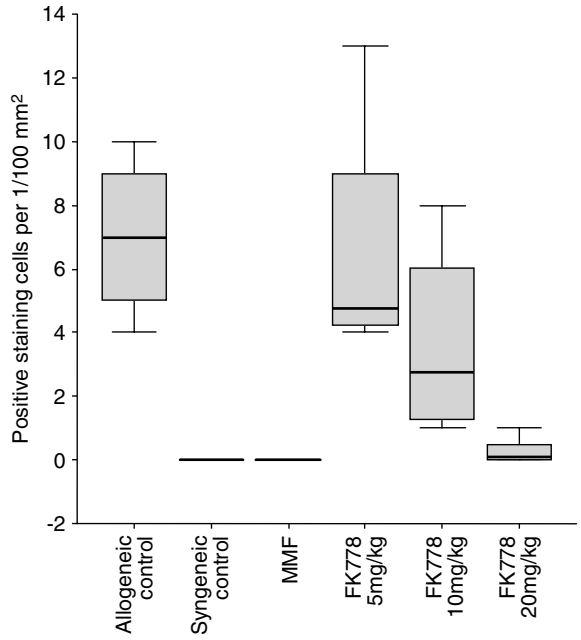

Figure 5 Immunohistology of corneal grafts. Density of infiltrating CD161+ cells (NK cells); $P = 0.002$, ANOVA.

Safety

One animal treated with MMF died on day 17 of emaciation. One animal that received FK778 20 mg/kg bodyweight died of emaciation on day 27. These rats were excluded from the study.

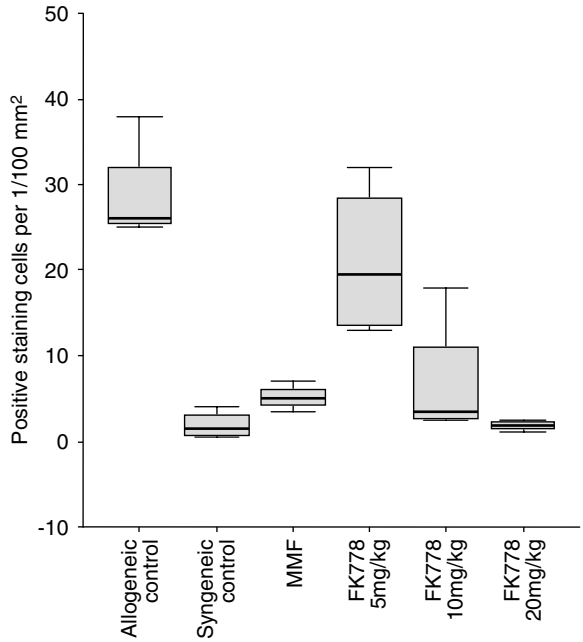

Figure 6 Immunohistology of corneal grafts. Density of infiltrating CD163+ cells (macrophages); $P < 0.0001$, ANOVA.

The group 3 animals (MMF 40 mg/kg) experienced a weight loss of 20 g (median, minimum 10 g, maximum 40 g) and those in group 6 (FK778 20 mg/kg) of 5 g (median, minimum 0 g, maximum 15 g) during the period of oral immunosuppression. Once therapy ceased, the rats gained weight constantly. We noted a constant increase in weight in all other groups. In groups 3 and 6, we observed soft stool during the first 18 days.

Discussion

Clear graft survival following normal-risk keratoplasty is superior to graft survival in solid organ transplantation owing to the immune privilege of the cornea and the anterior chamber, even without systemic immunosuppression or human leukocyte antigen matching.[17] In high-risk situations, such as vascularization of the recipient's cornea, history of previous keratoplasty, or positioning of the graft close to the limbus, the situation is different. Percentage of grafts that experience opacification owing to immune reaction is up to 75% in high-risk keratoplasties without systemic immunosuppression.[18–21]

Systemic immunosuppression following high-risk keratoplasty prolongs clear graft survival significantly.[11,19,21,22] In some units, cyclosporine A (CSA) and MMF are used routinely following penetrating high-risk keratoplasty.

As keratoplasty is not a life-saving procedure, the pros and cons of any systemic immunosuppression have to be

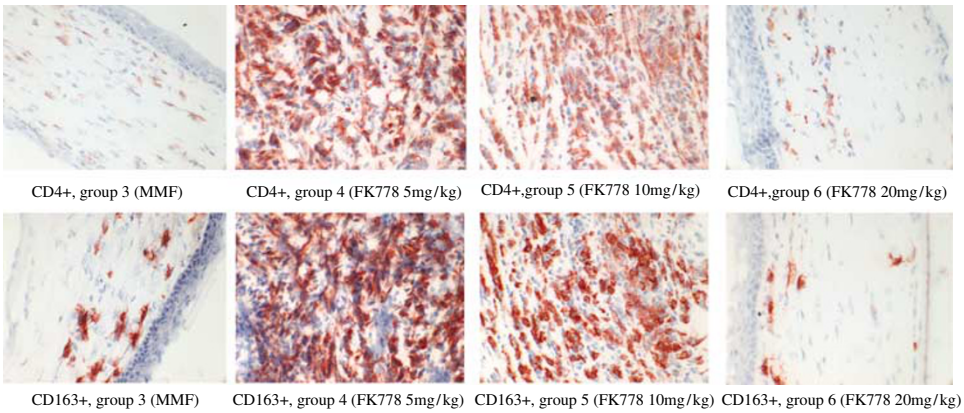

Figure 7 Immunohistology of corneal grafts; CD4+ (T helper cells) and CD163+ (macrophages) staining cells.

considered carefully. Side effects might lead to premature withdrawal of the immunosuppressive drug with a resulting higher risk for rejection.[12,23,24] Therefore, it is desirable to have a broader armamentarium of immunosuppressive agents offering a more favourable side effect profile and comparable efficacy in preventing graft rejection following penetrating high-risk keratoplasty.

The synthetic malononitrilamide FK778 is a derivative of leflunomide, which has high immunosuppressive potential. Leflunomide's potency in preventing graft rejection following rat keratoplasty was shown.[25] Today, leflunomide is used clinically only in treating rheumatoid arthritis. Owing its long half-time (1–4 weeks) it is not suitable to prevent graft rejection following organ transplantation.

On the other hand, FK778 could be an interesting agent in organ transplantation, as its efficacy is similar to that of leflunomide, but with significantly shorter half-time. It has been shown that FK778 inhibits acute rejection in experimental solid organ transplantation.[1–6]

Furthermore, FK778 shows some mechanisms, which are separate from the blockade of pyrimidine synthesis. FK778 inhibits the DC-derived activation of T-cells via blocking the activation of the transcription factor NF-KB .[26,27] FK778 influences further critical early steps in graft rejection of solid organs: FK778 leads to a reduction of the endothelial adhesion molecule upregulation and attenuates lymphocyte–endothelium interactions. Additionally, FK778 has antiproliferative potency on smooth muscle cells, which may be an important mechanism to inhibit the fibroproliferative lesions of chronic organ rejection.[28–30]

Furthermore, FK778 demonstrates inhibition of cytomegalovirus replication in animal and in vitro models.[7]

In this study, we have shown for the first time that FK778 is safe and effective in preventing immunologic corneal graft rejection in rats.

Efficacy

We found a dose-related, statistically significantly prolonged graft survival in all dosages (5, 10, 20 mg/kg body weight/day) compared with the allogeneic control group ($P<0.005$).

Graft survival in the 20 mg FK778 group and the 40 mg MMF group was comparable ($P=0.24$).

The immunosuppressive effect of FK778 was confirmed immunhistologically. A significant dose-dependent reduction in immune-cell infiltration was observed.

There was no significant difference in immune-cell infiltration in the grafts between the high-dosage FK778 group and the MMF group. There might be a special role of the FK778-mediated inhibition of DC activation in preventing graft rejection, as the only groups with no DC are the syngeneic control group and the high-dosage FK778 group. However, as the cell count was relatively low, no statistically significant difference was found.

Safety

We noted a weight loss in the 20 mg/kg FK778 and in the 40 mg/kg MMF groups. One animal in each group died of emaciation.

Conclusions

Systemic immunosuppression with FK778 is safe and effective in prolonging corneal allograft survival in the rat keratoplasty model. We observed a dose-related efficacy of FK778 both, *in vivo* and immunhistologically.

FK778's efficacy and safety (20 mg/kg) is comparable with that of MMF (40 mg/kg) in rat corneal transplantation.

It must be evaluated in clinical studies whether systemic FK778 has the potential to become an alternative immunomodulative drug for treatment following penetrating high-risk keratoplasty.

Acknowledgements

This work was presented as a free paper during the annual meeting of the Association for Research in Vision and Ophthalmology (ARVO) 04/30/06 – 05/04/06.

References

1 Deuse T, Schrepfer S, Reichenspurner H. The interaction between FK778 and tacrolimus in the prevention of rat cardiac allograft rejection is dose dependent. *Transplantation* 2004; **77**: 509–513.
2 Deuse T, Schrepfer S, Reichenspurner H. Immunosuppression with FK778 and mycophenolate mofetil in a rat cardiac transplantation model. *Transplantation* 2003; **76**: 1627–1629.
3 Bilolo KK, Ouyang J, Wang X, Zhu S, Jiang W, Qi S *et al.* Synergistic effects of malononitrilamides (FK778, FK779) with tacrolimus (FK506) in prevention of acute heart and kidney allograft rejection and reversal of ongoing heart allograft rejection in the rat. *Transplantation* 2003; **75**: 1881–1887.
4 Kyles AE, Gregory CR, Griffey SM, Bernsteen L, Pierce J, Lilja HS *et al.* Immunosuppression with a combination of the leflunomide analog, FK778, and microemulsified cyclosporine for renal transplantation in mongrel dogs. *Transplantation* 2003; **75**: 1128–1133.
5 Qi S, Zhu S, Xu D, Wang X, Ouyang J, Jiang W *et al.* Significant prolongation of renal allograft survival by delayed combination therapy of FK778 with tacrolimus in nonhuman primates. *Transplantation* 2003; **75**: 1124–1128.
6 Pan F, Ebbs A, Wynn C, Erickson L, Jang MS, Crews G *et al.* FK778, a powerful new immunosuppressant, effectively reduces functional and histologic changes of chronic rejection in rat renal allografts. *Transplantation* 2003; **75**: 1110–1114.
7 Vanrenterghem Y, van Hooff JP, Klinger M, Wlodarczyk Z, Squifflet JP, Mourad G *et al.* The effects of FK778 in combination with tacrolimus and steroids: a phase II multicenter study in renal transplant patients. *Transplantation* 2004; **78**: 9–14.
8 Allison AC. Mechanisms of action of mycophenolate mofetil in preventing chronic rejection. *Transplant Proc* 2002; **34**: 2863–2866.
9 Reis A, Reinhard T, Sundmacher R, Braunstein S, Godehardt E. Mycophenolate mofetil and FK506: two novel immunosuppressants in murine corneal transplantation. *Transplant Proc* 1998; **30**: 4344–4347.
10 Reis A, Reinhard T, Sundmacher R, Braunstein C, Godehardt E. Effect of mycophenolate mofetil, cyclosporin A, and both in combination in a murine corneal graft rejection model. *Br J Ophthalmol* 1998; **82**: 700–703.
11 Birnbaum F, Bohringer D, Sokolovska Y, Sundmacher R, Reinhard T. Immunosuppression with cyclosporine a and mycophenolate mofetil after penetrating high-risk keratoplasty: a retrospective study. *Transplantation* 2005; **79**: 964–968.
12 Reinhard T, Reis A, Bohringer D, Malinowski M, Voiculescu A, Heering P *et al.* Systemic mycophenolate mofetil in comparison with systemic cyclosporin A in high-risk keratoplasty patients: 3 years' results of a randomized prospective clinical trial. *Graefes Arch Clin Exp Ophthalmol* 2001; **239**: 367–372.
13 Herbort CP, Matsubara M, Nishi M, Mochizuki M. Penetrating keratoplasty in the rat: a model for the study of immunosuppressive treatment of graft rejection. *Jpn J Ophthalmol* 1989; **33**: 212–220.
14 Mayer K, Birnbaum F, Reinhard T, Reis A, Braunstein S, Claas F *et al.* FTY720 prolongs clear corneal allograft survival with a differential effect on different lymphocyte populations. *Br J Ophthalmol* 2004; **88**: 915–919.
15 Reis A, Megahed M, Reinhard T, Godehardt E, Spelsberg H, Braunstein C *et al.* Coadministration of the new macrolide immunosuppressant RAD and mycophenolate mofetil in experimental corneal transplantation. *Transplantation* 2000; **70**: 1397–1401.
16 Kaplan EL, Meier P. Nonparametric estimation from incomplete observations. *J Am Stat Assoc* 1958; **53**: 457–481.
17 Streilein JW, Yamada J, Dana MR, Ksander BR. Anterior chamber-associated immune deviation, ocular immune privilege, and orthotopic corneal allografts. *Transplant Proc* 1999; **31**: 1472–1475.
18 Hill JC. The use of cyclosporine in high-risk keratoplasty. *Am J Ophthalmol* 1989; **107**: 506–510.
19 Hill JC. Systemic cyclosporine in high-risk keratoplasty. Short- versus long-term therapy. *Ophthalmology* 1994; **101**: 128–133.
20 Reinhard T, Sundmacher R, Heering P. Systemic ciclosporin A in high-risk keratoplasties. *Graefes Arch Clin Exp Ophthalmol* 1996; **234**(Suppl 1): S115–S121.
21 Sundmacher R. Allograft rejection reactions after keratoplasty (author's transl)]. *Klin Monatsbl Augenheilkd* 1977; **171**: 705–722.
22 Reinhard T, Mayweg S, Sokolovska Y, Seitz B, Mittelviefhaus H, Engelmann K *et al.* Systemic mycophenolate mofetil avoids immune reactions in penetrating high-risk keratoplasty: preliminary results of an ongoing prospectively randomized multicentre study*. *Transpl Int* 2005; **18**: 703–708.
23 Reinhard T, Sundmacher R, Godehardt E, Heering P. Preventive systemic cyclosporin A after keratoplasty at increased risk for immune reactions as the only elevated risk factor]. *Ophthalmologe* 1997; **94**: 496–500.
24 Reis A, Reinhard T, Voiculescu A, Kutkuhn B, Godehardt E, Spelsberg H *et al.* Mycophenolate mofetil versus cyclosporin A in high risk keratoplasty patients: a prospectively randomised clinical trial. *Br J Ophthalmol* 1999; **83**: 1268–1271.
25 Coupland SE, Klebe S, Karow AC, Krause L, Kruse H, Bartlett RR *et al.* Leflunomide therapy following penetrating keratoplasty in the rat. *Graefes Arch Clin Exp Ophthalmol* 1994; **232**: 622–627.
26 Zeyda M, Kirsch BM, Geyeregger R, Stuhlmeier KM, Zlabinger GJ, Horl WH *et al.* Inhibition of human dendritic cell maturation and function by the novel

immunosuppressant FK778. *Transplantation* 2005; **80**: 1105–1111.
27 Zeyda M, Stuhlmeier KM, Kirsch B, Watschinger B, Horl WH, Stulnig TM *et al*. The malononitrilamide FK778 inhibits activation of NF-kappaB in human dendritic cells. *Transplant Proc* 2005; **37**: 1968–1969.
28 Deuse T, Schrepfer S, Schafer H, Koch-Nolte F, Schwedhelm E, Boger RH *et al*. FK778 attenuates lymphocyte-endothelium interaction after cardiac transplantation: *in vivo* and *in vitro* studies. *Transplantation* 2004; **78**: 71–77.
29 Schrepfer S, Deuse T, Schafer H, Reichenspurner H. FK778, a novel immunosuppressive agent, reduces early adhesion molecule up-regulation and prolongs cardiac allograft survival. *Transpl Int* 2005; **18**: 215–220.
30 Schrepfer S, Deuse T, Koch-Nolte F, Detter C, Reichenspurner H. FK778: new cellular and molecular mechanisms of action. *Transplant Proc* 2006; **38**: 757–761.