A keloid is an overgrowth of dense fibrous tissue that usually develops after healing of a skin injury. The accurate incidence of keloids is largely unknown, but does affect 4–16% of the black population and it is 15 times more common in Blacks population compared to Caucasians. The tissue extends beyond the borders of the original wound, usually does not regress spontaneously, and tends to recur after excision. Though the underlying pathogenic mechanisms are not fully understood, a recent study has shown that there is under expression of apoptosis-related genes in human keloid tissue and decreased apoptotic activity in fibroblasts derived from keloids.[5] However, this over-exuberant healing process may be similar in susceptible individuals during corneal healing after refractive surgery.

Corneal wound healing is a complex process involving epithelial, keratocyte, and endothelial interactions that are affected by their associations with wound bed matrix and by cytokine availability and activation.[6]

Keloid scar formation may be an indicator for subepithelial scarring after refractive laser surgery and patients should therefore be questioned about it in their preoperative assessment. This has caused concern in the past but there has been no previous evidence to support it. Stimuli that could promote an abnormal wound response in predisposed individuals better to be avoided and a longer period of postoperative steroid drops might be considered.[7]

This case is unusual because similar cornel subepithelial scarring developed in both eyes following different surgical procedures; PRK to the right eye and LASIK to the left eye. This suggests that there could be a systemic cause for this complication, in this case perhaps a propensity to keloid scar formation.

The link between corneal haze after refractive surgeries and the propensity for keloid formation in Caucasians needs be further investigated by a randomised controlled study.

References

1 Lui MM, Silas MA, Fugishima H. Complications of photorefractive keratectomy and laser *in situ* keratomileusis. *J Refract Surg* 2003; **19**: S247–S249.
2 Naoumidi I, Papadaki T, Zacharopoulos I, Siganos C, Pallikaris I. Epithelial ingrowth after laser *in situ* keratomileusis: a histopathologic study in human corneas. *Arch Ophthalmol* 2003; **121**: 950–955.
3 Wachtlin J, Langenbeck K, Schrunder S, Zhang EP, Hoffmann F. Immunohistology of corneal wound healing after photorefractive keratectomy and laser *in situ* keratomileusis. *J Refract Surg* 1999; **15**: 451–458.
4 Connon CJ, Marshall J, Patmore AL, Brahma A, Meek KM. Persistent haze and disorganisation of anterior stromal collagen appear unrelated following photo therapeutic keratectomy. *J Refract Surg* 2003; **19**: 323–332.
5 Sayah DN, Soo C, Shaw WW, Watson J, Messadi D, Longaker MT *et al*. Down regulation of apoptosis-related genes in keloid tissue. *J Surg Res* 1999; **87**: 209.
6 Gipson IK, Inatomi T. Extracellular matrix and growth factors in corneal wound healing. *Curr Opin Ophthalmol* 1995; **6**: 3–10.
7 Epstein R. Results of internet poll on outcome of LASIK in keloid formers. *J Refract Surg* 2000; **16**: 380–381.

R Girgis[1], DS Morris[2], A Kotagiri[1] and K Ramaesh[3]

[1]Worthing & Southland Hospitals NHS Trust, Worthing, UK

[2]Department of Ophthalmology, Royal Victoria Infirmary, Newcastle-upon-Tyne, UK

[3]Tennent Institute of Ophthalmology, Gartnavel General Hospital, Glasgow, UK

Correspondence: DS Morris,
Department of Ophthalmology,
Royal Victoria Infirmary,
Newcastle-upon-Tyne, UK
Tel: +44 7811 699435;
Fax: +44 1743 232406.
E-mail: danielsmorris@hotmail.com

No competing interests

Eye (2007) **21,** 96–97. doi:10.1038/sj.eye.6702180; published online 2 December 2005

Sir,

Entrapment of inferior rectus muscle as a complication of sinus balloon expansion for maxillary sinus fracture

Blunt facial or orbital trauma may cause fracture of the orbital or sinus walls. The most common type of orbital fracture is blow out fracture in which the inferior rectus muscle or orbital soft tissues attached to the muscle are entrapped within the orbital floor fracture.[1] In cases of blow out fracture, treatment usually consists of exploring the orbital floor and releasing the entrapped tissue. For additional fractures, different approaches exist that include sinus expansion for compressed sinus fractures.[2] This technique has been applied also to blow out fractures. Muscle entrapment is a potential complication of sinus expansion by balloon catheterization, although it

has never been described according to literature search with Medline® using the terms muscle entrapment, sinus fracture, sinus expansion, and balloon catheterization.

We present a patient who had an inferior rectus muscle entrapment as a result of sinus expansion by balloon catheterization for treating a compressed sinus fracture.

Case report

A 39-year-old male was injured in his face from a pipe spanner. On examination, the patient had swelling of the right cheek and right eyelids haematoma. Visual acuity was 20/20 in each eye. The intraocular pressure was normal in each eye. Ocular motility and convergence were full without complaints of diplopia. The ocular anterior and posterior segments were normal. A computed tomography (CT) examination of the orbits, without contrast media on a 16–MDCT scanner (Brilliance, Philips Medical System, Cleveland) showed right anterior, medial, and lateral compressed maxillary sinus wall fractures and a fracture of the right orbital floor without soft tissue entrapment (Figure 1a and b). Small bone fragments were detected within the sinus as well as blood (haemosinus). The patient was place on amoxycillin 500 mg and clavulinic acid 100 mg i.v. t.i.d. and underwent Caldwell–Luc surgery to correct the compressed maxillary sinus fracture. During surgery, the compressed fracture was exposed. Free small bony fragments and blood clots were removed. Foley balloon catheter was placed and inflated within the maxillary sinus expanding the sinus space. Prednisone 1 mg/kg i.v. was added.

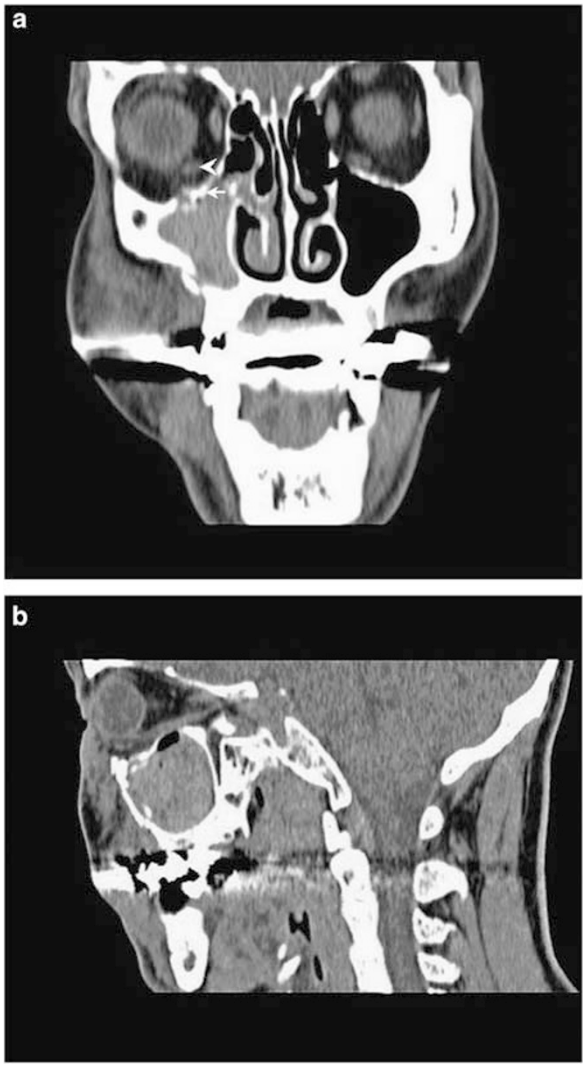

Figure 1 (a) A coronal CT scan of a 39-year-old patient injured from pipe spanner. Fracture of the orbital floor (short arrow) without entrapment of orbital soft tissue or inferior rectus (arrowhead) as well as haemosinus are noted. (b) A sagittal CT scan of the showing a normal course of the inferior rectus muscle within the orbit.

Following surgery, the patient complained of diplopia. The catheter was deflated and removed. The diplopia persisted and limitation of right supraduction to 30° was noted with positive forced-duction test. CT of the right orbit showed a disrupted course of the inferior rectus muscle in the orbit and stretching toward the orbital floor fracture due to entrapment of the inferior rectus sheath within bone fragments of the orbital floor (Figure 2a and b).

The patient underwent exploration of the orbital floor and the entrapped inferior rectus muscle was released. Following surgery, the patient resumed full ocular motility.

Comment

Balloon sinus expansion is one option for treatment of compressed sinus fracture. Complications of this procedure are rare and include necrosis of sinus mucosa and infection. In this patient, entrapment of the inferior rectus muscle within orbital floor fracture was a complication of this procedure. This complication has never been described although injuries to the inferior and medial rectus muscles have been described following endoscopic sinus surgery and Caldwell–Luc operation in a patient with hypoplastic maxillary sinus.[3–5]

We termed 'deflection sign' the disrupted course of the inferior rectus muscle in the orbit and stretching toward the orbital floor fracture on sagittal CT of the orbit. The possible mechanism for muscle entrapment is muscle displacement into the fracture when the sinus was expanded allowing its entrapment by some deflation. High intraorbital pressure due to active bleeding into the orbit may further increase the displacement of the muscle through the bony fracture.

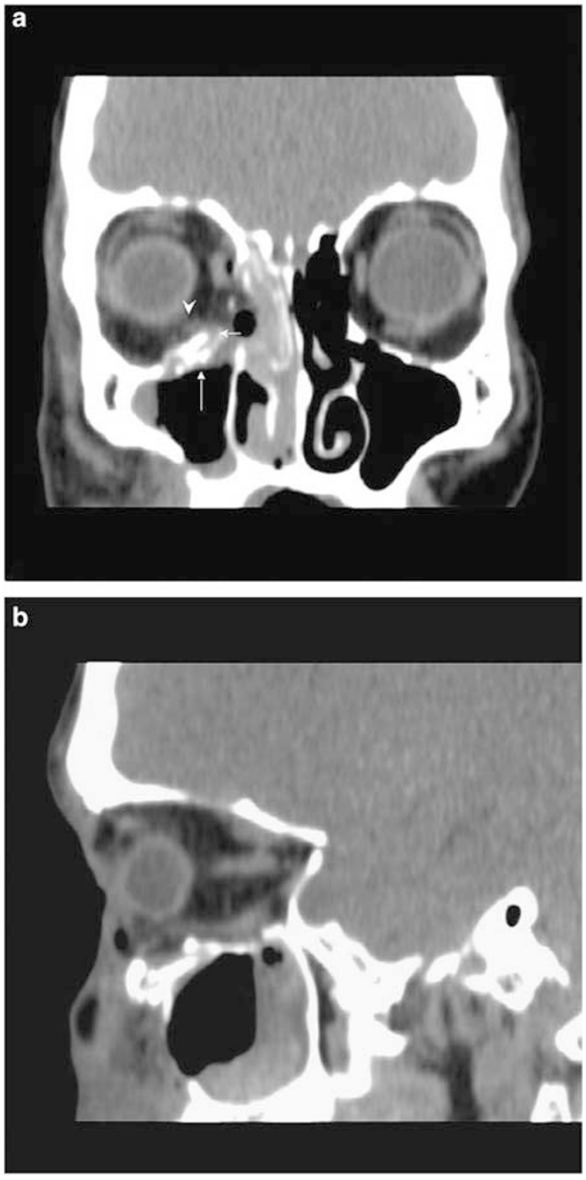

Figure 2 (a) A coronal CT scan of the same patient after Foley balloon catheterization demonstrating stretching of the inferior rectus muscle (arrowhead) toward the orbital floor fracture (short arrow) abutting bone fragments (long arrow). (b) A sagittal CT scan after Foley balloon catheterization showing a disrupted course of the inferior rectus muscle in the orbit and stretching toward the orbital floor fracture ('deflection sign'). Orbital floor exploration disclosed entrapment of the inferior rectus muscle sheath within the orbital floor fracture.

Balloon sinus expansion should be employed cautiously or avoided in the presence of orbital floor fracture. When employed, inflation should be slow and gradual and deflation should be avoided. Removal of the balloon may be delayed until complete healing. Otherwise, other open-system or endoscopic procedures may be preferred because they allow direct visualization of the surgical site.

References

1 Cruz AA, Eichenberger GC. Epidemiology and management of blow out fractures. *Curr Opin Ophthalmol* 2004; **15**: 416–421.
2 Miki T, Wada J, Haraoka J, Inaba I. Endoscopic transmaxillary reduction and balloon technique for blow out fractures of the orbital floor. *Minim Invasive Neurosurg* 2004; **47**: 359–364.
3 Carton A, Hislop S. Orbital floor injury with extraocular muscle entrapment following functional endoscopic sinus surgery. *Br J Oral Maxillofac Surg* 2000; **38**: 82–83.
4 Huang CM, Meyer DR, Partinaly JR *et al*. Medial rectus muscle injuries associated with functional endoscopic sinus surgery: characterization and management. *Ophthal Plast Reconstruct Surg* 2003; **19**: 25–37.
5 Pelletier CR, Jordan DR, Grahovac SZ. Inferior rectus muscle entrapment following Caldwell–Luc surgery associated with unrecognized hypoplastic maxillary antrum. *Can J Ophthalmol* 1997; **32**: 189–192.

EZ Rath[1], M Goldfeld[2], A Samet[3], U Rehany[1] and S Rumelt[1]

[1]Department of Ophthalmology, Western Galilee - Nahariya Medical Center, Nahariya, Israel

[2]Department of Radiology, Western Galilee - Nahariya Medical Center, Nahariya, Israel

[3]Department of Otorhinolaryngology, Western Galilee - Nahariya Medical Center, Nahariya, Israel

Correspondence: S Rumelt, Department of Ophthalmology, Western Galilee - Nahariya Medical Center, PO Box 21, 22100 Nahariya, Israel
Tel: +972 4 9107635;
Fax: +972 4 9107611.

Eye (2007) **21,** 97–99. doi:10.1038/sj.eye.6702398; published online 26 May 2006

Sir,

Angle-closure glaucoma in East Asian and European people. Different diseases?

Congratulations on the important article by He, Foster, Johnson and Khaw in the January 2006 issue of *Eye*. It is clear that the chronology of steps leading to angle-closure are not fully understand. One reason for this, I believe, is the continuing practice of describing the configuration of the anterior chamber angle almost exclusively in terms of the angle created by a tangent to the posterior surface of the cornea and the anterior surface of the iris. There still does not appear to be recognition that accurate description of the anterior