Eye (2006) 20, 840–866

www.nature.com/eye

CORRESPONDENCE

Sir,

Gaze-evoked amaurosis with cavernous sinus meningioma

Gaze evoked amaurosis is a rare symptom usually explained by vascular compromise of the retina or optic nerve in an eccentric gaze position caused by orbital and even intracranial disease (optic nerve sheath meningioma,[1,2] intraconal cavernous haemangioma,[1,2] orbital birdshot pellet,[3] dysthyroid orbitopathy,[4] pseudotumour cerebri,[5] orbital fracture,[6] nasopharyngeal angiofibroma,[6] idiopathic intracranial hypertension,[7] intracranial aneurysm).[8]

We report a patient with cavernous sinus meningioma who presented with symptoms of loss of vision of the right eye in right gaze.

Case report

A 37-year-old female patient was referred to our clinic by a neurologist for evaluation of right-sided visual loss occurring rapidly after initiating and sustaining right gaze. Vision recovered quickly on returning to primary gaze.

There was a 3 years' history of vertigo in right gaze, followed 1 year later by attacks of right-sided pain in the head, ear, and eye initiated on looking right, subsiding on returning to primary gaze. A neurological examination including MRI of head and neck revealed no explanation.

On a repeat neurological examination (3 years later) gaze-evoked amaurosis was reported and a nystagmus was noted in right gaze, which prompted an ophthalmologic referral.

The ophthalmologic examination revealed visual acuities of 6/6 OU. Visual acuity of the right eye dropped repeatedly to 6/18 within 5 s after assuming right gaze. Our patient reported decreasing vision moving from the temporal periphery to the centre of vision. After half a minute of sustained right gaze, a horizontal pendular nystagmus was noted in the fixating right eye. Vision recovered to 6/6 s after returning to the primary position. Eye movements were normal, there was no proptosis and no ptosis, pupillary light reactions were normal, the fundi showed no abnormalities (no papilloedema).

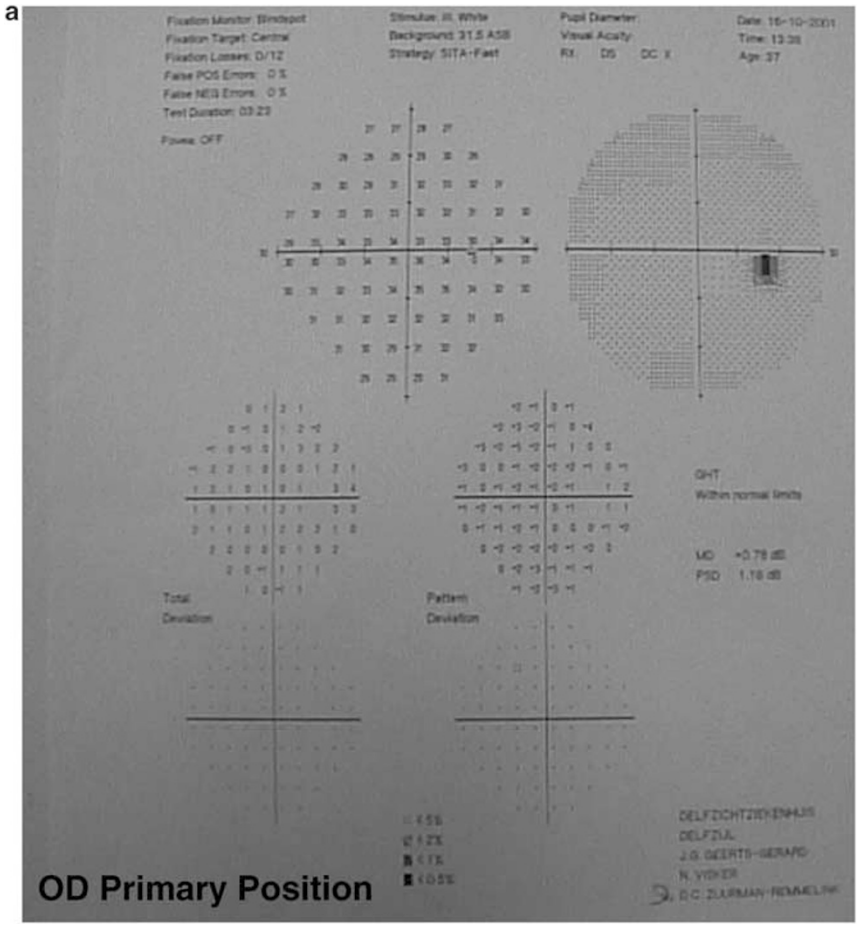

Figure 1 (a, b) Comparison of HFA 30-2 of right eye in primary position and in abduction. A central scotoma is present in abduction.

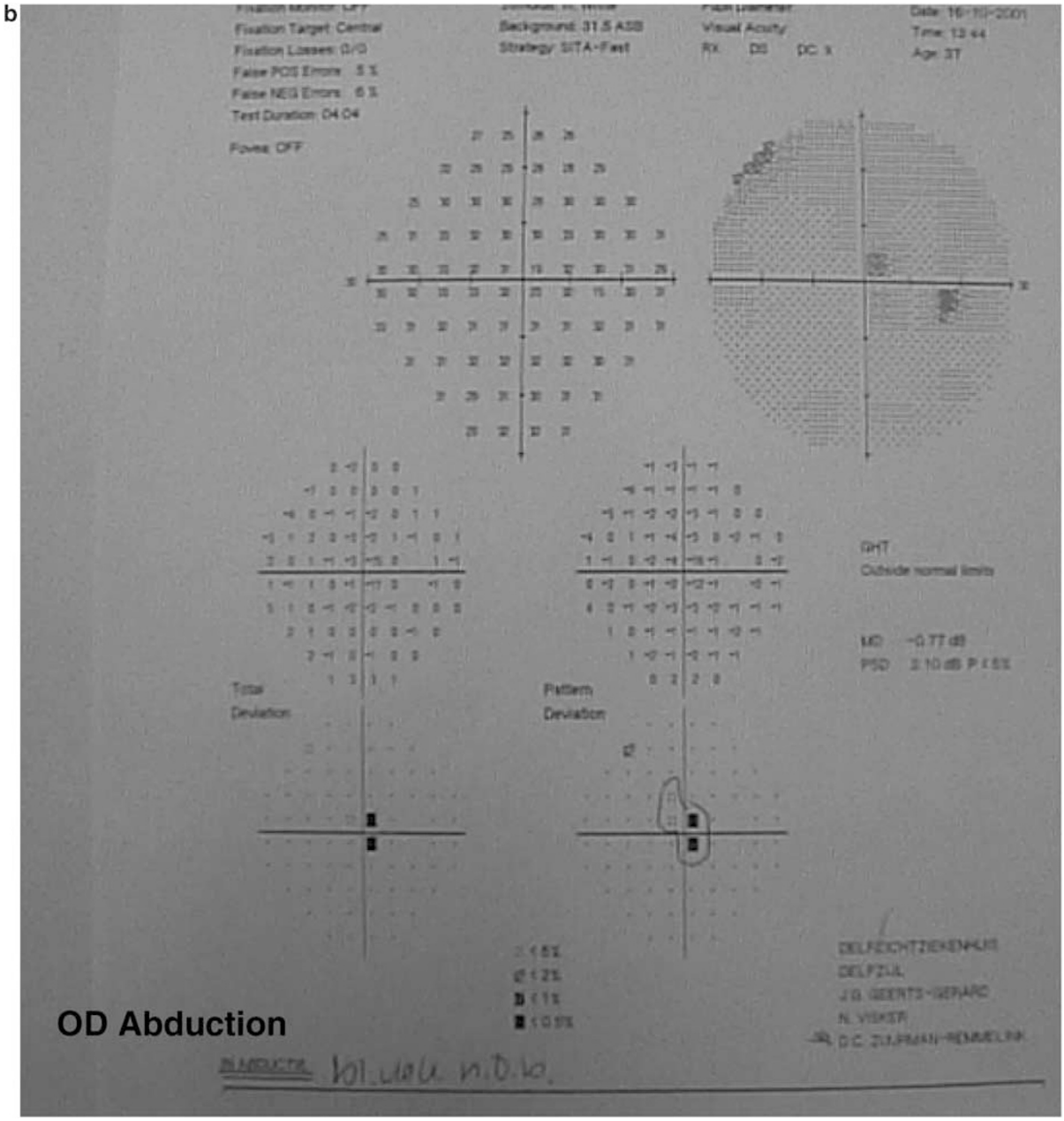

Figure 1 *Continued.*

A visual field test showed no abnormalities in PP and a central scotoma in right gaze (Figures 1a, b). A fluorescein angiogram (in right gaze) showed no abnormalities. VEP responses decreased markedly over both hemispheres in right gaze (beyond 30°) (Figure 2). A CDI showed a higher resistance index of the right ophthalmic artery in right gaze (Figure 3). An MRI showed a meningioma of the right cavernous sinus displacing the intracavernous internal carotid artery (Figures 4–6) and no abnormalities were seen in the right orbit and optic canal.

A conservative management was advised in view of the relatively benign symptoms and the possibility of surgery-related morbidity.

At 6 years after the onset of symptoms, our patient's condition has changed little apart from the recent onset of corneal hypesthesia.

Comment

To our knowledge, this is the first report of gaze-evoked amaurosis with an intracavernous sinus meningioma.

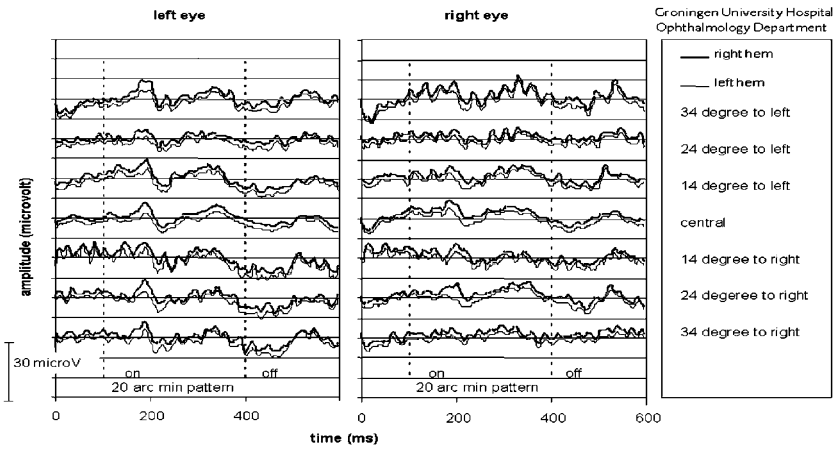

Figure 2 VEPs recorded in right and left hemisphere after each eye received stimuli from left to right gaze. The stimulus was 20 arc min pattern switched on at 100 ms and switched off at 400 ms. The VEPs were absent when right eye was abducted to 34° or more.

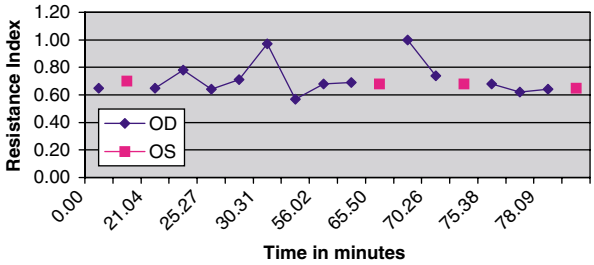

Figure 3 Colour Doppler of central retinal artery showed higher resistance index in right eye whenever in abduction, that is, 30.31 and 70.26 min. (Resistance index is peak systolic volume minus end diastolic volume divided by peak systolic volume).

Figure 4 MRI suggested meningioma in right cavernous sinus. See MRI images Figures 4–6. Figure 4: Transverse view. The right arterial carotid siphon is displaced ventrally by the tumour; however, the circulation is not compromised.

Figure 5 Postcontrast transverse views. The contrast stains the tumour homogenously. The tumour spreads out in Meckel's cavum or Trigeminal cavum.

The cause of visual loss is undoubtedly vascular of origin in view of its rapid onset and higher resistance index of the right ophthalmic artery as shown in the CDI with dextroversion of right eye.

Our patient refused to undergo an internal carotid artery angiography which might have yielded further interesting results to explain this phenomenon.

We assume that the perfusion of the right ophthalmic artery is compromised at its origin by compression, distortion and/or displacement of the internal carotid artery by the adjacent meningioma (Figure 4) without causing visual loss. On abduction of the right eye this haemodynamic compromise increases due to stretch or

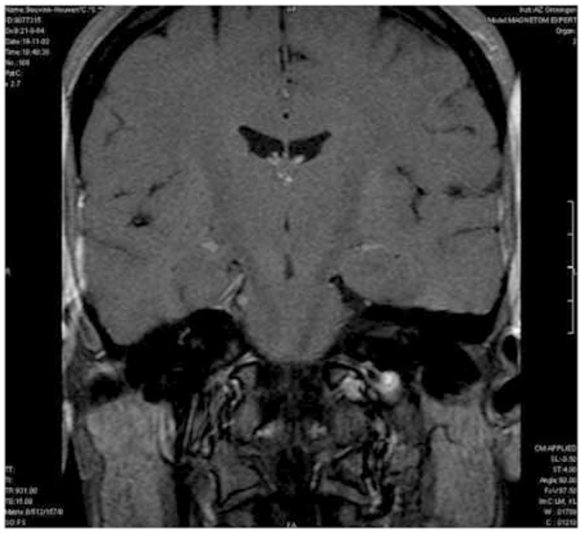

Figure 6 Coronal view. There is also meningeal spread dorsally along the uncus and along the clivus right to the median line in prepontine area.

adjacent tissue compression on an artery[8] leading to amaurosis. The location of this compromise could be anywhere—and possibly in multiple locations—from the origin of the ophthalmic artery up to the feeding vessels of the optic nerve in the meninges around the intracanalicular part of the optic nerve or even in the orbital apex.

In summary, we demonstrate a case that illustrates that gaze-evoked amaurosis may be caused, as previously reported,[8] by intracranial pathology that compromises blood perfusion.

Acknowledgements

We are grateful to the imaging departments of Delfzicht Ziekenhuis for providing CDI images, Electro physiological Ophthalmic Department, University Medical Center, Groningen for providing VEP images and Dr Mciners of Neuro radiology Department, University Medical Center, Groningen for the MRI images.

References

1 Orcutt JC, Tucker WM, Mills RP, Smith CH. Gazed evoked amaurosis. *Ophthalmology* 1987; **94**: 213–218.
2 Sarkies NJC. Optic nerve sheath meningioma: diagnostic features en therapeutic alternatives. *Eye* 1987; **1**: 597–602.
3 Danesh-Meyer HV, Savino PJ, Bilyk JR, Sergott RC, Kubis K. Gaze evoked amaurosis produced by intraorbital buckshot pellet. *Ophthalmology* 2001; **108**: 201–206.
4 Bremmer FD, Sanders MD, Stanford MR. Gaze evoked amaurosis in dysthyroid orbitopathy (letter). *Br J Ophthalmol* 1999; **83**: 501.
5 Pascual J, Combarros O, Berchiano J. Gazed evoked amaurosis in pseudotumor cerebri. *Neurology* 1988; **38**: 1654–1655.
6 Otto CS, Coppit GL, Mazzoli RA, Eusterman VD, Nixon KL, Ainbinder DJ *et al*. Gaze-evoked amuarosis: a report of 5 cases. *Ophthalmology* 2003; **110**: 322–326.
7 O'Duffy D, James B, Elston J. Idiopathic intracranial hypertension presenting with gaze-evoked amaurosis. *Acta Ophthalmol Scand* 1998; **76**: 119–120.
8 Sivak-Callcott J, Carpenter JS, Rosen CL, Ellis B, Hix C. Gazed evoked amaurosis associated with an intracranial aneurysm. *Arch Ophthalmol* 2004; **122**(9): 1404–1406.

MU Koch[1], AC Houtman[2] and RJW de Keizer[3]

[1]Ophthalmology, Delfzicht District Hospital, Delfzijl, Netherlands

[2]Ophthalmology, Martini District Hospital, Groningen, Netherlands

[3]Ophthalmology, University Medical Center, Leiden, Netherlands

Correspondence: MU Koch,
Tel: 0031503141435;
Fax: 0031599659261.
E-mail: eyekoch@home.nl

Eye (2006) **20,** 840–843. doi:10.1038/sj.eye.6701977; published online 17 June 2005

Sir,

Optical coherence tomography of macular crystalline opacities associated with chronic retinal detachment

Macular 'crystals' associated with chronic retinal detachment or dialysis are a rarely documented finding of unknown aetiology. We report two cases and describe for the first time the optical coherence tomography appearance of these crystalline opacities.

Case reports

Case 1

A 30-year-old lady, seen routinely by her optician, was referred for urgent ophthalmological assessment following the discovery of a chronic retinal detachment in the temporal retina of her left eye.