

# A model for the management of an atypical endophthalmitis outbreak

OA Anderson<sup>1</sup>, V Lee<sup>1</sup>, S Shafi<sup>2</sup>, D Keegan<sup>1</sup> and G Vafidis<sup>1</sup>

## Abstract

**Purpose of study** To present a model for the assessment, investigation, and management of an atypical outbreak of infectious endophthalmitis of indeterminate aetiology.

**Methods** A published statistical model was used to determine when the case-load constituted an outbreak. Intraocular surgery was discontinued and a multidisciplinary infection control team was formed aimed at identifying potential causative factors among the following categories: environment around theatre, preoperative preparation, intraoperative theatre practices, intraoperative surgical practices, postoperative practices, equipment maintenance guidelines, cleaning/sterilization practices, and microbiological screening.

**Results** Five cases of postoperative endophthalmitis developed following uncomplicated phacoemulsification cataract surgery by different surgeons over a 7-month period. Despite full investigation no single focus of infection could be determined. Four out of five cases were culture positive. Three grew *Streptococcus viridans* of different strains. The fourth culture grew *Staphylococcus aureus*. In the absence of a single causative factor, it was postulated the combined effect of multiple potential factors may have led to an increased bacterial load and subsequent infection rate. Improved practices were initiated including new cleaning protocols to combat the build-up of debris on phacoemulsification instruments. Cataract surgery was resumed with 3-monthly microbiological monitoring. There have been no further cases in the 12 months following the changes.

**Conclusion** Outbreaks of endophthalmitis typically present over a short time period and could often be attributed to a single infective cause. We present our experience of detecting and managing this cluster and recommend a 'ground-up' multidisciplinary model to manage future outbreaks of this devastating condition.

Eye (2005) 19, 972–980. doi:10.1038/sj.eye.6701695; published online 24 September 2004

**Keywords:** endophthalmitis; cataract; phacoemulsification

## Introduction

Postoperative endophthalmitis (POE) is one of the most devastating complications following cataract surgery. Despite optimal management, the visual outcome in many cases remains poor. The reported rate of POE in the Western world ranges from 0.1 to 0.3%.<sup>1–4</sup> Studies relating to the incidence of endophthalmitis following cataract extraction in the UK are limited to the results of the national cataract surgery survey<sup>5</sup> and the recent BOSU survey<sup>6</sup> with an estimated incidence figure was 0.14–0.16% or 1 case per 625–730 cataract extractions. Less well reported, in the ophthalmic literature, is the incidence of cluster cases (POE cases occurring in relative short succession in a single department). Many clusters reported in the literature tend to originate from a distinct infective source and occur over a relatively short time period of days to weeks.<sup>7,8</sup> With a readily identifiable source of infection, preventing further episodes simply involves eradicating that source. We present our experience of managing an atypical outbreak of endophthalmitis over a 7-month period with no identifiable source of infection. On the basis of lessons learnt, we propose a model for managing future outbreaks of this devastating condition.

<sup>1</sup>Central Eye Service  
Central Middlesex Hospital  
London, UK

<sup>2</sup>Department of  
Microbiology  
Northwick Park Hospital  
London, UK

Correspondence: V Lee  
Consultant Ophthalmic  
Surgeon  
Central Eye Service  
Central Middlesex Hospital  
Acton Lane  
Park Royal  
London NW10 7NS, UK  
Tel: +44 20 8963 7130  
Fax: +44 20 8963 7158  
E-mail: vickielee@mac.com

Received: 29 February 2004  
Accepted: 13 July 2004  
Published online:  
24 September 2004

**Methods**

Central Middlesex Hospital is a district general hospital in West London with six consultant ophthalmic surgeons serving a population of 250 000.

Approximately 1700 routine cataract operations are performed each year. All operations are performed in one of two dedicated eye theatres in a modern elective surgery suite.

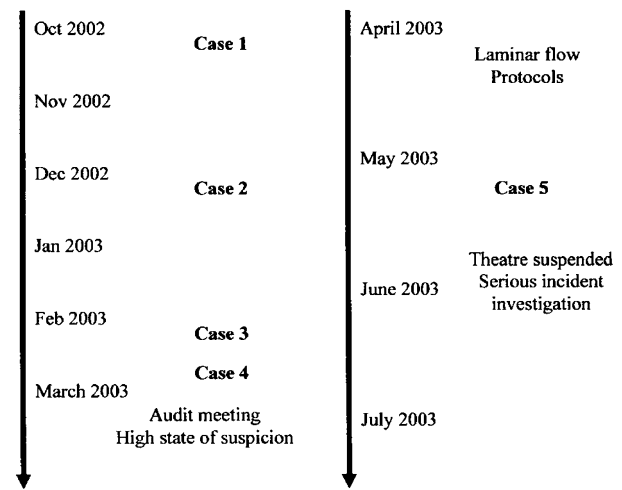
In accordance with Royal College Guidelines on Clinical Governance,<sup>9</sup> there is a critical incident reporting facility in our department for cases of POE. After the third and fourth cases were identified with these reporting mechanisms, a meeting was convened with the microbiologists. At that stage, based on the recommendations by Allardice *et al*,<sup>10</sup> the decision was to proceed with surgery with caution. Initial steps were taken to investigate potential origins of infection. All surgery was suspended after the fifth case and a full investigation was implemented.

**Investigation team**

An investigation team was immediately set up involving the following departments: microbiology (SS), ophthalmology (OA, VL, DK, GV), theatre nursing staff, clinical risk managers, and hospital managers. This team met on a twice-weekly basis and many aspects of concern came under scrutiny. Each aspect was assessed as to the potential risk and procedures were put into place to minimize that risk.

**Results**

Five cases (0.50%) of POE presented in the 7-month period between October 2002 and May 2003, during which 1000 cataract operations were performed (Figure 1). The expected endophthalmitis rate during this period would be one case (assuming a rate of 0.1%). All cases had uncomplicated temporal approach clear cornea phacoemulsification cataract surgery performed by three different consultant ophthalmic surgeons. Table 1 summarizes the details of each individual case. All patients underwent aqueous and vitreous sampling within 24 h of diagnosis and received intravitreal



**Figure 1** Time line of cases and events.

**Table 1** Patient details

|  | Case 1<br><i>Index case</i>    | Case 2         | Case 3   | Case 4                           | Case 5   |
|--|--------------------------------|----------------|--|----------------------------------|--|
| Operation date (days after index case)             | 0                              | 68             | 124  | 142                              | 208  |
| Presentation date (days after surgery)             | 25                             | 7              | 8  | 9                                | 11   |
| Age (years)  | 73                             | 57             | 85   | 79                               | 69   |
| Male/female  | Male                           | Male           | Female   | Male                             | Male   |
| Eye operated                                       | Left                           | Left           | Right  | Right                            | Left   |
| Coexistent disease                                 | Glaucoma                       | Past TB, myope | Nil  | CVA, branch vein occlusion       | Diabetes, anaemia  |
| Surgeon  | 1                              | 2              | 3  | 2                                | 1  |
| Perioperative subconjunctival antibiotic           | Cefuroxime                     | Cefuroxime     | Cefuroxime   | Cefuroxime                       | Gentamicin   |
| Organism cultured from aqueous and vitreous biopsy | <i>Staph. aureus</i> (aqueous) | Nil            | <i>Micrococcus</i> (aqueous),<br><i>Strep. viridans</i> (vitreous) | <i>Strep. viridans</i> (aqueous) | <i>Strep. viridans</i> (aqueous),<br><i>Strep. viridans</i> (vitreous) |
| Visual acuity at presentation with POE             | 6/60                           | HM             | CF   | CF                               | PL   |
| Final visual acuity                                | 6/9                            | 6/12           | 6/12   | CF                               | NPL  |

amikacin and vancomycin, systemic ciprofloxacin, and prednisolone. Four out of five patients were culture positive. Three grew *Streptococcus viridans* but with different strains. Patient 3 also grew *Micrococcus* in the aqueous sample. Patient 1 grew *Staphylococcus aureus* from the aqueous sample. Four patients responded to the initial treatment and required no further surgical intervention. Patient 5 unfortunately developed a total retinal detachment with a swollen ischaemic retina, which was inoperable at pars plana vitrectomy.

Intraocular surgery was discontinued pending the results of an investigation. Initial investigations were aimed at determining the cause of the outbreak. In the absence of a specific originating cause, we adopted a 'ground up' multidisciplinary approach aimed at assessing each area of pre-, peri-, and post-operative practice and determine any potential areas of risk before recommencing surgery. Surgery was resumed after 2 weeks with institution of recommendations from the investigation team. To date, 12 months after the last case, there have been no further cases of POE.

### Areas of investigation

#### 1. Environment around theatre

External environment assessment highlighted ongoing building works next to the theatre suite. Reports have suggested a link between building works and fungal infections, especially *Aspergillus*.<sup>11</sup> Internal environmental assessment highlighted the use of one of the eye theatres for podiatry procedures one evening per week.

#### 2. Preoperative preparation

Immediately prior to application of the surgical drape, the patient's lids and conjunctival sac were prepared with 10% povidone-iodine.

#### 3. Intraoperative theatre practices

(a) *Movement and access to theatres:* During surgery, there was free movement of staff to and from theatre. This included movement to and from the instrument preparation room and movement to and from the corridor outside via a single set of doors. This corridor was designed for use by both theatre staff and personnel from outside (wearing outside clothing). Concern was raised that opening a large set of doors during theatre may introduce unfiltered air into theatre.

(b) *Facemasks:* Facemasks were worn by all surgeons, assistants, and scrub nurses. Staff not directly involved with the surgical activity wore masks in most cases. Staff entering or leaving the surgical area did not always use a mask. It has been shown that facemasks reduce bacterial

contamination of the perioperative area,<sup>12</sup> although their effect on endophthalmitis rates are unknown.

(c) *Scrub nurse practices:* A long-standing practice of pouring sterile balanced salt solution (BSS) into a sterile pot on the instrument trolley was observed. This was the supply of BSS to be injected into the eye. This BSS fluid was exposed to the theatre air throughout the course of the operation. If theatre doors were opened during surgery, allowing unfiltered air in from outside, the BSS fluid could potentially become contaminated.

#### 4. Intraoperative surgical practices

All patients underwent a standard small incision temporal clear corneal phacoemulsification technique without intraoperative complications using the Alcon Legacy 20000 (Alcon Laboratories (UK) Limited) and insertion of a foldable Clariflex intraocular lens implant (IOL) (Advanced Medical Optics (AMO) Santa Ana, CA, USA). This three-piece foldable lens has a third generation silicone monofocal optic and polymethylmethacrylate (PMMA)-modified C haptics. Previous studies had found an increased risk of postoperative endophthalmitis with three-piece silicone IOLs with polypropylene haptics compared to single-piece PMMA IOLs.<sup>3,13</sup> None of the patients required corneal sutures.

Subconjunctival administration was the mode of perioperative antibiotic delivery in each case. Cefuroxime was used in four cases, with gentamicin in one (Table 1). Of the three cases which grew *Strep. viridans*, cefuroxime was used in two with gentamicin in the third. Cefuroxime was used in the case that grew *Staph. aureus* and the case with no bacterial growth.

#### 5. Documentation

There was no documentation as to which of the two ophthalmic theatres or phacoemulsification machines were used. BSS batch numbers were also not recorded. In the event of an outbreak accurate documentation allows assessment of factors in common with each case and helps identify areas of risk.

#### 6. Postoperative practices

(a) *Tonometry:* Patients had their eyes examined and tonometry performed following completion of the surgical list. The Goldmann tonometer head was cleaned with 70% v/v isopropyl alcohol BP between each patient and the dressing replaced following examination. Concern was raised as to the effectiveness of alcohol cleaning between patients, especially with regards to recent intraocular surgery.<sup>14</sup>

(b) *Postoperative patient risk factors:* No intraoperative complications occurred and none of the patients was noted to have a wound leak. One patient had a

postoperative IOP of 32 mmHg and was given oral acetazolamide. There was no suspicion that organisms entered the eye postoperatively either via an iatrogenically induced paracentesis leak to lower the pressure or via a persistent postoperative leak. All patients were discharged on maxitrol drops four times a day.

### 7. Cleaning/sterilization practices

Immediately following surgery, all hollow bore instruments (the phaco probes and the irrigation/aspiration (I/A) cannulae) were rinsed for 15 s with distilled water then for 15 s with air (at 30 psi) using the Quickrinse device (American Optisurgical Incorporated, CA, USA) to clean off the debris before sterilization. Concern was raised over the effectiveness of this method alone. Recent reports<sup>15,16</sup> found cannulated instruments to be contaminated with a variety of debris, even after syringe flushing. Bacteria were isolated on electron microscopy, but were believed to be nonviable following the sterilization process. The study introduced the Quickrinse device and while contamination rates improved, they were not fully eliminated. Concern was raised over whether residual cannula debris may decrease the potential effectiveness of the sterilization procedure, or may even induce postoperative inflammation if inadvertently introduced into the eye. In our unit, each surgeon had noticed occasions when I/A tips appeared to be blocked with debris.

Solid instruments were washed prior to sterilization to remove any debris. This was performed in the sterilization department using a prewash, main wash, and rinse cycle. One recent report has shown nonhollow bore instruments to still contain debris even after routine cleaning,<sup>15</sup> particularly dried viscoelastic.

A sterilization device called a 'Little Sister' was also present in theatre. This was used for sterilization of individual nonhollow bore instruments, on an occasional basis. Although it was steam sterilized to a temperature of 134–138°C, the air was not extracted by vacuum suction before steam introduction, which poses a potential risk of poor steam penetration.

### 8. Equipment maintenance guidelines

(a) *Phacoemulsification and irrigation/aspiration (I/A) handpieces*: Maintenance guidelines for all equipment were reviewed. The phacoemulsification tips were disposable as was the phacoemulsification tubing and cartridge. However, the nondisposable phacoemulsification equipment had been in service since purchase (1994—first batch purchased on opening department; 2000—second batch purchased on opening second theatre in new elective surgery suite). A recent publication by Leslie *et al*<sup>16</sup> recommended that the

automated I/A cannulae (Alcon Laboratories (UK) Limited) should be changed after 4 years because of build-up of debris. As a result, all intraocular surgery remained suspended until new surgical equipment arrived. All existing phacoemulsification and I/A sets were taken out of service to be investigated by the microbiology department.

(b) *Quickrinse maintenance guidelines*: There were no up-to-date guidelines found in the department regarding the maintenance of the Quickrinse.

### 9. Microbiological screening

Microbiological samples were taken from all the existing phacoemulsification sets. Four samples were taken from each set using 10 ml of sterile water to obtain the flushings. This included one sample each from the irrigation and aspiration channels of the phacoemulsification handpiece, and the same from the I/A handpiece. A total of 23 sets were sampled. There was no growth from any set. Subsequently, all 23 sets were attached to one of the two phacoemulsification machines. The machine was used to flush two further samples from the phacoemulsification handpieces (irrigation and aspiration) and the I/A handpieces (irrigation and aspiration). Two sets grew bacillus, when flushed via the phacoemulsification machine. Concern was raised as to whether external contamination of internal fluids could occur via the phacoemulsification cartridge, as bacillus was also grown from the cartridge placement site on the phacoemulsification machine. Our machines were serviced and tested and we were assured external contamination could not occur (Alcon Laboratories (UK) Limited, personal communication).

Microbiological samples were also taken from the Quickrinse bottle fluid and tubing and found to grow micrococcus and coliforms respectively.

### Changes implemented

The practices, mentioned above, had been in place since the foundation of the ophthalmology department on the site in 1994. In 1999, surgery was moved to a newly built day-surgery theatre suite. Practices remained essentially unchanged with regards to cataract surgery, despite the move. The investigation revealed no preceding alterations, which could be implicated as a potential cause. Therefore, it was agreed that the most appropriate course of action, the absence of a known origin of infection, was to eliminate any potential risk of contamination during surgery. One hoped by that bringing in broad changes the unknown potential cause of contamination would be eradicated. This included improving the environment around theatre by moving podiatry to another theatre. The laminar air flow was

tested and shown to be effective and clean (20 air changes/h). This and the nature of the organisms grown from the aqueous and vitreous biopsies showed that the building works did not constitute a serious risk in this outbreak. As an added precaution, the theatre doors opening onto the external corridor were to be kept locked and all staff movement minimized during surgery. Changes in intraoperative practices included obligatory wearing of masks by all theatre staff. Only two surgical trolleys were to be prepared at a time to minimize contamination. All reusable cannulae were taken out of service. Cannulae with injectable BSS were only to be replenished via the closed BSS bottle or via the phaco handpiece. Documentation of phacoemulsification machine used, instruments and disposables used were improved and a new ophthalmic sister was appointed was to ensure all measures are enforced. The microbiology department held additional infection control education sessions for the ophthalmology team.

Postoperative tonometry cleaning practices and guidelines were improved. A book documenting the changing of tonometer head cleaning fluid (presept) was commenced to ensure the fluids were replaced daily in line with the practice in the eye clinic. Guidance was drawn up as to who would require postoperative intraocular pressure (IOP) measurement, so as to limit unnecessary potential postoperative contamination. Most patients with a clear cornea, deep anterior chamber, and no predisposing risk factors now do not routinely have IOP measurements postoperatively, as a random IOP measured 2–3 h postoperatively is shown to be poorly correlated with the IOP fluctuations over 24 h following surgery.<sup>17</sup> We are concurrently considering using disposable tonometer heads for postoperative IOP measurements.<sup>18</sup>

Changes to cleaning and sterilization practices included disposal of the ‘Little Sister’ sterilizer with all instrument sterilization to occur in the theatre sterile supply unit (TSSU) only. In addition to the Quickrinse installed into theatres, a second one was installed in TSSU. A new protocol for cleaning hollow bore instruments was designed (Figure 2). This was more thorough than both the previous protocol and also the methods described by Leslie *et al*.<sup>16</sup> All hollow bore instruments were Quickrinse flushed immediately after surgery in theatres. Upon arrival in TSSU the instruments (excluding phacoemulsification handpieces) were cleaned in a newly purchased ultrasound bath. Quickrinse flushing was then repeated for a second time (including the phacoemulsification handpieces) in TSSU prior to sterilization. Changes to the maintenance guidelines resulted in the replacement of all I/A cannulae over 4 years old. A 3-monthly screening of

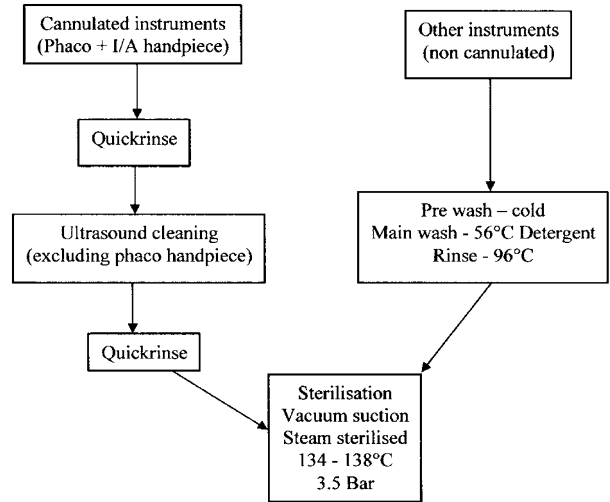


Figure 2 New process of cleaning and sterilizing instruments.

instruments for microbiological contamination was initiated.

We were reassured that Alcon (Alcon Laboratories (UK) Limited, personal communication) had conducted virus contamination studies to ensure the integrity of the Legacy machine, which had showed that there was no risk of crosscontamination of microorganisms from one patient to another. Both phacoemulsification machines were also inspected and found to be in good working condition. The manufacturers of Quickrinse were contacted for updated maintenance guidelines and a protocol drawn up for daily fluid changes and sterilization of the bottles and tubing.

Intraocular surgery was recommenced following implementation of the above changes. In accordance with the recommendations of Allardice *et al*,<sup>10</sup> the number of cases was reset to zero to determine over time whether the above changes had any influence on the future rate of POE. To date, 12 months after implementing the changes, there have been no further cases of POE.

## Discussion

Postoperative endophthalmitis is fortunately uncommon due to intrinsic ocular immunity combined with modern surgical and aseptic techniques. When POE outbreaks occur, the effect on an eye unit is devastating. The incidence, risk factors, prophylaxis, and management of POE have been widely reported in the ophthalmic literature.<sup>1–6,22,23</sup> However, the multidisciplinary process involved, from the point of determining what constitutes an outbreak, to investigating the cause of the outbreak and subsequent recommendations and changes in practice is less well documented. None of the members of our ophthalmic team had had any prior experience in

dealing with a POE outbreak and our aim is to share the lessons learnt.

### *When does a collection of cases constitute an outbreak?*

It is important to pose the question early as to whether a cluster of cases constitutes an outbreak (with a potential underlying cause) or simply consists of a random series of events occurring by chance. The implications are important. Misdiagnosing an outbreak as a chance event may lead to the occurrence of further unnecessary cases. Conversely, interpreting a series of chance events as an outbreak may lead to the closure of theatres, and an unnecessary time consuming and costly investigation. Our cluster of five cases over 7 months (0.50%) was in contrast to one case over the preceding 3 years (0.02%). The pattern of cases over the preceding 10 years was to have single episodes with long intervals between. We therefore felt this cluster unlikely to represent a simple rectification of our previously relatively low rates. We felt it wise to compare the recent rate not only with the previous local rate (and national/international rates) but with the previous local patterns of incidence. If small clusters are characteristic of the local incidence pattern, then the presence of a new cluster may be less alarming. The above points are qualitative in nature. When encountering a cluster more quantitative guidance is needed. How many cases of POE should be allowed to occur before suspecting something may be seriously wrong? After how many cases should one consider investigating? When should one close theatres? To answer this question we searched for previous experience. An article by Allardice *et al*<sup>10</sup> attempted to answer these very same questions. They used Poisson distribution to determine whether the number of cases are higher than can be expected by chance. On this basis they proposed a 'traffic light model'—whether to continue surgery (green), when to continue surgery but also commence an investigation (amber), and when to stop surgery and investigate (red). A *P*-value is given depending on how many cases of POE have occurred per number of operations since the first cluster case. It assumes a rate of 0.1% to be normal. It is therefore important to consider the local rate when assessing this paper. After the occurrence of our third and fourth cases in rapid succession (amber), we notified the microbiology department who commenced laminar flow microbiological investigation and assessment of theatre practices. After our fifth case (red) all intraocular surgery was stopped. It is still possible that the cluster was merely a chance event, but in the light of increasing numbers of cases there comes a point when this becomes unlikely. The above article uses a statistical method to highlight as to where that point might be.

In order to identify future clusters rapidly, it is essential that all eye units have a robust clinical governance strategy including the reporting of critical incidents, otherwise there may be difficulty in identifying atypical clusters of POE as described in our series.

### *Proposing a model of investigation*

#### *1. Assembling an investigative team*

It was important to act quickly and decisively and assemble a multidisciplinary team of all staff involved from both clinical and managerial disciplines: ophthalmologists, microbiologists, theatre nursing staff, clinical risk, and hospital management. The team should meet frequently (in this case we convened twice weekly over a fortnight) to assess the incoming evidence and decide on a response.

#### *2. Determining the cause of the outbreak*

Determining the cause of an outbreak involves identification of factors in common between each case. Most cases of POE are due to bacteria entering the eye at the time of surgery by means of surgical instruments, the irrigation fluid, or by contamination of the intraocular lens implant (IOL).<sup>19–22</sup> The incidence of positive cultures has been reported as 56% in the BOSU survey.<sup>6</sup> In many cases, the organisms involved are thought to originate from the periocular flora.<sup>20,23,24</sup>

While *Strept. viridans* is a common upper respiratory tract commensal organism, it is not commonly found in eyelid flora. A recent study isolated  $\alpha$ -haemolytic streptococci (*Strept. viridans*) in only 10% of preoperative conjunctival swabs, whereas coagulase-negative Staphylococcus and *Staph. aureus* were isolated in 56% and 13% of swabs respectively.<sup>25</sup> *Strept. viridans*, isolated in three out of four culture-positive cases, could have been present in the throats of any of the theatre staff. Further analysis showed this to be of at least two different strains. We found there was no surgeon, anaesthetist, or member of nursing staff in common with all cases and decided not to swab the throats of all theatre staff as the possibility that all cases originated from a single infecting focus appeared unlikely.

Suspicion surrounded the opening of surgery doors during cases, with potential disruption of air flow. We were concerned about a potential risk of contaminating open pots of intraocular BSS with upper respiratory tract organisms from the occasional staff not wearing face masks, or from corridor air entering during surgery. However, practice with regards to doors, face masks, and open BSS pots, had not changed for years. Therefore, it seemed unlikely to be the single causal factor behind this cluster.

Another area of suspicion surrounded the hollow bore instruments. Our department bought all its phacoemulsification instruments during 1994 and 2000. I/A hand pieces have been shown to contain debris even after routine cleaning and sterilization.<sup>16</sup> The investigation team was concerned that as the hand pieces age, corrosion and debris may interfere with effective sterilization of the instruments. The potential of biofilms preventing adequate steam penetration was considered but not proven. All I/A handpieces over 4 years old were replaced.

Clear corneal temporal incisions were performed on all the POE cases involved. Five out of six of the consultant surgeons routinely perform temporal incisions, but sit superiorly for a significant with the rule corneal astigmatism. The sixth surgeon routinely performs clear corneal superior incisions. A prospective study by Nagaki *et al*<sup>26</sup> compared POE rates following superior corneoscleral incisions *vs* temporal corneal incisions. Temporal incisions were shown to pose a higher risk, but it must be noted that the superior incision used in the study was corneoscleral and not clear corneal. Corneal incisions have been reported to pose a higher risk when compared to corneoscleral incisions.<sup>1,27</sup> Cooper *et al*<sup>27</sup> suggested reduced postoperative wound integrity to be a possible factor. All of our cases were assessed postoperatively on the day of surgery. No wound abnormality or leak was noted. The predominate use of temporal incisions predates the cluster by a number of years and was not felt to be a causal factor in our POE cluster.

The use of lens injectors has been reported to reduce the risk of POE.<sup>28</sup> It is postulated that this may be due to the injector preventing the lens from making contact with the ocular surface during insertion. Injectors, although available, are not routinely used in our department and were not used in any of the POE cases.

Postoperative subconjunctival cefuroxime, with gentamicin for those penicillin allergic, has been part of departmental cataract surgery protocol since the ophthalmology department was formed in 1994. This protocol is used by all but one surgeon who routinely uses postoperative intracameral vancomycin. All the POE cases had received either subconjunctival cefuroxime or gentamicin. Gram-positive infections still took place despite the presence of cefuroxime, even though it has Gram-positive activity.

A recent review of prophylactic measures, by Ciulla *et al*,<sup>29</sup> showed the evidence supporting the benefit of postoperative subconjunctival antibiotics to be inconclusive. Cefuroxime has been reported to be effective when administered via the subconjunctival<sup>30</sup> or intracameral route.<sup>31</sup> Via the intracameral route, the results were more striking in that all but one case

involved organisms resistant to cefuroxime. Gentamicin has been reported to be less effective.<sup>32</sup>

Ciulla *et al*<sup>29</sup> found stronger evidence supporting povidone-iodine as an effective form of endophthalmitis prophylaxis. It has been reported to be effective in reducing conjunctival flora<sup>33</sup> and in one prospective study was shown to be effective in reducing the rate of POE.<sup>23</sup> However, this study was controlled only with regards to preoperative disinfectant, the other parts of surgery being uncontrolled. Due to the rare nature of POE, high-quality prospective studies have proved difficult. As a result, a good deal of debate exists concerning prophylaxis against endophthalmitis.

The incidence of culture-positive bacterial contamination in the anterior chamber at the end of cataract surgery ranged widely from 0<sup>34</sup> to 46%<sup>35</sup> of cases found in previous studies. Given this wide variation, it is not clear why POE occurs in only a small number of patients in most eye units. This is often attributed to intrinsic ocular immunity being overwhelmed when a critical bacterial load is reached, or when there is impairment of the ocular defenses, such as in cases of vitreous loss establishing a communication between the aqueous and vitreous chambers. Bacteria may also enter the eye in the postoperative period because of cataract wound abnormalities, vitreous wicks, sutures, and inadvertent filtering blebs. However, all our operations were uncomplicated and of relatively short duration, being performed by experienced consultant surgeons. Apart from one patient being diabetic, none of the patients had any predisposing risk factors.<sup>36</sup>

The difficulty we faced was that despite a thorough and detailed investigation, no definite causative factor could be implicated. Instrument contamination was suspected, but although microbiological screening did grow organisms from two sets, the organism grown had never been implicated in the cluster. An upper respiratory tract origin was suspected. However, mask-wearing or door-opening habits had not changed. There were no preceding alterations of practice that could be implicated as a potential cause. In the presence of a cause, the solution is evident. In the absence of an identifiable cause, a solution still needed to be found. Assuming our cluster was not just due to chance, the only option available was a broad tightening of all potential risk factors.

### 3. Drafting of new protocols and recommendations

We recommend five main areas of investigation:

- (1) theatre environment;
  - (2) pre-, peri- and post-operative practices;
  - (3) instrument cleaning and sterilization;
  - (4) equipment maintenance, and
  - (5) documentation.
- New protocols should be aimed at overcoming risks detected in each of the above areas. The importance of

documentation cannot be overemphasized and is extremely useful in determining if any the endophthalmitis cases contain factors in common. For example, if all the cases occurred in one of two theatres, then that would point to a focus of contamination in that theatre. Unfortunately, it may only be following an outbreak that the absence of valuable documentation comes to light.

#### 4. Reauditing and ongoing microbiological surveillance

Maintaining ongoing microbiological surveillance after the introduction of new protocols is essential to monitor their effectiveness. Our microbiology department has been conducting ongoing sampling of instruments to ensure a safe environment. We now routinely educate patients, clinical and nursing staff to be highly alert to symptoms of endophthalmitis. It is necessary to exercise constant vigilance in detection, compliance to the protocols, and scrupulous monitoring in the hope that further outbreaks could be averted.

#### References

- Schmitz S, Dick HB, Krummenauer F, Pfeiffer N. Endophthalmitis in cataract surgery: results of a German survey. *Ophthalmology* 1999; **106**: 1869–1877.
- Aaberg Jr TM, Flynn Jr HW, Schiffman J, Newton J. Nosocomial acute-onset postoperative endophthalmitis survey. A 10-year review of incidence and outcomes. *Ophthalmology* 1998; **105**: 1004–1010.
- Menikoff JA, Speaker MG, Marmor M, Raskin EM. A case-control study of risk factors for postoperative endophthalmitis. *Ophthalmology* 1991; **98**: 1761–1768.
- Fisch A, Salvanet A, Prazuck T, Forestier F, Gerbaud L, Coscas G *et al*. Epidemiology of infective endophthalmitis in France. The French Collaborative Study Group on Endophthalmitis. *Lancet* 1991; **338**: 1373–1376.
- Desai P, Minassian DC, Reidy A. National cataract surgery survey 1997–8: a report of the results of the clinical outcomes. *Br J Ophthalmol* 1999; **83**: 1336–1340.
- Kamalarajah S, Silvestri G, Sharma N, Khan A, Foot B, Ling R *et al*. Surveillance of endophthalmitis following cataract surgery in the UK. *Eye* 2004; **18**: 580–587.
- Janknecht P, Schneider CM, Ness T. Outbreak of *Empedobacter brevis* endophthalmitis after cataract extraction. *Graefes Arch Clin Exp Ophthalmol* 2002; **240**: 291–295.
- Fridkin SK, Kremer FB, Bland LA, Padhye A, McNeil MM, Jarvis WR. *Acremonium kiliense* endophthalmitis that occurred after cataract extraction in an ambulatory surgical center and was traced to an environmental reservoir. *Clin Infect Dis* 1996; **22**: 222–227.
- The Royal College of Ophthalmologists. Ophthalmic Services 2003. The Royal College of Ophthalmologists: London, UK.
- Allardice GM, Wright EM, Peterson M, Miller JM. A statistical approach to an outbreak of endophthalmitis following cataract surgery at a hospital in the West of Scotland. *J Hosp Infect* 2001; **49**: 23–29.
- Tabbara KF, al Jabarti AL. Hospital construction-associated outbreak of ocular aspergillosis after cataract surgery. *Ophthalmology* 1998; **105**: 522–526.
- Alwitary A, Jackson E, Chen H, Holden R. The use of surgical facemasks during cataract surgery: is it necessary? *Br J Ophthalmol* 2002; **86**: 975–977.
- Bainbridge JWB, Teimory M, Tabandeh H, Kirwan J, Dalton R, Reid F *et al*. Intraocular lens implants and risk of endophthalmitis. *Br J Ophthalmol* 1998; **82**: 1312–1315.
- Smith CA, Pepose JS. Disinfection of tonometers and contact lenses in the office setting: are current techniques adequate? *Am J Ophthalmol* 1999; **127**: 77–84.
- Dinakaran S, Kayarkar VV. Debris on processed ophthalmic instruments: a cause for concern. *Eye* 2002; **16**: 281–284.
- Leslie T, Aitken DA, Barrie T, Kirkness CM. Residual debris as a potential cause of post phaco-emulsification endophthalmitis. *Eye* 2003; **17**: 506–512.
- Browning AC, Alwitary A, Hamilton R, Rotchford A, Bhan A, Amoaku WM. Role of IOP measurement on day of phakoemulsification cataract surgery. *J Cataract Refract Surg* 2002; **28**: 1601–1606.
- Goel S, Chua C, Dong B, Butcher M, Ahfat F, Hindi SK *et al*. Comparison between standard Goldmann applanation prism and disposable applanation prism in tonometry. *Eye* 2004; **18**: 175–178.
- Beigi B, Westlake W, Mangelschots E, Chang B, Rich W, Riordan T. Peroperative microbial contamination of anterior chamber aspirates during extracapsular cataract extraction and phacoemulsification. *Br J Ophthalmol* 1997; **81**: 953–955.
- Samad A, Solomon LD, Miller MA, Mendelson J. Anterior chamber contamination after uncomplicated phacoemulsification and intraocular lens implantation. *Am J Ophthalmol* 1995; **120**: 143–150.
- Doyle A, Beigi B, Early A, Blake A, Eustace P, Hone R. Adherence of bacteria to intraocular lenses: a prospective study. *Br J Ophthalmol* 1995; **79**: 347–349.
- Assia EL, Jubran RZ, Solberg Y, Keller N. The role of intraocular lenses in anterior chamber contamination during cataract surgery. *Graefes Arch Clin Exp Ophthalmol* 1998; **236**: 721–724.
- Speaker MG, Menikoff JA. Prophylaxis of endophthalmitis with topical povidone-iodine. *Ophthalmology* 1991; **98**: 1769–1775.
- Bannerman TL, Rhoden DL, McAllister SK, Miller JM, Wilson LA. The source of coagulase-negative staphylococci in the Endophthalmitis Vitrectomy Study. A comparison of eyelid and intraocular isolates using pulsed-field gel electrophoresis. *Arch Ophthalmol* 1997; **115**: 357–361.
- Johnson MW, Doft BH, Kelsey SF, Barza M, Wilson LA, Barr CC *et al*. The Endophthalmitis Vitrectomy Study: relationship between clinical presentation and microbiologic spectrum. *Ophthalmology* 1997; **104**: 261–272.
- Nagaki Y, Hayasaka S, Kadoi C, Matsumoto M, Yanagisawa S *et al*. Bacterial endophthalmitis after small incision cataract surgery. Effect of incision placement and intraocular lens type. *J Cataract Refract Surg* 2003; **29**: 20–26.
- Cooper BA, Holekamp NM, Bohigian G, Thompson PA. Case-control study of endophthalmitis after cataract surgery comparing scleral tunnel and clear corneal wounds. *Am J Ophthalmol* 2003; **136**: 300–305.
- Mayer E, Cadman D, Ewings P, Twomey JM, Gray RH, Claridge KG *et al*. A 10 year retrospective survey of cataract surgery and endophthalmitis in a single eye unit:



- injectable lenses lower the incidence of endophthalmitis. *Br J Ophthalmol* 2003; **87**: 867–869.
- 29 Ciulla TA, Starr MB, Masket S. Bacterial endophthalmitis prophylaxis for cataract surgery: an evidence-based update. *Ophthalmology* 2002; **109**: 13–24.
- 30 Lehmann OJ, Roberts CJ, Ikram K, Campbell MJ, McGill JI. Association between nonadministration of subconjunctival cefuroxime and postoperative endophthalmitis. *J Cataract Refract Surg* 1997; **23**: 889–893.
- 31 Montan PG, Wejde G, Koranyi G, Rylander M. Prophylactic intracameral cefuroxime. Efficacy in preventing endophthalmitis after cataract surgery. *J Cataract Refract Surg* 2002; **28**: 977–981.
- 32 Montan PG, Koranyi G, Setterquist HE, Stridh A, Philipson BT, Wiklund K. Endophthalmitis after cataract surgery: risk factors relating to technique and events of the operation and patient history: a retrospective case–control study. *Ophthalmology* 1998; **105**: 2171–2177.
- 33 Derekliis DL, Bufidis TA, Tsiakiri EP, Palassopoulos SI. Preoperative ocular disinfection by the use of povidone-iodine 5%. *Acta Ophthalmol (Copenh)* 1994; **72**: 627–630.
- 34 Leong JK, Shah R, McCluskey PJ, Benn RA, Taylor RF. Bacterial contamination of the anterior chamber during phacoemulsification cataract surgery. *J Cataract Refract Surg* 2002; **28**: 826–833.
- 35 Srinivasan R, Tiroumal S, Kanungo R, Natarajan MK. Microbial contamination of the anterior chamber during phacoemulsification. *J Cataract Refract Surg* 2002; **28**: 2173–2176.
- 36 Phillips II WB, Tasman WS. Postoperative endophthalmitis in association with diabetes mellitus. *Ophthalmology* 1994; **101**(3): 508–518.