References

1 Zaidi FH, Bloom PA, Corbett MC. Limbal stem cell deficiency: a clinical chameleon. *Eye* 2003; **17**: 837–839.

SJ Morgan

Sunderland Eye Infirmary
Queen Alexandra Road
Sunderland SR2 9HP, UK

Correspondence: SJ Morgan
Sunderland Eye Infirmary
Queen Alexandra Road
Sunderland SR2 9HP, UK
Tel: +44 191 565 6256
Direct line: +44 191 569 9279
Fax: +44 191 569 9060
E-mail: stephen.morgan@chs.northy.nhs.uk

Eye (2005) **19,** 813–814. doi:10.1038/sj.eye.6701655; published online 3 September 2004

Sir,

Matrix metalloproteinase expression in transplanted corneas

We are grateful to the comments from both centres which enable us to expand on the case of limbal stem cell deficiency (LSCD) that we originally described.[1] Firstly, donor epithelial defects can be intimately related to limbal stem cell function as early as the first day postoperatively—Ahmed and Ahmed have shown that corneal epithelial cell migration rate is 61 μm/h during the active healing phase of the epithelium, which means that the defect may close in 18–48 h, or even faster.[2] This rapid rate of recovery is a response to wounding, which has been conclusively shown by Lehrer *et al*[3] using double-labelling techniques. The latter experiments demonstrate three mechanisms to account for the persistent epithelial defect on day 1 following corneal grafting. First, replication of limbal stem cells. Second, additional cycles of cell proliferation that normally remain in reserve. Third, enhancement of transient amplifying cell (TAC) proliferation via a shortening of the cycling time. These processes may also be under circadian control.[4,5] The observed clinical epithelial defect day 1 postop in our patient is a clinical correlate of this upregulation of cell turnover in the limbus. This cellular upregulation has a further possible significance, as we shall discuss later specifically in response to Dr Zaher and Dr Ramesh's correspondence.

Regarding concerns about the rationale for our treatment of the first and second grafts, immunosuppression (steroid and cyclosporin) was not started to treat **either** the stem cell deficiency **or** the persistent epithelial defects. Rather, we started immunosuppression to treat **transplant rejection** which was causing stromal inflammation and, secondary to this, exacerbating poor healing at the site of the epithelial defect due to limbal stem cell deficiency. Immunosuppresion also served to reduce or prevent any further rejection occurring as a result of a persistent epithelial defect.

We appreciate Mr Morgan drawing attention to our use of cyclosporin drops and intensive topical preservative-free steroids. There is at present no hard verdict on the appropriateness of this choice over systemic administration of immunosuppressants. Opinions have varied since Kenyon and Tseng's[6] pioneering operations in the field were reported in 1989. For example, oral immunosuppression was used by Tsai and Tseng[7] in their work with limbal stem cell allografts, while other workers such as Tsubota *et al*[8] used a combination of both intensive systemic immunosuppression with cyclosporin and steroids, together with topical cyclosporin and two different types of topical steroid applied intensively (a total of 10 steroid drops per day).[7,8] Indeed Tan *et al*[9] noted in 1996 that the issue of immunosuppression was then under evaluation. More recently Xu *et al*[10] have convincingly shown *in vivo* in mammals that cyclosporin-A administered topically or systemically is equally effective in maintaining limbal stem cell grafts and the ocular surface. However, Tsubota *et al*[11] noted that limbal stem cell grafts may be more prone to tissue rejection than conventional corneal transplants, and this led them in at least one fairly recent clinical series to use systemic over topical immunosuppression. On the other hand, Shimazaki *et al*[12] have also in a fairly recent clinical series used intensive topical steroids for the treatment of LSCD with transplantation of limbal grafts and amniotic membrane grafts, as we did.

We disagree with Mr Morgan over the outcome of the course of events following the two corneal transplants, the first without and the second with limbal stem cell grafting, which, we feel, were markedly dissimilar. This is simply as the second corneal transplant survived.

It is in fact the similarities in both grafts that point to LSCD as the cause of the epithelial defects that occurred in both grafts—these being the identical shape *and* locations of the epithelial defects in both corneal grafts. These additionally matched those of the pterygium in the original host cornea, and, further, pterygium is also associated with LSCD.[12–14] Indeed, in addition to these identical anatomic and topographic defects across three

different corneal surfaces (host cornea, first donor cornea, second donor cornea), the patient displayed all three clinical features of LSCD at these locations that have been used to authoritatively diagnose the condition using clinical findings in the literature—haziness of the cornea and/or recurrent epithelial defects, persistent epithelial defect, and corneal conjunctivalisation (pterygium).[15] Finally, the recovery of corneal epithelium following limbal stem cell grafting adjacent to this site surely clinches the clinical diagnosis of LSCD.

In this regard, the only remaining controversy would seem to us over whether impression cytology was indicated—in the presence of such strong associations for LSCD *together* with the remarkably similar topography of ocular surface deficits in all three corneas, and in the absence of using harvested cells for culturing and autologous grafting,[15] impression cytology may be perceived as unnecessary and is indeed not universally practiced in this situation.

Dr Zaher and Dr Ramesh have offered an interesting possibility, aspects of which can also unify the constellation of associations for limbal stem cell malfunction found in our patient. However, while, as suggested by Dr Zaher and Dr Ramesh, matrix metalloproteinase (MMP) expression could account for many of these changes, including the temporal pattern of events, this would presumably also require upregulation of MMP expression in the limbus following corneal grafting, including the first transplant which was without a limbal stem cell graft. For both episodes of epithelial defect were associated with stromal changes, which following the first graft even led to a wound leak, while previously the stroma had been relatively preserved save for some involvement of its superficial extent by the pterygium. Further, the limbal stem cell graft would not have worked for abnormal limbal basal cells overproducing MMPs would not have been excised during limbal stem cell grafting, as the cells lie deep within the palisades of Vogt. However, suggesting a role for MMPs is nonetheless very interesting, as they may have another role.

Dr Zaher and Dr Ramesh correctly noted that limbal stem cells normally have a fairly slow turnover, and signs of deficiency are generally gradual in onset. While this is true in healthy eyes, it is crucial to note with our patient that in conditions of corneal wounding, as already detailed, reserve limbal cells come into action, accompanying an increase in cycling of limbal stem cells and TACs, making signs of deficiency very rapid indeed. That this may have a wider significance relevant to MMP expression is worth exploring. For, this very same cellular upregulation in the limbus causing the epithelial defect on day 1 may also be a source of upregulated MMP production, which dissolves superficial stroma (Bowman's layer) causing stromal oedema. MMPs work on any part of the stroma, but would have had the opportunity to attack the exposed superficial layer.

Upregulated cellular turnover at the limbus would also contribute to a rapid healing of the epithelium under either the original mechanism we proposed or through our modification to Dr Zaher and Dr Ramesh's very interesting suggestion. Both mechanisms are biologically plausible, and both suggest that the limbal stem cell graft we performed would be of benefit to the underlying pathology. Limbal stem cell grafts may thus function either by 'diluting' the effect of abnormal MMP-secreting cells and/or replacing deficient ones. This novel hypothesis may be an avenue deserving more consideration in future research. We are grateful to the authors from both centres for raising these issues which are relevant to understanding the myriad of roles limbal stem cells have.

References

1 Zaidi FH, Bloom PA, Corbett MC. Limbal stem cell deficiency: a clinical chameleon. *Eye* 2003; **17**(7): 837–839.
2 Ahmed A, Ahmed N. Delay in migration of the corneal epithelium after incorporation of [3H]-mannose in organ cultures. *Eur J Ophthalmol* 2003; **13**: 360–364.
3 Lehrer MS, Sun TT, Lavker RM. Strategies of epithelial repair: modulation of stem cell and transit amplifying cell proliferation. *J Cell Sci* 1998; **111**(Part 19): 2867–2875.
4 Lavker RM, Miller S, Wilson C, Cotsarelis G, Wei ZG, Yang JS *et al*. Hair follicle stem cells: their location, role in hair cycle, and involvement in skin tumor formation. *J Invest Dermatol* 1993; **101**(1 Suppl): 16S–26S.
5 Pellegrini G, Golisano O, Paterna P, Lambiase A, Bonini S, Rama P *et al*. Location and clonal analysis of stem cells and their differentiated progeny in the human ocular surface. *J Cell Biol* 1999; **145**(4): 769–782.
6 Kenyon KR, Tseng SC. Limbal autograft transplantation for ocular surface disorders. *Ophthalmology* 1989; **96**(5): 709–722 discussion 722–723.
7 Tsai RJ, Tseng SC. Human allograft limbal transplantation for corneal surface reconstruction. *Cornea* 1994; **13**(5): 389–400.
8 Tsubota K, Toda I, Saito H, Shinozaki N, Shimazaki J. Reconstruction of the corneal epithelium by limbal allograft transplantation for severe ocular surface disorders. *Ophthalmology* 1995; **102**(10): 1486–1496.
9 Tan DT, Ficker LA, Buckley RJ. Limbal transplantation. *Ophthalmology* 1996; **103**(1): 29–36.
10 Xu KP, Wu Y, Zhou J, Zhang X. Survival of rabbit limbal stem cell allografts after administration of cyclosporin A. *Cornea* 1999; **18**(4): 459–465.
11 Tsubota K, Satake Y, Kaido M, Shinozaki N, Shimmura S, Bissen-Miyajima H *et al*. Treatment of severe ocular-surface

disorders with corneal epithelial stem-cell transplantation. *N Engl J Med* 1999; **340**(22): 1697–1703.
12 Shimazaki J, Shinozaki N, Tsubota K. Transplantation of amniotic membrane and limbal autograft for patients with recurrent pterygium associated with symblepharon. *Br J Ophthalmol* 1998; **82**(3): 235–240.
13 Espana EM, Grueterich M, Romano AC, Touhami A, Tseng SC. Idiopathic limbal stem cell deficiency. *Ophthalmology* 2002; **109**(11): 2004–2010.
14 Zaidi FH, Weir R, Cheong-Leen R, Corbett MC, Sharkawi E, King ER. Ultraviolet light and stem cells. *Ophthalmology* 2004; **111**(1): 196.
15 Rama P, Bonini S, Lambiase A, Golisano O, Paterna P, De Luca M *et al*. Autologous fibrin-cultured limbal stem cells permanently restore the corneal surface of patients with total limbal stem cell deficiency. *Transplantation* 2001; **72**(9): 1478–1485.

FH Zaidi[1,2] and MC Corbett[2]

[1]Imperial College London, UK

[2]The Western Eye Hospital, St Mary's and The Western Eye Hospitals, London, UK

Correspondence: FH Zaidi
Department of Visual Neuroscience
Imperial College London
Room 9L01, Laboratory Block
Charing Cross campus
St Dunstan's Road
London W6 8RP, UK
Tel: +44 20 8383 3696
Fax: +44 20 8383 3651
E-mail: f.zaidi@imperial.ac.uk

Eye (2005) **19,** 814–816. doi:10.1038/sj.eye.6701656; published online 3 September 2004

Sir,

Optic disc drusen associated with neovascularization of optic disc

Optic disc drusen are known to be associated with other ocular conditions such as angioid streaks and retinitis pigmentosa and are rarely complicated by peripapillary disciform degeneration, central retinal arterial and venous occlusions. We report a patient who presented with bilateral optic disc drusen associated with bilateral neovascularization of the optic discs (NVD).

Case report

A 54-year-old woman who was asymptomatic was referred following a visit to an optician for a routine eye check. Her visual acuity was 6/4 in the right eye. Her left eye was amblyopic and had a visual acuity of 6/36. The anterior segments were normal in both eyes with normal intraocular pressures. Posterior segment did not show any evidence of inflammation. Fundus examination showed presence of well-marked optic disc drusen in both eyes (Figure 1a, b). In addition, she had NVD in both eyes with a small optic disc haemorrhage in the left eye. The retinas appeared normal in both eyes. On fluorescein angiography, the preinjection photographs clearly showed autofluorescence from optic disc drusen in both eyes (Figure 2a, b). Fluorescein angiogram also confirmed the NVD (Figure 2c, d) on both sides with normal choroid and retina. Systemic evaluation was normal.

A detailed discussion with the patient about treatment resulted in a decision to perform panretinal photocoagulation in the right eye first. When the patient was reassessed in 4 weeks, the NVD had regressed

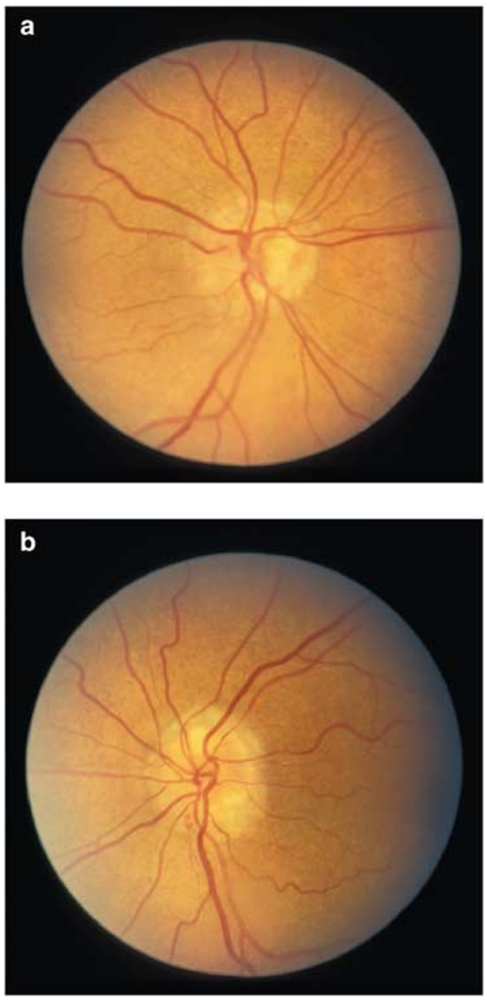

Figure 1 (a, b) Colour fundus photographs showing optic disc drusen and NVD.