

Malignant tumours of the salivary glands

RJ Bensadoun¹, MP Blanc-Vincent^{2,3}, P Chauvel¹, O Dassonville¹, G Gory-Delabaere^{2,4} and F Demard¹

¹Centre Antoine Lacassagne, Nice; ²FNCLCC, Paris; ³Institut Bergonié, Bordeaux; ⁴Centre Val d'Aurelle Paul-Lamarque, Montpellier, France

Malignant tumours of the salivary glands are relatively rare, with an estimated incidence of less than 1 per 100 000. They represent a little less than 5% of head and neck tumours. These are generally slow-growing tumours of varied histology, long doubling times and late locoregional and distant recurrences. Prolonged survival is possible, even with metastatic disease.

These recommendations do not consider salivary gland lymphomas. They were validated in August 1999 and an update is planned for the year 2000.

PROGNOSTIC FACTORS

The most important prognostic factors with respect to local control and survival are tumour size and clinical stage. Other independent factors are the histology, (low grade vs high grade) and the treatment (the quality of the surgical excision). Knowledge of these factors is part of initial staging, and allows the subsequent therapeutic strategy to be matched to the clinical situation.

DIAGNOSIS AND STAGING

Standard staging of malignant tumours of the salivary glands is based on clinical examination, imaging and histopathological examination.

From clinical examination, the size of the lesion, locoregional extension, and any signs suggestive of malignancy (e.g. facial paralysis, trismus, cutaneous infiltration) can be determined. Endoscopic examination (often under general anaesthesia) is required to obtain biopsy samples and to complete the staging of tumours of the minor salivary glands (notably those in the pharynx and larynx).

Clinical assessment of locoregional extension is based on examination of the neck. A total body examination is required to look for distant metastases. An assessment of performance status, nutritional status and of major organ function, using clinical and laboratory parameters, determines whether or not the patient has operable disease (standard).

Standard imaging consists of a cervico-facial CT scan or high-resolution ultrasound (level of evidence B). High-resolution ultrasonography must only be used by those teams trained in this method. For tumours under the maxilla, an orthopantomogram is necessary to complete staging (standard). MRI imaging and sialograms are options. Further imaging is done according to symptoms and signs suggestive of malignant involvement and extraglandular spread.

Histopathological examination is necessary to confirm a diagnosis of malignancy. An excision biopsy with frozen section is required for the major salivary glands (standard) and a simple biopsy for the minor salivary glands (standard). A preoperative diagnosis can be made by cytological analysis following fine-needle aspiration (option).

Staging

The TNM AJC/UICC classification is the most practical and the best adapted to treatment decision-making (standard). The histological classification differentiating the tumours according to grade (low vs high grade), is now universally recognized (standard).

TREATMENT

The basic treatment of salivary gland tumours is complete surgical excision (standard), with or without postoperative irradiation, according to the clinical stage and the histological grade. The combination of surgery and radiotherapy is the treatment of choice for high grade disease.

Routine postoperative radiotherapy is indicated for stage II, III and IV high grade tumours and for low grade stage III and IV tumours (standard). It is also indicated in all cases in which surgery has been macro- or microscopically incomplete (standard).

Neutron therapy alone, when possible, is the treatment of choice for inoperable tumours, whatever the stage and grade. To a lesser degree, neutron therapy provides an alternative treatment for locally advanced disease (stages III and IV) where surgery is likely to be difficult or to result in significant functional sequelae (option). This requires further evaluation. Postoperative neutron therapy is not indicated except in the case of large-volume residual disease (option, level of evidence C).

The place of chemotherapy remains unclear. It should only be given within a multicentre therapeutic trial. Treatment is according to clinical stage and histological grade.

Stage I, low grade / high grade: T1a T2a N0 M0

Complete surgical resection is the standard treatment for stage I tumours of the salivary glands (Figures 1 and 2). For tumours of the major salivary glands the gland must be completely excised (standard). For tumours of the minor salivary glands, a wide radical resection must be undertaken (standard). In all cases, the excision should be complete and in the case of encapsulated tumours, outside the capsule.

If the resection is macroscopically and microscopically complete, there is no indication for adjuvant radiotherapy, even for high grade tumours (standard).

If the excision is incomplete, or if histological examination has shown tumour at the excision margins, postoperative radiotherapy is indicated (standard). Postoperative irradiation should be with photons (\pm electrons) with standard fractionation (level of evidence A). Irradiation with neutrons can be given in cases of large-volume residual disease (option, level of evidence C).

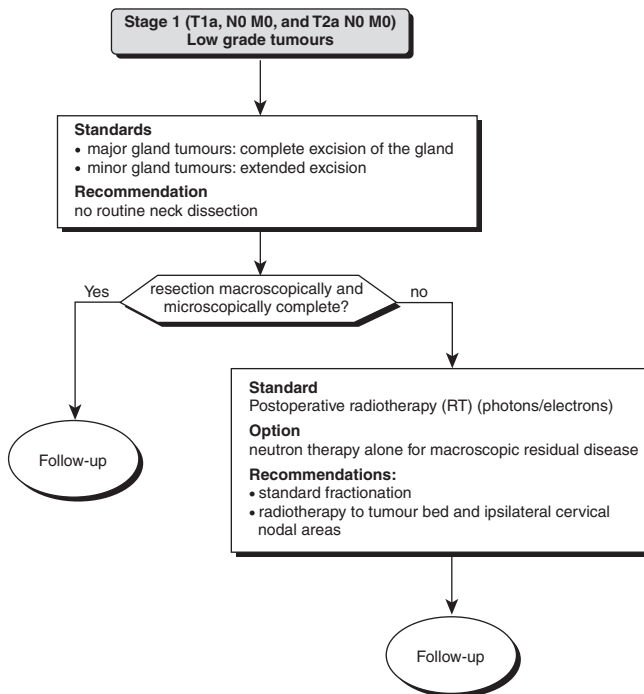


Figure 1 Treatment of stage I carcinoma of the salivary glands (low grade)

Routine ipsilateral nodal clearance is standard for T2 high grade tumours (standard, level of evidence B) and is an option for T1a tumours (option). If nodal involvement is detected at the time of surgery, ipsilateral neck dissection followed by routine postoperative radiotherapy is recommended (level of evidence B).

Stage II, T1b T2b T3a N0 M0

Low grade tumours

Surgery alone, of variable extent, is the standard treatment (Figure 3). If a complete resection is likely to result in a significant functional or cosmetic deficit, neutron therapy alone can be undertaken (option, level of evidence C). Postoperative radiotherapy must be undertaken if the surgical excision margins are involved (standard). In the case of positive nodes, extended surgical excision of the tumour and cervical nodes is followed by postoperative irradiation irrespective of whether the resection is macroscopically or microscopically complete (level of evidence B) or incomplete (level of evidence A).

High grade tumours

Surgery alone (complete excision, with or without subsequent extraglandular extension and ipsilateral neck dissection) is indicated for lesions limited to the gland (standard) (Figure 4). In the case of extension of the tumour to involve the facial nerve or crucial structures, the therapeutic options are extensive disfiguring surgery or neutron therapy alone. External irradiation (with neutrons) as first-line therapy can be considered for lesions judged to be incompletely resectable, or where extensive disfiguring surgery will be necessary with the risk of significant functional impairment (notably disease extending to the facial nerve, infratemporal fossa or the mandible) (option, level of evidence B).

Routine postoperative external irradiation to tumour and nodes is standard when the excision has been incomplete (macro- and

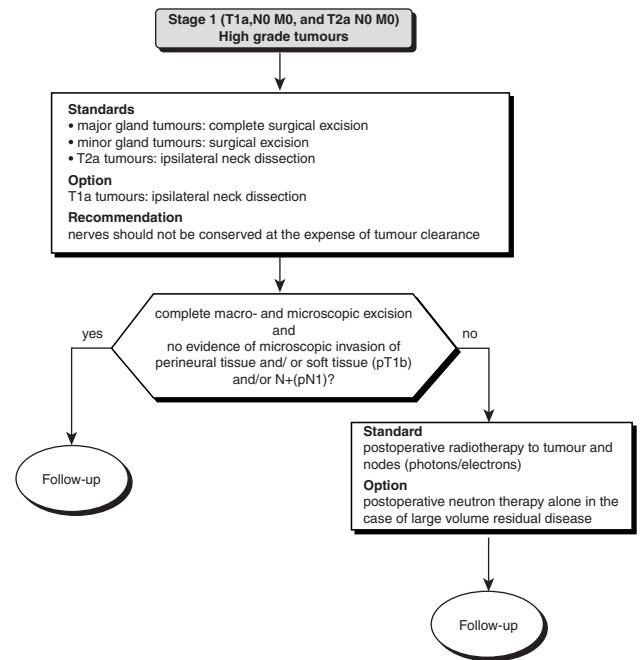


Figure 2 Treatment of stage I disease (high grade)

microscopically) or in the case of positive nodes (standard). It is recommended in cases of complete excision (option, level of evidence B). The role of chemotherapy, either as neoadjuvant or adjuvant treatment or with the aim of radiosensitization, must be evaluated in prospective therapeutic trials (it has no role as routine treatment).

Stage III, T3b T4a N0 M0 all T (except T4b) N1 M0

Low grade tumours

Low grade stage III tumours are treated in the same way as high grade stage II tumours (Figure 4). If surgery has been complete, postoperative irradiation to the tumour and nodes remains the standard treatment. Neutron therapy alone is preferable in certain cases where surgery would be very extensive and disfiguring. The standard treatment of N1 lesions is primary tumour and nodal surgery with uni- or bilateral neck dissection (bilateral in the case of midline tumours), followed by postoperative irradiation (standard). The extent of nodal irradiation will depend on the histological findings following neck dissection.

High grade tumours

For stage III high grade tumours, two types of treatment can be considered: complete excision of the primary tumour and nodes, followed by radiotherapy, or neutron therapy alone to both tumour and nodes (option) (Figure 5). The place of chemotherapy must be evaluated within prospective trials (it has no role as routine treatment).

Stage IV disease

T4b low and high grade, all N, M0

There is no standard therapeutic approach for the management of patients presenting with stage 4b low or high grade node-positive stage IV disease (Figure 6).

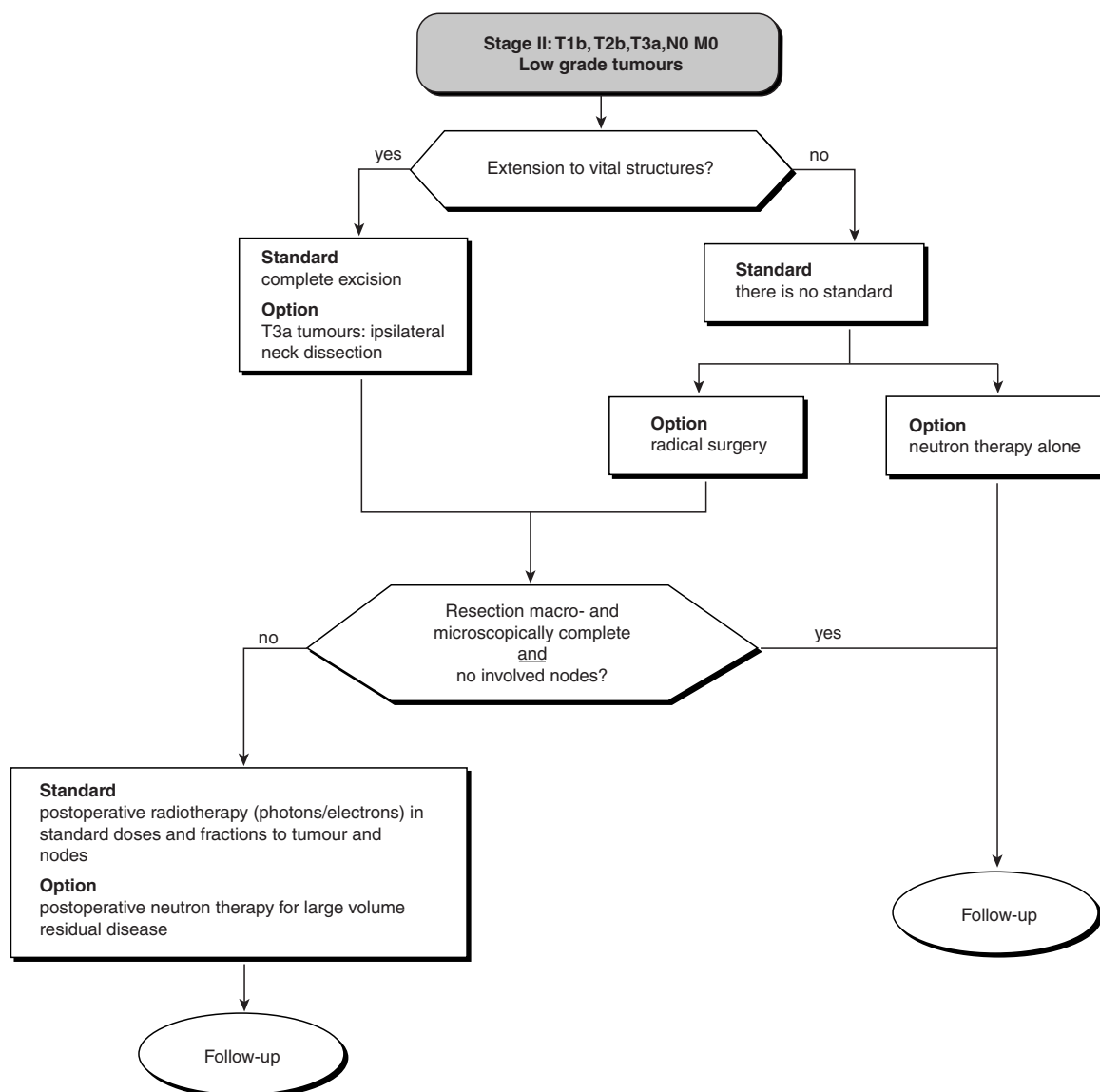


Figure 3 Treatment of stage II disease (low grade)

The therapeutic options are neutron therapy alone to tumour and nodes or extensive disfiguring surgery followed by radiotherapy (level of evidence B).

Surgery should be radical and carried out by cancer specialists. The role of chemotherapy remains to be evaluated within prospective therapeutic trials.

For T4b N0 M0 disease, neutron therapy alone is the technique of choice (level of evidence B). The role of chemotherapy must be evaluated within prospective therapeutic trials (no role in routine use).

All T, N2 or N3 M0 disease

If the primary lesion is easily resectable (T1–T2), the standard treatment is surgical excision of tumour and nodes. In all other cases, neutron therapy alone, when possible, is preferable to extensive disfiguring surgery (option) (Figure 6).

All T, all N, M1 disease (distant metastases)

In metastatic disease, the recommended therapeutic approach is palliative treatment (standard) and the evaluation of chemotherapy and/or surgery and/or radiotherapy within multicentre trials (option) (Figure 7). Elective surgical excision is the standard treatment for isolated pulmonary metastases.

Inoperable disease

In patients unfit for surgery, or with unresectable disease, the recommended treatment is neutron therapy alone where possible (option, level of evidence B) (Figure 8). Standard radiotherapy with photons, including those protocols using hyperfractionation or accelerated irradiation (which is still under evaluation in this condition) gives inferior results (level of evidence B).

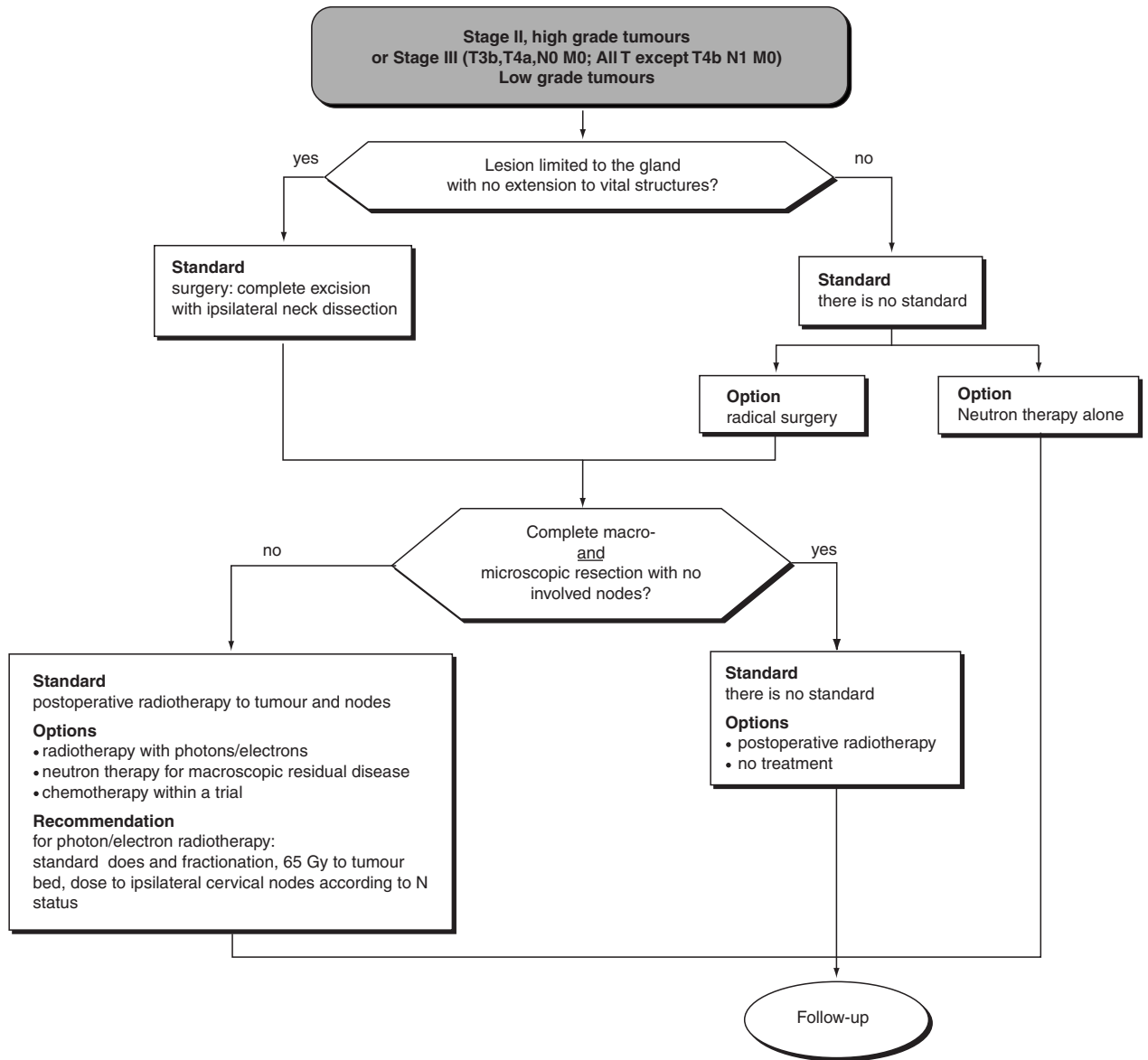


Figure 4 Treatment of stage II disease (high grade) or stage III (low grade)

Incomplete surgery followed by radiotherapy with photons, is not recommended. The place of chemotherapy, especially in high grade tumours, must be evaluated within prospective trials.

Loco-regional recurrence

There is no standard therapeutic approach. This will depend largely on the type of recurrence and above all on the treatment that has previously been given to the primary tumour. In the case of relapse after surgery, further surgery followed by postoperative radiotherapy, or neutron therapy alone can be considered (options). For recurrent disease after radiotherapy alone or after surgery followed by radiotherapy, the treatment options are: repeat surgery if possible, neutron therapy at a dose limited by the previous irradiation, or chemotherapy within a prospective trial (especially for high grade disease) (Figure 9).

For nodal relapses, uni- or bilateral nodal dissection (\pm post-operative irradiation), can be considered (options). If the recurrence

is inoperable, neutron therapy alone, irradiation with photons combined with localized hyperthermia, or chemotherapy within a prospective trial (especially for high grade disease) are the treatment options.

FOLLOW-UP

Monthly surveillance is recommended during the first 6 months following treatment (3 months in the case of low grade tumours and stage I and II disease). Thereafter, follow-up can be 4-monthly, then 6-monthly for 3–4 years, then annually. The assessment should include a chest X-ray (AP and lateral) every 6 months initially, then every year.

INTERNAL REVIEWERS

C Alzieu (Institut Paoli Calmettes, Marseille), P Barrellier (Centre François Baclesse, Caen), G Dolivet (Centre Alexis Vautrin,

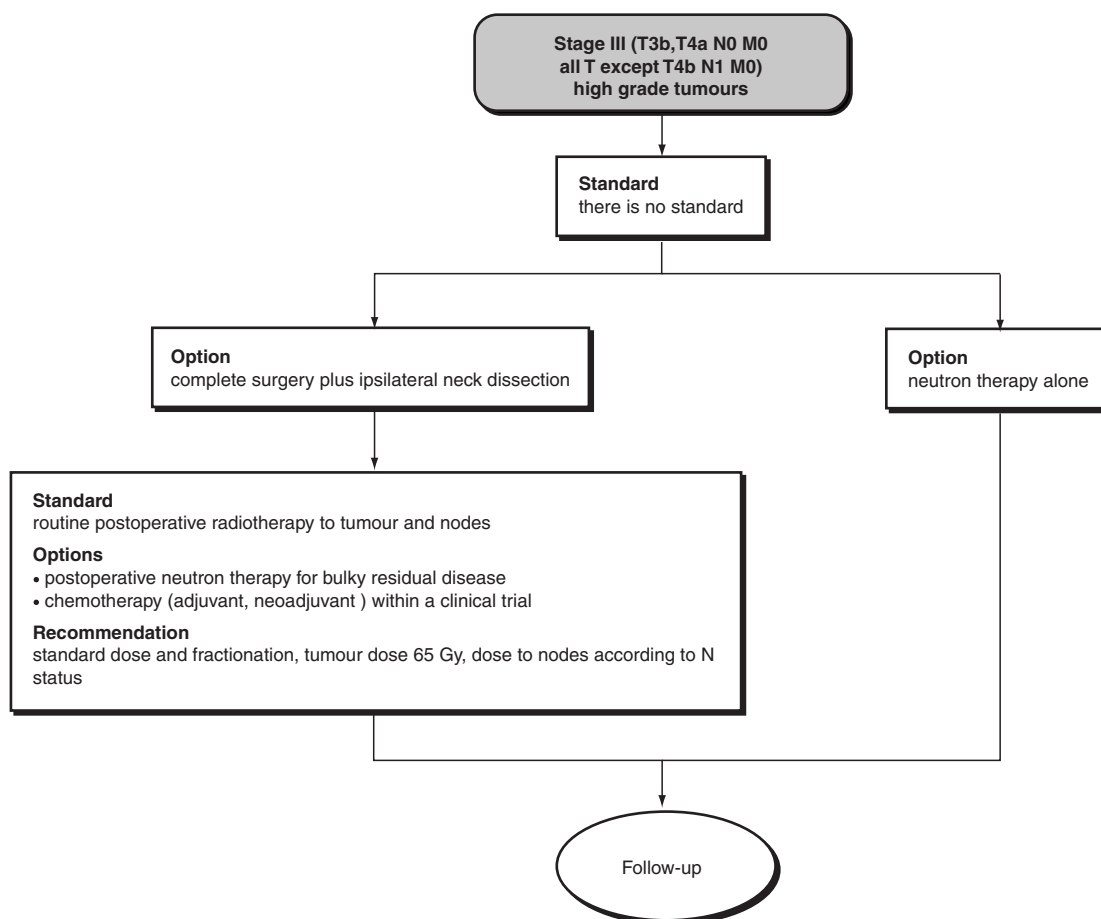


Figure 5 Treatment of stage III disease (high grade)

Vandœuvre-lès-Nancy), M Fabbro (Centre Val d'Aurelle, Montpellier), L. Geoffrois (Centre Alexis Vautrin, Nancy), B Gignoux (Centre Régional Léon Bérard, Lyon), JM Hannoun-Levi (Institut Paoli Calmettes, Marseille), JC Horiot (Centre Georges-François Leclerc, Dijon), P. Marandas (Institut Gustave Roussy, Villejuif), F Pech-Gourg (Institut Paoli Calmettes, Marseille), JL Renaud-Salis (Institut Bergonié, Bordeaux), J Rodriguez (Institut Curie, Paris), G Schwaab (Institut Gustave Roussy, Villejuif), T Tursz (Institut Gustave Roussy, Villejuif) and P Wibault (Institut Gustave Roussy, Villejuif).

EXTERNAL REVIEWERS

N Barbet (Macon), E Barthelme (Hôpital Bon Secours, Metz), I Bartholomot (Saint-Nazaire), P Bergerot (Saint-Nazaire), P Bertoin (Lyon) M Bethouart (Cabinet d'Anatomocytologie,

Roubaix), M Boukhefila (Wattrelos), N Breteau (CHR Hôpital de la Source, Orléans), P Breton (Centre Hospitalier Lyon Sud, Pierre-Bénite), JF Chassagne (CHU Hôpital Central, Nancy), R Combelles (Hôpital Purpan, Toulouse), R Coquard (Clinique Saint-Jean, Lyon), P Desprez (Centre Saint-Yves, Vannes), M Drey (Reims), F Economides (Dunkerque), D Fric (Clinique du Mail, Grenoble), B Guerrier (Hôpital Saint-Charles, Montpellier), D Heymans (Centre Saint-Michel, La Rochelle), M Housset (Hôpital Tenon, Paris), P Juin (CHU Hôpital la Timone, Marseille), G Le Clech (Hôpital de Pontchaillou, Rennes), P Martin (Clinique Saint-Jean, Lyon), KT Nguyen (Roubaix), C Pasteris (Clinique de Savoie, Annemasse), JL Reynoard (Clinique Victor Hugo, Angoulême), N Rouverand (Clinique de la Louvière, Lille), P Seguin (CHU Hôpital de Bellevue, Saint-Etienne), F Siberchicot (Hôpital Pellegrin Tripode, Bordeaux) and J Trotoux (Hôpital Boucicaud, Paris).

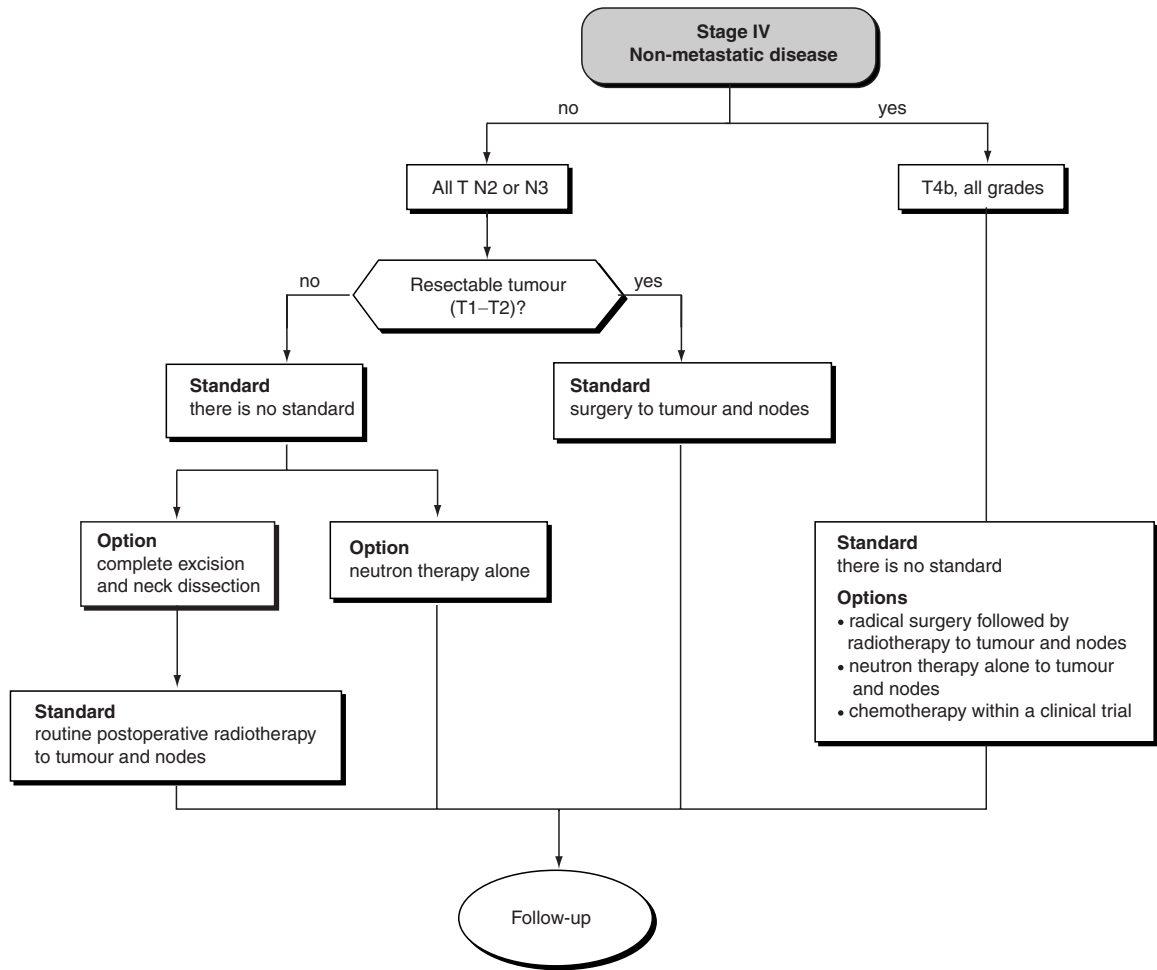


Figure 6 Treatment of stage IV non-metastatic disease

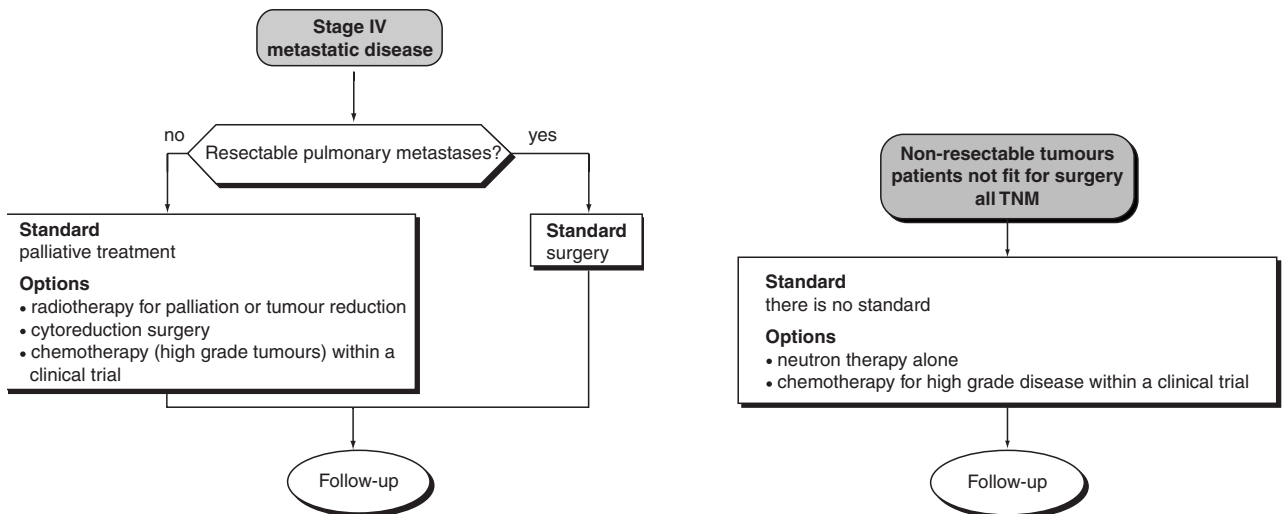


Figure 7 Treatment of stage IV metastatic disease

Figure 8 Treatment of inoperable disease

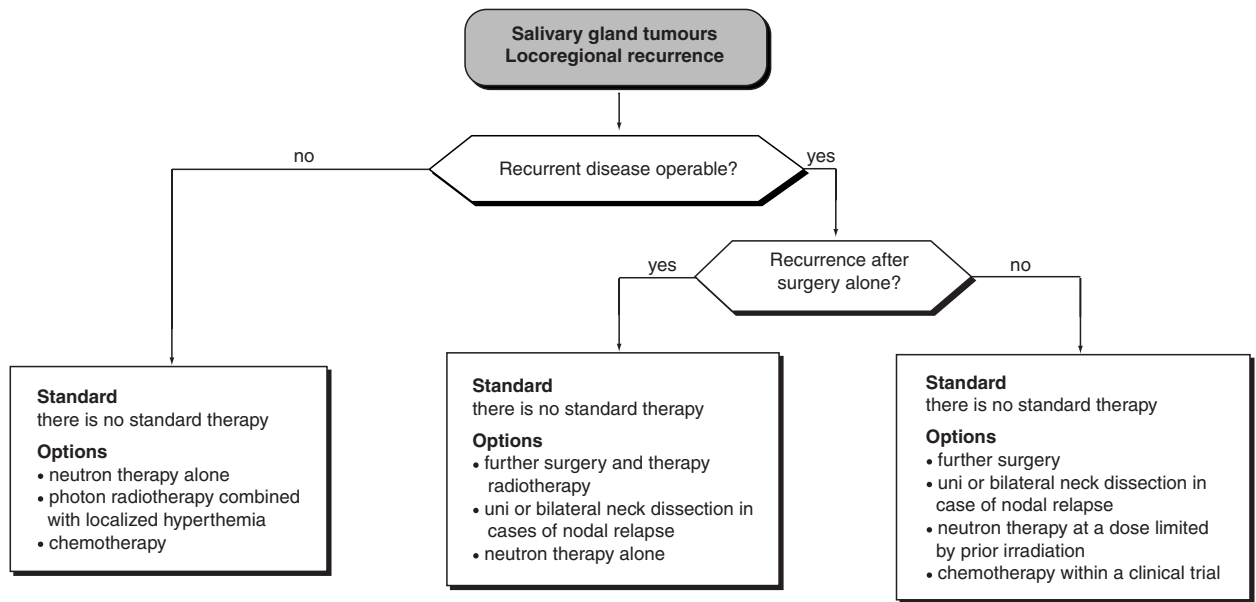


Figure 9 Treatment of locoregional recurrence