

Review

First international consensus on the methodology of lymphangiogenesis quantification in solid human tumours

I Van der Auwera¹, Y Cao², JC Tille³, MS Pepper⁴, DG Jackson⁵, SB Fox⁶, AL Harris⁷, LY Dirix¹ and PB Vermeulen^{*,1}

¹Translational Cancer Research Group Antwerp, Laboratory of Pathology, University of Antwerp/University Hospital Antwerp, Edegem 2650, Belgium; Oncology Centre, General Hospital Sint-Augustinus, Wilrijk 2610, Belgium; ²Laboratory of Angiogenesis Research, Microbiology and Tumor Biology Center, Karolinska Institutet, Stockholm 171 77, Sweden; ³Department of Microbiology, Laboratory of Angiogenesis Research, Tumor and Cell Biology, Karolinska Institutet, Stockholm 171 77, Sweden; ⁴NetCare Molecular Medicine Institute, Unitas Hospital and Department of Immunology, Faculty of Health Sciences, University of Pretoria, Pretoria 0002, South Africa; ⁵Medical Research Council Human Immunology Unit, Weatherall Institute of Molecular Medicine, John Radcliffe Hospital, Oxford OX3 9DS, UK; ⁶Department of Pathology, Peter MacCallum Cancer Centre, Victoria 8006, Australia; ⁷Cancer Research UK Molecular Oncology Laboratories, Weatherall Institute of Molecular Medicine, University of Oxford, John Radcliffe Hospital, Oxford OX3 9DS, UK

The lymphatic system is the primary pathway of metastasis for most human cancers. Recent research efforts in studying lymphangiogenesis have suggested the existence of a relationship between lymphatic vessel density and patient survival. However, current methodology of lymphangiogenesis quantification is still characterised by high intra- and interobserver variability. For the amount of lymphatic vessels in a tumour to be a clinically useful parameter, a reliable quantification technique needs to be developed. With this consensus report, we therefore would like to initiate discussion on the standardisation of the immunohistochemical method for lymphangiogenesis assessment.

British Journal of Cancer (2006) 95, 1611–1625. doi:10.1038/sj.bjc.6603445 www.bjcancer.com

Published online 21 November 2006

© 2006 Cancer Research UK

Keywords: lymphangiogenesis; lymphatic vessel density (LVD); lymphatic endothelial cell proliferation (LECP); podoplanin; lymph node metastasis; vascular endothelial growth factor (VEGF)

Metastasis is the leading cause of cancer mortality. Metastatic cancer cells can escape from their site of origin and spread to distant organs through invasion of the vascular system and/or the lymphatic system. Tumour vascularisation is widely accepted as a *bona fide* indicator of tumour growth, metastases and patient survival. In 1996, Peter Vermeulen *et al* (1996) published a first international consensus on the methodology and criteria of the evaluation of angiogenesis quantification in solid tumours and 5 years later, a second consensus report, in which new concepts and mechanisms of tumour vascularisation were integrated, appeared (Vermeulen *et al*, 2002). Both reports were aimed at improving the standardisation of angiogenesis quantification in order to allow intratumourous microvessel density to be applied as a prognostic indicator and, moreover, as a reliable predictor of the risk of malignant transformation of premalignant lesions and of response to cancer treatment. Contrary to angiogenesis, the *de novo* formation of lymphatic vessels or lymphangiogenesis and its role in promoting the metastatic spread of tumour cells has only recently become a focal point of cancer research with an increasing number of studies showing a relationship between patient survival and lymphatic density in different tumour types. In order to confirm the potential prognostic value of lymphangiogenesis in

patients with cancer, a quantification method that is characterised by a low intra- and interobserver variability needs to be developed. In this first consensus report, we would like to provide an overview of current concepts of the lymphatic vasculature and its regulating factors and propose guidelines for the estimation of the ongoing lymphangiogenesis in solid human tumour sections.

Structural and molecular characteristics of the lymphatic vasculature

The vascular and lymphatic systems play complementary roles in tissue perfusion and subsequent extracellular fluid reabsorption. Lymphatic vessels comprise a complex open-ended capillary network that collect lymph from various organs and tissues. Lymphatic vessels are lined by a single layer of nonfenestrated endothelium that is attenuated over most of its surface, except in the perinuclear region which bulges into the lumen (Leak, 1976). Lymphatic endothelium has an incomplete or absent basement membrane and has overlapping junctional complexes. Lymphatics are attached to the underlying matrix through anchoring filaments (Leak and Burke, 1968), which keep the vessel patent and therefore aid lymphatic flow even in areas with elevated hydrostatic pressure and these filaments may mediate outside-in signalling from the extracellular matrix akin to integrins. The complex anchoring filaments–focal adhesions may also control the permeability of lymphatic endothelium and finely adjust lymph formation to the physiological conditions of the extracellular matrix.

*Correspondence: Dr PB Vermeulen, Laboratory of Pathology, General Hospital St-Augustinus, Oosterveldlaan 24, 2610 Wilrijk, Belgium; E-mail: peter.vermeulen@gvagrugroup.be

Received 24 May 2006; revised 18 September 2006; accepted 26 September 2006; published online 21 November 2006

There are some differences in structure in different parts of the lymphatic system. Lymphatic vessels in tissues are absorbing capillaries with walls consisting solely of endothelium that drain into collecting vessels. Collecting lymphatic vessels have a thin circumferential extracellular coat and pericytes that reduce lymphatic fluid extravasation (Pepper and Skobe, 2003b). The transition between the absorbing and collecting vessels occurs gradually and so-called precollectors have been described which drain into prenodal collecting vessels with an irregular and tortuous course. The precollectors and collecting lymphatic vessels also have valves that enable uni-directional lymph flow (Swartz and Skobe, 2001).

Vascular and lymphatic endothelial cells share many similarities (Alitalo *et al*, 2005). Indeed, although initially thought to be restricted to blood vascular endothelial cells (BVECs), rod-like electrondense Weibel-Palade bodies containing Factor VIII-related antigen (von Willebrand factor) have been reported in lymphatic endothelial cells (LECs) (Di Nucci *et al*, 1996; Marchetti, 1996; Sacchi *et al*, 1999). Furthermore, 98% of genes were expressed at comparable levels by BVECs and LECs in culture (Petrova *et al*, 2002; Podgrabinska *et al*, 2002; Hirakawa *et al*, 2003) with the

differences in those genes being involved in the regulation of lymphangiogenesis and lymphatic function (Sleeman *et al*, 2001) (vide infra). Nevertheless, akin to vascular endothelium, comparative studies suggest that different lymphatic endothelia have different phenotypes that are likely to mediate various biological activities (Garrafa *et al*, 2006).

Molecular players of tumour lymphangiogenesis

Similar to angiogenesis, the growth of lymphatic vessels is regulated by a large number of growth factors (Table 1, Figure 1). Initially, members of the vascular endothelial growth factor (VEGF) family, VEGF-C and VEGF-D, were thought to be the only lymphangiogenic factors that stimulate lymphangiogenesis via activation of VEGFR-3 specifically expressed on normal LECs (Oh *et al*, 1997; Achen *et al*, 1998). The observation that a number of tumours expressing these two factors at low or undetectable levels that metastasize via the lymphatic system suggests that additional signalling systems probably exist (Cao, 2005a).

In xenographic and transgenic mouse tumour models, the overexpression of VEGF-A in tumours leads to lymphatic

Table 1 Molecular players of lymphangiogenesis

Gene	Involvement in lymphangiogenesis	Reference
VEGF-C	Essential for sprouting the first lymphatic vessel from Prox-1-positive endothelial cells of veins Overexpression in mouse tumour models promotes the growth of intratumourous lymphatic vessels and metastasis to regional lymph nodes	Karkkainen <i>et al</i> (2004) Skobe <i>et al</i> (2001), Karpanen <i>et al</i> (2001)
VEGF-D	Overexpression in mouse tumour models induces the formation of lymphatic vessels within the tumour and leads to spread of the tumour to lymph nodes	Stacker <i>et al</i> (2001)
VEGFR-3	Plays an important role in the development of the lymphatic vasculature Induces proliferation of cultured LECs Induces lymphangiogenesis in transgenic mice	Karkkainen <i>et al</i> (2000) Mäkinen <i>et al</i> (2001) Veikkola <i>et al</i> (2001)
VEGF-A	Overexpression in mouse tumour models induces the growth of peritumourous lymphatic vessels and leads to lymphatic metastasis VEGFR-2 is expressed in LECs Can induce lymphangiogenesis indirectly by recruiting VEGFR-1 expressing inflammatory cells including monocytes/macrophages and neutrophils	Bjorndahl <i>et al</i> (2005b), Hirakawa <i>et al</i> (2005) Hong <i>et al</i> (2004) Cursiefen <i>et al</i> (2004)
FGF-2	Stimulates proliferation, migration and tube formation of cultured LECs Induces sprouting of lymphatic vessels in a mouse corneal model can induce lymphangiogenesis indirectly by recruiting inflammatory cells	Chang <i>et al</i> (2004), Shin <i>et al</i> (2005) Chang <i>et al</i> (2004), Kubo <i>et al</i> (2002)
PDGF-BB	Stimulates cell motility of cultured LECs Isolated LECs express both PDGFR-alpha and beta Overexpression in a mouse tumour model stimulates the growth of intratumourous lymphatic vessels and lymphatic metastasis	Cao <i>et al</i> (2004)
Ang-2	Ang-2-knockout mice show disorganised and hypoplastic dermal and intestinal lymphatic capillaries	Gale <i>et al</i> (2002)
Ang-1	Restores lymphatic defects of Ang-2-knock-out mice Promotes LYVE-1-positive lymphatic vessel formation in murine cornea	Gale <i>et al</i> (2002) Morisada <i>et al</i> (2005)
HGF	Stimulates proliferation, migration and tube formation of cultured LECs Induces sprouting and growth of new LYVE-1 expressing lymphatic vessels in mice corneal and tumour models	Kajjya <i>et al</i> (2005) Cao <i>et al</i> (2006), Jiang <i>et al</i> (2005)
IGF-1	Stimulates proliferation and migration of cultured LECs IGFR-1 is present in lymphatic endothelium Induces growth of new LYVE-1 expressing lymphatic vessels in murine cornea	Bjorndahl <i>et al</i> (2005a)
IGF-2	Stimulates proliferation and migration of cultured LECs IGFR-1 and -2 are present in lymphatic endothelium Induces growth of new LYVE-1 expressing lymphatic vessels in murine cornea	Bjorndahl <i>et al</i> (2005a)

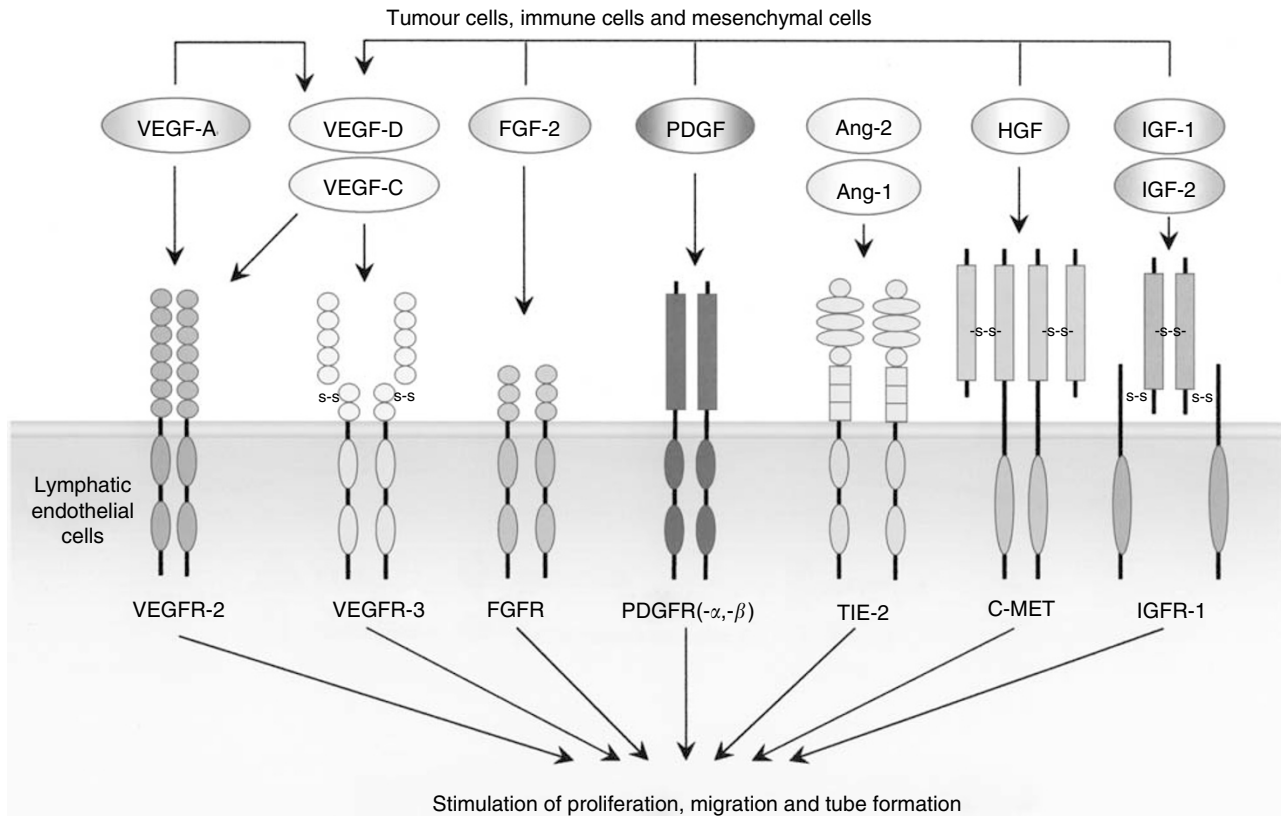


Figure 1 Lymphangiogenic growth factors and their receptors.

metastasis via intra- and peritumourous lymphatic vessels (Hirakawa *et al*, 2005; Bjorndahl *et al*, 2005b). It appears that VEGF-A indirectly induces lymphangiogenesis by recruiting VEGFR-1 expressing inflammatory cells including monocytes/macrophages and neutrophils that produce VEGF-C/D because VEGFR-3 antagonists are able to block VEGF-A-induced lymphangiogenesis (Cursiefen *et al*, 2004). However, the direct effect of VEGF-A on lymphangiogenesis has also been reported since VEGFR-2 is expressed in LECs (Hong *et al*, 2004). Similar to VEGF-A, FGF-2 can indirectly induce lymphangiogenesis via the VEGF-C/D/VEGFR-3 pathway by the recruitment of inflammatory cells, although a recent study also shows that FGF-2 may also directly stimulate the growth of LECs *in vitro* and lymphangiogenesis *in vivo* (Kubo *et al*, 2002; Chang *et al*, 2004; Shin *et al*, 2005). PDGF-BB was only recently described as a direct lymphangiogenic factor that promotes lymphatic metastasis (Cao *et al*, 2004). Both PDGF receptor alpha (PDGFR-α) and beta (PDGFR-β) are expressed on isolated LECs and all three prototypes of PDGFs, PDGF-AA, PDGF-BB and PDGF-CC, are able to induce lymphangiogenesis (Cao *et al*, 2004). Members of the angiopoietin (Ang-1 and -2), hepatocyte growth factor (HGF) and insulin-like growth factor (IGF-1 and IGF-2) family are newly reported direct lymphangiogenic factors (Gale *et al*, 2002; Morisada *et al*, 2005; Bjorndahl *et al*, 2005a; Cao, 2005b).

These known lymphangiogenic factors exhibit overlapping angiogenic activity on blood vessels. Thus, exposure of these growth factors to blood vessels and lymphatic vessels leads to simultaneous stimulation of angiogenesis and lymphangiogenesis (Cao, 2005b). However, under certain circumstances, both FGF-2 and VEGF-A have been reported to specifically induce only lymphangiogenesis and not angiogenesis (Chang *et al*, 2004; Bjorndahl *et al*, 2005b). The molecular mechanism underlying the differential effects of the same factor is currently unknown.

Quantification of tumour lymphangiogenesis: prognostic/predictive value in oncology

In most cancers, lymph node (LN) metastasis is an important prognostic factor. However, LN status does not allow a solid prediction of prognosis for patients presenting with small tumours without LN involvement. Other reliable markers predictive of LN metastasis might improve prognostication and might be useful for therapeutic decision-making in these early cancers. Information about lymphatic invasion and the number of lymphatic vessels has been shown promising in this regard. In breast cancer, for example, the invasion of tumour cells into lymphatic vessels was shown to be predictive of LN involvement and a prognostic factor for overall and disease-free survival (Schoppmann *et al*, 2004; Lee *et al*, 2006). Indeed, peritumourous vascular invasion, especially lymphovascular invasion (LVI), has been included as a novel adverse prognostic factor in a series of guidelines and recommendations for postoperative adjuvant systemic therapies of early breast cancer developed by an International Consensus Panel during the St Gallen Conference, 2005 (Goldhirsch *et al*, 2005). The presence of peritumourous vascular invasion defined an intermediate risk for patients with node-negative breast disease, but its value in patients with node-positive breast disease was considered uncertain and insufficient at that time. Another clear example is early gastric cancer, in which the incidence of LN micrometastasis has been shown to be higher in patients with, than without LVI, indicating a close link between LVI and the initial stage of LN metastasis (Arigami *et al*, 2005). Lymphovascular invasion was found to be an adverse prognostic indicator in several studies of gastric cancer (Hyung *et al*, 2002; Kooby *et al*, 2003; Dicken *et al*, 2006). Other examples are node-negative bladder carcinoma (Lotan *et al*, 2005) and node-negative oesophageal carcinoma (Vazquez-Sequeiros *et al*, 2002) in which LVI was shown to be

correlated with outcome. These data suggest that LVI may provide useful information for prognosis and clinical management in those patients who present with early tumours without LN involvement.

A correlation of lymphatic vessel density (LVD) detected by immunohistochemistry with an unfavourable prognosis has been observed in breast cancer, head and neck cancer, melanoma, cervical cancer, non-small-cell lung cancer, bladder cancer, colorectal cancer and gastric cancer. However, for the amount of lymphatic vessels in a solid tumour to be a reliable marker of prognosis, the quantification technique has to be characterised by a low intra- and interobserver variability. Results obtained at different institutes should be comparable in order to allow meta-analyses. Recently, the Programme for the Assessment of Clinical Cancer Tests Strategy group and a working group of a NCI-EORTC collaboration have reported guidelines for tumour marker studies with the objectives of facilitating the evaluation of the appropriateness and quality of study design, methods, analyses, and improving the ability to compare results across studies (McShane *et al*, 2005). In Table 2 we listed prognostic studies showing an association of LVD with the survival of patients with cancer and indicated how well the REporting Recommendations for tumour MARKer (REMARK) were followed as a tool for the reader. This consensus report aims to lower the methodological variability of lymphangiogenesis quantification in tumour tissue sections, bearing the REMARK guidelines for prognostic studies in mind.

LYMPHATIC ENDOTHELIAL-SPECIFIC ANTIBODIES FOR IMMUNOHISTOCHEMISTRY

The selection of the optimal marker of the lymphatic endothelium is clearly a critical step in the assessment of LVD since false data arising from low specificity of the staining must be avoided. Major research efforts during these last years have led to the discovery of a large spectrum of candidate lymphatic markers (Figure 2). The following paragraphs focus on markers for which antibodies are available and provide a discussion on the specificity of each marker for LECs.

VEGFR-3

The vascular endothelial growth factor receptor 3 (VEGFR-3/Flt4) is a tyrosine kinase that is predominantly expressed in LECs in adult tissues (Kaipainen *et al*, 1995; Kukk *et al*, 1996). As VEGFR-3 expression has also been found in fenestrated capillaries of several organs including the bone marrow, splenic and hepatic sinusoids, kidney glomeruli and endocrine glands (Partanen *et al*, 1999) and in endothelial cells of the proliferating neovasculature in breast cancer (Valtola *et al*, 1999), this marker is not reliable for discriminating between lymphatic and blood vascular endothelium.

Desmoplakin

The glycoprotein desmoplakin locates exclusively to the intracellular junctions between the endothelial cells of lymphatic vessels (Schmelz and Franke, 1993). Antibodies against desmoplakin have indicated specificity for lymphatic endothelium in human tongue (Ebata *et al*, 2001) but further studies are required to confirm the distinctive nature of desmoplakin staining in other tissue types.

β -chemokine receptor D6

By using *in situ* binding assays it was shown that the β -chemokine receptor D6 is expressed on LECs in the skin (Hub and Rot, 1998). Monoclonal antibodies raised against the receptor specifically stained endothelial cells that were also stained with antipodoplanin antibodies (see below) and showed no immunoreactivity with

endothelial cells lining the blood vessels (Nibbs *et al*, 2001). D6-immunoreactive lymphatic vessels were also abundant in mucosa and submucosa of small and large intestine and appendix, but were not observed in heart, kidney, liver, skeletal muscle, brain, cerebellum, pancreas, prostate and thyroid. This demonstrates the emerging heterogeneity of lymphatic endothelium, and it may be necessary to use specific markers depending on which tissue is being investigated.

Prox-1

Another marker of the lymphatic endothelium is the homeodomain protein Prox-1, which is required for the regulation of lymphatic vascular development from pre-existing embryonic veins (Wigle and Oliver, 1999). Prox-1 expression has also been found in other cell types, including nonendothelial cells in the lens, heart, liver, pancreas and nervous system (Stacker *et al*, 2002). Antibodies against human Prox-1 to visualise lymphatic vessels in tumour sections have only been used in a limited number of studies (Agarwal *et al*, 2005; Van der Auwera *et al*, 2005). Although its nuclear localisation makes Prox-1 not the most ideal marker for quantifying lymphatic vessels microscopically, it could be a useful marker for double immunostaining with other markers such as podoplanin and LYVE-1.

LYVE-1

LYVE-1 is an integral membrane glycoprotein that functions as a receptor for hyaluronan (GlcNAc1-4GlcUAb1-3)_m, a ubiquitous extracellular matrix glycosaminoglycan involved in cell migration and differentiation. The expression of LYVE-1 in endothelial cells of lymphatic vessels and LN sinuses and its absence from blood vessel endothelium was first demonstrated by immunohistochemical staining with polyclonal antibodies generated against recombinant human and murine LYVE-1 Fc fusion protein which showed characteristic staining of lymphatic vascular structures in skin, intestine and secondary lymphoid tissue (Banerji *et al*, 1999; Prevo *et al*, 2001). During embryogenesis, LYVE-1 is expressed in cardinal vein endothelium, just before budding of the primordial lymph sacs (E12.5 in the mouse), almost simultaneous with the expression of the lymphogenic transcription factor Prox-1 (Wigle and Oliver, 1999); expression then persists into adulthood in most afferent vessels and lymphatic sinuses, but is absent from thoracic duct. LYVE-1 is also abundant in discontinuous endothelia including human and mouse liver sinusoids and human spleen sinusoids but is absent from the 'normal' haemovasculature. Extensive analyses in many different laboratories have confirmed these findings and demonstrated that LYVE-1 is a reliable marker for distinguishing lymphatic vessels from blood vessels in a range of different human cancers (e.g. head and neck squamous cell carcinoma (Beasley *et al*, 2002; Maula *et al*, 2003), cutaneous melanoma (Dadras *et al*, 2003; Straume *et al*, 2003) and carcinomas of the thyroid (Hall *et al*, 2003), lung (Koukourakis *et al*, 2005), pancreas (Von Marschall *et al*, 2005), breast (Williams *et al*, 2003; Bono *et al*, 2004), cervix (Van Trappen *et al*, 2003) and prostate (Trojan *et al*, 2004)), as well as normal tissues in both adult and foetus. Nevertheless, the observation that expression of LYVE-1 can be downmodulated in some tissues, for example, in response to inflammation (Johnson L and Jackson DG, unpublished), and is absent in some tumour-associated lymphatics (Rubbia-Brandt *et al*, 2004; Stessels *et al*, 2004; Van der Auwera *et al*, 2004) underlines the importance of utilising multiple markers (e.g. LYVE-1/podoplanin, LYVE-1/Prox-1, etc.) to characterise lymphatic vessels in comprehensive studies of lymphangiogenesis. Besides lymphatic and sinusoidal vessel endothelium, LYVE-1 is also expressed in some macrophage-like cells present in inflamed tissue and in tumour infiltrates. The special significance of these findings has been revealed in recent studies of lymphangiogenesis

Table 2 List of studies on the prognostic value of lymphangiogenesis in solid human tumours

Reporting recommendations for tumour marker prognostic studies	Audet et al (2005)	Birner et al (2001)	Bono et al (2004)	Chen et al (2004)	Dadras et al (2003)	Franchi et al (2004)	Gombos et al (2005)	Kato et al (2005)	Kyzas et al (2005)	Massi et al (2006)	Maula et al (2003)	Miyata et al (2006)	Naka-mura et al (2005)	Naka-mura et al (2006)	Omachi et al (2006)	Renyi-Vamos et al (2005)	Schopp-mann et al (2004)	Straume et al (2003)	No. of studies in which guidelines were used
1. State marker examined, study objectives and prespecified hypothesis	Green	Green	Green	Green	Green	Green	Green	Green	Green	Green	Green	Green	Green	Green	Green	Green	Green	Green	12
2. Give the patients' characteristics (source, inclusion and exclusion criteria)	Green	Green	Green	Green	Green	Green	Green	Green	Green	Green	Green	Green	Green	Green	Green	Green	Green	Green	8
3. Describe treatments received and how chosen	Green	Green	Green	Green	Green	Green	Green	Green	Green	Green	Green	Green	Green	Green	Green	Green	Green	Green	10
4. Give the type of biological material, methods of preservation and storage	Green	Green	Green	Green	Green	Green	Green	Green	Green	Green	Green	Green	Green	Green	Green	Green	Green	Green	10
5. Specify the assay method; provide a detailed protocol (quality control procedures, reproducibility assessment, quantitation methods, scoring and reporting protocols). Specify whether and how assays were performed blinded to the study end point	Green	Green	Green	Green	Green	Green	Green	Green	Green	Green	Green	Green	Green	Green	Green	Green	Green	Green	8
6. State the method of case selection (retrospective or prospective stratification or matching). Specify the time period from which cases were taken, the end of follow-up period and the median follow-up time	Green	Green	Green	Green	Green	Green	Green	Green	Green	Green	Green	Green	Green	Green	Green	Green	Green	Green	1
7. Precisely define all clinical end points examined	Green	Green	Green	Green	Green	Green	Green	Green	Green	Green	Green	Green	Green	Green	Green	Green	Green	Green	8
8. List all candidate variables examined or considered for inclusion in models	Green	Green	Green	Green	Green	Green	Green	Green	Green	Green	Green	Green	Green	Green	Green	Green	Green	Green	14
9. Give rationale for sample size; if the study was designed to detect a specified effect size, give the target power and effect size	Green	Green	Green	Green	Green	Green	Green	Green	Green	Green	Green	Green	Green	Green	Green	Green	Green	Green	0
10. Specify all statistical methods (details of any variable selection procedures and other model building issues, how model assumptions were verified and how missing data were handled)	Green	Green	Green	Green	Green	Green	Green	Green	Green	Green	Green	Green	Green	Green	Green	Green	Green	Green	0
11. Clarify how marker values were handled in the analyses, if relevant describe method used for cut point determination	Green	Green	Green	Green	Green	Green	Green	Green	Green	Green	Green	Green	Green	Green	Green	Green	Green	Green	17

Table 2 (Continued)

Reporting recommendations for tumour marker prognostic studies	Audet et al (2005)	Birner et al (2001)	Bono et al (2004)	Chen et al (2004)	Dadras et al (2003)	Franchi et al (2004)	Gombos et al (2005)	Kato et al (2005)	Kyzas et al (2005)	Massi et al (2006)	Maula et al (2003)	Miyata et al (2006)	Nakamura et al (2005)	Nakamura et al (2006)	Omachi et al (2006)	Renyi-Vamos et al (2005)	Schoppmann et al (2004)	Straume et al (2003)	No. of studies in which guidelines were used
12. Describe the flow of patients through the study (the number of patients included in each stage of the analysis and reasons for dropout)	Green	Green	Green	Green	Green	Green	Red	Green	Green	Green	Yellow	Green	Green	Green	Green	Green	Green	Green	15
13. Report distribution of demographic characteristics (age and sex), standard prognostic variables, tumour marker, number of missing values	Green	Red	Yellow	Green	Green	Green	Green	Green	Green	Green	Green	Green	Green	Green	Green	Green	Green	Green	14
14. Show the relation of the marker to standard prognostic variables	Green	Green	Green	Green	Green	Green	Green	Green	Green	Green	Green	Green	Green	Green	Green	Green	Green	Green	18
15. Present univariate analyses showing the relation between the marker and outcome, with the estimated effect (hazard ratio and survival probability)	Red	Green	Green	Green	Red	Red	Red	Red	Red	Red	Red	Red	Red	Red	Red	Red	Red	Red	9
16. For key multivariate analyses, report estimated effect with confidence intervals for the marker and all other variables in the model	Green	Yellow	Green	Green	Red	Red	Red	NA	Green	Green	Yellow	Green	Red	Green	NA	Green	Green	Green	8
17. Among reported results, provide estimated effects with confidence intervals from an analysis in which the marker and prognostic variables are included	Red	Green	Green	Green	Red	Red	Red	Red	Red	Red	Red	Red	Red	Red	Red	Red	Red	Red	10
18. If done, report results of further investigations, such as checking assumptions, sensitivity analyses and internal validation	NA	NA	NA	NA	NA	NA	NA	NA	NA	NA	NA	NA	NA	NA	NA	NA	NA	NA	5
19. Interpret the results in the context of prespecified hypotheses and other relevant studies; include a discussion of limitations of the study	Green	Yellow	Green	Green	Yellow	Yellow	Yellow	Yellow	Green	Yellow	Yellow	Yellow	Red	Green	Yellow	Red	Red	Yellow	5
20. Discuss implications for future research and clinical value	Green	Green	Green	Green	Green	Green	Red	Red	Green	Green	Green	Green	Green	Green	Green	Green	Green	Red	15
Score	12.5	14.5	15.5	15.5	12.0	10.0	11.5	9.0*	11.0	11.0	12.0	14.5	13.0	13.0	10.0*	14.0	12.5	14.0	

We indicated whether the REMARK guidelines did apply (green), did not apply (red) or did only partly apply (yellow) to the relevant study and subsequently a general score on how well the guidelines were followed was computed for each study (1, 0.5 or 0; maximum value of 19 or 17*).

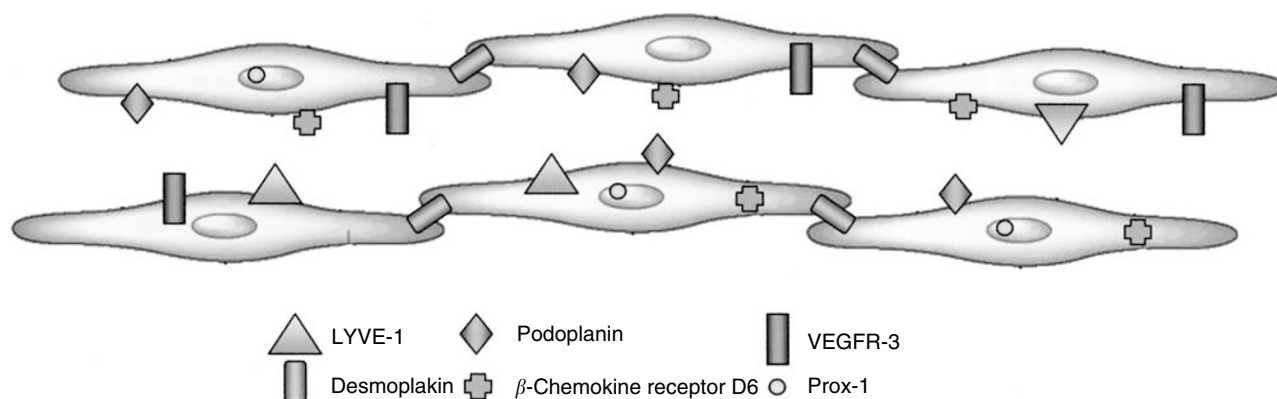


Figure 2 Representation of lymphangiogenic markers on lymphatic endothelial cells.

occurring during corneal neovascularisation (Maruyama *et al*, 2005) and in transplanted kidney rejection (Kerjaschki *et al*, 2006) where LYVE-1⁺/CD68⁺ cells were shown to be incorporated into newly dividing lymphatic vessels. These findings indicate the fascinating possibility that LYVE-1⁺ macrophage-like cells may represent bone marrow derived progenitors with the capacity to differentiate towards lymphatic vessel endothelium as well as regulators of VEGF-C induced lymphoproliferation (*vide infra*).

Podoplanin

Podoplanin is a ~38-kd surface glycoprotein that is expressed in osteoblastic cells, lung alveolar type I cells and kidney podocytes (Wetterwald *et al*, 1996; Breiteneder-Geleff *et al*, 1997). The specificity of podoplanin expression on lymphatic but not blood vascular endothelium has been demonstrated in the skin (Breiteneder-Geleff *et al*, 1999). However, podoplanin appears to be only present in small lymphatic vessels and not in larger ones that have smooth-muscle cells (Stacker *et al*, 2002). So far, there is no evidence of podoplanin expression in BVECs (Stacker *et al*, 2002), suggesting that it can be considered as a reliable marker of the lymphatic endothelium. Recently, it was indicated by Schacht *et al* (2005) that the commercially available monoclonal D2-40 antibody specifically recognises human podoplanin. The antibody has been shown to be a highly selective marker of lymphatic endothelium in sections of both frozen and formalin-fixed paraffin-embedded normal and neoplastic tissues (Kahn *et al*, 2002a) and has been proven valuable in detecting lymphatic invasion in various malignant neoplasms (Kahn and Marks, 2002b). In a direct comparison of the D2-40 antibody and an antibody against podoplanin on paraffin sections of a series of head and neck squamous cell carcinomas, both antibodies were shown to have extremely high specificity (99.7 and 98.8% for podoplanin and D2-40) and sensitivity (92.6 and 97.3% for podoplanin and D2-40) for lymphatic endothelium (Evangelou *et al*, 2005).

A comparative study of antibodies directed at LYVE-1, podoplanin, Prox-1 and the D2-40 antibody on serial sections of breast carcinomas indicated that significantly more intra-tumourous lymphatic vessels stained with D2-40 (Van der Auwera *et al*, 2005), thus demonstrating that this marker is highly sensitive for lymphatic endothelium. Besides being reactive with lymphatic vessels, D2-40-staining has also been observed in basal epithelial cell layers of the epidermis (Niakosari *et al*, 2005) and of human breast and prostate gland (Agarwal *et al*, 2005; Zeng *et al*, 2005).

Just as tumour vasculature has a markedly different phenotype from normal vessels, so it is highly likely that tumour lymphatic vessels will differ from normal and gene array studies on lymphatic endothelium isolated from tumours will be of major interest to help develop new markers relevant to tumour therapy and outcome. Fiedler *et al* (2006) very recently reported that the CD34 protein, a recognised vascular endothelial marker, is selectively expressed in tumour-associated LECs and not in resting organ LECs. The expression of CD34 by tumour-associated LECs was identified in colon cancer, breast cancer, lung cancer and melanoma. These findings underline the importance of CD34 as an activation antigen of human LECs and as a potential diagnostic and prognostic tumour marker.

METHODOLOGY OF LYMPHANGIOGENESIS QUANTIFICATION IN SOLID TUMOURS BY HISTOMORPHOMETRY

Lymphatic vessel density

By analogy with angiogenesis, tumour-associated LVD is most frequently assessed by counting the number of immunostained vessels in tumour sections, as defined by Weidner *et al* (1991) in 1991. Microvessel density (MVD) is determined in vascular 'hot spots' or areas giving the impression at low magnification of containing numerous microvessels. Vascular 'hot spots' are thought to represent localised areas of biological importance since they originate from tumour cell clones with the highest angiogenic potential which will predominantly enter the circulation and give rise to vascularised metastases. Localised changes in oxygen tension are indeed a strong angiogenic drive. The reproducibility of the assignment of these 'hot spots' is a critical variable in the analysis of MVD and the success of finding the relevant 'hot spot' depends on the training and experience of the investigator (Vermeulen *et al*, 2002). The methodology of counting the number of microvessel entities in regions with an elevated vascular density has been adapted for the assessment of LVD, although this is based on the assumption that a functional increase in lymphatic vessels occurs in 'hot spots'. Since data on the association of lymphangiogenesis with hypoxia are still contradictory, the relevance of counting lymphatic vessels in 'hot spots', as opposed to an overall lymphatic vessel count, has been questioned (Shields *et al*, 2004).

The number of lymphatic vessels in a microscopic field is the net result of previous phases of tumour lymphangiogenesis and of lymphatic vessel remodelling or regression, which implicates that the measurement of LVD is not necessarily a reflection of the ongoing tumour lymphangiogenesis. Nevertheless, several studies

in different cancer types have found a correlation of LVD with lymphangiogenic factor expression, and with the occurrence of lymphatic metastases and survival, suggesting that LVD contains important information on the degree of tumour lymphatic vasculature.

There is still a considerable debate about the role of intratumourous *vs* peritumourous lymphatic vessels in the pathology of primary human tumours. Several studies have shown that the density of lymphatic vessels located immediately adjacent to the tumour is associated with the presence of LN metastases (Dadras *et al*, 2003; Bono *et al*, 2004; Franchi *et al*, 2004; Gombos *et al*, 2005; Hachisuka *et al*, 2005; Kyzas *et al*, 2005; Mou *et al*, 2005; Renyi-Vamos *et al*, 2005; Zeng *et al*, 2005; Massi *et al*, 2006; Roma *et al*, 2006). Moreover, in a retrospective prognostic study, Dadras *et al* (2003) found that the size of peritumourous lymphatic vessels was the most significant independent factor that correlates with LN metastasis in human malignant melanomas. However, other studies show that intratumourous and not peritumourous lymphatic vessels are vital for lymphatic metastasis (Beasley *et al*, 2002; Hall *et al*, 2003; Maula *et al*, 2003; Audet *et al*, 2005; Kuroyama *et al*, 2005; Kyzas *et al*, 2005; Massi *et al*, 2006).

The infiltration of lymphatic vessels into the tumour may have a passive role in cancer metastasis by creating an increased opportunity for metastatic tumour cells to leave the primary tumour site but might also establish a paracrine signalling pathway for tumour cell growth and invasion through the release of specific growth factors or chemokines (Cassella and Skobe, 2002). Michaela Skobe *et al* have shown that lymphatic capillaries activated by factors produced by tumours, such as VEGF-C, promote tumour cell invasion by increasing tumour cell transendothelial migration through the expression of the CC-type chemokine ligand 1 on LECs and its receptor CC-type chemokine receptor 8 on tumour cells (Alitalo *et al*, 2004). Moreover, secondary lymphoid chemokine is constitutively produced by LECs in the skin (Saeki *et al*, 1999) and other organs (Gunn *et al*, 1998) and was found to attract dendritic cells to the lymphatic vessels by interaction with its primary receptor CCR7. This chemokine receptor is highly expressed in human breast cancer cells, malignant breast tumours and metastases, triggering actin polymerisation, pseudopodia formation, and the directional migration and invasion of these cells (Muller *et al*, 2001).

Chalkley counting

Although tumour-associated lymphangiogenesis has mainly been assessed by counting the number of immunostained lymphatic vessels, other techniques, such as Chalkley point overlap morphometry, are available. This method involves the use of an eyepiece graticule containing 25 randomly positioned dots, which is rotated so that the maximum number of points is on or within the vessels of the vascular 'hot spot'. Thus, instead of counting the individual microvessel, the overlaying dots are counted. Hall *et al* (2003) investigated the relationship between LVD, determined by Chalkley counting, and clinical and pathological variables in patients with well-differentiated papillary thyroid carcinoma. In a multivariate analysis, the Chalkley score was found to be significantly associated with the presence of nodal metastases at presentation. A similar association has also been shown in head and neck cancer (Audet *et al*, 2005).

The Chalkley count is a reflection of the relative area taken by the lymphatic vasculature and offers a suitable alternative for LVD assessment according to Weidner's guidelines. As no decisions have to be made on whether adjacent stained structures are separate microvessel or not, Chalkley point counting should be a more objective approach. The most observer-dependent step though still remains, that is, the selection of the vascular 'hot spot'.

Lymphatic endothelial cell proliferation (LECP)

LECP is measured by a double immunostaining of tumour sections with antibodies directed at a LEC marker (antipodoplanin or anti-LYVE-1) and a marker of proliferating cells (anti-Ki67 or anti-PCNA). Lymphatic vessels containing proliferating nuclei have been observed in breast cancer (Van der Auwera *et al*, 2005), endometrial cancer (Koukourakis *et al*, 2005), head and neck cancer (Beasley *et al*, 2002) and melanoma (Dadras *et al*, 2003; Straume *et al*, 2003). This suggests the presence of active intratumourous lymphangiogenesis, at least in some tumour types. In addition to the sprouting of lymphatic vessels, the enlargement of lymphatic vessels is also accompanied by the proliferation of LECs. It has been reported that both lymphangiogenesis and lymphatic hyperplasia play a role in tumour dissemination (Skobe *et al*, 2001; Stacker *et al*, 2001; He *et al*, 2005). In a VEGF-C overexpressing animal model, a tumour-induced increase in the diameter of collecting lymphatic vessels was associated with an enhanced passage of clusters of tumour cells to the sentinel LNs (He *et al*, 2005). Increased lymphatic vessel perimeters and areas were also found to be correlated with the occurrence of lymphatic metastasis in some human tumours (Nathanson *et al*, 1997; Dadras *et al*, 2003; Franchi *et al*, 2004; Van der Auwera *et al*, 2005; Liang *et al*, 2006; Massi *et al*, 2006).

Computerised image analysis systems

The major drawbacks of the visual MVD counting method are its inherent subjectivity and the difficulty of standardisation between laboratories. In contrast, image cytometry is more objective and reproducible and moreover, many image cytometry software packages allow additional information on vessel luminal area and vessel luminal perimeter. However, the widespread application of image cytometry is hampered by the need for specialised equipment to perform the analyses. Another limitation of this method is the possibility of confounding signals of nonendothelial structures in the stromal compartment. Choi *et al* (2005) performed a direct comparison of visual and image cytometric lymphatic vessel density counting on D2-40-immunostained sections of invasive breast carcinomas. They used an automated scanning microscope and an automated image analysis application that identified stained ring-like structures based on colour and morphometry in areas marked during direct microscopic microvessel counting. D2-40 microvessel densities determined by direct microscopy and image cytometry were significantly correlated. However, only the visual D2-40 data were associated with LN status and VEGF-family gene expression.

SURROGATE MARKERS OF TUMOUR-ASSOCIATED LYMPHANGIOGENESIS

Histopathological markers

Fibrotic focus Similar to angiogenesis, the fibrotic focus and the growth pattern might be considered as surrogate histopathological markers for tumour-associated lymphangiogenesis (Vermeulen *et al*, 2002). A fibrotic focus is defined as a fibrosclerotic scar-like area replacing necrosis in the centre of a carcinoma. The presence of a fibrotic focus in breast cancer is considered to be a surrogate marker of hypoxia-driven angiogenesis as it was shown to predict for higher MVD and for a higher fraction of proliferating endothelial cells (Jitsuiki *et al*, 1999; Colpaert *et al*, 2003a). Similarly, its presence in breast cancer is associated with a higher LECP but not with a higher LVD (Van der Auwera *et al*, 2005).

Tumour growth pattern It has been previously shown that different growth patterns in primary breast cancer reflect differences in angiogenesis. In the infiltrative growth pattern, the

carcinoma cells invade between pre-existing structures without a significant disturbance of the tissue architecture. Expansively growing breast tumours form a well-circumscribed nodule consisting of carcinoma cells and desmoplastic connective tissue. The endothelial cell proliferation fraction and the Chalkley count were highest in the expansive growth pattern (Colpaert *et al*, 2003b; Van den Eynden *et al*, 2005). Recently, it became clear that the growth pattern is also a histological surrogate marker of lymphangiogenesis (Van der Auwera *et al*, 2005). LECP, both in the tumour parenchyma and at the tumour periphery, was significantly higher in the expansive growth pattern compared with the infiltrative growth pattern. In addition, the intratumourous LVD was highest in the infiltrative growth pattern. An association between the growth pattern and the presence of lymphangiogenesis has also been observed in human non-small-cell lung cancer (Renyi-Vamos *et al*, 2005).

Tumour levels of lymphangiogenic growth factors The expression, in various human cancers, of lymphangiogenic factors such as VEGF-C and VEGF-D, is closely related to tumour-induced lymphatic dilatation or lymphangiogenesis (less frequent) and thereby to LN metastasis (Pepper *et al*, 2003a).

In breast cancer, increased expressions of VEGF-C and VEGF-D in the tumour cells, both on the mRNA and protein level, are known to be associated with high LVD, lymphatic invasion and LN metastasis (Nakamura *et al*, 2003; Choi *et al*, 2005; Nakamura *et al*, 2005; Huang *et al*, 2006; Li *et al*, 2006). Straume *et al* (2003) have compared LVD, evaluated by counting the number of LYVE-1-positive vessels in hot spots, with the protein expression of several (lymph)angiogenic growth factors in cutaneous melanoma specimens. Among the factors tested (VEGF-A, VEGF-C, VEGFR-1, VEGFR-2, VEGFR-3, FGF-2, ephrin-A1/2, interleukin-8 and thrombospondin-1), only the expression of FGF-2 was significantly associated with increased LVD. Furthermore, evidence for the existence of an association between VEGF-C or VEGF-D expressions and the number of tumour lymphatic vessels has also been provided for colorectal cancer (Ohno *et al*, 2003; Jia *et al*, 2004; Wang *et al*, 2005), gastric cancer (Yonemura *et al*, 2001; Onogawa *et al*, 2005; Shida *et al*, 2005; Juttner *et al*, 2006), thyroid cancer (Yasuoka *et al*, 2005), early-stage squamous cell cancer of the uterine cervix (Gombos *et al*, 2005) and pancreatic cancer (Sipos *et al*, 2004). In non-small-cell lung cancer, however, the existence of an association between VEGF-C expression and LVD remains contradictory (Lu *et al*, 2005; Renyi-Vamos *et al*, 2005; Takanami, 2006).

Other markers

The main disadvantage of the histological surrogate markers of lymphangiogenesis is the inherent interobserver variability. A more objective approach is the quantification of circulating levels of lymphangiogenic growth factors, such as VEGF-C and VEGF-D, and of circulating lymphatic endothelial progenitor cells.

Circulating levels of lymphangiogenic growth factors From a practical point of view, the detection of circulating levels of VEGF-C and VEGF-D protein/antigen in preoperative blood samples might be a useful indicator of advanced disease.

In some cancers, circulating lymphangiogenic factors are increased compared to healthy individuals or patients with benign tumours, for example, VEGF-C in lung non-small-cell carcinoma (Tamura and Ohta, 2003). However, in ovarian carcinoma, breast carcinoma, cervix adenocarcinoma and head and neck carcinoma this seems not to be the case (Table 3). Furthermore, in colorectal cancer, VEGF-C is increased in cancer patients but not VEGF-D (George *et al*, 2001; Duff *et al*, 2005). In lung non-small-cell carcinoma, cervical squamous cell carcinoma and colorectal cancer, a higher preoperative circulating VEGF-C level strongly correlated with LN metastasis and also lymphatic vessel invasion (the latter only in lung non-small-cell carcinoma). Concerning VEGF-D, plasma levels are increased in patients with angiosarcoma compared to healthy controls, and in one study on prostate carcinoma, a correlation between VEGF-D levels and LN metastasis was found (Kaushal *et al*, 2005).

The above results should be seen in context, since there are only a few studies on circulating VEGF-C and VEGF-D levels compared to the expression of their mRNA or protein levels in cancer.

Lymphatic endothelial progenitor cells (LEPCs) Bone marrow-derived circulating endothelial precursor cells contribute to newly blood vessel formation both under physiological and pathological conditions. The measurement of circulating endothelial cells in peripheral blood of patients with cancer has been integrated in clinical studies exploring the efficacy of antiangiogenic therapies. Evidence for the existence of LEPCs has only recently been found. Salven *et al* (2003) identified a subset of CD34+ cells that coexpress the stem/precursor cell marker CD133 and VEGFR-3. These cells are functionally nonadherent endothelial precursor cells that can differentiate into mature adherent VEGFR-3+ endothelial cells in the presence of vascular growth factors. In a corneal lymphangiogenesis model of irradiated mice reconstituted with donor BM cells, both CD34+ /VEGFR-2+ cells and CD34+ /

Table 3 Studies on circulating VEGF-C and VEGF-D levels in patients with cancer

Tumour	Markers (source)	Comments	Reference
Colorectal ca.	VEGF-C (plasma)	Increased in cancer patient compared to control	Duff <i>et al</i> (2003)
	VEGF-C (plasma)	Significantly higher in advanced Dukes C and D (LN+) compared to Dukes A and B (LN-)	
	VEGF-C (plasma)	Decreased expression in cancer patient compare to control	Duff <i>et al</i> (2005)
	VEGF-D (serum)	No difference between cancer and control	George <i>et al</i> (2001)
Non-small cell lung ca.	VEGF-D (plasma)	No difference between cancer and control	Duff <i>et al</i> (2005)
	VEGF-C (serum)	Increased in carcinoma compared to benign lesions and control individuals	Tamura and Ohta (2003)
Cervical ca.	VEGF-C (serum)	Correlation with pathologic stage, LN metastasis and lymphatic vessel invasion	Tamura <i>et al</i> (2004a,b)
	VEGF-C (serum)	Increased in squamous cervical cancer compared to controls	Mitsuhashi <i>et al</i> (2005)
	VEGF-C (serum)	Correlation with FIGO stage, tumour size and recurrence but not with LN metastasis	
Prostate ca.	VEGF-C (serum)	No increase in cervical adenocarcinoma compared to controls	Mathur <i>et al</i> (2005)
	VEGF-C (serum)	Increased in cervical cancer compared to controls	Kaushal <i>et al</i> (2005)
Angiosarcoma	VEGF-D (plasma)	Increased in early stage (LN neg) compare to late stage (LN or bone) metastasis	Amo <i>et al</i> (2004)
Ovarian ca.	VEGF-D (serum)	Increased compared to controls	Mathur <i>et al</i> (2005)
Breast ca.	VEGF-C (serum)	Not increased compared to controls	Hoar <i>et al</i> (2004)
Head and neck ca.	VEGF-D (plasma)	Not increased compared to controls	Strauss <i>et al</i> (2005)
	VEGF-C (plasma)	Not increased compared to controls	

VEGFR-3+ cells were found to be incorporated into the newly formed lymphatic vessels (Religa *et al*, 2005). A second population of candidate LECs has now been identified. A subpopulation of human circulating CD14+ monocytes was shown to also express VEGFR-3 on its surface and could be stimulated *in vitro* to express VEGF-C as well as the LEC marker podoplanin (Schoppmann *et al*, 2002; Kerjaschki *et al*, 2006). It was speculated that these cells participate in inflammation-associated *de novo* lymphangiogenesis in nephrectomy specimens of rejected kidney transplants (Kerjaschki *et al*, 2006). Maruyama *et al* (2005) have provided direct evidence of the incorporation of transdifferentiated monocytes-macrophages into growing lymphatic vessels. In a mouse corneal transplantation model, macrophages could transdifferentiate into LECs by forming cell aggregates and vesicles that integrate into an existing lymphatic vessel. Moreover, *in vitro* experiments demonstrated that CD11b+ macrophages were capable of forming tube-like structures that expressed markers of lymphatic endothelium such as LYVE-1 and podoplanin. These data indicate a novel role for macrophages in lymphangiogenesis. Gene expression profiling studies are necessary for characterisation of LECs in peripheral blood and will improve our understanding of lymphatic endothelial function in cancer.

RECOMMENDED METHODOLOGY

So far, studies on the importance of lymphangiogenesis for tumour growth have yielded inconsistent conclusions and this is mostly due to differences in the applied methodology and the lack of standardisation. In Table 4, a proposition for the standardisation of the immunohistochemical method for lymphangiogenesis assessment is given.

Methods of lymphangiogenesis quantification in solid tumours rely upon the use of markers that allow an accurate discrimination between lymphatic vessels and blood vessels in histological tissue sections. At present the most reliable marker is likely to be podoplanin, which is recognised by the monoclonal D2-40 antibody with a high specificity and sensitivity. Although LYVE-1 has been proven valuable for distinguishing between lymphatic vessels and blood vessels in histological tissue sections, it has been reported that LYVE-1 expression in tumour lymphatic vessels can be downmodulated, for example, in breast cancer (Stessels *et al*, 2004; Van der Auwera *et al*, 2004). None of the proposed markers fulfils the criteria of an ideal lymphatic vessel marker, which should be exclusively found on all types of LECs in all pathological conditions. Therefore, the use of multiple immunohistochemical stains on serial sections of random subgroups of cases is recommended to confirm the actual staining of lymphatic vessels. The best combination of markers of the lymphatic endothelium

could vary on the tissue type. As more insights on the molecular pathways of lymphatic differentiation emerge, novel potential markers of the lymphatic endothelium might be identified.

The quantification of LVD has been proven valuable for the risk assessment of regional LN involvement in patients with cancer. By using the Chalkley point overlap morphometric technique the observer-dependent step of measuring LVD can be abolished since the Chalkley count is a relative area estimate rather than a true vessel count. However, the method that most likely reflects the ongoing tumour lymphangiogenesis would be the analysis of proliferating LECs, which can be assessed by a double immunostain with podoplanin to stain lymphatic vessels, together with Ki-67 to stain proliferating cells.

As it seems that the patterns of lymphangiogenesis vary among malignancies lymphangiogenesis should be evaluated both intratumourous and at the tumour periphery.

SUMMARY AND FUTURE DIRECTIONS

For every major type of cancer LN involvement is strongly associated with poor survival and usually is one of the major factors associated with poor prognosis. Whether this is the mechanism for poor prognosis or a marker for aggressive underlying molecular pathway is difficult to determine clinically. The pathway of metastasis via lymphatic vessels, regional LNs and then into the systemic circulation is an accepted pathway of metastasis, although in recent years the emphasis has switched to the importance of angiogenesis and direct systemic spread. Nevertheless, it is not possible to quantify the relative contribution to spread currently between these different routes and the very strong association of LN involvement with outcome is a key factor in the staging of all cancers. Understanding such an important prognostic factor, the mechanisms regulating it and how it might be related to prognosis are important issues regardless of any possible therapeutic approach.

Understanding the mechanisms by which lymphangiogenesis occurs or tumour cells migrate to lymphatic vessels, or indeed understanding how new lymphatic vessels are generated from other cell types such as macrophages or circulating progenitor cells is all highly relevant to potential mechanisms of growth of metastases. VEGF-A-overexpressing primary tumours have been shown to induce sentinel LN lymphangiogenesis before metastasising (Hirakawa *et al*, 2005) and also in human cancer lymphangiogenesis appears to occur in secondary sites, for example, in LN metastases of breast cancer (Van den Eynden *et al*, 2006). This might suggest that primary tumours begin preparing their future metastatic site by inducing the growth of new lymphatic vessels.

Table 4 Proposed standard method for the assessment of lymphangiogenesis

Methodological aspect	Proposed standard	Advantage
1. Immunostaining	Double immunostain with the D2-40 monoclonal antibody and the anti-Ki-67 monoclonal antibody	Highly specific and sensitive marker of the lymphatic endothelium
2. Selection of the quantification fields	Manual vascular hot spot selection at low magnification (e.g. $\times 10$) – in viable tumour tissue and adjacent (e.g. within diameter of one field at $\times 200$ magnification) stromal tissue	All highly vascular areas can be detected
3. Quantification of lymphatic vessels	Chalkley point graticule method	Exclusion of the subjective step of identifying individual lymphatic vessels in an endothelial cell cluster
4. Quantification of LEC proliferation	Counting of the number of proliferating LECs vs nonproliferating LECs	Reflection of the ongoing lymphangiogenesis
5. Number of observers	Sequential assessment by two investigators	More practical in a clinical setting than co-observation

Lymphangiogenesis is a complex process that is regulated by multiple factors that are produced by various cell types. Some of the originally angiogenic signalling molecules, such as VEGF-A and FGF-2, have been implicated in the control of lymphatic vessel growth as well, indicating a close link between angiogenesis and lymphangiogenesis. Novel insights into the interrelationship between both processes will lead to a better understanding of the mechanisms of growth of metastases and will have important implications for cancer therapy. Many potent antiangiogenic compounds that can be used in anticancer therapy have been identified and are currently being investigated in clinical trials. It is not clear whether these antiangiogenic agents also affect lymphangiogenesis and hence, biopsy studies should also stain for effects on lymphatic vessels to dissect their possible role in response to therapy.

The search for specific lymphangiogenesis inhibitors has led to the identification of a number of potential antilymphangiogenic compounds that have been shown to suppress metastasis of tumours to regional LNs in experimental animal models. These include antibodies that either block the activity of the ligands

VEGF-C and VEGF-D directly by binding to the ligand or by preventing the interaction with VEGFR-3 and soluble dimeric fusion proteins containing the extracellular ligand binding site of VEGFR-3 (Banerji *et al*, 1999; Thiele and Sleeman, 2006). However, many questions concerning their potential therapeutic role in the management of human cancer are raised. Although the point could be made that when patients first present they already have lymphatic metastasis or not, and these will be treated surgically or with other means, it would be highly desirable to prevent metastasis in patients who are at increased risk of second primaries. A clear example is breast cancer with second cancers either in the treated breast or the opposite breast and reducing the incidence of new primaries, but also reducing the instance of secondary deposits from the new primaries is a key therapeutic aim.

Understanding the mechanisms of lymphangiogenesis could be helpful in the adjuvant situation of managing common cancers with treatment aimed at both stopping proliferation and recurrence of primary tumours and their regional metastases.

REFERENCES

- Achen MG, Jeltsch M, Kukk E, Makinen T, Vitali A, Wilks AF, Alitalo K, Stackner SA (1998) Vascular endothelial growth factor D (VEGF-D) is a ligand for the tyrosine kinases VEGF receptor 2 (Flk1) and VEGF receptor 3 (Flt4). *PNAS* **95**: 548–553
- Agarwal B, Saxena R, Morimiya A, Mehrotra S, Badve S (2005) Lymphangiogenesis does not occur in breast cancer. *Am J Surg Pathol* **29**: 1449–1455
- Alitalo K, Mohla S, Ruoslahti E (2004) Lymphangiogenesis and cancer: meeting report. *Cancer Res* **64**: 9225–9229
- Alitalo K, Tammela T, Petrova TV (2005) Lymphangiogenesis in development and human disease. *Nature* **438**: 946–953
- Amo Y, Masuzawa M, Hamada Y, Katsuoka K (2004) Serum concentrations of vascular endothelial growth factor-D in angiosarcoma patients. *Br J Dermatol* **150**: 160–161
- Arigami T, Natsugoe S, Uenosono Y, Arima H, Mataka Y, Ehi K, Yanagida S, Ishigami S, Hokita S, Aikou T (2005) Lymphatic invasion using D2–40 monoclonal antibody and its relationship to lymph node micrometastasis in pN0 gastric cancer. *Br J Cancer* **93**: 688–693
- Audet N, Beasley NJ, MacMillan C, Jackson DG, Gullane PJ, Kamel-Reid S (2005) Lymphatic vessel density, nodal metastases, and prognosis in patients with head and neck cancer. *Arch Otolaryngol Head Neck Surg* **131**: 1065–1070
- Banerji S, Ni J, Wang SX, Clasper S, Su J, Tammi R, Jones M, Jackson DG (1999) LYVE-1, a new homologue of the CD44 glycoprotein, is a lymph-specific receptor for hyaluronan. *J Cell Biol* **144**: 789–801
- Beasley NJP, Prevo R, Banerji S, Leek RD, Moore J, van Trappen P, Cox G, Harris AL, Jackson DG (2002) Intratumoral lymphangiogenesis and lymph node metastasis in head and neck cancer. *Cancer Res* **62**: 1315–1320
- Birner P, Schindl M, Obermair A, Breitenacker G, Kowalski H, Oberhuber G (2001) Lymphatic microvessel density as a novel prognostic factor in early-stage invasive cervical cancer. *Int J Cancer* **95**: 29–33
- Bjorndahl M, Cao R, Nissen LJ, Clasper S, Johnson LA, Xue Y, Zhou Z, Jackson D, Jon Hansen A, Cao Y (2005a) Insulin-like growth factors 1 and 2 induce lymphangiogenesis *in vivo*. *PNAS* **102**: 15593–15598
- Bjorndahl MA, Cao R, Burton JB, Brakenhielm E, Religa P, Galter D, Wu L, Cao Y (2005b) Vascular endothelial growth factor-A promotes peritumoral lymphangiogenesis and lymphatic metastasis. *Cancer Res* **65**: 9261–9268
- Bono P, Wasenius VM, Heikkila P, Lundin J, Jackson DG, Joensuu H (2004) High LYVE-1-positive lymphatic vessel numbers are associated with poor outcome in breast cancer. *Clin Cancer Res* **10**: 7144–7149
- Breiteneder-Geleff S, Matsui K, Soleiman A, Meraner P, Poczewski H, Kalt R, Schaffner G, Kerjaschki D (1997) Podoplanin, novel 43-kd membrane protein of glomerular epithelial cells, is down-regulated in puromycin nephrosis. *Am J Pathol* **151**: 1141–1152
- Breiteneder-Geleff S, Soleiman A, Kowalski H, Horvat R, Amann G, Kriehuber E, Diem K, Weninger W, Tschachler E, Alitalo K, Kerjaschki D (1999) Angiosarcomas express mixed endothelial phenotypes of blood and lymphatic capillaries: podoplanin as a specific marker for lymphatic endothelium. *Am J Pathol* **154**: 385–394
- Cao R, Bjorndahl MA, Gallego MI, Chen S, Religa P, Hansen AJ, Cao Y (2006) Hepatocyte growth factor is a novel lymphangiogenic factor with an indirect mechanism of action. *Blood* **107**: 3531–3536
- Cao R, Bjorndahl MA, Religa P, Clasper S, Garvin S, Galter D, Meister B, Ikomi F, Tritsarlis K, Dissing S, Ohhashi T, Jackson DG, Cao Y (2004) PDGF-BB induces intratumoral lymphangiogenesis and promotes lymphatic metastasis. *Cancer Cell* **6**: 333–345
- Cao Y (2005a) Direct role of PDGF-BB in lymphangiogenesis and lymphatic metastasis. *Cell Cycle* **4**: 228–230
- Cao Y (2005b) Opinion: emerging mechanisms of tumour lymphangiogenesis and lymphatic metastasis. *Nat Rev Cancer* **5**: 735–743
- Cassella M, Skobe M (2002) Lymphatic vessel activation in cancer. *Ann NY Acad Sci* **979**: 120–130
- Chang LK, Garcia-Cardena G, Farnebo F, Fannon M, Chen EJ, Butterfield C, Moses MA, Mulligan RC, Folkman J, Kaipainen A (2004) Dose-dependent response of FGF-2 for lymphangiogenesis. *Proc Natl Acad Sci U S A* **101**: 11658–11663
- Chen F, Takenaka K, Ogawa E, Yanagihara K, Otake Y, Wada H, Tanaka F (2004) Flt-4-positive endothelial cell density and its clinical significance in non-small cell lung cancer. *Clin Cancer Res* **10**: 8548–8553
- Choi WW, Lewis MM, Lawson D, Yin-Goen Q, Birdsong GG, Cotsonis GA, Cohen C, Young AN (2005) Angiogenic and lymphangiogenic microvessel density in breast carcinoma: correlation with clinicopathologic parameters and VEGF-family gene expression. *Mod Pathol* **18**: 143–152
- Colpaert CG, Vermeulen PB, Fox SB, Harris AL, Dirix LY, van Marck EA (2003a) The presence of a fibrotic focus in invasive breast carcinoma correlates with the expression of carbonic anhydrase IX and is a marker of hypoxia and poor prognosis. *Breast Cancer Res Treat* **81**: 137–147
- Colpaert CG, Vermeulen PB, Van Beest P, Soubry A, Goovaerts G, Dirix LY, Harris AL, van Marck EA (2003b) Cutaneous breast cancer deposits show distinct growth patterns with different degrees of angiogenesis, hypoxia and fibrin deposition. *Histopathology* **42**: 530–540
- Cursiefen C, Chen L, Borges LP, Jackson D, Cao J, Radziejewski C, D'Amore PA, Dana MR, Wiegand SJ, Streilein JW (2004) VEGF-A stimulates lymphangiogenesis and hemangiogenesis in inflammatory neovascularization via macrophage recruitment. *J Clin Invest* **113**: 1040–1050
- Dadras SS, Paul T, Bertocini J, Brown LF, Muzikansky A, Jackson DG, Ellwanger U, Garbe C, Mihm MC, Detmar M (2003) Tumor lymphangiogenesis: a novel prognostic indicator for cutaneous melanoma metastasis and survival. *Am J Pathol* **162**: 1951–1960
- Di Nucci A, Marchetti C, Serafini S, Piovella F (1996) P-selectin and von Willebrand factor in bovine mesenteric lymphatics: an immunofluorescent study. *Lymphology* **29**: 25–28
- Dicken BJ, Graham K, Hamilton SM, Andrews S, Lai R, Listgarten J, Jhangri GS, Saunders LD, Damaraju S, Cass C (2006) Lymphovascular invasion is associated with poor survival in gastric cancer: an application of gene-expression and tissue array techniques. *Ann Surg* **243**: 64–73

- Duff SE, Li C, Renehan A, O'Dwyer ST, Kumar S (2003) Immunodetection and molecular forms of plasma vascular endothelial growth factor-C. *Int J Oncol* **22**: 339–343
- Duff SE, Saunders M, McCredie V, Kumar S, O'Dwyer ST, Jayson GC (2005) Pre-operative plasma levels of vascular endothelial growth factor A, C and D in patients with colorectal cancer. *Clin Oncol (R Coll Radiol)* **17**: 367–371
- Ebata N, Nodasaka Y, Sawa Y, Yamaoka Y, Makino S, Totsuka Y, Yoshida S (2001) Desmoplakin as a specific marker of lymphatic vessels. *Microvasc Res* **61**: 40–48
- Evangeliou E, Kyzas PA, Trikalinos TA (2005) Comparison of the diagnostic accuracy of lymphatic endothelium markers: Bayesian approach. *Mod Pathol* **18**: 1490–1497
- Fiedler U, Christian S, Koidl S, Kerjaschki D, Emmett MS, Bates DO, Christofori G, Augustin HG (2006) The Sialomucin CD34 is a marker of lymphatic endothelial cells in human tumors. *Am J Pathol* **168**: 1045–1053
- Franchi A, Gallo O, Massi D, Baroni G, Santucci M (2004) Tumor lymphangiogenesis in head and neck squamous cell carcinoma: a morphometric study with clinical correlations. *Cancer* **101**: 973–978
- Gale NW, Thurston G, Hackett SF, Renard R, Wang Q, McClain J, Martin C, Witte C, Witte MH, Jackson D, Suri C, Campochiaro PA, Wiegand SJ, Yancopoulos GD (2002) Angiopoietin-2 is required for postnatal angiogenesis and lymphatic patterning, and only the latter role is rescued by Angiopoietin-1. *Dev Cell* **3**: 411–423
- Garrafa E, Alessandri G, Benetti A, Turetta G, Corradi A, Cantoni AM, Cervi E, Bonardelli S, Parati E, Giuliani SM, Ensoli B, Caruso A (2006) Isolation and characterization of lymphatic microvascular endothelial cells from human tonsils. *J Cell Physiol* **207**: 107–113
- George ML, Tutton MG, Janssen F, Arnaout A, Abulafi AM, Eccles SA, Swift RI (2001) VEGF-A, VEGF-C, and VEGF-D in colorectal cancer progression. *Neoplasia* **3**: 420–427
- Goldhirsch A, Glick JH, Gelber RD, Coates AS, Thurlimann B, Senn HJ, Panel members (2005) Meeting Highlights: INTERNATIONAL Expert Consensus on the Primary Therapy of Early Breast Cancer 2005. *Ann Oncol* **16**: 1569–1583
- Gombos Z, Xu X, Chu CS, Zhang PJ, Acs G (2005) Peritumoral lymphatic vessel density and vascular endothelial growth factor C expression in early-stage squamous cell carcinoma of the uterine cervix. *Clin Cancer Res* **11**: 8364–8371
- Gunn MD, Tangemann K, Tam C, Cyster JG, Rosen SD, Williams LT (1998) A chemokine expressed in lymphoid high endothelial venules promotes the adhesion and chemotaxis of naive T lymphocytes. *PNAS* **95**: 258–263
- Hachisuka T, Narikiyo M, Yamada Y, Ishikawa H, Ueno M, Uchida H, Yoriki R, Ohigashi Y, Milki K, Tamaki H, Mizuno T, Nakajima Y (2005) High lymphatic vessel density correlates with overexpression of VEGF-C in gastric cancer. *Oncol Rep* **13**: 733–737
- Hall FT, Freeman JL, Asa SL, Jackson DG, Beasley NJ (2003) Intratumoral lymphatics and lymph node metastases in papillary thyroid carcinoma. *Arch Otolaryngol Head Neck Surg* **129**: 716–719
- He Y, Rajantie I, Pajusola K, Jeltsch M, Holopainen T, Yla-Herttuala S, Harding T, Jooss K, Takahashi T, Alitalo K (2005) Vascular endothelial cell growth factor receptor 3-mediated activation of lymphatic endothelium is crucial for tumor cell entry and spread via lymphatic vessels. *Cancer Res* **65**: 4739–4746
- Hirakawa S, Hong YK, Harvey N, Schacht V, Matsuda K, Libermann T, Detmar M (2003) Identification of vascular lineage-specific genes by transcriptional profiling of isolated blood vascular and lymphatic endothelial cells. *Am J Pathol* **162**: 575–586
- Hirakawa S, Kodama S, Kunstfeld R, Kajiya K, Brown LF, Detmar M (2005) VEGF-A induces tumor and sentinel lymph node lymphangiogenesis and promotes lymphatic metastasis. *J Exp Med* **201**: 1089–1099
- Hoar FJ, Lip GY, Belgore F, Stonelake PS (2004) Circulating levels of VEGF-A, VEGF-D and soluble VEGF-A receptor (sFlt-1) in human breast cancer. *Int J Biol Markers* **19**: 229–235
- Hong YK, Lange-Asschenfeldt B, Velasco P, Hirakawa S, Kunstfeld R, Brown LF, Bohlen P, Senger DR, Detmar M (2004) VEGF-A promotes tissue repair-associated lymphatic vessel formation via VEGFR-2 and the alpha1beta1 and alpha2beta1 integrins. *FASEB J* **18**: 1111–1113
- Huang JH, Li Y, Liu L, Yang HC, Hai J, Tang LL, Hu TH (2006) Lymphangiogenesis and location of tumor lymphatic vessels induced by VEGF-C in primary breast cancer. *Zhong Nan Da Xue Xue Bao Yi Xue Ban* **31**: 36–39, 51
- Hub E, Rot A (1998) Binding of RANTES, MCP-1, MCP-3, and MIP-1alpha to cells in human skin. *Am J Pathol* **152**: 749–757
- Hyung WJ, Lee JH, Choi SH, Min JS, Noh SH (2002) Prognostic impact of lymphatic and/or blood vessel invasion in patients with node-negative advanced gastric cancer. *Ann Surg Oncol* **9**: 562–567
- Jia YT, Li ZX, He YT, Liang W, Yang HC, Ma HJ (2004) Expression of vascular endothelial growth factor-C and the relationship between lymphangiogenesis and lymphatic metastasis in colorectal cancer. *World J Gastroenterol* **10**: 3261–3263
- Jiang WG, Davies G, Martin TA, Parr C, Watkins G, Mansel RE, Mason MD (2005) The potential lymphangiogenic effects of hepatocyte growth factor/scatter factor *in vitro* and *in vivo*. *Int J Mol Med* **16**: 723–728
- Jitsuiki Y, Hasebe T, Tsuda H, Imoto S, Tsubono Y, Sasaki S, Mukai K (1999) Optimizing microvessel counts according to tumor zone in invasive ductal carcinoma of the breast. *Mod Pathol* **12**: 492–498
- Juttner S, Wissmann C, Jons T, Vieth M, Hertel J, Gretschel S, Schlag PM, Kemmner W, Hocker M (2006) Vascular endothelial growth factor-D and its receptor VEGFR-3: two novel independent prognostic markers in gastric adenocarcinoma. *J Clin Oncol* **24**: 228–240
- Kahn HJ, Bailey D, Marks A (2002a) Monoclonal antibody D2–40, a new marker of lymphatic endothelium, reacts with Kaposi's sarcoma and a subset of angiosarcomas. *Mod Pathol* **15**: 434–440
- Kahn HJ, Marks A (2002b) A new monoclonal antibody, D2–40, for detection of lymphatic invasion in primary tumors. *Lab Invest* **82**: 1255–1257
- Kaipainen A, Korhonen J, Mustonen T, van Hinsbergh VWM, Fang G, Dumont D, Breitman M, Alitalo K (1995) Expression of the Fms-like tyrosine kinase 4 gene becomes restricted to lymphatic endothelium during development. *PNAS* **92**: 3566–3570
- Kajiya K, Hirakawa S, Ma B, Drinnenberg I, Detmar M (2005) Hepatocyte growth factor promotes lymphatic vessel formation and function. *EMBO J* **24**: 2885–2895
- Karkkainen MJ, Ferrell RE, Lawrence EC, Kimak MA, Levinson KL, McTigue MA, Alitalo K, Finegold DN (2000) Missense mutations interfere with VEGFR-3 signalling in primary lymphoedema. *Nat Genet* **25**: 153–159
- Karkkainen MJ, Haiko P, Sainio K, Partanen J, Taipale J, Petrova TV, Jeltsch M, Jackson DG, Talikka M, Rauvala H, Betscholtz C, Alitalo K (2004) Vascular endothelial growth factor C is required for sprouting of the first lymphatic vessels from embryonic veins. *Nat Immunol* **5**: 74–80
- Karpanen T, Egeblad M, Karkkainen MJ, Kubo H, Yla-Herttuala S, Jaattela M, Alitalo K (2001) Vascular endothelial growth factor C promotes tumor lymphangiogenesis and intralymphatic tumor growth. *Cancer Res* **61**: 1786–1790
- Kato T, Prevo R, Steers G, Roberts H, Leek RD, Kimura T, Kameoka S, Nishikawa T, Kobayashi M, Jackson DG, Harris AL, Gatter KC, Pezzella F (2005) A quantitative analysis of lymphatic vessels in human breast cancer, based on LYVE-1 immunoreactivity. *Br J Cancer* **93**: 1168–1174
- Kaushal V, Mukunyadzi P, Dennis RA, Siegel ER, Johnson DE, Kohli M (2005) Stage-specific characterization of the vascular endothelial growth factor axis in prostate cancer: expression of lymphangiogenic markers is associated with advanced-stage disease. *Clin Cancer Res* **11**: 584–593
- Kerjaschki D, Huttary N, Raab I, Regele H, Bojarski-Nagy K, Bartel G, Krober SM, Greinix H, Rosenmaier A, Karhofer F, Wick N, Mazal PR (2006) Lymphatic endothelial progenitor cells contribute to *de novo* lymphangiogenesis in human renal transplants. *Nat Med* **12**: 230–234
- Kooby DA, Suriawinata A, Klimstra DS, Brennan MF, Karpeh MS (2003) Biologic predictors of survival in node-negative gastric cancer. *Ann Surg* **237**: 828–835
- Koukourakis MI, Giatromanolaki A, Sivridis E, Simopoulos C, Gatter KC, Harris AL, Jackson DG (2005) LYVE-1 immunohistochemical assessment of lymphangiogenesis in endometrial and lung cancer. *J Clin Pathol* **58**: 202–206
- Kubo H, Cao R, Brakenhielm E, Mäkinen T, Cao Y, Alitalo K (2002) Blockade of vascular endothelial growth factor receptor-3 signaling inhibits fibroblast growth factor-2-induced lymphangiogenesis in mouse cornea. *PNAS* **99**: 8868–8873
- Kukk E, Lymboussaki A, Taira S, Kaipainen A, Jeltsch M, Joukov V, Alitalo K (1996) VEGF-C receptor binding and pattern of expression with VEGFR-3 suggests a role in lymphatic vascular development. *Development* **122**: 3829–3837
- Kuroyama S, Kobayashi N, Ohbu M, Ohtani Y, Okayasu I, Kakita A (2005) Enzyme histochemical analysis of lymphatic vessels in colon carcinoma: occurrence of lymphangiogenesis within the tumor. *Hepatogastroenterology* **52**: 1057–1061
- Kyzas PA, Geleff S, Batistatou A, Agnantis NJ, Stefanou D (2005) Evidence for lymphangiogenesis and its prognostic implications in head and neck squamous cell carcinoma. *J Pathol* **206**: 170–177

- Leak LV (1976) The structure of lymphatic capillaries in lymph formation. *Fed Proc* 35: 1863–1871
- Leak LV, Burke JF (1968) Ultrastructural studies on the lymphatic anchoring filaments. *J Cell Biol* 36: 129–149
- Lee AH, Pinder SE, Macmillan RD, Mitchell M, Ellis IO, Elston CW, Blamey RW (2006) Prognostic value of lymphovascular invasion in women with lymph node negative invasive breast carcinoma. *Eur J Cancer* 42: 357–362
- Li YS, Kaneko M, Amatya VJ, Takeshima Y, Arihiro K, Inai K (2006) Expression of vascular endothelial growth factor-C and its receptor in invasive micropapillary carcinoma of the breast. *Pathol Int* 56: 256–261
- Liang P, Hong JW, Ubukata H, Liu HR, Watanabe Y, Katano M, Motohashi G, Kasuga T, Nakada I, Tabuchi T (2006) Increased density and diameter of lymphatic microvessels correlate with lymph node metastasis in early stage invasive colorectal carcinoma. *Virchows Arch* 448(5): 570–575
- Lotan Y, Gupta A, Shariat SF, Palapattu GS, Vazina A, Karakiewicz PI, Bastian PJ, Rogers CG, Amiel G, Perotte P, Schoenberg MP, Lerner SP, Sagalowsky AI (2005) Lymphovascular invasion is independently associated with overall survival, cause-specific survival, and local and distant recurrence in Patients with negative lymph nodes at radical cystectomy. *J Clin Oncol* 23: 6533–6539
- Lu ZQ, Li HG, Xie DR, Zhang HZ, Shen XM, Zeng YJ, Zeng H (2005) Expression and clinical significance of vascular endothelial growth factor C and vascular endothelial growth factor receptor 3 in non-small cell lung carcinoma. *Ai Zheng* 24: 1132–1135
- Mäkinen T, Veikkola T, Mustjoki S, Karpanen T, Catimel B, Nice EC, Wise L, Mercer A, Kowalski H, Kerjaschki D, Stacker SA, Achen MG, Alitalo K (2001) Isolated lymphatic endothelial cells transduce growth, survival and migratory signals via the VEGF-C/D receptor VEGFR-3. *EMBO J* 20: 4762–4773
- Marchetti C (1996) Weibel-Palade bodies and lymphatic endothelium: observations in the lymphatic vessels of normal and inflamed human dental pulps. *Vasa* 25: 337–340
- Maruyama K, Ii M, Cursiefen C, Jackson DG, Keino H, Tomita M, Van Rooijen N, Takenaka H, D'Amore PA, Stein-Streilein J, Losordo DW, Streilein JW (2005) Inflammation-induced lymphangiogenesis in the cornea arises from CD11b-positive macrophages. *J Clin Invest* 115: 2363–2372
- Massi D, Puig S, Franchi A, Malvey J, Vidal-Sicart S, Gonzalez-Cao M, Baroni G, Ketabchi S, Palou J, Santucci M (2006) Tumour lymphangiogenesis is a possible predictor of sentinel lymph node status in cutaneous melanoma: a case–control study. *J Clin Pathol* 59: 166–173
- Mathur SP, Mathur RS, Gray EA, Lane D, Underwood PG, Kohler M, Creasman WT (2005) Serum vascular endothelial growth factor C (VEGF-C) as a specific biomarker for advanced cervical cancer: Relationship to insulin-like growth factor II (IGF-II), IGF binding protein 3 (IGF-BP3) and VEGF-B. *Gynecol Oncol* 98: 467–483
- Maula SM, Luukka M, Grenman R, Jackson D, Jalkanen S, Ristamaki R (2003) Intratumoral lymphatics are essential for the metastatic spread and prognosis in squamous cell carcinomas of the head and neck region. *Cancer Res* 63: 1920–1926
- McShane LM, Altman DG, Sauerbrei W, Taube SE, Gion M, Clark GM (2005) Reporting recommendations for tumor MARKer prognostic studies (REMARK). *Nat Clin Pract Urol* 2: 416–422
- Mitsuhashi A, Suzuka K, Yamazawa K, Matsui H, Seki K, Sekiya S (2005) Serum vascular endothelial growth factor (VEGF) and VEGF-C levels as tumor markers in patients with cervical carcinoma. *Cancer* 103: 724–730
- Miyata Y, Kanda S, Ohba K, Nomata K, Hayashida Y, Eguchi J, Hayashi T, Kanetake H (2006) Lymphangiogenesis and angiogenesis in bladder cancer: prognostic implications and regulation by vascular endothelial growth factors-A, -C, and -D. *Clin Cancer Res* 12: 800–806
- Morisada T, Oike Y, Yamada Y, Urano T, Akao M, Kubota Y, Maekawa H, Kimura Y, Ohmura M, Miyamoto T, Nozawa S, Koh GY, Alitalo K, Suda T (2005) Angiopoietin-1 promotes LYVE-1-positive lymphatic vessel formation. *Blood* 105: 4649–4656
- Mou JH, Yan XC, Li ZP, Wang D, Duan GJ, Xiang DB, Xiao HL, Zhang QH (2005) Characteristic and clinicopathologic significance of lymphangiogenesis in colorectal cancer. *Zhonghua Bing Li Xue Za Zhi* 34: 348–352
- Muller A, Homey B, Soto H, Ge N, Catron D, Buchanan ME, McClanahan T, Murphy E, Yuan W, Wagner SN, Barrera JL, Mohar A, Verastegui E, Zlotnik A (2001) Involvement of chemokine receptors in breast cancer metastasis. *Nature* 410: 50–56
- Nakamura Y, Yasuoka H, Tsujimoto M, Imabun S, Nakahara M, Nakao K, Nakamura M, Mori I, Kakudo K (2005) Lymph vessel density correlates with nodal status, VEGF-C expression, and prognosis in breast cancer. *Breast Cancer Res Treat* 91: 125–132
- Nakamura Y, Yasuoka H, Tsujimoto M, Kurozumi K, Nakahara M, Nakao K, Kakudo K (2006) Importance of lymph vessels in gastric cancer: a prognostic indicator in general and a predictor for lymph node metastasis in early stage cancer. *J Clin Pathol* 59: 77–82
- Nakamura Y, Yasuoka H, Tsujimoto M, Yang Q, Imabun S, Nakahara M, Nakao K, Nakamura M, Mori I, Kakudo K (2003) Flt-4-positive vessel density correlates with vascular endothelial growth factor-D expression, nodal status, and prognosis in breast cancer. *Clin Cancer Res* 9: 5313–5317
- Nathanson SD, Anaya P, Avery M, Hetzel FW, Sarantou T, Havstad S (1997) Sentinel lymph node metastasis in experimental melanoma: relationships among primary tumor size, lymphatic vessel diameter and ^{99m}Tc-labeled human serum albumin clearance. *Ann Surg Oncol* 4: 161–168
- Niakosari F, Kahn HJ, Marks A, From L (2005) Detection of lymphatic invasion in primary melanoma with monoclonal antibody D2–40: a new selective immunohistochemical marker of lymphatic endothelium. *Arch Dermatol* 141: 440–444
- Nibbs RJB, Kriehuber E, Ponath PD, Parent D, Qin S, Campbell JDM, Henderson A, Kerjaschki D, Maurer D, Graham GJ, Rot A (2001) The {beta}-chemokine receptor D6 is expressed by lymphatic endothelium and a subset of vascular tumors. *Am J Pathol* 158: 867–877
- Oh SJ, Jeltsch MM, Birkenhager R, McCarthy JE, Weich HA, Christ B, Alitalo K, Wiltig J (1997) VEGF and VEGF-C: specific induction of angiogenesis and lymphangiogenesis in the differentiated avian chorio-allantoic membrane. *Dev Biol* 188: 96–109
- Ohno M, Nakamura T, Kunimoto Y, Nishimura K, Chung-Kang C, Kuroda Y (2003) Lymphangiogenesis correlates with expression of vascular endothelial growth factor-C in colorectal cancer. *Oncol Rep* 10: 939–943
- Omachi T, Kawai Y, Mizuno R, Nomiyama T, Miyagawa S, Ohhashi T, Nakayama J (2006) Immunohistochemical demonstration of proliferating lymphatic vessels in colorectal carcinoma and its clinicopathological significance. *Cancer Lett* (in press)
- Onogawa S, Kitadai Y, Amioka T, Kodama M, Cho S, Kuroda T, Ochiuni T, Kimura S, Kuwai T, Tanaka S, Chayama K (2005) Expression of vascular endothelial growth factor (VEGF)-C and VEGF-D in early gastric carcinoma: correlation with clinicopathological parameters. *Cancer Lett* 226: 85–90
- Partanen TA, Alitalo K, Miettinen M (1999) Lack of lymphatic vascular specificity of vascular endothelial growth factor receptor 3 in 185 vascular tumors. *Cancer* 86: 2406–2412
- Pepper MS, Skobe M (2003b) Lymphatic endothelium: morphological, molecular and functional properties. *J Cell Biol* 163: 209–213
- Pepper MS, Tille JC, Nisato R, Skobe M (2003a) Lymphangiogenesis and tumor metastasis. *Cell Tissue Res* 314: 167–177
- Petrova TV, Makinen T, Makela TP, Saarela J, Virtanen I, Ferrell RE, Finegold DN, Kerjaschki D, Yla-Herttuala S, Alitalo K (2002) Lymphatic endothelial reprogramming of vascular endothelial cells by the Prox-1 homeobox transcription factor. *EMBO J* 21: 4593–4599
- Podgrabska S, Braun P, Velasco P, Kloos B, Pepper MS, Jackson DG, Skobe M (2002) Molecular characterization of lymphatic endothelial cells. *PNAS* 99: 16069–16074
- Prevo R, Banerji S, Ferguson DJP, Clasper S, Jackson DG (2001) Mouse LYVE-1 is an endocytic receptor for hyaluronan in lymphatic endothelium. *J Biol Chem* 276: 19420–19430
- Religa P, Cao R, Björndahl M, Zhou Z, Zhu Z, Cao Y (2005) Presence of bone marrow-derived circulating progenitor endothelial cells in the newly formed lymphatic vessels. *Blood* 106: 4184–4190
- Renyi-Vamos F, Tovari J, Fillinger J, Timar J, Paku S, Kenessey I, Ostoros G, Agocs L, Soltesz I, Dome B (2005) Lymphangiogenesis correlates with lymph node metastasis, prognosis, and angiogenic phenotype in human non-small cell lung cancer. *Clin Cancer Res* 11: 7344–7353
- Roma AA, Magi-Galluzzi C, Kral MA, Jin TT, Klein EA, Zhou M (2006) Peritumoral lymphatic invasion is associated with regional lymph node metastases in prostate adenocarcinoma. *Mod Pathol* 19: 392–398
- Rubbia-Brandt L, Terris B, Giostra E, Dousset B, Morel P, Pepper MS (2004) Lymphatic vessel density and vascular endothelial growth factor-C expression correlate with malignant behavior in human pancreatic endocrine tumors. *Clin Cancer Res* 10: 6919–6928
- Sacchi G, Weber E, Agliano M, Cavina N, Comparini L (1999) Lymphatic vessels of the human heart: precollectors and collecting vessels. A morpho-structural study. *J Submicrosc Cytol Pathol* 31: 515–525
- Saeki H, Moore AM, Brown MJ, Hwang ST (1999) Cutting edge: secondary lymphoid-tissue chemokine (SLC) and CC chemokine receptor 7 (CCR7) participate in the emigration pathway of mature dendritic cells from the skin to regional lymph nodes. *J Immunol* 162: 2472–2475

- Salven P, Mustjoki S, Alitalo R, Alitalo K, Rafii S (2003) VEGFR-3 and CD133 identify a population of CD34+ lymphatic/vascular endothelial precursor cells. *Blood* **101**: 168–172
- Schacht V, Dadras SS, Johnson LA, Jackson DG, Hong YK, Detmar M (2005) Up-regulation of the lymphatic marker podoplanin, a mucin-type transmembrane glycoprotein, in human squamous cell carcinomas and germ cell tumors. *Am J Pathol* **166**: 913–921
- Schmelz M, Franke WW (1993) Complexus adhaerentes, a new group of desmoplakin-containing junctions in endothelial cells: the syndesmos connecting retothelial cells of lymph nodes. *Eur J Cell Biol* **61**: 274–289
- Schoppmann SF, Bayer G, Aumayr K, Taucher S, Geleff S, Rudas M, Kubista E, Hausmaninger H, Samonigg H, Gnant M, Jakesz R, Horvat R (2004) Prognostic value of lymphangiogenesis and lymphovascular invasion in invasive breast cancer. *Ann Surg* **240**: 306–312
- Schoppmann SF, Birner P, Stockl J, Kalt R, Ullrich R, Caucig C, Kriehuber E, Nagy K, Alitalo K, Kerjaschki D (2002) Tumor-associated macrophages express lymphatic endothelial growth factors and are related to peritumoral lymphangiogenesis. *Am J Pathol* **161**: 947–956
- Shayan R, Achen MG, Stacker SA (2006) Lymphatic vessels in cancer metastasis: bridging the gaps. *Carcinogenesis* **27**: 1729–1738
- Shida A, Fujioka S, Ishibashi Y, Kobayashi K, Nimura H, Mitsumori N, Suzuki Y, Kawakami M, Urashima M, Yanaga K (2005) Prognostic significance of vascular endothelial growth factor D in gastric carcinoma. *World J Surg* **29**: 1600–1607
- Shields JD, Borsetti M, Rigby H, Harper SJ, Mortimer PS, Levick JR, Orlando A, Bates DO (2004) Lymphatic density and metastatic spread in human malignant melanoma. *Br J Cancer* **90**: 693–700
- Shin JW, Min M, Larriou-Lahargue F, Canron X, Kunstfeld R, Nguyen L, Henderson JE, Bikfalvi A, Detmar M, Hong YK (2005) Prox1 promotes lineage-specific expression of FGF receptor-3 in lymphatic endothelium: a role for FGF signaling in lymphangiogenesis. *Mol Biol Cell* **E05**–E04
- Sipos B, Klapper W, Kruse ML, Kalthoff H, Kerjaschki D, Kloppel G (2004) Expression of lymphangiogenic factors and evidence of intratumoral lymphangiogenesis in pancreatic endocrine tumors. *Am J Pathol* **165**: 1187–1197
- Skobe M, Hawighorst T, Jackson DG, Prevo R, Janes L, Velasco P, Riccardi L, Alitalo K, Claffey K, Detmar M (2001) Induction of tumor lymphangiogenesis by VEGF-C promotes breast cancer metastasis. *Nat Med* **7**: 192–198
- Sleeman JP, Krishnan J, Kirkin V, Baumann P (2001) Markers for the lymphatic endothelium: in search of the Holy Grail? *Microsc Res Tech* **55**: 61–69
- Stacker SA, Achen MG, Jussila L, Baldwin ME, Alitalo K (2002) Lymphangiogenesis and cancer metastasis. *Nat Rev Cancer* **2**: 573–583
- Stacker SA, Caesar C, Baldwin ME, Thornton GE, Williams RA, Prevo R, Jackson DG, Nishikawa S, Kubo H, Achen MG (2001) VEGF-D promotes the metastatic spread of tumor cells via the lymphatics. *Nat Med* **7**: 186–191
- Stessels F, Van den Eynden G, Van der Auwera I, Salgado R, Van den Heuvel E, Harris AL, Jackson DG, Colpaert CG, Van Marck E, Dirix LY, Vermeulen PB (2004) Breast adenocarcinoma liver metastases, in contrast to colorectal cancer liver metastases, display a non-angiogenic growth pattern that preserves the stroma and lacks hypoxia. *Br J Cancer* **90**: 1429–1436
- Straume O, Jackson DG, Akslen LA (2003) Independent prognostic impact of lymphatic vessel density and presence of low-grade lymphangiogenesis in cutaneous melanoma. *Clin Cancer Res* **9**: 250–256
- Strauss L, Volland D, Kunkel M, Reichert TE (2005) Dual role of VEGF family members in the pathogenesis of head and neck cancer (HNSCC): possible link between angiogenesis and immune tolerance. *Med Sci Monit* **11**: BR280–BR292
- Swartz MA, Skobe M (2001) Lymphatic function, lymphangiogenesis, and cancer metastasis. *Microsc Res Tech* **55**: 92–99
- Takanami I (2006) Lymphatic microvessel density using D2–40 is associated with nodal metastasis in non-small cell lung cancer. *Oncol Rep* **15**: 437–442
- Tamura M, Oda M, Matsumoto I, Tsunozuka Y, Kawakami K, Ohta Y, Watanabe G (2004a) The combination assay with circulating vascular endothelial growth factor (VEGF)-C, matrix metalloproteinase-9, and VEGF for diagnosing lymph node metastasis in patients with non-small cell lung cancer. *Ann Surg Oncol* **11**: 928–933
- Tamura M, Oda M, Tsunozuka Y, Matsumoto I, Kawakami K, Ohta Y, Watanabe G (2004b) Chest CT and serum vascular endothelial growth factor-C level to diagnose lymph node metastasis in patients with primary non-small cell Lung Cancer. *Chest* **126**: 342–346
- Tamura M, Ohta Y (2003) Serum vascular endothelial growth factor-C level in patients with primary nonsmall cell lung carcinoma: a possible diagnostic tool for lymph node metastasis. *Cancer* **98**: 1217–1222
- Thiele W, Sleeman JP (2006) Tumor-induced lymphangiogenesis: a target for cancer therapy? *J Biotechnol*
- Trojan L, Michel MS, Rensch F, Jackson DG, Alken P, Grobholz R (2004) Lymph and blood vessel architecture in benign and malignant prostatic tissue: lack of lymphangiogenesis in prostate carcinoma assessed with novel lymphatic marker lymphatic vessel endothelial hyaluronan receptor (LYVE-1). *J Urol* **172**: 103–107
- Valtola R, Salven P, Heikkilä P, Taipale J, Joensuu H, Rehn M, Pihlajaniemi T, Weich H, deWaal R, Alitalo K (1999) VEGFR-3 and its ligand VEGF-C are associated with angiogenesis in breast cancer. *Am J Pathol* **154**: 1381–1390
- Van den Eynden GG, Van der Auwera I, Van Laere SJ, Colpaert CG, Turley H, Harris AL, van Dam P, Dirix LY, Vermeulen PB, van Marck EA (2005) Angiogenesis and hypoxia in lymph node metastases is predicted by the angiogenesis and hypoxia in the primary tumour in patients with breast cancer. *Br J Cancer* **93**: 1128–1136
- Van den Eynden GG, Van der Auwera I, Van Laere SJ, Huygelen V, Colpaert CG, van Dam P, Dirix LY, Vermeulen PB, Van Marck EA (2006) Induction of lymphangiogenesis in and around axillary lymph node metastases of patients with breast cancer. *Br J Cancer* [E-pub ahead of print]
- Van der Auwera I, Van den Eynden GG, Colpaert CG, Van Laere SJ, van Dam P, Van Marck EA, Dirix LY, Vermeulen PB (2005) Tumor lymphangiogenesis in inflammatory breast carcinoma: a histomorphometric study. *Clin Cancer Res* **11**: 7637–7642
- Van der Auwera I, Van Laere SJ, Van den Eynden GG, Benoy I, van Dam P, Colpaert CG, Fox SB, Turley H, Harris AL, Van Marck EA, Vermeulen PB, Dirix LY (2004) Increased angiogenesis and lymphangiogenesis in inflammatory vs noninflammatory breast cancer by real-time reverse transcriptase-PCR gene expression quantification. *Clin Cancer Res* **10**: 7965–7971
- Van Trappen PO, Steele D, Lowe DG, Baithun S, Beasley N, Thiele W, Weich H, Krishnan J, Shepherd JH, Pepper MS, Jackson DG, Sleeman JP, Jacobs IJ (2003) Expression of vascular endothelial growth factor (VEGF)-C and VEGF-D, and their receptor VEGFR-3, during different stages of cervical carcinogenesis. *J Pathol* **201**: 544–554
- Vazquez-Sequeiros E, Wang L, Burgart L, Harmsen W, Zinsmeister A, Allen M, Jondal M, Wiersema M (2002) Occult lymph node metastases as a predictor of tumor relapse in patients with node-negative esophageal carcinoma. *Gastroenterology* **122**: 1815–1821
- Veikkola T, Jussila L, Makinen T, Karpanen T, Jeltsch M, Petrova TV, Kubo H, Thurston G, McDonald DM, Achen MG, Stacker SA, Alitalo K (2001) Signalling via vascular endothelial growth factor receptor-3 is sufficient for lymphangiogenesis in transgenic mice. *EMBO J* **20**: 1223–1231
- Vermeulen PB, Gasparini G, Fox SB, Colpaert C, Marson LP, Gion M, Belien JA, de Waal RM, Van Marck E, Magnani E, Weidner N, Harris AL, Dirix LY (2002) Second international consensus on the methodology and criteria of evaluation of angiogenesis quantification in solid human tumours. *Eur J Cancer* **38**: 1564–1579
- Vermeulen PB, Gasparini G, Fox SB, Toi M, Martin L, McCulloch P, Pezzella F, Viale G, Weidner N, Harris AL, Dirix LY (1996) Quantification of angiogenesis in solid human tumours: an international consensus on the methodology and criteria of evaluation. *Eur J Cancer* **32A**: 2474–2484
- Von Marschall Z, Scholz A, Stacker SA, Achen MG, Jackson DG, Alves F, Schirner M, Haberey M, Thierach KH, Wiedenmann B, Rosewicz S (2005) Vascular endothelial growth factor-D induces lymphangiogenesis and lymphatic metastasis in models of ductal pancreatic cancer. *Int J Oncol* **27**: 669–679
- Wang TB, Huang YH, Lan P, Song XM, Wang JP (2005) Correlation of lymphangiogenesis to progression of colorectal cancer. *Ai Zheng* **24**: 1276–1279
- Weidner N, Semple JP, Welch WR, Folkman J (1991) Tumor angiogenesis and metastasis – correlation in invasive breast carcinoma. *N Engl J Med* **324**: 1–8
- Wetterwald A, Hoffstetter W, Cecchini MG, Lanske B, Wagner C, Fleisch H, Atkinson M (1996) Characterization and cloning of the E11 antigen, a marker expressed by rat osteoblasts and osteocytes. *Bone* **18**: 125–132
- Wigle JT, Oliver G (1999) Prox1 function is required for the development of the murine lymphatic system. *Cell* **98**: 769–778

- Williams CS, Leek RD, Robson AM, Banerji S, Prevo R, Harris AL, Jackson DG (2003) Absence of lymphangiogenesis and intratumoural lymph vessels in human metastatic breast cancer. *J Pathol* **200**: 195–206
- Yasuoka H, Nakamura Y, Zuo H, Tang W, Takamura Y, Miyauchi A, Nakamura M, Mori I, Kakudo K (2005) VEGF-D expression and lymph vessels play an important role for lymph node metastasis in papillary thyroid carcinoma. *Mod Pathol* **18**: 1127–1133
- Yonemura Y, Fushida S, Bando E, Kinoshita K, Miwa K, Endo Y, Sugiyama K, Partanen T, Yamamoto H, Sasaki T (2001) Lymphangiogenesis and the vascular endothelial growth factor receptor (VEGFR)-3 in gastric cancer. *Eur J Cancer* **37**: 918–923
- Zeng Y, Opeskin K, Horvath LG, Sutherland RL, Williams ED (2005) Lymphatic vessel density and lymph node metastasis in prostate cancer. *Prostate* **65**: 222–230