

## ARTICLE

# Forty-two supernumerary marker chromosomes (SMCs) in 43 273 prenatal samples: chromosomal distribution, clinical findings, and UPD studies

Oliver Bartsch<sup>\*,1,2</sup>, Anne Loitzsch<sup>2</sup>, Peter Kozlowski<sup>3</sup>, Marie-Luise Mazauric<sup>3</sup>  
and Gabriele Hickmann<sup>3</sup>

<sup>1</sup>Institute for Human Genetics, Mainz University School of Medicine, Mainz, Germany; <sup>2</sup>Institute of Clinical Genetics, Dresden University of Technology, Dresden, Germany; <sup>3</sup>Center for Prenatal Diagnosis and Genetics, Düsseldorf, Germany

Fluorescence *in situ* hybridization (FISH) analyses were performed on supernumerary marker chromosomes (SMCs) detected in 43 273 prenatal diagnoses over a period of 11 years, 1993–2003. A total of 42 pregnancies with SMC were identified, indicating a prevalence of one in 1032. A total of 15 SMCs were endowed with detectable euchromatin (prevalence, 1/2884), including six SMCs containing the cat eye critical region (CECR) on chromosome 22q11.21 (1/7212). *De novo* SMCs were found in 29 pregnancies (1/1492), including 14 euchromatic SMCs (48.2%). Follow-up studies were available for 24 cases. Nine pregnancies (37.5%) were terminated; two children (8.3%) were born with Pallister–Killian syndrome and cat eye syndrome (CES), respectively; 13 children (54.1%) showed apparently normal development. *Familial* SMCs were identified in 13 pregnancies (1/3328) from 11 unrelated women. They were all acrocentric. In all, 10 were heterochromatic and one was an extra der(22)t(11;22) chromosome. A total of 12 cases were available for follow-up. One pregnancy was terminated due to anhydramnios, spina bifida, and cystic-dysplastic kidneys; one child suffered from a der(22) syndrome; 10 children (83.3%) appeared unaffected. *Studies for uniparental disomy* were performed on seven pregnancies and revealed a case of maternal heterodisomy for chromosome 22. So far this is the largest FISH study of prenatally ascertained SMCs and the first study with detailed data on the prevalence. Findings illustrate the spectrum and clinical outcomes of prenatally diagnosed SMCs, and indicate a higher frequency of SMCs than generally assumed. *European Journal of Human Genetics* (2005) 13, 1192–1204. doi:10.1038/sj.ejhg.5201473; published online 3 August 2005

**Keywords:** prenatal diagnosis; supernumerary marker chromosomes; frequency; clinical outcome; uniparental disomy

## Introduction

Supernumerary marker chromosomes (SMCs) are disturbing findings at prenatal diagnosis<sup>1</sup> that have been reported to occur at frequencies between 1.5/1000<sup>2</sup> and 0.4/1000.<sup>3</sup>

Fluorescence *in situ* hybridization (FISH) has greatly improved the prenatal analysis of SMCs.<sup>4–8</sup> Although most cases have been characterized by standard FISH, special techniques such as chromosomal microdissection,<sup>9</sup> subcentromere-specific multicolor FISH (subcenM-FISH), and multicolor banding (MCB) have been applied to exceptional cases.<sup>7</sup>

Occasionally, SMCs lead to spontaneous abortions. Specific SMCs have been associated with Pallister–Killian syndrome (Online Mendelian Inheritance in Man (OMIM)

\*Correspondence: Priv-Doz Dr O Bartsch, Institut für Humangenetik, Universitätsklinikum, Langenbeckstr. 1, D-55101 Mainz, Germany.

Tel: +49 6131 17 5791; Fax: +49 6131 17 5690;

E-mail: bartsch@humgen.klinik.uni-mainz.de

Received 17 January 2005; revised 22 June 2005; accepted 28 June 2005;

published online 3 August 2005

601803), inverted duplication 15q12–q13 syndrome, isochromosome 18p syndrome, and cat eye syndrome (CES) (OMIM 115470). However, the majority of SMCs do not grossly interfere with fetal development, because they contain little or no euchromatin. In many cases, the clinical outcome is hard to predict because the euchromatic content of the SMC is unclear, because of the different degrees of mosaicism, and the possibility of uniparental disomy (UPD). Hence, genetic counseling after identification of an SMC is complicated. Familial SMCs confer low risks. The empirical risk for congenital anomalies is approximately 13% for randomly associated *de novo* SMCs,<sup>3–6</sup> 7% for SMCs derived from acrocentric chromosomes (excluding the 15s), and 28% for SMCs derived from nonacrocentric autosomes.<sup>10</sup> As a result of the high risks and many uncertainties regarding the clinical outcome, many pregnancies with *de novo* SMC are terminated. However, effective FISH studies can reduce uncertainties, giving affected couples a better reproductive choice.

Here, we present an 11-year survey of prenatally ascertained SMCs, which were all studied by FISH. During the study period (1993–2003), 42 pregnancies with an SMC were identified in 43 273 consecutive prenatal diagnoses.

## Materials and methods

### Study and subjects

Cases were ascertained by a survey of prenatal karyotypes from 43 273 pregnancies that had been analyzed after amniocentesis (AC), chorionic villus sampling (CVS), or fetal blood sampling (FBS) at the Center for Prenatal Medicine and Genetics, Düsseldorf, Germany, from January 1, 1993 until December 31, 2003. SMCs were detected in 42 pregnancies of 40 unrelated women (five CVS, 37 amniocenteses; Tables 1 and 2). Prenatal diagnosis was performed because of advanced maternal age (AMA,  $\geq 35$  years) in 29 women, a maternal age of 34 years combined with anxiety (cases 1, 3, 13, and 31), abnormal fetal ultrasound (cases 5, 7, 10, and 28), a previous pregnancy with familial SMC (cases 7 and 17), a maternal age of 15 years (case 27), extreme anxiety (case 35), and an uncharacterized SMC in the partner (case 39). Cases included three twin pregnancies, each with an SMC present in only one twin (cases 1, 12, and 26). The chromosomal origin, whether *de novo* or familial, was determined by parental karyotyping. When no SMC was found in both parents, it was considered *de novo*. Follow-up studies were performed using medical reports and telephone interviews of the women and/or physicians. Seven cases from this study were previously reported (see Results section).

## Cytogenetic and FISH analyses

Standard karyotyping was performed using G banding at a resolution of 400 or more bands. SMCs were further characterized by using 4,6-diamidino-2-phenyl-indole (DAPI) staining and, in some cases, AgNOR staining. FISH was performed on metaphase spreads from AC, CVS, or FBS. SMCs were classified according to Plattner *et al*<sup>12</sup> with some modifications (Table 3). Bisatellited SMCs (classes I and II) were studied with DNA probes detecting for  $\beta$ -satellite DNA in the acrocentric short arms, the  $\alpha$ -satellite subsets on chromosomes 13 and 21 (D13Z1/D21Z1), 14 and 22 (D14Z1/D22Z1), 15 (D15Z1, D15Z4), and 22 (D22Z2). SMCs(15) and SMCs(22) were further investigated with probes for the Prader-Willi/Angelman region (PW/ACR) and CECR. Minute ring-like SMCs (classes III and IV) were assigned to aliphoid suprafamilies using reduced stringency conditions and aliphoid DNA probes for chromosomes 10 (D10Z1, a member of suprafamily 1 on chromosomes 1, 3, 5, 6, 7, 10, 12, 16, and 19), 8 (D8Z2; family 2 on 2, 4, 8, 9, 13, 14, 15, 18, 20, 21, and 22), X (DXZ1; family 3 on X, 11, 17, and 1), and Y (DYZ3; family 4 on Y, 4, and 15).<sup>13</sup> In a second step, minute SMCs were studied under standard FISH conditions with the appropriate chromosome-specific aliphoid DNA probes, locus-specific probes, and/or chromosome paints (Tables 1 and 2). An analiphoid minute (case 13) required chromosomal microdissection.<sup>9</sup> Other SMCs (class V) showed informative banding patterns that were confirmed by hybridization of the appropriate DNA probes. DNA probes (Tables 1 and 2) were purchased from Appligene/Oncor (Illkirch, France) and Vysis (Downers Grove, IL, USA). Plasmids pUC1.77 and pHUR195 (D1Z satellite III DNA at chromosome 1q12 and D16Z4 at 16q11.2, kindly provided by Dr Joop Wiegant, Leiden University, The Netherlands) were labeled using nick translation. DNAs of cosmids, BACs, and YACs (Tables 1 and 2) were amplified and labeled as described in previous studies.<sup>14,15</sup> SMCs(22) were analyzed using cosmid cos121<sup>16</sup> and, following the report of McTaggart *et al*,<sup>17</sup> additional BAC clones (Tables 1 and 2).<sup>11</sup> Slides were counterstained with DAPI and analyzed using Axioskop™ epifluorescence microscopes (Carl Zeiss, Göttingen, Germany) and the ISIS™ imaging system (MetaSystems, Altlussheim, Germany). At least six informative metaphases were scored for each probe.

## Molecular studies

Following reports on SMCs and UPD,<sup>18,19</sup> UPD analysis of the chromosomes homologous to the SMC was performed in a subset of cases, if the result could aid the woman in her decision on how to proceed with the pregnancy. Fetal and parental DNAs were available for cases 14, 17A, 17B, 34, 36, 38, and 39. Between four and nine different polymorphic DNA markers (see Results section), spaced over the entire chromosome, were analyzed using the ABI 310 Genetic

**Table 1** Twenty-nine pregnancies with *de novo* supernumerary marker chromosomes

Case no.	Reason for prenatal diagnosis	Chromosomal origin	Percentage of cells with SMC <sup>a</sup> (%)	Euchromatin detected	Class <sup>b</sup>	Result of UPD studies	Karyotype	Clinical observations and follow-up
13	Age 34 and anxiety	1	50	Yes	IV	—	47,XY,+mar/46,XY.rev ish and ish r(1)(q43q44)(wcp1+,D1Z5-,D1Z7/D5Z2/ D19Z3-,D1S555/D1Z9-) <sup>c</sup>	Liveborn, normal at 6 months
34	Age 40	1	25	Yes	IV	Normal	47,XX,+mar[7]/46,XX[21].ish r(1)(p11.1q21.1)(RP5-940J24/AL157950-,D1Z5+,D1Z7/D5Z2/D19Z3+,pUC1.77/D1Z+,RP11-35B4/AL359093+)	Not available
35	Anxiety	4	60	No	III	—	47,XX,+mar[20]/46,XX[13].ish r(4)(p11q11)(D4Z1+)	TOP, no anomalies noted at post-mortem
38	Age 39	6	83	No	III	Normal	47,XX,+mar[26]/46,XX[5].ish r(6)(p11q11)(pcp6p-,RP11-362K18/AL365328.18-,D6Z1+,pcp6q-,RP11-387L5/AL512368.9-)	Delivery using vacuum extractor at week 39, birth weight 2830 g, no congenital anomalies, normal development at 7 months
3	Age 34 and anxiety	8	84 at AC 100 at FBS	No	III	—	48,XX,+2mar[4]/47,XX,+mar[17]/46,XX[4].ish r(8)(p11q11)(D8Z2+)	Liveborn, normal at 6 years
32	Age 42	8	20 at CVS 60 at AC	Yes	IV	—	47,XX,+mar[7]/46,XX[30].ish r(8)(p11.2-12q11)(wcp8+,pcp8p+,pcp8q dim)	TOP, no postmortem
29	Age 44	11	72	No	III	—	47,XY,+mar[32]/46,XY[12].ish r(11)(p11q11)(wcp11-,baclB1/MAPK8IP1-, D11Z1+)	Liveborn, normal at 3 months
5	Abnormal US, polyhydramnion, esophageal atresia	12	50	Yes	V	—	47,XY,+mar[10]/46,XY[10].ish i(12)(p10)(wcp12+)	Pallister-Killian syndrome, premature delivery at 33 weeks, died 1 day old
12	Age 40	13/21	66	No	I	—	47,XX,+mar/46,XX.ish i(13or21)(p10)(D13Z1/D21Z1+) <sup>c,d</sup>	Liveborn, normal at 4.5 years
16	Age 35	13/21	100	No	I	—	49,XY,+3mar[8]/47,XY,+mar[10].ish i(13or21)(p10)(D13Z1/D21Z1+) <sup>d</sup>	Liveborn, normal at 3 years
21	Age 41	13/21	100	No	I	—	47,XY,+mar.ish i(13or21)(p10)(wcp13-,wcp21-,D13Z1/D21Z1+) <sup>d</sup>	Liveborn, normal at 3 years
1	Age 34 and anxiety	15	100	Yes	II	—	47,XX,+mar.ish dic(15)(q13)(D15Z1++,D15S11++)	TOP
4	Age 37	15	50	No	I	—	47,XY,+mar[10]/46,XY[10].ish dic(15)(q11)(D15Z1++,D15S11-,GABRB3-)	Liveborn, normal at 6 years
10	Abnormal US, nuchal edema, heart defect, hydronephrosis	15	50 at AC 66 at FBS	Yes	V	—	47,XX,+mar/46,XX.ish i(15)(qter→q24::q24→qter)(wcp15+,D15Z2-,FES++) <sup>c</sup>	TOP, mild growth retardation and renal abnormalities at postmortem
14	Age 36	15	100	No	I	Normal	47,XY,+mar.ish dic(15)(q11)(D15Z1++,D15Z2++,D15S11-,SNRPN-,D15S10-)	Liveborn, normal at 3 years
11	Age 35	16	63	No	III	—	47,XY,+mar[60]/46,XY[34].ish r(16)(p11q11.2)(wcp16-,D16Z2+,D16Z4+)	TOP, no malformations on inspection, no postmortem
31	Age 34 and anxiety	16	70	No	III	—	47,XX,+mar[21]/46,XX[9].ish r(16)(p11q11.2)(D16Z2+,D16Z4 dim,wcp16 dim)	TOP, no post-mortem
30	Age 37	17	67	No	III	—	47,XX,+mar[36]/46,XX[17].ish r(17)(p11q11)(D17Z1+,wcp17-)	Liveborn, normal at 4 months
19	Age 39	18	100	Yes	V	—	47,XY,+mar.ish i(18)(p10)(wcp18+,yac854G8/D18S476++,D18Z1+)	TOP, no postmortem
23	Age 38	18	100	Yes	V	—	47,XY,+mar.ish i(18)(p10)(yac854G8/D18S476++,D18Z1+)	TOP, no postmortem
15	Age 41	19	63 at AC 30 at FBS	Yes	IV	—	47,XX,+mar[14]/46,XX[8].ish r(19)(p11-13.1q11-13.1)(D1Z7/D5Z2/D19Z3+,wcp1-,wcp5-,wcp19+)	Liveborn, normal at 3 years
25	Age 35	21	78	No	III	—	47,XY,+mar[26]/46,XY[7].ish r(21)(p11q11)(D13Z1/D21Z1+,wcp13-,wcp21+)	Normal at 2 years
8	Age 38	22	ND at AC 30 at FBS	No	I	—	47,XY,+mar[3]/46,XY[7].ish i(22)(p10)(D22Z2+,cos121/Z00042-)	Normal at 5 years
9	Age 37	22	100	Yes	IV	—	47,XX,+mar.ish r(22)(p11q11.2)(D22Z2+,D14Z1/	TOP, no postmortem

**Table 1** (Continued)

Case no.	Reason for prenatal diagnosis	Chromosomal origin	Percentage of cells with SMC (%)	Euchromatin detected	Class <sup>b</sup>	Result of UPD studies	Karyotype	Clinical observations and follow-up
22	Age 39	22	30	Yes	II	—	D22Z1+,cos121/Z00042+) 47,XY,+mar[17]/46,XY[17].ish dic(22)(q11.2)(D22Z22++,D14Z1/D22S609-)	Liveborn, mild cat eye syndrome at 1.5 years
24	Age 42	22	100	No	I	—	47,XX,+mar.ish i(22)(p10)(D22Z22++,D14Z1/D22Z1+,cos121/Z00042-)	Liveborn, normal at 2 years
33	Age 38	22	100	Yes	II	—	47,XY,+mar.ish dic(22)(q11.2)(D14Z1/D22Z1++,cos121/IZ00042++,CTA-201C11/D22S553/D22S609-)	Not available
36	Age 37	22	19 at AC 3 at FBS	Yes	II	UPD22, maternal heterodisomy	47,XY,+mar[11]/46,XY[46].ish +der(22)(pter→q13;p11.2→pter)(β-sat-DNA+, D14Z1/D22Z1+,cos121/Z00042+,CTA-201C11/D22S553/D22S609+,CTA-217D6/BCR+,CTA-256C5/D22S102+,CTA-799F10/D22S163-:::β-sat-DNA+)	Premature delivery at 33 weeks, birth weight 2000 g, no congenital anomalies, normal development at 6 months
40	Age 37	22	100	Yes	II	—	47,XY,+mar .ish dic(22)(q11.21)(D14Z1/D22Z1++,CTA-639G4/D22S543++,CTA-115F6/D22S420++,CTA-201C11/D22S553/D22S609++,CTA-219G6/ HCF2++orf+)	Not available

<sup>a</sup>Percentage at AC except where stated otherwise.

<sup>b</sup>Classes defined in Table 3.

<sup>c</sup>Exact number of normal/abnormal cells not available, only percentages archived.

<sup>d</sup>Alternatively, this could be the product of a 13;21 translocation.

Age, advanced maternal age ≥ 35 years.

US, fetal ultrasound; ND = not determined; TOP = termination of pregnancy.

Analyzer. Paternity testing was not performed due to legal restrictions.

## Results

### De novo SMCs

Table 1 summarizes the cases with *de novo* SMCs and provides the FISH karyotypes. Figure 1 shows representative G banding results. Figure 2 shows results after FISH. In total, 29 (72.5%) of the 40 different SMCs were *de novo*. Of these, nine (31%) were present in all analyzed cells and 20 (69%) demonstrated mosaicism. Apart from case 16, all mosaics showed another cell line with a normal karyotype. Case 16 had three copies of the SMC in most cells and one SMC in the other cells. Four pregnancies were studied for UPD, one with an abnormal result (case 36, see *Chromosome 22*).

**Chromosome 1 Case 13:** As reported previously (case 1),<sup>9</sup> an AC was performed at 15+4 weeks of gestation. Karyotyping showed a minute SMC in 50% of the cells. Absence of alphoid DNA using FISH suggested a neocentric SMC. After chromosomal microdissection and reverse painting, and FISH studies using a subtelomeric probe for 1q (Oncor P5402, D1S555/D1Z9), the SMC was found to represent 1q43–q44, excluding the 1q subtelomeric region. Apart from a transient bigeminal pulse, no abnormalities were noted in neonatal age. The mother reported a normal development at the age of 6 months.

**Case 34:** An AC was performed at 15+3 weeks of gestation. Karyotyping demonstrated a minute round DAPI-positive SMC (Figure 1) in 25% of the cells and FISH indicated trisomy for the pericentromeric area of chromosome 1 and for a small segment from 1q21 (Figure 2). Fetal ultrasound at 16 weeks was normal. Molecular studies showed normal biparental inheritance at loci D1S1646, D1S550, D1S1595, and D1S180, excluding UPD1. The pregnancy was continued but not available for follow-up.

**Chromosome 4 Case 35:** This 25-year-old woman requested an AC at 14+5 weeks of gestation because her partner had a brother with mental retardation of unknown origin. The ultrasound at 14+5 weeks showed a normal male fetus. A small ring-like DAPI-positive SMC (Figure 1) was evident in 60% of the cells. FISH demonstrated a minute ring composed entirely of pericentric heterochromatin from chromosome 4 (Figure 2). The pregnancy was terminated at 19+2 weeks of gestation. Autopsy showed no external or internal fetal anomalies.

**Chromosome 6 Case 38:** An AC was performed at 14+2 weeks of gestation. A detailed fetal ultrasound was normal. G banding (Figure 1) and DAPI staining revealed a minute ring-like DAPI-positive SMC in 83% of the cells. The FISH signal with the alphoid probe for chromosome 6 covered

**Table 2** Thirteen pregnancies (11 different families) with familial supernumerary marker chromosomes

Case no.	Reason for prenatal diagnosis	Chromosomal origin	Percentage of cells with SMC <sup>a</sup> (%)	Class <sup>b</sup>	Result of UPD studies	Karyotype	Clinical observations and follow-up
27	Age 15 years	13/21	100	I	—	47,XY,+mar.ish i(13or21)(p10)(D13Z1/D21Z1+)mat <sup>c</sup>	Liveborn, normal at 1 year
37	Age 35 years	13/21	100	I	—	47,XY,+mar.ish i(13or21)(p10)(β-satellite-DNA++,D13Z1/ D21Z1+)pat <sup>c</sup>	Emergency birth at 28 weeks after premature ablation of the placenta, normal at 1 year
6	Age 35 years	13/21 and 15	100	I	—	47,XX,+mar.ish der(13or21;15)(p10p10)(wcp13-,D13Z1/D21Z1+,wcp15-,D15Z1+,D15S11-,wcp21-)mat	Liveborn, normal at 5 years
17A	Age 36 years	15	100	I	Normal	47,XY,+mar.ish dic(15)(q11)(D15Z1++,D15Z2++,SNRPN-)mat	Liveborn, normal at 3 years
17B	Age 38 years and maternal SMC	15	100	I	Normal	47,XY,+mar.ish dic(15)(q11)(D15Z1++,D15Z2++,SNRPN-)mat	Liveborn, normal at 6 months
39	Paternal SMC	15	100 at CVS	I	Normal	47,XX,+mar.ish dic(15)(q11)(D15Z1++,SNRPN-)pat	Not available
2	Age 37 years	22	100	I	—	48,XY,+marx2[12]/47,XY,+mar[9].ish dic(22)(q11.1)(D14Z1/ D22Z1++,cos121/ Z00042-)mat	Liveborn, normal at 6 years
7A	Abnormal US	22	100	I	—	47,XY,+mar.ish i(22)(p10)(D22Z2++,D14Z1/D22Z1 dim)pat	TOP, anhydramnios, spina bifida aperta, and dysplastic kidneys on US, no postmortem
7B	Paternal SMC	22	100	I	—	47,XY,t(4;5)(q28q33)de novo,+i(22)(p10)pat	Liveborn, normal at 4.5 years
18	Age 35 years	22	100	I	—	47,XY,+mar.ish i(22)(p10)(D22Z2+or++,D14Z1/ D22Z1-)pat	Liveborn, normal at 2.5 years
20	Age 40 years	22	100	I	—	47,XY,+mar.ish i(22)(p10)(D22Z2++,D14Z1/ D22Z1+,cos121/ Z00042-)pat	Liveborn, normal at 2.5 years
26	Age 36 years	22	100	V	—	47,XY,+mar.ish der(22)t(11;22)(q23.3q11.2)(CTA-919E7/ D22S942+,MLL+)pat	Liveborn, multiple malformations, died 1 day old
28	Nuchal translucency	22	100	I	—	47,XX,+mar.ish i(22)(p10)(D22Z2++,D14Z1/D22Z1 dim)pat	Liveborn, aside from adducted feet normal at the age of 4 months

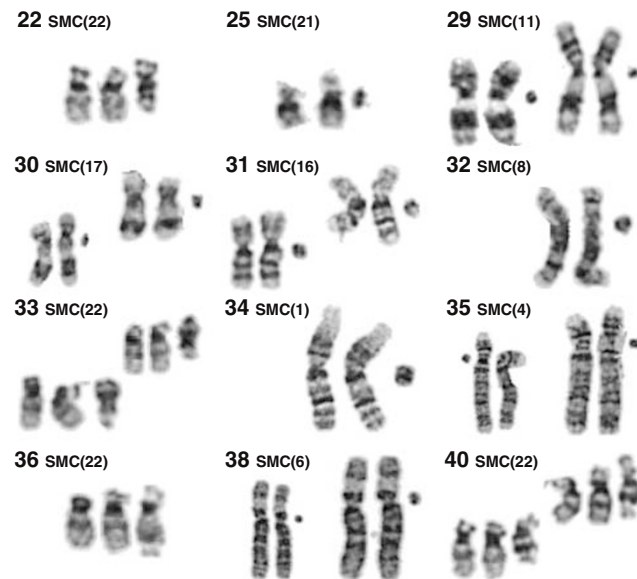
<sup>a</sup>Percentage at AC except where stated otherwise.<sup>b</sup>Defined in Table 3.<sup>c</sup>Alternatively, this could be the product of a 13;21 translocation.Age, advanced maternal age  $\geq 35$  years.

US, fetal ultrasound; TOP = termination of pregnancy.

**Table 3** Classification of SMCs used in the present study, prevalences of the different SMCs, and summary of chromosomal findings

Class	Definition	Pregnancies	Prevalence	Summarized chromosomal findings
I	Small bisatellited SMCs without the critical region for PWS/AS or CES	19 (45.2%)	1/2277	Five isochromosomes 13p or 21p <sup>a</sup> One dicentric chromosome 13 or 21 and 15 Five dicentric chromosomes 15q11 (4 cases) Seven isochromosomes 22p (6 cases) One dicentric chromosome 22q11.1
II	Larger bisatellited SMCs containing either the PWS/AS region or the CESC	5 (11.9%)	1/8654	One isochromosome 15q13 Two small (type I) CES chromosomes One larger (type II) CES chromosome One atypical (type III) CES chromosome
III	Minute ring-like SMCs showing only centromere heterochromatin	8 (19%)	1/5409	Minutes representing chromosomes 4cen, 6cen, 8cen, 11cen, 16cen (2x), 17cen, and 21cen
IV	Minute ring-like SMCs showing euchromatin	5 (11.9%)	1/8654	Minutes conferring small proximal trisomies of 1q, 8p, 19p and/or q, and 22q One analphoid ring chromosome 1q43–q44
V	Other SMCs	5 (11.9%)	1/8654	One isochromosome 12p One analphoid duplication 15q24–q26 Two isochromosomes 18p One der(22)t(11;22) extrachromosome

<sup>a</sup>Alternatively, these SMCs could be the product of a 13;21 translocation.



**Figure 1** Partial G banded karyotypes showing SMCs and chromosomes of origin from the more recent *de novo* cases. Case numbers are indicated in the upper left corner. All SMCs other than the left SMC(4) (case 35) are depicted to the right of the original chromosomes.

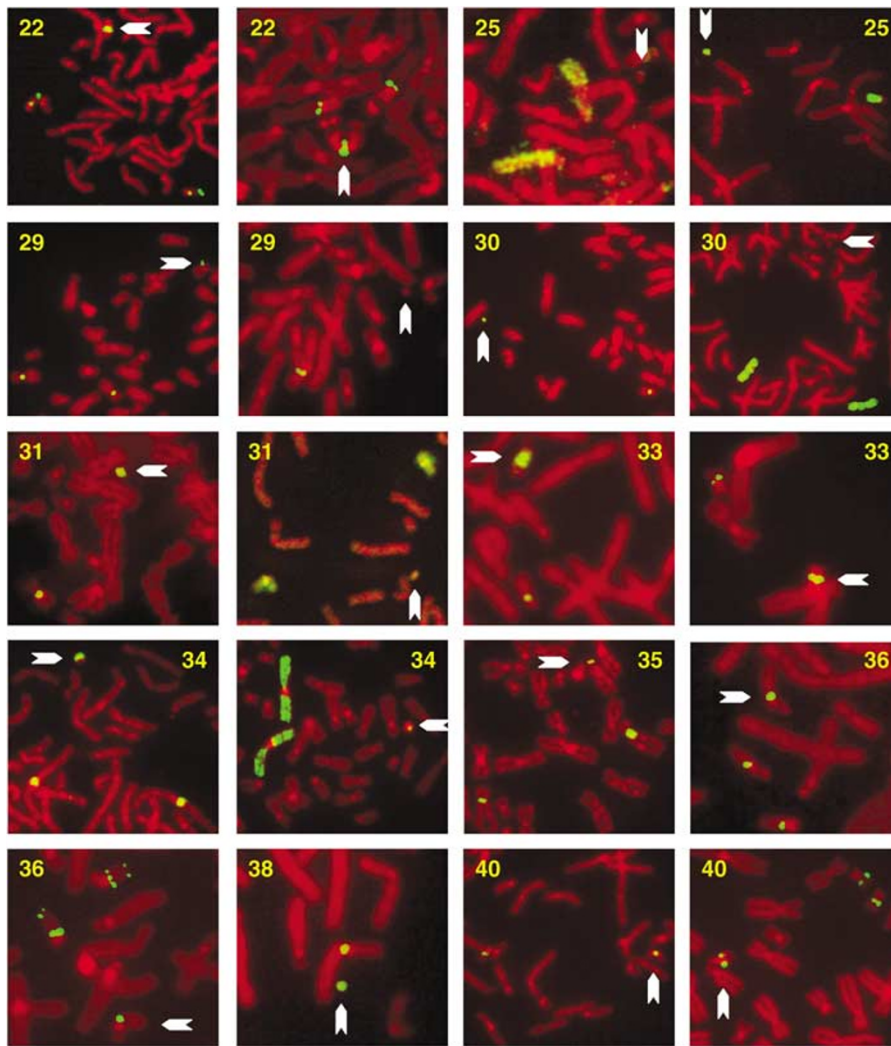
the entire SMC (Figure 2), suggesting breakpoints within the aliphoid DNA. UPD6 was excluded using nine different polymorphic markers. Seven markers (D6S477, D6S1050, D6S1031, D6S1056, D6S474, D6S1003, and D6S503) were

informative and demonstrated normal biparental inheritance, excluding UPD6. The child was born at term using a vacuum extractor. Birth weight was 2830 g, length 49 cm, and OFC 32 cm. No congenital anomalies were noted. The mother reported normal development at age 7 months.

**Chromosome 8 Case 3:** An AC was performed at 15+6 weeks of gestation. G banding showed two minute circular SMCs in 16% of the cells, one SMC in 68% of the cells, and normal chromosomes in the other cells. FISH indicated an SMC(8). The hybridization signal with the aliphoid probe for 8 fully covered the SMC, suggesting the absence of euchromatin. At age 6 years, the girl was phenotypically normal.

**Case 32:** A CVS was performed at 11+6 weeks of gestation. Karyotyping showed a ring-like 18p-sized SMC (Figure 1) in 14% of the cells. Following an AC at 14 weeks of gestation, the SMC was recovered in 19% of the metaphases and characterized using multifluor FISH (24-color painting) and partial chromosome paints for 8p (pcp8p) and 8q (pcp8q). Findings indicated an SMC(8) containing a minute euchromatic segment from 8p and possibly also from 8q. A detailed fetal ultrasound was normal. The pregnancy was terminated.

**Chromosome 11 Case 29:** An AC was performed at 14+5 weeks of gestation. G banding showed a minute SMC (Figure 1) in 72% of the cells. The FISH signal using an aliphoid probe for chromosome 11 covered the entire SMC



**Figure 2** Partial metaphases after FISH from the more recent *de novo* cases. Case numbers are indicated on each image. SMCs are marked by arrows. The following DNA probes were used: case 22 (left) BAC CTA-639G4 (chromosome 22q11.1) showing two extra copies by dosage estimate on the SMC, and BAC CTA-384D8 (22q13.33), absent on SMC, (right) BAC CTA-678G6 (22q11.21), two extra copies on SMC by dosage estimate; case 25 (left) wcp13, no signal on SMC, (right) wcp21 painting the SMC; case 29 (left) alphoid probe for chromosome 11 covering the entire SMC, (right) BAC clone IB1, absent on SMC; case 30 (left) alphoid probe for chromosome 17 covering the entire minute SMC, (right) wcp17 showing no detectable euchromatin; case 31 (left) alphoid probe for chromosome 16 covering almost the entire SMC, (right) wcp16 producing a weak signal above the background noise level; case 33 (left) alphoid probe for chromosomes 14 and 22 showing two extra copies on this CES chromosome, (right) cos121 showing two extra copies by dosage estimate; case 34 (left) D1Z satellite III DNA probe pUC1.77 identifying the SMC as a highly reduced chromosome 1, (right) wcp1 painting a small segment of the SMC; case 35 (left) alphoid probe for chromosome 4 covering the entire minute SMC; case 36 (first image) BAC CTA-678G6 one extra copy on this unusual (type III) CES chromosome, by dosage estimate from several metaphases, (second image) BAC CTA-201C11, one extra copy by dosage estimate, and BAC CTA-799F10, absent on this SMC; case 38, alphoid probe for chromosome 6 covering the entire minute SMC; case 40 (left) BAC CTA-201C11, two extra copies on this large (type II) CES chromosome by dosage estimate from several metaphases, and (right) BAC CTA-219G6, either one or two extra copies on this CES chromosome, dosage estimate not feasible.

(Figure 2). A whole chromosome paint for 11, which paints the euchromatin but not the heterochromatin, and BAC clone IB1 (a gift from Dr Gerard Waeber, University of Lausanne, Switzerland) (Figure 2), which detects the *MAPK8IP1* gene at 11p11.2, respectively, produced no detectable signals on the SMC. Findings suggested that the SMC contained only centromere heterochromatin. The boy had no apparent anomalies at age 3 months.

**Chromosome 12 Case 5:** A woman had an ultrasound at 28 + 3 weeks gestation showing polyhydramnion and esophageal atresia. Concomitant karyotyping by means of AC showed a nonsatellited, F-group sized metacentric SMC in 50% of the cells. An isochromosome 12p (Pallister-Killian syndrome) was suspected and confirmed using FISH. The boy was born at 33 weeks of gestation and died at day one of life.

**Chromosome 13 or 21** *Case 12:* In this twin pregnancy, an AC was performed at 15+1 weeks of gestation. One twin had a normal karyotype and the cotwin had a small bisatellited SMC in 66% of her cells. FISH identified a 13p or 21p isochromosome or translocation. The twin with the SMC was phenotypically unaffected at 4.5 years. Her sister with the normal karyotype died at age of 1 year of sudden infant death.

*Case 16:* An AC was performed at 17 weeks of gestation. Karyotyping demonstrated three identical small, bisatellited, DAPI-negative SMCs in 45% of the cells and one SMC in 55%. FISH indicated that the SMCs consisted of 13p or 21p material. The boy had no apparent anomalies at the age of 3 years.

*Case 21:* Following an AC performed at 16 weeks of gestation, a small bisatellited SMC was evident in all cells. FISH demonstrated a 13p or 21p isochromosome or translocation. The boy had no anomalies at age 3 years.

**Chromosome 15** *Case 1:* In this female twin pregnancy, an AC was performed at 15+4 weeks of gestation. One twin had a large bisatellited DAPI-positive SMC and the cotwin had a normal karyotype. Using FISH, the SMC was identified as a dicentric SMC(15) with two copies of the PW/ACR. A selective termination was performed. The cotwin was normal at birth.

*Case 4:* An AC was performed at 15 weeks of gestation. A small bisatellited DAPI-positive SMC was found in 50% of the cells. FISH showed a dicentric SMC(15) lacking the PW/ACR. The boy showed no anomalies at age 6 years.

*Case 10:* This was reported previously (case 2).<sup>9</sup> After an ultrasound showing nuchal edema, a heart defect, and hydronephrosis, concomitant AC and FBS were performed at 22+5 weeks of gestation. A nonsatellited, F-group sized submetacentric SMC was found in 50% and 66% of cells, respectively. FISH showed no alphoid DNA on the SMC. The banding pattern tentatively suggested an origin from the distal chromosome 15q, which was confirmed by FISH. The pregnancy was terminated at 24 weeks. Post-mortem studies showed mild growth retardation (weight 690g, signs of maturity 21 weeks), bilateral hydronephrosis, polycystic left kidney (Potter IV), and dysplastic right kidney.

*Case 14:* An AC was performed at 14+2 weeks of gestation. Karyotyping revealed a bisatellited DAPI-positive SMC in all cells and FISH indicated a dicentric chromosome 15 without the PW/ACR. Molecular studies indicated biparental inheritance at loci D15-ACTC, D15S659, and D15S175, excluding UPD15. The boy had no anomalies at age 3 years.

**Chromosome 16** *Case 11:* An AC was performed at 15+6 weeks of gestation. After G banding, a ring-like, 18p sized SMC was seen in 63% of the cells. The combined FISH signals with an alphoid probe for 16 (D16Z2) and a satellite

II probe (pHUR195, D16Z4) covered the entire SMC, which may have arisen from a ring chromosome 16 by subsequent deletion(s). A whole chromosome paint 16 (wcp16), which excludes the pericentric heterochromatin, showed no signal on the SMC, suggesting the absence of euchromatin DNA. After genetic counseling,<sup>20</sup> the pregnancy was terminated at 19 weeks. Placenta weight was normal. The fetus weighed 210g and showed no external malformations. Further post-mortem studies were declined.

*Case 31:* An AC was carried out at 16+0 weeks of gestation and showed a circular 18p sized SMC (Figure 1) in 70% of the cells. FISH using an alphoid probe (locus D10Z1) at low stringency indicated the presence of alphoid suprafamily 1 DNA. Using an alphoid probe for chromosome 16 (locus D16Z2), a signal was present on the SMC (Figure 2). A satellite II probe (pHUR195, D16Z4) yielded a weak signal on the SMC. Similarly, the wcp16 produced very minor signals barely above the background noise level (Figure 2). Hence, the SMC contained little if any euchromatin. The detailed fetal ultrasound was apparently normal. The pregnancy was terminated. Autopsy data were not available.

**Chromosome 17** *Case 30:* A minute ring-like SMC (Figure 1) was detected in 67% of the cells after an AC performed at 14+5 weeks of gestation. FISH with a chromosome 17  $\alpha$ -satellite probe and a wcp17 revealed an SMC(17) with very little or no euchromatin (Figure 2). The girl had no apparent anomalies at the age of 4 months.

**Chromosome 18** *Case 19:* A nonmosaic small metacentric SMC was evident after CVS performed at 10+6 weeks gestation. An isochromosome 18p was suspected after karyotyping and was confirmed using FISH. The pregnancy was terminated at 12 weeks of gestation.

*Case 23:* This woman had an AC at 14+3 weeks gestation. Karyotyping showed a small metacentric SMC present in all cells. An isochromosome 18p was suspected and confirmed using FISH. Detailed fetal ultrasound showed a dolichocephaly but no other anomalies. The pregnancy was terminated.

**Chromosome 19** *Case 15:* An AC was performed at 16+4 weeks of gestation and showed a minute ring-like SMC in 63% of the cells. Using FISH at low stringency, DNA of the alphoid suprachromosomal family 1 was present at the SMC. An alphoid probe for chromosomes 1, 5, and 19 (D1Z7/D5Z2/D19Z3) and wcp19 yielded FISH signals covering most of the SMC, whereas wcp1 and wcp5 did not hybridize with the SMC. An SMC(19) containing some euchromatin was diagnosed. The girl had no anomalies at age 3 years.

**Chromosome 21** *Case 25:* A minute SMC was evident in 78% of the cells of an AC taken at 15+2 weeks gestation.



FISH indicated a minute ring-like SMC(21). Detailed fetal ultrasounds at 15+2 and 20+2 weeks of gestation were normal. The pregnancy was continued. The boy had no anomalies at age 2 years.

**Chromosome 22** *Case 8:* An AC was undertaken at 18+1 weeks of gestation. A small submetacentric bisatellited SMC was detected in a subset of cells. For confirmation and FISH, FBS was performed and the SMC was recovered in 30% of the cells. Using FISH, a dicentric chromosome 22q11 without the CECR was identified. The boy had no anomalies at the age of 5 years.

*Case 9:* A minute ring-like SMC was evident in all cells of an amniotic fluid sample taken at 14+5 weeks gestation. Using FISH a small ring chromosome 22 including the CECR was detected. The pregnancy was terminated. Further information was declined.

*Case 22:* This was reported previously (patient 2).<sup>11</sup> A small (type I) CES chromosome<sup>17</sup> was detected in 50% of the cells in an AC. The boy reportedly had mild CES at the age of 1.5 years. Detailed medical records were not available.

*Case 24:* A CVS at 10+6 weeks of gestation was performed, and disclosed a small bisatellited SMC in all cells. FISH indicated an isochromosome 22p without the CECR. The girl had no anomalies at age 2 years.

*Case 33:* This was previously reported (patient 3).<sup>11</sup> Following a strong vaginal bleeding in the first trimester, an AC was performed at 14+3 weeks of gestation. G banding (Figure 1) and FISH (Figure 2) revealed a small (type I) CES SMC present in all cells. No additional data were available.

*Case 36:* This had an unusual (type III) CES chromosome as reported previously (patient 7).<sup>11</sup> The SMC (Figure 1) was present in 19% of the cells of an AC performed at 14+6 weeks of gestation and in 3% of cells after FBS. It revealed a trisomy of 22p11–q13. Here, we report results of UPD studies, which indicated uniparental maternal heterodisomy 22 (UPHetD22mat) (Table 4). The amount of DNA from the SMC was below the detection limit of the assay. Although the paternal origin of the SMC was not proven, it is most likely of paternal origin. The boy was not dysmorphic at birth and reportedly showed normal development at age 6 months.

*Case 40:* This was previously reported (patient 6).<sup>11</sup> An AC was performed at 14+5 weeks of gestation. G banding

(Figure 1) and FISH (Figure 2) showed a large (type II) CES SMC present in all cells. The woman considered termination of the pregnancy. No additional data were available.

#### Familial SMCs

Familial SMCs were found in 13 pregnancies (13 out of 42, 30.9%) from 11 unrelated women (Table 2). Seven (63.6%) were inherited paternally and four (36.3%) maternally. The familial SMCs were present in all cells. One pregnancy (case 2) showed two different cell lines containing one and two copies of the SMC, respectively. Three cases (Table 2) were studied for UPD, all with normal results.

**Chromosome 13 or 21** *Case 27:* A very small bisatellited, metacentric SMC was found after an AC performed at 14+1 weeks of gestation. FISH indicated a 13p or 21p isochromosome or translocation. The mother displayed the same SMC. The boy had no apparent anomalies at age 1 year.

*Case 37:* Following an AC performed at 16 weeks of gestation, a bisatellited SMC was seen in the amniocytes and in paternal blood lymphocytes. FISH indicated an origin from chromosome 13p and/or 21p. At 28 weeks of gestation, the woman had a premature ablation of the placenta and an emergency Caesarean section. Birth weight was 770 g, length 35 cm, and Apgar 7/7/9 after 1/5/10 min. At age 12 months, the boy was not dysmorphic and showed no signs of developmental delay.

**Chromosomes 13 or 21 and chromosome 15** *Case 6:* This phenotypically normal woman had a female cousin with mental retardation of unknown origin. An AC was performed at 16+5 weeks of gestation. A small bisatellited SMC was identified and also found in maternal lymphocytes. Using FISH, a small dicentric SMC with alphoid DNA of chromosomes 13 or 21 and of chromosome 15 was detected. This girl had no apparent anomalies at age 5 years.

**Chromosome 15** *Case 17A:* A small bisatellited SMC was identified after an AC performed at 15+5 weeks of gestation and in maternal lymphocytes. FISH demonstrated a dicentric SMC(15) without the PW/ACR. Molecular studies indicated a normal biparental inheritance at loci D13S232, D13S218, D13S317, D13S796, D13S285, D14S597, D14S306, D14S617, D15S122, D15-ACTC,

**Table 4** Short sequence repeat polymorphisms analyzed in case no. 36

Locus	Location	Alleles		Result
		Mother – Father	Amniocytes	
D22S941	22q11.21	235/243–245/247	–235/243	No paternal allele
D22S944	22q11.21	162/164–164/162	–162/164	Possibly Mendelian
D22S274	22q13.31	200/200–200/198	–200/200	Possibly Mendelian
D22S1169	22q13.32	112/114–119/125	–112/114	No paternal allele

D15S175, and D15S642, excluding UPD for chromosomes 13, 14, and 15. Fetal ultrasound was normal. The boy had no apparent anomalies at age 3 years.

*Case 17B:* At the age of 38, this woman had another AC showing the SMC. Molecular studies indicated biparental inheritance at loci D14S597, D14S306, D15S122, D15-ACTC, and D15S642, excluding UPD14 and UPD15. Clinical findings at age 6 months were normal.

*Case 39:* After 2 years of sterility, a small dicentric SMC was identified in lymphocytes of the partner of a 28-year-old woman, and in lymphocytes of his father. Intracytoplasmic sperm injection (ICSI) was performed without success. Thereafter, a pregnancy occurred spontaneously. Following CVS at 11+6 weeks of gestation and FISH, an inverted duplication of chromosome 15 lacking the PW/ACR was identified. Molecular studies showed a normal biparental inheritance at different polymorphic markers (D15S1365, D15S817, D15S195, D15S523, and D15S533) excluding UPD15. The pregnancy commenced normally, but was not available for follow-up.

**Chromosome 22** *Case 2:* An AC was performed at 14+1 weeks of gestation. Two copies of a small metacentric, bisatellited SMC were present in 57% of the cells and one copy of the SMC in 43%. The SMC was maternally inherited. FISH demonstrated a minute dicentric chromosome 22 made up of two short arms and two pericentromeric regions, but without the CECR. The girl was normal at an age 6 years.

*Case 7A:* In a 31-year-old woman, an AC was performed at 19+2 weeks of gestation following a fetal ultrasound showing anhydramnios, spina bifida aperta, and cystic-dysplastic kidneys. A small metacentric, bisatellited SMC was identified in amniocytes and in paternal lymphocytes. FISH indicated an isochromosome 22p with a partially duplicated centromere. The pregnancy was terminated.

*Case 7B:* Another AC in her next pregnancy showed the same SMC and an additional *de novo* translocation of chromosomes 4 and 5. This boy had no apparent anomalies at age 4.5 years.

*Case 18:* This small metacentric bisatellited SMC was detected following an AC at 14 weeks of gestation. The SMC was found to be of paternal origin. FISH indicated an isochromosome 22p. The boy had no apparent anomalies at age 2.5 years.

*Case 20:* An AC was performed at 17+3 weeks of gestation. A bisatellited metacentric SMC was found in the amniocytes and in paternal lymphocytes. Using FISH, the SMC was an isochromosome 22p. The boy had no apparent anomalies at age 2.5 years.

*Case 26:* This was previously reported (patient 9).<sup>11</sup> In a twin pregnancy, an AC was performed at 15 weeks of gestation. An SMC was detected and using FISH, a der(22)t(11;22) extrachromosome was identified. A constitutional 11;22 translocation was identified in the cotwin

and in the father. The affected twin had severe malformations and died on day one of life.<sup>11</sup> The cotwin had no anomalies.

*Case 28:* Following an abnormal (2.9 mm) nuchal translucency, a 28-year-old woman had a CVS performed at 12 weeks of gestation. A small, bisatellited SMC was evident in all cells and in paternal lymphocytes. FISH indicated an isochromosome 22p. The girl was born at term. Weight was 3910 g, length 53 cm, and Apgar 8/10. Apart from adducted feet she had no apparent anomalies at the age of 4 months.

## Discussion

So far, this is the largest FISH study of prenatally diagnosed SMCs. Apart from the detailed review of Crolla,<sup>10</sup> so far only one large-scale study of the euchromatic DNA content in pre- and postnatal SMCs has been reported.<sup>7</sup>

## Frequencies of the different SMCs

Our study shows a prevalence of 1/1032 ( $n=42$ ) for SMCs at prenatal diagnosis, 1/1492 for *de novo* SMCs ( $n=29$ ), and 1/3328 for the familial SMCs ( $n=13$ ). Previous studies reported SMC frequencies of 0.4/1000,<sup>3</sup> 0.8/1000,<sup>21</sup> 1/1000,<sup>5</sup> and 1.5/1000.<sup>2</sup> The higher frequencies could possibly be explained by (i) nonrandom ascertainment of cases, (ii) withdrawal of materials at an earlier point of time in gestation, and/or (iii) greater maternal age. In our study, none of these possibilities is persuasive. The maternal age distribution was inconspicuous, materials were withdrawn at usual points in time of gestation, and all but six pregnancies (14%; Tables 1 and 2) were ascertained due to maternal age and/or anxiety. Therefore, we consider the frequency of 1/1000 for prenatally diagnosed SMCs to be representative.

Table 3 classifies the SMCs in the present study. At a prevalence of 1/1602, heterochromatic SMCs (classes I and III;  $n=27$ ) were almost twice as frequent as euchromatic SMCs (classes II, IV, and V;  $n=15$ ) with a prevalence of 1/2884. Euchromatic SMCs usually originated *de novo* and accounted for approximately one half of *de novo* SMCs (48.2%; 14 of 29); the remaining *de novo* SMCs were heterochromatic. Apart from one case, all familial SMCs were heterochromatic and, therefore, without phenotypic effects. In the one case (no. 26) with abnormalities, the SMC arose from a 3:1 malsegregation of a balanced translocation.

Regarding the morphology, we have shown that 57.1% of the prenatally diagnosed SMCs are bisatellited ( $n=24$ ). Five bisatellited SMCs (5/24, 20.8%) contained detectable euchromatin (class II; PW/ACR or CECR). About 32% of the SMCs were ring-like minutes ( $n=13$ ), and of these, 38% showed euchromatin (class IV minutes;  $n=5$ ). Another 12% of the SMCs were miscellaneous (class V;  $n=5$ ). These all occurred *de novo* and showed tentatively recognizable

banding patterns: an acrocentric (class V) SMC proved to be a der(22)t(11;22) chromosome, a submetacentric SMC (case 10) was identified as an inverted duplication of chromosome 15q24 as reported previously,<sup>9</sup> and three metacentric SMCs represented isochromosomes 12p and 18p, respectively.

### FISH strategy

Six different DNA probes (for  $\beta$ -satellite DNA on the acrocentric short arms; the alphoid DNA subsets on chromosomes 13/21, 14/22, and 15; the PWS/AS chromosomal region, and the CECR) are sufficient for a basic classification of bisatellited SMCs (classes I and II). However, as shown here and elsewhere, a subset of cases may require additional probes.<sup>7,11,17</sup> The stepwise investigation of minute SMCs (classes III and IV) included (i) the identification of the  $\alpha$ -satellite suprachromosomal family by low-stringency hybridization allowing cross-hybridization between members of the same suprafamily,<sup>13</sup> (ii) the identification of the chromosomal origin by high-stringency (chromosome-specific) hybridization of alphoid DNA probes, and (iii) analysis of the euchromatin DNA content using region-specific probes such as BACs.<sup>7,11</sup> There have been attempts to detect the euchromatin on SMCs by using of whole chromosome painting,<sup>16</sup> but due to the presence of centromeric DNA in some paints, this approach is artifact prone: heterochromatic and euchromatic SMCs (classes I vs II or classes III vs IV) may be confused. This study has shown that the stepwise procedure is effective and fast; final results were obtained (usually within 1 week) for 92.3% (12 of 13) of the minute SMCs. All other (class V) SMCs were tentatively identified by their cytogenetic properties and required only confirmatory FISH studies. Overall, only one case (2.5%; case 13) required the use of more complex FISH techniques.<sup>9</sup>

### Small (class I) bisatellited SMCs

SMCs of the acrocentric short arms and small dicentric chromosomes 15 or 22 are assumed to be devoid of dosage-sensitive genes. Nevertheless, it is widely assumed that they confer a small risk for congenital anomalies above the baseline risk of the general population. Interestingly, this study includes a case possibly supporting such extra risk. One (6%) of the 17 pregnancies with a class I SMC featured bifid spine, dysplastic kidneys, anhydramnios, and a familial isochromosome 22p (case 7A). The clinical findings are not imputable to the presence of undetected euchromatin between the centromere and the CECR (chromosome 22q11.21) on this SMC, because they have not been previously reported with tri- or tetrasomy of chromosome 22q11.<sup>22</sup> Neither can they be explained by imprinting defects caused by the possible presence of UPD22, because chromosome 22 is not known to harbor imprinted genes.<sup>23,24</sup> The reduction to homozygosity of recessive mutations by UPD remains a remote possibility,

because in rare cases, neural tube defects (NTDs) were associated with 22q11 deletions.<sup>25,26</sup> Oligohydramnios and absent/malformed kidneys have been reported with full trisomy 22.<sup>27</sup> Our patient had no additional signs of trisomy 22, or of a 22q11 deletion. In fact, the combination of kidney cysts and NTD appears to be extremely rarely associated with chromosomal aberrations: thus far, there has been only one report involving chromosome 3.<sup>28</sup> However, the combination has been reported with the VACTERL association,<sup>29</sup> a relatively frequent disorder (1 in 5000 newborns) that has been linked with maternal diabetes, inhibition of cholesterol biosynthesis, and the Hedgehog signaling pathway.<sup>30</sup> Therefore, we consider the abnormalities and the SMC(22) in case 7A to be most likely a chance association. Nevertheless, the data support that pregnancies with a class I SMC have a slightly increased risk for abnormalities.

### Prevalence of the CECR and possible maternal age effect

The CECR was present in six SMCs (prevalence 1/7212) or, excluding the familial case 26, in five *de novo* SMCs (1/8655). The *de novo* cases included a small ring chromosome (case 9), an atypical CES chromosome (case 36),<sup>11</sup> and three typical CES chromosomes (cases 22, 33, and 40).<sup>17</sup> There has been no previous report on the prevalence of SMCs conferring extra copies of the CECR at prenatal diagnosis. For the CES, a frequency between 1:50 000 and 1:150 000 was estimated from patients observed in Switzerland (OMIM 115470). The large difference between the pre- and postnatal data (1:8655 vs 1:50 000–150 000) requires explanation. Population-based investigations are likely to ascertain fewer cases of CES than prenatal studies for various reasons including spontaneous abortions, oligo- or asymptomatic outcome in some patients,<sup>6,31</sup> (also this study) and terminations of pregnancy. AMA could possibly be another factor. Hook and Cross<sup>21</sup> reported a significant maternal age effect for *de novo* SMCs in their study of 75 000 prenatal diagnoses. Recently, Crolla *et al*<sup>8</sup> confirmed the maternal age effect for *de novo* SMCs(15), but for SMCs(22) their data were inconclusive. Considering that the inverted duplications of chromosomes 15 and 22 share similar origins because they both may arise in female meiosis from errors of recombination at sites of low copy repeats (LCRs),<sup>32–36</sup> the higher frequency of CES chromosomes in this study vs in the population could also, in part, be indicative of a maternal age effect.

### Minute ring-like SMCs (classes III and IV)

Minute ring-like SMCs (classes III and IV) were identified in 13 pregnancies (3.0 per 10 000 prenatal samples). All had occurred *de novo*. There were eight cases (61.5%) of heterochromatic (class III) SMCs and of these, five resulted in children without anomalies carrying SMCs 6, 8, 11, 17, and 21, respectively (cases 38, 3, 29, 30, and 25). Three

pregnancies were terminated due to maternal anxiety. Five pregnancies (38.5%) showed (class IV) SMCs conferring small proximal trisomies, but four of these were previously reported (case 13), terminated (cases 9 and 32), or not available for follow-up (case 34), and hence provided no new phenotypic information. A pregnancy with a mosaic SMC(19) (63% at AC, 30% at FBS; case 15) was informative regarding the phenotype. The child had no anomalies at age 3 years. There have been six previous cases with mosaic SMC(19) and a known outcome. Of these, two showed anomalies.<sup>10</sup> Hence, including our case, mosaic *de novo* (class IV) SMCs(19) at prenatal diagnosis confer an empirical risk of approximately 20% for congenital anomalies.

### Uniparental disomy

This study includes a case (no. 36) of maternal heterodisomy for chromosome 22 associated with a bisatellited SMC(22). Recently, the early postzygotic reduction of a chromosome to a SMC was identified as a mechanism to rescue a trisomic conceptus.<sup>24</sup> Case 36 is the second example of trisomy rescue by fortuitous formation of an SMC from the paternal homolog 22.<sup>24</sup> The SMC conferred trisomy for chromosome 22p11–q13, but was present in only 19% of amniocytes and 3% of lymphocytes. Hence, we consider the normal phenotype of the patient at age 6 months to be most likely due to the low degree of mosaicism for the SMC. Moreover, the case adds evidence to that maternal UPD 22 usually has no adverse effects.<sup>23,24</sup>

### Acknowledgements

We thank Arleta Frensel for providing technical assistance, Prof Georg Klaus Hinkel for continuous support, and Dr Thomas Liehr for results (cases 32 and 38) using multifluor FISH and partial chromosome paints.

### Electronic-database information

URLs and accession numbers for data in this article are as follows: Online Mendelian Inheritance in Man (OMIM, <http://www.ncbi.nlm.nih.gov/Omim>) for the CES (MIM 115470) and isochromosome 12p (OMIM 601803).

### References

- 1 Ferguson-Smith MA, Yates JR: Maternal age specific rates for chromosome aberrations and factors influencing them: report of a collaborative European study on 52 965 amniocenteses. *Prenat Diagn* 1984; 4 (Spec No): 5–44.
- 2 Sachs ES, Van Hemel JO, Den Hollander JC, Jahoda MG: Marker chromosomes in a series of 10 000 prenatal diagnoses. Cytogenetic and follow-up studies. *Prenat Diagn* 1987; 7: 81–89.
- 3 Warburton D: *De novo* balanced chromosome rearrangements and extra marker chromosomes identified at prenatal diagnosis: clinical significance and distribution of breakpoints. *Am J Hum Genet* 1991; 49: 995–1013.
- 4 Blennow E, Bui TH, Kristoffersson U *et al*: Swedish survey on extra structurally abnormal chromosomes in 39 105 consecutive prenatal diagnoses: prevalence and characterization by fluorescence *in situ* hybridization. *Prenat Diagn* 1994; 11: 1019–1028.
- 5 Brondum-Nielsen K, Mikkelsen M: A 10-year survey, 1980–1990, of prenatally diagnosed small supernumerary marker chromosomes, identified by FISH analysis. Outcome and follow-up of 14 cases diagnosed in a series of 12 699 prenatal samples. *Prenat Diagn* 1995; 15: 615–619.
- 6 Hastings RJ, Nisbet DL, Waters K, Spencer T, Chitty LS: Prenatal detection of extra structurally abnormal chromosomes (ESACs): new cases and a review of the literature. *Prenat Diagn* 1999; 19: 436–445.
- 7 Starke H, Nietzel A, Weise A *et al*: Small supernumerary marker chromosomes (SMCs): genotype–phenotype correlation and classification. *Hum Genet* 2003; 114: 51–67.
- 8 Crolla JA, Youings SA, Ennis S, Jacobs PA: Supernumerary marker chromosomes in man: parental origin, mosaicism and maternal age revisited. *Eur J Hum Genet* 2005; 13: 154–160.
- 9 Spiegel M, Hickmann G, Senger G, Kozlowski P, Bartsch O: Two new cases of anaphoid marker chromosomes. *Am J Med Genet* 2003; 116A: 284–289.
- 10 Crolla JA: FISH and molecular study of autosomal supernumerary marker chromosomes excluding those derived from chromosome 15: II. Review of the literature. *Am J Med Genet* 1998; 75: 367–381.
- 11 Bartsch O, Rasi S, Hoffmann K, Blin N: FISH of supernumerary marker chromosomes (SMCs) identifies six diagnostically relevant intervals on chromosome 22q and a novel type of bisatellited SMC(22). *Eur J Hum Genet* 2005; 13: 592–598.
- 12 Plattner R, Heerema NA, Yurov YB, Palmer CG: Efficient identification of marker chromosomes in 27 patients by stepwise hybridization with alpha-satellite DNA probes. *Hum Genet* 1993; 91: 131–140.
- 13 Alexandrov IA, Medvedev LI, Mashkova TD, Kisselev LL, Romanova LY, Yurov YB: Definition of a new alpha satellite suprachromosomal family characterized by monomeric organization. *Nucleic Acids Res* 1993; 21: 2209–2215.
- 14 Bartsch O, Wagner A, Hinkel GK *et al*: FISH studies in 45 patients with Rubinstein–Taybi syndrome: deletions associated with polysplenia, hypoplastic left heart and death in infancy. *Eur J Hum Genet* 1999; 7: 748–756.
- 15 Zhu G, Bartsch O, Skrypnik C *et al*: Failure to detect DUP25 in lymphoblastoid cells derived from patients with panic disorder and control individuals representing European and American populations. *Eur J Hum Genet* 2004; 12: 505–508.
- 16 Liehr T, Pfeiffer RA, Trautmann U: Typical and partial cat eye syndrome: identification of the marker chromosome by FISH. *Clin Genet* 1992; 42: 91–96.
- 17 McTaggart KE, Budarf ML, Driscoll DA, Emanuel BS, Ferreira P, McDermid HE: Cat eye syndrome chromosome breakpoint clustering: identification of two intervals also associated with 22q11 deletion syndrome breakpoints. *Cytogenet Cell Genet* 1998; 81: 222–228.
- 18 Cheng SD, Spinner NB, Zackai EH, Knoll JH: Cytogenetic and molecular characterization of inverted duplicated chromosomes 15 from 11 patients. *Am J Hum Genet* 1994; 55: 753–759.
- 19 James RS, Temple IK, Dennis NR, Crolla JA: A search for uniparental disomy in carriers of supernumerary marker chromosomes. *Eur J Hum Genet* 1995; 3: 21–26.
- 20 Hengstschläger M, Bettelheim D, Drahonsky R, Deutinger J, Bernaschek G: Prenatal diagnosis of a *de novo* supernumerary marker derived from chromosome 16. *Prenat Diagn* 2001; 21: 477–480.
- 21 Hook EB, Cross PK: Extra structurally abnormal chromosomes (ESAC) detected at amniocentesis: frequency in approximately 75 000 prenatal cytogenetic diagnoses and associations with maternal and paternal age. *Am J Hum Genet* 1987; 40: 83–101.
- 22 Rosias PPR, Sijstermans JMJ, Theunissen PMVM *et al*: Phenotypic variability of the cat eye syndrome. Case report and review of the literature. *Genet Couns* 2001; 12: 273–282.
- 23 Schinzel AA, Basaran S, Bernasconi F, Karaman B, Yuksel-Apak M, Robinson WP: Maternal uniparental disomy 22 has no impact on the phenotype. *Am J Hum Genet* 1994; 54: 21–24.

- 24 Bartels I, Schlueter G, Liehr T: Supernumerary small marker chromosome (SMC) and uniparental disomy 22 in a child with confined placental mosaicism of trisomy 22: trisomy rescue due to marker chromosome formation. *Cytogenet Genome Res* 2003; **101**: 103–105.
- 25 Nickel RE, Magenis RE: Neural tube defects and deletions of 22q11. *Am J Med Genet* 1996; **66**: 25–27.
- 26 Forrester S, Kovach MJ, Smith RE, Rimer L, Wesson M, Kimonis VE: Kousseff syndrome caused by deletion of chromosome 22q11–13. *Am J Med Genet* 2002; **112**: 338–342.
- 27 Tinkle BT, Walker ME, Blough-Pfau RI, Saal HM, Hopkin RJ: Unexpected survival in a case of prenatally diagnosed non-mosaic trisomy 22: clinical report and review of the natural history. *Am J Med Genet* 2003; **118A**: 90–95.
- 28 Allderdice PW, Browne N, Murphy DP: Chromosome 3 duplication q21-qter deletion p25-pter syndrome in children of carriers of a pericentric inversion inv(3)(p25q21). *Am J Hum Genet* 1975; **27**: 699–718.
- 29 Krapp M, Geipel A, Germer U, Krokowski M, Gembruch U: First-trimester sonographic diagnosis of distal urethral atresia with megalourethra in VACTERL association. *Prenat Diagn* 2002; **22**: 422–424.
- 30 Bale AE: Hedgehog signaling and human disease. *Annu Rev Genomics Hum Genet* 2002; **3**: 47–65.
- 31 Bartsch O, Aksu F, Fenner A, Schwinger E: [Atypical cat eye syndrome. Fluorescence *in situ* hybridization of metaphase chromosomes]. *Monatsschr Kinderheilkd* 1992; **140**: 460–463.
- 32 Mignon C, Malzac P, Moncla A: Clinical heterogeneity in 16 patients with inv dup 15 chromosome: cytogenetic and molecular studies, search for an imprinting effect. *Eur J Hum Genet* 1996; **4**: 88–100.
- 33 Crolla JA, Howard P, Mitchell C, Long FL, Dennis NR: A molecular and FISH approach to determining karyotype and phenotype correlations in six patients with supernumerary marker(22) chromosomes. *Am J Med Genet* 1997; **72**: 440–447.
- 34 Christian SL, Fantes JA, Mewborn SK, Huang B, Ledbetter DH: Large genomic duplicons map to sites of instability in the Prader-Willi/Angelman syndrome chromosome region (15q11–q13). *Hum Mol Genet* 1999; **8**: 1025–1037.
- 35 Edelmann L, Pandita RK, Spiteri E *et al*: A common molecular basis for rearrangement disorders on chromosome 22q11. *Hum Mol Genet* 1999; **8**: 1157–1167.
- 36 Roberts SE, Maggouta F, Thomas NS, Jacobs PA, Crolla JA: Molecular and fluorescence *in situ* hybridization characterization of the breakpoints in 46 large supernumerary marker 15 chromosomes reveals an unexpected level of complexity. *Am J Hum Genet* 2003; **73**: 1061–1072.