

Send your letters to the editor, British Dental Journal, 64 Wimpole Street, London W1G 8YS  
E-mail [bdj@bda.org](mailto:bdj@bda.org)  
Priority will be given to letters less than 500 words long. Authors must sign the letter, which may be edited for reasons of space.



## Unfair accusations

Sir, in response to the letter from Dr Fallon (*BDJ* 2006; 201: 130), we would like to reassure Dr Fallon and other readers of the *BDJ* that Dentsply is completely committed to the future of UK dentistry.

As one of the UK's major manufacturers of dental consumables, specifically anaesthetic, we do take full responsibility when we are unable to supply any products to our customers.

The long lead time in re-supplying our anaesthetic range to the market following the decision by the US authorities to cease production, has largely been due to delays from the UK regulatory body the MHRA who are required to approve manufacturing changes. We are still waiting for a response from them regarding Xylocaine. Citanest is now fully approved and we will be supplying small amounts to the larger UK dealers throughout the rest of the year. Our manufacturer is preparing to increase production at the beginning of 2007.

Dentistry is our sole concern – we do not have business in any other industry and we take our commitment to the dental profession very seriously.

One excellent example of our commitment and dedication to dentistry in the UK is our cooperative programme with teaching hospitals. The future of dentistry is of the utmost importance to us, hence we continually invest in the profession through special grants and tailored materials for undergraduate programmes and we are continuously involved in other sponsorship and educational initiatives.

We have also worked hard to provide a highly informative and valued education programme for DCPs that saw over 1,200 delegates go through Dentsply courses in the first seven months of 2006.

Our research and development budget is unrivalled, providing innovations to answer various continuing challenges such as simpler protocols, less chair time and better aesthetic results.

We apologise without reserve for the problems that the anaesthetic shortage has caused our customers, but to

accuse Dentsply of being disloyal to UK customers is unfair.

**D. Real-Firman**  
Commercial Director, Dentsply  
By email  
doi: 10.1038/sj.bdj.4813994

## Slumbering time-bomb

Sir, further to recent correspondence with reference to bisphosphonates, a paper<sup>1</sup> in the March 2006 *New Zealand Dental Journal* reports that nitrogen-containing bisphosphonates persist in bone for at least 12 years. Of further concern was a patient who presented with spontaneous, non-healing bone exposure on the lingual aspect of the right mandible ie unrelated to extraction treatment.

Our local OMFS colleagues last year reported that they were dealing with a number of BON cases.

As this matter resembles a slumbering time-bomb, it would seem prudent to incorporate questions relating to such medication in patient medical questionnaires. Even with long-standing patients it can at times be alarming to read updated medical forms, when verbally we have been assured (from the patient's perspective!) that 'not much has changed'.

**F. Dean**  
New Zealand

1. Hay K D, Bishop P A. Association of osteonecrosis of the jaws and bisphosphonate pharmacotherapy: Dental implications. *New Zeal Dent J* 2006; 102: 4-9.

doi: 10.1038/sj.bdj.4813995

## Jaw centre

Sir, I was very pleased to see reference in the *BDJ* to the fact that 'Tension headache may be TMJD' (2006; 200: 605), for several reasons. First, and perhaps foremost, is that this is an area in which we can help our patients, often after they've not been able to find help elsewhere.

Secondly, for many who diagnose and treat these patients, it is good to see reference to the fact that this is often not primarily a joint problem but one of a disharmony of the stomatognathic system. Thirdly, it highlights the difficulties we see in communicating valid and reliable

TMJD signs and symptoms and to this end I can strongly recommend that we use those that have been used in North America for some time.

ICCMO (The International College of Craniomandibular Orthopaedics) has groups globally. It celebrates its 26<sup>th</sup> anniversary this year and is keen to recruit dentists with an interest in this area. One could do far worse than to investigate what this group has to offer the dentist keen to help those suffering the symptoms of TMJD. ICCMO can be contacted through their executive director, Hallie Truswell at [www.jawcentre.co.uk](http://www.jawcentre.co.uk) or 619 N. 35<sup>th</sup> Street, No 307 Seattle, WA 98103 USA.

**S. Bray**  
Dorset  
doi: 10.1038/sj.bdj.4813996

## Outside the ivory tower

Sir, we write in response to the letter from J. F. Roberts and N. Attari (*BDJ* 2006; 200: 600-601) regarding our recent paper on the Hall technique.<sup>1</sup>

We are currently writing up the two year results of a randomised control clinical trial, run in general dental practice and, when published, the data should address many of the authors' concerns regarding the technique. Our main reason for replying, though, is to challenge the assumption which seems to be implicit within the letter that all is well with our current treatment methods for managing dental caries in children. Although we fully advocate vigorous preventive and restorative management of active dental caries, increasingly we are becoming less interested in bringing absolute excellence in dental care to a small minority of lucky children, who by happy accident of high parental income or geographical location, have access to dental care from highly skilled specialists such as Dr Roberts. Instead, we are more concerned about helping the majority of children achieve their basic human right of a childhood free from dental sepsis and pain. One does not, unfortunately, have to go looking 'in the field, in developing countries' [sic] for children whose dental needs are not being met.

We are evaluating the Hall technique scientifically, through audit, and a prospective randomised clinical trial, just as our colleague, Dr Foley, did for the copper cement our correspondents mentioned.<sup>2</sup> That material was proved to be ineffective by that scientific research, so we now have an answer which we can show to its 'proponents, and proselytising disciples'. We are subjecting the Hall technique to the same rigorous process before advocating its widespread use, and we will continue to research into caries management techniques which may be as clinically effective, yet more acceptable to children and dental practitioners than some of the established restorative techniques seem to be. It is not often that academics might suggest to practising dentists that they take a look at what is going on outside their ivory tower, but we wonder if it might not be appropriate to do so here.

D. Evans

N. Innes

By email

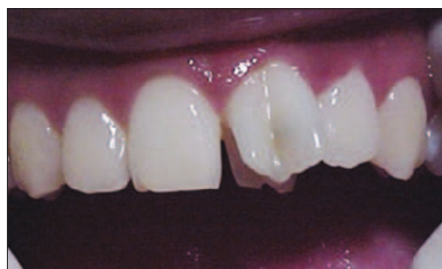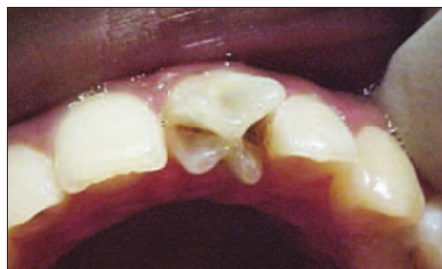1. Innes N P T, Stirrups D R, Evans D J P *et al.* A novel technique using preformed metal crowns for managing carious primary molars in general practice – a retrospective analysis. *Br Dent J* 2006; **200**: 451-454.
2. Foley J, Evans D, Blackwell A. Partial caries removal and cariostatic materials in carious primary molar teeth: a randomised controlled clinical trial. *Br Dent J* 2004; **197**: 697-701.

doi: 10.1038/sj.bdj.4813997

## 'X' shaped incisor

Sir, we write in reference to the article by Sumer *et al.* (*BDJ* 2005; **199**: 429-430), which described an unusual presentation of a Talon's cusp on a central incisor.

A similar case of an 'X' shaped incisor but in a 14-year-old girl presented to our



Figs 1-2 Upper left central incisor with an 'X' shaped appearance.

paediatric dentistry clinic at the University of the West Indies. The patient had no other anomalies, a full complement of permanent teeth with moderate caries and was concerned about the appearance of her front tooth.

The upper left central incisor had an 'X' shaped appearance when viewed incisally, with caries along the intersecting branches of the 'X' (Figs 1-2).

Sumer *et al.* suggested an aetiology of a talon's tooth with labial and lingual talons, however, we would like to propose an alternative cause. The tooth was wider mesiodistally than its antimere, the patient had a full complement of teeth and as the tooth needed endodontic treatment, we were able to establish that the tooth had an intricate coronal morphology more suggestive of a case of incomplete gemination.

We would like to know if readers have any other views.

T. Percival

R. Naidu

H. Al Bayaty

M. Ramsahai

Trinidad and Tobago

doi: 10.1038/sj.bdj.4813998

## Positive control

Sir, I write with reference to the article *How to reduce the stress of general practice* by Newton *et al.* (*BDJ* 2006; **200**: 437-440).

It is gratifying that there is now more interest in the effect of excessive stress in general dental practice. It is over 25 years since Professor Isaac Marks and I reported on the successful treatment of a dentist who through excessive stress developed a phobia of practising dentistry.<sup>1</sup>

Despite the title of the paper '*to REDUCE the stress of*', the quote below contradicts that by speaking of '*a stress FREE environment*'.

It also appears from their paper that the authors are not clear on the difference between excessive destructive stress and beneficial constructive stress, in '*that managers have a responsibility to seek to provide a stress free work environment for all employees*.' If there was no stress, the dental team would fall asleep!

The central point of treatment is to reduce 'anxiety' stress from a severe debilitating level to an optimum mild 'facilitating' level, not to abolish it altogether.

Dentistry is an interesting, stimulating and caring profession. Its stress has to be monitored and controlled informally and if necessary formally to produce optimum performance and job satisfaction for the dental team.

I quote from our paper '*One contribution to the stress of executives and professionals, including dentists, is the difficulty which is often experienced in pacing the workload at a comfortable rate.*' Teaching dentists to use 'an individual stress scale', then apply ergonomic principles to control the workload, eg do not do the most difficult task first thing in the morning, have proper tea breaks, plan and work to time etc.

Following these principles many colleagues have been helped to improve their professional life. Some however have been guided into other occupations.

Self awareness of the stress of dentistry and its positive control and management makes for a satisfying and successful professional life. Life is not stress free.

C. Wilks

Billesdon

1. Marks I M, Wilks C G W. Treatment of a dentist's phobia of practising dentistry. *Br Dent J* 1979; **147**: 189.

doi: 10.1038/sj.bdj.4813999

## Eastman excitement

Sir, in view of a number of developments we wish to clarify the position about both hospital and institute at the Eastman, as they enter exciting new phases.

Eastman Dental Hospital (EDH) is currently part of the University College London Hospitals NHS Foundation Trust. A new main UCH opened in 2005, and EDH services such as oral health care under sedation or general anaesthesia in paediatric dentistry, special care dentistry and maxillofacial surgery have already been relocated to UCLH. The Trust's intent is now to relocate EDH nearby the main hospital and, with talks well established, a Project Director has been appointed. In 3-5 years UCLH will have a state of the art Eastman Dental Hospital to support dental teaching and training and provide world class care for patients.

Eastman Dental Institute (EDI) is currently part of University College London (UCL) founded 180 years ago. With over 50 years of experience, EDI is a leader in education and research in the oral health care sciences, which has been recognised in the first award to a dental institution of The Queen's Anniversary Prize for Higher and Further Education. Moves for EDI to join UCL began 10 years ago since when there have been a number of positive developments at EDI and outstanding successes both in research and education.

A number of further positive developments are occurring, such as widening participation; collaborations in Asia; and collaborations closer to home.

---

For example, EDI is talking to King's College London Dental Institute, part of King's College London (KCL) about enhanced collaboration: both are already leading internationally recognised centres of dental research and education, and UCL and KCL are involved in discussions centrally concerning a possible more formal Strategic Partnership between the two dental institutes.

As readers will clearly recognise, the Eastman is very much alive and kicking.

R. Welfare

C. Scully CBE

By email

doi: 10.1038/sj.bdj.4814000

## An expert witness

Sir, I have followed the editorial by Martin on antibiotic prophylaxis for the prevention of infective endocarditis. I have noted the letters in response by Ramsdale, Morrison, Palmer and Fabri – *Lethal consequences* and Gibbs, Cowie and Brooks – *Defying explanation*, and I am most concerned at the effect these opposing views may have upon the general dental practitioner as to whether or not they should prescribe prophylactic antibiotic.

I must give my own views as an expert witness who has been asked to comment on at least six past and present cases. In these cases it is alleged that the failure to provide appropriate antibiotic prophylaxis has led to disastrous consequences for the patients who have contracted infective endocarditis.

Whether or not there is a causative link is I believe at the present time irrelevant; it has always been accepted practice to provide appropriate antibiotic prophylaxis, and unless there is incontrovertible evidence that the use of antibiotic prophylaxis was not indicated where 'at risk' patients are concerned, then I believe the view of the court would be that a prudent dentist would provide antibiotic prophylaxis, and not to do so would be below an acceptable standard of care.

Until there is a definitive ruling accepted by all parties as to the use of prophylactic antibiotic, I would urge my colleagues to protect themselves (and until it is proved otherwise their patients) by adhering to standard guidelines for the prescription of prophylactic antibiotic.

A. Halperin

London

doi: 10.1038/sj.bdj.4038

## Future training needs

Sir, when faced with a patient's dental problems, most dentists usually take the view that nothing is too difficult for them and that even if the recommended

treatment does not succeed then it would provide the opportunity for further treatment later. This, in my opinion, is motivated by the need to make a reasonable living. On the downside, this has led to an increase in patients' complaints, litigation and ever increasing regulatory paper work. When professional confidence in one's ability is low this can be the cause of defensive treatments.

However, a welcome aspect of this situation is the emergence of specialists: *New scheme launched* (BDJ 2006; 200: 606), which led me to imagine the development of dentistry in the future. The BDS course should be developed to a duration of five years in which students should learn principles and gain practical experience at the same time. A concise explanation of fundamentals should be followed by frequent hands-on experience (both management and clinical) as well as reading and project work. The fourth year should be dedicated to a chosen specialist subject. The vocational training year should be scrapped as a separate entity and incorporated as a fifth year with time spent partially at dental practices and partially at a local hospital/dental hospital. A unified training programme across the country is important, as graduates move around looking for jobs and it will encourage standardisation across the industry as well as enabling graduates to practise immediately upon graduation. At present it feels strange to have a degree but not be allowed to work. It will make our vocational training verifiable by supervision. We are, at present, unable to enforce it on foreign graduates especially from EU countries.

As to the actual delivery of dental services to the patients, they should be seen for assessment and simple relief of symptoms only and then promptly referred to a colleague who has a specialisation in the relevant field. This would work as a two way process between dental practitioners. The number of dentists:specialists in a given area should be regulated to meet local demands adequately and the treatment provided in this way will be of accepted quality standards which will cause fewer problems and will last longer. The pricing should be structured so that dentists make a good professional living whilst the patient/government saves money in managing bureaucracy and payments for never ending repeat and corrective treatments. A postgraduate specialisation would still be needed for referrals.

I hope this will stimulate further ideas on the very important subject of future training needs of dental students and



delivery of dental services in the UK to meet future discerning demands.

I. A. S. Syed

By email

doi: 10.1038/sj.bdj.4814001

## Arresting caries

Sir, I read with interest *The wide gulf* (*BDJ* 2006; 200: 600) by Messrs Roberts and Attari. Noting their opinion that a 'well adapted fissure sealant has the potential to arrest superficial caries', they also assert that 'this is not the case for deep dentinal caries where substrate is available from the pulp'.

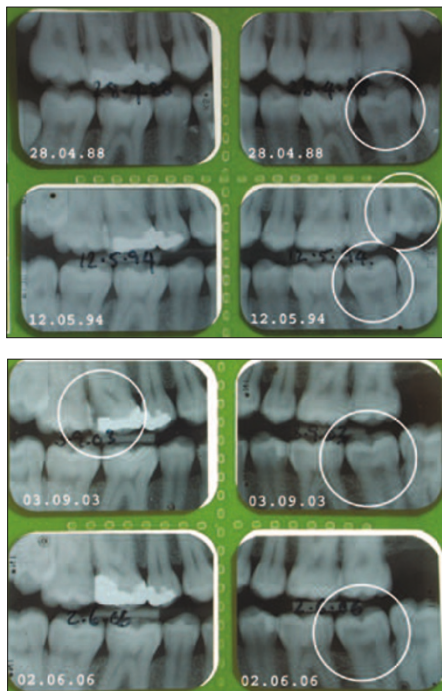
I wondered what the evidence was for this. I present the case of a patient for whom I provided a sealant on a lower left second molar in April 1988, in the presence of fairly advanced occlusal caries – see bitewing radiographs (Figs 1-2). The patient, a then 17-year-old male, has attended irregularly since and cheerfully admits 'not to like the dentist'.

Further sequential bitewing radiographs were taken on the occasions that the patient attended for the following episodes of his dental history illustrating active caries and disease in other teeth:

May 1994 – patient attended with carious broken down upper left third molar which was extracted LA.

June 1998 – attended with LL5 distal caries (new cavity) and fractured marginal ridge restored with direct composite resin.

September 2003 – attended with UR6 deep distal caries (new cavity) and marginal ridge breakdown. Temporary dressing placed after caries excavation LA. Tooth subsequently restored with pin



Figs 1-2 Bitewing radiographs.

retained amalgam. Evidence of occlusal caries developing in two lower wisdom teeth noted, treatment declined.

June 2006 – attended with chronic pericoronitis at UR8. Extraction of UR8 declined.

Referring to the radiographs, I am unable to detect any progress of the carious lesion at LL7 over the 18-year period. During this time one wisdom tooth required extraction and two other teeth required restoration. Each of these teeth had developed a carious lesion at a previously unrestored surface.

Referring to Messrs Roberts and Attari's letter again, I submit that in my patient's case, there is good clinical evidence (albeit not a clinical trial) that a sealant provided for occlusal caries in the presence of advanced caries into dentine, has arrested the caries over an 18-year period. Surely, one might ask, if the pulp was supplying the substrate for the caries, then pulpal exposure would have been expected by now?

A. M. Lester

Basingstoke

doi: 10.1038/sj.bdj.4814002

## Sincere concerns

Sir, I feel I must challenge the introduction of Professor Becker's fifth article, in his otherwise excellent series on dental implants (*BDJ* 2006; 201: 199-205).

The inference from the opening paragraph is that there is no place for root amputations, hemisections, etc, in general dental practice. Nothing is further from the truth.

In my 35 years in dental practice, I have often used these simple procedures to maintain an otherwise severely compromised tooth. Frequently these inexpensive procedures were carried out for patients of limited means, and where very expensive implant fixtures would have been out of the question.

I remember a similar discussion and correspondence many moons ago when overdentures were revisited. I have sincere and serious concerns about some 'modern' attitudes. The old ways are not always the best ways, nor are the new ways, but let's have reasoned, balanced evidence based opinion.

C. Emery

Portsmouth

doi: 10.1038/sj.bdj.4814039

## Grass roots observation

Sir, aren't science and 'evidence based dentistry' wonderful? If you want an argument, ask a scientist, but if you want to treat a patient, ask a practitioner.

While I appreciate the science behind Dr Zadik's letter (*BDJ* 2006; 201: 2) I am afraid he has missed the point of

my observations (*BDJ* 2004; 196: 515 and *BDJ* 2006; 200: 363). Of course I have been more than willing to follow the theoretical practice of not using any antibiotics postoperatively or of using a full five or seven days' course of antibiotics postoperatively, both of which he suggests. Unfortunately when I have tried either in the past, I occasionally had a patient return with post-operative infection.

The point of my letters (and apparently also of Dr Williams') is that since using single dose 200 mg metronidazole, I have had not a single case of postoperative infection. Why this is may be a mystery, but just because he says science states that it cannot occur, does not mean it is untrue.

I can only suggest (as I did back in 2004) that some oral surgery unit needs to take this on as a full time research project, and publish its findings in time. Theoretical science is all very well, but contrary to Dr Zadik's suggestion, just occasionally you have to be open minded enough to use observation at grass roots level. Otherwise none of us would accept that the theoretically impossible flight of the bumble bee does actually occur – would we?

R. Kitchen JP

Bristol

doi: 10.1038/sj.bdj.4814003

## Dental Letters

Sir, as an old and long retired member of the dental profession may I say how thrilled I have been to see the mass of movement of dentists from the NHS to independent practice? May this continue apace.

Over 50 years the damage successive governments have caused to dentistry is quite shocking. Most of it in an effort to save public finance at our expense. I do not believe that their latest effort is any less destructive.

For those who do not remember, perhaps I should point out that prior to the NHS the National Health Insurance provided 'Dental Letters' to the poorer members of the public so that they could reclaim part of the cost of their treatment by the then private practitioners. I believe most of us were happy to accept this. Perhaps something like this could happen again. Perhaps, to begin with, it might be popular in areas where there are no longer any NHS dentists. Our negotiators would be accused of insatiable greed.

I congratulate all who have left the NHS. I enjoy the envy of friends who are medical GPs!

W. J. M. Hale

Plymouth

doi: 10.1038/sj.bdj.4814004