IN BRIEF

- The development of buccal bone exostoses subsequent to free gingival grafts has been reported in a small number of cases since 1991, when the first two cases were described.
- The most recent five cases reported in the literature were published in periodontal journals.
- This case report may help dentists recognise the unusual condition.
- No previous case reports have involved teeth that have also been supporting fixed or removable prostheses.

Bony exostoses developed subsequent to free gingival grafts: case series

L. A. Chambrone[1] and L. Chambrone[2]

Bony exostosis (BE) is described as a benign localised overgrowth of bone of unknown aetiology. Buccal bony exostosis (BBE) development secondary to soft tissue graft procedures has been reported in a small number of cases. The dental literature describes BBE development also at sites where free gingival grafts (FGG) have been used to increase the amount of gingiva. The following case series describes BBE development at nine sites (five cases) at which FGG was performed to increase the width of the attached gingiva. The presence of exostoses has been recognised during postoperative visits. Histological examination revealed osseous enlargements compatible with the diagnosis of exostoses at two re-entry procedures. In conclusion, based on previous reports, periosteal trauma, eg fenestration, seems to be the main aetiologic agent associated with the development of BBE in areas where FGG were placed.

Bony exostosis (BE) is described as an unknown aetiology peripheral localised benign bone overgrowth, with a base continuous to the original bone and which seems to have a nodular, flat or pedunculate protuberance[1] located on the jawbone's alveolar surface.[2] Different exostoses species can generally be found during the periodontal examination, eg mandibular tori, palatal tori, palatal alveolar exostoses and multiple exostoses. Mandibular tori were observed in more than a quarter of modern dry skulls and palatal alveolar exostoses in more than a half.[3] Both BE species may be found more usually in young male dentate subjects, probably from alveolar bone origin.[3] Multiple exostoses are found somewhat less usually than mandibular tori or palatal alveolar exostoses on the maxillary buccal surface below the mucobuccal fold in the molar region.[4] Other types of BE have been found over the past years associated with unusual postoperative conditions.

Buccal bony exostosis (BBE) development secondary to soft tissue graft procedures has been reported in a small number of cases, eg as a consequence of shallow vestibules increasing with the use of skin grafts[5,6] or subsequent connective tissue graft.[7] The periodontal literature describes BBE development also at sites where free gingival grafts (FGG) have been used to increase the amount of gingiva (Pack *et al.*[8] two cases; Efeoglu and Demiel[9] two cases; Czuszak *et al.*[10] one case; Otero-Cogide *et al.*[11] nine cases; and Echeverria *et al.*[12] one case). (Table 1)

The main BBE causing agents are unclear, but all previous reports have been unanimous in suggesting that periosteal trauma seems to be associated with such exostoses development.[5-12]

The following case series describes the BBE development at nine sites (five cases) of previous FGG performed to increase the width of the attached gingiva. All surgeries were achieved by accidental or intentional periosteal fenestration of the receipt sites.

CASE 1

In 1979, a healthy 50-year-old female patient had an FGG placed on the buccal level 44-45 area, to increase the attached gingiva width prior to a prosthetic treatment with a fixed cantilever partial denture. Five years later it was noticed that the graft was presenting a discreet progressive enlargement. In 1994, 15 years later, the patient requested correction of the area. The site was painless and very hard on palpation (Fig.1) and had a dense radiographic appearance (Fig. 2).

Fig. 1 Pronounced exostosis at FGG site in case 1

[1*]Professor and Chair, Periodontics, Faculty of Dentistry, Methodist University of São Paulo (UMESP), São Bernardo do Campo, Brazil; [2]Volunteer Assistant Professor, Periodontics, Faculty of Dentistry, Methodist University of São Paulo (UMESP), São Bernardo do Campo, Brazil
*Correspondence to: Dr Luiz Armando Chambrone, Rua Cristianópolis, 220 São Paulo SP 03128-030, Brasil
Email: luiz.chambrone@metodista.br

Refereed Paper
Received 30.09.04; Accepted 09.02.05
doi: 10.1038/sj.bdj.4812571

Table 1 Development of exostoses following free gingival grafts: case reports

Reference	Age when graft placed	Gender	Date of surgery	Location	Toris Presence	Time since graft
Pack *et al* 1991 14	36	F	1977	33-34*	mandible	09 years
	26	F	1977	34-35	absent	11 years
Efeoglu & Demirel 1994 [15]	17	F	N/R	43*	absent	06 years
	23	F	N/R	32-33	absent	01 year
Czuszak *et al* 1996 [16]	17	F	1977	34-35	absent	17 years
Otero-Cagide et al 1996 [17]	23	F	1980	14*; 24; 31-41	mandible	14 years
	22	F	1976	33-34*; 43-44	absent	16 years
	26	F	N/R	33-34	maxilla	05 years
	18	F	N/R	33-34	absent	07 years
	30	F	N/R	13; 23-24	absent	02 years
	20	M	N/R	13; 23; 33; 43	absent	10 years
	19	F	N/R	34	absent	05 years
	19	F	N/R	23	absent	15 years
	24	F	N/R	14	absent	16 years
Echeverria *et al* 2002 [18]	23	F	1980	33-34	absent	19 years
This report	50	F	1979	33-34	absent	19 years
	17	M	1978	14-15; 24-25; 34; 43	absent	24 years
	37	F	1975	44	absent	26 years
	34	F	1986	33-35; 43	absent	15 years
	31	F	1987	43-44; 31-41*	absent	14 years
Comments	Mean age: 25.6	18 female (90%) 2 male (10%)		5 incisors (10%) 20 canines (40%) 25 premolars (50%)	15% of patients with torisa	

N/R = Not related
*Re-entry sites

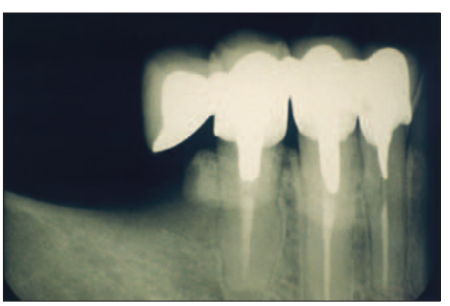

Fig. 2 Increased radiopacity at FGG site in case 1

Full thickness flap elevation revealed the presence of a nodular osseous area. Collected bone was sent for a histological examination, revealing a very dense lamellar bone formation compatible to the exostosis diagnosis (Fig. 3). Healing occurred uneventfully. The patient was continuously observed until 2001.

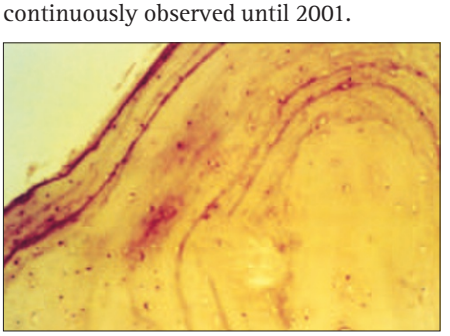

Fig. 3 Histological examination from the FGG site in case 1

During the surgical procedure, a small accidental incision occurred at the periosteum over the root surface (tooth 43) of the receipt site (Fig. 4). Re-entry procedures showed the root surface recovered by bone proceeding from the exostosis.

Fig. 4 Accidental periosteal fenestration at FGG site in case 1

CASE 2

In 1978 a 17-year-old male patient presented four aberrant frenums attached near to the gingival margin, buccally adjacent to teeth 15-14, 24-25, 34-43 and 44. Frenectomy technique was performed associated with free gingival grafts. Throughout the postoperative years a slow exostosis in the previously grafted sites was noticed (Figs 5-8). These areas had been presenting increased volume, hard density on palpation and also painless conditions; radiographic assessment revealed an increased radiopacity area related to teeth 24-25. The patient did not present toris mandibularis or toris palatinus. He was aware of these clinical findings but he did not wish to have them removed.

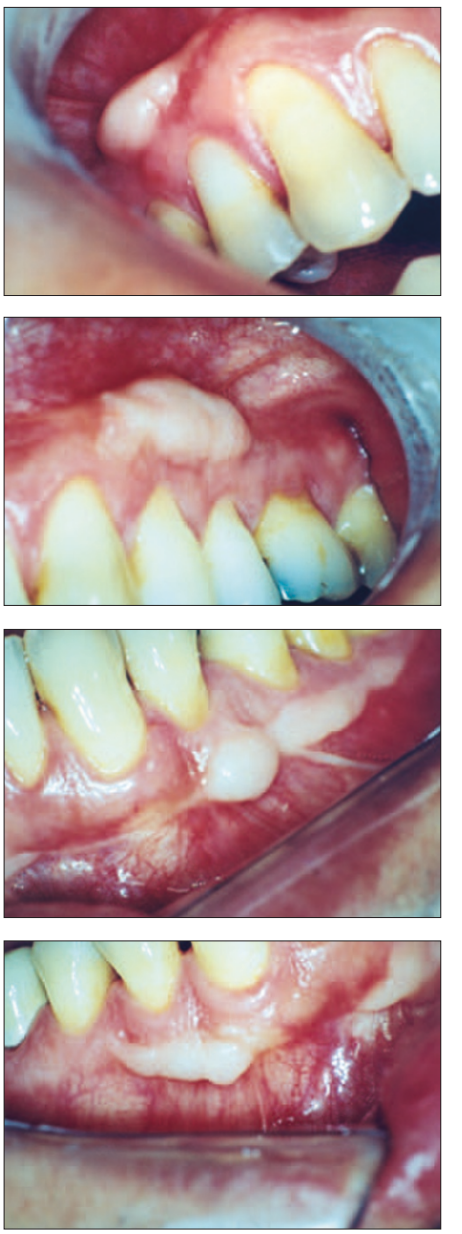

Figs 5, 6, 7 and 8 (top to bottom) Clinical appearance of bony exostosis at FGG site in case 2

CASE 3

In 1975 a 37-year-old female patient underwent two FGG involving the buccal surface of teeth 33-35 and 43 to increase the attached gingival width prior to prosthetic crowns fabrication and a partial removable denture with free-end denture bases. Throughout the following 26-year period a very slow and gradual increase in the area had been noticed, painless, hard on palpation – and radiograph assessment revealed increased radiopacity. The patient was satisfied with the results and did not wish to have them corrected.

CASE 4

In 1986 a healthy 34-year-old female received an FGG at the buccal area of teeth 43 and 44 to increase the keratinised gingiva associated with frenectomy to remove

a high frenum inserted close to the free gingival margin.

A linear fenestration was performed in the receipt site periosteum where the frenum was inserted. The clinical result was excellent, however the grafted area volume increased in the following years, presenting a larger hard consistent painless enlargement over the corresponding area. Since the patient was unconcerned, the BE was not removed.

CASE 5

A 31-year-old woman was referred to our private dental office presenting with the lower lip frenum insertion close to the lower incisors' papillae, 31-41, and a narrow attached gingival zone. In 1987, frenectomy with linear periosteal fenestration was accomplished to remove the muscle insertions in association with an FGG. Healing followed uneventfully and a wide keratinised gingiva was obtained. The grafted area maintained a healthy aspect, but with a slow and progressive volume increased over the time. After 14 years, in 2001, in the exact area of the periosteum fenestration, an enlargement was clearly evident. Flap reflection showed quite a resistant compact bone formation which was partially removed. Histological examination confirmed the exostosis diagnosis.

DISCUSSION

BBE development subsequent to free gingival grafts has been reported in a small number of cases,[8-12] since 1991 when the first two cases were described.[8]

The authors suggest that patients presenting toris or any kind of BE are highly susceptible to bony overgrowth responses. Another four reports have been adding hypotheses and clinical characteristics to this uncommon osseous proliferation. Efeoglu and Demirel[9] state that '*it is also possible that other clinicians might have assumed the thick gingival grafts they saw during their patients' postoperative visits were not thick soft tissue grafts, but were, in reality, exostoses*.' Czuszak *et al.*[10] suggested that this exostoses development may be coincidental and not due to FGG. Otero-Cagide *et al.*[11] speculated that the bone formation after an FGG may be the result of a periosteal trauma combination during site preparation and the activation of osteoprecursor cells contained in the connective tissue of the graft. Echeverria *et al.*[12] previously noticed that the total exostoses that have been related after an autogenous FGG were located in the cuspid-premolar area. They suggested that the grafted areas may be influenced by factors acting at this level, eg excessive forces, surgical trauma and genetic factors.[12]

Among the related reports, all the authors suggest that the periosteal trauma seemed to be the main aetiological agent associated with the exostosis development.[5-12] In cases of skin grafts, the occurrence of periosteum fenestration after the graft suture position has also been observed. This surgical trauma can be associated with the liberation of osteoprogenitor cells from the periosteum-bone interface inducing osteogenesis.[6] We are in agreement with this because at our nine reported sites this osseous formation has been verified after surgical procedures in which periosteal trauma occurred, eg periosteal fenestration. At the first presented case the root was exposed and the exostosis covered the fenestration.

Frenectomies were achieved through linear receipt site periosteum fenestrations,[13,16] with high muscle inserts removal in association with autogenous FGG placed over the fenestrated areas, when frenum attachments were toward the marginal gingiva interfering in oral hygiene. The majority of exostoses have been found in these areas. It is possible that when we were trying to leave the receipt site free from elastic fibres and muscle inserts (preparing the appropriate bed for the graft), micro-fenestrations may have occurred, and consequently, may have also stimulated the exostosis formation. It can be observed among the cases reported in the literature[8-12] that the areas operated on have corresponded in the majority of cases, to muscle insert location areas (Table 1). Accidental lesions may probably stimulate the bony formation development. In our five cases, these osseous formation developments have always been related with accidental or intentional periosteal fenestrations. However, bony overgrowth can be seen in three of these cases covering tooth roots that have been supporting fixed and removable prostheses.

The concept that BE formation can occur in response to heavy occlusal forces with the purpose of reinforcing bone trabeculae, was initially described by Glickman and Smulow.[17] This new bone formation, providing buttressing, was divided into exostosis and lippings. A previous study investigated the prevalence, characteristics and evidence for BBE or lippings formation in a sample of 416 selected teeth in 52 modern skeletal specimens.[18] BBE and lippings were found at 7% and 17.6% respectively (adjacent to 25% of teeth).[18] BBE were mainly observed around the upper premolar-molar area, especially in males. Lippings were seen in lower incisors, premolars and molars, with no gender distribution. However, the authors suggest that 'other factors may be of greater importance in the aetiology of buccal bone enlargements'.[18]

Case reports of benign osseous proliferation beneath posterior fixed partial denture pontics have been related in the dental literature.[19-25] As aetiological agents we (the authors) suggest genetic factors, functional stresses and chronic irritation. Two patients (cases 3 and 5) had the graft areas associated with teeth that have been supporting removable partial dentures; the other one (case 1), to teeth that had been supporting a cantilever. It is possible that the combination of periosteal (fenestration) and occlusal function (as a low-grade irritation) is responsible for this osseous proliferation.

Clinically, a review of the published reports (Table 1) suggested that canines and premolars, 89.8%, are more susceptible to BBE development. This fact was also observed by Echeverria *et al.*[12] On the other hand, reasons for BE formation are more speculative. As previously mentioned, there have been patients who have developed BBE in the presence of other extraoral exostoses, as well. However, it should be noticed that intraoral toris were only observed in 15% of all subjects (Table 1). Sonnier *et al.*[3] observed that palatal alveolar exostoses and mandibular tori can be found more often in young male dentate subjects (suggestive of alveolar bone origin). In contrast, the collective results from published case reports and the findings of the present paper (Table 1) indicate that 90% of the 20 subjects, who presented BBE after FGG, are females. Despite these differences, the development of such osseous overgrowths may be associated with the presence of teeth and their surrounding periodontal structures.

CONCLUSION

In conclusion, based on previous reports, periosteal trauma, eg fenestration, seems to be the main aetiologic agent associated with BBE development in areas where an autogenous FGG was placed. However, other stimuli alone, or in combination acting at this level, eg functional stresses and genetic factors, particularly in autogenous grafts, are of special interest. Thus, clinical studies with larger samples are needed to establish whether periosteal fenestration is the main aetiologic agent. Another sample of patients who underwent FFG and periosteum linear fenestration has been showing discreet clinical signs of exostosis formation, which will be confirmed by future postoperative visits.

1. Stafne E C, Gibilisco J A. *Oral roentgenographic diagnosis.* 4th ed. pp 189-191. Philadelphia: W B Saunders Company, 1975.
2. Eversole L R. Clinical outline of oral pathology: Diagnosis and treatment. pp 96. Philadelphia: Lea & Febiger, 1978.

3. Sonnier K E, Horning G M, Cohen M E. Palatal tubercles, palatal tori, and mandibular tori: prevalence and anatomical features in a U.S. population. *J Periodontol* 1999; **70:** 329-336.
4. Shafer W G, Hine M K, Levy B M. *A textbook of oral pathology.* 2nd ed. pp137. Philadelphia: W B Saunders Company, 1963.
5. Siegel W M, Pappas J R. Development of exostoses following skins grafts vestibuloplasty: report of a case. *J Oral Maxillofac Surg* 1986; **44:** 483-484.
6. Hegtvedt A K, Terry B C, Burkes E J, Patty S R. Skin graft vestibuloplasty exostosis. A report of two cases. *Oral Surg Oral Med Oral Pathol* 1990; **69:** 149-152.
7. Corsair A J, Iacono V J, Moss S S. Exostosis following a subepithelial connective tissue graft. *J Int Acad Periodontol* 2001; **3:** 38-41.
8. Pack A R C, Gaudie W M, Jennings A M. Bony exostosis as a sequela to free gingival grafting: two case reports. *J Periodontol* 1991; **62:** 269-271.
9. Efeoglu A, Demirel K. A further report of bony exostosis occurring as a sequela to free gingival grafts. *Periodont Clin Investig* 1994; **16:** 20-22.
10. Czuszak C A, Tolson I V, Kudryk V L, Hanson B S, Billman M A. Development of an exostosis following a free gingival graft: case report. *J Periodontol* 1996; **67:** 250-253.
11. Otero-Cagide F J, Singer D L, Hoover J N. Exostosis associated with autogenous gingival grafts: a report of nine cases. *J Periodontol* 1996; **67:** 611-616.
12. Echeverria J J, Montero M, Abad D, Gay C. Exostosis following a free gingival graft. *J Clin Periodontol* 2002; **29:** 474-477.
13. Robinson R E. Mucogingival junction surgery. *J Calif Dent Ass* 1957; **33:** 379-385.
14. Robinson R E. Periosteal fenestration in mucogingival surgery. *J West Soc Periodont* 1961; **9:** 107-111.
15. Carranza Hijo F A, Carraro J J, Dotto C A, Cabrini R L. Effect of periosteal fenestration in gingival extension operations. *J Periodontol* 1966; **37:** 335-340.
16. Sarian R, Leite Neto J P. Experimental muco-gingival surgery in dogs: periosteum linear fenestration compared with sutured muco-periosteum (in Portuguese). *Rev Fac Odont S Paulo* 1974; **12:** 33-42.
17. Glickman I, Smulow J B. Buttressing bone formation in the periodontium. *J Periodontol* 1965; **36:** 365-370.
18. Horning G M, Cohen M E, Neils T A. Buccal Alveolar exostoses: prevalence, characteristics, and evidence for buttressing bone formation. *J Periodontol* 2000; **71:** 1032-1042.
19. Burkes E J Jr, Marbry D L, Brooks R E. Subpontic osseous proliferation. *J Prosthet Dent* 1985; **53:** 780-785.
20. Morton T H Jr, Natkin E. Hyperostosis and fixed partial denture pontics: report of 16 patients and review of literature. *J Prosthet Dent* 1990; **64:** 539-547.
21. Ruffin S A, Waldrop T C, Aufdemorte T B. Diagnosis and treatment of subpontic osseous hyperplasia. Report of a case. *Oral Surg Oral Med Oral Pathol* 1993; **76:** 68-72.
22. Mesaros A J Jr, Evans D B. Subpontic osseous hyperplasia. *Gen Dent* 1994; **42:** 264-266.
23. Daniels W C. Subpontic osseous hyperplasia: a five-patient report. *J Prosthodont* 1997; **6:** 137-143
24. Lorenzana E R, Hallmon W W. Subpontic osseous hyperplasia: a case report. *Quint Int* 2000; **31:** 57-61.
25. Frazier K B, Baker P S, Abdelsayed R, Potter B. A case report of subpontic osseous hyperplasia in the maxillary arch. *Oral Surg Oral Med Oral Pathol Oral Radiol Endod* 2000; **89:** 73-76.