

Send your research letters to the editor,
British Dental Journal, 64 Wimpole Street,
London W1G 8YS E-mail bdj@bda.dentistry.org.uk.

Priority will be given to letters less than 500 words long. Authors must sign the letter, which may be edited for reasons of space.



Oral & maxillofacial services

Sir, the British Association of Oral and Maxillofacial Surgeons (BAOMS) are one of many organisations that have been invited to respond to the consultative phase of the General Dental Council's review of its specialist lists. In order to inform their response the information sub-committee of BAOMS felt it would be helpful to obtain some data regarding current oral and maxillofacial services. We thought a summary of the results might be of interest to your readership.

Three-quarters of practising oral and maxillofacial surgeons (235 of an estimated 313 in England, Scotland and Wales) replied to a questionnaire distributed by letter, email and telephone. Thirteen vacant consultant posts were identified in the units served by this group. Whilst 33 treatment waiting lists exceeded the relevant government targets, 31 of these (98%) were confined to dento-alveolar surgery. Programme trainers reported that 11 (9%) of 121 specialist registrar posts were unfilled.

In a separate questionnaire information regarding the scope of practice of 197 Staff Grades and Associate Specialists in the specialty was sought. A total of 97 (49%) exclusively carried out dento-alveolar surgery with another 70 (36%) also being involved in the occasional management of some simple hard tissue trauma. Only 13 (7%) were involved in more complex surgical procedures.

We hope that this information will prove useful in the continuing review process. Any revision or reconfiguration of the specialist lists will presumably take into account the current delivery of the service and the best way to answer the actual needs of patients. Further information about BAOMS can be obtained through the website www.baoms.org.uk or by emailing office@baoms.org.uk.

B. Avery

C. Kerawala

A. E. Brown

London

doi:10.1038/sj.bdj.4812478

Periodontology in the UK

Sir, we read with interest the opinion of Dr van Steenberghe (*BDJ* 2005; 198: 187) regarding Mike Grace's leader (*BDJ* 2004; 197: 111) about a BDA survey question on periodontology in the UK.

As an academic, Dr van Steenberghe will doubtless be aware that the survey response rate of 19% (to which Dr Grace drew attention) would render any scientific study unpublishable. An acceptable rate from which to draw inferences would be around 80% or upwards. Dr Grace was simply using the findings as a literary device to make a point about a subject dear to his heart.

Dr van Steenberghe can rest assured that there is hope for periodontology in the UK, which is one of few countries with a list of nationally recognised specialists. Implant treatment planning and surgery are a routine part of UK periodontal practice, and although we also have recognised specialists in oral medicine, periodontists may diagnose and treat gingival conditions which might come under this heading.

As consultants in the largest UK periodontal department, we find an exceptional level of interest in our undergraduates, particularly in the fourth year when they have their major exposure to the subject. Our postgraduate courses are renowned in many countries, and we also started the first UK full specialist training course in the subject. Foreign governments frequently want their specialists trained here, but regrettably we have to turn away many promising postgraduate applicants each year because of a lack of space. Other UK periodontal departments report similar experiences. In short, the interest in the subject is considerable.

Furthermore, the British Society of Periodontology (BSP) is more active than it has ever been, and many well-attended events are arranged around the UK each year, in addition to the spring and autumn meetings.

T. L. P. Watts

(President-Elect BSP)

M. Ide (Honorary Secretary BSP)

London

doi:10.1038/sj.bdj.4812479

Dental irrigators

Sir, I must concur with P. T.

Blenkinsopp's letter (*BDJ* 2005; 198: 385) regarding the ready availability and promotion of dental irrigators in the UK. At the BDA Conference in 2004, Dr Philip Preshaw's Talking Points in Dentistry lecture on 'Full mouth disinfection' recommended subgingival irrigation with chlorhexidine immediately after full and thorough scaling. He suggested the cleaning should be completed in the minimum time from start to finish when two or more appointments were required for periodontal treatment, the recommended chlorhexidine irrigation being used to minimise the recolonisation of any remaining pathogenic microbial flora to the freshly scaled crevices and pockets. Continued use of irrigation at home would complete the treatment to a more satisfactory level. Unfortunately, chlorhexidine has well known disadvantages when used for any length of time.

While irrigation does reduce the debris and loose bacterial content of the interdental spaces and crevices, adding mouthwash does little to reduce the pathogenic microbial biofilms. US firm Aloe Vera of America, Inc commissioned bacteriological studies for their newly developed stabilised aloe vera in the 1970s and 1980s. Their patented stabilisation process kept the bio-activity the same as that of the freshly cut aloe leaves. This process prevented the destructive oxidation of the beneficial properties of the inner gel. Their investigations showed that *Streptococcus mutans* and its biofilm, when immersed in high concentrations of the stabilised aloe vera, literally came away from the hard tissue surface of the tooth, and subsequent regrowth was suppressed. With the biofilm gone, plaque and calculus did not develop. The company found that a number of other periodontal pathogens were similarly affected. Irrigation was the vehicle of choice in delivering the stabilised aloe vera into the crevice and pocket areas. Also noted

were the anti-inflammatory and desensitisation benefits of the plant material to the adjacent tissues. Suitable irrigators such as the Water Pik should be promoted and be more widely available, as they are another excellent aid in the treatment and management of periodontal disease. Suitable additives to the irrigation fluid can actively prevent or minimise the destructive actions of pathogenic microbial flora in the oral environment. The message is wipe and wash, or tape and irrigate.

G. C. Leigh

Somerset

doi:10.1038/sj.bdj.4812480

Endodontics series

Sir, thank you for your recent series of articles on endodontics. I found them fascinating and informative. I have been in practice for more than 30 years and after reading only the first two articles, I changed my views, so much so, that I have completely embraced this technique and have yet to have a failure.

I am led to believe that the average *Streptococcus Viridans* is about one micron in diameter. With this in mind I began wondering about the nature of apical obturation, since how can we be absolutely certain the canal is sealed? Also, bearing in mind the possibility of lateral canals, indeed the certainty of their existence, are we not in a similar position to the farmer trying to keep harvest mice out of his cornfield with hedges instead of a solid steel wall?

This analogy shows that Dr Carrotte's series of articles are bang on the money, in that access and complete disinfection of the canal is paramount. I also feel that we can give ourselves a false sense of security when we review a root filling with a post operative radiograph showing the filling to the apex, if this therapy has not included a thorough debridement, and a copious irrigation of the canal with sodium hyperchlorite.

If the observations on the size of bacteria are correct, do radiographs really tell us if we have reached the apex? Let's say we are 1/100th of an inch short, could we really detect this on an ordinary periapical, chemical or digital, even with a decent amount of magnification? Bringing the microorganism to a human scale, this distance would roughly equal the Mersey Tunnel and how many people could stand in that?

In addition, it has long been my belief that x-rays travel in straight lines, and

because of this, the following scenario is possible. Figure 1 shows an ideal root canal filling (RCF) in an upper incisor with the beam passing through the root in a bucco-palatal direction. Figure 2 shows a similar tooth, but this time the RCF is approximately 1mm short of the apex. Figure 3 shows the same tooth but this time the beam travels in the mesio-distal direction. *Quod erat demonstrandum!* Sometimes I really wish I had the same optical capabilities as superman!

P. Jeavons

Sutton-in-Ashfield

doi:10.1038/sj.bdj.4812481

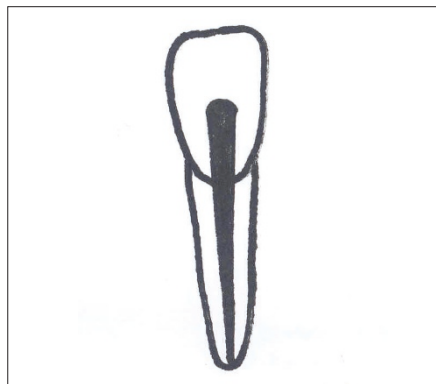

Figure 1

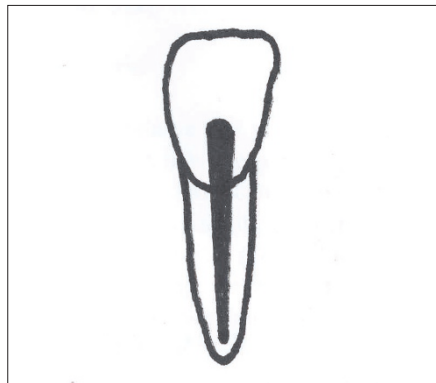


Figure 2

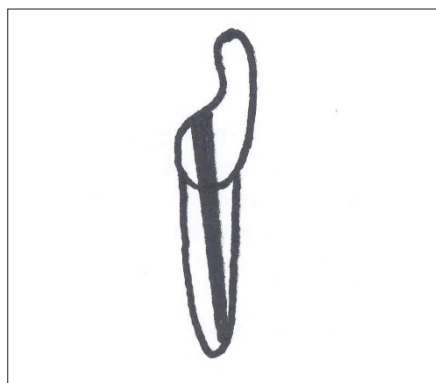


Figure 3