Modern Pathology (2007) 20, 905–913

www.modernpathology.org

EGFR expression as an ancillary tool for diagnosing lung cancer in cytology specimens

Eric X Wei[1], Amal A Anga[2], Sherry S Martin[2], Joyce G Jackson[2], Mary L Nordberg[2,3], Guillermo A Herrera[4] and Elba A Turbat-Herrera[4]

[1]*Department of Hematopathology, University of Texas, MD Anderson Cancer Center, Houston, TX, USA;* [2]*Department of Pathology, Louisiana State University Health Sciences Center, Shreveport, LA, USA;* [3]*Feist–Weiller Cancer Center, Louisiana State University Health Sciences Center, Shreveport, LA, USA and* [4]*Department of Pathology, Saint Louis University, Saint Louis, MO, USA*

Lung cancer evolves in a multistep process, and its early detection portends a better prognosis. Bronchial washings/brushings and fine-needle aspirations are often used as early screening and cytological diagnosis of lung cancer. In some cases, it is difficult to differentiate morphologically malignant from reactive cells. Epidermal growth factor receptor (EGFR) is a transmembrane receptor overexpressed in high percentage lung cancers, and contributes to tumor growth. Assessing EGFR expression levels by fluorescence *in situ* hybridization (FISH) and immunohistochemistry (IHC) may provide critical information of tumor marker abnormalities, assist in the cytological diagnosis, and stratify patients for EGFR inhibitor therapy. Fifty patients with bronchial washings/brushings or fine-needle aspiration specimens, and corresponding histologically confirmed lung biopsies, were studied for EGFR expression with FISH and IHC. Copy numbers of the EGFR gene locus were analyzed with those of chromosome 7 by FISH. EGFR and FISH results were compared to our FISH data with combined EGFR, c-myc, 5p15.2, and chromosome 6 probes in selected cases. Cell blocks, if available, and tissue biopsy sections were used for EGFR IHC. The intensity of IHC was scored, and quantified. Only balanced aneuploidy of EGFR was identified by FISH. Gene amplification was not detected. The chromosomal abnormalities of EGFR were often accompanied by other chromosomal aneuploidies demonstrated in c-myc (8q24), 5p15.2 or 6p, indicating a general genomic instability. About half of the specimens with confirmed malignancy showed EGFR balanced aneuploidy by FISH, and gene copy number was not coupled with protein expression in many cases. The benign or reactive cytology specimens confirmed by biopsies had high specificity by FISH (96%) and IHC (88%). FISH and IHC analysis of EGFR, possibly along with other tumor markers, may be a useful ancillary tool to classify difficult cytology cases and inform clinicians arranging targeted chemotherapy.
Modern Pathology (2007) **20,** 905–913; doi:10.1038/modpathol.3800939; published online 20 July 2007

Keywords: EGFR; lung carcinoma; cytology; FISH; diagnosis

Lung cancer claims the highest cancer-related mortality rate among men and women in the United States. More individuals die of lung cancer than those of colon, breast, and prostate cancer combined. The majority of lung cancer patients present at an advanced stage. Lung cancer can be broadly divided into small cell carcinoma, squamous cell carcinoma, adenocarcinoma, and large cell carcinoma,[1–3] which includes neuroendocrine large cell carcinoma. Some cases may reveal mixed phenotypes, that is, adenosquamous carcinoma. Lung cancer evolves in a multistep process.[2] Squamous cell carcinoma of the lung starts from bronchial epithelial dysplasia, to carcinoma *in situ*, to invasive carcinoma.[3] Adenocarcinoma may have atypical adenomatous hyperplasia as a premalignant condition.[3] Detection of lung cancer at its early stage or precursor lesion portends a better prognosis.

Bronchial washings/brushings and fine-needle aspirations are often used as early screenings for cytological diagnoses of lung cancer. Sometimes, it is difficult to differentiate morphologically malignant from reactive cells. Chronic granulomatous inflammation or fungal infection may cause atypical squamous metaplasia, which resembles squamous cell carcinoma.[4,5] Reactive type II pneumocytes

Correspondence: Dr EX Wei, MD, PhD, Department of Hematopathology, The University of Texas MD Anderson Cancer Center, 1515 Holcombe Boulevard, Houston, TX 77030, USA.
E-mail: ericxwei@yahoo.com
Presented as an abstract at the United States and Canadian Academy of Pathology annual meeting in Atlanta, GA in 2006. Dr EX Wei received the Pathologist-in-Training Outstanding Presentation Award by Papanicolaou Society of Cytopathology.
Received 6 February 2007; revised 18 April 2007; accepted 7 May 2007; published online 20 July 2007

mimic bronchioloalveolar carcinoma, atypical bronchial epithelial cells in a pulmonary infarct may look like adenocarcinoma,[4] and reserve cell hyperplasia may be confused with small cell carcinoma. Although experienced cytopathologists can correctly separate benign from malignant conditions most of the time, some controversial or atypical cases may require ancillary studies to make a definitive diagnosis. Molecular techniques have been used to identify genetic changes in tumor cells and may help clarify the diagnoses. Chromosomal instability, loss of heterozygosity, and failure of cell-cycle checkpoint controls are involved in tumorigenesis of lung cancer.[3] Various oncogenes and tumor suppressor genes participate in the molecular pathway of tumor progression.

Epidermal growth factor receptor (EGFR) is a transmembrane receptor overexpressed in a certain percentage of lung carcinomas, and contributes to tumor growth. The gene resides on chromosome 7p12, encoding a 170 kDa membrane-associated glycoprotein. Upon binding its ligand, it dimerizes, autophosphorylates itself, and initiates a signal transduction cascade.[2,6] It is reported to be occasionally mutated and/or amplified in lung carcinoma. Assessing EGFR expression levels by fluorescence *in situ* hybridization (FISH) and immunohistochemistry (IHC) may provide critical information by detecting tumor marker abnormalities, assist in the cytologic diagnosis, and select patients for EGFR inhibitor therapy.

In this study, 50 patients with bronchial washings/brushings or fine-needle aspiration specimens and corresponding histologically confirmed lung biopsies were examined. Cytology samples were studied for EGFR expression by FISH and IHC. Copy numbers of the EGFR gene locus and their correlations with its protein expression were studied. Selected cases were also tested with combined EGFR, c-myc, 5p15.2, and centromere of chromosome 6 probes. Cell blocks, if available, and surgical biopsy sections were used for detection of EGFR protein expression.

Materials and methods

Cytology Specimens

Fifty patients with bronchial washings/brushings or fine-needle aspiration specimens and corresponding histologically confirmed lung biopsies were studied for EGFR expression by FISH and IHC. The patients were seen at the Louisiana State University Health Sciences Center in Shreveport, LA as inpatients or in the outpatient clinics between the years 2004 and 2006. The classification of diseases was based on final surgical biopsies performed usually at the same time as cytology specimens. Among them, 25 patients were negative for malignancy or reactive with inflammation, and squamous metaplasia; the other 25 patients were positive for primary lung squamous cell carcinoma, adenocarcinoma, adenosquamous carcinoma, or poorly differentiated carcinoma. The cytology specimens were stained with Papanicolaou and/or Diff-Quik method. Cell blocks and surgical biopsies were formalin-fixed and paraffin-embedded. The corresponding surgical pathology slides were stained with hematoxylin and eosin. In a few cases, special histochemical stains such as mucicarmine were used to aid in the classification of these tumors. Immunohistochemical studies were used when needed for further classification.

DNA Probes

FISH studies were initiated using a standard procedure with fluorescent-labeled dual-colored probes (LSI EGFR/CEP7™ Vysis, Downers Grove, IL, USA). A SpectrumRed™-labeled EGFR-specific probe hybridizes to the EGFR locus on chromosome 7 at 7p12; and a SpectrumGreen™-labeled centromeric probe binds to the centromere of chromosome 7 as a control to normalize copy numbers. At least 30 cells selected from four different areas were analyzed by two independent readers. Amplification is determined as a ratio of EGFR to centromere of chromosome 7 signal of two or more per cell. Selected cases were also tested with combined probes, 7p12 (LSI™EGFR holding the EGFR gene, labeled with SpectrumRed), 8q24 (LSI™MYC containing c-myc gene, marked with SpectrumGold™), 5p15.2 (LSI™5p15 SpectrumGreen) and centromere of chromosome 6 (CEP™6 SpectrumAqua™; Vysis).

FISH

FISH analyses were performed on cytology slides with adequate cell populations. The slides were washed in fresh xylene, dehydrated in ethanol, and then soaked in $2 \times$ SSC (sodium chloride sodium citrate solution) buffer briefly. After incubation with protease K (0.5 mg/ml) at 37°C for 30 min, the slides were denatured for 5 min at 80°C in 70% formamide/$2 \times$ SSC. The probes, mixed with blocking DNA, were denatured for 5 min at 80°C before hybridization. The slides were incubated with the probe mixture at 37°C overnight, and washed briefly with $2 \times$ SSC, 0.3% Nonidet P-40 (NP-40) at 72°C. The nuclei were counterstained with 4′,6-diamidine-2′-phenylindole dihydrochloride and *p*-phenylenediamine in phosphate-buffered solution and glycerol (DAPI II; Vysis). The slides were examined under a fluorescence microscope (Olympus, Tokyo, Japan) equipped with a bandpass filter set (Vysis). Only individual, well-defined cells on cytology slides were scored. The numbers of EGFR and CEP7 signals were counted in each epithelial cell and assessed for amplification or aneuploidy: cells with EGFR/CEP7 ratio ≥ 2.0 were considered amplified for EGFR, while cells in which both EGFR

and chromosome 7 centromere increased equally were regarded as aneuploidy. For combined probes 7p12, 8q24, 5p15, and CEP6, any increase or decrease from two signals for each probe were labeled as positive for aneuploidy.

Immunohistochemistry

Four micrometers serial sections of paraffin blocks from surgical biopsy specimens, or, cell blocks from cytology preparation, if available, were used for EGFR protein expression (EGFR pharmDx™, Dakocytomation). Diaminobenzidine was used as the chromogen to identify positive results. Normal epithelium and stromal cells provided a negative internal control. The scoring for EGFR IHC was as follows: negative, no detectable staining; 1+, discernible cytoplasmic and/or faint discontinuous membrane staining; 2+, moderate and continuous membranous staining; 3+, strong and continuous membranous staining.[6] Quantitation of the percentage of EGFR expression was performed using an automated cellular imaging system (ACIS, Chromavision Inc., San Juan Capistrano, CA, USA).

Results

FISH

FISH analysis was performed on cytology slides from 25 benign cases and 25 malignant specimens. Among the 25 benign samples, 24 showed negative results by demonstrating two EGFR signals and two centromere 7 signals in at least 30 epithelial cells examined (Tables 1 and 2). Reactive epithelial changes arising in a background of immature squamous metaplasia or chronic inflammation, may result in atypical morphology in cytology samples, but negative FISH findings by EGFR/CEP7 or 4-probe method, suggested a benign process that was further verified by surgical core biopsy (Figure 1). Rarely, reactive atypical epithelial cells showed aneuploidy in chromosome 6 with unknown significance, but they almost never demonstrated aneuploidy or gene amplification of EGFR, c-myc, and 5p15.2 (data not shown). Only one case with marked interstitial fibrosis and chronic inflammation, highly atypical by cytology, revealed low trisomy in EGFR, that is, ≤ 2 copies in $>40\%$ cells, 3 copies in 10–40% cells, and ≥ 4 copies in $< 10\%$ cells.[7] Among the 25 malignant cases, 12 cases showed aneuploidy of EGFR with equally increased

Table 2 EGFR/CEP7 FISH results

	Tumor	*Nontumor*	*Total*
Positive	12	1	13
Negative	13	24	37
Total	25	25	50

Sensitivity = 12/25 = 48%; specificity = 24/25 = 96%; PPV = 12/13 = 92%.

Table 1 Surgical biopsy, cytology, EGFR FISH, and EGFR IHC results for patients with and without lung carcinoma

Patient	*Biopsy*	*Cytology*	*FISH*	*IHC*	*Patient*	*Biopsy*	*Cytology*	*FISH*	*IHC*
1	AD	NSCLC	Neg	Neg	26	G, CI	Neg	Neg	Neg
2	AD	NSCLC	Neg	Neg	27	G, CI	Neg	Neg	Neg
3	AD	NSCLC	Pos	2+	28	G, CI	Neg	Neg	1+
4	SCC	SCC	Neg	3+	29	F, CI	Suspicious	Neg	Neg
5	AD	NSCLC	Neg	2+	30	F, CI	Neg	Neg	Neg
6	AD	NSCLC	Neg	2+	31	F, CI	Suspicious	Neg	Neg
7	SCC	NSCLC	Neg	3+	32	R, Chemo	Atypical	Neg	Neg
8	AD	NSCLC	Neg	1+	33	SM	Atypical	Neg	Neg
9	AD	NSCLC	Pos	2+	34	CI	Neg	Neg	Neg
10	AD	NSCLC	Pos	1+	35	F, CI	Suspicious	Pos	1+
11	AD	NSCLC	Pos	3+	36	F, CI	Atypical	Neg	Neg
12	AD	NSCLC	Pos	3+	37	F, CI	Neg	Neg	Neg
13	AD	NSCLC	Pos	2+	38	A, G	Atypical	Neg	Neg
14	AD	Suspicious	Pos	2+	39	F, CI	Neg	Neg	Neg
15	SCC	NSCLC	Neg	3+	40	R, Chemo	Atypical	Neg	Neg
16	AD	AD	Pos	2+	41	SM	Atypical	Neg	Neg
17	SCC	SCC	Neg	2+	42	F, R	Neg	Neg	Neg
18	ADSCC	SCC	Neg	Neg	43	R, Radiat	Atypical	Neg	Neg
19	SCC	NSCLC	Pos	1+	44	SM, CI	Atypical	Neg	Neg
20	AD	NSCLC	Pos	1+	45	G, CI	Neg	Neg	Neg
21	AD	Atypical	Neg	1+	46	CI	Neg	Neg	Neg
22	ADSCC	NSCLC	Pos	2+	47	CI	Neg	Neg	Neg
23	SCC	NSCLC	Pos	1+	48	Neg	Neg	Neg	Neg
24	AD	NSCLC	Neg	1+	49	SM	Neg	Neg	1+
25	SCC	NSCLC	Neg	1+	50	Neg	Neg	Neg	Neg

AD, adenocarcinoma; ADSCC, adenosquamous cell carcinoma; Chemo, chemotherapy effect; CI, chronic inflammation; F, fibrosis; G, granulomatous changes; Neg, negative; NSCLC, non-small cell lung carcinoma; Pos, positive; R, reactive changes; Radiat, radiation effect; SCC, squamous cell carcinoma.

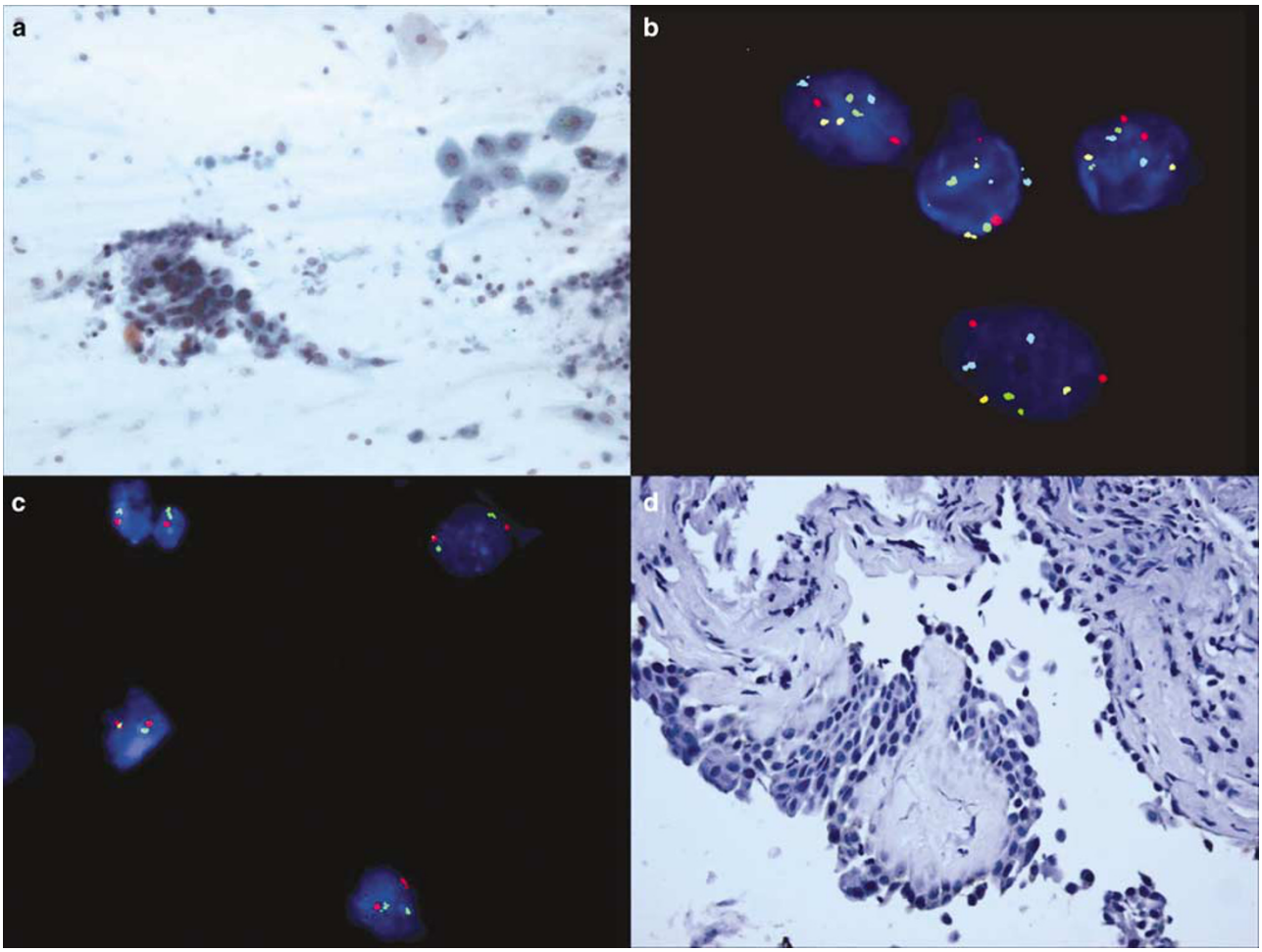

Figure 1 Squamous metaplasia and chronic inflammation are established by biopsy, while cytology (**a**) was read as atypical bronchial epithelial cells. All of the cells show normal hybridization signals on the 4-probe FISH (**b**) and EGFR/CEP7 FISH (**c**). The metaplastic squamous cells are negative for EGFR immunostain in biopsy (**d**).

EGFR and centromere 7 signals per tumor cell; the other 13 cases revealed two normal signals for EGFR and centromere 7 (Tables 1 and 2). Interestingly, only balanced aneuploidy of EGFR was identified by FISH. Gene amplification, although reported in other reports,[6,8,9] was not detected by FISH. EGFR chromosomal abnormalities in non-small cell carcinomas were almost always accompanied by other chromosomal abnormalities exhibited in c-myc, 5p15.2, or chromosome 6, suggesting a general genomic instability (Figures 2 and 3). About half of the malignant cases examined did not reveal any chromosomal abnormalities in EGFR, c-myc, 5p15, or chromosome 6. EGFR/CEP7 FISH had close to 50% sensitivity in lung cytology specimens, but it has very high, that is, 96%, specificity (Table 2). Its positive predictive value was 92%. Suspicious or atypical cytology samples, if positive by EGFR/CEP7 FISH, revealed a high probability of being malignant. In this series, only one atypical case by cytology but negative by biopsy showed low trisomy aneuploidy of EGFR by FISH.

Immunohistochemistry

IHC was performed on the corresponding surgical biopsies obtained at the same time as the cytology specimens, and/or cell blocks. Among the 25 benign cases, 3 cases were positive for EGFR protein expression, and 22 cases showed no immunoreactivity (Tables 1 and 3). Within the 25 malignant samples, 22 cases demonstrated EGFR cytoplasmic and/or membranous immunostaining, and 3 cases were negative (Tables 1 and 3). EGFR IHC had approximately 88% sensitivity, and 88% specificity. Its positive predictive value was 88%. Squamous cell carcinoma stained more frequently, and stronger, with higher percentage of positive cells per section for EGFR, compared to adenocarcinoma (Figure 4). Heterogeneity of positive immunostaining was usually noted within a single tumor nodule. Positivity of tumor cells ranged from 10 to 90%. Peripheral tumor cells often stained more intensely than central ones, possibly due to 'edge effect' (adsorption). Sometimes, there was non-specific

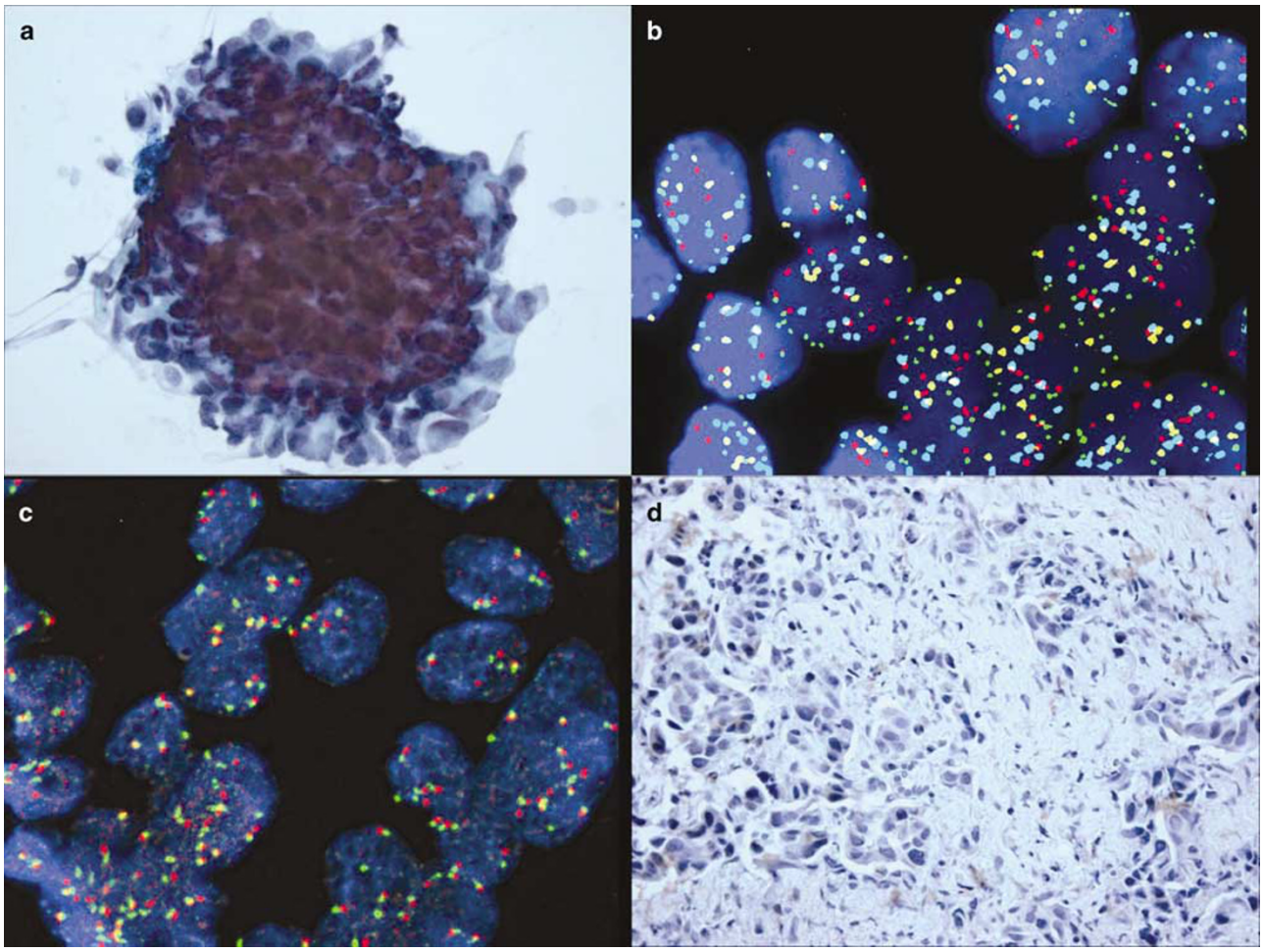

Figure 2 Invasive squamous cell carcinoma, confirmed by transbronchial biopsy, is called in cytology (**a**) positive for poorly differentiated carcinoma, favoring non-small cell carcinoma. The 4-probe FISH (**b**) shows 5–8 copies of EGFR, 5p15, c-myc, and chromosome 6 in large tumor cells. EGFR aneuploidy is found by EGFR/CEP7 FISH (**c**) with equally increased copy number of EGFR and centromere 7. No gene amplification of EGFR is detected. However, the tumor cells demonstrate barely detectable cytoplasmic EGFR staining by IHC in biopsy (**d**).

staining of benign basal layer cells and normal squamous epithelial cells.

Correlation of FISH and IHC

There was relatively good correlation in benign conditions, but poor correlation in lung carcinomas, between EGFR FISH and IHC. In 25 nontumor specimens, 24 samples showed negative EGFR FISH results, among which, 22 cases demonstrated concordant EGFR IHC negativity and two cases revealed focal weak positivity; one case had low trisomy by FISH and focal-positive IHC. In contrast in 25 lung carcinomas, 12 cases exhibited low to high EGFR polysomy by FISH and variably weak to strong EGFR immunoreactivity; 13 cases exhibited EGFR negativity by FISH, among which, 10 cases had discordant EGFR protein expression, while 3 cases showed negative immunostaining. Tumor cells with EGFR high-polysomy aneuploidy in some instances revealed weak cytoplasmic positivity for EGFR protein overexpression (Figure 2). Conversely, lung carcinomas with strong EGFR immunostaining were sometimes normal in FISH assays for EGFR aneuploidy or gene amplification (Figure 4).

EGFR Expression for Diagnostic Clarification

In the malignant group, patient 14 was diagnosed by cytology as highly suspicious for carcinoma, with drying artefact (Table 1; Figure 3). FISH showed EGFR high trisomy, and IHC demonstrated EGFR 2+ positivity. It was confirmed by surgical biopsy as adenocarcinoma, which indicated that EGFR expression was helpful to resolve the final diagnosis. For the other controversial case, patient 21 was called atypical by cytology, EGFR FISH was negative, and IHC only revealed 1+ immunoreactivity (Table 1). In this case, EGFR studies were not quite contributory to diagnostic clarification.

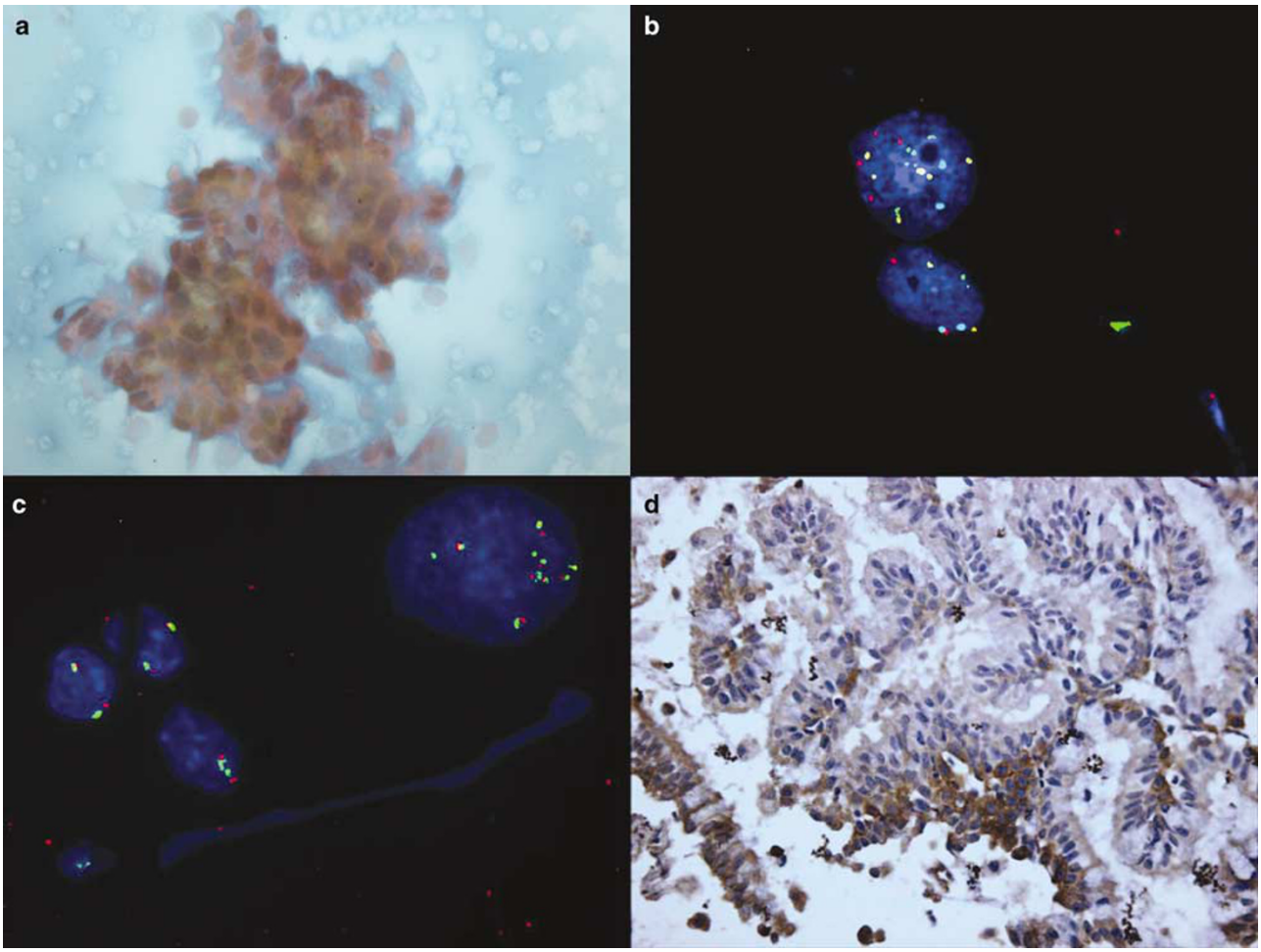

Figure 3 Adenocarcinoma, verified by biopsy, is diagnosed by cytology (**a**) as highly suspicious for carcinoma, with drying artefact. The 4-probe FISH (**b**) demonstrates 4–8 copies of EGFR, c-myc, 5p15.2, and chromosome 6 in large cells, while the small cells are normal. EGFR shows aneuploidy by EGFR/CEP7 FISH (**c**) with 3–8 gene copies in large cells, with small cells appearing normal. The glandular tumor cells reveal moderate membranous EGFR positivity in biopsy (**d**).

Table 3 EGFR IHC results

	Tumor	*Nontumor*	*Total*
Positive	22	3	25
Negative	3	22	25
Total	25	25	50

Sensitivity = 22/25 = 88%; specificity = 22/25 = 88%; PPV = 22/25 = 88%.

In the benign category, patients 29, 31, and 35 were called highly atypical, suspicious for carcinoma, and patients 32, 33, 36, 40, 41, 43, and 44 were designated as atypical with no other designation on the basis of the cytology sample evaluation. Except for patient 35, all the other patients revealed negative EGFR FISH and IHC results, which proved utility of EGFR expression to support the diagnoses in benign, reactive, or post-therapy conditions. In patient 35, EGFR exhibited low trisomy and 1 + IHC. This could be either a false-positive result, or could possibly represent an early evolving premalignant condition, a hypothesis that cannot be confirmed at this time.

Discussion

In this study, balanced aneuploidy, but not gene amplification, was detected in close to 50% of lung carcinomas. It was usually accompanied with other chromosomal abnormalities, such as aneuploidy in c-myc and 5p15, indicating general genomic instability. FISH assay of EGFR/CEP7 had very high specificity, as almost none of the benign or reactive specimens exhibited EGFR aneuploidy or gene amplification, except for one reactive sample with low-EGFR trisomy by FISH and focal immunoreactivity. IHC did not correlate well with EGFR aneuploidy in lung carcinomas. Although tumor cells with EGFR abnormality by FISH were all weakly to strongly positive for EGFR protein expression, increased gene copy numbers did not correspond well with immunoreactivity levels. In

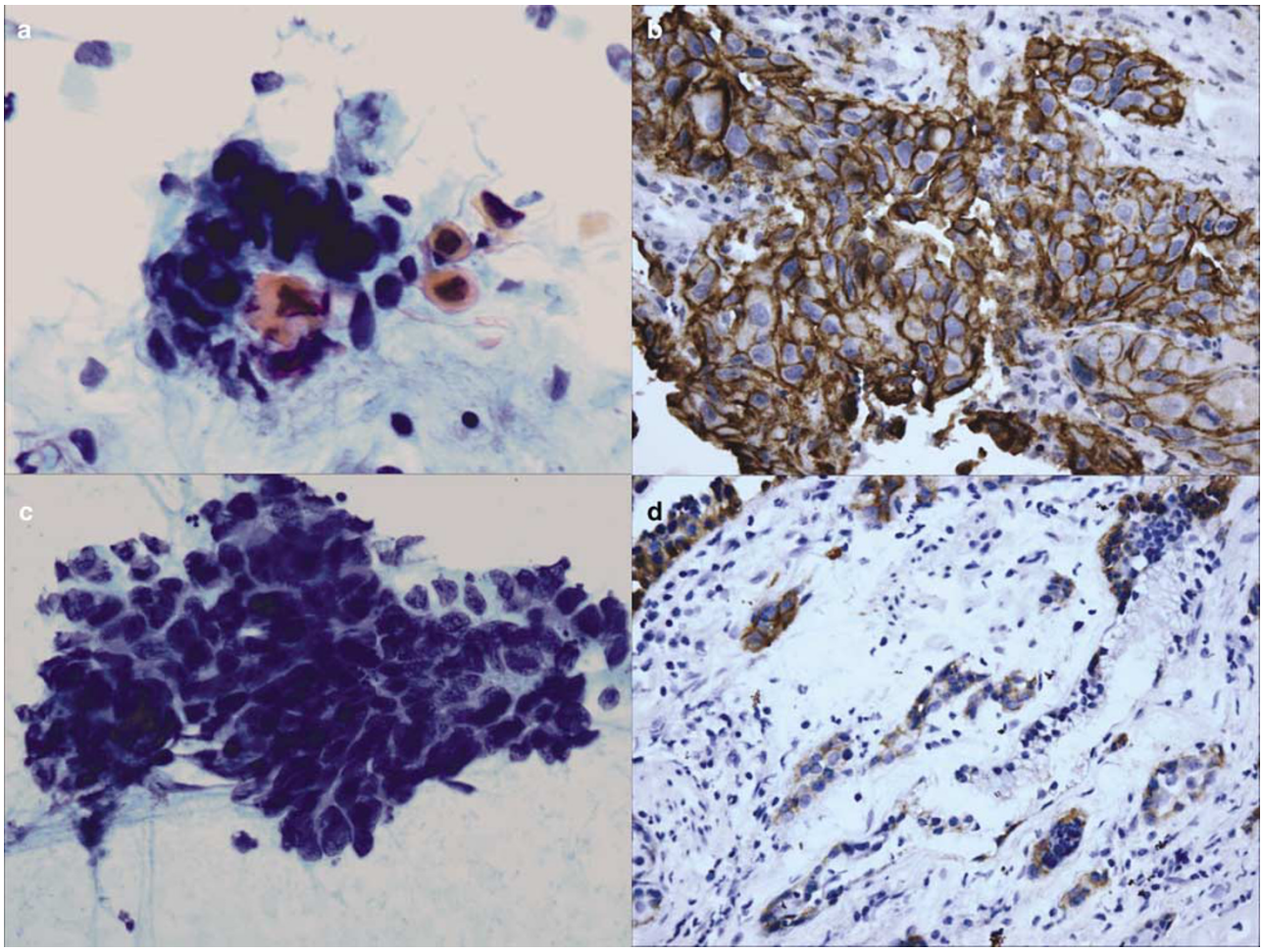

Figure 4 Squamous cell carcinoma (**a**) tends to stain more frequently, stronger, with more percentage of positive cells per section for EGFR (**b**), compared to adenocarcinoma (**c** and **d**). Positive immunostain heterogeneity can be seen within a single tumor nodule with positive tumor cells ranging from 5 to 90%. Peripheral tumor cells often stain more intensely than central tumor cells. EGFR protein overexpression does not necessarily correlate with abnormalities by FISH. Both cases shown here have normal findings by the 4-probe FISH and EGFR/CEP7 FISH.

contrast, strong EGFR immunoreactivity did not predict EGFR genetic locus aberrance, as it was occasionally completely normal by FISH. Squamous cell carcinoma often had stronger EGFR immunostaining than adenocarcinoma.[8] Because basal cells, metaplastic squamous cells, and cells at the edge of the tissue sections occasionally revealed nonspecific EGFR protein overexpression, IHC results may sometimes be difficult to interpret. EGFR by FISH was always negative in these cells.

Fine-needle aspirations and bronchial brushings/washings have been routinely performed for evaluation of patients with possible lung carcinoma.[10,11] Histopathology of bronchoscopic or core-needle biopsies is often used for confirmation of the cytologic diagnosis. However, not all lung lesions are accessible to biopsy or to bronchoscopy. Cytology may be the only available diagnostic technique to make a diagnosis of lung carcinoma. A definite diagnosis on cytology lung specimens is needed for further management plans. Various types of ancillary methods have been tested to improve the sensitivity and specificity of the diagnosis, including IHC, FISH,[10,11] mutational assays, and microsatellite instability analysis. Genetic and epigenetic changes such as promoter hypermethylation have been usually found in malignant cells.[1] Mutations in mitotic checkpoint genes MAD1 and BUB1, and inactivation of cell-cycle checkpoint genes p53, CHK2, 14-3-3, and CHFR contribute to lung cancer pathogenesis.[3] Chromosomal short or long arms losses or gains, and amplifications of certain genomic regions have also been reported. Specifically, myc, Ras, and EGFR gene families are often implicated. EGFR draws research and clinical interest, much due to the available targeted chemotherapy. The HER gene family on the cell surface activates downstream signal transduction through RAS-MAPK, PI3K/AKT, and JAK/STAT pathways.[3,12] It may function as an oncogene in tumorigenesis, through activation by excessive ligands, such as EGF or TGF-α, gene amplification, or mutations in its tyrosine kinase domain. Targeted therapies against EGFR are either aiming at its

extracellular domain with monoclonal antibodies such as Cetuximab, or using tyrosine kinase inhibitors (TKI), like Gefitinib and Erlotinib.[12,13] Therefore, detecting EGFR expression in lung carcinomas may be useful for therapeutic purposes.

EGFR protein expression in analyzed lung carcinomas ranges from 16 to 67%.[8,14] In our series, EGFR immunoreactivity was positive in 88% of lung carcinomas, and 12% of benign lung samples. The difference in positivity in the various groups may be due to lack of standardization of IHC protocols and interpretation of the results.[8] At least cytoplasmic reactivity and/or membrane staining was considered in this study as evidence of protein expression. Tumor cells often stain unevenly within a single group with positivity ranging from 5 to 90%, partly maybe due to genetic heterogeneity and further somatic mutations. Sometimes, nonspecific staining is noted in benign basal layer cells and metaplastic squamous epithelial cells. Perhaps, EGFR is important in normal cellular function and thus is expressed at a detectable level in early stages of cell differentiation. Because of the nonspecific reactivity in benign conditions, evaluation of malignancy by EGFR IHC may not be quite as reliable as by EGFR FISH.

Previous studies of EGFR gene amplification in lung carcinoma reveal conflicting data. Southern blot and FISH for EGFR showed its frequency ranging from 0% and 9 to 23%.[6,9,15] In our series of 25 patients with NSCLCs, we did not detect gene amplification. There was neither clustering of EGFR signals, corresponding to amplified signals in homogeneously staining regions, nor multiple scattered signals, indicating double minute chromosomes. In selected cases assayed with combined EGFR, c-myc, 5p15, and CEP6 probes, EGFR aneuploidy was almost always associated with aneuploidy in other markers, implicating a general genomic instability. Assessing EGFR by FISH in lung cancer is more complicated than analyzing HER2/Neu by FISH in breast cancer, because of the high occurrence of supernumerary copy numbers of CEP7. It has been proposed that those with disomy, low trisomy, high trisomy, and low polysomy EGFR are considered EGFR FISH negative, with ≥ 4 copies of EGFR in $\geq 40\%$ cells. In contrast, those with high-polysomy EGFR (with ≥ 4 copies in $\geq 40\%$ cells) and gene amplification are regarded as EGFR FISH positive.[2,7,16] Six patterns of EGFR gene amplification in lung cancer have been recognized, including 4–10 copies of EGFR gene clusters, and ≥ 15 EGFR signals in $\geq 10\%$ cells, even when EGFR/CEP7 ratio is ≤ 2.[17] EGFR FISH-positive patients, compared to those negative patients, are more likely to respond to EGFR TKI, and have longer disease-free survival and overall survival.[7,10,16,18,19] In our series, some of the confirmed NSCLC specimens with balanced aneuploidy EGFR by FISH had ≥ 4 copies of EGFR signal in $\geq 40\%$ cells. These can be assigned to the high-polysomy group, and may benefit from TKI therapy.

The good correlation in benign conditions and relatively poor correlation in lung carcinomas between EGFR FISH and IHC is intriguing. Existing literature also reports variable patterns of correlation. Suzuki *et al*[6] found EGFR protein overexpression in lung carcinomas was accompanied mainly by gene amplification, eventual lymph node metastasis and possibly aggressive behavior. Hirsch *et al*[20] reported balanced 40% disomy, 38% trisomy, 13% polysomy, and 9% gene amplification by FISH in lung carcinomas, and good correlation between EGFR gene copy number and protein expression. Dacic *et al*[8] on the other hand, proposed that EGFR protein expression was uncoupled from gene amplification in most cases, and had no correlation with tumor grade, lymph node metastasis, and tumor grade. In our series, EGFR aneuploidy or diploidy was not related to IHC expression in many cases. Alternative mechanisms such as transcriptional or translational regulation need to be explored.[8]

In summary, FISH and IHC analyses of EGFR may be useful adjunct methods to stratify controversial cases and to provide important prognostic information. If suspicious or atypical lung cytology specimens are positive for EGFR aneuploidy by FISH, there is a significant probability of malignancy. There is no good correlation between EGFR FISH and IHC in lung carcinomas. Other regulatory processes may explain the discordance. FISH and IHC analysis of EGFR expression, possibly in conjunction with other tumor markers, may be useful ancillary tools to classify difficult cytology cases and provide critical information to clinicians if targeted chemotherapy is being considered.

References

1 Kopper L, Timar J. Genomics of lung cancer may change diagnosis, prognosis and therapy. Pathol Oncol Res 2005;11:5–10.
2 Prudkin L, Wistuba II. Epidermal growth factor receptor abnormalities in lung cancer. Pathogenetic and clinical implications. Ann Diagn Pathol 2006;10:306–315.
3 Tomida S, Yatabe Y, Yanagisawa K, *et al.* Throwing new light on lung cancer pathogenesis: updates on three recent topics. Cancer Sci 2005;96:63–68.
4 Crapanzano JP, Zakowski MF. Diagnostic dilemmas in pulmonary cytology. Cancer 2001;93:364–375.
5 Naryshkin S, Young NA. Respiratory cytology: a review of non-neoplastic mimics of malignancy. Diagn Cytopathol 1993;9:89–97.
6 Suzuki S, Dobashi Y, Sakurai H, *et al.* Protein overexpression and gene amplification of epidermal growth factor receptor in nonsmall cell lung carci nomas. An immunohistochemical and fluorescence *in situ* hybridization study. Cancer 2005;103: 1265–1273.
7 Cappuzzo F, Hirsch FR, Rossi E, *et al.* Epidermal growth factor receptor gene and protein and gefitinib

sensitivity in non-small-cell lung cancer. J Natl Cancer Inst 2005;97:643–655.
8 Dacic S, Flanagan M, Cieply K, *et al.* Significance of EGFR protein expression and gene amplification in non-small cell lung carcinoma. Am J Clin Pathol 2006;125:860–865.
9 Shiraishi M, Noguchi M, Shimosato Y, *et al.* Amplification of protooncogenes in surgical specimens of human lung carcinomas. Cancer Res 1989;49: 6474–6479.
10 Halling KC, Rickman OB, Kipp BR, *et al.* A comparison of cytology and fluorescence *in situ* hybridization for the detection of lung cancer in bronchoscopic specimens. Chest 2006;130:694–701.
11 Sokolova IA, Bubendorf L, O'Hare A, *et al.* A fluorescence *in situ* hybridization-based assay for improved detection of lung cancer cells in bronchial washing specimens. Cancer 2002;96:306–315.
12 Ettinger DS. Clinical implications of EGFR expression in the development and progression of solid tumors: focus on non-small cell lung cancer. Oncologist 2006;11:358–373.
13 Tsao MS, Sakurada A, Cutz JC, *et al.* Erlotinib in lung cancer – molecular and clinical predictors of outcome. N Engl J Med 2005;353:133–144.
14 Pastorino U, Andreola S, Tagliabue E, *et al.* Immunocytochemical markers in stage I lung cancer: relevance to prognosis. J Clin Oncol 1997;15: 2858–2865.
15 Slebos RJ, Evers SG, Wagenaar SS, *et al.* Cellular protoonocogenes are infrequently amplified in untreated non-small cell lung cancer. Br J Cancer 1989;59:76–80.
16 Hirsch FR, Varella-Garcia M, McCoy J, *et al.* Increased epidermal growth factor receptor gene copy number detected by fluorescence *in situ* hybridization associates with increased sensitivity to gefitinib in patients with bronchioloalveolar carcinoma subtypes: a Southwest Oncology Group Study. J Clin Oncol 2005;23: 6838–6845.
17 Varella-Garcia M. Stratification of non-small cell lung cancer patients for therapy with epidermal growth factor receptor inhibitors: the EGFR fluorescence *in situ* hybridization assay. Diagn Pathol 2006;1:19.
18 Suzuki M, Shigematsu H, Hiroshima K, *et al.* Epidermal growth factor receptor expression status in lung cancer correlates with its mutation. Hum Pathol 2005;36:1127–1134.
19 Takano T, Ohe Y, Sakamoto H, *et al.* Epidermal growth factor receptor gene mutations and increased copy numbers predict gefitinib sensitivity in patients with recurrent non-small-cell lung cancer. J Clin Oncol 2005;23:6829–6837.
20 Hirsch FR, Varella-Garcia M, Bunn Jr PA, *et al.* Epidermal growth factor receptor in non-small-cell lung carcinomas: correlation between gene copy number and protein expression and impact on prognosis. J Clin Oncol 2003;21:3798–3807.