

**Conclusions:** The upregulated expression of these 4 transcription factors in carcinoma from radical prostatectomy specimens suggests that androgen receptor activation occurs in hormone naïve primary prostate cancer. Interestingly, the increased mRNA expression for SHP in HGPIN suggests it may play a role in prostate cancer initiation and early progression. Further studies of the expression of these genes at different stages of prostate cancer are planned to determine their relative in initiation and progression of prostate cancer.

### 809 Potential Roles of Cytologic T-Lymphocytes and Nature Killer Cells in Prostate Basal Cell Layer Disruptions and Tumor Invasion

C Zhao, C Mannion, YG Man. Armed Forces Institute of Pathology, Washington, DC; Hackensack Medical Center, Hackensack, NJ.

**Background:** The physical disruption of the basement membrane and basal cell layer is a pre-requisite for prostate tumor invasion. The disruption of the basement membrane is believed to result from elevated proteolytic enzymes, while the mechanism of basal cell layer disruptions remains elusive. As our previous studies with antibodies to basal cell specific antigens and leukocyte common antigen (LCA) revealed, focal basal cell layer disruptions are consistently surrounded by or adjacent to LCA positive cells (Man et al, Cancer Detect Prev, In press). This current study attempts to assess whether these cells belong to a cytotoxic cell population.

**Design:** Consecutive tissue sections from human prostate tumors (n=30) with co-existing normal, hyperplastic, *in situ*, and invasive components were double immunostained with two different chromogens for the high molecular weight cytokeratin 34bE12 to identify basal layer disruptions, and each of the following markers, CD4, CD8, CD56, microphage, perforin, and mast cell tryptase, to elucidate the correlation of these molecules with focal basal layer disruptions.

**Results:** Multiple focal basal cell layer disruptions were seen in each of the cases. These disruptions were consistently surrounded by or adjacent to CD8, CD56, perforin, and mast cell tryptase positive cells. Tumor cells overlying focally disrupted basal cell layers often displayed distinct morphological alterations in cellular density and polarity, as well as the nuclear size and shape, compared to the adjacent cells within the same duct, but away from the disruption. The CD4 and microphage positive cells also appeared to be associated with basal cell layer disruptions, but the number of these cells varied substantially and the association was less consistent.

**Conclusions:** The consistent detection of CD8, CD56, perforin, and mast cell tryptase positive cells near focal basal cell layer disruptions suggest that cytotoxic T lymphocytes, nature killer cells and mast tryptase positive cells are likely to promote basal cell layer disruptions and tumor invasion. The development of specific agents to target these cells may have significant clinical value in treatment and prevention of tumor invasion.

This study was supported in part by grants DAMD17-01-1-0129 and DAMD17-01-1-0130 from Congressionally Directed Medical Research Programs to Yan-Gao Man, MD., PhD.

### 810 Interferon Signal Transduction Pathway Is Disturbed in a Subset of High Grade Invasive Urothelial Carcinomas

M Zhou, P Sadhukhan, R Rackley, J DiDonato. The Cleveland Clinic Foundation, Cleveland, OH.

**Background:** Interferons are known to have a variety of biological activities including antitumor, antiviral and immunomodulatory effects. Recent cell culture and gene expression profiling studies have suggested that interferon signaling pathways may play a key role in the development and progression of high grade urothelial carcinoma. This study evaluated the expression of several key genes in the interferon signaling pathways in low grade non-invasive (LGTC) and high grade invasive urothelial carcinoma (HGTC).

**Design:** Construction of tissue microarray: 33 invasive HGTC, 6 LGTC and 3 benign urothelium. Immunohistochemical staining and evaluation: Immunostains were performed with antibodies against NFkB (P50), Stat3, Phospho-Stat3, and ISGF-3g (p48). Benign urothelium served as control. Stains significantly higher or lower than that of benign urothelium were considered as positive or negative for that marker. A case was scored as negative only if all 3 tissue cores from the same case were negative. A case was scored as positive if any of 3 tissue cores was positive. For NFkB and Stat3, the cytoplasmic staining was evaluated. For phospho-Stat3, the nuclear staining was evaluated. For P48, both cytoplasmic and nuclear staining was evaluated.

**Results:** Normal urothelium was negative for NF kB (P50) and Stat3 expression, but showed consistent positive nuclear stain for phospho-Stat3 and both cytoplasmic and nuclear staining for P48. The expression of P50, Stat-3, Phospho-Stat3 and P48 was summarized in the Table. Expression of phospho-Stat3 and P48 was heterogeneous in TCC, with many tumor cells having lost expression and only a small fraction of tumor cells retaining expression.

**Conclusions:** About 1/3 of HGTC are positive for P50 and Stat3, in contrast to 0% of LGTC, suggesting these two genes play an important role in the development of high grade, more aggressive disease in a subset of transitional cell carcinoma. There is an increased loss of phospho-Stat3 and P48 in HGTC (although not statistically significant due to small sample size), suggesting a possible role for these two genes in the development of HGTC.

	P50	Stat3	Phospho-Stat3	P48
HGTC	10/33 (30.3%)	13/33 (39.4%)	7/33 (21.2%)	12/33 (36.4%)
LGTC	0/6 (0%)	0/6 (0%)	3/6 (50%)	4/6 (67%)
p value	0.12	0.06	0.15	0.20

Expression of P50, Stat3, phospho-Stat 3 and P48 in TCC

### 811 Lack of Association between Epidermal Growth Factor Receptor Overexpression and Disease Recurrence in Clear Cell Renal Cell Carcinoma

M Zhou, J Finke, R Bukowski, R Tubbs. The Cleveland Clinic Foundation, Cleveland, OH.

**Background:** The prognostic significance of epidermal growth factor receptor (EGFR) overexpression in clear cell renal cell carcinoma (CCRCC) is controversial. Some studies have shown it is an unfavorable prognostic factor, while other studies found no association between EGFR overexpression and prognosis. Recent reports that anti-EGFR therapy was ineffective for CCRCC further raised the question about the biological function of EGFR in CCRCC. We studied EGFR overexpression in a cohort of CCRCC with long-term follow-up (> 10 years).

**Design:** 44 CCRCC were used to construct a tissue microarray (TMA). All patients were treated with radical/partial nephrectomy and had been followed for  $\geq 10$  years. Eleven had cancer recurrence within 1 year, 22 within 1-10 years, and 11 were recurrence-free more than 10 years after surgery. The TMA was stained with anti-EGFR antibody. EGFR overexpression was scored using two methods. 1. **Simple scoring**- strong circumferential membranous stain (3), weak circumferential membranous stain (2), weak partial membranous stain (1) and negative staining (0). Only staining intensity 2 and 3 were considered positive for EGFR overexpression. 2. **Composite scoring**-the staining intensity (0-3) was multiplied by the percentage of positive cells with EGFR overexpression score ranging from 0 to 300.

**Results:** Using the simple scoring method, EGFR overexpression was found in 7/11 (63.6%), 18/22 (81.8%) and 5/11 (45.5%) of patients with recurrence within 1, 1-10 and >10 years after surgery ( $p > 0.05$ ). There was no correlation between EGFR overexpression and tumor recurrence status or tumor stage ( $p = 0.37$  and  $0.55$ ). However, EGFR overexpression correlated with Furrman nuclear grade ( $r = 0.372$ ,  $p = 0.036$ ). Using the composite scoring method, mean EGFR overexpression score was  $120 \pm 78$ ,  $122 \pm 77$  and  $82 \pm 85$  for patients with recurrence within 1, 1-10 and >10 years after surgery respectively ( $p > 0.2$ ). There was no correlation between EGFR overexpression level and disease recurrence status, tumor stage or Furrman nuclear grade.

**Conclusions:** EGFR overexpression correlates with Furrman nuclear grades in CCRCC. However, it is not significantly different between patients with recurrence within 1, 1-10 and >10 years after surgery. There is no correlation between EGFR overexpression and prognosis.

## Gynecologic

### 812 Prognostic Significance of Peritumor Lymphatic Vessel Density in Early Stage Squamous Cell Carcinoma of the Cervix

G ACS, X Xu, T Pasha, C Chu, PJ Zhang. University of Pennsylvania Medical Center, Philadelphia, PA.

**Background:** The role of angiogenesis in the development and progression of cervical carcinoma is established. However, in cervical cancers the earliest feature of disseminated disease is regional lymph node involvement. Despite its role in tumor dissemination, little is known about the role of tumor lymphangiogenesis in metastases and whether lymphatic spread occurs via pre-existing lymphatic channels or vessels newly formed by lymphangiogenesis. The recently developed monoclonal antibody D2-40 was reported to be a selective marker for lymphatic endothelium useful in identifying lymphatic invasion in various malignant neoplasms.

**Design:** We examined the intra- and peritumor lymphatic vessel density (LVD) in a series of 112 FIGO stage I and II cervical squamous cell carcinomas using D2-40 immunohistochemistry on formalin-fixed paraffin-embedded tissue sections. The lymphatic vessel density within the tumors (intratumor LVD) and within 2 mm of the edge of the tumors (peritumor LVD) was determined in 10 high power fields (X400) with the highest number of D2-40 positive lymphatic vessels. The intra- and peritumor LVD was correlated with clinicopathologic tumor features, D2-40 immunoreactivity in tumor cells and patient outcome.

**Results:** Intra- and peritumor LVD was significantly higher compared to benign squamous cervical mucosa ( $p < 0.0001$ ). Peritumor LVD ( $9.56 \pm 0.47$ , mean  $\pm$  SEM) was significantly higher compared to intratumor LVD ( $7.84 \pm 0.49$ ) ( $p < 0.01$ ). High peritumor, but not intratumor, LVD was significantly associated with low D2-40 immunoreactivity of tumor cells ( $p = 0.005$ ), presence of lymphatic invasion ( $p < 0.0001$ ), nodal metastasis ( $p = 0.026$ ) and FIGO stage ( $p = 0.032$ ). Intra- and peritumor LVD showed no correlation with patient age, tumor size or grade. High peritumor, but not intratumor, LVD was highly significantly associated with poor recurrence-free ( $p < 0.0001$ ) and overall survival ( $p < 0.0001$ ) in both uni- and multivariate analysis.

**Conclusions:** The monoclonal antibody D2-40 specifically labels lymphatic vessels and is a useful marker for determination of lymphatic vessel density. Cervical squamous cell carcinomas showing high peritumor LVD are associated with more advanced, aggressive disease and poor outcome. Determination of peritumor LVD may serve as an independent prognostic and/or predictive factor in cervical cancers.

**813 The Temporal Variation in the Distribution of Hyaluronic Acid, CD44s and CD44v6 in Human Endometrium across the Menstrual Cycle**

AM Afify, S Craig, AF Paulino. UC DAVIS, Sacramento, CA; Genzyme Genetics, New York, NY.

**Background:** The human endometrium undergoes extensive remodeling during the course of the normal menstrual cycle. Hyaluronic acid (HA) is a prominent component of the extracellular matrix especially in tissues undergoing rapid growth and regeneration. Its role in such biologic processes is partly mediated by its relationship with CD44, its major cell surface receptor. The purpose of this study is to examine the levels of deposition of HA and expression of CD44s and CD44v6 in human endometrium across the menstrual cycle.

**Design:** Archival paraffin-embedded cellblocks from proliferative endometrium (n=10 cases), secretory endometrium (n=12) and decidualized stroma (n=8) were stained for hyaluronic acid (1:2000, Seikagahu Corp.), CD44s (1:1000, Bender MedSystems) and CD44v6 (1:1500, Bender MedSystems). Specimens from the secretory phase were further subdivided into 3 categories: early (day 15-22), mid (day 19-23) and late secretory (day 24-28). Sections from umbilical cord, tonsil, and squamous cell carcinoma served as positive controls for HA, CD44s and CD44v6, respectively. Negative controls for Positive staining was defined as droplet to diffuse intracytoplasmic or extracellular staining for HA and uniform membranous staining for CD44.

**Results:**

	HA		CD44s		CD44v6	
	Glands	Stroma	Glands	Stroma	Glands	Stroma
<b>Proliferative (n=10)</b>	0(0%)	10(100%)	0(0%)	0(0%)	0(0%)	0(0%)
<b>Secretory (n=12)</b>	0(0%)	12(100%)	1(8%)	11(92%)	9(75%)	0(0%)

HA staining was observed in the endometrial stroma throughout the menstrual cycle but was most intense (3+) and diffuse during the mid-secretory phase. Perivascular staining for HA was noted throughout the cycle and was most intense adjacent to the spiral arterioles in the secretory phase. Staining for CD44s and CD44v6 was noted only in the secretory phase. Decidualized stromal cells showed diffuse intense CD44s expression in 88% (7/8).

**Conclusions:** Our data indicates temporal and geographic differences in HA and CD44 staining in the endometrium. The variations in intensity and location appear to be in concert with the menstrual cycle. The timing of peak staining of HA and CD44s in the stroma and the upregulation of CD44v6 in secretory glands are coincident with the period in which the endometrium is most receptive to embryo implantation. Whether these changes are mere hormonal consequences or actually help modulate the cyclical changes in the endometrium warrants further study.

**814 Prognostic Marker for Endometrial Adenocarcinoma: Expression of Stromal Hyaluronan in the Presence of Decreasing Levels of CD44v6 Reflects Tumor Progression**

AM Afify, S Craig, AF Paulino, R Stern. UC Davis, Sacramento, CA; Genzyme Genetics, New York, NY; UC San Francisco, San Francisco, CA.

**Background:** Hyaluronan (HA) is a high molecular weight glycosaminoglycan of the extracellular matrix. In many epithelial malignancies, HA is expressed by the peritumoral stroma, probably up regulated by signals from epithelial tumor cells. CD44 is the receptor for HA. The standard form (CD44s) is an 85-90 kDa integral membrane glycoprotein. Combinations of additional 10 variant exons can be inserted into a single extracellular position in the CD44 molecule, thus creating a great variety of isoforms. The purpose of this study was to evaluate the significance of HA, CD44s and CD44v6 molecules in benign, hyperplastic, and malignant endometrial epithelia.

**Design:** Cellblocks from proliferative endometrium (11), secretory endometrium (12), endometrial polyps (11), simple hyperplasia (13), complex hyperplasia without atypia (9), complex hyperplasia with atypia (17), and adenocarcinoma (21) were stained for HA, CD44s, and CD44v6. Sections from umbilical cord, tonsil, and squamous cell carcinoma served as positive controls for HA, CD44s and CD44v6, respectively. Positive staining was defined as droplet to diffuse intracytoplasmic or extracellular staining for HA and uniform membranous staining for CD44.

**Results:**

	HA		CD44s		CD44v6	
	GLANDS	STROMA	GLANDS	STROMA	GLANDS	STROMA
Proliferative	0(0%)	11(100%)	0(0%)	0(0%)	0(0%)	0(0%)
Secretory	0(0%)	12(100%)	1(8%)	11(92%)	9(75%)	0(0%)
Simple hyperplasia	0(0%)	2(15%)	2(15%)	0(0%)	0(0%)	11(85%)
Complex (-) atypia	0(0%)	5(56%)	4(44%)	0(0%)	1(11%)	6(67%)
Complex (+) atypia	0(0%)	15(88%)	14(82%)	4(24%)	17(100%)	8(47%)
Adenocarcinoma	0(0%)	21(100%)	16(76%)	6(29%)	18(86%)	3(14%)

**Conclusions:** With the progression of hyperplasia and with increasing atypia to adenocarcinoma, levels of stromal CD44v6 fall while those of stromal HA increase. This suggests that free, unbound HA most likely originating from the stroma, is an ominous indicator in endometrial carcinoma, particularly when there are insufficient levels of CD44v6 receptor for binding of its HA ligand. The difference in CD44s and CD44v6 expression between the stroma and the glandular epithelium could be due to the fact that they may be controlled by different mechanisms. Our findings suggest that CD44 might be functionally involved in the multiple mechanisms of the development and progression of endometrial cancer.

**815 DcR3 Expression in the Development and Behavior of Epithelial Ovarian Tumors**

AJ Ali, BVS Kallakury, RA Ambros, CE Sheehan, S Kim, S Yang, JS Ross, L Zhang. Albany Medical College, Albany, NY; Georgetown University Hospital, Washington, DC; Lombardi Cancer Center, Washington, DC.

**Background:** DcR3 (decoy receptor 3), is a TNF and Fas-related cell surface receptor without transmembrane domain which binds to the Fas ligand (FasL) with high affinity, blocks the interaction of Fas-FasL, and attenuates the pro-apoptotic signaling

mediated by Fas. The expression of DcR3 facilitates the ability of immune targeted cells to escape cell death and thus promotes cell survival. Recent studies have shown an overexpression of DcR3 by certain malignant tumors, which includes carcinomas of the lung, stomach, pancreas, and colon as well as malignant gliomas. The clinical and pathologic significance of DcR3 expression in ovarian neoplasia has not been previously characterized.

**Design:** Sections from 70 formalin-fixed, paraffin-embedded primary ovarian tumors including benign tumors, tumors of low malignant potential (LMP), and primary carcinomas were immunostained with monoclonal mouse anti-human DcR3, followed by biotinylated anti-mouse IgG, streptavidin-HRP and AEC. The staining of DcR3 was semiquantitatively scored and the results were correlated against clinicopathologic variables.

**Results:** DcR3 expression was identified for 4 of 6 (66%) cystadenomas, 8 of 8 (100%) tumors of LMP, and 52 of 56 (93%) carcinomas. A trend for correlation of DcR3 expression with regard to benign versus LMP versus carcinoma was noted, but did not reach significance (p=0.1). Within the histologic subgroups of carcinomas, no statistically significant correlation was identified between DcR3 expression in stage, grade, or time of survival.

**Conclusions:** Although DcR3 expression was detected in carcinomas of the ovary, it was also detected in the benign tumors and in tumors of LMP and did not correlate with any clinicopathologic studies. While DcR3 may not be prognostically significant in ovarian neoplasms as compared to other tumors, it nonetheless may have biologic implications, and may play a role in tumor cell escape from host immune surveillance.

**816 Discrepancies in Assessing Depth of Invasion in Endometrial Carcinoma**

AS Ali, RA Soslow. Memorial Sloan-Kettering Cancer Center, New York, NY.

**Background:** Non-neoplastic endometrial stroma ranges in appearance from densely cellular and blue to paucicellular and pink, thereby resembling smooth muscle. We sought to determine the impact of endometrial stromal alteration in assessing the invasion depth in endometrial carcinoma.

**Design:** Slides from 129 endometrial carcinomas diagnosed between 1995 and 1997 were reviewed. The mean patient age was 62.5 years (range 35-87). Of 129 cases, 108 (83.7%) were endometrioid, 7 (5.4%) mixed endometrioid and papillary serous, 6 (4.7%) papillary serous, 5 (3.9%) mixed endometrioid and clear cell carcinoma, 2 (1.6%) clear cell carcinoma and 1 (0.78%) squamous cell carcinoma. Of the endometrioid carcinomas, 74 (68.5%) were FIGO grade 1, 21 (19.4%) FIGO grade 2 and 13 (12.0%) FIGO grade 3. According to pathology reports, 25 (19.4%) of the carcinomas were limited to the endometrium, 67 (51.9%) invaded <50% of the myometrium (superficially invasive) and 37 (28.7%) invaded >50% of the myometrium (deeply invasive). Each case was analyzed for depth of tumor invasion and prevalence of endometrial stromal alteration.

**Results:** In 43 of 129 cases (33.3%), the depth of invasion was overestimated in the original pathology report (0.4 mm to 6.0 mm) and in 18 cases (14.0%) the depth of invasion was underestimated (0.5 mm to 5.0 mm). 106 of 129 cases (82.2%) showed some degree of endometrial stromal alteration, ranging from 10% to 90% in any given case. Upon correcting the depth of invasion, 27 cases (20.9%) showed a significant change in tumor depth. Of the 27 cases, 20 (74.1%) were downgraded from superficially invasive to non-invasive and 1 (3.7%) from deeply invasive to non-invasive. The factors that contributed to overcalling the depth of invasion included mistaking tumor involving adenomyosis for invasion and not recognizing tumor limited to the endometrium when it was predominantly exophytic. 3 cases (11.1%) were upgraded from non-invasive to superficially invasive and 3 (11.1%) from superficially invasive to deeply invasive. The degree of stromal metaplasia in inaccurately staged cases did not differ significantly from that seen in correctly diagnosed cases.

**Conclusions:** Errors in measuring depth of invasion significantly altered the measurement of invasion depth in one-fifth (20.9%) of cases. This may have important implications in adjuvant treatment planning and patient prognosis. Adenocarcinomas colonizing adenomyosis and exophytic tumors represent challenges in assessing invasion depth. Stromal alteration did not contribute to assessing invasion depth in this series.

**817 Maspin Expression in Serous Endometrial Carcinoma: Its Relationship with Angiogenesis and Clinicopathologic Outcome**

R Ali-Fehmi, S Dean, MH Arabi, F Lonardo, M Che, FW Abdul-Karim, AR Munkarah. Wayne State Univ, Karmanos Cancer Institute, Detroit, MI; Case Western Univ.

**Background:** Maspin (Ma) is a Mammary Serine Protease Inhibitor tumor suppressor gene that inhibits invasion and angiogenesis. Interestingly, the protein activity and prognostic significance in various cancers is highly impacted by its cellular localization (nuclear vs. cytoplasmic). The objective of this study was to determine the patterns of expression and cellular localization of Ma in serous endometrial carcinoma (SEC).

**Design:** Using our database we identified 75 surgically staged patients with SEC diagnosed (1995-2002). Clinicopathologic information was retrieved by retrospective review of medical records. Two paraffin blocks from each case were immunostained using antibodies against Ma, VEGF and p53. The immunoreactivity was semiquantitatively scored based on staining intensity and distribution. The cellular distribution of Ma stain was scored as nuclear or cytoplasmic, the latter including cases with cytoplasmic or combined nuclear and cytoplasmic stain.

**Results:** The mean age of the patients was 67 years (range 41 to 91) and mean follow-up was 23 (4 to 90 months). Patient distribution by FIGO surgical stage was as follows: 33 stage I, 10 Stage II, 25 stage III and 7 stage IV. In 45 cases (62%) there was no evidence of myometrial invasion. Ma expression was detected in 43/70(61%). The relation between Ma expression, its cellular localization, and specific tumor characteristics is shown in Table 1. Cytoplasmic Ma expression was associated with unfavorable prognostic factors including myometrial invasion, advanced stage, and increased VEGF expression. In multivariate analysis (Cox proportional hazard model)

of age, stage, vascular invasion, myometrial invasion, expression of VEGF, Ma, and Ma C localization, only high stage, myometrial invasion and Ma C localization impacted survival ( $p=0.000$ ,  $p=0.009$ ,  $p=0.060$ , respectively).

Table 1

	Myometrial invasion		Stage		VEGF	
	No (13)	Yes (30)	Low I-II 22	High III-IV 21	Low 20	High 10
Ma Stain (43)	5(63%)	3(37%)	7(88%)	1(12%)	6(67%)	2(33%)
N stain (8)	8(23%)	27(77%)	15(45%)	20(55%)	14(41%)	8(59%)
C stain (35)	0.04	0.03				
P value						

**Conclusions:** Ma expression was seen in 61% of SEC evaluated, and the cytoplasmic localization of the protein associated with worse prognosis. Our data are compatible with the hypothesis that alteration of Maspin expression from nuclear to cytoplasmic localization may result in deregulation of tumor inhibitor properties.

### 818 Mixed Serous-Endometrioid Carcinoma of the Uterus

R Ali-Fehmi, H Nassar, M Che, AR Munkarah, E Silva. Wayne State Univ, Karmanos Cancer Institute, Detroit, MI; M.D. Anderson Cancer Hospital, Houston, TX.

**Background:** The concept of molecular targeting in cancer therapy is rapidly progressing and necessitates a good knowledge of the molecular profile of the cancer to be treated. While studies have shown a difference in the molecular profile between endometrioid and serous endometrial carcinomas, the expression of various molecular markers in mixed lesions with both histologic components has not been well established.

**Design:** We identified 22 cases with endometrial cancer having both serous component (SC) and endometrioid component (EC). The HE slides were reviewed by 3 pathologists, confirming the mixed nature of the lesions and quantitating the % component of each histologic subtype. Immunohistochemical staining was performed on 2 blocks from each case for the following markers: p53 (22 cases), Her2 (16), EGFR (20), PTEN (20) and  $\beta$ -catenin (20). For each component, p53 staining was reported as % of positive cells, Her2 and EGFR were reported on a scale of 0 to 3 (0-1, negative; 2-3, positive), PTEN and  $\beta$ -catenin were reported as positive or negative with special attention to the localization of the staining.

**Results:** The serous component ranged from 20-60% (median 40%). P53 expression was detected in both histologic components in 19/22 cases and was absent in 3. In 17 (77%), the % of p53 positive cells was significantly higher in the SC (30-90; median 80) compared to the EC (10-60; median 40). In 2 cases (9%), the EC exhibited a higher % of p53 positive cells. For Her-2, 4 cases (25%) showed positive expression in the SC and negative expression in EC, 2 cases (12.5%) had positive expression in the EC and negative in the SC and in 3 cases (19%) both components were strongly positive. For EGFR, 5 cases (25%) showed positive expression in the SC and negative in the EC, one case (5%) was positive in the EC and negative in the SC. For PTEN, positive expression was noted in the SC of 10 cases (50%); none of the lesions stained positive in the EC.  $\beta$ -catenin was strongly expressed in both EC and SC of all lesions with a cytoplasmic and membranous pattern of expression.

**Conclusions:** We have demonstrated that, in this patient population of mixed endometrial cancers, the serous and endometrioid components exhibit a different molecular profile with the serous component having a higher expression of p53, Her-2, EGFR and PTEN. This raises the question whether mixed lesions are polyclonal in origin or this noted difference is a result of molecular alterations in the process of tumor progression.

### 819 Undifferentiated Endometrial Carcinoma of the Uterine Cavity

B Altrabulsi, A Malpica, D Bodurka, R Broadus, M Deavers, E Silva. MD Anderson Cancer Ctr, Houston; Baylor University, Dallas, TX.

**Background:** Endometrial undifferentiated carcinoma (UC) is poorly recognized because the FIGO grading system for endometrioid carcinoma classifies cases that are entirely solid as grade 3. Therefore, UC is frequently diagnosed as endometrioid endometrial adenocarcinoma grade 3 (EE Ca G3). This study compares the diagnostic and the clinical features of UC with those of EE Ca G3.

**Design:** We compared 16 cases of pure UC with 33 cases of EE Ca G3. All of the cases had complete clinical information and pathology material. Immunohistochemistry was performed for keratin (CK) and EMA in 35 cases.

**Results:** The age of the 16 patients (pts) with UC ranged between 40 and 69 years (yrs) (mean 59 yrs). Six (46%) pts presented with early stage disease (4 stage 1 and 2 stage 2). Seven (54%) pts presented with advanced stage disease (2 stage 3 and 5 stage 4). Staging information was not available for 3 patients. UC was characterized by a proliferation of medium-sized, monotonous cells growing in a solid patternless fashion. Glands were not identified. CK stain was performed on 12 cases and was positive in 11 cases. EMA was positive in all 12 cases. The age of the 33 pts with EE Ca G3 ranged from 40 to 90 yrs (mean 68 yrs). Twenty-three (70%) pts presented with early stage disease (21 stage 1 and 2 stage 2) and 10 (30%) pts presented with advanced stage disease (8 stage 3 and 2 stage 4). Focal glandular differentiation was seen, but the solid component was different from that of UC. Trabeculae, chords and well demarcated groups of cells were identified. The tumor cells were larger than the cells of UC. Immunostains for CK and EMA were positive in 23 of 23 cases. Ten of 16 (62.5%) patients with UC died within 5 yrs of follow-up. Four of 10 (40%) died in less than 2 yrs. Thirteen of 33 (39.3%) patients with EE Ca G3 died of disease within 5 yrs of follow-up. Two of 13 (15%) died in less than 2 yrs.

**Conclusions:** 1) UC is a more aggressive neoplasm than EE Ca G3. Important differences are seen in the age, stage, and survival. The mean age at presentation for UC is 59 yrs while for EE Ca G3 it is 68. In the UC group, 54% of pts presented at high stage while only 30% of pts with EE Ca G3 presented at high stage. In 2 and 5 yrs 40% and 62% of pts with UC and 15% and 30% of pts with EE Ca G3 died of disease. 2) We propose modifying the endometrial carcinoma grading system by allowing for a distinction between EE Ca G3 and UC, even in cases of entirely solid tumor.

### 820 Molecular Profile of Grade 3 Endometrial Endometrioid Carcinoma (EEC): Is It a Type I or Type II Endometrial Carcinoma (EC)?

T Alvarez, AK Bhan, E Miller, E Oliva. Massachusetts General Hospital, Boston, MA.

**Background:** Two types of EC have been defined by molecular studies. Low-grade endometrioid carcinoma (EEC), the prototype of type I EC, is characterized by mutations of microsatellite instability genes (MLH-1/MSH-2), PTEN, K-ras and beta-catenin genes. Type II EC includes serous and clear cell carcinomas which frequently show p53 mutations and c-erb-2 amplification. The molecular profile of grade 3 EEC has not been well characterized. In a recent clinicopathologic study the behavior of grade 3 EEC was found to be closer to type II EC. The goal of this study is to define the immunohistochemical and molecular profile of grade 3 EEC and to compare it to type I and type II ECs.

**Design:** Two tissue microarrays were constructed from paraffin-embedded blocks of 29 grade 3 EECs. Immunohistochemical (IHC) evaluation included: p53, c-erb-2, p16, WT-1, MLH-1/MSH-2, and cyclin D. Nuclear immunoreactivity for p53, p16, WT-1, MLH-1/MSH-2 and cyclin D-1 and membranous staining for c-erb-2 were evaluated. A tumor was considered positive when more than 10% of the cells were immunoreactive and for c-erb-2 when the staining intensity was at least moderate. FISH was performed for cyclin D-1 and c-erb-2. Gene amplification was defined as the presence of either > 10 gene signals or > 3 times as many gene signals than centromere signals in at least 5% of tumor cells. Nine complete tumor sections were used as control to verify TMA results for IHC and FISH.

**Immunohistochemical results.** Loss of MLH-1: 17% (5/29); Loss of MSH-2: 10% (3/28); Loss of at least one MSI (MLH-1/MSH-2): 25% (7/28); Loss of p16: 71% (20/28); WT-1: 0% (0/29); Cyclin D-1: 26% (7/27); p53: 71% (20/28); c-erb-2: 6% (2/29).

**FISH results:** Cyclin D-1: No gene amplification was found. C-erb-2: One of the two positive tumors by immunohistochemistry showed gene amplification.

**Conclusions:** Grade 3 EECs show a molecular profile intermediate between type I and II ECs. Similarities to type II EC include frequent overexpression of p53 and loss of p16, immunohistochemical expression of cyclin D-1 and low incidence of mutations of microsatellite instability genes. However, WT1 expression, cyclin D1 and c-erb-2 amplification, more frequently seen in type II EC, were either absent or low in grade 3 EECs indicating differences between these tumors and type II EC at the molecular level.

### 821 Expression of COX-2, VEGF, Ki-67, and p53, in Squamous Cervical Neoplasia

MH Arabi, S Bandyopadhyay, L Fathallah, H Nassar, H Mujtaba, R Ali-Fehmi. Wayne State University, Karmanos Cancer Institute, Detroit, MI.

**Background:** COX-2 has been shown to play a role in carcinogenesis by stimulating angiogenesis, cell proliferation, and inhibiting apoptosis. Overexpression of COX-2 has been associated with a worse outcome in patients with invasive carcinomas in multiple organs including squamous cell carcinoma of the cervix. The aim of the study is to analyze and compare the expression of COX-2 in high grade squamous intraepithelial lesions (HGSIL) and invasive squamous cell carcinoma (ISCC).

**Design:** Formalin-fixed paraffin-embedded tissue sections from 60 cases of ISCC and 20 cases of HGSIL were immunostained using antibodies for COX-2, VEGF, Ki-67, and P53. Immunoreactivity of COX-2, VEGF, Ki-67, and P53 was semi-quantitatively scored based on staining intensity and distribution. COX-2 and VEGF were scored as high and low. Statistical analysis was performed using Chi-square and Spearman's correlation tests.

**Results:** The mean age of the patient population was 32 years (19-62 y) for the HGSIL and 55 years (23-81 y) for the ISCC. The molecular profile of the cases is shown in table 1. Overexpression of COX-2 was higher in HGSIL than in ISCC ( $P<0.004$ ), Ki-67 and P53 expressions were higher in ISCC than HGSIL lesions. VEGF expression was similar in both lesions. We found a correlation between COX-2 and VEGF expression in both lesions ( $r=0.73$ ,  $p<0.00$ ). No correlation was seen between COX-2 expression and Ki-67 or P53 expression.

Table 1

	High COX-2	Ki-67	P53	High VEGF
HGSIL (n=20)	25%	55%	14%	60%
ISCC	15%	79%	36%	57%
P value	0.004	0.000	0.164	0.1

**Conclusions:** The higher expression of COX-2 in high grade SIL compared to invasive squamous cell carcinoma in the cervix indicates a possible role for COX-2 in the early steps of carcinogenesis of squamous cervical neoplasia. We found a correlation between COX-2 and VEGF in these lesions, in keeping with the known role of COX-2 in angiogenesis.

### 822 STUMPed: Enhancing Histologic Classification of Uterine Smooth Muscle Neoplasms

KA Atkins, N Arronte, C Darius, L Rice. University of Virginia, Charlottesville, VA.

**Background:** Most uterine smooth muscle tumors (USMTs) are clearly leiomyoma (M) or leiomyosarcoma (LMS) based on a combination of mitoses, cytologic atypia, and tumor cell necrosis. However, an extremely challenging area histologically and clinically are smooth muscle tumors of uncertain malignant potential (STUMP), tumors that do not fall into an obviously benign or malignant category based on the prominence of each of the three histologic features and clinical experience. p16 is a tumor suppressor gene that has been found to be overexpressed in LMS by gene expression studies. This pilot study was undertaken to evaluate the role of p16 by immunohistochemistry in the classification of uterine smooth muscle tumors and to glean some understanding of the molecular biology of LMS.

**Design:** Twelve leiomyosarcomas, 5 STUMP, and 15 leiomyomas were reviewed, classified according to the criteria by Bell et al, and used to construct a tissue array. Clinical charts for the corresponding 32 patients were reviewed and demographic data as well as clinical outcome was recorded and correlated with findings on immunohistochemistry. The USMTs were assessed for p16 positivity by the avidin-biotin-immunoperoxidase complex method.

**Results:** 75% (9/12) LMS had over 20% strong nuclear and cytoplasmic reactivity for p16 and 2/12 had faint but diffuse reactivity compared to 8% (1 case) of M, which had focal 5% reactivity. One out of 2 initially classified STUMPs but with known recurrence had strong p16 positivity. Three of 5 STUMPS without recurrence were negative for p16.

**Conclusions:** p16 is strongly expressed by LMS and a positive reactivity may be useful in further classifying histologically difficult cases such as STUMPs. LMS may be in part a result in a defect in the p16/cyclin D1/retinoblastoma pathway. It is uncertain whether the protein is functional; this is currently under investigation.

### 823 The Presence of a Malignant Polyp in Advanced Uterine Serous Carcinoma Is Associated with a Significantly Worse Prognosis

*S Bandyopadhyay, MH Arabi, H Nassar, R Flesham, FW Abdul-Karim, AR Munkarah, R Ali-Fehmi.* Wayne State Uni, Karmanos Cancer Institute, Detroit, MI; Case Western Uni, Cleveland, OH.

**Background:** Some investigators have reported that uterine serous carcinoma arising in a polyp (USC-P) have an increased risk of metastasis and recurrence. The aim of this study is to investigate whether the presence of a malignant polyp in patients with uterine serous carcinoma has a prognostic significance.

**Design:** Using our departmental database, we identified 75 surgically staged patients with uterine serous carcinoma, diagnosed 1995-2002. The following clinical and pathological parameters were recorded: age at diagnosis, FIGO stage, postoperative therapy, length of follow-up, myometrial invasion, lymphovascular invasion, lymph nodes metastases, and adnexal involvement. For this study, we defined USC-P as any serous carcinoma where a cancerous polyp was detected in the endometrium regardless of surgical stage, confirmed by two pathologists. We compared survival of patients with USC without polyp and USC-P in early stage (IA) and late stage (III and IV) disease separately using Kaplan-Meier.

**Results:** The mean age of the patients was 70 years (53-83 y). We found 28 cases of USC-P and 46 without polyp (USC). The distribution by FIGO stage for the USC-P was: IA-16, IB-1, II-1, III-5, IV-3. The distribution by FIGO stage for the USC: IA-4, IB-6, IC-3, II-9, III-20, IV-4. The median follow up for the patients with early stage was 45 months (4-90 m) and for late stage was 25 months (2-60 m). There was no difference in survival between USC-P and USC in patients with early stage. Only one patient with USC died of disease at 10 months from diagnosis. For late stage disease, patients with USC-P had a significant worse outcome than those with USC (median survival of 4 months vs. to 29 months).

**Conclusions:** The current study shows that the prognosis of women with stage IA uterine serous carcinoma associated with a polyp is excellent and comparable to those without a polyp. The poor prognosis noted in the USC-P patients with advanced stage disease is significant and warrants further investigation.

### 824 Immunoprofile of Endocervical and Endometrial Stromal Cells and Its Potential Application in Localization of Tumor Involvement

*JE Barroeta, TL Pasha, G Acs, PJ Zhang.* University of Pennsylvania Medical Center, Philadelphia, PA.

**Background:** Determining the involvement of uterus or cervix in tumors arising in the female genital tract is critical for tumor staging. Knowledge of the immunophenotype of the stromal cells native in these locations might be helpful in localizing tumor involvement. CD10 and WT1 have been found to be specific for endometrial stromal cells (EMSC) when compared to myometrium. Little is known about their specificity when tested against endocervical stromal cells (ECSC), immunoprofile of which has not yet been well evaluated.

**Design:** Paraffin sections of benign endocervix (n20) and endometrium (n23) and adenocarcinomas of endocervix (n9) and endometrium (n12) were stained with monoclonal antibodies to CD10 and WT1 as well as other fibroblastic/myofibroblastic markers such as CD34, SMA, and factor XIIIa with standard immunohistochemical methods. The status of the benign endometria was atrophic/inactive (n5), secretory (n6), proliferative (n10) and menstrual (n1). In 17 cases, lower uterine segment (LUS) was also available for evaluation. Immunoreactivity of the background stromal cells was recorded as positive (>75% and strong staining); focally positive (<30% and dim staining); or "-".

**Results:** Results are summarized in table 1. ECSC were CD34+ and CD10- while EMSC were CD34+ and CD10+. SMA was positive in the EMSC, mostly in the basalis. WT-1 was positive in EMSC of benign endometrium but is negative in that of endometrial carcinoma (EMCA). The EMSC and ECSC phenotypes were transformed to each other or overlapped in LUS. The functional status of endometria did not change the immunoprofile of either ECSC or EMSC.

**Conclusions:** The normal immunoprofile is CD34+, CD10-, WT1- for ECSC and CD34-, CD10+, WT1+ for EMSC. The loss of WT1 expression in EMSC of EMCA is unclear and merit further study. The pattern of CD34 and CD10 staining in background stromal cells might be helpful in determining tumor location or involvement in uterine and cervical regions.

Table 1

Dx \ Ab	CD34	SMA	WT-1	CD10	FXII	D2 40
ECSC	Benign (n=20) 94 / 6 f	10 / 50 f	0 / 17 f	29 / 65 f	0 / 11 f	50
	ECCA** (n=9)	67 / 33 f	10 / 70 f	0 / 50 f	0 / 29 f	0 / 89 f
EMSC	Benign (n=23)	0 / 52 f	17 / 65 f	39 / 35 f	100	8 / 13 f
	EMCA (n=12)	8 / 25 f	42 / 58 f	0	42 / 42 f	0 / 58 f

\*All values represent percentages of positive cases. Ab: antibody, f: focal, ECCA: endocervical carcinoma, EMCA: endometrial carcinoma.

### 825 ER/PR Receptor Expression in Endometrioid Carcinoma: Do We Need To Test Every Case?

*JE Bernard, A Shabaik.* UCSD, San Diego, CA.

**Background:** Estrogen and progesterone hormone receptor status in uterine endometrioid carcinomas is used by clinicians for prognostic and treatment decisions. Previous studies have evaluated the relation between tumor expression of hormone receptors and FIGO grade and many conclude there is an inverse relationship. Experience from our daily practice suggests that almost all cases are ER and PR positive. Our interest was to test this suggestion and see if testing for ER/PR receptor expression may not be necessary in every case.

**Design:** We retrospectively reviewed estrogen and progesterone receptor immunohistochemistry results for 51 cases of uterine endometrioid carcinoma diagnosed at our institution. Histologic sections of endometrioid tumor with HE and ER/PR immunostains were examined and hormone receptor expression was graded as negative (no positivity), partially positive (<50% of tumor cells positive) and strongly positive (≥50% of tumor cells positive). Only areas of tumor with classic endometrioid morphology were evaluated for hormone expression. Of the 51 cases examined, 20 were FIGO grade 1, 21 were FIGO grade 2 and 10 were FIGO grade 3.

**Results:** All cases of endometrioid carcinoma, FIGO grade 1, expressed ER and PR in areas with classic endometrioid morphology. All but one case of FIGO grade 2 was positive for ER/PR receptor expression. All but two cases of FIGO grade 3 endometrioid carcinoma expressed ER/PR receptors.

**Conclusions:** Testing for ER/PR receptor expression may not be needed in every case of low-grade endometrioid carcinoma with classic morphology. However, a larger scale study may be needed before such a strategy is implemented.

### 826 HER-2/neu Gene Amplification in Paget's Disease of the Nipple and Extramammary Site: A Chromogenic In Situ Hybridization (CISH) Study

*MK Bianco, MA Vasef.* University of Iowa Hospitals and Clinics, Iowa City, IA.

**Background:** HER-2/neu gene amplification and/or protein overexpression predict a more aggressive clinical course in invasive breast carcinoma. With the availability of molecular targeted therapy, reliable assessment of HER-2/neu overexpression has become a routine test in most diagnostic laboratories. Currently, fluorescence in situ hybridization (FISH) is considered the gold standard in evaluating indeterminate cases by immunohistochemistry. Although FISH reliably detects HER-2/neu gene amplification, the distinction between in situ and invasive tumor is problematic. In contrast, CISH is useful for separating in situ from invasive tumor, since there is relative preservation of the architecture in this method. We employed CISH to detect HER-2/neu gene amplification in Paget's disease of the nipple and in Paget's disease of the vulva.

**Design:** Previously diagnosed cases of Paget's disease of the nipple (n=11) and vulva (n=15) were selected from the archival files of the Department of Pathology at the University of Hospitals and Clinics. Representative paraffin embedded tissue sections were studied by CISH to identify HER-2/neu gene amplification.

**Results:** Seven of eleven (64%) cases of Paget's disease of the nipple showed multiple copies of the HER-2/neu gene, evident as peroxidase positive intranuclear large clusters. In contrast, fourteen of fifteen (93%) cases of Paget's disease of the vulva showed normal copy number of the gene, evident as 2 dot-like peroxidase positive signals. In one case, up to 6 copy number of gene was identified per nucleus. This finding may likely indicate aneuploidy rather than true gene amplification.

**Conclusions:** In contrast to Paget's disease of the nipple where HER-2/neu gene amplification is commonly identifiable in a significant number of cases, this gene appears to be uncommonly amplified in Paget's disease of the vulva.

### 827 Low Grade Dysplasia Pap Smears and Negative Cervical Biopsies: Are They Really Non-Correlating Specimens?

*JP Bissonnette, DC Wilbur.* Massachusetts General Hospital, Harvard Medical School, Boston, MA.

**Background:** It is estimated that diagnostic low grade squamous dysplasia (LSIL) Pap smears and concurrent or follow up cervical biopsies have correlation rates as low as 50%. This low correlation rate can be a source of frustration for clinicians. In transient low grade dysplasias a spectrum of histologic changes may be present. This study compares LSIL Pap smears with non-correlating biopsies to define potential morphology that may represent evidence of a present or resolving HPV infection when diagnostic features are not apparent.

**Design:** LSIL cytology slides and non-correlating cervical biopsies were retrieved from the files and reviewed for confirmation of original interpretation. The biopsies were scored for morphologic changes that were below the threshold of mild dysplasia (1=normal mucosa; 2=mild nuclear enlargement without hyperchromasia that may be associated with rare dyskeratotic cells and superficial blood vessels; 3=nuclear enlargement with hyperchromasia and outline irregularity, multinucleation, dyskeratotic cells, hyperkeratosis/parakeratosis, and papillomatous change with superficial vessels; 4=diagnostic changes of mild dysplasia).

**Results:** Twenty cytology/biopsy pairs were obtained. All cytology specimens were confirmed to show LSIL and all biopsies showed no classic features diagnostic of low grade dysplasia. Fifteen of the cervical biopsies were concurrently performed at the time of cytologic sampling. Follow up biopsies included 4 at 1 month and 1 at 2.5 months. Twelve of the cervical biopsies scored 3 (60%), 7 scored 2 (35%), and 1 scored 1 (5%). None of the biopsies scored 4.

**Conclusions:** 60% of the biopsies had a score of 3, meaning that most cases showed changes apart from normal that may be considered "soft" features of a transient HPV infection. An additional 35% showed more subtle changes distinct from normal. While not diagnostic for dysplasia, mention of such changes in reports with an explanation of origin may be useful in providing optimum diagnostic information to clinicians in order to bring closure to the cytology - biopsy loop.

**828 Pathologic Features of Endometrial Cancers in Women with HNPCC**

R Broaddus, J Green, H Lynch, J Terdiman, K Lu. M.D. Anderson Cancer Center, Houston, TX; Memorial University of New Foundland, NL, Canada; Creighton, Omaha, NE; UC-San Francisco, San Francisco, CA.

**Background:** HNPCC is a familial cancer syndrome caused by mutation of a mismatch repair gene, usually MLH1 or MSH2. Traditionally, colon cancer has been the most intensely studied malignancy in this syndrome. However, it is known that women with HNPCC also frequently develop endometrial cancer. In some HNPCC families, endometrial cancer is more prevalent than colon cancer. It is not known whether HNPCC endometrial cancers have unique pathologic features compared to those in the general population. Knowing such pathologic data is critical for understanding the natural history of this disease in this unique patient population.

**Design:** A gynecological pathologist (RRB) reviewed the pathology reports and H&E stained slides for a cohort of women with HNPCC and endometrial cancer (n=49) from 4 different hereditary cancer registries (MDACC, Newfoundland, Creighton, and UCSF). The tumor histotype and grade, depth of myometrial invasion, lymphatic/vascular invasion, cervix involvement, and pathological stage were recorded. These results were compared to those from a cohort of young (less than 50 years old) women with endometrial cancer (n=42) who have been confirmed as having intact MLH1 and MSH2 via formal genetic testing. Pathologic data for a total of 91 patients was statistically analyzed by Fisher's exact test.

**Results:** No statistically significant differences in pathologic characteristics were detected between the two patient groups. The average patient age for the HNPCC endometrial cancer group was 46.9 years. Most (86%) of the HNPCC endometrial cancers were the endometrioid type, grades 1, 2, and 3. The HNPCC group tended to have more non-endometrioid tumors (papillary serous carcinoma, clear cell carcinoma, MMMT), but this difference was not statistically significant (p=0.06). Nearly 25% of HNPCC endometrial cancers were stage II or stage III at the time of hysterectomy; these cases would qualify for adjuvant therapy.

**Conclusions:** To our knowledge, this is the largest formal pathologic analysis of endometrial cancer in HNPCC. Our data suggest that the pathologic characteristics of endometrial cancer in women with HNPCC are similar to those in young, non-mutation carriers. Furthermore, the data suggest that HNPCC endometrial cancer is not associated with a particular tumor histotype. Approximately 25% of cases are stage II or greater and would require adjuvant therapy following hysterectomy.

**829 Distinctive Histology in a Subgroup of MLH-1 Methylated, MSI-High Endometrial Cancers**

R Broaddus, S Xie, E Silva, K Lu. M.D. Anderson Cancer Center, Houston, TX.

**Background:** Pathologic features of MSI-high colon cancers have been extensively studied. Certain features, such as mucinous/signet ring cell histology, tumor infiltrating lymphocytes, and Crohn's like lymphocytic infiltrate, can be associated with some of these tumors, but no microscopic feature is predictive of MSI-high. It is known that 15-25% of sporadic endometrial cancers are MSI-high due to silencing of MLH1 by promoter methylation. The pathologic features of these endometrial tumors have not been examined in detail.

**Design:** Endometrial cancers (85 endometrioid, 19 UPSC, and 24 MMMT; n=138) were examined for methylation of MLH1 via methylation-specific PCR. Since MLH1 methylation results in loss of MLH1 protein, IHC was used to confirm methylation results. MSI analysis was performed for tumors that were methylated at MLH1 and showed lack of MLH1 immunostaining. The pathologic features of the MLH1 methylated, MSI-high endometrial cancers were then analyzed via light microscopy.

**Results:** Approximately 18% (26/138) of the endometrial cancers were MSI-high due to MLH1 methylation and subsequent loss of MLH1 protein. A subgroup (5/26, 19%) of the MLH1 methylated tumors that had been previously classified as endometrioid adenocarcinoma, FIGO grade 3 (EC3), had distinctive histologic features not usually associated with EC3. This distinctive histology was characterized as "undifferentiated" in that the tumor cells were monotonous and small-to-medium sized, larger than histiocytes but smaller than usual endometrioid tumor cells. The "undifferentiated" tumor cells grew in solid, dis cohesive sheets without a pattern or gland formation. EC3 consisted of larger tumor cells that were cohesive and had at least focal gland formation. By IHC, the "undifferentiated" tumors were positive for pancytokeratin, but the staining was patchy compared to that seen in endometrioid tumors. The "undifferentiated" tumors were entirely negative for ER and PR, whereas most EC3 had at least focal staining for these hormone receptors. No staining for neuroendocrine markers was detected.

**Conclusions:** We have identified a distinctive, "undifferentiated" group of MSI-high endometrial cancers that is associated with MLH1 methylation. These tumors, however, represent only a small subgroup of all the MSI-high endometrial cancers, most of which do not have distinguishing pathologic features. Interestingly, we have not observed the "undifferentiated" histology in MSI-high endometrial cancers from women with HNPCC and MSH2 mutations, suggesting a genotype-phenotype relationship.

**830 Expression of CD1a Positive Dendritic Cells and Galectin-3 in Vulvar Squamous Lesions**

H Brustmann. Thermenklinikum, Moedling/Vienna, Lower Austria, Austria.

**Background:** Dendritic cells (DC) are antigen-presenting cells and may play a role in tumor regression as well as protective immunity to tumor growth. Galectin-3 (Gal-3) is a multifunctional protein involved in tumor biology and progression.

**Design:** Tissue sections of normal vulvar epithelial (NE, N=10), vulvar condylomas (VC, N=24), vulvar intraepithelial lesions (VIN, N=26), as well as primary vulvar squamous carcinomas (SCC, N=22) were immunostained with monoclonal antibodies against CD1a and Gal-3 (Novocastra) using a standard immunohistochemical method (Vectastain Universal Elite ABC Kit, Vector Laboratories, CA). CD1a positive

intraepithelial DC were determined as the mean number of DC out of 10 high power fields. Gal-3 immunostaining was evaluated for staining quantity and intensity and cases were categorized in three groups of negative or weak, moderate and strong immunoreactivity. SCC were staged as FIGO I (N=13) and FIGO II (N=9) as well as graded as grade 1 (N=17) and grade 2 (N=5).

**Results:** The number of CD1a expressing DC increased from NE (mean=18±standard deviation [SD]=5,33) to VC 20,25±11,6), to VIN (31,7±20,6), and was lowest in SCC (3,73±3,24). These differences were statistically significant (P<0,0001, ANOVA). DC were not related with FIGO stage (P=0,33) and grade (P=0,32); decreased numbers of DC were associated with tumor recurrence (P=0,048). Gal-3 expression was negative or weak in NE, VC and VIN; in contrast, moderate or strong cytoplasmic immunoreactivity was often found in SCC (P<0,0001). Gal-3 expression was not related with FIGO stage, grade, and recurrence (P=0,78, P=0,15, P=0,54, respectively).

**Conclusions:** Epithelial infiltration of DC is increased in VIN compared with NE and VC and significantly reduced in SCC. Cytoplasmic Gal-3 expression is significantly increased in SCC, marking a step towards an infiltrating phenotype in vulvar neoplasia.

**831 WT-1, TTF-1 and HPV Testing Can Distinguish between Small Cell Carcinomas of the Ovary, Cervix and Lung**

JW Carlson, MR Nucci, J Brodsky, CP Crum, MS Hirsch. Brigham & Women's Hospital, Boston, MA.

**Background:** The origin of small cell carcinoma (SCCA) of the ovary, hypercalcemic-type has not been established. Suggested possibilities include a variant of epithelial-stromal tumors or germ cell tumors. However, neither has been definitively validated. Although morphologically similar to small cell neuroendocrine carcinomas from other sites, the hypercalcemic variant of ovarian SCCA does not express neuroendocrine markers. Prior studies have shown that SCCA of the lung and cervix are associated with p16, and p16 and HPV, respectively; these markers have not been studied in ovarian SCCAs. The goals of this study were 1) to determine if a novel panel of immunostains and HPV testing could be used to distinguish ovarian SCCAs (hypercalcemic and pulmonary types), SCCAs of the cervix, and SCCAs of the lung, and 2) to address the histogenetic origin of SCCA, hypercalcemic-type.

**Design:** In total, 29 cases were studied: 9 ovarian SCCAs (7 hypercalcemic-type; 2 pulmonary-type), 6 SCCAs of the cervix, and 14 SCCAs of the lung (including 1 metastatic to the ovary). Cases were immunostained for TTF-1, WT-1, p16, cKIT and OCT 3/4, and tested for HPV by PCR analysis. Slides were evaluated in a blinded fashion and the results were compared between the different groups. Tumors were considered positive if >5% of tumor cells were immunoreactive.

**Results:** The findings are outlined in the following table:

	Ov. SCCA, HCa-Type	Ov. SCCA, Pulm.-Type	Cervical SCCA	Lung SCCA
WT-1	6/7 (86%)	0/2 (0%)	1/6 (17%)	0/14 (0%)
TTF-1	0/7 (5%)	1/2 (50%)	1/6 (17%)	13/14 (93%)
cKIT	0/7 (0%)	0/2 (0%)	3/6 (50%)	5/10 (50%)
OCT 3/4	0/7 (0%)	0/2 (0%)	0/6 (100%)	0/14 (0%)
p16	7/7 (100%)	2/2 (100%)	5/6 (83%)	13/14 (93%)

WT-1 was diffusely positive (4+; >50% tumor cells +) in 5 of 6 ovarian SCCAs, hypercalcemic-type; the 6th case was 2+ (5-25% tumor cells +). TTF-1 was diffusely positive in 11 of 13 lung SCCAs; 2 cases were 2+. p16 and cKIT demonstrated variable staining patterns (range <5% to >50% tumor cells +). Of the cases tested, HPV was only identified in SCCA of the cervix.

**Conclusions:** A panel of immunostains including WT-1, TTF-1, and neuroendocrine markers, plus HPV testing by PCR, can help distinguish SCCAs of ovary, cervix and lung. p16 is not useful for this differential diagnosis. The absence of cKIT and OCT 3/4 immunoreactivity further supports the hypothesis that SCCA of the ovary, hypercalcemic-type is not of germ cell origin.

**832 Cell Signaling Pathways in Ovarian Epithelial Tumors: 4EBP1 as a Novel Prognostic Factor**

J Castellvi, A Garcia, J de la Torre, F Rojo, A Gil, S Ramon y Cajal. Vall d'Hebron University Hospital, Barcelona, Spain.

**Background:** Cell signaling includes multiple pathways and a myriad of factors and proteins. Oncogenic alterations at this level is one of the hallmarks of cancer. In this sense the mTOR pathway has focused the attention of many studies. 4EBP1 is a downstream protein of mTOR that binds to eIF4E inhibiting mRNA translation. When 4EBP1 is phosphorylated releases eIF4E and favours mRNA translation and cell transformation. Moreover, eIF4E can be phosphorylated by Mnk 1 and 2, that are activated by MAPK. P70S6K is another downstream-mTOR protein that phosphorylates the ribosome protein S6, that stimulates translation of mRNA. P70S6K can also be activated by ERK/MAPK. The aim of this study is to analyse the real role of these pathways in ovarian cancer through the expression of downstream factors which drive the proliferation signal and to correlate them with clinicopathological characteristics.

**Design:** Tissue microarrays of 112 ovarian epithelial tumors were constructed, including 11 serous cystadenomas, 5 mucinous cystadenomas, 10 serous borderline tumours, 15 mucinous borderline tumors, 26 serous carcinomas, 14 mucinous carcinomas, 16 clear cell carcinomas and 15 endometrioid carcinomas. Immunohistochemistry with phospho-antibodies was done for AKT, 4EBP1, p70S6K, S6 and MAPK. Positivity was semiquantitatively scored, including intensity (0 to 3) and percentage of cells.

**Results:** 73% of the tumors were positive for 4EBP1, 43% for p70S6K, 20% for S6, 21% for AKT and 33% for MAPK. There was more expression of p70S6K and S6 in carcinomas than in benign and borderline tumors (p=0.01 and p=0.02, respectively) while there were no significant differences with 4EBP1, AKT and MAPK. Serous, clear cell and

endometrioid carcinomas showed the higher and stronger positivity for all markers. Mucinous tumor did not show relevant AKT expression. Only 4EBP1 and p70S6K were associated with decrease in the overall survival of carcinomas (log rank=0.02 and 0.05, respectively).

**Conclusions:** In ovarian carcinomas significant expression of 4EBP1 and of p70S6K were associated with high grade tumors and poor prognosis. Only 1/3 of cases positive for 4EBP1 and p70S6K had expression of AKT suggesting that they are activated by AKT dependent and independent pathways. The study of these downstream cell signaling factors, like 4EBP1, can be a hallmark in the biological characterization of epithelial ovarian tumors.

### 833 Expression of Wilms Tumor Gene (WT-1) in Primary Peritoneal Serous Carcinomas

*M Chivukula, M Kapali.* Magee-Womens Hospital, University of Pittsburgh, Pittsburgh, PA.

**Background:** WT-1 or Wilm's tumor gene is a tumor suppressor gene expressed by epithelial ovarian carcinomas and has been established to be a sensitive and specific marker of serous carcinomas of ovary. Histologically it is difficult to distinguish the serous carcinomas of the peritoneum from the ovarian serous carcinomas though the origin of the two tumors is different. Studies have showed that WT-1 is expressed in Primary peritoneal serous carcinomas (PPSC) as well but previous studies related to WT-1 expression have few only cases of PPSCs (range 3-6 cases). In our study we included larger number of cases of PPSC (25 cases) to confirm the expression of WT-1 and also included other ovarian and endometrial carcinomas.

**Design:** We retrieved 25 cases of PPSC, 20 cases of endometrioid adenocarcinomas, 2 cases of sex-cord stromal tumors and 1 case of endometrial serous papillary carcinoma. 2 cases of ovarian papillary serous carcinoma were used as control and immunohistochemical staining for WT-1 was performed.

**Results:** 23/25 (92%) cases of PPSC showed strong 3+ diffuse nuclear positivity, 1 (4%) case showed 2+ nuclear positivity and 1(4%) case showed no staining. All the 20 cases (100%) of endometrioid adenocarcinomas, sex-cord stromal tumors showed no staining with WT-1. The 2 cases of ovarian serous papillary carcinomas used as control cases showed 3+ diffuse nuclear positivity. There was focal strong positivity in 1 case of endometrial papillary carcinoma

**Conclusions:** These findings confirm the strong positive expression of WT-1 in PPSC. In general PPSC have poor prognosis and this correlates with the strong diffuse immunoreactivity with WT-1. Previous studies have shown WT-1 over expression in ovarian papillary serous carcinomas. Hence WT-1 staining does not help in distinguishing ovarian from primary peritoneal serous papillary tumors. Genetic studies may be necessary to separate these two tumor types.

### 834 Cytoplasmic CD24 Expression in Advanced Ovarian Serous Borderline Tumors

*YL Choi, SY Kang, EY Cho, GH Ahn.* Samsung Medical Center, Sungkyunkwan University School of Medicine, Seoul, Korea.

**Background:** CD24, originally described as a B-cell marker, has been known as one of the candidate molecular markers of epithelial ovarian cancer. We aimed to determine the pattern and extent of CD24 expression in ovarian serous tumors and to clarify its correlation with pathological parameters, especially those associated with the early event of tumor progression in serous tumor of borderline malignancy.

**Design:** A total of 114 ovarian serous tumors including 9 adenomas, 34 borderline and 71 carcinomas were analyzed immunohistochemically using a CD24 monoclonal antibody on paraffin blocks. The CD24 expression was evaluated as a membranous or cytoplasmic pattern. The intensity of staining was semi-quantitatively estimated as negative, weak, moderate or strong.

**Results:** In normal epithelium and serous cystadenomas, the CD24 expression was localized to the apical membranous portion. Some of borderline tumors (29.4%) showed additional cytoplasmic expression. The cytoplasmic expression of borderline tumors had statistical correlation with microinvasion ( $p < 0.001$ ) and omental implant ( $p = 0.019$ ). 70 cases of serous adenocarcinomas showed strong diffuse cytoplasmic expression of CD24, which had a statistical correlation with shortened survival ( $p = 0.0126$ ).

**Conclusions:** The loss of apical localization with the acquisition of the cytoplasmic staining of CD24 protein is a surrogate marker of stromal invasion in ovarian serous tumor of borderline malignancy. Furthermore, the increase in the cytoplasmic expression of CD24 protein is correlated with the shortened survival time of patients with ovarian serous adenocarcinomas.

### 835 KOC Expression in Ovarian Mucinous Tumors: Potential Role in Differentiating Mucinous Tumors of Low Malignant Potential from Mucinous Carcinomas

*A Ciampa, C Li, G Fanger, K Dresser, A Khan, K Rock, B Xu.* UMass Medical School, Worcester, MA; Corixa Corporation, Seattle, WA.

**Background:** Ovarian mucinous tumors are the second most common epithelial neoplasm of the ovary. Approximately 75% of mucinous tumors are benign, 10% are of low malignant potential (LMP) and 15% carcinomas. It can be difficult sometimes to distinguish mucinous LMPs from early invasive mucinous carcinomas even for an experienced pathologist. Currently, there is no reliable immunohistochemical or molecular method to aid in the separation of these two entities. In an effort to search for ancillary methods to facilitate classification of ovarian mucinous tumors, we evaluated the expression of a novel antibody - KOC (K homology domain containing protein Overexpressed in Cancer) in ovarian mucinous tumors. KOC was identified by cDNA library subtraction and monoclonal mouse antibody was raised against E. coli derived KOC protein.

**Design:** Immunoperoxidase staining using KOC monoclonal antibody was performed on formalin-fixed paraffin-embedded sections of 13 mucinous cystadenomas, 32 mucinous tumors of LMP, and 6 mucinous cystadenocarcinomas. Only strong cytoplasmic staining was considered as positive.

**Results:** Six of 6 (100%) mucinous cystadenocarcinomas were positive for KOC, 11 of 13 (85%) cases of mucinous cystadenomas were negative for KOC and 2 were focally weakly positive for KOC. Of the 32 cases of mucinous LMPs, 17 (53%) were negative, 10 (31%) were diffusely positive, and 5 (16%) were focally positive. Amongst the 10 diffusely positive LMP cases, 4 showed intraepithelial carcinoma, 2 showed microinvasion, 1 showed significant epithelial piling up and 1 showed striking stromal reaction which was explained by reaction to mucin rather than microinvasion.

KOC Positivity in Ovarian Mucinous Tumors

	KOC+	KOC-	Focal +
Adenomas (n=13)	0% (0/13)	85% (11/13)	15% (2/13)
LMPs (n=32)	31% (10/32)	53% (17/32)	16% (5/32)
Carcinomas (n=6)	100% (6/6)	0% (0/6)	0% (0/6)

**Conclusions:** KOC are expressed in all mucinous cystadenocarcinomas. Almost all mucinous cystadenomas and a majority of mucinous LMPs are negative for KOC staining. A high percentage of KOC positive LMP cases show an intraepithelial carcinoma or/and microinvasion. KOC appears to be a useful marker for tumor progression and it may be used to facilitate the distinction between mucinous LMPs from carcinomas and for early detection of an incipient carcinoma arising from a mucinous LMP.

### 836 Molecular Genotyping and Microsatellite Instability in Mixed Uterine Serous Papillary and Endometrioid Adenocarcinomas

*BZ Clark, JL Hunt, D Lomago, DJ Dabbs.* University of Pittsburgh, Pittsburgh, PA.

**Background:** Mixed serous papillary and endometrioid-type carcinomas of the endometrium are rare. Most prior studies of each separate tumor type in non-mixed tumors have suggested distinct molecular mechanisms of pathogenesis of these neoplasms. In endometrioid-type carcinomas, loss of tumor suppressor genes (TSGs) PTEN and K-ras, and microsatellite instability (MSI) are commonly observed. Loss of p53 and p16 are commonly observed in pure serous papillary carcinomas, and microsatellite instability is rare. The objective of the study was to assess loss of tumor suppressor genes and MSI in four mixed serous papillary and endometrioid-type carcinomas, and to compare the genetic profiles in the biphasic components.

**Design:** Mixed serous papillary and endometrioid-type endometrial carcinomas were selected for inclusion and the diagnosis was confirmed. Microdissection of the two components was performed from blank slides, and DNA was extracted from the tissue fragments. Polymerase chain reaction (PCR) was performed using labeled primers adjacent to and flanking TSGs. Loss of heterozygosity of six different TSGs (p53, PTEN, p21, p16, RB, and VHL) was assessed at 13 loci, and MSI was assessed using the five NCI-recommended loci.

**Results:** Allelic loss at loci associated with PTEN and P53 were observed in both endometrioid and serous papillary components in all four cases. Two cases showed additional losses associated with p21 and p16, generally with greater allelic losses in the serous papillary components. Allelic losses were observed at the same loci or in just the serous papillary component in 90% of informative loci in one case and in 81% in the other case, and no MSI was observed in either case. High-level microsatellite instability was observed in both endometrioid and serous papillary components in the two other cases, with no evidence of greater allelic loss in the serous papillary component.

**Conclusions:** In this study, two groups of mixed tumors seem to exist: those associated with MSI and possibly loss of mis-match repair genes, and those associated with loss of tumor suppressor genes. In the cases not associated with MSI, the findings strongly suggest a common clonal etiology for the two morphologically distinct components. Based on clinical data and molecular MSI data, a DNA mis-match repair defect was suggested in the two patients with high-level MSI. Additional studies of mixed tumors are needed to determine whether this phenotype has a higher risk of being associated with a hereditary cancer syndrome.

### 837 Use of Histone Deacetylase 8 (HDAC8), a New Marker of Smooth Muscle Differentiation, in the Subclassification of Mesenchymal Tumors of the Uterus, Particularly Epithelioid Smooth Muscle Tumors

*L de Leval, D Waltrigny, W Glenisson, J Boniver, RH Young, V Castronovo, E Oliva.* CHU Sart-Tilman, Liege, Belgium; Center for Experimental Cancer Research, Liege, Belgium; Massachusetts General Hospital, Boston, MA.

**Background:** Endometrial stromal tumors (EST) and smooth muscle tumors (SMT) are usually recognized on a routine morphologic basis, but their distinction is sometimes problematic. Histone deacetylases (HDACs) were originally identified as nuclear enzymes regulating histone acetylation. We recently showed that in normal human tissues, HDAC8 is exclusively expressed in the cytoplasm of cells with smooth muscle differentiation (SMD) (visceral and vascular smooth muscle cells, myoepithelial cells and myofibroblasts). In this study, we examined HDAC8 expression in SMT and EST of the uterus.

**Design:** Immunohistochemical analysis of HDAC 8 was performed on 15 leiomyomas (LM), 9 highly cellular leiomyomas (HCL), 8 epithelioid SMT (ESMT), 13 leiomyosarcomas (LMS) and 17 EST including 5 with SMD. The tumors were also stained for desmin, h-caldesmon, smooth muscle actin (SMA), smooth muscle myosin (SMM) and CD10. Extent (percentage) and intensity (1+ to 3+) of staining were recorded.

**Results:** In LM, all smooth muscle (SM) antibodies had similar expression. In HCL, desmin showed the largest extent and highest intensity of staining. In ESMT, HDAC8 had the highest percentage of positive cases, but was weak in 4/8 cases. All SM antibodies had similar frequency of staining in LMS; however HDAC8 showed overall less intensity (typically 2+). HDAC8, h-caldesmon and SMM did not stain conventional areas of ESTs.

**Conclusions:** HDAC8 is as sensitive as h-caldesmon, desmin and SMM for the diagnosis of SMT of the uterus, and it is more commonly expressed in ESMT compared to other SM markers. HDAC8 may accordingly aid in establishing the diagnosis of an ESMT which is often negative for other SM markers. Since HDAC8 and SMM were equally specifically absent in conventional areas of EST, they may be used as reliable markers in the classification of mesenchymal tumors of the uterus.

	HDAC8	Desmin	H-caldesmon	SMA	SMM	CD10
LM	15/15	15/15	15/15	15/15	15/15	6/15
HCL	8/9	9/9	9/9	9/9	9/9	4/9
ESMT	8/8	2/8	1/8	4/8	4/8	0/8
LMS	11/13	10/13	12/13	12/13	10/13	5/13
EST	5/17*	6/17**	3/17*	7/17***	3/17*	14/17****

\*only in areas of SM differentiation; \*\* in conventional areas of ESTs (4) and in areas of SM differentiation (2); \*\*\* in conventional areas of ESTs (5) and in SM areas (3); \*\*\*\* including all cases with SM differentiation

### 838 Identification of a Novel Estrogen-Regulated Gene (EIG121) That Is Overexpressed in Type 1 but Not Type 2 Endometrial Cancer

*L Deng, P Davies, G Shipley, D Loose, G Stancel, R Broaddus.* UT MD Anderson Cancer Center, Houston, TX; UT-Houston Health Science Center, Houston, TX.

**Background:** The association of endometrial endometrioid adenocarcinoma (EEC) and excessive estrogen exposure has been well established, but the underlying molecular mechanisms are largely unknown. The effects of estrogen on the endometrium are likely mediated by an array of downstream genes whose expression may be regulated by estrogen. The identification of such genes and pathways that are affected by estrogenization may shed light on the mechanisms of estrogen action in the endometrium.

**Design:** Two pools of endometrial RNA, each from 20 postmenopausal women receiving either placebo or EES estrogen replacement therapy for 3 months were subjected to cDNA microarray analysis. A novel gene identified by this approach was EIG121, a putative transmembrane receptor. The microarray results were verified by real-time quantitative RT-PCR in an additional set of benign endometrial biopsies from postmenopausal (n=30) and premenopausal (n=15) women. EIG121 expression was also measured in EEC (n=19) and uterine MMMT (n=10). The endometrioid tumors are an example of Type 1 endometrial cancer, which is associated with estrogen excess and tends to be more clinically indolent. The MMMT are an example of Type 2 endometrial cancer, which is estrogen independent and is more clinically aggressive.

**Results:** In postmenopausal endometrium, the expression of EIG121 was induced 2-3 fold by two different forms of hormone replacement therapy, EES and Premarin. In premenopausal endometrium EIG121 expression was significantly higher in the estrogen-dominated proliferative phase than the secretory phase (p<0.01). In the EEC tumors, the expression of EIG121 was drastically elevated, on average increased 57-fold compared to normal endometrium. EIG121 expression decreased with increasing tumor grade. In contrast, uterine MMMT demonstrated suppressed EIG121 expression that was less than 5% the expression observed in normal endometrium.

**Conclusions:** We have identified a novel gene, EIG121, that is induced at low levels in normal endometrium by exposure to estrogen. In endometrioid tumors, the expression of EIG121 is greatly exaggerated compared to estrogen exposed normal endometrium. The levels of EIG121 decrease with tumor grade, with less than baseline levels detected in the highly aggressive uterine MMMT. These results suggest that EIG121 may represent a good endometrial biomarker associated with the hyperestrogenic state and Type 1 endometrial cancer

### 839 Detection of HPV DNA in Metastases from Gynecologic Squamous Cell Carcinomas as an Aid to Diagnosis

*L Dobbs, L Earls, K Hewan-Lowe.* Brody School of Medicine at East Carolina University, Greenville, NC.

**Background:** Patients with a prior diagnosis of a squamous cell carcinoma (SCCA) from a gynecologic site (eg; uterine cervix or vulva) sometimes present years later with a metastasis at a site that is not typical for gynecologic tumors. The high degree of association of human papillomavirus (HPV) with SCCA of the cervix and vulva provides a unique marker for malignancies arising from these anatomic locations. Molecular testing for the presence of HPV in the primary tumor and in metastases provides objective evidence of the primary site of a metastasis.

**Design:** Five patients with a prior history of a gynecologic SCCA developed metastases in the following unusual sites: skin of the thigh, great toe, lung, mediastinal lymph nodes, supraclavicular lymph node, small bowel, and colon. Sites of the primary tumor included cervix (four cases) and vulva (one case). The time period between the diagnosis of the primary malignancies and the occurrence of metastases ranged from one to eleven years (average four years). For molecular testing, DNA was extracted from paraffin blocks of both the primary malignancy and the metastatic tumors. The extracted DNA was then tested for the presence of HPV DNA using polymerase chain reaction methodology (PCR). The primers used included either the MY09/MY11 primers or HPV16 E6-specific primers, or both. PCR products were detected using conventional agarose gel electrophoresis.

**Results:** In all five cases, HPV DNA was identified in both the primary SCCA and in the metastasis at the unusual site.

**Conclusions:** The finding of HPV DNA in the primary gynecologic SCCA and the site of unusual metastasis provides objective evidence that confirms the origin from a gynecologic primary. Both the gynecologic primary and the metastasis at the unusual site should be simultaneously tested to exclude the possibility of other HPV related SCCA. Detection of HPV DNA appears to be independent of the time at which the metastasis occurs. Therefore, in the context of an HPV related SCCA of the female genital tract, HPV testing can be used to confirm the source of a metastasis.

### 840 c-Flip Expression May Play a Role in the Suppression of Apoptosis in Endometrial Carcinoma

*X Dolcet, D Llobet, J Pallares, M Rue, X Matias-Guiu.* Hospital Universitari Arnau de Vilanova. University of Lleida., Lleida, Catalonia, Spain.

**Background:** Apoptosis resistance has an important role in tumor development and progression. c-FLIP is a key regulator of the extrinsic apoptotic pathway, triggered by death ligands of the TNF-alpha family. c-FLIP has been shown to be up-regulated in several types of human cancer.

**Design:** Immunohistochemical expression of c-FLIP was assessed in a tissue microarray (TMA), constructed from paraffin-embedded blocks of 95 endometrial carcinomas (EC). It was correlated with stage, histological type and grade, apoptotic index, and immunostaining for PTEN, AKT, Active Caspase-3, and M-30, that recognizes a neoepitope that is liberated as a result of an early caspase cleavage of cytokeratin 18 during apoptosis. Moreover, the endometrial adenocarcinoma Ishikawa cell line (ICL) was treated with either TRAIL or CH11 (antagonistic FAS antibody). It was characterized for the expression of c-FLIP, TRAIL and FAS by semiquantitative RT-PCR. Transfection of c-FLIP was performed using Lipofectamine 2000. Cell viability and apoptotic morphology was determined.

**Results:** Immunostaining for c-FLIP was frequent in the TMA (56.9% of cases). There was a statistically significant difference in c-FLIP expression between Stage I and II tumors. However, c-FLIP staining did not show statistically significant correlations with histological type and grade, apoptosis index, PTEN, AKT, Active Caspase-3, and M-30. ICL showed mRNA expression for DR4 and DR5 TRAIL receptors and FAS receptor. However, treatment of these cells with either TRAIL or CH11 failed to induce cell death. Co-treatment of ICL cells with TRAIL or CH11 plus the transcription inhibitor actinomycin D (AD) resulted in a decreased viability, induction of caspase-8 activity and apoptotic nuclear morphology. AD treatment induced marked down-regulation of c-FLIP mRNA expression. ICL transfected with c-FLIP overcomes apoptosis induced by TRAIL or CH11 plus AD treatment.

**Conclusions:** These results suggest that c-FLIP immunostaining is frequent in endometrial carcinoma. Results obtained from Ishikawa cell line suggest that c-FLIP may participate in the process of apoptosis resistance in endometrial carcinoma.

### 841 Atypical Immature Metaplasia: p16 Immunoprofiling

*MA Duggan, T Magliocco.* University of Calgary, Calgary, AB, Canada.

**Background:** Amongst lesions reported as atypical immature metaplasia (AIM), some represent an SIL (squamous intraepithelial lesion), whereas others are benign. Because p16 immunopositivity is a surrogate marker of high risk HPV DNA, it may have a role in identifying high grade SIL amongst AIM lesions. The goal of this study was to characterize the p16 immunoprofile of cervical lesions interpreted as AIM.

**Design:** All diagnoses of AIM from a regional colposcopy service were retrieved from the files of the regional laboratory. The slides were reviewed to identify the atypical area, which was then reclassified using published criteria. The area was stained with P16INK4a Ab-7 Clone 16P07 (Lab Vision Corporation, CA, U.S.A.) using standard immunoperoxidase techniques. The atypical area was reviewed and the p16 staining evaluated.

**Results:** From 172 specimens, 163 had sufficient tissue for p16 evaluation. Positivity was present in 82 (47.6%). It was focal in 59 (71.9%) and diffuse in 23 (28%), and was mostly (69.5%) in the lower or lower to middle third of the lesion. The review diagnoses were 3 (1.7%) normal, 54 (31.3%) benign, 60 (34.8%) AIM, 43 (25%) LSIL, 10 (5.8%) HSIL, and ungradeable SIL in 2 (1.1%). HSIL had a high positivity rate (80%), and a diffuse pattern of staining which occupied all or the lower two thirds of the lesion. LSIL and AIM were somewhat similar. Each had a medium positivity rate (53%), and a focal pattern of staining, which occurred in the lower and middle thirds of the lesion. Benign lesions had a low positivity rate (35%) and a focal pattern of staining mostly confined to the lower third of the lesion. Normal cervix was negative.

**Conclusions:** AIM in this laboratory is a heterogeneous entity with 32% reclassified as an SIL. p16 immunoprofiling is useful in the identification of HSIL and benign lesions. The similarity of AIM with LSIL suggests it is a type of LSIL involving immature squamous metaplasia.

### 842 Low D2-40 Immunoreactivity in Cervical Biopsy Material Predicts the Presence of Lymphatic Invasion and Nodal Metastasis

*KL Dumoff, X Xu, T Pasha, C Chu, PJ Zhang, G Acs.* University of Pennsylvania Medical Center, Philadelphia, PA.

**Background:** The recently developed monoclonal antibody D2-40 reacts with the oncofetal antigen M2A. In a series of cervical squamous cell carcinomas, we have recently found a significant correlation between the level of D2-40 immunoreactivity in the tumor cells and the presence of lymphatic invasion and nodal metastasis, suggesting that the M2A antigen may play a role in the interaction of tumor cells with the lymphatics.

**Design:** We examined whether D2-40 immunoreactivity in cervical biopsy material can predict the presence of nodal metastasis and lymphatic invasion in the main tumor mass. The pattern of D2-40 immunoreactivity was analysed using formalin-fixed paraffin-embedded sections in a series of forty-eight cases of cervical biopsies and the corresponding subsequent radical hysterectomy specimens showing invasive squamous cell carcinoma. D2-40 immunoreactivity in the tumor cells was evaluated semiquantitatively on a 4-tiered scale. Based on the extent and intensity of reactivity, an immunostaining score (0-300) was determined for each case. The correlation between the results obtained in the biopsy and hysterectomy materials, as well as the correlation of D2-40 immunoreactivity with the presence of lymphatic invasion and nodal metastasis were examined.



**Results:** We found a highly significant positive correlation between the D2-40 immunostaining scores obtained in biopsy and corresponding hysterectomy materials ( $r=0.8835$ ,  $p<0.0001$ ). In biopsy and hysterectomy materials, low D2-40 immunoreactivity (score  $<25$ ) showed a highly significant correlation with the presence of lymphatic invasion ( $p<0.0001$  for both) and nodal metastasis ( $p=0.0058$  and  $p=0.0275$ , respectively). The sensitivity, specificity, positive and negative predictive value of low D2-40 immunoreactivity in biopsy material for predicting the presence of lymphatic invasion were 0.9091, 0.8571, 0.9375 and 0.8000, respectively. The corresponding values for predicting nodal metastasis were 0.8947, 0.5000, 0.5484 and 0.8750, respectively.

**Conclusions:** The presence of lymphatic invasion and nodal metastasis are highly significant risk factors in cervical carcinoma. Our results suggest that D2-40 immunostaining may serve as a useful marker to predict the presence of these risk factors in cases when only cervical biopsy material is available in patients with unresectable disease.

#### 843 The "Mixed-Pattern Secretory" Endometrium: Is It Clonal Rather Than Hormonal?

JA Elvin, Z Peerwani, CP Crum, GL Mutter. Brigham & Women's Hospital, Boston, MA.

**Background:** Mixed patterns in secretory endometrium are common but have not been characterized in detail. This study examined the frequency and distribution of focal discrete changes in endometrial secretory maturation, with attention to possible causes.

**Design:** Fifty (50) consecutive cases of endometrial samples classified as secretory endometria were culled from divisional files and reviewed by a panel of three pathologists. Cases with evidence of exogenous hormone effect or those composed predominantly of endometrial polyp fragments were excluded. Based on consensus opinion, the cases were subdivided into those exhibiting 1) a uniform pattern of secretory differentiation and 2) focal discrete changes in secretory maturation. The mean ages of the two groups were tabulated.

**Results:** The endometrial biopsy specimens were obtained from women ranging in age from 32 to 52 (mean age = 41.9) for a variety of clinical indications, including menorrhagia, intermenstrual spotting, infertility, recurrent pregnancy loss, fibroids and endometrial polyps. In 17 of 41 evaluable samples (41.5%) two or more glands were identified that were distinguished from the background secretory pattern by one or more of the following: 1) a frankly proliferative phenotype, 2) tubular glands with pseudostratified nuclei lacking mitotic activity or secretory maturation, and 3) glands containing secretory features but demonstrating pseudostratified epithelial cells and/or enlarged nuclei. In virtually all cases, the glands in question were confined to a discrete region of the sample and in some, clearly linked to a specific gland unit. The mean age for those with focal alterations in secretory maturation were the same as those without (40.6 with artifact; 42.1 without artifact). No association between the indication for biopsy and the presence or absence of the clonal population were identified.

**Conclusions:** The observational data strongly indicate that clonal events occurring within the endometrium are common during the reproductive years and will influence the morphologic appearance of secretory phase endometrium identified in biopsies and curettings. We further suggest that clonal regions of endometrial glands, which are unable to respond normally to luteal phase hormones from the ovarian follicle, rather than an abnormal luteal phase ovarian follicle, produce the histologically recognizable mixed pattern secretory endometrium.

#### 844 Exfoliation Artifact in Endometrial Samples: A Unique Mimic of Papillary Serous Carcinoma (UPSC) Associated with Hysteroscopy

JA Elvin, CP Crum. Brigham & Women's Hospital, Boston, MA.

**Background:** Uterine papillary serous carcinoma (UPSC) carries a poor prognosis, and its recognition (and exclusion) in endometrial samples is critical in diagnostic practice. Arias-Stella-like reactions, hypersecretory endometria, reparative surface epithelial changes, and a variety of metaplastic and neoplastic patterns may mimic UPSC. This report summarizes our experience with 10 endometrial samples that contained a unique benign mimic, which we term "exfoliation artifact".

**Design:** The cases under study were accrued in routine practice and were brought to the attention of the authors when divisional pathologists were concerned that neoplasia was present. Cases were brought to the divisional conference over a period of two years and this entity was identified after repeated review.

**Results:** Exfoliation artifact was characterized by disaggregated luminal epithelial cells within endometrial glands, producing a picture reminiscent of "intraglandular papillary" growth patterns seen in UPSC. Typically, multiple contiguous glands were involved in a zonal distribution, each with a uniform pattern of disorganization that was most prominent on the luminal surface. Nuclei were darkly stained, but were uniform and indistinct, often with poor cytoplasmic preservation. The adjacent stroma typically displayed subtle preservation artifacts that accompanied the exfoliation artifact and diminished in areas of normal appearing glands. In extreme cases, the entire epithelium exfoliated, filling the gland lumen. In 2 cases p53 immunostaining was negative. In all cases with clinical information, a history of hysteroscopy was obtained.

**Conclusions:** Exfoliation artifact is a distinct procedure-related entity that can mimic UPSC. Features helpful in distinguishing this process from UPSC include its zonal distribution, lack of conspicuous nuclear atypia, uniform disaggregation of the luminal epithelial cells, and subtle but discernible preservation artifacts in the adjacent endometrial stroma. A p53 immunostain will differentiate UPSC from exfoliation artifact, but is typically not necessary if attention is paid to the aforementioned histologic features.

#### 845 Platelet Derived Growth Factor Receptor-alpha Expression Is Frequently Observed in Clear Cell Carcinoma of the Ovary

RE Emerson, LA Baldrige, D Matei. Indiana University School of Medicine, Indianapolis, IN.

**Background:** Carcinomas of the ovarian surface epithelium commonly present at advanced stage and most cases are not cured with existing chemotherapy regimens. Therefore, there is great interest in uncovering molecular alterations in these tumors that may lead to new therapeutic interventions. Platelet derived growth factor receptor (PDGFR) overexpression has been observed in several neoplasms, primarily in tumors derived from the mesenchyme. PDGFR- $\alpha$  expression has been noted in 30-40% of ovarian carcinomas. We evaluated a series of primary ovarian clear cell carcinomas for immunohistochemical evidence of PDGFR- $\alpha$  expression and for activation of a downstream target of PDGFR, phosphorylated Akt (pAkt).

**Design:** Nineteen primary clear cell ovarian carcinomas were evaluated. Immunohistochemical staining was performed with antibodies reactive with PDGFR- $\alpha$  and pAkt. Slides were scored based on the degree of cytoplasmic staining in the malignant epithelial cells with a 0 to 3+ scale.

**Results:** Moderate (2+) or strong (3+) staining for PDGFR was seen in 16/19 (84%) of clear cell carcinomas. Moderate or strong staining for pAkt was seen in 17/19 (89%) clear cell carcinomas, suggesting that the PDGF-PDGFR pathway is activated in this setting.

**Conclusions:** PRGFR overexpression is observed in ovarian clear cell carcinomas in a higher percentage of cases than that reported for serous and endometrioid carcinomas. Given that ovarian clear cell carcinomas have poor clinical outcome and are chemoresistant, this observation has therapeutic significance suggesting that these tumors may be suitable for therapies targeting PDGFR.

#### 846 Frequency of Allelic Loss of Tumor Suppressor Genes in Uterine Smooth Muscle Tumors

NN Esposito, JL Hunt, A Bakker, MW Jones. University of Pittsburgh, Pittsburgh, PA; Magee-Womens Hospital of UPMC, Pittsburgh, PA.

**Background:** Uterine smooth muscle tumors of uncertain malignant potential (STUMP) are difficult both from the diagnostic and patient management standpoint since they are not classifiable as benign or malignant by conventional histologic criteria. Relatively few studies have compared leiomyomas (LMY), STUMP, and leiomyosarcomas (LMS) at the genetic level. This study used genetic profiling across a series of tumor suppressor genes to analyze the frequency of allelic imbalance (AI) in these diagnostically challenging cases.

**Design:** Typical LMY, STUMP, and LMS were included and the initial pathologic diagnosis was confirmed for this IRB-approved study. Both tumor and adjacent normal myometrium were microdissected, DNA was extracted, and fluorescence based polymerase chain reaction (PCR) targeting short tandem repeats near 7 tumor suppressor genes (p16, p21, p53, VHL, XRCC3, RB, NM-23) was performed. PCR products were detected using semi-quantitative capillary gel electrophoresis. The height of the allele peaks in tumor samples was compared to normal. A ratio of  $<0.75$  was considered to indicate the presence of AI. Fractional allelic loss (FAL) was calculated as the number of loci with AI divided by the number of informative loci. Data were assessed for statistical significance using SPSS software (Fisher's exact test).

**Results:** Five LMY, six STUMP, and 10 LMS were selected to be included. The mean FAL for LMY (18%) was not significantly different from that of STUMP (21%), while the mean FAL of LMS (52%) was significantly different from that of LMY ( $p=0.001$ ) and STUMP ( $p=0.002$ ). Loss of NM-23, a reported tumor metastasis suppressor gene, was found only in LMS (56%). Mean follow-up was 41 months (STUMP) and 64 months (LMS). None of the six patients with STUMP experienced recurrent disease, while eight of the 10 patients diagnosed with LMS died of recurrent and/or metastatic disease. There was no significant difference in FAL between patients with LMS who died of disease and those who were alive at follow-up.

**Conclusions:** Uterine LMS have significantly higher frequencies of allelic loss than both LMY and STUMP, and uniquely exhibit loss at the NM-23 gene locus. The difference in rate of AI between LMY and STUMP is not significant, suggesting that STUMP are probably not borderline or low-grade malignant neoplasms. Rather, they may represent an unusual morphologic variant of LMY. Molecular profiling may thus provide a valuable tool in assessment of malignancy in uterine smooth muscle tumors.

#### 847 Primitive Neuroectodermal Tumors of the Uterus. The M.D. Anderson Experience

ED Euscher, EG Silva, MT Deavers, CF Levenback, A Malpica. The University of Texas M.D. Anderson Cancer Center, Houston, TX.

**Background:** Primitive neuroectodermal tumors (PNETs) in the uterus are very rare neoplasms with fewer than 20 cases reported in the literature thus far. In this study, we present the clinicopathologic features of 17 such cases seen at the M.D. Anderson Cancer Center (MDACC) over a period of 11 years.

**Design:** Seventeen cases of PNETs were retrieved from the files of the Department of Pathology at our institution spanning 1993-present. All of the pathology material was reviewed at MDACC. In all cases, immunohistochemistry was utilized. The most common immunoperoxidase stains included: cytokeratin (15), synaptophysin (16), neurofilament (11), and CD99 (9). Clinical information was obtained from patients' charts, and death was confirmed using social security death index databases.

**Results:** Ages ranged from 31-81 years (median 58). Clinical presentations included vaginal bleeding (9); back pain (1); presumed fibroids (2), pelvic mass (1), incidental finding at hysterectomy (1); and unknown (3). Twelve patients had surgery or imaging to determine stage: I (2); II (0); III (6); and IV (4). Five patients had biopsy only. Twelve tumors were pure PNET. In 2 tumors, PNET was the major component



admitted with unclassified sarcoma or rhabdomyosarcoma. In 3 cases, PNET was a minor component admixed with Grade 2 endometrioid carcinoma, adenocarcinoma or MMMT. Immunoperoxidase studies results are as follows: 13/15 tumors were cytokeratin negative, and 2 were focally positive; 15/16 were synaptophysin positive; 10/11 were neurofilament positive; and 7/9 were CD99 positive, and 2 had nonspecific staining. Follow up ranged from 1 to 41 months: dead of disease (8), no evidence of disease (2), alive with disease (1) and alive with an unknown disease status (2). Four patients were lost to follow up. Both patients without evidence of disease were stage III, and PNET was either pure or the major element. One patient had neoadjuvant chemoradiation followed by hysterectomy, and one had extensive surgery followed by hormonal therapy. **Conclusions:** In conclusion, PNET of the uterus is a rare tumor usually discovered at an advanced stage in postmenopausal women. Cytokeratin, neurofilament, synaptophysin, and CD99 can aid in making the diagnosis. An aggressive course may be seen even in stage I tumors, but prolonged survival can be achieved with aggressive surgery and/or chemoradiation.

#### 848 A Clinicopathologic Study of E-Cadherin and $\beta$ -Catenin Expression in Early Stage Cervical Carcinoma Using a Tissue Microarray

*O Fadare, H Reddy, J Wang, D Hileeto, PE Schwartz, W Zheng.* Yale University, New Haven, CT; University of Southern California, Los Angeles, CA.

**Background:** The disruption of intercellular adhesions is an important component of the acquisition of invasive properties in epithelial malignancies. Alterations in the cell-cell adhesion complex, E-Cadherin/ $\beta$ -Catenin, have been implicated in the oncogenesis of carcinomas arising from various anatomic sites. In this study, we investigated the immunohistochemical expression of E-Cadherin and  $\beta$ -Catenin in a cohort of early stage cervical cancers to determine its prognostic significance.

**Design:** A tissue microarray of 147 cases of FIGO stage IA and IB cervical carcinomas (96 Squamous cell carcinomas [SCC], 35 adenocarcinomas [AC], 12 adenocarcinomas [ASQ], 4 miscellaneous types) was constructed from our archived surgical pathology files and stained with monoclonal antibodies to E-Cadherin [NCH-38, DakoCytomation, CA] and  $\beta$ -Catenin [17C2, Novocastra, UK]. Cases were scored by multiplying the intensity of staining (1 to 3 scale) by the percentage of cells stained (0-100%) for a potential maximum score of 300. For both markers, preserved expression was defined as bright membranous staining with a score of 200 or above. Impaired expression included any of the following: negative staining, a score less than 200, or exclusively cytoplasmic or nuclear delocalization.

**Results:** Impaired expression of  $\beta$ -Catenin was found in 85.7%, 66.7% & 58.3% of AC, SCC and ASQ respectively. Comparison of AC and SCC expression rates showed only a marginally significant difference ( $p=0.06$ ); SCC compared with ASQ showed no statistically significant difference [NS] ( $p>0.05$ ). Impaired expression of E-Cadherin was found in 94.3%, 86.5% & 100% of cases of AC, SCC & ASQ respectively. The differences between the histologic subtypes were NS. For the whole cohort, a comparison of cases showing impaired versus preserved expression of E-Cadherin and  $\beta$ -Catenin expression showed NS with respect to recurrence free survival, overall survival, patient age, histologic grade, and lymphovascular invasion. There was no correlation between the status of both markers for all 3 histologic subtypes (overall Spearman correlation co-efficient  $r=0.12$ ,  $p=0.14$ ).

**Conclusions:** Impairment of E-Cadherin and  $\beta$ -Catenin expression is very frequent in stage I cervical cancers. However, in this study, E-Cadherin and  $\beta$ -Catenin expression did not significantly correlate with clinicopathologic parameters of prognostic significance.

#### 849 Clinicopathologic Features of Rhabdomyosarcoma of Gynecologic Origin in Adults

*SE Ferguson, S Anderson, DS Chi, W Gerald, RA Soslow.* Memorial Sloan-Kettering Cancer Center, New York, NY.

**Background:** Rhabdomyosarcoma (RMS) is the most common soft tissue tumor found in children. Up to 20% of tumors originate in the genital tract making this the second most common site. However, RMS of gynecologic origin in adults is less common and there is little published literature on the sites of origin, histologic subtypes and clinical outcomes. The purpose of this study was to describe the clinical and pathologic features of gynecologic RMS in adults.

**Design:** Histologic slides were reviewed from women 16 years of age and older who were diagnosed with RMS between 1963 and 2003. Cases were included if they contained the classic histologic features of RMS as described in the 2003 WHO classification of tumors and excluded if they contained any atypical or malignant epithelial components. Clinical data were obtained through retrospective chart review.

**Results:** Fifteen patients were identified with a median age at diagnosis 46 (16-69) years. The primary tumor site was: cervix 8 (53%), uterus 3 (20%), vulva 2 (13%), ovary 1 (6.7%), and fallopian tube 1 (6.7%). Eleven of the tumors were of embryonal histologic subtype (cervix 8, uterus, 1; ovary, 1). The other histologic subtypes included alveolar, 2 (vulva) and pleomorphic, 2 (uterine 1, fallopian tube 1). The majority (79%) of these patients presented with locoregional disease (Intergroup RMS Study Group I - III). Twelve patients (86%) were primarily treated with a surgical procedure and 7 received initial chemotherapy. Of the 11 patients with adequate follow-up data, 9 (82%) had recurrent disease and 8 (73%) were dead of disease at a median follow-up time of 17 (4-112) months. The median time until recurrence was 7 (0-21) months.

**Conclusions:** To our knowledge, this report represents the largest series in the literature of RMS in adult women. Though most women presented with locoregional disease there was a high rate of recurrence and poor overall survival, which contrasts the pediatric population. In addition, less than half of these patients received chemotherapy as a component of their initial treatment. Adult RMS of gynecologic origin appears morphologically similar to pediatric RMS however their behavior is

more aggressive with poor overall survival. It is unclear whether these outcomes are the result of differences in clinical management or because these tumors are biologically distinct. These patients should be considered for upfront systemic therapy due to the aggressive nature of these tumors.

#### 850 Clinicopathologic Features of Bone Metastases in Patients with Endometrial Cancer

*SE Ferguson, R Soslow.* Memorial Sloan Kettering Cancer Center, New York, NY.

**Background:** Endometrial cancer is the most common gynecologic malignancy in women with over 40,000 new cases estimated for 2004. Though most women present with stage one disease and have excellent overall survival there is estimated to be over 7,000 deaths due to recurrent endometrial cancer. The majority of recurrences occur locally; however, distant metastases do occur. The purpose of this study was to describe the clinical and pathologic features of endometrial cancer metastatic to bone.

**Design:** All women with endometrial cancer with metastatic disease to bone were identified between 1980 and 2003. Cases were included if they had biopsy proven metastatic endometrial cancer to bone. Clinical data were obtained through retrospective chart review.

**Results:** Seventeen patients were identified with a diagnosis of endometrial cancer metastatic to bone. Only seven (41%) had the diagnosis confirmed by a bone biopsy. The median age at time of their endometrial cancer diagnosis was 59 years (range, 31-64 yrs). All patients had FIGO stage III/IV disease (IIIb, 1; IIIc, 3; IVb, 2; unstaged, 1). The majority of tumors were of endometrioid histology (86%) and were FIGO grade II or III (86%). The remaining case was a clear cell carcinoma, and none were serous. The median time to bone metastases was 7 months (range, 0-12 mos). Two patients had bone metastases at time of initial diagnosis and four (57%) developed metastatic disease to bone as their first site of recurrence. All of the patients had pain at the site where metastatic disease was later confirmed. Three (42%) had a negative bone scan; however all of these women had positive CT or MRI imaging. The most common sites of bone metastases were, pelvic (5); vertebral spine (2), femur (2), calvarium (1), humerus (1), tibia (1), ribs (1), and clavicle (1). All patients had therapy for their recurrence using radiotherapy (5), resection (4), chemotherapy (5) or a combination (7) of these. Of the 6 patients with follow-up data within the last 6 months, 2 are dead of disease and 4 are alive with disease.

**Conclusions:** Endometrial cancer metastasizes to bone; however, this is a rare event. Women who ultimately develop bone metastases present with high stage disease. The sites of bony metastases are heterogeneous however they most commonly occur in pelvic bones. Since these women uniformly present with bone pain, this symptom should warrant further investigation.

#### 851 The Effects of Androgen Therapy on the Female Genital Tract

*LV Ffolkes, V Agrawal, MC Parkinson, E Benjamin.* University College London Hospitals NHS Trust, London, United Kingdom; Institute of Urology, London, United Kingdom.

**Background:** Androgens are used therapeutically for a wide variety of conditions but their use in women has been limited due to unwanted virilising side effects. The histological features induced by these drugs on the female genital tract are therefore, rarely seen. Female patients desiring female-to-male gender reassignment are given intensive psychotherapy together with androgen therapy for a minimum period of one year. This is followed by definitive surgery comprising salpingo-oophorectomy, total abdominal hysterectomy and reconstructive genital surgery. Genital tract histology from an audit of patients undergoing gender reassignment surgery is presented.

**Design:** Gender reassignment surgery (1993-2003) was identified from pathology database files and the study restricted to 28 patients (aged 24 to 54 years) in whom androgen intake was validated. Most patients received 250mg of testosterone (Sustanon) intramuscularly monthly. The duration of therapy was 1 to 17 years, mean 7 years, median 6 years. A small group were given daily oral androgen therapy. Slides from the operative specimens were reviewed and histological features of the cervix, endomyometrium, ovaries and fallopian tubes were noted.

**Results:** Common findings in the cervix were atrophy of the ectocervix or replacement of squamous epithelium by transitional type (13/28). The endometrium showed predominantly inactive or weakly proliferative glands in 21/28 cases. In one case menstrual endometrium was seen. Recent corpora lutea were seen in the ovaries of 8/28 patients. The myometrium and fallopian tubes were unremarkable.

**Conclusions:** Long term androgen therapy induces specific changes in the cervix and endometrium. The presence of corpora lutea in the ovaries indicates a failure of suppression of ovulation in some patients receiving long term therapy. There was no evidence of malignancy in the specimens examined.

#### 852 Early Complete Hydatidiform Mole: A Clinicopathologic Study of 210 Cases

*M Fukunaga.* Jikei University Daisan Hospital, Komae, Tokyo, Japan.

**Background:** With the increased use of ultrasound complete hydatidiform mole (CM) is being diagnosed at increasingly early stages of gestation. Thus, the classic features of CM may be lacking and CM can be easily misdiagnosed as partial mole (PM) or hydropic abortion (HA).

**Design:** Between 1981 and 2002, 210 cases of early CM (6-12 weeks' gestation, mean: 9.2 weeks) were identified at Jikei University Hospital and its affiliated hospitals. Clinicopathologic features of early CMs were examined. These cases were also analyzed by DNA flow cytometry (FC).

**Results:** Patients ages ranged from 18 to 48 years (mean: 29.2 years). Histologically, villi showed diffuse or focal stromal edema with bulbous or clubbed outlines and focal to circumferential trophoblastic hyperplasia. Villous stroma was hypercellular with capillary-like structures, and karyorrhectic debris was observed. Extravillous

intermediate trophoblasts showed atypia. There were no fetal parts or amnion. Two patients had twins with CM. These cases were histologically characterized by two populations of villi, one with non-edematous stroma and another with edema and moderate trophoblastic hyperplasia. No nucleated red blood cells were observed except in the two cases with twins. By DNA FC, 155 cases were diploid, 29 tetraploid and 26 (non-triploid, non-tetraploid) aneuploid. There were no histologic differences among the diploid, tetraploid and aneuploid CMs. In the follow-up information, 14 of 73 diploid CMs (19.2%) and 4 of 18 tetraploid CMs (22.2%) had invasive mole, and one each with diploid and tetraploid CMs developed choriocarcinoma. None of 18 patients with aneuploid CM had sequelae.

**Conclusions:** Early CMs have somewhat different histologic features than classical second-trimester CMs. The histologic features include: 1) bulbous or club-shaped villi, 2) focal or diffuse villous edema, 3) focal to circumferential trophoblastic hyperplasia, 4) cellular villous stroma with capillary-like structures and karyorrhectic debris, 5) atypia of extravillous intermediate trophoblasts. When only limited material is submitted, CM may be diagnosed on histology alone. There were no histologic differences among the diploid, tetraploid and aneuploid CMs. DNA FC is helpful in equivocal cases. Aneuploid CMs are associated with lower risk for persistent disease than diploid or tetraploid CMs.

### 853 Interobserver and Intraobserver Variability in the Diagnosis of Hydatidiform Mole

*M Fukunaga, H Katabuchi, T Nagasaka, Y Mikami, S Minamiguchi, JM Lage.* Jikei University, Komae, Tokyo, Japan; Kumamoto University, Kumamoto, Japan; Nagoya University, Nagoya, Aichi, Japan; Tohoku University, Sendai, Miyagi, Japan; National Kyoto Medical Center, Kyoto, Japan; Medical University of South Carolina, Charleston, SC.

**Background:** Surgical pathologists often encounter hydropic villi in products of conception at the 1<sup>st</sup> trimester and must determine whether the villi represent complete hydatidiform mole (CM), partial hydatidiform mole (PM) or hydropic abortion (HA). The distinction between these is important to decide treatment for patients. The aim of this study is to assess inter- and intraobserver variability in the histologic diagnosis of hydatidiform mole among 5 placental pathologists.

**Design:** To evaluate interobserver variability, one representative slide from each of 50 mixed cases of PM, CM and HA of the 1<sup>st</sup> trimester were circulated among 5 placental pathologists. All pathologists used the same histologic criteria by Szulman and Surti (Am J Obstet Gynecol 1978; 132:20-27). For the 2<sup>nd</sup> round, the same cases were submitted with DNA ploidy data. For the 3<sup>rd</sup> round, the slides were recoded and distributed to assess intraobserver agreement. Kappa ( $\kappa$ ) value was calculated for the interobserver agreement in the 1<sup>st</sup> and 2<sup>nd</sup> rounds.

**Results:** There was agreement among 4 or 5 pathologists for only 30 of 50 cases in the 1<sup>st</sup> round. There were problems in differentiating between PM and HA in most of the remaining 20 cases. The  $\kappa$  values varied from poor ( $\kappa = -0.104$ ) to excellent ( $\kappa = 0.761$ ) in the 1<sup>st</sup> round. In the 2<sup>nd</sup> round, there was agreement in 39 of 50 cases and the level of agreement remarkably increased and ranged from fair to good ( $\kappa = 0.552$ ) to excellent ( $\kappa = 0.851$ ). The number of discrepant cases, PM versus HA, was reduced to 2. 7 cases showed difficulties in distinguishing CM from HA. The intraobserver agreement ranged from 50% to 90%.

**Conclusions:** Poor interobserver agreement was demonstrated when histology alone was used for diagnosis. Discordance was most frequently seen in PM versus HA, and resulted from the difficulty in the evaluating trophoblastic hyperplasia. Polar trophoblastic growth seen in HA could be observed in PM. The addition of ploidy data resulted in a significant improvement in concordance. Ploidy study is useful in equivocal cases. Significant interobserver and intraobserver variability was observed among even placental pathologists. New histologic criteria adaptable for differentiation of early lesions are needed.

### 854 Uterine Cellular Leiomyomata: Molecular Resemblance to the Usual Type Leiomyomata

*HG Gao, K Mittal, L Chiriboba, H Yee, JJ Wei.* New York University, New York, NY.

**Background:** Uterine cellular leiomyomata, a variant of benign leiomyomata, account for a small proportion of fibroid uteri. The cellular features of the tumors sometimes create a diagnostic challenge. Immunostains may be needed to differentiate them from leiomyosarcomas or endometrial stromal tumors. Although the pathogenesis of uterine leiomyomata remains unknown, many molecular changes have been identified in the usual type. Application of the established markers for the cellular type may be useful in the molecular level to characterize the biological behaviors of the cellular type. In this study, we examined some selected tumorigenic factors in the cellular type leiomyomata and compared the findings with those in the usual type leiomyomata.

**Design:** A total of 30 hysterectomy specimens with the uterine cellular leiomyomata and the matched myometrium were collected. Tissue cores from the myometrium (2 cores) and the tumors (3 cores) were arrayed on one block. The potential tumorigenic factors ER, PR, GCR, RXR, RAR, MIB-1, BCL-2, hamartin, HMG2 and S100 were examined by immunohistochemistry, scored by semiquantitation and analyzed by mean values of net gain or loss of the markers in the tumors compared with the matched myometrium. The expression pattern of the markers from 30 cases of the cellular type was compared with those from 120 cases of the usual type leiomyomata.

**Results:** The mean age for hysterectomy with the cellular leiomyomata was 50.2 yrs (ranged from 37 to 76 yrs), which was 4 years older than the mean age for hysterectomy with the usual type leiomyomata. The average tumor size was 5.1 cm (1.6 cm smaller than the tumor size of the usual type leiomyomata). The nuclear receptors of PR, RXR, and RAR were up regulated, ER had a minimal change and GCR was down regulated in 80% cellular leiomyomata compared with the myometrium. The up regulations of BCL2 and HMG2 were found in more than half of the cases. No change of hamartin in tumors compared with myometrium was noted. The

immunoreactivity for MIB-1 in the tumors was three times higher than that in the matched myometrium. S-100 was found to be focally immunoreactive in 40% of normal myometrium but negative in all tumors.

**Conclusions:** We previously established a panel of selective tumorigenic markers in the usual type leiomyomata. The expression pattern of the markers in the 30 cellular leiomyomata is almost identical to that in 120 usual type leiomyomata. Therefore, we conclude that the molecular pathogenesis of the cellular leiomyomata may be similar to the usual type leiomyomata.

### 855 Ephrin B1 in Ovarian Tumours: A Potential Therapeutic Target Expressed in a Subset of Carcinomas

*A Garcia, J Castellvi, J De la Torre, J Hernandez, F Rojo, S Ramon y Cajal.* Vall d'Hebron University Hospital, Barcelona, Spain.

**Background:** Differential gene expression studies are showing new set of genes that can be related with prognosis is determined human tumours. In some studies ephrin B1 was shown to be upregulated in ovarian carcinomas. Because ephrin B1 is an angiogenic factor and a tyrosin-kinase protein, it could be a relevant target in cancer treatment. The aims of this work is to study ephrin B1 expression in epithelial ovarian tumours by immunohistochemistry and western-blotting, comparing its results with histological type, grade of differentiation and overall survival.

**Design:** Tissue microarrays of formalin fixed and paraffin embedded as well as western-blotting obtained by frozen tissue of 112 ovarian epithelial tumours were constructed and immunohistochemistry, for ephrin B1 were performed. The series included 11 serous cystadenomas, 5 mucinous cystadenomas, 10 serous borderline tumours, 15 mucinous borderline tumors, 26 serous carcinomas, 14 mucinous carcinomas, 16 clear cell carcinomas and 15 endometrioid carcinomas. A three-tiered score system was used to evaluate the immunohistochemical expression.

**Results:** Ephrin B1 was detected in almost 60% of ovarian tumours. A higher expression was observed in clear cell carcinomas (90%), serous carcinomas (80%) and endometrioid carcinomas (50%). Well differentiated mucinous carcinomas and benign tumour were negative. The differences of positivity between malignant carcinomas and benign tumours were statistically significant ( $p=0.002$ ). Ephrin B1 expression was associated with a decrease rate of disease recurrence and overall survival although no statistical significance were observed in a univariate analysis ( $p=0.13$ ).

**Conclusions:** A distinctive pattern of ephrin B1 expression can be observed in ovarian tumours. Clear cell, serous, and endometrioid carcinomas show higher expression, while well differentiated mucinous carcinomas, borderline and benign tumours are predominantly negative. Borderline tumours were negative or showed a mild positivity. Because, eph receptors and ephrins are a target for new therapeutic inhibitors, this pattern of ephrin B1 expression should be considered in future clinical studies.

### 856 Interobserver Variation in the Assessment of Extra-Ovarian Implants of Serous Borderline Tumors (Serous Tumors of Low Malignant Potential)

*CB Gilks, JK McKenney, S Kalloger, TA Longacre.* University of British Columbia, Vancouver, BC, Canada; University of Arkansas for Medical Sciences, Little Rock, AR; Stanford University, Stanford, CA.

**Background:** The most important prognostic factor in patients with advanced stage serous borderline tumors is assessment of the invasiveness of the extra-ovarian implants. There is currently no consensus with respect to which features of the implants are most significant, nor have there been studies on the reproducibility of histopathological assessment of the implants.

**Design:** Slides from 151 cases of advanced stage serous borderline tumor were identified in the archives of the Dept. of Pathology, Stanford University. The following features were assessed in the extra-ovarian implants: cleft formation, micropapillarity, infiltration of single epithelial cells, mitotic activity, nuclear pleomorphism, presence of nucleoli. As well, the invasiveness of the implants was assessed according to the criteria of Bell, Weinstock, and Scully (BWS) (Cancer 1988:2212) and Bell, Smith Sedhev, and Kurman (BSK) (Am J Surg Pathol 2001:419), respectively. Comparison of inter-observer variation was done by calculation of kappa ( $\kappa$ ) statistic, where a  $\kappa$  value of 0-0.4 indicates no or minimal agreement, 0.4-0.6 moderate agreement, 0.6-0.8 substantial agreement and 0.8-1 near perfect inter-observer agreement.

**Results:** The interobserver agreement in assessment of single histological parameters ranged from substantial to none, with kappa statistics for each variable assessed as follows: presence of micropapillarity -  $\kappa = 0.71$ , individual cells within the stroma -  $\kappa = 0.50$ , mitotic activity -  $\kappa = 0.46$ , periglandular cleft formation -  $\kappa = 0.34$ , prominent nucleoli -  $\kappa = 0.20$ , nuclear pleomorphism -  $\kappa = -0.03$ . Assessment of invasiveness proved to be much more reproducible, whether according to the BWS criteria ( $\kappa = 0.84$ ) or the BSK criteria ( $\kappa = 0.72$ ).

**Conclusions:** While there is considerable interobserver variation in the assessment of individual histopathological parameters within extra-ovarian implants of serous borderline tumors, architectural features tend to be more reproducibly assessed than cytological features. There is excellent inter-observer agreement in the over-all assessment of implant invasiveness.

### 857 The Clinical Role of Phospholipase A<sub>2</sub> in Metastatic Ovarian Carcinoma

*M Gurevitz, CG Trope, B Davidson, R Reich.* School of Pharmacy, Faculty of Medicine, The Hebrew University of Jerusalem, Jerusalem, Israel; The Norwegian Radium Hospital, University of Oslo, Oslo, Norway.

**Background:** The Arachidonic acid (AA) pathway has been shown to have a central role in the biology of epithelial tumors. Phospholipase A<sub>2</sub> (PLA<sub>2</sub>) initiates this cascade

by releasing AA from cell membranes. The present study analyzed the expression of PLA<sub>2</sub> and its relationship with matrix metalloproteinase (MMP) expression and clinical parameters in metastatic ovarian carcinoma.

**Design:** Seventy-eight fresh frozen malignant effusions from patients diagnosed with epithelial ovarian carcinoma were studied for mRNA expression of secretory PLA<sub>2</sub> (sPLA<sub>2</sub>) IB and IIA, their receptor sPLA<sub>2</sub>R, cytoplasmic PLA<sub>2</sub> (cPLA<sub>2</sub>), PLA<sub>2</sub>-activating protein (PLAP) and MMP-2 using RT-PCR. Phosphorylated cPLA<sub>2</sub> (p-cPLA<sub>2</sub>) protein expression was studied in 124 effusions and 23 corresponding solid tumors using immunohistochemistry (IHC). Expression was analyzed for possible correlation with effusion site, FIGO stage, histological grade, chemotherapy status and survival.

**Results:** PLA<sub>2</sub> isoforms, sPLA<sub>2</sub>R, PLAP and MMP-2 mRNA was found in the majority (>95%) of specimens. p-cPLA<sub>2</sub> protein was expressed in 107/124 (86%) effusions. sPLA<sub>2</sub>R levels correlated with cPLA<sub>2</sub> (p=0.02) and sPLA<sub>2</sub>-IB (p=0.002) levels, and PLAP expression correlated with that of sPLA<sub>2</sub>-IIA (p=0.001). sPLA<sub>2</sub>-IIA (p=0.018) and p-cPLA<sub>2</sub> expression correlated with that of MMP2 (p=0.003). Lower expression of sPLA<sub>2</sub>-IIA (p<0.001) and p-cPLA<sub>2</sub> (p=0.023) was found in post-chemotherapy effusions. In univariate survival analysis of all patients, PLAP mRNA expression predicted worse overall survival (OS, p=0.047), with both worse OS (p=0.003) and progression-free survival (PFS, p=0.016) in patients with post-chemotherapy effusions.

**Conclusions:** PLA<sub>2</sub> isoforms are frequently expressed in metastatic ovarian carcinoma. The co-expression of PLA<sub>2</sub> and sPLA<sub>2</sub>R suggests autocrine signaling along this pathway in this cancer. PLAP is a novel predictor of poor outcome in metastatic OC cells in effusions.

**858 Diagnostic Utility of Immunohistochemical Expression of Cdx2 and Cytokeratin (CK)7/20 in Metastatic Carcinomas of the Ovary from Gastrointestinal Tract**

HI Ha, H-I Lee, MJ Kim, JY Ro, K-R Kim. University of Ulsan College of Medicine, Asan Medical Center, Seoul, Korea.

**Background:** Metastatic tumors to the ovary are often clinically detected prior to the primary tumors. Cdx2 is known to be a specific and sensitive immunohistochemical marker for the intestinal differentiation and its high frequency expression has been described in the gastrointestinal adenocarcinomas. We evaluated whether the frequently used immunohistochemical markers for tracing primary sites, Cdx2, CK 7 and 20, are helpful to suggest a gastrointestinal tract as a possible primary site of the metastatic ovarian carcinomas in this country, where Krukenberg tumor is common.

**Design:** We examined the immunohistochemical expression of Cdx2, CK 7 and 20 on the 118 metastatic carcinomas of the ovary from stomach (n=71 cases), large intestine (n=43), and appendix (n=4), of which the primary sites could be confirmed by clinical, radiological, and histopathologic findings. Expression patterns were correlated with the primary organ site, location of the tumor (antrum/body/cardia for stomach, left/right for large intestine), and histologic differentiation of metastatic tumor (well/moderate/poor, intestinal/diffuse).

**Results:** In the tumors of gastric origin, the most frequent CK7/20 pattern was CK7+/20+ (56%) followed by CK7+/20- (23%) and CK7-/CK20+ (19%), and Cdx2 was positive only in 34%. In the tumors of large intestinal origin, the most frequent pattern was CK7-/20+ (61%) followed by CK7+/20+ (32%) and CK7+/20- (7%), and Cdx2 was positive in 61%. In the tumors of appendiceal origin, CK7+/20+ and CK7-/20+ were identified in 50% each, and Cdx2 was positive in 50%. Cdx2 expression was significantly lower in the poorly differentiated and signet ring cell carcinomas than in the well or moderately differentiated carcinomas, and in the diffuse type than the intestinal type of both gastric and large intestinal origins. The CK7/20 expression patterns were not correlated with the location of the tumor within the same organs or the histological differentiation of the tumor.

**Conclusions:** Care must be taken in the application of these markers because their expressions are less sensitive and less specific in metastatic carcinomas of the ovary than in the primary sites, and these results may be attributable to a higher incidence of metastasis in the poorly differentiated or signet ring cell carcinomas to the ovary than in the well or moderately differentiated carcinomas.

**859 Differential Expression of Cadherins and Catenins Associates with Distinct Ovarian Carcinoma Types**

D Hardisson, D Sarrió, G Hernández-Cortés, C Sánchez-Estévez, G Moreno-Bueno, A Suárez, J Palacios. Hospital La Paz (UAM), Madrid, Spain; Centro Nacional de Investigaciones Oncológicas (CNIO), Madrid, Spain; Hospital La Paz (UAM), Madrid, Spain.

**Background:** Ovarian carcinoma (OvC) is the leading cause of death among all gynecologic malignancies. In the last years, it has been demonstrated that alterations in the cadherin-catenin adhesion complexes are involved in tumor initiation, progression and metastasis. The aim of this study was to evaluate the immunoreactivity of the cadherin-catenin complex in ovarian carcinoma and to correlate their expression with clinicopathological features.

**Design:** Immunohistochemical staining was performed in 85 ovarian carcinomas: clear cell (CCs), n=31; serous (SCs), n=28; endometrioid (ECs), n=13; mucinous (MCs), n=13 using a tissue microarray. Mouse monoclonal antibodies against E-cadherin, P-cadherin N-cadherin, cadherin-11, β-cadherin, γ-catenin, and p120ctn were applied using the LSAB method.

**Results:** Overall, membranous expression of E-CD, N-CD, and P-CD was observed in 96%, 29.8%, and 8.4% of the OvCs analyzed, respectively. Cadherin-11 was rarely expressed in tumor cells but frequently in the stromal cells adjacent to the tumor nests. Each of the cadherins was differentially expressed among the histological types of OvCs: E-CD preserved expression was frequent in MCs (61.5%) but very rare in SCs (3.6%). Serous tumors showed the higher incidence of N-CD (67.9%) and P-CD (21.4%)

expression compared to the other histotypes. MCs and CCs rarely expressed N-CD or P-CD. With respect to catenins, significative differences were observed among the histological types: CC tumors and SCs showed more frequently reduced or absent expression of β-catenin, γ-catenin and p120 than other types. MCs were characterized by the frequent preservation of the three catenins. Abnormal nucleocytoplasmic β-catenin expression was clearly associated with the EC histotype, since all cases showing this pattern (12%) were endometrioid tumors (p<0.001). Cytoplasmic localization of γ-catenin and p120 was observed in 4.5% and 7% of OvCs respectively, but these expression patterns were not associated to any histological type.

**Conclusions:** Our results suggest that each of the different histological types of OvC show a distinct cadherin and catenin expression profile that could help in the differential diagnosis of these tumors and could explain differences in biological characteristics, such as the ability to dissemination.

GRANTS: FIS PI020342, PI020355

**860 Frequency of Extrauterine Disease in Serous Carcinoma and Serous Endometrial Intraepithelial Carcinoma (EIC) Confined to an Endometrial Polyp**

D Hileeto, O Fadare, W Zheng. Yale University School of Medicine, New Haven, CT.

**Background:** Uterine papillary serous carcinoma (UPSC) and its early form serous endometrial intraepithelial carcinoma (EIC) are both unique in their propensity to show extensive extrauterine disease even when present as minute foci within the endometrium. It is unclear whether the extrauterine disease represents metastasis or multicentricity. However, it is known that early UPSC or serous EIC tend to involve endometrial polyps (EMP). The purpose of the current study is to compare the frequency of extrauterine disease in UPSC and/or serous EIC that are entirely confined to EMP to potentially gain more insight into the role of EMP in these highly malignant neoplasms.

**Design:** All cases of EMP-confined UPSC, serous EIC, or serous EIC & UPSC diagnosed over an 8-year period (1995-2003) were retrieved from the archived Surgical Pathology files at Yale. In these cases, uterine disease was entirely limited to the associated EMP, with no disease in the adjacent endometrium or elsewhere in the uterus. These cases were then investigated for the presence of histologically confirmed extrauterine disease. Frequencies of extrauterine disease between the groups were compared using Chi Square analysis.

**Results:** There were 18 UPSC, 7 serous EIC and 16 serous EIC/UPSC confined to EMP. The frequencies of extrauterine disease were 5/18 (28%), 0/7 (0%) and 8/16 (50%) respectively. Extrauterine disease was significantly less likely to be identified in serous EIC confined to an EMP compared to either UPSC or serous EIC/UPSC that is similarly EMP-confined (p<0.05). Although serous EIC/UPSC appeared to have a much higher frequency of extrauterine disease compared to pure UPSC, the difference was not statistically significant.

**Conclusions:** Our findings confirm previous studies showing that serous carcinoma is frequently associated with extrauterine disease even when confined to an EMP. However, serous EIC confined to an endometrial polyp seldom shows extrauterine disease based on this study. The findings suggest an as yet undefined modulatory role of EMP on the biologic properties of serous EIC that are confined to them. Further studies on the role of other factors including EMP stroma or epithelial stromal interactions within EMP are needed.

**861 Mucinous Carcinomas of the Ovary: Immunohistochemistry Can Help Distinguish Primary Mucinous Ovarian Carcinoma from Metastatic Mucinous Carcinoma of Appendiceal Origin**

MS Hirsch, JL Hornick. Brigham & Women's Hospital and Harvard Medical School, Boston, MA.

**Background:** Primary ovarian mucinous adenocarcinomas (ACAs) can be difficult to distinguish from GI metastases. This distinction is critical for proper staging and patient management. In particular, appendiceal ACAs may be clinically occult, and not uncommonly present as metastases. A recent study has shown that ovarian surface involvement, bilaterality, and vascular invasion favor a metastasis. However, in some cases, histologic findings alone are insufficient to make this distinction, and ancillary studies may be required. Little data exist regarding the immunophenotype of appendiceal mucinous ACAs. The goal of this study was to determine whether a panel of immunostains could help distinguish primary ovarian mucinous ACAs from metastatic mucinous appendiceal ACAs to the ovary.

**Design:** In total, 51 tumors were studied: 21 primary ovarian mucinous ACAs, 22 primary appendiceal mucinous ACAs, and 8 appendiceal mucinous ACAs metastatic to the ovary were immunostained for CK7, CK20, MUC2, CDX-2, DPC4 (Smad4), and β-catenin. Slides were evaluated in a blinded fashion, and the results were compared between the different groups.

**Results:** The findings are outlined in the following table:

Immunohistochemistry Results in Mucinous Adenocarcinomas

	Primary Ovarian	Primary Appendiceal		Metastatic Appendiceal	
CK7	21/21 (100%)	7/22 (32%)	p<0.01	2/8 (25%)	p<0.01
CK20	9/21 (43%)	21/22 (95%)	p<0.01	8/8 (100%)	p<0.01
MUC2	8/21 (38%)	21/22 (95%)	p<0.01	8/8 (100%)	p<0.01
CDX-2	6/21 (29%)	22/22 (100%)	p<0.01	7/8 (88%)	p=0.01
DPC4 (loss)	1/21 (5%)	6/22 (27%)	p=0.09	2/8 (25%)	NS
βcatenin (nuclear)	0/21 (0%)	2/22 (9%)	NS	0/8 (0%)	NS

The frequency of staining for CK7, CK20, MUC2, and CDX-2 was significantly different between primary ovarian mucinous ACAs and primary or metastatic mucinous appendiceal ACAs. In the appendiceal mucinous ACAs, nearly all positive cases showed strong, diffuse staining for CK20, MUC2, and CDX-2 in >50% of tumor cells. In contrast, diffuse staining for these markers was rarely observed in primary ovarian mucinous ACAs.

**Conclusions:** A panel of immunohistochemical markers including CK7, CK20, MUC2, and CDX-2 can help distinguish metastatic mucinous appendiceal ACA from primary ovarian mucinous ACA. The low sensitivity of DPC4 and  $\beta$ -catenin for appendiceal mucinous ACAs limits their use in this differential diagnosis.

#### 862 The Weakly Positive Hybrid Capture II<sup>®</sup> (HCII) Result for HPV: Correlation with Polymerase Chain Reaction

*MS Hirsch, L Yuan, CP Crum, JM Federscheider.* Brigham & Women's Hospital, Boston, MA.

**Background:** Hybrid capture II (HCII) is routinely used to screen for human papillomavirus (HPV) in Thin-prep specimens following a diagnosis of ASCUS. The findings are thought to be highly specific for an absence of HPV infection with a RLU <1; however, the specificity of weakly positive values (RLU 1-5) is variable.

**Design:** Consecutive Thin-prep specimens with a diagnosis of ASCUS were analyzed by HCII. Samples scoring between 1 and 5 RLU were analyzed by PCR using generic primers designed to amplify a wide range of HPVs. HPV types were determined by RFLP of digested viral DNA products (Access-Genetics). Results were scored as negative, low risk, uncertain risk (HPV 53), high risk, and unknown type.

**Results:** Over a 5-month period, 1604 specimens were analyzed by HCII; 517 (32%) were HCII positive (RLU > 5), and 990 (62%) were negative (RLU < 1). The remaining 97 (6%) were weakly positive (RLU 1-5). Eight-five of these cases were analyzed by PCR: 34 (40%) were negative for HPV, 13 (15%) were low risk, 10 (12%) were of uncertain risk, 21 (25%) were high risk, and 7 (8%) were of unknown subtype. There was no distinct clustering of RLU values for each set of diagnoses rendered by PCR: values when negative for HPV ranged from 1.07-4.83; values with a low risk diagnosis ranged from 1.22 to 4.22; those of uncertain risk ranged from 1.23 to 4.42; values with a high risk HPV ranged between 1.13 and 4.75; and those of unknown HPV subtype ranged between 1.32 and 4.47. Follow-up information (i.e. subsequent pap smear, cervical biopsy or cone, endocervical curettings, or repeat HPV testing) was available for 15 cases. Seven cases that were negative by PCR were negative at follow up. One negative case was followed by a cone biopsy that was positive for HSIL. Two low-grade positives by PCR were negative on subsequent biopsy. Five high grade HPV results by PCR had follow-up sampling: 3 were negative and 2 were HSIL on biopsy.

**Conclusions:** A substantial percentage of weakly-positive HCII assays for HPV are either not corroborated by PCR or are attributed to HPVs other than the common high risk types (55%), amounting to approximately 3% of all HCII tests in this practice. Validation of weakly-positive HCII tests by a second assay is recommended. However, the sensitivity of PCR in this setting, and the degree of risk imposed by surrogate factors (such as age, subsequent exposures) for a short-term HSIL outcome in this group are unknown.

#### 863 The Roles of Mitogen-Activated Protein Kinase in Serous Borderline Tumor and Low-Grade Serous Carcinoma

*C-L Ho, G Pohl, RJ Kurman, T-L Wang, I-M Shih.* Johns Hopkins Medical Institutions, Baltimore, MD; National Chung-Kung University, Tainan, Taiwan.

**Background:** Our previous studies have demonstrated that a subset of serous tumors that include low-grade serous carcinoma and its precursor, serous borderline tumor (SBT) harbor mutations in either KRAS or BRAF. Activating mutations in KRAS and BRAF genes are thought to contribute to tumor development through constitutive activation of their downstream target, mitogen-activated protein kinase (MAPK). The purpose of this study is to investigate the molecular mechanism of KRAS/BRAF/MAPK pathway in the tumorigenesis of ovarian low-grade serous tumor.

**Design:** To address the role of MAPK in tumor development of low-grade ovarian serous tumors, we inactivated MAPK in ovarian tumor cells using CI-1040, a compound that specifically inhibits MEK, an upstream effector of MAPK and thus prevents MAPK activation. Cellular proliferation and apoptosis were determined in ovarian serous tumor cell lines and primary cultures and the results correlated with the mutational status of KRAS and BRAF. Long serial analysis of gene expression (SAGE) was performed to identify the downstream molecular target of activated MAPK.

**Results:** We observed profound growth inhibition and apoptosis in CI-1040 treated tumor cells (MPSC1) with mutations in either KRAS or BRAF as compared to the ovarian cancer cells containing wild-type sequences with the same treatment. LongSAGE identified several differentially expressed genes in CI-1040 treated MPSC1 cells which harbored an activating mutation in BRAF (V599L). The most striking were downregulation of cyclin D1 in which the pattern were also observed in 5 CI-1040 treated tumor cells based on quantitative real-time PCR. Constitutive expression of cyclin D1 partially reversed the growth inhibitory effect of CI-1040 in MPSC1 cells.

**Conclusions:** Our findings indicate that an activated MAPK pathway is critical in tumor growth and survival for ovarian tumors with KRAS or BRAF mutations through the expression cyclin D1 and suggest that the MAPK inactivation-induced phenotypes depend on the mutational status of KRAS and BRAF in ovarian tumors.

#### 864 Mutations of BRAF and KRAS Precede the Development of Ovarian Serous Borderline Tumors

*C-L Ho, RJ Kurman, T-L Wang, I-M Shih.* Johns Hopkins Medical Institutions, Baltimore, MD.

**Background:** Molecular genetic changes that are associated with the initiating stage of tumor development are important in tumorigenesis. Ovarian serous borderline tumors (SBTs), putative precursors of low-grade serous carcinomas, are among the few human neoplasms with a high frequency of activating mutations in BRAF and KRAS genes. However, it remains unclear as to how these mutations contribute to

tumor progression. To address this issue, we compared the mutational status of BRAF and KRAS in both SBTs and the adjacent epithelium from cystadenomas, the presumed precursor of SBTs.

**Design:** A total of eight small SBTs and the associated cystadenomas were collected. The epithelium from the SBTs and adjacent cystadenoma was collected separately using the Palm laser capture microdissection microscope. Genomic DNA was prepared and was subject to mutational analysis of KRAS and BRAF genes.

**Results:** We found that 3 of 8 SBTs contained mutant BRAF and 4 SBTs contained mutant KRAS. All specimens with mutant BRAF harbored wild type KRAS and vice versa. Thus, 7 (88%) of 8 SBTs contained either BRAF or KRAS mutations. The same mutations detected in SBTs were also identified in the cystadenoma epithelium adjacent to the SBTs in 6 (86%) of 7 informative cases. As compared to SBTs, the cystadenoma epithelium, like ovarian surface epithelium, lacks cytological atypia.

**Conclusions:** Our findings provide cogent evidence that mutations of BRAF and KRAS occur in the epithelium of cystadenomas adjacent to SBTs and strongly suggest that they are very early events in tumorigenesis, preceding the development of SBT.

#### 865 Immunohistochemical Studies of Clear Cell Carcinomas of the Ovary and Non-Small Cell Carcinomas of the Lung with Clear Cell Features

*NR Howell, W Zheng, L Cheng, PB Kane, SX Liang.* SUNY, Stony Brook, NY; Yale Sch of Med, New Haven, CT; Indiana Univ Sch of Med, Indianapolis, IN.

**Background:** Clear cell tumors occur as primary neoplasms in a number of anatomical sites. Since they share many overlapping morphological features, these tumors can be challenging for the pathologist, especially when presenting as metastatic lesions in uncommon locations. For example, diagnosing metastatic clear cell carcinoma from the lung in the ovary can be difficult. There have been no case reports in the literature. We recently encountered a case that posed this challenge and was resolved with the use of immunohistochemical stains. We expanded the study to include a panel of immunohistochemical markers to differentiate primary ovarian clear cell carcinoma (OCCC) from primary lung cancer with prominent clear cell features (LCCC).

**Design:** Fourteen OCCC (n=14) and 14 LCCC (n=14) were retrieved from files at Stony Brook University Hospital from 1994 to 2003. Paraffin sections were analyzed for TTF1, WT1, OCT4, ER, PR, CEA, and CA125. Five percent or more cells with positive staining were considered as positive. Statistical analysis was performed with the Chi-square test. P value <0.05 was considered statistically significant.

**Results:** Table 1 summarizes the results of positive immunostains. Seven LCCC but none of the OCCC stained with TTF1. Eighty-five percent LCCC but none of the OCCC stained with CEA. All OCCC and 1 LCCC stained with CA125. These results are statistically significant. In addition, a new marker, OCT4, which is known to stain some gynecologic malignancies, showed positive stains in 28% of OCCC, as compared to none in LCCC, which also has statistical significance (p=0.031). WT1, ER and PR showed variable staining in a small number of cases in both LCCC and OCCC. Those differences do not reach a statistically significant level.

**Conclusions:** Immunohistochemical stains can play an important role in determining the origin of clear cell carcinoma when both lung and ovary are involved by morphologically similar tumors. TTF1, OCT4, CEA and CA125 are the most useful markers. A combination of clinical information, histology and immunohistochemical stains can aid in identifying the primary site of a clear cell carcinoma.

	LCCC (n=14)	OCCC (n=14)	p value
TTF1	7 (50)	0	0.002
WT1	2 (14)	4 (28)	0.357
OCT4	0	4 (28)	0.031
ER	1 (7)	4 (28)	0.139
PR	0	3 (21)	0.067
CEA	12 (85)	0	<0.001
CA125	1 (7)	14 (100)	<0.001

#### 866 Minimal Uterine Serous Carcinoma: A Clinicopathological Study of 40 Cases

*P Hui, M Kelly, D O'Malley, F Tavassoli, P Schwartz.* Yale University School of Medicine, New Haven, CT.

**Background:** "Minimal uterine serous carcinoma" is a recent term to include "intraepithelial serous carcinoma" or "endometrial intraepithelial carcinoma" and "superficial serous carcinoma", representing the non-invasive intraepithelial and early invasive stages of uterine serous carcinoma, respectively. Studies of such early carcinomatous changes are important as the background endometrium may harbor pre-neoplastic alterations, especially precursor lesions or benign lesions in transformation.

**Design:** A search of Yale's pathology files from 1985 through 2003 was performed to identify consecutive cases of minimal uterine serous carcinoma. H&E stained sections were reviewed. P53 immunohistochemistry was performed. Follow-up data was obtained by reviewing medical records.

**Results:** Forty cases of minimal uterine serous carcinoma were identified. All patients were postmenopausal. There were 9 cases of intraepithelial serous carcinoma and 31 cases of superficial serous carcinoma. Five intraepithelial serous carcinomas and sixteen superficial serous carcinomas exclusively involved an endometrial polyp. Eighteen minimal uterine serous carcinomas also involved, in addition to a polyp, the endometrium proper in the form of intraepithelial serous carcinoma (13 cases) and superficial serous carcinoma (5 cases). Strong and diffuse nuclear staining of p53 was seen in 68% of the cases. Overall, minimal uterine serous carcinomas were found to involve an endometrial polyp in 88 % of the cases (35/40) and were confined to the polyp in 53% (21/40). Extruterine tumors were present in 45 % of the cases (18/40). Twenty-two patients with tumor limited to their uteri demonstrated an overall survival of 94% (2 to 73 months of follow-up). Eight of 18 patients with extruterine tumors died of their malignancy (1.5 to 62 months of follow-up).

**Conclusions:** A significant majority of minimal uterine serous carcinomas involve an endometrial polyp. Complete surgical staging is important to predict the prognosis. When the lesion is confined to an endometrial polyp and/or the endometrium proper, the clinical outcome is excellent. The strong association between a minimal uterine serous carcinoma and an endometrial polyp in postmenopausal women suggests that the latter may provide a microenvironment, within which precursor lesions for serous carcinoma may develop. Such an association deserves a greater attention, both in clinical practice and in exploring the pathogenesis of this aggressive malignancy in women.

### 867 Uterine Tumors Resembling Ovarian Sex Cord Tumors Are Polyphenotypic Neoplasms with True Sex Cord Differentiation

JA Irving, S Carinelli, M Arguelles, J Prat. Hospital de la Santa Creu i Sant Pau. Autonomous University of Barcelona, Spain; Istituti Clinici di Perfezionamento, Milano, Italy.

**Background:** Uterine tumors resembling ovarian sex cord tumors (UTROSCT) are an unusual group of neoplasms exhibiting a predominant sex cord-like morphology. Immunohistochemical markers of sex cord, endometrial stromal, smooth muscle, and epithelial differentiation were applied to a series of UTROSCT to determine their utility in the diagnosis and phenotyping of these tumors.

**Design:** The clinical and pathological features of 5 UTROSCT and 3 endometrial stromal tumors with sex cord-like elements (ESTSCLE) were reviewed. Immunohistochemistry for calretinin, melan A, CD99, inhibin, CD10, desmin, and CAM 5.2 was performed on formalin-fixed, paraffin-embedded tissue from each case.

**Results:** All 8 cases showed immunoreactivity for  $\geq 1$  markers of sex cord differentiation. Results for the 5 UTROSCT cases are shown below. (-, negative; +, <10%; ++, 10-50%; +++, >50% of tumor cells positive)

Case	Calretinin	Melan A	CD99	Inhibin	CD10	Desmin	CAM 5.2
1	+++	++	-	+	+++	-	++
2	+++	-	+	-	++	-	-
3	+++	+	+	-	+	+	+++
4	+++	-	+++	+	-	+	+++
5	+++	-	+	-	+	+	+++

**Conclusions:** 1) UTROSCT show immunoreactivity for multiple markers of sex cord differentiation, most consistently for calretinin. 2) Morphologically and immunohistochemically, UTROSCT are polyphenotypic tumors with true sex cord differentiation.

### 868 Synchronous Endometrioid Carcinomas of the Uterine Corpus and Ovary: Alterations in the Beta-Catenin Pathway Are Associated with Independent Primary Tumors and Favorable Prognosis

JA Irving, LI Catasus, A Gallardo, E Bussaglia, M Romero, X Matias-Guiu, J Prat. Hospital de la Santa Creu i Sant Pau. Autonomous University of Barcelona, Spain; Medical College of Georgia, Augusta, GA.

**Background:** Diagnosis of synchronous endometrioid carcinomas of the uterine corpus and ovary as either separate independent primary or as metastatic tumors may be facilitated by molecular analysis in problematic cases. Furthermore, determination of genetic alterations associated with this group of neoplasms may indicate molecular markers of less aggressive behaviour.

**Design:** We examined 12 cases of synchronous carcinomas of the uterus and ovary, correlating conventional gross and histological parameters with molecular genetic alterations common to single endometrioid carcinomas occurring in these sites.

**Results:** We identified a high frequency of molecular alterations in both independent and metastatic tumors, including microsatellite instability (uterine tumors, 50% and 67%, respectively; ovarian tumors, 33% and 67%) and *P TEN* mutations (uterine tumors, 38% and 100%; ovarian tumors, 33% and 83%). Nuclear immunoreactivity for beta-catenin and *CTNNB1* mutations were restricted to independent uterine and ovarian tumors; these alterations were not identified in any tumors in the metastatic group. In contrast to metastatic tumors, the diagnosis of independent primary endometrioid carcinomas was associated with favorable patient outcome, with 8 of 9 patients showing no evidence of disease at a mean 4.75 years (range 0.6-11.9 years) from the operative date.

**Conclusions:** The restriction of nuclear immunoreactivity for beta-catenin and *CTNNB1* mutations to independent uterine and ovarian tumors, and their absence in any of the metastatic tumors provides direct evidence for a divergence of molecular mechanisms for oncogenesis in the subset of synchronous endometrioid carcinomas. The molecular genetic classification of synchronous independent versus metastatic tumors based on beta-catenin expression/mutation correlates with the clinical outcome.

### 869 Lung Carcinoma Metastatic to the Ovary - A Clinicopathologic Study of 33 Cases

JA Irving, RH Young. Massachusetts General Hospital, Boston, MA; Harvard Medical School, Boston, MA.

**Background:** Information on spread of primary lung carcinoma to the ovary is limited. We report the largest series of such cases to date to better characterize this phenomenon and review issues related to the differential diagnosis with primary ovarian tumors.

**Design:** We reviewed the clinicopathologic features of 33 cases of lung carcinoma metastatic to the ovary, occurring synchronously or one antecedent to the other.

**Results:** The mean patient age was 46 years (range 26 to 76). A history of prior lung carcinoma was documented in 48% of cases (16/33); lung and ovarian tumors occurred synchronously in 36% (12/33), and an ovarian tumor was detected prior to the lung tumor in 5 cases (15%). Almost half of all cases were small cell carcinomas (42%), and the remainder were large cell undifferentiated carcinomas (30%) and adenocarcinomas

(24%); there was a single case of squamous cell carcinoma and one atypical carcinoid. Tumor was limited to the lung and one or both ovaries in 51% of cases. Two-thirds of the ovarian tumors were unilateral; of these, 13 (68%) were right-sided. Morphologic features common to many of the ovarian tumors were multinodular growth, widespread necrosis, and extensive lymphovascular invasion; involvement of the ovarian surface was infrequent. The most common primary tumors considered in the differential diagnosis included unusual variants of surface epithelial tumors and sex cord stromal tumors.

**Conclusions:** 1. The most common primary lung tumors metastatic to the ovary are small cell carcinomas, followed by large cell undifferentiated and adenocarcinomas; metastatic squamous cell carcinoma is rare.

2. Lung carcinoma metastatic to the ovary tends to occur in relatively young women, with the lung primary being occult in occasional cases.

3. When morphologic patterns unusual for a primary ovarian neoplasm are encountered, attention to clinical history and pathological features including multinodular growth, extensive necrosis and lymphovascular invasion, should enable the correct diagnosis to be made in the majority of cases without need of special studies. Absence of associated typical surface epithelial neoplasia may be a helpful clue to a metastatic nature, indicating the importance of thorough sampling.

### 870 Fatty Acid Synthase (FAS) Expression in Invasive Cervical Carcinomas

H Ji, CY Hsu, BM Ronnett, TC Wu, FP Kuhajda. The Johns Hopkins Medical Institutions, Baltimore, MD.

**Background:** Fatty acid synthase (FAS) is the enzyme responsible for endogenous synthesis of saturated long-chain fatty acids through the NADPH dependent condensation of acetyl-CoA and malonyl-CoA. In recent years, a growing body of evidence indicates that FAS is over-expressed by several human cancers, such as breast, prostate, endometrium and ovary. It has also been shown that inhibition of FAS leads to significant anti-tumor effects in both human breast and prostate cancer xenografts. Therefore, FAS has been identified as a new therapeutic target for established human cancer. This study is to evaluate FAS expression in invasive cervical carcinomas.

**Design:** Immunohistochemical staining for FAS expression was performed on tissue microarray sections of 124 cervical squamous carcinomas and 14 cervical adenocarcinomas. Three human cervical cancer cell lines, HeLa, CaSki and SiHa, were cultured onto glass slides and stained for FAS by immunocytochemical methods. A monoclonal mouse anti-human FAS antibody was used. In addition, the enzymatic activity of FAS in cervical cancer cell lines was measured using a  $^{14}C$  acetate-incorporation assay in the presence of a potent FAS inhibitor, C75.

**Results:** Diffuse cytoplasmic staining of FAS was detected in 82.3% (102/124) squamous carcinomas and 71.4% (10/14) adenocarcinomas. All three cervical cancer cell lines showed strong cytoplasmic FAS expression. The FAS enzymatic activity of the cell lines was significantly inhibited by incubation with C75 (t test,  $p < 0.05$ ).

**Conclusions:** Our results demonstrate that FAS is expressed by the majority of cervical carcinomas, and FAS activity is significantly decreased by the presence of an inhibitor. Therefore, FAS may represent a potential drug target for management of invasive cervical carcinomas.

### 871 Areas of Leiomyoma Associated with Some Uterine Leiomyosarcomas

A Joutovsky, K Mittal. NYU School of Medicine, New York, NY.

**Background:** Pathogenesis of uterine leiomyosarcomas (LMS) is poorly understood. It is unknown if these tumors arise de-novo or from pre-existing leiomyomata (LM) or atypical leiomyomata. In this study we evaluated morphologic heterogeneity within uterine LMS to identified possible precursor lesions.

**Design:** We reviewed 10 cases of total hysterectomy performed for the diagnosis of LMS. All slides from the grossly recognized tumor were evaluated for the degree of atypia and mitotic count within the leiomyosarcomas. The slides with the lowest and highest mitotic count were stained with monoclonal antibody to p53, MIB-1 and ER/PR. The number of cells stained was subjectively assessed to nearest 5%, with 1% for rare positive cells.

**Results:** Morphologically benign tumor areas were identified in 5 of the 10 tumors. These areas showed < 5 mitoses/10 HPF, with 1+ atypia in 4 cases and 1-2+ atypia in one case. Immunostains could be done in 4 of these 5 cases. These morphologically benign areas showed a p53 expression of 1% in each of the 4 cases, with low MIB-1 and high ER/PR expression. Morphologically malignant areas had 13 to 31 mitosis/10 HPF, 2+ to 3+ atypia, p53 expression of 70% to 100% and MIB-1 expression of 40% to 100%. The benign and malignant areas merged imperceptibly in all cases.

**Conclusions:** Morphologic and immunohistochemical spectrum of changes from benign to malignant is seen in 50% of LMS. Some uterine LMS may arise from pre-existing leiomyomata.

### 872 Women with Undiagnosed Colorectal Adenocarcinomas Presenting with Ovarian Metastases: Clinicopathologic Features and Comparison to Women with Known Colorectal Adenocarcinoma Having Ovarian Metastases

K Judson, R Vang, B Ronnett. The Johns Hopkins Hospital, Baltimore, MD.

**Background:** Recognition of an ovarian tumor as a metastasis from an undiagnosed primary gastrointestinal carcinoma can be difficult when characteristic clinicopathologic features of metastatic disease are not present. The purpose of this study was to analyze the clinicopathologic features of cases of ovarian metastases from undiagnosed colorectal adenocarcinomas (CRA) compared with those having metastases from known CRAs.

**Design:** Clinicopathologic features of 11 patients with ovarian metastases from undiagnosed CRAs (OV-UCRA) were compared to those of 11 patients having metastases from known CRAs (OV-KCRA).

**Results:**

	Age (mean/median)	Bowel Symptoms	Pelvic Mass	Bilateral (Clinical and/or surgical)	Bilateral (gross and/or microscopic)	Size of Ovarian Tumor (mean/median)	Mucinous Differentiation in Ovarian Tumor
OV-UCRA	49/48	1/11	11/11	5/11	7/11	15.2/17.0	6/11
OV-KCRA	58/58	3/4 (synch) 2/7 (metach)	3/4 (synch) 4/7 (metach)	2/11	3/11	12.5/15.0	1/11

Key: metach, metachronous; synch, synchronous

All CRAs and ovarian metastases for OV-UCRA were diagnosed synchronously whereas 7 CRAs for OV-KCRA were diagnosed prior to the ovarian metastases and 4 were diagnosed synchronously. Metastases in cases of OV-UCRA were more frequently bilateral but for cases with unilateral tumor the pathologic status of the contralateral ovary was not known in 8 cases of OV-KCRA compared to 3 cases of OV-UCRA; these ovaries of unknown status were presumably surgically negative. Those without mucinous differentiation had typical features of CRA, imparting an "endometrioid" appearance. A confluent pattern was present in 6/11 OV-UCRA and 4/11 OV-KCRA.

**Conclusions:** Compared to women with OV-KCRA, women with OV-UCRA tend to be younger and more often premenopausal (based on age less than 50) and have a greater frequency of bilateral ovarian metastases, suggesting the premenopausal ovary may be more susceptible to metastatic disease. The uniform presentation as pelvic masses with virtually no bowel symptoms, relatively large size of these ovarian metastases, frequent unilateral involvement based on clinical/surgical findings, frequent lack of an infiltrative pattern, and frequent mucinous differentiation are features that can contribute to misclassification of these metastases as primary ovarian neoplasms. The possibility of metastatic disease should be considered for ovarian tumors with mucinous and/or endometrioid differentiation, even when characteristic clinicopathologic features are lacking.

### 873 The Yield of Endocervical Curettage (ECC) in the Work-Up of Cervical Intraepithelial Neoplasia

*M Khan, MH Stoler, M Schiffman, the ALTS Group.* National Cancer Institute, Bethesda, MD; University of Virginia Health System, Charlottesville, VA.

**Background:** Endocervical curettage (ECC) is often performed to aid the evaluation of the cervix of patients referred for colposcopy and guided biopsy. However, its diagnostic utility has been debated. We estimated the diagnostic yield of ECC in patients sent for colposcopy in the multi-center ASCUS-LSIL Triage Study (ALTS), a randomized trial of management strategies for equivocal or mildly abnormal cytology.

**Design:** 5060 women were followed for 2 years, with varying numbers of colposcopic examinations depending on study arm. An exit colposcopy was scheduled for all women. At colposcopy, visible lesions were biopsied, and ECC was performed when indicated (e.g., uncertain extent of canal lesions) to evaluate the endocervical canal. A masked Quality Control pathology group diagnosed all pathology; the outcome for this analysis included cervical intraepithelial neoplasia grade 2, grade 3, and cancer (CIN2+). The data set includes the results of ECC compared to the concurrent cervical biopsy result and to final histopathologic diagnosis (defined as the worst histopathologic result from all specimens) during the 2 years of follow-up.

**Results:** Of the 5060 ALTS participants, 3690 (mean age, 27.0, S.D. 8.8) underwent at least one colposcopy that yielded some biopsy or ECC material. Because many women had >1 colposcopy, the total number of analyzable examinations was 5,495; of these, 3,987 had biopsy alone, 389 had ECC alone, and 1,119 had both biopsy and ECC. The yield of CIN2+ was 602 (15.1% of 3,987), 7 (1.8% of 389), and 248 (22.2% of 1,119), respectively. Among women with both biopsy and ECC, the biopsy alone contributed 200 CIN2+ cases (17.9%), the ECC alone detected 8 (0.7%), and both specimens revealed CIN2+ in 40 (3.6%). Thus, only 1.8% (15/857) of CIN2+ colposcopy results derived from ECC alone. Of the 939 cases of CIN2+ diagnosed cumulatively in ALTS, 15 (1.6%) were detected only by ECC. Of the 542 cases of CIN3+ diagnosed, 12 (2.2%) were detected only by ECC.

**Conclusions:** In the ALTS population, more than 95% of ECCs did not yield a diagnostic abnormality of CIN2 or worse. The frequency of ECC alone yielding a diagnosis of CIN2+ was on the order of 1-3%. Therefore, in the colposcopic evaluation of patients with ASCUS or LSIL cytology, the low yield of endocervical curettage suggests that this common procedure might be overused.

### 874 Diagnostic and Pathogenetic Significances of Apoptosis and Proliferating Activity (PA) in the Villous Stroma of Complete Hydatidiform Moles (CHMs)

*MJ Kim, HI Lee, S-Y Jun, JY Ro, K-R Kim.* University of Ulsan College of Medicine, Asan Medical Center, Seoul, Korea; Hallym University, Pyongchon Sacred Heart Hospital, Anyang, Korea.

**Background:** In former days, avascularity of chorionic villi was thought to be the main pathogenetic mechanism of CHMs. However, numerous blood vessels have been identified in the villous stroma of CHMs that were evacuated in very early gestational periods with the assistance of high resolution ultrasonography. The overexpression of apoptosis-related molecules and the increased apoptosis in CHMs, and the ablation of paternally imprinting gene resulting in an increased apoptosis during the human development suggest that apoptosis may be related to the pathogenetic mechanism of CHMs. Herein, we quantitatively measured the apoptosis and PA of villous stromal cells in very early CHMs and compared with those of

partial hydatidiform moles (PHMs) and normal early placental tissue to test their diagnostic utility, if any, and to know whether the changes of apoptosis or PA in the stromal cells are related to the decreased or absent vascularity of CHMs in the later gestational periods.

**Design:** Histopathological and the immunohistochemical findings (IHCs) for p57<sup>kip2</sup> were used for subclassification of the gestational trophoblastic disease in all cases. IHCs for caspase 3 and Ki-67 were performed in CHMs (n=63), PHMs (n=9) and therapeutic abortuses (TAs, n=10), all of which were evacuated before 13th gestational weeks. Apoptosis defined by caspase 3 immunopositivity and PA defined by Ki-67 immunopositivity in the villous stromal cells were counted among 800-1200 villous stromal cells with the aid of a microscope at x100 linked via a color CCD video camera with image analyzer software and compared.

**Results:** The apoptotic rate was significantly higher in CHMs (36.6%) compared with that of PHMs (2.5%) and TAs (1.7%) (p<0.001). The PA, however, was not significantly different among the three groups. The patients who had persistent trophoblastic diseases after evacuation of CHMs tended to show lower apoptosis (31.5% vs.38.7%) and higher PA(15.0% vs.10.2%) compared with those who were not, but the results were not statistically significant.

**Conclusions:** Increased apoptosis in the villous stroma is a useful feature in the diagnosis and the differential diagnosis of CHMs from PHM or hydropic abortion, and it may be pathogenetically related to form avascular villi in the later gestational periods by interfering the angiogenesis of the villous stroma in the CHMs.

### 875 Immunohistochemistry for CDX-2, Cytokeratin 7 and 20, CEA, CA125, and Her-2/neu in Distinction of Metastatic Carcinoma in the Ovary from Primary Ovarian Carcinoma: A Tissue Microarray Study

*MJ Kim, YK Bae, JH Choi.* Yeungnam University College of Medicine, Daegu, Korea.

**Background:** Distinction of primary ovarian carcinoma from metastatic carcinoma involving the ovary can be difficult based on histologic examination only. Immunophenotyping may be of help in this setting, however there is no single antibody specific for distinction between these tumors. This study was undertaken in order to determine a best panel of antibodies useful in distinguishing metastatic carcinomas from primary ovarian carcinomas by immunohistochemical analysis for CDX-2, cytokeratin(CK)7 and CK20, CEA, CA125 and Her-2/neu.

**Design:** Paraffin-embedded tissue sections from 57 ovarian carcinoma ( 26 serous, 18 mucinous, 7 clear cell, and 6 endometrioid), and 40 metastatic tumors to the ovary (18 gastric, 11 colorectal, 7 appendiceal, 1 pulmonary, 1 pancreatic, 1 breast, and 1 renal origin) including matching primary tumors were immunostained for CDX-2(BioGenex), CK7 and CK20(DAKO), CEA(DAKO), CA125(DAKO), and Her-2/neu(Zymed) using tissue microarray. The extent (0:<10%, 1+:11-50%, 2+:>50%) and intensity(0, 1+:weak, 2+:strong) of the staining were recorded.

**Results:** CDX-2 immunoreactivity was observed in colorectal(90%) and appendiceal(100%) origin of metastatic carcinoma, however CDX-2 was negative in all ovarian carcinoma except for mucinous subtype. Almost all primary ovarian carcinoma including mucinous one showed diffuse and strong immunoreactivity for CK7. CEA showed a similar immunohistochemical profile to the CDX-2. CA125 was seen in all serous subtype and Her-2 overexpression was noted in 29% of ovarian clear cell carcinoma.

**Conclusions:** These results suggest that CDX-2(or CEA), and CK7 are a best panel of immunohistochemical marker useful in distinguishing metastatic carcinomas to the ovary from primary ovarian carcinomas. In addition, CA125 and Her-2 are another helpful markers for serous and clear cell subtype of the ovary, respectively.

#### Immunohistochemical results

Tumor type	CDX-2	CK7	CK20	CEA	CA125	Her2/neu
Ovarian carcinoma						
Serous	0/26	26/26	6/26	0/26	26/26	0/26
Mucinous	10/18	17/18	12/18	11/18	2/18	3/18
Clear cell	0/7	7/7	0/7	0/7	6/7	2/7
Endometrioid	0/6	5/6	2/6	1/6	1/6	0/6
Metastatic carcinoma						
Stomach	8/18	14/18	16/18	12/18	0/18	2/18
Colorectum	10/11	6/11	11/11	10/11	1/11	0/11
Appendix	7/7	0/7	7/7	7/7	0/7	0/7
Lung	0/1	1/1	0/1	1/1	0/1	0/1
Pancreas	0/1	1/1	1/1	1/1	0/1	0/1
Breast	0/1	1/1	0/1	0/1	1/1	0/1
Kidney	0/1	0/1	0/1	0/1	0/1	0/1

### 876 Endometrial Adenocarcinoma in Women under 30 Years of Age with Long Follow-Up

*T Kiyokawa, T Hamada, H Takahashi, M Sasaki, M Suzuki, M Kawakami.* Jikei University School of Medicine, Minat-ku, Tokyo, Japan.

**Background:** Endometrial carcinoma (CA) is rare in women younger than 30 yrs. Recent studies suggest that pathologic features and outcome of such women are the same as the older women. We present the clinicopathological features of 7 cases of endometrial CA in Japanese women younger than 30 years of age.

**Design:** Seven cases of endometrial CA in women younger than 30 years were retrieved from the files of the department of pathology at our hospital between 1989 and 2003, covering a period of 15 yrs. Clinical information was obtained by medical chart review. H and E slides were reviewed.

**Results:** All the patients (pts) were Japanese and their age ranged from 23-29 yrs (mean 26.3 yrs). All were nulliparous and 2 had history of hormone therapy for ovarian dysfunction. All but one complained of abnormal vaginal bleeding, and in the last patient the tumor was detected during infertility work-up. Three pts were overweight or obese with body mass index (BMI) 25, 34, and 37 while the remaining 4 were not. Treatment (Tx) were as follows; hormonal Tx only in 1, TAH+BSO in 2, TAH+BSO+Chemo in 4. Of 6 pts with surgical Tx, 2 pts had previously failed

hormonal Tx. In all the pts CA were endometrioid type; Grade 1 in 5, and Grade 2 in 2. A background of atypical complex hyperplasia was present in 3 pts, and of atypical polypoid adenomyoma in another 3. In the pts treated surgically, the FIGO stage was stage 1 in 4pts and stage 3 in 2pts. Follow-up information was available in all (1yr and 3 mo to 13 yr and 4 mo, mean 8yr and 5 mo). In one non-obese patient whose stage was Ib, tumor recurred 6 years and 9 months after hysterectomy and died 8 years and 10 months after the initial Tx. Another patient with BMI of 25 had removed metastatic CA in a pelvic lymph node 2 years after the initial surgery but were disease free for 9 years thereafter. The other pts including 1 with hormone Tx only were disease free.

**Conclusions:** Endometrial CA is a rare malignancy in women younger than 30 yrs. These pts tend to have lower-grade tumor and favorable outcome. However, the tumor may recur in rare cases and careful long-term follow-up is necessary after the initial treatment.

**877 Expression of Ezrin Is an Independent Prognostic Factor in Human Ovarian Carcinoma**

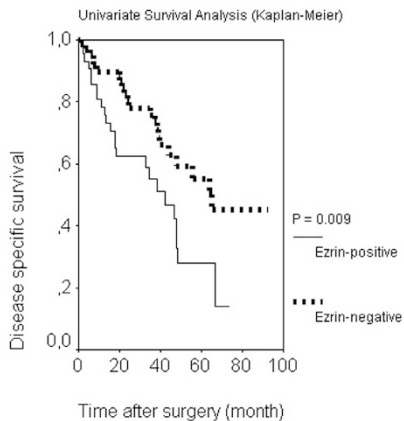
*M Köbel, E Knolle, S Hauptmann.* Martin-Luther-University, Halle, Germany.

**Background:** Ovarian carcinoma was accountable for more than 2,000 cancer death in Germany in 2002. The high mortality rate is ascribed to late diagnosis in FIGO stage IIIc or higher with peritoneal dissemination. The crucial point of implantation on the peritoneum is the interaction of tumor cells with mesothelium. Thereby hyaluronic acid (HA) on mesothelial cells binds to CD44 of ovarian carcinoma cells. Submembranal ligands of CD44 are ERM (ezrin, radixin, moesin) proteins, which are closely related to the NF2 tumor-suppressor gene merlin. Several studies have shown that ERM proteins enhance tumor cell motility and invasion.

**Design:** We investigated expression of ezrin and moesin by immunohistochemistry in 169 ovarian epithelial surface tumors, and correlated it to clinicopathological parameters as well as to recurrence free- and disease specific survival. Ovarian carcinoma cell line SKOV-3 exhibited ezrin and moesin expression, which was significantly inhibited by siRNA. The functional consequence was studied in a Boyden Chamber Assay.

**Results:** Overexpression of ezrin was detected in 45 % of 114 ovarian carcinomas, and in 73 % of 45 borderline tumors, but not in 10 cystadenomas and 5 normal ovaries. In univariate survival analysis of invasive carcinomas expression of ezrin was associated with a significantly reduced median survival (P=0.009). This remained significant in multivariate analysis (relative risk 3.51; 95% CI 1.35 - 9.10; P=0.010). Moesin expression showed no correlation to recurrence free- and disease specific survival. In vitro inhibition of ezrin expression alone did not exert an effect on invasion of SKOV-3 cells, but the combined blocking of ezrin and moesin expression reduced Matrigel invasion.

**Conclusions:** Our study indicate that ezrin expression is an independent prognostic factor in ovarian carcinomas, but only combined blocking of ezrin and moesin reduced ovarian carcinoma invasion, which implies a functional redundancy.



**878 Survival Benefit for Patients with Advanced-Stage Transitional Cell Carcinomas vs. Other Subtypes of Ovarian Carcinoma after Chemotherapy with Platinum and Paclitaxel**

*F Kommos, S Kommos, D Schmidt, J Pfisterer, A du Bois.* A2.2, Mannheim, Germany; Campus Kiel, Universitaetsklinikum Schleswig Holstein, Kiel, Germany; Dr.-Horst-Schmidt-Kliniken (HSK), Wiesbaden, Germany.

**Background:** Transitional cell carcinoma (TCC) of the ovary is a less well recognized histological type of ovarian carcinoma resembling TCC of the urinary bladder. It was suggested that TCC of the ovary may have a better prognosis as compared to other types of ovarian carcinomas, possibly due to a better response to chemotherapy.

**Design:** It was the aim of the present retrospective study to compare incidence and outcome of patients with TCCs and other subtypes of ovarian carcinoma from a large homogeneous collective of patients with primary advanced-stage ovarian carcinoma. Between 1 and 9 H&E-stained sections from a total of 302 cases from a prospective randomized, multi-center, phase III study of patients with ovarian cancer, FIGO-stages IIB-IV, comparing cisplatin plus paclitaxel (PT) with paclitaxel plus carboplatin (TC) were available for histological retyping of ovarian carcinomas applying current WHO

criteria. TCC of the ovary was diagnosed if one or more of the typical transitional cell patterns (excluding malignant Brenner tumor) were present exclusively or in at least 90% of the tumor tissue present. Survival analysis was performed according to the method of Kaplan & Meier.

**Results:** 16 of 312 tumors (5,3%) were diagnosed as TCC. The remaining cases were of the following histological types: 135 (44,7%) serous, 24 (7,9%) mucinous, 58 (19,2%) endometrioid, 37 (12,3%) clear cell, and 32 (10,6%) undifferentiated carcinomas. Only 1 of the 16 TCCs had been previously diagnosed as such by referring pathologists. 5-year survival of patients with TCC was 57% as compared to 32% for patients with ovarian carcinomas of other types (p=0,03).

**Conclusions:** TCC of the ovary seems to be a less well recognized entity. In the current series, TCCs had a significantly better prognosis as compared to all other types of ovarian carcinomas after standardized chemotherapy. Since TCC may have been underdiagnosed in past series of ovarian carcinomas, the true incidence of ovarian TCC is still unknown. More studies of large series applying standardized histopathological criteria are therefore mandatory. Thorough histological typing of ovarian cancer seems to be of clinical importance.

**879 Immunohistochemical Stain for p16 Can be Misleading in Distinguishing Endometrial from Endocervical Adenocarcinoma in Small Tissue Samples**

*CS Kong, CB Gilks, TA Longacre.* Stanford University School of Medicine, Stanford, CA; Vancouver General Hospital, Vancouver, BC, Canada.

**Background:** Endometrial and endocervical adenocarcinomas can appear histologically identical and it can be difficult to determine primary site of origin based on curettage specimens. The distinction is clinically important since the recommended surgical treatment differs depending on whether the tumor is of cervical or uterine corpus origin. Immunohistochemical stain for p16 has been proposed as a useful marker for distinguishing endocervical from endometrial adenocarcinomas, but p16 expression has not been extensively studied in uterine corpus carcinomas.

**Design:** Immunohistochemical stain for p16INK4A (clone E6H4, DakoCytomation) was performed on two tissue microarrays composed of unequivocal cases of cervical (22 adenocarcinomas, 196 squamous cell carcinomas) and uterine corpus carcinomas (171), as well as 5 whole sections of endocervical adenocarcinoma.

**Results:** In this study, the small fragments of tumor on the tissue microarray mimic the small samples obtained by endocervical curettage or endometrial biopsy.

	Negative	Weak	Focal Strong	Diffuse Strong
Cervix Squamous CA	14	41	21	120
Cervix AdenoCA	4	4	3	16
Uterine Corpus	83	38	24	26

Diffuse strong staining was present in both high grade (serous) and low grade (endometrioid) corpus carcinomas, as well as in squamous morular elements.

**Conclusions:** Diffuse strong staining with p16 has been previously reported to correlate with an endocervical primary and diffuse weak or focal strong reactivity with an endometrial primary. These patterns of reactivity are generally confirmed by this study and while they may be useful in whole tissue sections, the tissue microarray data indicates that reliance on differential staining patterns can be misleading in small tissue samples, such as are encountered in routine biopsy and curettage specimens.

**880 Expression of DNA Mismatch Repair Gene Products in Endometrial Carcinomas and Clinicopathologic Correlation**

*L Kordunsky, B Xu, B Banner, C Li.* University of Massachusetts Medical School, Worcester, MA.

**Background:** Microsatellite instability (MSI) is a consistent feature of tumors from patients with the hereditary non-polyposis colorectal cancer syndrome. It is caused by defects in DNA mismatch repair genes including human mutL homolog 1 (MLH1), human mutS homolog 2 (MSH2) and others. MSI has also been reported in a variety of sporadic cancers such as gastric, renal cell, and endometrial carcinomas. In this study, we evaluated expression of MLH1 and MSH2 gene product proteins in endometrioid adenocarcinoma using immunohistochemical methods and correlated the loss of MLH1 and MSH2 expressions with clinicopathologic parameters of this tumor.

**Design:** Twenty-five cases of endometrial carcinoma, endometrioid type, were selected from the surgical pathology files of UMMHC. Four-micron sections of formalin-fixed, paraffin-embedded tissue were stained with MLH1 and MSH2 antibodies. Loss of MLH1 and MSH2 expression was evaluated semi-quantitatively as total loss (0% of cells positive), partial loss (< 75% of cells positive), or minimal loss (>75% of cells positive). MLH1 and MSH2 staining in endometrial carcinoma were compared with those of normal endometrium on the same case.

**Results:** Normal endometrium showed strong diffuse nuclear immunostaining for both MLH1 and MSH2. As shown in Table 1, significant loss of MLH1 expression was observed in 19 out of 25 (76%) cases including total loss in 5 cases (20%), and partial loss in 14 cases (56%). Total loss of MSH2 expression was identified in one case (4%), and partial loss in 10 cases (40%). No correlation was found between loss of MLH1 or MSH2 expression and FIGO stage, tumor architectural and nuclear grade, or age of the patient.

Table 1. Loss of MLH1 and MSH2 Expression in Endometrioid Carcinoma (n=25)

	Total	Partial	Minimal
MLH1	20% (5/25)	56% (14/25)	24% (6/25)
MSH2	4% (1/25)	40% (10/25)	56% (14/25)

**Conclusions:** Our results demonstrate that expression of both MLH1 and MSH2 is significantly reduced in endometrial carcinoma, endometrioid type, supporting the concept that DNA mismatch repair gene alteration plays an important role in the pathogenesis of this tumor. In addition, the frequency of total or partial loss of MLH1 expression is significantly higher than that of MSH2, suggesting that MLH1 gene product is more frequently affected in some endometrial carcinomas.



### 881 KOC/L523 Expression Aids in Differential Diagnosis between Endocervical and Endometrial Adenocarcinomas

L Kordunsky, B Xu, Z Jiang, B Woda, K Dresser, M Retter, M Vacanti, C Li. University of Massachusetts Medical School, Worcester, MA; Corixa Corporation, Seattle, WA.

**Background:** KOC (K Homology Domain Containing Protein Over-Expressed in Cancer), also known as L523, is an oncofetal RNA binding protein expressed in several malignant tumors originated in a variety of organs including lung, pancreas, ovary, and lymph node. KOC expression profiles among uterine malignancies have not been investigated. The aim of this study was to evaluate the expression of KOC in endocervical and endometrial adenocarcinomas.

**Design:** Cervical biopsies and hysterectomy specimens with endocervical adenocarcinoma (ECCA, n=9) or endometrial adenocarcinoma, endometrioid type (EMCA, n=25) were obtained from the surgical pathology files of UMMHC. Sections were cut at 4 microns and immunostained using KOC antibody on an automated immunostainer. Positive KOC staining was graded as 1+ (<25% of cells positive) or 2+ (> 25% of cells positive).

**Results:** KOC expression was not observed in either normal endocervix or normal endometrium. As shown in Table 1, eight out of nine (89%) ECCA cases demonstrated KOC expression, including seven cases with 2+ staining and one case with 1+ staining. In contrast, only one (4%) and two (8%) out of twenty-five EMCA cases showed 2+ and 1+ staining, respectively.

Table 1. Immunohistochemical Staining Results for KOC in ECCA and EMCA (Expressed as the Percentage of Cases in Each Category)

	Negative	2+	1+
ECCA	11(1/9)	78 (7/9)	11 (1/9)
EMCA	88(22/25)	4 (1/25)	8 (2/25)

**Conclusions:** Our findings demonstrate significant high level of KOC expression in ECCA as compared to EMCA, suggesting that KOC expression may be helpful in the distinction between ECCA and EMCA, particularly on curettage specimens in daily surgical pathology practice. In addition, our data also indicate that KOC may play an important role in ECCA development and progression.

### 882 Higher Frequencies of Chromosomal Aberrations in Ovarian Compared to Extragenital Endometriosis: A Possible Link to Endometrioid Adenocarcinoma

M Körner, E Burckhardt, L Mazzuchelli. University of Bern, Bern, Switzerland; Istituto Cantonale di Patologia, Locarno, Switzerland.

**Background:** Both ovarian and extragenital endometriosis are common, but association with endometrioid adenocarcinoma occurs mainly in the ovary. Up to now, little is known about the pathogenetic mechanisms influencing the progression rates from endometriosis to cancer.

**Design:** Ten extragenital and 10 ovarian endometriosis cases, 8 ovarian endometrioid adenocarcinomas within endometriotic cysts, and 12 normal endometria were investigated by fluorescence in situ hybridization (FISH) using centromere enumeration probes for chromosomes 1, 7, 9, and 17. The degree of chromosomal aneusomies was semi-quantitatively assessed. Adjacent connective tissue served as internal control.

**Results:** Trisomy rates for chromosomes 1 and 7, and monosomy rates for chromosomes 9 and 17 progressed from normal endometrial glands to ovarian endometriosis and carcinoma, ranging from 16% to 41% for trisomy 1, 16% to 43% for trisomy 7, 33% to 72% for monosomy 9, and 30% to 66% for monosomy 17. In comparison, aneusomy rates in adjacent connective tissue were below 7%. Ovarian endometriosis harbored a higher mean proportion of cells aneusomic for all investigated chromosomes than extragenital endometriosis (p<0.001). In the ovaries, the mean aneusomy frequencies were comparable in endometriosis unassociated with cancer and endometriosis adjacent to carcinoma, but were significantly higher in invasive carcinomas (p<0.001).

**Conclusions:** The data add new evidence for a link between ovarian endometriosis and endometrioid cancer. The higher chromosomal instability found in ovarian compared to extragenital endometriosis suggests a possible role of the ovarian stromal milieu in the induction of genetic changes which may eventually lead to progression to invasive carcinoma. Since significant chromosomal aberrations can be present in normal tissues, such as endometrium, we furthermore suggest that cytogenetic data obtained by FISH on paraffin sections should be assessed semi-quantitatively and not on the basis of arbitrary cut-off values.

### 883 c-erbB2 Status in Ovarian Carcinomas: A Combined Evaluation Using FISH, CISH and Immunohistochemistry

E Kostopoulou, D Kaisaridou, M Ioannou, M Nakou, M Netsika, G Kalodimos, F Karassavidou, S Barbanis, G Koukoulis. University of Thessaly, Larissa, Greece.

**Background:** The therapeutic and prognostic implications of c-erbB2 overexpression in ovarian carcinomas are not clearly defined and they have been studied less extensively than those in breast carcinomas. Pertinent unanswered questions can be attributed to the application of different, not standardized methods for the detection of c-erbB2 overexpression in a small number of studies, leading to contradictory findings.

**Design:** Representative samples were obtained from 45 ovarian carcinomas (predominantly serous papillary type, borderline tumors not included). Slides were immunostained with well-characterized monoclonal antibodies (clones CB11 Biogenex and TAB250 ZYMED) and the immunoreactivity was assessed according to guidelines established for breast carcinomas (0 to 3+). In situ hybridization was performed for the detection of c-erbB2 gene amplification using fluorescent as well as biotin-labeled probes, FISH and CISH, with commercially available reagents (from Vysis/PathVysion and ZYMED respectively).

**Results:** c-erbB2 amplification was noted in 7 cases (15.5%). FISH and CISH produced similar findings. Three of the 7 cases showed 3+ immunoreactivity and four demonstrated 2+ immunostaining. Additional 4 cases showed 2+ /3+ immunostaining

without detectable amplification. In few cases, gene amplification as well as immunohistochemically detectable overexpression was more prominent in scattered, large bizarre tumor cells. Most of the cases, 34/45, showed minimal or no immunoreactivity (1+ or 0).

**Conclusions:** In contrast to the high frequency of c-erbB2 overexpression reported in the older literature, (up to 66%), and in keeping with recent data from a phase II trial of the Gynecologic Oncology Group (J Clin Oncol 21:283,2003), overexpression of c-erbB2 is limited to a subset of ovarian carcinomas (15.5%-24.4%). CISH can be as accurate as FISH, if a centromeric probe for chromosome 17 is used. The available evidence suggests that in ovarian carcinomas mechanisms of overexpression other than amplification may be involved and studies using real time QRT PCR might be useful.

### 884 Influence of Histological Type, Organ of Origin, and Wnt Pathway Status on Gene Expression Profile in Ovarian and Uterine Carcinomas

MP Kshirsagar, KA Shedden, DR Schwartz, R Wu, H Yu, DE Mizek, S Hanash, H Katabuchi, LH Ellenson, KR Cho. The University of Michigan, Ann Arbor, MI; Kumamoto University, Kumamoto, Japan; Weil Medical College of Cornell University, New York, NY.

**Background:** Each histological type of ovarian carcinoma may represent a pathogenetically distinct entity. In support of this notion, and comparable to the situation in the endometrium, characteristic genetic alterations are associated with each ovarian carcinoma type. Moreover, ovarian and endometrial carcinomas showing the same type of differentiation (e.g., serous or endometrioid) share many of these characteristic genetic changes. Hence, it is possible that type of differentiation is at least as important as organ of origin in determining a given carcinoma's gene expression signature. We have previously shown that alterations of a single cellular signaling pathway, i.e., the canonical Wnt signaling pathway, is a major determinant of gene expression in ovarian endometrioid carcinomas. Whether such defects lead to a similar gene expression signature in their endometrial counterparts has not yet been determined.

**Design:** To address these issues, we employed oligonucleotide microarrays to compare gene expression profiles amongst 103 primary uterine and ovarian carcinomas with endometrioid and serous differentiation. Comparisons were made between serous and endometrioid carcinomas within the same organ, and between organs within the same histological tumor type ("histotype").

**Results:** We found that histotype and organ are both associated with significant effects on gene expression and contribute to gene expression profiles in parallel – organ effects are equivalent in the two histotypes, and histotype effects are equivalent in the two organs. Finally, we found that uterine and ovarian endometrioid adenocarcinomas with deregulated Wnt signaling show a gene expression signature that is largely distinct from that of comparable tumors with intact Wnt signaling.

**Conclusions:** This study begins to form a framework for understanding the respective roles of organ of origin, type of differentiation, and specific molecular defects in predicting gene expression patterns in the most common types of ovarian and uterine cancers.

### 885 Extragenital Gastrointestinal Stromal Tumors (EGISTs) Presenting as Vulvovaginal/Rectovaginal Septal Masses: A Diagnostic Pitfall

MM Lam, CL Corless, JR Goldblum, MC Heinrich, E Downs-Kelly, BP Rubin. University of Washington Medical Center, Seattle, WA; Oregon Health and Science University, Portland, OR; Cleveland Clinic Foundation, Cleveland, OH.

**Background:** Gastrointestinal (GI) stromal tumor (GIST) is the most common mesenchymal tumor of the GI tract. The majority of GISTs arise in the stomach and small bowel, while a smaller number occur elsewhere in the GI tract. Rare cases are identified outside of the GI tract and are known collectively as extragenital gastrointestinal GISTs (EGISTs). Because of their malignant potential and recent advances in the management of GISTs with imatinib mesylate (Gleevec), it is imperative that these tumors are correctly diagnosed. In this study, we reviewed the clinical and pathologic characteristics of three cases of EGIST presenting as vulvovaginal/rectovaginal septal masses that were originally misdiagnosed, presumably due to their unusual anatomic locations.

**Design:** Three cases of EGIST presenting as vulvovaginal/rectovaginal septal masses were obtained from the surgical pathology files. The patients' clinical charts were reviewed. Immunohistochemical studies for KIT (CD117), CD34, pan-cytokeratin (AE1/AE3), smooth muscle actin and desmin, and KIT mutational analysis were performed.

**Results:** The original diagnoses were leiomyoma in one case and leiomyosarcoma in two cases. The lesions were localized to the rectovaginal septum (1) or vagina (2) and ranged from 4-8 cm in diameter. All three lesions had a spindle cell morphology that mimicked a smooth muscle tumor. Mitotic figures numbered from 12 to 16/50 HPFs (15 median). Immunohistochemistry revealed that all three cases were strongly positive for KIT (CD117) and CD34, and negative for smooth muscle actin, desmin and pan-cytokeratin. KIT sequence analysis revealed oncogenic mutations in all 3 cases. Follow-up revealed local recurrence at 10 years in two cases, while the other case is recent.

**Conclusions:** EGISTs that present as gynecological masses are rare but may be more common than is currently recognized. Misdiagnosis may lead to inappropriate therapy, because conventional chemotherapy and radiotherapy are not effective in the treatment of GISTs, while imatinib mesylate (Gleevec) has a proven role in managing these tumors. Thus it is imperative to consider EGISTs in the differential diagnosis of mesenchymal neoplasms in the vulvovaginal/rectovaginal septum.

**886 SNPs in Fas Promoter Region as a Risk Factor of Cervical Squamous Cell Carcinoma**

*E Lerma, M Romero, A Gallardo, Ll Catusas, E Bussaglia, J Prat.* Hospital de la Santa Creu i Sant Pau. Autonomous University of Barcelona, Spain.

**Background:** The role of host susceptibility to cervical carcinoma is largely unknown. We studied whether single nucleotide polymorphisms (SNPs) in the Fas promoter region (positions -1377 G/A and -670 A/G) could determine individual susceptibility to cervical cancer progression.

**Design:** The clinicopathologic features of 38 patients with cervical invasive squamous cell carcinoma were reviewed. They were subclassified into three subgroups: A) 13 low-stage (I - II) barrel-shaped tumors; B) 17 low-stage nonbarrel-shaped tumors; and C) 8 stage III - IV tumors. Genomic DNA was extracted from paraffin blocks. SNPs at -1377 and -670 locations were assessed by RFLP and DNA sequencing. Statistical analysis was performed with the SPSS/win 11.5.

**Results:** No statistically significant differences in the clinical and pathological data between our three groups were detected. Both, overall and disease-free survival were related to stage ( $p < 0.05$ ). Results of SNPs from studied cases (36 for SNP at -1377 and 34 for SNP at -670) are shown below:

POLYMORPHISM -1377				
GENOTYPE	Group A	Group B	Group C	GEN POPULATION
GG	12/12 (100%)	11/16 (69%)	8/8 (100%)	76%
GA	0	4/16 (25%)	0	22%
AA	0	1/16 (6%)	0	2%

POLYMORPHISM -670				
GENOTYPE	Group A	Group B	Group C	GEN POPULATION
GG	4/11 (36%)	3/15 (20%)	4/8 (50%)	26%
GA	5/11 (46%)	8/15 (53%)	1/8 (12%)	51%
AA	2/11 (18%)	4/15 (27%)	3/8 (38%)	23%

**Conclusions:** FAS-1377A allele was only detected in low-stage nonbarrel-shaped tumors, with a frequency of 0.19 (general population: 0.13); it could represent a marker of favorable prognosis. FAS-670G allele was more frequent than expected in low-stage barrel-shaped tumors and in high-stage tumors; it could be a marker of adverse prognosis.

**887 Gastrointestinal Stromal Tumors Metastatic to the Ovary**

*MF Lerwill, JA Irving, RH Young.* Massachusetts General Hospital, Boston, MA; Harvard Medical School, Boston, MA.

**Background:** Metastatic sarcomas of the ovary are rare, and metastatic gastrointestinal stromal tumor (GIST) presenting as an ovarian mass has not been reported. Establishment of the correct diagnosis has important prognostic and therapeutic implications.

**Design:** We conducted a clinicopathologic and immunohistochemical study of 5 cases of GIST metastatic to one or both ovaries. Immunohistochemistry was performed using the avidin-biotin peroxidase method with antibodies against c-kit (CD117), CD34, desmin, h-caldesmon, S100, pan-cytokeratin, and vimentin on formalin-fixed, paraffin-embedded tissue from each case.

**Results:** In 4 cases, the primary tumor was located in the small bowel or its mesentery, detected synchronously with or, in 1 case, 27 years previous to the ovarian tumors. One case was a gastric primary identified 18 months subsequent to the ovarian tumors. The ovarian tumors were bilateral in 3 cases and unilateral in 2. All cases were either spindle (3) or mixed spindle-epithelioid (2) cell type. The diagnosis in all 5 cases was confirmed with positive c-kit and negative desmin immunostaining. Variably positive immunoreactivity for h-caldesmon was seen in all 5 cases, and 3 cases were CD34-positive.

**Conclusions:** 1. GIST metastatic to the ovary is infrequent, and should be considered in the differential diagnosis when bilateral spindle or epithelioid ovarian neoplasms are encountered.

2. Identification of an ovarian sarcoma should prompt acquisition of additional clinical information, with awareness that history of a primary tumor in the small bowel or stomach may be remote.

3. Distinction from other mesenchymal tumors of the ovary, specifically leiomyosarcoma, is facilitated by a c-kit positive/CD34 positive/desmin negative immunophenotype.

**888 Metastatic Colorectal Adenocarcinoma in the Ovary: Still a Diagnostic Challenge**

*MR Lewis, MT Deavers, EG Silva, A Malpica.* M.D. Anderson Cancer Center, Houston, TX.

**Background:** Although metastatic colorectal adenocarcinoma (MtCA) in the ovary is a well-described entity, it still represents a diagnostic challenge. Its recognition is important from therapeutic and prognostic standpoints. In this study, we present the clinicopathologic features of 86 such cases.

**Design:** Eighty-six cases of MtCA in the ovary were retrieved from the files of our department (spanning 1999-present). H&E slides were reviewed in all cases. Immunohistochemical stains for CK7 and CK20 were performed in 32 cases. Gross features were obtained from pathology reports, and clinical information was retrieved from patients' (pts) charts.

**Results:** Pts ranged in age from 24 to 85 years (median 51); 24% were under age 40. Presenting symptoms included abdominal pain (31 cases), rectal bleeding (11), change in bowel habits (15), and vaginal bleeding (2). In 19 cases, an ovarian mass was the first manifestation of the disease; 49 pts had a known history of colorectal

adenocarcinoma. Ovarian involvement was bilateral in 36 cases and unilateral in 40 (including 19 cases in which the only involved ovary measured  $\geq 10$  cm). Omental/peritoneal disease was noted in 46 cases at presentation. Involved ovaries ranged from 2.5 to 29 cm, and most were solid and cystic. Many involved ovaries featured smooth capsules without gross evidence of surface involvement by tumor. In general, the tumors had the typical histologic features of MtCA, including a garland pattern and dirty necrosis. In a few cases, foci of benign-appearing epithelium were seen. Immunohistochemical stains showed that the tumors were generally CK7(-) and CK20(+), although focal CK7 (+) was seen in 5 cases. In 7 cases, the tumor was originally misinterpreted as a primary ovarian neoplasm (endometrioid, 4; mucinous, 1; papillary serous carcinoma, 1; poorly differentiated Sertoli-Leydig cell tumor, 1). Six of these 7 cases were initially treated as ovarian primaries. All pts were treated surgically; nearly all received chemotherapy, and 8 also received radiation therapy.

**Conclusions:** MtCA in the ovary still presents a diagnostic challenge; in this study of 86 cases (8%) were initially misinterpreted as primary ovarian tumors. In 22% of the cases the tumor in the ovary was the first manifestation of the disease. Unilateral and bilateral cases were nearly equal in number. Almost half of the unilateral cases measured  $> 10$  cm; 24% of the pts were  $< 40$  years old. MtCA needs to be in the differential diagnosis of an ovarian mass, even if large and unilateral or in a young pt, to secure the proper treatment of these pts.

**889 Expression of a Novel Carcinoma Antigen (KOC/L523) in Adenocarcinoma In Situ of the Uterine Cervix**

*C Li, Z Jiang, L Kordunsky, K Dresser, K Rock, M Retter, A Fraire.* University of Massachusetts Medical School, Worcester, MA; Corixa Corporation, Seattle, WA.

**Background:** Adenocarcinoma in situ (AIS) of the uterine cervix is currently regarded as the precursor lesion of invasive adenocarcinoma. However, there is very limited molecular evidence to support this concept, and there are also few diagnostic molecular markers for AIS. KOC (K Homology Domain Containing Protein Over-Expressed in Cancer), also known as L523, is a newly identified carcinoma-associated antigen, which was initially discovered in lung squamous cell carcinoma using PCR-based cDNA library subtraction in conjunction with high throughput microarray screening techniques. The aim of this study was to evaluate the expression of KOC in AIS and benign endocervical glands (BEG).

**Design:** Cervical biopsies and hysterectomy specimens with AIS (n=20) or BEG (n=8) were obtained from the surgical pathology files of UMMHC. All 20 cases of AIS had BEG in the same specimen, making a total of 28 samples of BEG available for study. Sections were cut at 4 microns and immunostained using KOC antibody on an automated immunostainer. Positive KOC staining was graded as 1+ ( $< 25\%$  of cells positive) or 2+ ( $> 25\%$  of cells positive).

**Results:** Immunohistochemical staining results for KOC are expressed as the percentage of cases in each category as shown in the following table.

Negative	2+	1+		
Benign	100 (28/28)	0.0 (0/28)	0.0 (0/28)	
AIS	10 (2/20)	80 (16/20)	10 (2/20)	

**Conclusions:** Our findings demonstrate significant expression of KOC in AIS as compared to benign endocervical glands, suggesting that KOC expression may be helpful in the distinction of AIS from BEG, particularly in difficult cases. Our data also suggest that KOC may play a role in AIS development and progression and support the notion of AIS as a precursor of invasive carcinoma.

**890 In Search of New Molecular Markers in the Diagnosis of Endometrial Cancer**

*EML Li Ning, RSJ Ricketts, MA Palau, C Otis, DD Roberts, MJ Merino.* NCI/NIH, Bethesda, MD; Tufts University School of Medicine, Springfield, MA.

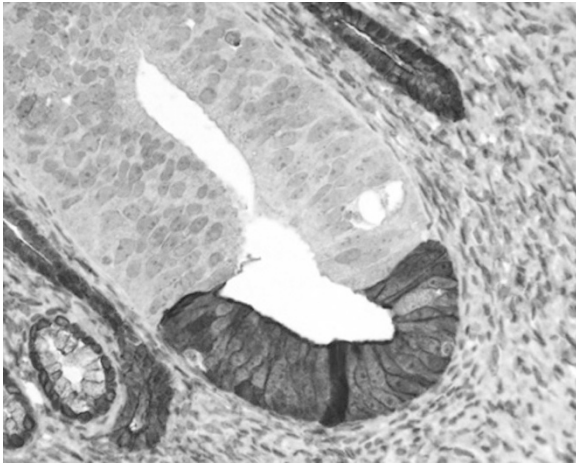
**Background:** Endometrial carcinoma is one of the most common gynecologic malignancies in the United States. As with so many other malignant tumors, no markers for early detection are available. Proteomics is a useful tool for the identification of preferentially expressed proteins that can be used not only as tumor markers for diagnosis but also in the design of new and more effective therapeutic drugs. Our study was aimed to identify and analyze new proteins of possible clinical value in cases of endometrial carcinoma.

**Design:** Frozen tissue sections from different types of endometrial carcinomas were obtained and microdissected. At least 100  $\mu$ g of protein were obtained from each case and 2-D protein analysis was performed. Gels were scanned and matching of spots expressed by the different samples was performed using the Melanie 3.0 software (Geneva Bioinformatics, Geneva, SW). Spots that expressed preferentially were selected and removed for sequencing. Immunohistochemistry was later performed on formalin-fixed paraffin embedded sections with commercially available antibodies.

**Results:** Proteomics analysis demonstrated the presence of the following proteins: heat shock protein 27, NADH-ubiquinone oxidoreductase, peroxiredoxin 6, apolipoprotein-A1 precursor, glutathione s-transferase pi (GST pi) and annexin IV. These proteins have been associated with cell growth, metastatic potential and drug resistance. Immunohistochemistry of GST pi showed staining differences in the subcellular compartments. Nuclear staining was found preferentially in papillary serous carcinomas, while endometrioid carcinomas showed cytoplasmic staining. The pattern of expression of annexin IV seemed to be associated with the degree of tumor differentiation (figure).

**Conclusions:** We have documented that protein expression is different in different types of endometrial cancer, and recognized proteins which may have a potential role

as markers of differentiation, tumor progression and drug resistance (annexin IV and GST pi). Identification of these new proteins may be of great importance in the development and design of novel chemotherapy strategies.



### 891 Utility of p16<sup>INK4A</sup>, CEA, Ki67, p53 and ER/PR in the Differential Diagnosis of Benign, Premalignant and Malignant Glandular Lesions of the Uterine Cervix

J Liang, K Mittal, J Wei, H Yee, S Goswami, L Chiriboga, P Shukla. New York University Medical Center, New York, NY.

**Background:** Early detection of premalignant and malignant glandular lesions of the uterine cervix and their distinction from benign mimics is crucial but sometimes difficult. Overexpression of p16 induced by HPV has been found to be associated with the cervical squamous carcinoma. p16 was also reported to be expressed in cervical adenocarcinoma. CEA is another valuable marker for endocervical glandular lesions. In this study, we investigated utility of expression of p16<sup>INK4A</sup>, CEA, Ki67, p53 and ER/PR in evaluating the benign, premalignant and malignant glandular lesions of the uterine cervix

**Design:** A total of 21 cervical cone or LEEP specimens were collected including 11 adenocarcinoma in situ (ACIs), 2 endocervical glandular dysplasia (EGD) and 8 benign mimics (BM). A histological score for each case according to the criteria proposed by Ioffe OB et al was assigned independently by four pathologists. Formalin-fixed, paraffin-embedded sections were immunostained with p16, CEA, p53, Ki67 and ER/PR. Immunoreactivity was scored based on intensity (0= none, 1= mild, 2=moderate, 3= marked) and percentile staining (0=<1%, 1= 2-10%, 2=11-40%, 3=>40%). A comparison of histological scores with immunoscores was analyzed.

**Results:** The histological scores based on stratification, nuclear atypia, mitoses and apoptosis and immunoscores are summarized in Table 1. The histological scores assigned independently by four pathologists were all equal or above 6 for ACIs, between 3 and 5 for EGD and equal or below 4 for BM. 1) These findings validate the scoring scheme proposed by Ioffe OB et al: score 0 to 3 = benign, 4 to 5 = dysplasia, 6 to 9 = ACIs. 2) There is increased expression of p16 and CEA in EGD compared with BM, with further increase in ACIs. 3) Ki67 is increased in ACIs compared with EGD 4) There is a loss of ER/PR in cervical ACIs, but not in EGD.

**Conclusions:** 1) The scoring scheme proposed by Ioffe OB et al is a useful tool in differential diagnosis of cervical glandular lesions for increased diagnostic accuracy and interobserver agreement. 2) Most cervical glandular lesions can be differentiated by using a combination of the histological scores with a panel of immunomarkers.

Table 1

	Histological scores	Histological scores			Immunoscores		
		p16	CEA	Ki-67	p53	ER	PR
ACIs (n=11)	8.2 (6.5-8.5)	5.2	4.9	5.8	1.8	2.5	2.2
EGD (n=2)	4.0 (3.5-4.5)	3.5	2.5	2.0	2.0	5.0	5.2
BM (n=8)	2.6 (1.5-3.5)	0.3	1.0	2.0	0.5	5.5	5.0

### 892 Occurrence of Endometrial Glandular Dysplasia Precedes Uterine Papillary Serous Carcinoma

SX Liang, EC Ulukus, SK Chambers, T Rutherford, PE Schwartz, W Zheng. Yale University School of Medicine, New Haven, CT; Stony Brook Medical Center, Long Island, NY.

**Background:** We have recently defined a new entity called endometrial glandular dysplasia (EmGD), which is commonly and specifically associated with serous EIC and UPSC. EmGD has been proposed as a true precancerous lesion of UPSC with supporting evidence in both morphology and molecular biology (Int J Surg Pathology 2004, 12:207-23). This study is to examine the time period from the occurrence of EmGD to full-blown UPSC via a retrospective clinicopathologic study.

**Design:** Total of 188 UPSC cases were indexed in the past 10 years. All cases, except 4, were fully staged hysterectomy specimens. In order to identify if EmGD existed prior to the development of UPSC, we retrospectively examined all available endometrial biopsy specimens from the period of 3 months or earlier prior to hysterectomies. A total of 258 benign postmenopausal uteri were included as a

control. All available preceding biopsies were reviewed. Any endometrial abnormalities morphologically qualify as EmGD in preceding biopsies were recorded and subjected to p53 and MIB-1 stainings.

**Results:** Among the 188 UPSC cases, 170 did not have recorded evidence of preceding endometrial biopsy, while 18 cases had at least 1 biopsy sample available for review and further studies. Out of the 18 cases, 5 showed presence of EmGD and 13 were non-EmGD including 7 resting endometrium, 5 endometrial polyp and 1 hyperplasia. The 5 EmGD cases showed that 3 involved an endometrial polyp and 2 were present in loose fragments of endometrial biopsy materials. Among these 5 EmGD cases, no abnormalities were mentioned in 3 and endometrial glands with focal atypia were mentioned in 2 in previous pathology reports. All 5 cases were confirmed with p53 and MIB-1 stainings. The time from identifying EmGD to the presence of full-blown UPSC ranged from 7 to 98 months with an average of 22 months. Among the 258 control cases, 21 previous endometrial biopsies were found. No EmGD was identified in all 21 samples. Four showed break down related metaplastic changes with mild nuclear atypia, but p53 and MIB-1 stainings were negative.

**Conclusions:** EmGD occurs preceding to the development of UPSC. The window period from finding of a EmGD lesion to a full-blown UPSC ranges from 7 to 98 months with an average 22 months. The findings support that EmGD is likely to be the precursor lesion of UPSC. Further studies are needed to address reversibility, risk of UPSC development, and clinical management of EmGD.

### 893 p53 Expression Is Common in Lichen Sclerosus and Not Associated with Dysplasia

B Liegl, S Regauer. Medical University of Graz, 8036 Graz, Austria.

**Background:** Lichen sclerosus (LS) is a chronic, lymphocyte-mediated skin disease which can be seen in association with vulvar squamous cell carcinoma (SCC). The etiology of LS-induced vulvar carcinogenesis is unknown. However, it is believed that a precursor lesion called "differentiated VIN" (d-VIN) with atypical basal / suprabasal keratinocyte proliferations and p53 expression rapidly progresses to carcinoma. Descriptions of d-VIN are rare and most reports identified d-VIN adjacent to SCC. Our aim was to investigate the frequency of d-VIN in biopsies / excisions of LS unassociated with SCC in comparison with LS-associated SCC.

**Design:** We examined a total of 195 biopsies / excision of 30 early, 77 late, 30 hypertrophic vulvar LS (age range 21 – 86 years), 26 pediatric vulvar and penile LS (age range 4-18 years), 32 vulvar LS associated with SCC (age range 23-82 years) and 5 normal vulvar control biopsies for the expression of p53 and the presence of d-VIN. p-53 staining was divided into staining of basal keratinocytes (continuous linear or single cells), basal and suprabasal staining and plaque-like staining.

**Results:** Staining of p53 was observed in 190 / 195 biopsies of LS. **Normal vulvar biopsies, early LS and pediatric LS** showed mostly discontinuous single cell staining, occasionally continuous staining of basal keratinocytes. **Late LS** showed no p-53 staining in 5/77 patients. Discontinuous linear staining (68%) predominated over plaque-like suprabasal staining. **Hypertrophic LS** revealed basal and suprabasal staining in 61%, while exclusively basal keratinocyte staining was observed in only 32%. Linear basal and suprabasal keratinocyte staining were associated with dermal sclerosis, cystic degeneration, dense lichenoid and nodular lymphoid infiltrates. d-VIN was observed in only 2 patients with hypertrophic LS and 7 patients with LS-associated SCC. All 32 SCC showed strong staining for p53 in basal and suprabasal cells.

**Conclusions:** p-53 staining in basal keratinocytes is a common observation. In the vast majority of cases, p-53 expression is not associated with dysplasia or atypia. d-VIN is an extremely rare lesion occurring in less than 5% of our total patient population and in only 1% of our LS cases unassociated with LS. In our opinion, the high frequency of p-53 staining is associated with a stress reaction to ischemia and inflammatory infiltrates. We therefore like to caution of an over-interpretation of p-53 staining as indicating a premalignant change. Evaluation of p-53 expression in our opinion is a poor screening tool for identifying precancerous lesions.

### 894 Utility of MUC2 and Thymidylate Synthase Immunohistochemistry in Ovarian Mucinous Tumors Associated with "Pseudomyxoma Peritonei"

F Liu, CJ Sung, C Zhang, C Browar, MR Qudus, MM Steinhoff, WD Lawrence. Women & Infants Hospital, Brown Medical School, Providence, RI.

**Background:** "Pseudomyxoma peritonei" (PMP), or disseminated peritoneal adenomucinosis, is histologically defined by dissecting mucin, variable amounts of mucinous epithelium, and reactive fibrosis. Most PMP arises from mucinous appendiceal and/or ovarian neoplasm(s), and the latter are largely regarded as metastatic. Previous studies of MUC2 expression have shown PMP to arise from a gastrointestinal (GI), often appendiceal, tumor rather than an ovarian primary. Thymidylate synthase (TS) is involved in the tumor suppressor pathway of 80% of colorectal cancers (CRC) and patients with high TS respond poorly to modulated MTX-5-FU therapy and have a low overall survival rate. However, immunohistochemistry has not been applied to the study of TS antibodies on GI type ovarian mucinous tumors (OMTs) with PMP. The aim of this project was to evaluate the nature and utility of MUC2 and TS immunostaining in OMTs associated with PMP.

**Design:** 5-micron sections of formalin-fixed, paraffin-embedded tissue from 20 metastatic OMTs with PMP and 9 primary OMTs without PMP were immunostained for MUC2 using the DAKO EnVision<sup>+</sup> system. Histologically, all tumors were either of borderline GI type or well differentiated adenocarcinomas (WDCA). Sections from 20 ovarian mucinous borderline or WDCA associated with PMP were also stained with antibody against TS. MUC2 and TS positivity was scored from 0-3 based on the combined percentage of cells stained and intensity of staining. Statistical analyses were performed using the Mann-Whitney test (InStat 3.05 software).

**Results:** All ostensibly metastatic OMTs associated with PMP showed diffuse and strong MUC2 positivity whereas only 1 of 9 (11%) primary OMTs without PMP displayed focal positivity. Therefore, MUC2 has a sensitivity of 100%, a specificity of 89%, a positive predictive value of 95% and negative predictive value of 100% ( $p < .0001$ ). Of the 20 OMTs associated with PMP that were immunostained for TS, only 1 (5%) exhibited focal strong TS positivity, 2 (10%) displayed focal weak TS positivity, and 17 (85%) showed complete TS negativity.

**Conclusions:** We confirm that MUC2 is a reliable marker for GI-derived metastatic OMTs with PMP and that MUC2 can aid in the distinction of metastatic vs primary OMTs. TS is generally not over-expressed in OMTs associated with PMP. The association of TS expression in OMTs with PMP and their clinical response to modulated MTX-5-FU therapy is worthy of further study.

### 895 Does the Lack of THY1 Gene Expression Support Different Histogenetic Mechanisms for Ovarian Serous Borderline and Invasive Tumors?

F Liu, CJ Sung, C Zhang, MR Quddus, JM Kasznica, MM Steinhoff, WD Lawrence. Women & Infants Hospital, Brown Medical School, Providence, RI.

**Background:** Epithelial ovarian cancer is the leading cause of death from gynecologic malignancies in the United States. Loss of heterozygosity (LOH) studies have shown mutations at the 11q23-qter region to be associated with ovarian carcinogenesis. The THY1 gene has been mapped to this region but despite extensive investigation, its exact function and physiologic role remain unknown. Some studies have shown that THY1 can trigger a variety of cellular functions such as proliferation, lymphokine release, differentiation and apoptosis. A recent report indicates that THY1 could be a putative tumor suppressor gene for human ovarian cancer. The aim of this study is to evaluate THY1 expression in ovarian invasive serous carcinoma (ISC), serous borderline tumor (SBLT) and benign ovarian surface epithelium and inclusion glands in order to investigate the role of the THY1 gene in the genesis of ovarian SBLTs and carcinoma.

**Design:** Five-micron sections of formalin-fixed, paraffin-embedded blocks from 15 high grade ISC, 12 SBLT (nonmicropapillary) and 10 normal ovaries were immunostained with an antibody against THY1 using the DAKO EnVision<sup>+</sup> system. THY1 positivity was scored from 0-3 based on the combined percentage of cell stained and intensity of staining. Statistical analysis was performed using Mann-Whitney Test (InStat 3.05 software).

**Results:** The benign ovarian epithelium was completely immunonegative with THY1. One case (8%) of 12 SBLT showed focal weak immunostaining for THY1. In contrast, four cases (27%) of ISC showed strong THY1 cytoplasmic immunopositivity; six cases (40%) exhibited moderate THY1 immunopositivity; and the remaining five cases (33%) displayed focal weak THY1 immunopositivity. There is an overall significant difference in THY1 immunostaining between ISC and SBLT ( $p < .001$ ), as well as between ISC and benign ovarian epithelium ( $p < .0001$ ). There is no significant difference in THY1 staining between SBLT and benign ovarian epithelium ( $p > .653$ ).

**Conclusions:** Our study demonstrates a significantly greater expression of THY1 in ovarian ISC as compared to SBLT and benign ovarian epithelium both of which had weak to no staining. This supports i) the generally held notion that non-micropapillary SBLTs probably do not play a role in the genesis of frank ovarian carcinoma, ii) the cytologically benign nature of usual SBLTs.

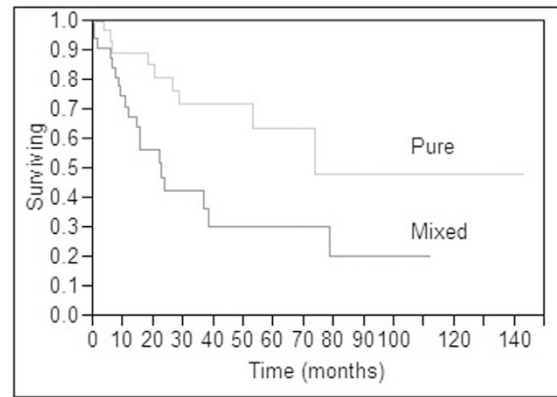
### 896 Is Pure Uterine Clear Cell Carcinoma Clinically Distinct from Endometrioid/Serous Carcinoma with a Clear Cell Component?

S Logani, RA Soslow, E Oliva, JD Nolen, AA Aleodor, NA Saunders, A Polydorides, LH Ellenson. Emory University, Atlanta, GA; Memorial Sloan Kettering, New York, NY; Massachusetts General Hospital, Boston, MA; Weill Medical College of Cornell University, New York, NY.

**Background:** Mutational analysis of pure uterine clear cell carcinoma (CCC) suggests genetic heterogeneity in this tumor subtype. We investigated the hypothesis that pure CCC are clinically distinct in behavior from mixed endometrioid (EC) or serous (SC) carcinoma with a clear cell component.

**Design:** A multi-institutional search accrued 68 CCC for study (34 pure and 34 mixed carcinomas, matched for pathologic stage). Slides and reports were reviewed to ascertain pathologic stage and follow-up was obtained from the computer files and tumor registry. A Cox proportional hazards model was constructed to assess the relationship between patient survival and the following parameters: age, tumor size, clear cell histology, node status, depth of myometrial invasion, and vascular invasion. Statistical analysis was performed using the SAS JMP software (5.0.1.2). A type I error rate of 0.05 was set at the outset. Kaplan-Meier curves were plotted using clear cell histology (pure vs. mixed) as a dichotomous variable, using the log-rank test for significance.

**Results:** Staging data was obtained on 33 pure CCC (16 stage I, 17 stage II-III) and 31 mixed carcinomas (16 stage I, 15 stage II-III). The pure CCC had a median survival time of 74 months compared to 23 months for the mixed carcinomas. This difference was statistically significant ( $p < 0.05$ ; Cox proportional hazards model), supporting the Kaplan-Meier analysis (Fig 1). Lymph node involvement and presence of vascular invasion were found to be significant independent parameters for patient survival.



**Conclusions:** Pure uterine CCC appears to be clinically distinct, further supporting the hypothesis that the genetic heterogeneity observed in this tumor subtype compared to those in EC/SC is clinically relevant. Pure CCC has a significantly better survival than EC or SC with a clear cell component. Lymph node involvement and vascular invasion were found to be independent prognostic parameters in this study.

### 897 Tenascin: A Possible Marker for Invasive Adenocarcinoma of the Uterine Cervix

M Lomme, CJ Sung, MR Quddus, MM Steinhoff, F Liu, WD Lawrence. Women & Infants' Hospital and Brown Medical School, Providence, RI.

**Background:** Tenascin is an extracellular matrix glycoprotein thought to play a role in the differentiation, proliferation, and migration of cells. Its expression is increased in a variety of normal processes including embryogenesis, wound healing, and tissue involution, as well as during certain pathologic states such as tumorigenesis and metastasis. Studies of tenascin in breast, endometrial, and gastric carcinomas have suggested that increased tenascin expression may be related to the invasive potential of a malignant tumor and may be used as a marker for tumor progression. This study investigated the differences in tenascin expression in invasive (INV) and in situ (AIS) adenocarcinomas of the uterine cervix.

**Design:** Residual paraffin-embedded tissue of 16 cases of normal endocervical mucosa, 11 cases of AIS, and 8 cases of INV were immunostained with monoclonal antibody to tenascin. Staining patterns and intensity of tenascin expression in the non-neoplastic vs. neoplastic tissues were compared.

**Results:** In normal endocervical mucosa, 100% of the glandular epithelium was negative for tenascin expression and 19% showed focal weak staining of the surrounding stroma. In AIS, 27% of the cases showed weak tenascin expression in the dysplastic glandular epithelium and 64% of the cases showed weak or moderate staining of the stroma. In well and moderately differentiated invasive adenocarcinomas, 63% showed moderate or strong epithelial staining and 71% showed moderate or strong stromal staining. In 2 cases, foci of poorly-differentiated INV were present which showed no epithelial staining but strong diffuse peritumoral stromal staining. In 30% of AIS cases and 87.5% of well and moderately differentiated invasive adenocarcinomas, a distinct increase in epithelial and/or stromal staining along the advancing edge of the glandular epithelium was present.

**Conclusions:** There are distinct differences in tenascin expression in non-neoplastic vs. neoplastic endocervical mucosa. These include absence of tenascin expression in normal endocervical glandular epithelium; distinct epithelial and/or stromal staining at the advancing edge of some AIS and most invasive adenocarcinomas; and strong staining of stroma surrounding overt destructive invasion. Tenascin may therefore, prove useful in studying the tumor biology of in situ and invasive endocervical carcinoma by serving as an indicator of imminent and early invasion, as well aiding in the distinction of in situ vs. invasive growth in diagnostically difficult lesions.

### 898 Uterus-Like Masses (Endomyometriosis): Clinico-Pathologic Profile of 5 Cases

RK Malhotra, W Slater, SH Merchant, EG Silva, MB Amin. William Beaumont Hospital, Royal Oak, MI; Wayne State University, Detroit, MI; University of New Mexico, Albuquerque, NM; The University of Texas, M D Anderson Cancer Center, Houston, TX.

**Background:** Uterus-like mass or endomyometriosis is an extremely rare entity; and consists of extra-uterine tumors that recapitulate a 'uterine wall'. Approximately 12 cases have been described and mostly reported as isolated case reports in the literature. We present the clinical and pathologic profile of 5 additional cases of endomyometriosis presenting as tumor-like masses.

**Design:** The clinical history, pre-operative investigations and surgical pathology reports were obtained from the medical records. Histology slides were reviewed in all cases.

**Results:** Brief clinical profile and significant pathologic findings are summarized in Table 1. Cases 1,3 and 4, showed large, predominantly solid masses, with central cavity lined by endometrial glands and stroma, surrounded by thick smooth muscle layers, reminiscent of a uterine wall. Case 2, showed central cystic luminal dilatation with

hemorrhagic material, and a thin smooth muscle wall surrounding it, resembling a distended uterine wall on histology. Case 5 is a partly solid/cystic mass with areas of hemorrhage. Microscopically, interlacing bundles of smooth muscle were seen admixed with areas typical of endometriosis.

**Conclusions:** Uterus-like masses are extremely rare, and possess distinctive gross and histologic features. They can occur at various sites, including ovary, para-ovarian region or involve the gastro-intestinal tract. Clinically, patients can present with elevated CA-125, and presence of solid masses on radiologic evaluation, raising a suspicion of ovarian malignancy. Awareness of this entity could lead to accurate diagnosis this lesion.

Table 1

	Case 1	Case 2	Case 3	Case 4	Case 5
Age (years)	67	48	33	47	24
Pre-op CA-125 levels	188	NA	NA	125	NA
Site	Right para-ovarian	Left ovary	Right Ovary	Cecum	Abdominal wall
Size	3.5 cm	4.5 cm	NA	5 cm	2.4 cm
Gross findings	Solid white	Partially cystic	Fragmented, solid white	Solid white	Solid with numerous cystic spaces
Associated Conditions	None	None	None	Borderline Mucinous Lesion of ovary	Recent pregnancy

NA: not available

### 899 A Comparison of the Performance of Smooth Muscle Myosin Heavy Chain (SMMS-1) Versus Caldesmon, Desmin, and Smooth Muscle Actin in the Evaluation of Uterine Smooth Muscle Tumors

*A Malpica, J Averyt, MT Deavers, E Euscher, EG Silva.* The University of Texas M.D. Anderson Cancer Center, Houston, TX; The Methodist Hospital, San Antonio, TX.

**Background:** Traditional immunomarkers for uterine smooth muscle tumors include desmin and smooth muscle actin. More recently, two other markers for evaluating these tumors have become commercially available: caldesmon and SMMS-1. In this study we present the performance of these four immunomarkers in the evaluation of four different types of uterine smooth muscle tumors including: usual leiomyomas, cellular leiomyomas, highly cellular leiomyomas, and leiomyosarcomas.

**Design:** The following smooth muscle neoplasms were retrieved from the files of the Department of Pathology at our institution: usual leiomyomas (UL, 11), cellular leiomyomas (CL, 9), highly cellular leiomyomas (HCL, 9), and leiomyosarcomas (LM, 3). Hematoxylin and eosin stained slides were reviewed in all cases and diagnoses were confirmed. Paraffin-embedded tissue sections on positively charged glass slides were stained with the following monoclonal antibodies: desmin (DAKO, clone D33, 1:200), SMA (Sigma, clone 1A4, 1:3000), caldesmon (DAKO, clone h-CD, 1:30), and SMMS-1 (DAKO, clone SMMS-1, 1:50). DAKO's LSAB™ 2 peroxidase system was used. Immunostaining was assessed in a semiquantitative fashion as follows: negative (N), focally positive (F, up to 25% of the cells positive), and diffusely positive (D, more than 25% of the cells positive).

**Results:** Our results are summarize in the following table.

	SMA	Desmin	Caldesmon	SMMS-1
UL	11-D	11-D	9-D, 2-F	11-D
CL	9-D	9-D	9-D	8-D, 1-F
HCL	9-D	9-D	3-D, 2-F, 4-N	8-D, 1-F
LM	3-D	2-D, 1-F	1-D, 2-N	2-F, 1-N

**Conclusions:** 1. The expression of SMMS-1 in uterine leiomyomas is comparable to desmin and SMA. 2. SMMS-1 is more frequently expressed in highly cellular leiomyomas than caldesmon. 3. In highly cellular leiomyomas caldesmon tends to enhance the smooth muscle around blood vessels. 4. Desmin and SMA are more diffusely expressed than caldesmon and SMMS-1 in leiomyosarcomas.

### 900 Interobserver Variability of the Two-Tier System for Grading Ovarian Serous Carcinoma

*A Malpica, MT Deavers, C Tornos, RJ Kurman, R Soslow, J Seidman, EN Atkinson, EG Silva.* The UT M.D. Anderson Cancer Center, Houston, TX; Memorial Sloan Kettering Cancer Center, New York, NY; Johns Hopkins University, Baltimore, MD; Washington Hospital Center, Washington, DC.

**Background:** Recently we have proposed and published a two-tier system for grading ovarian serous carcinomas (OvSeCas). This system based primarily on the assessment of nuclear atypia (NA) with the mitotic index (MI) used as a secondary feature has been found to be of prognostic significance. Also, it appears to be user friendly and to have a good reproducibility according to our experience with pathologists and fellows in our department who have been using it for a period of 12 years. In this study we present the results of a test in which 7 gynecologic pathologists from 4 different institutions used this system for grading 80 cases of OvSeCas.

**Design:** Eighty cases of OvSeCas were retrieved from the files of Pathology at M.D. Anderson Cancer Center. They included 40 low-grade (LG) and 40 high-grade (HG) SeCas. The cases were separated in each category according to the degree of NA which was evaluated in the worst looking area. LGSeCas were characterized by the presence of mild to moderate NA (mostly uniform round or oval nuclei with evenly distributed chromatin, in some cases nucleoli were conspicuous); HGSeCas were characterized by variation ( $\geq 3:1$ ) in nuclear size and shape with irregular chromatin, and the variable presence of macronucleoli. The MI, used as a secondary feature, was evaluated in the most active area. In general, LGSeCas contained  $\leq 12$  mitoses per 10 HPFs and HGSeCas contained  $>12$  mitoses per 10 HPFs. A website was developed with the criteria herein present, examples of LG and HGSeCas, and a log form to facilitate the data entry. On each case one representative H&E slide was reviewed. Additionally, each reviewer had access to four H&E slides as examples of LG and HGSeCas (2 each). Interobserver agreement was calculated using the Kappa statistics as per STATA® Soft Package, release 8.

**Results:** In 66 of 80 cases (75% of the cases), all of the reviewers agreed. In 10 of 80 cases (12.5% of the cases), only 1 reviewer disagreed. These cases encompassed 9 LG and 1 HGSeCas. In 1 of 80 cases (1.25% of the cases), 2 reviewers disagreed. This was a LGSeCas. In 3 of 80 cases (3.75% of the cases), 3 reviewers disagreed. These cases were LGSeCas. Statistical analysis revealed a kappa = 0.87.

**Conclusions:** The two-tier system for grading ovarian SeCas is an easy and highly reproducible method for grading these neoplasms.

### 901 Survivin Expression in Epithelial Ovarian Neoplasia

*J Malysz, SW Lee, TM Nazir, CE Sheehan, JS Ross, RA Ambros.* Albany Medical College, Albany, NY; Medical College, Hallym University, Chunchon, South Korea, Korea.

**Background:** Survivin, a member of the inhibitors of apoptosis proteins (IAP) family, is a 16.5 kD cytoplasm protein located on chromosome 17q25. The expression of survivin mRNA and protein is found ubiquitously in fetal tissues and transformed cell lines, but is down-regulated in normal adult tissues. Survivin is expressed in many common human malignancies, including cancers of the lung, prostate, colon, pancreas and breast and is associated with tumor aggressiveness and unfavorable outcome.

**Design:** Formalin-fixed paraffin-embedded tissue sections from 72 common ovarian epithelial tumors including 12 benign cystadenomas, eight tumors of low malignant potential (LMP), and 52 carcinomas were immunostained by an automated method (Ventana Medical Systems, Tucson, AZ) using a specific antibody against survivin (Santa Cruz Biotechnology, Santa Cruz, CA). Staining was semiquantitatively scored based on both intensity and distribution and results were correlated with morphologic and prognostic variables.

**Results:** Five (25%) of 20 benign tumors and tumors of LMPs showed high survivin expression as defined by at least regional distribution and moderate intensity compared to 28 (54%) of 52 carcinomas ( $p=0.03$ ). In the subgroup of carcinomas, no correlation was found between survivin expression and tumor type, grade, stage or outcome.

**Conclusions:** This study demonstrates that survivin expression is increased in ovarian carcinomas versus benign and low malignant potential tumors and suggests a possible role for survivin in ovarian tumorigenesis.

### 902 The Clinical Significance of CD9/Motility Related Protein-1 (MRP-1) in Invasive Squamous Cell Carcinoma of the Uterine Cervix: A Tissue Microarray Study

*H Masoudi, BC Gilks, D Huntsman, E Yorlida, LC Horn, DJ Van Niekerk.* University of BC, Vancouver, BC, Canada; Vancouver General Hospital and University of BC, Vancouver, BC, Canada; University of Leipzig, Leipzig, Germany.

**Background:** The tetraspanins form a family of about 30 molecules mainly expressed on the cell surface. They have been reported to be involved in many physiological or pathological processes, including cell adhesion, proliferation, and cell motility. Previous studies have reported that expression of the tetraspanin CD9/MRP-1 is related to behaviour of cancer cells in different tumors. In the current study we investigated the relationship of CD9 expression level to patient outcome in cervical cancer.

**Design:** Tissue microarrays containing 130 cases of invasive cervical carcinoma were studied by immunohistochemical staining for CD9. Subsequently the slides were scored semiquantitatively. Patients were stratified into two categories, depending on CD9 expression: strong positive ( $\geq 50\%$  positive cells), or reduced expression ( $<50\%$  positive cells). Statistical analysis was done using SPSS 11.0 statistical suite. Univariate analysis of relapse free and overall survival and multivariate analyses based on Cox proportional hazards standard model were done.

**Results:** In the study described herein, we observed that 78 tumors showed strong positive immunostaining for CD9 and 32 tumors showed reduced CD9 immunostaining. In univariate analysis, as expected, lymph node status, tumor stage and depth of invasion were significant predictors of recurrence free survival ( $p<0.0001$ ,  $p=0.0355$ ,  $p=0.0354$  respectively). Reduced expression of CD9 showed statistical significance as a predictor of decreased disease free ( $p=0.0001$ ) and overall ( $p<0.0001$ ) survival. The statistical significance of CD9 expression was retained for node positive patients ( $p=0.0019$ ) but not node negative patients, when the results were stratified for nodal status. In multivariate analysis CD9 retained its significance as a prognostic factor ( $p=0.001$ ) independent of lymph node status, depth of invasion and tumor stage.

**Conclusions:** Reduced expression of CD9/MRP-1 on cervical cancer is associated with a poor prognosis, independent of known clinical and pathological prognostic indicators. It thus has potential as a marker to identify patients with higher risk of recurrence after therapy.

### 903 Histologic Patterns of Lymph Node Involvement in Women with Primary Ovarian Serous Tumors of Low Malignant Potential (S-LMP): A Clinicopathologic Study of 58 Cases

*JK McKenney, BL Balzer, TA Longacre.* Stanford University, Stanford, CA; UAMS, Little Rock, AR.

**Background:** Although lymph node involvement (LNI) in patients with ovarian serous tumors of low malignant potential (S-LMP) has not been shown to affect prognosis, the histologic patterns of LNI have not been extensively studied.

**Design:** Standard histologic sections of all available lymph nodes were evaluated in 58 women with ovarian S-LMP who underwent lymph node sampling. Patterns of LNI were correlated with histology of the ovarian tumor(s), peritoneal implant(s), and follow-up.

**Results:** Thirty (52%) women with S-LMP had LNI of 1 to 20 lymph nodes (mean=3). Sites of involvement included iliac (9), omental/mesenteric (8), pelvic (5), para-aortic (5), obturator (2) and axillary (1) lymph nodes. Nodal endosalpingiosis was present in 19 of 30 (63%) women with LNI, compared to 12 of 28 (43%) without LNI ( $p=0.19$ ). LNI was confined to the sinuses in 11 (37%), the parenchyma in 5 (17%), and present

in both in 14 (46%). Histologic patterns were often mixed and included individual cells and papillae in sinuses (27/30;90%); complex papillae within epithelial-lined spaces (intraglandular pattern) (17/30;57%); individual cells with prominent eosinophilic cytoplasm (14/30;47%); and micropapillary (5/30;17%). Rare cases with the intraglandular pattern exhibited foci identical to ovarian stromal microinvasion. Five had a stromal response and one had extranodal extension. Nodular aggregates (1-8 mm) were present in five. Five (17%) women with LNI had stromal microinvasion in the ovary and 26 (87%) had peritoneal implants (5 invasive), whereas 1 (4%) woman without LNI had stromal microinvasion and 16 (57%) had implants (0 invasive). Follow-up (mean, 77 months; median 64 months) was available in 48 of 58 (83%) women. Disease-free survival was 76% in women with LNI compared to 93% without LNI (p=0.21). One woman with LNI died of disease. There was no correlation between histologic pattern, extent of node involvement, or number of involved nodes and overall survival.

**Conclusions:** Nodal involvement by S-LMP is histologically heterogeneous and no distinct pattern correlates with overall survival. Although there is a trend in decreased disease-free survival in women with S-LMP and LNI that is not explained by implant subtype, this association does not reach statistical significance. The presence of histologic patterns similar to ovarian stromal microinvasion suggests that S-LMP in lymph node sinuses may in some cases arise in endosalpingiosis.

**904 Classification of Extra-Ovarian Implants Associated with Ovarian Serous Tumors of Low Malignant Potential (S-LMP): Clinicopathologic Study of 181 Cases**

*JK McKenney, CB Gilks, TA Longacre.* Stanford University, Stanford, CA; University of British Columbia, Vancouver, BC; UAMS, Little Rock, AR.

**Background:** Peritoneal implant subtype (invasive vs noninvasive) is a prognostic indicator in ovarian S-LMP, yet the pathologic criteria and risk of recurrence and death associated with invasive implants are controversial.

**Design:** Peritoneal implants from 181 women with S-LMP were assessed for micropapillary architecture, single cells or groups of cells, invasion into underlying tissue, solid epithelial nests with surrounding clefts, mitoses, nuclear pleomorphism and nucleoli and correlated with clinical follow-up.

**Results:** Twenty-three (13%) women had implants with invasion into underlying tissue, 21 had micropapillary architecture and/or solid epithelial nests with surrounding clefts without invasion of underlying tissue and 35 had single cells without invasion of underlying tissue. Twenty-three women had implants without underlying tissue present to evaluate (detached implants). Two patterns of extra-ovarian involvement caused difficulty in classification: 1) diffuse extension along omental septa with preservation of individual lobules (by definition, these were scored as non tissue invasive), and 2) clefts surrounding small papillae/solid nests. Cytologic features were not sufficiently reproducible to further evaluate. Follow-up (mean, 89 months) was available in 156 of 181 (86%) women. Overall survival was 71% in women with tissue invasive implants compared to 95% without invasion (p=.004). Disease-free survival was 59% in women with tissue invasive implants compared to 88% without invasion (p=.006). The presence of micropapillary architecture and/or solid epithelial nests with clefts in absence of tissue invasion was also associated with decreased disease-free survival (p=.03), but not overall survival (p=.589). Overall survival was 97% in women with implants featuring 'infiltration' by single cells in absence of tissue invasion (p=NS). No women with detached implants had an adverse outcome.

**Conclusions:** Peritoneal implants with invasion into underlying tissue are associated with decreased overall survival and disease-free survival. Micropapillary architecture and/or solid epithelial nests with surrounding clefts without tissue invasion are also associated with decreased disease-free survival, but not overall survival. There was no difference in outcome in women with detached implants or implants featuring 'infiltration' by single cells or groups of cells in absence of tissue invasion.

**905 p16 Highlights Significant Cervical Glandular Dysplasia**

*S Mehrotra, A Paintal, N Siddiqui, SE Pambuccian, S Setty, A Kajdacsy-Balla.* University of Illinois at Chicago, Chicago, IL.

**Background:** While screening has led to a decline in incidence and mortality rates of cervical squamous cell carcinoma, there has been no impact on cervical adenocarcinoma. We and others have recently observed that there is a tendency to overlook subtle glandular atypia/dysplasia when obvious squamous lesions are present. Knowing the value of p16INK4a and Ki-67 expression in evaluating HPV-driven cervical dysplasia/carcinoma we investigated the role of these markers in highlighting potential precursors of adenocarcinoma.

**Design:** We selected 57 consecutive cases of Atypical Squamous Cells (ASC) and Atypical Glandular Cells (AGC) cytologic diagnoses with follow-up biopsies (50) and cones (7) performed within the subsequent 6 months. A consensus diagnosis by 3 study pathologists of the extent of "glandular atypia" (using the criteria of Ioffe and Silverberg) and squamous dysplasia was used as the gold standard. The distribution of nuclear and cytoplasmic positivity of p16 (Dako) and nuclear positivity of Ki-67 (Dako) was assessed.

**Results:** The follow-up biopsies of the 40 ASC diagnosis showed: 11 WNL, 16 CIN1 and 13 CIN2 and above. The follow-up biopsies of the 17 AGC diagnosis showed: 10 WNL, 6 CIN1 and 1 CIN2 and above. p16 and Ki-67 immunostaining were strongly associated with the histologic areas of squamous dysplasia. Consensus diagnosis showed 8/57 cases of glandular atypia/AIS. There was p16 glandular staining in 19/57 cases and Ki-67 staining in 19/57 cases. CIN2 and above cases had strong gland positivity in 5/14 cases and CIN1 had 8/22. Most importantly, 5 of 21 cases with no squamous dysplasia showed strong gland positivity for p16 and Ki-67. Of these 5 cases, only 3 originally has an AGC diagnosis and 2 had histologic atypia.

**p16 STAINING OF SQUAMOUS AND GLANDULAR AREAS**

	Squamous p16+	Squamous p16-	Glandular p16+	Glandular p16-	Total
WNL	4	17	6	15	21
CIN1	15	7	8	14	22
>=CIN2	14	0	5	9	14

**Conclusions:** We detected strong p16 and Ki-67 staining in glandular areas with/without adjacent squamous dysplasia in cervical biopsies of patients with a previous ASC/AGC diagnosis. This may be particularly of importance when the biopsy is reported as normal (5/21=24%), which by the current algorithm disregards the original cytologic abnormality. We conclude that p16 and Ki-67 immunostaining are useful in highlighting potential glandular abnormalities in biopsies obtained in the follow-up of ASC and AGC. An intriguing question that emerges from our study is whether these individuals have precursor lesions that require further investigation.

**906 The Mucin Expression Profile in 317 Cases of Endometrial Carcinoma and Correlation with Tumor Type and Grade**

*K Merati, C Morrison, DE Cohn, NC Ramirez, JM Fowler, LB De Lott, WL Frankel.* Ohio State University, Columbus, OH.

**Background:** Mucin expression patterns have been studied in tumors from various sites. The two general categories of mucins include the transmembrane group, MUC1 and MUC4; and the secretory gel forming mucins, MUC2, MUC5AC, and MUC6. Previous studies have shown the association of MUC1 expression with poor prognosis and MUC2 and MUC5AC with a mucinous phenotype. The pattern of mucin expression in endometrial carcinomas has not been documented. We determined the mucin expression profile in endometrial carcinomas and evaluated whether there was a correlation between mucin expression and tumor type and or grade.

**Design:** 317 cases of endometrial carcinoma were retrieved from the archival files and diagnoses were confirmed. Tissue cores from formalin-fixed, paraffin-embedded donor blocks (2 cores per block) were arrayed to create a tissue microarray of cores measuring 0.6 mm. Sections were stained with monoclonal antibodies against MUC1, MUC2, MUC4, MUC5AC and MUC6. Staining was considered positive if greater than or equal to 5% of cells stained positively in either core. Mucin expression was correlated with tumor type (endometrioid vs. non-endometrioid) and tumor grade.

**Results:** MUC1 was expressed in 271/317 (87%) endometrial carcinomas, MUC2 in 2/312 (0.6%), MUC4 in 77/310 (25%), MUC5AC in 1/309 (0.3%), and MUC6 in 4/306 (1.3%). The endometrioid tumors showed a higher rate of expression of MUC1 than the non-endometrioid tumors (229/262, 87% vs. 42/55, 76%, p<0.05). There were no significant differences in the expression of the other mucins between endometrioid and non-endometrioid tumors. No significant differences in any of the mucins were noted among different tumor grades.

**Conclusions:** The majority of endometrial carcinomas showed MUC1 expression while MUC4 was seen in 25% of cases. MUC2, MUC5AC, and MUC6 were expressed only in rare endometrial carcinomas. Tumor grade did not correlate with the expression of the mucins.

**907 Proliferative Activity and Biomarker Expressions in Atypical Lobular Endocervical Glandular Hyperplasia (Atypical LEGH)**

*Y Mikami, T Kiyokawa, M Ono, H Sasano.* Tohoku University Graduate School of Medical Science, Sendai, Miyagi, Japan; Jikei University Medical School, Minato-ward, Tokyo, Japan.

**Background:** Lobular endocervical glandular hyperplasia with atypical features (atypical LEGH) has been suggested to be closely associated with minimal deviation adenocarcinoma (MDA) of mucinous-type ("adenoma malignum"), but its biologic characteristics remain to be elucidated.

**Design:** Atypical and typical LEGHs and MDAs were examined by immunohistochemistry to determine MIB-1 labeling index and expressions of p53, p21, p27, and bcl-2 proteins. The atypical LEGH was defined as a glandular lesion showing architecture of typical LEGH without evidence of destructive invasion, and demonstrating (1) nuclear enlargement, (2) irregular nuclear contour, (3) distinct nucleoli, (4) coarse chromatin texture, (5) loss of polarity, (6) occasional mitotic figures, (7) apoptotic bodies, and/or (8) infolding of epithelium or distinct papillary projection with fine fibrovascular stroma. Totally 10 cases of atypical LEGH were retrieved from the file and examined, of which nine and five accompanied typical LEGH and MDA, respectively. In addition, seven MDAs were also examined. The labeling indexes were scored 0(less than 1%), 1(1-10%), 2(11-20%), 3(21-30%), 4(31-40%), 5(41-50%), 6(51-60%), 7(61-70%), 8(71%-80%), 9(81-90%), or 10(91-100%).

**Results:** Atypical LEGH showed increased proliferating activities with MIB-1 labeling index scores ranging from 0 to 10 (median, 1), and occasional p53 expression in five of ten cases, whereas typical LEGH only rarely showed MIB-1 labeling index less than 1%, and did not show p53 immunoreactivity. MDA showed MIB-1 labeling index scores ranging from 0 to 10 (median 5), and showed p53 immunoreactivity in five of 12 cases. Occasional LEGH with or without atypia expressed p21 and/or p27 as seen in a subset of MDA. bcl-2 expression was not identified in any cases.

**Conclusions:** At least some examples of atypical LEGH appear neoplastic in nature, and MIB-1 labeling index and p53 immunohistochemistry can be used as an aid for its recognition. Further investigations are awaited to delineate biologic characteristics of atypical LEGH.

Labeling index scores	n	MIB-1	p53	bcl-2	p21	p27
LEGH	9	0	0	0	0	0-5 (med 4)
AtypLEGH	10	0-10 (med 1)	0-10 (med 3.5)	0	0-6 (med 0)	0-10 (med 9.5)
MDA	12	0-10 (med 5)	0-10 (med 0)	0	0-5 (med 0)	1-10 (med 9)

AtypLEGH; atypical LEGH, med; median

### 908 Characterization of the Epithelial Membrane Protein 2 in the Progression of Endometrial Adenocarcinoma

D Mohan, M Wadehra, D Seligson, J Braun, S Natarajan. Cedars-Sinai Medical Center, Los Angeles, CA; University of California, Los Angeles, CA.

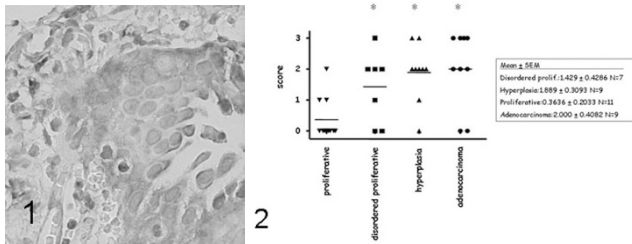
**Background:** Endometrial Carcinoma (EC), the most common gynecological malignancy, has 39,000 new cases and 6600 deaths yearly. Premalignant EC (atypical hyperplasia) is poorly understood. Useful biochemical markers of the premalignant state do not exist yet. Risk of recurrence and death in EC are currently only stratifiable by grade and stage parameters, and no biological markers are known that can predict progression of disease or serve as a focus for targeted therapy research.

EMP2 functions as a trafficking molecule required by a variety of proteins and glycolipids to efficiently transfer from the post-Golgi endosomal compartment to the plasma membrane. Modulation of EMP2 expression and localization causes pleiotropic changes on the plasma membrane of selected members of several classes of molecules, including integrins, MHC class I/immunoglobulin superfamily members (eg., CD54), and GPI-linked proteins. Moreover, EMP2 mediates trafficking of these molecules to glycolipid-enriched lipid raft microdomains (GEMs). GEMs are thought to be important for receptor complexing and resultant signal transduction.

**Design:** EMP2 expression was assessed using immunohistochemistry with antisera produced in rabbits to extracellular peptide of the human EMP2 protein [Fig1]. Each group of 7-11 patients were scored for EMP2 expression from 0-3.

**Results:** Means: Proliferative Endometrium, 0.36; Disordered Proliferative 1.43; Hyperplasia 1.89; Adenocarcinoma 2.00. [Fig 2]

**Conclusions:** EMP2 expression increases in the progression of premalignant to malignant endometrium. Which opens the possibility of disordered EMP2 regulation playing a role in the pathogenesis. Potentially, pharmacologic targeting of EMP2 could play a novel therapeutic role. We will evaluate more cases by tissue micro array methodology.



### 909 COX-2, EGFR, WT-1 and HER-2/neu Expression in Epithelial Ovarian Tumors

JM Mosquera, K Meehan, J Rotmensch, EL Yordan, F Manosca, AM Gown, P Bitterman. Rush University Medical Center, Chicago, IL; PhenoPath Laboratories, Seattle, WA.

**Background:** Ancillary techniques aid the surgical pathologist to better characterize tumors and optimize clinical management. We describe the immunohistochemical profile of a wide spectrum of ovarian epithelial tumors, with emphasis on COX-2, EGFR, WT-1 and HER-2/neu.

**Design:** Formalin fixed, paraffin embedded tissues from 156 patients were studied: 96 serous, 31 endometrioid, 16 clear, 3 mucinous, 3 transitional, and 1 poorly differentiated carcinoma (NOS), as well as 5 borderline tumors and one borderline tumor with invasive implants. Commercial antibodies were used for immunohistochemical detection of COX-2, EGFR, WT-1, Her-2/neu and p53. Mean clinical follow-up was 54 months and Kaplan-Meier survival analysis was applied.

**Results:** Five proteins were differentially detected in the ovarian tumor subtypes as follows: 1) Higher expression of COX-2 was present in endometrioid (35%) and clear (37%) carcinomas, in comparison to serous carcinomas (17%). 2) Her-2/neu overexpression was seen in only one of 156 cases (1.6%), a serous carcinoma. 3) High EGFR expression was detected in 12% of clear, 10% of endometrioid, and 4% of serous carcinomas, and in the one case of invasive implants. 4) As expected, p53 was detected in more serous carcinomas (75%) than clear (13%) and endometrioid carcinomas. The one poorly differentiated carcinoma (NOS) was also diffusely positive. 5) WT-1 expression was significantly higher in serous carcinomas (63%), including one case of micropapillary and one of psammoma carcinoma. In contrast, only 6% of endometrioid and 6% of clear cell carcinomas were positive. The only transitional carcinoma was also positive for WT-1 likewise with the two borderline serous tumors.

There was no significant statistical correlation between any protein expression and survival.

**Conclusions:** 1) The expression of COX-2 has been associated with chemotherapy resistance and poor outcome in ovarian carcinoma. In our series, about a third of endometrioid and clear cell carcinomas showed high expression. 2) In contrast to previous studies, we show that Her-2/neu overexpression in high-grade ovarian carcinomas is quite uncommon, suggesting that the use of Trastuzumab has a very limited clinical value. 3) Interestingly, a small proportion of clear, serous and endometrioid carcinomas showed high expression of EGFR. Hence, some patients may benefit from the newly FDA approved Cetuximab, a monoclonal antibody directed against EGFR.

### 910 Distinction of Endocervical and Endometrial Adenocarcinomas in Biopsy and Curettage Specimens: Utility of Immunohistochemistry for p16 and Hormone Receptors

S Movahedi-Lankarani, BM Ronnett. The Johns Hopkins Hospital, Baltimore, MD.

**Background:** Determining the origin of uterine adenocarcinomas can be difficult in biopsy and curettage specimens because the morphologic spectrum of endocervical (ECA) and endometrial adenocarcinomas (EMA) overlaps. Previous studies have shown the utility of immunohistochemistry (IHC) for p16 and estrogen (ER) and progesterone (PR) receptors and in situ hybridization for human papillomavirus (HPV) in the distinction of ECAs and EMAs in hysterectomy specimens. The goal of this study was to determine the utility of IHC for p16, ER, and PR in distinguishing ECAs from EMAs in biopsy or curettage specimens.

**Design:** Biopsy and curettage specimens from 15 ECAs and 19 EMAs for which subsequent hysterectomy specimens unequivocally confirmed the site of origin were evaluated by IHC. Staining distribution (percentage of positive cells) and intensity were assessed. HPV in situ hybridization analysis is pending.

**Results:** The mean and median size of the biopsy/curettage specimens for the ECAs were 92 mm<sup>2</sup> and 30 mm<sup>2</sup>, respectively (range: 2.0 - 353 mm<sup>2</sup>), and for the EMAs these values were 97 mm<sup>2</sup> and 84 mm<sup>2</sup>, respectively (range: 2.0 - 294 mm<sup>2</sup>). P16 expression was moderate-strong and diffuse in all ECAs (mean percentage positive cells: 94%, range: 80 - 100%). In contrast, 16 (84%) of the EMAs showed patchy and generally weaker staining for p16 (mean percentage positive cells: 32%, range: 0 - 50%). The 3 EMAs that showed diffuse p16 staining were very small specimens (5.9 mm<sup>2</sup>, 7.9 mm<sup>2</sup>, and 45 mm<sup>2</sup>). Only 1 ECA was positive for ER and PR, showing strong diffuse staining. In contrast, 17 (89%) of the EMAs were ER-positive (mean percentage positive cells: 72%, range: 0 - 100%) and 18 (95%) were PR-positive (mean percentage positive cells: 77%, range: 0 - 100%).

**Conclusions:** IHC for p16, ER, and PR can be applied to biopsy and curettage specimens to assist in the distinction of ECAs from EMAs. Very small specimens (less than 45 mm<sup>2</sup>) can be problematic in that the small amount of tissue precludes recognition of the characteristic patchy p16 staining pattern of EMAs which distinguishes them from ECAs in larger specimens. In such cases, correlation with ER and PR staining patterns is useful to distinguish ECAs from EMAs.

### 911 Endometrial Atrophy and Atrophic Endometriosis Exhibit Histological Alterations That Are Associated with Epithelial Cell Glial Fibrillary Acidic Protein Expression

SK Murray, AK Guha. Dalhousie University, Halifax, NS, Canada.

**Background:** Glial fibrillary acidic protein (GFAP) is a cytoskeletal intermediate filament that, with rare exceptions, is restricted to the central and peripheral nervous systems. GFAP in increased quantities may have growth inhibitory and toxic effects. During analysis of uterine tumors that have been reported to express GFAP we identified this protein in the background benign atrophic endometrial epithelium. This prompted us to undertake a study of GFAP expression in benign endometrium.

**Design:** From routine surgical pathology material we selected for study a collection of samples of ovarian endometriosis (OE) and a variety of endometrial biopsies with benign alterations. Each was subjected to automated immunostaining (Benchmark™ and Nexes™, Vantana Medical Systems Inc.) for GFAP (polyclonal GFAP antibody, DakoCytomation Inc., Code No. Z0334). Histological features of the endometrium including proliferative change (PE), secretory change (SE), inactive and/or atrophic change (I-AE), and metaplastic alterations were recorded.

**Results:** A total of 150 endometrial and 25 ovarian specimens were analyzed. Endometrial epithelial GFAP expression statistically correlated with I-AE (p<0.01). The proportion of cases expressing GFAP included: I-AE 89% (67/75), PE 7.5% (3/40), SE 6.7% (1/15), mixed PE + I-AE 60% (12/20). Positive staining was always focal within small strips of I-AE. Among cases positive for GFAP expression 60% (50/83) exhibited subnuclear cytoplasmic localization of the filament accompanied by flattening of the apical cytoplasm, cytoplasmic eosinophilia and hyperchromatic nuclei. Metaplastic alterations strongly correlated with I-AE and GFAP expression (p<0.05). With the exception of one case, positive GFAP expression in PE was restricted to rare isolated atrophic glands. OE samples exhibited focal GFAP expression (36%, 9/25) restricted to zones resembling I-AE.

**Conclusions:** GFAP expression is related to the proliferative status of the native endometrial epithelium and zones of endometriosis, and is specifically associated with endometrial atrophy or senescence. To the best of our knowledge this is a previously unexplored area of the role of this unique intermediate filament in epithelial cell biology. Abnormal GFAP induction may be involved in the pathogenesis of gynecologic diseases associated with endometrial atrophy or dysfunction and certain aggressive malignancies associated with atrophy such as serous carcinoma and malignant Mullerian mixed tumor.

### 912 Glial Fibrillary Acidic Protein (GFAP) Expression Is a Feature of Aggressive Variants of Endometrial and Ovarian Carcinoma Arising within Atrophic 'GFAP-Expressing' Background Epithelium

SK Murray, AK Guha. Dalhousie University, Halifax, NS, Canada.

**Background:** It is generally accepted that aggressive variants of endometrial malignancy arise within atrophic epithelium. There is increasing evidence that similar tumors in the ovary may arise from endometriosis. GFAP is a unique intermediate filament (IF) generally restricted to the nervous system and it may be growth inhibitory and toxic at elevated levels. We have identified expression of GFAP in atrophic endometrial epithelium and in atrophic endometriosis. This prompted us to undertake a study of GFAP expression in endometrial and ovarian carcinoma.

**Design:** The laboratory Information system of Dalhousie University Department of Pathology was searched [Jan. 1/02-Jan.1/04] for cases of endometrial and ovarian carcinoma, specifically for endometrioid carcinoma (EC), mucinous carcinoma (MC),



serous carcinoma (SPC), and malignant Mullerian mixed tumor (MMMT). The slides were retrieved and reviewed, and two representative blocks from each tumor were selected for automated immunostaining (Benchmark™ and Nexes™, Vantana Medical Systems Inc.) utilizing a polyclonal rabbit anti-bovine GFAP antibody (Dako Cytomation Inc., Code No. Z0334).

**Results:** The proportion of cases expressing GFAP in each tumor category included: uterine SPC-61%(14/23), ovarian SPC-62%(31/50), uterine MMMT-81%(13/16), ovarian MMMT-67%(2/3), uterine CCC (0/9), ovarian CCC (0/4), uterine EC-3%(4/150), ovarian EC (0/7), and ovarian MC (0/6). When present GFAP expression was strong but focal [usually <20% cells] and was statistically associated with the histological types of MMMT and SPC ( $p<0.01$ ). Background atrophic endometrium was present in 20 cases of uterine SPC and MMMT and demonstrated strong focal staining for GFAP in 18 (90%). Hyperplastic endometrium around uterine EC was negative for GFAP but occasional isolated atrophic glands in the background were positive. In the 4 cases of EC with GFAP staining, it was restricted to a high-grade solid component of the EC.

**Conclusions:** GFAP expression is strongly correlated with aggressive variants of endometrial malignancy (SPC, MMMT), and their ovarian counterparts. The association of GFAP expression with background atrophic endometrial lining epithelium corroborates other clinicopathologic, molecular, and epidemiologic evidence that indicate an origin from atrophy rather than hyperplasia. Furthermore, this data implies previously unknown functions of GFAP IF within epithelial cells, and may lead to new diagnostic and therapeutic strategies.

### 913 Immunohistochemical Evaluation of the c-kit Proto-Oncogene Expression in Sarcomas of the Gynecologic Region

*M Nakayama, T Mitsuhashi, Y Shimizu, S Ban, F Ogawa, T Hirose, O Ishihara, M Shimizu.* Saitama Medical School, Iruma-gun, Saitama, Japan.

**Background:** KIT is expressed in most gastrointestinal stromal tumors (GISTs) by definition, and they usually show c-kit proto-oncogene mutation (deletion). Imatinib has been reported to inhibit the tyrosine kinase activity of KIT protein, and is highly effective for GISTs. Recently, KIT expression in mesenchymal tumors of the uterus and the ovary were reported; however, their outcomes were not consistent. In this study, we immunohistochemically examined KIT expression in sarcomas of the female genital tract.

**Design:** Formalin-fixed, paraffin-embedded archival tissues from 25 surgically resected and 1 biopsy specimens from 26 patients were used. Histological diagnoses included 14 uterine leiomyosarcomas (LMS), 6 carcinosarcomas (CS) (3 in the uterus, 3 in the ovary), 5 endometrial stromal sarcomas (ESS), and 1 vaginal epithelioid sarcoma (VES). Immunohistochemical studies were performed using c-kit polyclonal antibody (A4502, Dako, Carpinteria, CA) with heat-induced antigen retrieval. Appropriate positive and negative controls were run together with the above tumors.

**Results:** Only 4 of the above tumors were positive for KIT on immunohistochemical studies, all of which were CS. Specific KIT immunoreactivity was observed in the carcinosarcomatous components in 3 cases, and in a portion of the sarcomatous component in 1 case. None of the other tumors (2 CS, 14 LMS, 5 ESS, and 1 VES) showed KIT immunoreactivity.

**Conclusions:** In this study, KIT expression was demonstrated only in CS. Other reports have indicated that all sarcomas were positive for KIT regardless of histological types (Leath CA 3rd, et al. *J Reprod Med*, 2004) and that both carcinosarcomatous and sarcomatous components of CS were positive (Winter WE 3rd, et al. *Gynecol Oncol*, 2003). One of the reasons for this inconsistency may derive from the methods of KIT immunohistochemical staining. The species of anti-KIT antibodies, the method and the time of incubation for primary antibody, and the form of antigen retrieval may affect the results of KIT staining. We used a refined method of KIT immunostaining, whereby we eliminated non-specific staining and confirmed with GISTs and other stromal tumors. Further investigation is needed for the evaluation of the effectiveness of Imatinib to KIT-positive gynecologic tumors, and c-kit gene mutations of KIT-positive tumors in the current study are now under investigation.

### 914 Late (> 10 Yrs) Recurrences of Ovarian Cancer: A Study of 896 Cases of Macroscopically Resectable Ovarian Surface Epithelial Carcinoma

*QB Nakonechny, J Santos, K Swenerton, CB Gilks.* University of British Columbia, Vancouver, BC, Canada; British Columbia Cancer Agency, Vancouver, BC, Canada.

**Background:** Ovarian surface epithelial cancers recur frequently, typically within 5 years from the time of diagnosis. The clinical and pathological features of ovarian surface epithelial carcinomas that recur 10 or more years after initial presentation are poorly documented.

**Design:** 2558 patients with ovarian surface epithelial carcinoma are recorded in the Cheryl Brown Ovarian Cancer Outcomes Unit of the British Columbia Cancer Agency for the years 1984 to 2000 (a population-based registry serving a population of approximately 4 million). 896 of these patients had "early" ovarian cancer, defined as the presence of no macroscopic residual disease post-hysterectomy (i.e. no gross residual disease) and these cases form the basis of this study. All recurrences occurring greater than 10 years post-hysterectomy and bilateral salpingo-oophorectomy were identified in the database and slides reviewed, when available.

**Results:** Nine cases were identified and two of these were excluded based on slide review; one was a primary cervical carcinoma with ovarian metastasis and the second was a serous borderline tumor. For the remaining seven cases, the median patient age was 42 yrs (range 36 to 64). There were three endometrioid, grade 2 (one stage III and two stage Ic), two undifferentiated, grade 3 (both stage Ic), one mucinous, grade 1 (stage Ic) and one clear cell, grade 2 (stage IIc). Six patients died of disease, with a median survival of 16 months post-recurrence (range 1 to 41 months), and one

patient is alive with disease. The recurrences were documented by cytology in six of the cases and a colon biopsy in one case. Sites of recurrence included liver in three cases, with retroperitoneal, intraperitoneal, colonic and pulmonary involvement each occurring in a single case.

**Conclusions:** Recurrence of ovarian surface epithelial carcinoma greater than 10 years after initial presentation is a rare event in this series of patients with "early" ovarian cancer. Recurrences in these patients with no macroscopic residual disease at the time of hysterectomy are typically seen in patients who presented with early stage disease and are of uncommon (non-serous) histological subtypes.

### 915 Expression of COX2 in Uterine Serous Carcinoma

*H Nassar, MH Arabi, S Bandyopadhyay, A Munkarah, R Ali-Fehmi.* Wayne State University/Harper Hospital, Detroit, MI; Karmanos Cancer Institute, Detroit, MI.

**Background:** Evidence is increasing on the role of COX-2 in different aspects of carcinogenesis namely apoptosis, stromal invasion, metastases and angiogenesis. Recent publications support such a role in gynecologic cancers. In the uterus, few reports have shown an over-expression of COX-2 in endometrioid type adenocarcinoma, which was associated with parameters of aggressiveness such as grade and myometrial invasion. No previous study however had analyzed the expression of COX-2 in uterine serous carcinoma (USC). Our focus is to describe the expression of COX-2 in regard to tumor stage and angiogenesis.

**Design:** We retrieved 58 cases of USC from our pathology files, 27 of which were early-stage tumors (IA and IB) and 31 were late-stage (III and IV). On those cases we performed immunohistochemical staining for COX-2, VEGF and p53. COX-2 and VEGF were scored as low and high based on the intensity and percentage of positive cells. We scored p53 as percentage of positive cells after counting 1000 cells, using 10% as a cutoff for positivity. The correlation between different parameters (stage, COX-2, VEGF and p53) was done using Fisher's exact test.

**Results:** The mean age of the patients was 60 years for the early stage group and 63 years for the late stage group. COX-2 over-expression was seen in 30% of the early stage tumors and was significantly higher in the late stages (70%,  $p=0.03$ ). High VEGF expression was more often seen in late stage tumors (54% vs. 45%), the difference however did not reach statistical significance. The percentage of p53 positivity was similar in both groups (52% vs. 48%). We found a correlation between COX-2 expression and VEGF expression in both early and late stage disease (Pearson correlation  $r=0.63$ ;  $p<0.001$ ). No correlation was seen between p53 expression and COX-2 in both groups.

**Conclusions:** To our knowledge, this is the first report investigating COX-2 expression in USC. The increase in COX-2 expression noted with higher stage disease suggest that it may play a role in the progression of these tumors. In keeping with the role of COX-2 in angiogenesis, we also found a high correlation between the overexpression of COX-2 and VEGF in these neoplasms.

### 916 Well-Differentiated Adenocarcinoma In Situ of the Cervix. A Rare Variant That May Be Mistaken for a Benign Lesion

*FP O'Connell, KR Lee.* Brigham and Women's Hospital and Harvard Medical School, Boston, MA.

**Background:** The characteristic histologic features of adenocarcinoma in situ of the cervix (AIS) are well known. We describe 8 cases of a rare intraepithelial glandular lesion some or all of which we feel are a "well-differentiated" variant of AIS.

**Design:** Eight cases of atypical glandular proliferations of the cervix, all with a similar "well differentiated" histologic appearance were identified; 7 were from consultation files and 1 from the pathology files of Brigham and Women's Hospital. All cases caused difficulties and controversies in diagnosis. Cases were assessed for cytoplasmic characteristics, nuclear stratification, atypia and number of mitoses and apoptoses, based on the system of Ioffe et al.. Where possible, they were evaluated for MIB1 (>25%) p16, and HPV. Clinical information and follow-up was obtained.

**Results:** The patients ranged in age from 22 to 53 years (mean 37 years); 6 presented with atypical glandular cells on pap smear, one during pregnancy. The remaining 2 cases were incidental findings: one following TAH BSO for endometriosis, one following LEEP for CIN 3 on a biopsy. The largest specimens per case were 2 hysterectomies, 5 cone biopsies and 1 biopsy. The glandular cells in all cases differed from the usual AIS in having abundant cytoplasm which varied from pale pink and bubbly to mucinous, and only minimal (6 cases) or moderate (2 cases) nuclear stratification. Furthermore, all cases had only either grade 1 or grade 2 (of 3) nuclear atypia and 7 of 8 had conspicuous nucleoli. The average number of mitoses and apoptoses per gland ranged from 0.5 to 7.5. Only 2 lesions fulfilled criteria for typical AIS by Ioffe grading (both grade 6 of a possible 9). MIB1 was > 25% in 4 of 6 cases; P16 was reactive in 6 of 7; HPV was present in 2 of 6. Coexistent adenocarcinoma was present in 2 cases (1 minimal deviation) and CIN 3 in one. One patient with invasive adenocarcinoma developed a vaginal recurrence. The remaining 4 patients with follow up data (2 post hysterectomy; 2 post cone biopsy) had no evidence of disease at 4 mo to 11 yr.

**Conclusions:** We describe the histologic and biomarker characteristics of 8 unusual in situ cervical glandular lesions with well-differentiated morphologic features that may be misdiagnosed as benign. Although they do not meet traditional diagnostic criteria, we feel they are likely to be a hitherto undescribed "well-differentiated" variant of AIS.

### 917 Nectin-1 Expression in the Normal and Neoplastic Human Female Gynecologic Tract

*SD Oh, T Valyi-Nagy, D Shukla, G Guzman.* Univ. of Illinois at Chicago, Chicago, IL.

**Background:** Nectin-1 is an immunoglobulin-like adhesion molecule that participates in the formation of adherens junctions. Animal and human studies have shown that nectin-1 is widely expressed in epithelial tissues. Reduced expression of nectin-1 has

been reported in invasive squamous cell carcinomas of the human skin. Our aim was to determine the pattern of nectin-1 expression in the normal and neoplastic human female genital tract.

**Design:** We performed a retrospective study involving standard immunohistochemical staining of normal human gynecologic specimens (n =18) and neoplastic tumors, including squamous dysplasia and invasive squamous cell carcinoma of uterine cervix and vulva, adenocarcinoma of the endometrium, and serous papillary carcinoma of the ovary (n =13). All specimens were graded according to intensity of cytoplasmic staining from 0 to 4 (0= no staining, 4= strongest intensity of staining).

**Results:** Widespread and strong cytoplasmic nectin-1 positivity was found in normal vulvar and cervical squamous mucosa, and endocervical, endometrial, and fallopian tube epithelium (mean grade, x =2.63). In contrast, the vulvar, endocervical, endometrial, and ovarian stroma showed minimal to absent staining (mean grade, x = 0.58). There was a significant difference in staining intensity of the normal epithelium versus the stroma (p < 0.00001, Wilcoxon matched pairs-signed ranks test). All neoplastic tissues including squamous dysplasia, squamous cell carcinoma, and adenocarcinoma showed strong cytoplasmic nectin-1 staining (mean grade, x = 3.08). The advancing edge of these tumors, however, showed significantly decreased or absent expression of nectin-1 (mean grade, x = 1.39). Statistical analysis showed significant difference in staining intensity of the dysplasia and center of tumor versus advancing edge of tumor (p < 0.005, Wilcoxon matched pairs-signed ranks test).

**Conclusions:** Our findings provide novel information about the pattern of nectin-1 expression in the female gynecologic tract in normal and neoplastic conditions. There is a significant difference in the staining pattern of normal epithelium versus normal stroma. Dysplastic and invasive carcinomas of the female genital tract stain strongly with nectin-1 and this staining is reduced or absent in the advancing edge of these tumors. These findings suggest that downregulation of nectin-1 may be associated with the loss of cell-to-cell adhesion at the advancing edge of invasive carcinomas of the female genital tract.

### 918 PTEN Mutation in "Surface Epithelial Changes" of the Endometrium

*B Ologun, MR Qudus, CJ Sung, H Bai, MM Steinhoff, WD Lawrence.* Women & Infants Hospital and Brown Medical school, Providence, RI.

**Background:** So-called "surface epithelial changes" (SECs) have been reported to be associated with a typical low grade endometrioid carcinoma (EMCA) in about 49% cases (Int J Gynecol Pathol 1995 14:191-7) as well as with atypical endometrial hyperplasia (AEH). Various patterns of SECs have been described, including a mucinous pattern simulating microglandular endocervical hyperplasia and syncytial aggregates of relatively bland eosinophilic cells (frequently with papillary and/or squamous differentiation) simulating either benign papillary "metaplasia" or malignant papillary neoplasms. Although they are cytologically bland and mimic endometrial epithelial metaplasias, SECs develop directly from underlying EMCA and are considered a consistent marker for underlying malignancy. However, their true biologic nature has not been investigated. Alterations of PTEN have been reported in EMCA, as well as in their glandular precursors without accompanying morphologic changes of malignancy. The aim of this study was to investigate mutations of PTEN in SECs to determine its utility in predicting the presence of endometrial glandular neoplasia and its precursors.

**Design:** Twenty seven endometrial biopsies containing SECs were retrieved from the pathology archival files of our institution. Fourteen cases had associated AEH, and the remaining 13 cases had surface epithelial changes only. Four  $\mu$  sections were cut from each block and stained with antibodies to PTEN and one section was stained with H&E to confirm the presence of SECs. Positive and negative control slides were run with each batch of staining. The absence of nuclear and/or cytoplasmic staining was interpreted to represent a mutation of PTEN.

**Results:** PTEN mutation was found in 10 of 27 (37%) of cases of SEC. In 8 of 14 cases of associated SECs and AEH, the PTEN mutation was found in the epithelium of both the SECs and AEH. The remaining 2 cases containing only SECs also exhibited PTEN mutation. Subsequent followup procedures in 10 cases of SECs only yielded 3 EMCA, 2 AEH, and 1 simple endometrial hyperplasia.

**Conclusions:** The detection of a PTEN mutation in an endometrial biopsy containing only SECs appears to confer a high risk for the presence of an associated endometrial glandular lesion in a subsequent endometrial sampling. More studies with a greater number of cases are needed to prove the utility of PTEN immunostaining in the identification of SECs and their predictive potential for endometrial glandular lesions.

### 919 Human Papillomavirus Testing in the Follow-Up of Women with High-Grade Intraepithelial Lesions after Loop Electrosurgical Excision Procedure

*J Ordi, LM Puig-Tintore, A Torné, E Sierra, R Esteve, M Marginet, M Solé, E Campo.* IDIBAPS-Hospital Clínic. University of Barcelona. School of Medicine, Barcelona, Spain.

**Background:** Premalignant lesions of the uterine cervix are associated to infections by high-risk human papillomaviruses (HR-HPV). Thus, molecular techniques of HPV detection are increasingly being used in the evaluation of patients with cervical lesions. HR-HPV testing has been recently used to improve monitoring of women treated for high-grade squamous intraepithelial lesions (H-SIL). The aim of our study was to assess the usefulness of HR-HPV testing using the Hybrid Capture II (HCII) assay in the follow-up of patients with H-SIL treated with loop electrosurgical excision procedure (LEEP) and to evaluate whether any factors are related to recurrent disease.

**Design:** 188 women (mean age 40.1 $\pm$ 10.8, range 22–83) with a histologically confirmed H-SIL underwent a LEEP at our institution. A pre-excision HR-HPV detection was available in 150 women. Surgical specimens were thoroughly evaluated. All women were monitored by cervical cytology at 3, 6, 12 and 24 months. HR-HPV HCII detection

was conducted in all patients at 3-24 months (mean 14.7 $\pm$ 11.1). When cytologic abnormalities or a positive HR-HPV test were detected a colposcopy with biopsy of suspicious areas was performed.

**Results:** 29% of women developed recurrence of H-SIL. The sensitivity, specificity and negative predictive value (NPV) of a positive HCII test for HR-HPV were respectively 98.2%, 75.9% and 99.0%, whereas the values of an abnormal cytology [atypical squamous cell of unknown significance (ASC-US) or SIL] were 83.6%, 90.2% and 93.0%. Positive resection margins were significantly associated with recurrence (64.4% vs. 18.3%, p<0.001). Pre-excision quantification of HR-HPV by HCII [in relative light units (RLU)] was significantly higher in cases with positive than in cases with negative LEEP margins (1115.4 $\pm$ 956.2 vs. 678.9 $\pm$ 748.8, p=0.004) and in recurrent than in non-recurrent cases (1092.6 $\pm$ 874.5 vs. 738.2 $\pm$ 815.9, p=0.012). Pre-excision HR-HPV RLU above 1000 were significantly associated with recurrent disease when compared with women with lower values (66% vs. 34%, p=0.006).

**Conclusions:** HR-HPV detection by HCII test has an excellent sensitivity and NPV and can be included for monitoring women treated for H-SIL. High pre-excision viral loads are associated with positive LEEP margins and post-treatment recurrences.

### 920 Human Papillomavirus Load in Hybrid Capture II Assay: Does Increasing the Cutoff Improve the Test?

*J Ordi, LM Puig-Tintore, E Sierra, A Torne, R Esteve, M Marginet, M Sole, M Santos, E Campo.* IDIBAPS-Hospital Clinic, University of Barcelona, School of Medicine, Barcelona, Spain.

**Background:** Premalignant and malignant lesions of the uterine cervix are almost constantly associated to infections by high-risk human papillomaviruses (HR-HPV). Thus, molecular techniques of HPV detection are increasingly being used in the evaluation of patients with cervical lesions. Hybrid Capture II (HCII) assay is a broadly used technique that detects the presence of 13 HR-HPV types and provides a quantitation of the viral DNA load. The reaction is chemoluminescent, and positive specimens are those with relative light units (RLU) equal or greater than the mean of positive controls containing 1.0 pg/mL. However, it has been recently suggested that the test may be optimized by using a higher cutoff. The aim of our study was to evaluate the optimal RLU level for detecting high-grade squamous intraepithelial lesions (H-SIL) or cervical cancer (CC).

**Design:** 2271 women (mean age 38.7 $\pm$ 12.3, range 15–92) were referred to a colposcopic clinic due to cytology of atypical cells of unknown origin (ASC-US), SIL or CC. All women underwent a new Pap test, a colposcopy with biopsy of suspicious areas when present, and HR-HPV detection using the test HCII for HR-HPV. After completing the study 72 women were diagnosed of CC, 466 of H-SIL, 652 of low grade SIL (L-SIL), whereas no lesion was detected in 1081 women. ROC analysis was used to evaluate the sensitivity and specificity for detecting H-SIL and CC.

**Results:** HR-HPV was detected in 91.7% of CC, 96.6% of H-SIL, 85.1% of L-SIL and 21.6% of negative cases. Mean viral load was significantly higher in positive cases with CC (630  $\pm$  811), H-SIL (643  $\pm$  1078) and L-SIL (592  $\pm$  950) than in normal cases (68  $\pm$  194) (p<0.001). The sensitivity and specificity of HC II at different cutoffs for H-SIL or higher are shown in the table.

Threshold (URL-pg/mL)

	>1	>2	>3	>5	>10
Sensitivity	95.7%	93.9%	92.8%	90.1%	85.7%
Specificity	54.6%	59.5%	62.4%	65.1%	68.7%
PPV	39.6%	41.9%	43.4%	44.5%	46.0%
NPV	97.6%	96.9%	96.5%	95.5%	93.9%

The number of cases with H-SIL or higher not detected by the test increased from 23 at 1 URL to 33 at 2 URL, 39 at 3 URL, 53 at 5 URL, and 77 at 10 URL, with the first case of H-SIL lost at 1.02 URL.

**Conclusions:** The use of a higher cutoff for the relative unit ratio (higher viral load) in the HCII test improves the specificity but significantly increases the number of cases with H-SIL or carcinoma not detected, reducing the sensitivity of the test.

### 921 Apoptosis-Related Protein Expression in Endometrial Carcinoma. A Tissue Microarray Study

*J Pallares, X Dolcet, D Llobet, M Rue, X Matias-Guiu.* Hospital Universitari Arnau de Vilanova. University of Lleida., Lleida, Spain.

**Background:** Proteins controlling cell death are thought to be important in tumor development and progression. The Bcl-2 members of the Bcl-2 family play a major role in the regulation of apoptosis, either by promoting (Bax, Bak, Bcl-XS) or suppressing (Bcl-2, Bcl-XL) cell death.

**Design:** A tissue microarray was constructed from paraffin-embedded blocks of 95 endometrial carcinomas (EC). Immunohistochemical evaluation included: Bax, Bak, Bcl-2, Bcl-XS, Bcl-XL. Results were correlated with clinical and pathological data as well as with apoptotic index and immunostaining for M30 and Active Caspase 3.

**Results:** Bax expression was very frequent in EC (98.75%). Bak immunostaining was observed in 82.92% of EC. Bcl- XS and Bcl- XL were positive in 70.73% and 76.19%, respectively. Bax showed a significant correlation with Bak (r = 0.25, p = 0.03) and with Bcl-XL (r = 0.27, p = 0.02), but did not correlate with Bcl-2, the apoptotic index, M30 and Active Caspase 3. Bak did not correlate with Bcl-2 and Bcl-XL. There was a very significant positive correlation between these two forms of Bcl- X (r = 0.75, p = 0.000). Bcl- XL expression increased in non-endometrioid endometrial carcinomas (mean: 107.77) compared to endometrioid endometrial carcinomas (mean: 63.01) (p = 0.039). Bcl- XL also increased in stage III EC (mean: 97.5) compared to stage I (mean: 58.07) (p = 0.05).

**Conclusions:** Proteins controlling cell death are frequently expressed in endometrial carcinoma. The significant association between Bax and Bak suggest a complementary role in the regulation of apoptosis in endometrial carcinoma.

### 922 CDX2 Immunohistochemical Staining Patterns in Mucinous Neoplasms of the Female Genital Tract

KJ Park, M Bramlage, EC Pirog, LH Ellenson. Memorial Sloan Kettering Cancer Center, New York, NY; New York Presbyterian Hospital Cornell Medical Center, New York, NY.

**Background:** CDX2 protein is a caudal related homeobox transcription factor that is responsible for the differentiation of intestinal-type epithelium (ITE). The monoclonal antibody has been shown to be highly specific for ITE and its neoplastic counterpart. Numerous studies have demonstrated a role for CDX2 immunohistochemistry (IHC) in differentiating metastatic colonic adenocarcinoma (CAD) from other metastatic carcinomas. Mucinous tumors (MT) of the female genital tract (FGT) are often in the differential diagnosis when considering a gastrointestinal (GI) primary. The purpose of this study was to characterize the CDX2 staining patterns of MT of the FGT to evaluate its usefulness in differentiating these tumors, not only from CAD, but also from each other.

**Design:** Fifty-nine cases of MT arising in the cervix, endometrium and ovary were retrieved from the surgical pathology files of the NYPH Cornell Medical Center. A paraffin block of formalin-fixed tissue was selected from each case and IHC was performed for CDX2, CK7 and CK20 using the avidin-biotin retrieval method. Tumors were scored semiquantitatively by one author (KJP) based on the amount and intensity of staining. Positive nuclear staining of tumor cells was rated as follows: 0 (no signal), 1+ (1-25% of cells), 2+ (26-75%), 3+ (76-100%). The intensity of the signal was scored as weak (1+) or strong (2+) as compared to positive controls.

**Results:** Expression of CDX2 in the FGT showed predominantly no or minimal positivity in the tumor cells; 69% showed no signal, 20% were 1+ and 11% were 2+ or 3+. Signal intensities were observed to be 1+ or 2+, sometimes within the same tumor. All tumors were CK7+ and CK20-.

	CDX2 (0)	CDX2 (1+)	CDX2 (2+/3+)
Cervix (n=17)	65%	12%	23%
Endometrium (n=34)	74%	24%	3%
Ovary (n=8)	63%	25%	12%
<b>Total</b>	<b>69%</b>	<b>20%</b>	<b>11%</b>

CDX2 Positivity (n=59)

**Conclusions:** Though CDX2 is specific for ITE, it has been shown that it can also stain non-GI mucinous neoplasms. The staining properties of this antibody in FGT MT has not been thoroughly studied. In this study, CDX2 is predominantly negative or focally positive in these cases, including in the ovary, which up to 64% have been reported as positive. There was no significant difference in staining patterns between the various organs of the FGT. Therefore, using CDX2 in conjunction with CK7 and CK20 can be of further assistance in differentiating GI primaries from MT of the FGT.

### 923 Benign Metastasizing Leiomyoma Is Clonally Derived from Uterine Leiomyoma

KT Patton, V Papavero, L Chiang, A Yeldandi, P Hui, XJ Yang. Feinberg School of Medicine, Northwestern University, Chicago, IL; Indiana University Medical Center, Indianapolis, IN; Yale University School of Medicine, New Haven, CT.

**Background:** Benign metastasizing leiomyoma (BML) is a rare condition characterized by multiple benign-looking smooth muscle tumors usually involving the lung in women with uterine leiomyoma. It is not clear whether BML is a benign uterine leiomyoma colonizing the lung; a metastasis of a low grade leiomyosarcoma; or primary pulmonary leiomyomatosis coexisting with but independent of uterine leiomyoma. We studied a case of BML arising in a 44 year-old female who presented with multiple pulmonary nodules. We used X-chromosome inactivation analysis to determine whether pulmonary tumors in BML were clonally derived from uterine primary tumors.

**Design:** Sections were prepared from two separate pulmonary nodules and the uterine leiomyoma. H&E sections, and immunohistochemistry for estrogen receptor (ER), progesterone receptor (PR) and Ki-67 were evaluated. The polymorphic CAG repeat sequence within the human androgen receptor (AR) gene was amplified from DNA isolated from formalin-fixed tissue.

**Results:** The two pulmonary tumors had identical histology and immunohistochemical profile (bland histology, ER+, PR+, and very low Ki-67 index) as the uterine tumor did. The two pulmonary tumors and the uterine tumor showed an identical pattern of AR allelic inactivation indicating they are derived from the same clone.

**Conclusions:** We provide evidence that benign metastasizing leiomyoma is clonally derived from benign-appearing uterine leiomyoma. Despite the benign appearance of some uterine leiomyomas histologically and immunohistochemically, they may spread to the lungs and possibly other sites. Because of its hormonal receptor status, benign metastasizing leiomyoma can be treated with anti-hormonal therapy although extensive disease may be associated with an increased morbidity and even mortality. This tumor should be regarded as a neoplasm with low malignant potential.

### 924 Prognostic Relevance of Insulin-Like Growth Factor 1-Receptor (IGF-1R), PTEN, Akt, Bad and Caspase-3 in Endometrial Carcinoma

FM Peiró, G Peiró, C Alenda, A Payá, E Adrover, FI Aranda. Hospital General Universitario de Alicante, Spain.

**Background:** Growth factors and tumor suppressor gene proteins modulate cell survival and proliferation. Therefore, dysregulation of these mechanisms are known to contribute to neoplastic transformation and growth. In Endometrial carcinoma (EC) little is known about the role of IGF-1R, PTEN and their downstream-targets, the serine/threonine kinase Akt and Bad, and Caspase-3.

**Design:** Formalin-fixed paraffin-embedded tissue from 113 EC were immunostained with antibodies to IGF-1R (NeoMarkers), PTEN (Zymed), phospho-Akt (Ser473) (Cell Signaling), phospho-Bad (Ser136) (Santa Cruz Biotech), and caspase-3 (Novocastra) using the avidin-biotin peroxidase (ABC) method. Slides were scored

semi-quantitatively based on staining proportion (0%, <10%, 10-50%, >50%) and intensity (1+, 2+, 3+). The results were correlated with several clinical pathologic factors and the outcome of the patients. The univariate analysis was performed with Kaplan-Meier method, and the differences were assessed with the log-rank test.

**Results:** Median age of the patients was 65 years (range 41-83). Tumors were predominantly of endometrioid type (87%), FIGO grade 2 (54%), FIGO pT1b (49%), less than 50% of myometrial invasion (63%) and had no LVI (74%). Mean follow-up was 45 months. Elevated levels (>50%) of IGF-1R and caspase-3 were 29% and 76% respectively. p-Akt was positive (intensity 2-3+) in 75% cases and p-Bad in 70%. Loss of PTEN (<1% of positive cells) was observed in 6%. A positive correlation was seen between IGF-1R and p-Bad (p=0.031), and only as a trend with high levels of caspase-3 (p=0.15), endometrioid type (p=0.07), FIGO III-IV stage (p=0.13) and nuclear grade 3 (p=0.3). Tumors with PTEN contained more frequently high levels of caspase-3 (p=0.03). However those cases with loss of PTEN tend to have high IGF-1R (p=0.12), presented in low FIGO stage (p=0.3) and patients were older than 55 (p=0.19). p-Akt negative tumors had no LVI (p=0.04), high caspase-3 (p<0.000) and negative p-bad (p=0.07). Patients with tumors with histologic grade and nuclear 1, early stages, negative LVI and low expression of IGF-1R had longer survival (all p<0.04).

**Conclusions:** Our data show that upregulation of IGF-1R and/or loss of PTEN occurs in a subset of EC. Moreover, expression of apoptotic markers such as Akt/Bad and caspase-3 seem to be influenced by IGF-1R and PTEN, which suggest their role in this neoplasia. However, only IGF-1R had prognostic relevance.

### 925 Analysis of Teratomas for Isochromosome 12p: Evidence Supporting a Dual Pathway for Teratomatous Elements in the Ovary

CK Poulos, L Cheng, K Ma, TM Ulbright. Indiana University School of Medicine, Indianapolis, IN.

**Background:** Teratomas are the most common germ cell tumors (GCT) of the ovaries and include a variety of forms with a range of clinical behavior. As in testicular teratomas, they may be benign, malignant or a component of mixed GCTs. In the testis, data support separate pathogeneses for prepubertal and postpubertal teratomas, with derivation of the former from a non-transformed germ cell and the latter from differentiation of a nonteratomatous, malignant GCT. The absence of cytogenetic abnormalities (including isochromosome 12p [i(12p)]) in mature ovarian teratomas suggests that they may be analogous to prepubertal testicular teratomas, but there are no data regarding genetic changes in the teratomatous components of ovarian mixed GCTs. This study seeks to examine the origin of ovarian teratomas by using fluorescence *in-situ* hybridization (FISH) to look for i(12p) in the teratomatous components of mixed GCTs and in mature cystic teratomas.

**Design:** Paraffin sections from 5 mixed GCTs of the ovary with teratomatous components and from 5 mature cystic teratomas of the ovary were subjected to FISH for the presence of i(12p) using 12p spectrum green and 12 centromeric spectrum orange probes. Additional components in the mixed GCTs were yolk sac tumor and embryonal carcinoma.

**Results:** None of the patients with pure mature cystic teratoma displayed i(12p) or other evidence of 12p amplification (12p signal:centromeric signal, 0.96-1.06). On the other hand, 4 of 5 (80%) cases of mixed GCT had i(12p) in their nonteratomatous components and 3 of 5 (60%) in the teratomatous component. 1 of the 2 cases without i(12p) in the teratomatous portion of the mixed GCT also did not demonstrate 12p abnormalities in other elements of the mixed GCT.

**Conclusions:** i(12p) was seen in the teratomatous and nonteratomatous components of ovarian mixed GCTs but not in mature, cystic teratomas. These findings support that teratoma in mixed ovarian GCTs has a different pathogenesis compared to mature cystic teratoma of the ovary. Furthermore, the finding of i(12p) in both the teratomatous and nonteratomatous components of mixed GCTs supports that the teratoma derives from other components, similar to the situation in the testis.

### 926 Expression of 14-3-3 $\sigma$ Protein Is Independent of Expression of p53 and p16 in Vulvar Intraepithelial Neoplasia and Invasive Squamous Cell Carcinoma

A Powers, WR Hart, B Yang. Cleveland Clinic Foundation, Cleveland, OH.

**Background:** 14-3-3  $\sigma$  is a p53-regulated protein involved in numerous cellular signaling pathways associated with cell cycle control and DNA repair. 14-3-3  $\sigma$  induces G2 arrest in response to DNA damage and also inhibits apoptosis through interaction with pro-apoptotic proteins, including Bax and BAD. Recent studies have shown that expression of 14-3-3  $\sigma$  is silenced through promoter hypermethylation in squamous cell carcinoma (SCC) of the vulva. However, expression of the 14-3-3  $\sigma$  protein in vulvar SCC and its precursors has not yet been studied.

**Design:** We studied the protein expression of 14-3-3  $\sigma$ , p16 and p53 in 5 cases of normal vulvar skin, 5 cases of vulvar squamous hyperplasia, 23 cases of vulvar intraepithelial neoplasia (VIN) and 9 cases of invasive SCC of the vulva. Twenty-three cases of VIN included 14 cases of classic (bowenoid) type and 9 cases of differentiated (simplex) type.

**Results:** Immunohistochemical studies showed that 14-3-3  $\sigma$  is negative to weakly positive with a submembranous cytoplasmic staining pattern in normal vulvar skin and squamous hyperplasia. Moderate to strong expression of 14-3-3  $\sigma$  was seen in 100% (9/9) of invasive SCC and 87% (20/23) of VIN, including 13/14 cases of classic VIN and 7/9 cases of differentiated VIN. A perinuclear cytoplasmic and nuclear staining pattern was characteristically seen in VIN, but not in normal skin or squamous hyperplasia. There was no significant difference in staining pattern or intensity between classic and differentiated VIN. Expression of 14-3-3  $\sigma$  was independent of the expression of p53 and p16. Expression of p53 protein was seen in 67% (6/9) of invasive SCC. P53 staining patterns were different in classic and differentiated VIN.

p53 was continuously expressed in the basal and suprabasal zone in 78% (7/9) of cases of differentiated VIN, but was patchy and focally expressed in 43% (6/14) cases of classic VIN. p16 was expressed in all 14 cases of classic VIN, but only in 1/9 (11%) cases of differentiated VIN.

**Conclusions:** Our findings indicate that 14-3-3  $\sigma$  is overexpressed in VIN, independent of p53 and p16 expression. In contrast to the absent to weakly positive submembranous cytoplasmic staining pattern seen in normal vulvar skin and squamous hyperplasia, 14-3-3  $\sigma$  relocalizes to the perinuclear cytoplasm and nucleus in VIN and invasive SCC. As overexpression of 14-3-3  $\sigma$  is seen both in classic and differentiated VIN, 14-3-3  $\sigma$  immunostaining may be useful, in conjunction with p53 and p16, in detection of VIN and vulvar SCC.

### 927 Pseudoactinomycotic Granules of the Gynecologic Tract

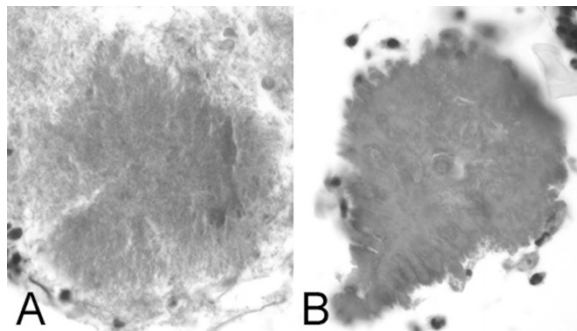
*B Pritt, H Blaszyk, K Cooper, S Mount.* University of Vermont, Burlington, VT.

**Background:** The filamentous bacteria *Actinomyces* may cause serious infection in the gynecologic (GYN) tract, making definitive diagnosis of actinomycotic granules (AMGs) in GYN specimens clinically important. Non-infectious pseudoactinomycotic granules (PAMGs) may mimic the microscopic appearance of AMGs and present a diagnostic pitfall. There is a paucity of studies defining criteria to differentiate the similar-appearing entities, PAMGs and AMGs.

**Design:** Of the 32,779 gynecologic specimens examined at this institution from 1998 to 2003, a computer search identified 3 cases of PAMGs and 4 cases of AMGs. To further delineate the composition of both AMGs and PAMGs, histochemical stains comprising von Kossa, Periodic Acid Schiff with amylase (PAS-A), Gomori's Methenamine Silver (GMS), Brown and Bren, and Ziehl-Neelsen were performed using appropriate controls.

**Results:** On hematoxylin and eosin (H&E) stained sections, AMGs were seen as distinct granules with eosinophilic peripheral radiating filaments and a dense central core (Figure A). In contrast, H&E stained sections of PAMGs demonstrated irregular club-like peripheral projections without a central dense core (Figure B). AMGs and PAMGs both stained negatively with von Kossa, PAS-A, GMS, and Ziehl-Neelsen stains. The Brown and Bren stain, on the other hand, highlighted the gram positive filamentous bacteria associated with AMGs and was entirely negative in PAMGs.

**Conclusions:** PAMGs pose an important diagnostic pitfall, necessitating knowledge of distinguishing characteristics from AMGs. A combination of light microscopy and histochemistry, particularly the Brown and Bren stain, aids in this distinction.



### 928 Correlation of p16, MCM2, and Cyclin E as Molecular Markers for Cervical Disease in IHC and ICC Formats

*NK Prpic, M Parker, S Sampson, J Hessling, A Taylor, T Fischer.* TriPath Oncology, Durham, NC.

**Background:** Numerous molecular markers have been shown to be useful tools in detecting the presence of underlying high grade dysplasia in cervical samples. The purpose of this study was to demonstrate the correlation between cervical tissue and SurePath™ slides using p16, MCM2 and Cyclin E.

**Design:** All cases (tissue and cytology) were stained with p16 (DakoCytomation), MCM2 (Novocastra) and Cyclin E (Novocastra) using Dako's Envision+ detection system on the Dako Autostainer. Tissue Micro Arrays containing normal cervix, CIN I, CIN II, CIN III, SCCa, and AdenoCa were used to test each antibody to determine staining characteristics and feasibility for cervical cytology testing. Residual cytology samples were processed on the TriPath Imaging PrepStain™ Slide Processor and stained with each antibody. Total cases tested were NIL=15, ASC-US=21, LSIL=20, ASH-H=2, HSIL=22, and Cancer=14. A cytotechnologist and pathologist reviewed the slides and indicated a "positive" if the nucleus of immature or abnormal appearing cells stained brown.

**Results:** Cyclin E showed relatively low sensitivity, but high specificity, with no significant staining of metaplastic-type cells in most of the NIL cases. For ASC-US, there was no significant staining in abnormal cells for Cyclin E and moderate staining for MCM2. This data correlates with histology results where the majority of the normal cervix or CIN I cases showed minimal nuclear staining. Staining for HSIL and cancer cases was consistent with the histologic findings for Cyclin E. MCM2 had moderate to strong nuclear staining in approximately 50% of the CIN II and higher cases. p16 demonstrated a reasonable level of sensitivity and specificity albeit less than MCM2. Metaplastic-type cells were positive for p16, NIL cases were negative while 7/21 ASC-US cases were positive. Regarding HSIL cases, approximately half showed positive staining with p16 while all cancer cases were positive. These cytology results were less satisfactory than the histologic findings in which p16 showed strong staining in CIN II and higher cases with minimal reactivity in normal cervix and CIN I.

**Conclusions:** Cyclin E and MCM2 produced the most consistent results for the cytology or histology specimens. MCM2 demonstrated more variable findings on histology but an improvement in sensitivity over Cyclin E for cytology. The histology findings for p16 did not correlate as well with the cytology results. Cyclin E and MCM2 are useful molecular markers for cervical disease when applied to tissue and cytology specimens.

### 929 Comparison of Expression of Immunohistochemical Markers in Uterine Papillary Serous Carcinoma (UPSC) and Serous Neoplasms of Ovary

*G Rasty, C Rowsell, A Covens.* University of Toronto, Toronto, ON, Canada.

**Background:** The purpose of the study is to compare the expression of different tumor markers such as Wilms tumor susceptibility gene 1 in Uterine papillary serous carcinoma (UPSC) and serous neoplasms of ovary.

**Design:** A panel of immunohistochemistry antibodies (p16, E-cadherin, CA125, Wt-1 and Calretinin) was evaluated on paraffin sections of 48 neoplasms. 26 cases were Uterine papillary serous carcinomas and 22 serous neoplasms of ovary (8 serous cystadenomas, 2 borderline serous tumors, 12 serous adenocarcinomas). Two pathologists scored the slides according to the proportion of positive cells as negative (0%), weak (<50%) and strong (>50%).

**Results:** A trichotomous logistic regression model was performed. WT1 had a statistically significant positivity in ovarian neoplasm ( $p < 0.0001$ ) as it was positive in 19/22 ovarian tumors. It was positive in 6/26 uterine papillary serous carcinomas (4 with weak expression). The frequency distribution of WT-1 in UPSC vs. ovarian serous neoplasms was  $< 0.0001$  [ $P$  (chi-square test)]. CA125 was positive in 20/22 of ovarian tumors and in 23/26 UPSC. E-cadherin and p16 were almost equally expressed in both ovarian and Uterine papillary serous carcinomas. Calretinin was weakly positive in 1/22 ovarian carcinomas and 2/26 UPSC.

**Conclusions:** An immunohistochemical panel that includes antibodies against WT1 may reliably distinguish between serous neoplasm of ovary and uterine papillary serous carcinoma. Antibodies against p16, CA125, Calretinin or E-cadherin may not be as useful in this regard.

### 930 Endometrial Stromal Sarcoma - Observational Evidence of a Genetic Background?

*S Regauer, O Reich.* Medical University of Graz, Graz, Austria.

**Background:** Endometrial stromal sarcomas (ESS) are estrogen-dependent uterine tumors in young women representing only 0.2% of all gynaecological oncological diseases. The individual steps involved in malignant transformation of endometrial stromal cells are unclear, but hormonal treatments have been implicated. Due to their rarity, risk factors or genetic associations are largely unknown. We, the authors, are in contact with more than 100 patients with ESS via an internet support group. Our aim was to analyze this large ESS patient cohort for possible familial cancers aggregations with the help of a detailed questionnaire.

**Design:** 64 patients of the ESS group returned the questionnaire with answers relating to age at diagnosis, organs involved at diagnosis (stage), recurrences and metastases; menarche, menopause, pregnancies, hormonal treatments, other hormone dependent diseases, personal and familial oncological history.

**Results:** At diagnosis, 94% of women with ESS were younger than 45 years and premenopausal. 50% of ESS patients had a history of hormonal treatment (estrogen replacement therapy, in-vitro-fertilization treatment and birth control pills) or estrogen-dependent diseases such as endometriosis and leiomyomas. One patient each had a synchronous thyroid cancer, cutaneous malignant melanoma, breast and cutaneous squamous cell carcinoma. One familial case of ESS was observed. An oncological family history in was reported by 47% of patients, and parents were affected in 26%. Among the parental oncological diseases, there were 6 breast carcinomas, 2 prostate carcinomas and 2 colon carcinomas. Among all malignancies, breast carcinoma was the most prevalent familial cancer in 25% of patients, followed by endometrial carcinoma (8%), lung cancer (7%) and prostate carcinoma (5%). Multiple familial cancers were observed in 25% of patient with mostly hormone-dependent cancers (breast carcinomas associated with endometrial (2 families), prostate (2 families), colon (2 families) and ovarian carcinoma (1 family) and multiple myeloma (1 family). 10% of patients with ESS reported that several family members (up to 5 women) were diagnosed with breast carcinoma.

**Conclusions:** Patients with ESS are young, report hormonal treatments and have a family history of hormone-dependent carcinomas suggesting a strong genetic predisposition in the oncogenesis of ESS. Patients with ESS may suffer from an inherited genetic predisposition similar to familial breast and prostate carcinomas, which may render them susceptible to hormone-dependent growth promotion.

### 931 Gonadotropin-Releasing Hormone Receptor Expression in Endometrial Stromal Sarcomas

*O Reich, FF Nogales, S Regauer.* Medical University of Graz, Graz, Austria; University of Granada, Granada, Spain.

**Background:** Endometrial stromal sarcomas (ESS) are extremely rare gynecological tumors. ESS are estrogen-sensitive tumors with poorly defined adjuvant hormonal treatment protocols after surgical therapy. Gonadotropin-releasing hormone (GnRH) and its receptors have been identified in several human hormone dependent malignant tumors, such as breast, ovarian and endometrial cancer. GnRH agonist represent potentially useful adjuvant therapy options for these tumors and clinical trials are underway to test their efficacy. It is intriguing to speculate that ESS may also express GnRH receptors (GnRH-R) and that women with ESS may also benefit from adjuvant hormonal therapy with GnRH agonist.

**Design:** To investigate a possible role for GnRH agonists in the treatment of ESS, we evaluated GnRH-R expression in 30 patients with ESS. Tissues of primary ESS was available for 29 patients. Tissues of recurrent or metastatic ESS was studied in 5 patients. Archival formalin-fixed and paraffin-embedded material was analyzed for

expression of GnRH-R type I and GnRH-R type II. For immunohistochemical analysis, representative 2- $\mu$ m thick sections of the ESS were incubated with guinea-pig antisera to GnRH-R I (1:1000) and GnRH-R II (1:2000) after proteinase pretreatment. The antisera were generously provided by PD Dr. Gundker, Dept. of Obstetrics and Gynecology, Georg-August University of Goettingen, Germany.

**Results:** Expression of GnRH receptor type I and II was demonstrated in 22 / 29 primary ESS. The staining pattern was diffuse cytoplasmic in 19/22 ESS and granular/vesicular with perinuclear distribution in 3/22 ESS. The percentage of positive tumor cells ranged from 10-80% in 19/22 ESS. Only 3 primary ESS showed staining in 100% of tumor cells. Recurrences and metastases in 5 patients with ESS were observed in the omentum, vagina /urinary bladder, small intestines and lymph nodes. The metastases and recurrent tumors showed a higher percentage of tumor cells expressing GnRH-R than in the primary tumors. In 4/5 recurrent / metastatic ESS, 100% of tumor cells were positive for GnRH-R.

**Conclusions:** The demonstration of GnRH-R I and II expression in tissues of ESS and the increase in expression in recurrences and metastases of ESS may be a rationale for a clinical study of GnRH analogs in the treatment of women with ESS.

### 932 Expression of Thyroid Transcription Factor (TTF-1) in Uterine Endometrioid and Uterine Papillary Serous Carcinoma: A Tissue Microarray Study of 101 Cases

L Rezeanu, M Crawford, C Subramony, L Gui. University of Mississippi Medical Center, Jackson, MS.

**Background:** TTF-1 is a nuclear homeodomain transcription factor, expressed in the developing thyroid, lung and brain of vertebrates. TTF-1 is a highly specific marker for primary adenocarcinoma of the lung and thyroid origins and is useful in identifying primary and metastatic adenocarcinoma of the lung. However, TTF-1 expression has been reported in primary adenocarcinoma of other organs. This study is to investigate TTF-1 expression in uterine endometrioid (EC) and uterine papillary serous carcinoma (UPSC).

**Design:** Tissue microarray (TMA) blocks were constructed using archival formalin-fixed paraffin blocks from 81 EC and 20 UPSC. The array blocks were created with two 1 mm cores taken from different areas of each block. Four micron sections from the TMA blocks were stained in an automated immunostaining system (Ventana System) using antibody directed against TTF-1 (from Ventana) with appropriate controls. The results were reported as positive or negative nuclear staining; the distribution graded as 1-3+ (1+ = 0 to 33% of tumor cells showing positive staining; 2+ = 34 to 66%; 3+ = 67 to 100%) and intensity graded as (weak-w and strong-s).

#### Results:

Number, distribution and intensity of TTF-1 positive tumors

Tumor type	#positive	%positive	1+	2+	3+
EC (n=81)	4	5%	3(1w, 2s)		1(s)
UPSC(n=20)	4	20%	1(w)	2(2s)	1(s)

Distribution of positive staining: 1+ = 0-33%; 2+ = 34-66%; 3+ = 67-100%; w-weak; s-strong

TTF1 was found to express in 5% of EC and one case stained strongly. In UPSC, 20% of the cases expressed TTF-1 and 3 cases stained strongly.

**Conclusions:** We showed that TTF-1 is sometimes expressed in both EC and UPSC. This study suggests that in appropriate clinical setting, EC and UPSC should also be included in the differential diagnosis of an adenocarcinoma that is positive for TTF-1.

### 933 Endocervical-Like Mucinous Borderline Tumors of the Ovary: A Clinicopathologic Analysis of 31 Cases

IM Rodriguez, JA Irving, J Prat. Hospital de la Santa Creu i Sant Pau. Autonomous University of Barcelona, Spain.

**Background:** Endocervical-like mucinous borderline tumors (ELMBT) are a subset of mucinous ovarian tumors encountered less frequently than those of intestinal type. These tumors exhibit distinct characteristics, including occurrence at a relatively young age and smaller size, with a higher frequency of bilaterality and associated endometriosis. Tumors with these features are associated with a favorable prognosis. The purpose of this study was to determine the frequency and prognostic significance of intraepithelial carcinoma and microinvasion in ELMBT, findings which have been reported infrequently.

**Design:** Clinicopathologic features of 31 ELMBT, selected from hospital and consultation files, were reviewed. Tumors exhibiting foci of confluent intracyclic growth and/or by foci of moderate to marked nuclear atypia were subclassified as borderline tumors with intraepithelial carcinoma (BIEC). Tumors with  $\geq 1$  foci of single cells, irregular glands, or small nests, infiltrating the stroma were subclassified as ELMBT with microinvasion (MBTmi).

**Results:** Of the 31 cases, 4 cases (13%) were subclassified as BIEC and 4 cases (13%) as MBTmi; 3 cases showed both BIEC and microinvasion. All but 1 of the 31 patients were stage I. Follow-up data was available for 21 patients; all showed no evidence of disease at a mean interval of 5.7 years. Six of 8 patients with BIEC and/or MBTmi had available follow up data; all 6 patients were without evidence of disease at a mean interval of 6.6 years.

**Conclusions:** ELMBT, specifically those with intraepithelial carcinoma and/or microinvasion, are associated with an excellent prognosis.

### 934 Utility of Immunohistochemistry in Determining the Site of Origin of Metastatic Mucinous Carcinomas Involving the Ovary

B Ronnett, AM Gown, TS Barry, R Vang. Johns Hopkins Hospital, Baltimore, MD; PhenoPath Laboratories, Seattle, WA.

**Background:** When a mucinous carcinoma is suspected to be metastatic in the ovary based on characteristic pathologic features, the specific primary site may not be evident based on clinical and morphologic features. The value of an expanded panel of immunohistochemical markers for determining the likely primary site has not been extensively studied.

**Design:** Immunohistochemical studies were performed to compare the expression patterns in 54 cases of metastatic mucinous carcinomas involving the ovary, including 42 from known and 12 from unknown (UNK) primary sites. The known sites of origin included lower gastrointestinal tract (LGI; colon, rectum, and appendix), pancreas and bile ducts (Pan/BD), and stomach (STOM). The UNK tumors were interpreted as metastatic based on the presence of characteristic gross and microscopic features. Cases were scored based on the percentage of positive cells: negative (-) =  $\leq 5\%$ ; positive (+) =  $> 5\%$ .

#### Results:

Primary site	CK7+	CK20+	CK7-/CK20+	CDX2+	Dpc4+	Mesothelin+	CA-125+
LGI	3/26 (12%)	23/26 (88%)	21/26 (81%)	22/26 (85%)	19/21 (90%)	2/26 (8%)	1/26 (4%)
Pan/BD	10/12 (83%)	10/12 (83%)	2/12 (17%)	8/12 (67%)	5/11 (45%)	6/12 (50%)	4/12 (33%)
STOM	3/4 (75%)	4/4 (100%)	1/4 (25%)	4/4 (100%)	4/4 (100%)	1/4 (25%)	0/4 (0%)
UNK	9/12 (75%)	10/12 (83%)	3/12 (25%)	8/12 (67%)	10/12 (83%)	3/12 (25%)	2/12 (17%)

**Conclusions:** CK7 positivity by itself suggests an upper gastrointestinal tract origin whereas CK20 positivity by itself is non-specific; the CK7-/CK20+ profile suggests lower gastrointestinal tract origin. Loss of Dpc4 is rather specific for pancreas-bile duct origin and implicates those organs when the primary site is unknown. Positivity for mesothelin is most frequently seen with pancreas-bile duct origin; it is somewhat specific (90%) but not particularly sensitive (50%). CA-125 positivity occurs in non-ovarian mucinous carcinomas and thus cannot be used as evidence of ovarian origin. The immunophenotype of the tumors from unknown primary sites suggests that the majority are not of LGI origin.

### 935 Clinical Significance of pSTAT3 Expression in Ovarian Carcinoma

DG Rosen, HM Amin, RC Bast, R Lai, J Liu. The University of Texas M. D. Anderson Cancer Center, Houston, TX; University of Alberta and Cross Cancer Institute, Edmonton, AB, Canada.

**Background:** STAT3 (signal transducer and activator of transcription-3) is a transcription factor that is activated/phosphorylated (pSTAT3) by several growth factors and cytokines. pSTAT3 is an oncogene that does not only transmit a signal from the cell surface to the nucleus but also directly participates in the transcription of a wide array of genes in control of apoptosis and cell cycle regulation. Emerging literature suggests that STAT3 signaling may play a critical role in cancer formation and progression.

**Design:** We used tissue microarrays containing 322 tissue samples of human ovarian cancer from patients who had surgery between 1990 and 2000 at M.D. Anderson Cancer Center and linked pSTAT3, EGFR, Her2/neu, Bcl-2 and Ki-67 immunohistochemical staining results to a comprehensive clinicopathological database to analyze tumor characteristics and patient survival.

**Results:** Of 296 scorable cases, constitutive expression of pSTAT3 occurred in 173 cases (58%). pSTAT3 constitutive expression was significantly associated with undifferentiated and clear cell carcinoma histotype ( $p < 0.0001$ ), low tumor grade ( $p = 0.05$ ), high proliferation index ( $p = 0.01$ ), overexpression of EGFR ( $p < 0.0001$ ) and Her2/neu ( $p = 0.03$ ). A trend to a better survival was found in patients with low levels of pSTAT3 expression (42% 5yr rate survival) compared to high expression (14% 5yr rate survival). No association was found between pSTAT3 and FIGO stage, relapse, level of cytoreduction or Bcl-2.

**Conclusions:** Expression of pSTAT3 is significantly associated with tumor grade, growth factor receptors EGFR and Her2/neu and with high proliferation index, suggesting an important role of pSTAT3 in ovarian carcinoma progression and aggressiveness.

### 936 Expression of hTERT and hTR RNA Correlates with Poor Prognosis in Ovarian Carcinoma

DG Rosen, G Yang, JA Lanza, AT Tong, J Liu. MD Anderson Cancer Center, Houston, TX.

**Background:** Telomeres are repetitive, non-coding DNA sequences that prevent chromosome ends from being recognized as double-strand DNA breaks providing protection from destabilizing agents. It consists of two core functional components: the catalytic subunit of human telomerase reverse transcriptase (hTERT) and a telomerase RNA template (hTR). Telomerase is activated in the majority of immortal cell lines in culture and in most malignant tumors. We investigated the expression of both hTERT and hTR components by in situ hybridization (ISH) in a large cohort of ovarian carcinoma using tissue microarrays (TMA).

**Design:** Two sets of TMA blocks were designed. One contained tissue from five normal ovaries, 10 ovarian cystadenomas, 20 borderline lesions and 30 ovarian carcinomas were selected. The second set contained 441 cases of primary ovarian carcinoma. In situ hybridization was performed on paraffin sections using digoxigenin labeled antisense hTERT and hTR probes. Level of expression was semi-quantitatively assessed using a 0-4 grading system. No expression was defined as "0", whereas "1" was defined as weak, "2" as intermediate, and "3" as strong. Difference in proportions was calculated using chi square analysis or Pearson correlation as appropriate. Overall survival time was assessed by Kaplan-Meier analysis.

**Results:** hTERT and hTR subunits were moderately to strongly expressed in 76% and 89% of ovarian carcinomas, 80% and 100% of borderline lesions, weakly expressed in 100% and 100% of cystadenomas respectively. None of the 5 normal ovaries expressed hTR or hTERT. Level of expression of both hTERT ( $p < 0.00001$ ) and hTR ( $p = 0.0007$ ) was increasingly higher in high grade lesions compared to normal ovaries and cystadenomas. High level expression of hTERT ( $p = 0.05$ ) and hTR ( $p = 0.03$ ) correlated with poorer survival. A significant correlation index was found between the two subunits ( $p = 0.005$ ). No significant correlation was found with tumor grade, stage, histotype or relapse.

**Conclusions:** High level of expression of hTR and hTERT correlates with poorer overall survivals. Therefore, their expressions serve as poor prognostic markers for human ovarian cancer. Although the expression is absent in normal ovarian surface epithelium, the high level expression in high percentage of benign as well as malignant tumors renders them unreliable markers in differentiating malignant tumors from benign ones in clinical settings.

**937 Endometrial Endometrioid Adenocarcinoma with a Micropapillary Pattern of Growth. Histologic and Immunohistochemical Characterization**  
*M Roychowdhury, S Pambuccian, E Gulbahe, C Manivel, J Jessurun.* University of Minnesota, Minneapolis, MN.

**Background:** Adenocarcinomas with micropapillary pattern of growth have been recognized as aggressive tumors in various organs including the breast, urinary bladder, ovary, and lung. The reason why this morphologic feature affects tumor behavior is unknown. Based on the expression of the surface glycoprotein MUC1 in the basal surface of the cells, in contrast to the luminal or cytoplasmic staining seen in adenocarcinomas without a micropapillary pattern, it has been suggested that the antiluminal (stromal facing) expression alters epithelial-stromal interactions facilitating spread. Recently we have encountered examples of endometrioid endometrioid adenocarcinomas that focally exhibited a micropapillary pattern of growth, a feature that has not been emphasized before. This study was planned to define the pathologic and immunohistochemical (IHC) characteristics of endometrioid adenocarcinomas with micropapillary pattern of growth.

**Design:** A total of 350 endometrial epithelial tumors were reviewed (6/96-6/04). Cases were classified as endometrioid, serous, clear cell or other. A micropapillary pattern was defined as papillary projections devoid of stroma or cleft formation around neoplastic cells in invasive tumors. IHC for p53, Bcl2, Ki-67, MUC1, CD10 and Ecadherin were done in all endometrioid adenocarcinomas with a micropapillary (EAM) pattern and in selected cases of serous, clear cell (CCA) and conventional endometrioid adenocarcinomas (EA) as controls.

**Results:** 14 EAM were identified, representing 4% of all cases. The micropapillary pattern was present focally in 3 cases. The epithelial clusters either derived from malignant endometrial tubular glands forming intraluminal polypoid structures or sprouted from macropapillary structures (with stroma). FIGO grade 3 adenocarcinoma was frequently found in association with EAM. 10/14 (71%) of EAM showed strong immunoreactivity for p53, similar to serous tumors. CCA and EA were negative. Immunoreactivity for Ki67 was present in 50% or more cells in 57% of EAM, 66% of serous tumors, 30% of EA and in none of CCA. Antiluminal staining with MUC 1 was observed focally in 3 cases. CD10, Bcl2 and Ecadherin were noncontributory.

**Conclusions:** 1- A micropapillary pattern of growth is more frequently encountered in tumors exhibiting high histologic grade.

2- Compared to EA, EAM frequently expresses p53 and has a high proliferative index as estimated by Ki67 staining.

3- Antiluminal staining for MUC1 is not a frequent occurrence in these tumors.

**938 Measurement of Tumor Depth of Invasion Is of Value in Risk Assessment of Vulvar Carcinomas**

*I Rufforny, EJ Wilkinson, NA Massoll.* University of Florida, Gainesville, FL.

**Background:** Current trend in management of patients with superficially invasive vulvar cancer is conservative, with emphasis on vulvar sparing. The aim of this study is to evaluate the validity of the measurement of varying depths of tumor invasion up to 5 mm as it relates to the frequency of lymph node metastasis, recurrence, and survival in women with primary vulvar squamous cell carcinoma.

**Design:** Seventy-five cases of superficially invasive squamous cell carcinoma of the vulva ( $\leq 5$  mm depth of invasion) were analyzed from 1980 to 2001. Depth of invasion, as defined by World Health Organization (WHO), is the measurement from the epithelial-dermal junction of the adjacent most superficial dermal papillae to the deepest point of invasion. The results of analysis of multiple factors, including age, stage, treatment modality, depth of tumor invasion, presence of vascular space involvement, metastases to the regional lymph nodes and recurrences are presented. The cases are analyzed according to the maximal depth of invasion:  $\leq 1$  mm - 24 patients,  $>1$  to  $\leq 2$  mm - 19 patients,  $>2$  to  $\leq 3$  mm - 17 patients, and  $>3$  to  $\leq 5$  mm - 15 patients.

**Results:** The 75 patients ranged in age from 34 to 92 years, mean of 57.

Twenty-one of 24 patients with tumor invading  $\leq 1$  mm in depth were treated with wide local excision alone. None developed metastasis or died. One patient, a cardiac transplant recipient, had local recurrence 5 years later.

Of 36 patients with tumor invading  $>1$  to  $\leq 3$  mm in depth, 5 underwent wide local excision (2 recurred locally); 27 patients were treated with vulvectomy and lymphadenectomy (6 recurred locally, 1 developed lymph node metastasis, 1 had metastasis to lung, and 3 died of disease); 4 were treated with vulvectomy alone (1 recurred locally with urethral extension and groin metastasis).

Of 15 patients with tumor invading  $>3$  to  $\leq 5$  mm in depth, 5 were treated with wide local excision (2 recurred locally, 1 of which died); 9 underwent vulvectomy and lymphadenectomy (1 recurred); 1 treated with radical vulvectomy alone had groin metastasis and died.

**Conclusions:** Patients with vulvar carcinoma with a depth of invasion of 1 mm or less (Stage 1A) can be effectively treated with wide local excision without inguinal-femoral lymphadenectomy. Patients with tumors having a depth of invasion exceeding 1 mm have increased risk of lymph node metastasis and recurrence. Measurement of depth of invasion is of value in discriminating tumor that can be treated by local wide excision from those with risk for recurrence and lymph node metastasis.

**939 Double Immunostaining for Cytokeratin and Collagen IV Is Useful for Detection of Microinvasion in Vulvar and Cervical Intraepithelial Neoplasia**

*D Rush, E Hyjek, RN Baergen, LH Ellenson, EC Pirog.* University of Florida College of Medicine, Gainesville, FL; Weill Medical College of Cornell University, New York, NY.

**Background:** Histopathological identification of early invasion in vulvar intraepithelial neoplasia (VIN3) or cervical intraepithelial neoplasia (CIN3) may be difficult with the use of routine H&E staining. Presence of inflammation at the dermal-epidermal junction and tangential tissue sectioning are the most common diagnostic pitfalls. The goal of our study was to examine the utility of double immunostaining for cytokeratin and collagen IV in distinguishing of microinvasive carcinoma from intraepithelial neoplasia.

**Design:** The study group consisted of 10 cases of "VIN3, suspicious for invasion" and 10 cases "CIN3, suspicious for invasion". Cases of vulvar carcinoma (n=10) and cervical carcinoma (n=25) were included as a positive control group. Cases of VIN3 (n=15) and CIN3 (n=10) were included as a negative control group. All cases were double immunostained for cytokeratin and collagen IV and continuity of the basement membrane and the presence of stromal invasion was assessed.

**Results:** A well defined, continuous basement membrane (BM) was visualized in all cases of VIN3 and CIN3. A discontinuous or absent BM was observed around the malignant cells on the invasive tumor front in all cases of vulvar and cervical carcinoma; however some of the centrally located tumor nests were surrounded by a well formed BM. In 2 cases of "VIN 3, suspicious for invasion" and 4 cases of "CIN 3, suspicious for invasion" foci of dysplastic squamous cells breaching through the BM gaps were identified with the use of double immunostain, and these cases were reclassified as "superficially invasive/ microinvasive carcinoma". A well defined, continuous BM was present in the remaining cases "suspicious for invasion".

**Conclusions:** Double immunostaining for cytokeratin-collagen IV is useful for evaluation of early invasion in equivocal cases of vulvar and cervical intraepithelial neoplasia.

**940 Pathology of the Endometrium in Women Biopsied for a Thickened Endometrial Stripe on Ultrasound**

*DS Rush, NA Massoll, EJ Wilkinson.* University of Florida College of Medicine, Gainesville, FL; Malcolm Randall VA Medical Center, Gainesville, FL.

**Background:** Measurement of the endometrial thickness as it appears on transvaginal ultrasound (TVUS) examination is currently used routinely in the evaluation of post-menopausal (PM) women as a screening test for the presence of endometrial pathology. This practice has been supported by numerous studies demonstrating that, at least in PM patients with post-menopausal bleeding (PMB), the presence of significant disease is effectively excluded by a normal appearance on TVUS. The utility of TVUS screening in asymptomatic (ASX) patients is more controversial, although widely practiced. It has been our experience that biopsies performed for the further evaluation of endometrial thickening seen on TVUS rarely demonstrate significant pathology, particularly in ASX patients. In fact, paradoxically, the most common diagnosis rendered on these biopsies is atrophy. This apparent contradiction between the sonographic and histologic appearances of the endometrium has been largely ignored in the literature on the use of ultrasound as a screening tool and has yet to be explained.

**Design:** The computerized records of the department of pathology at Shands Hospital at University of Florida were searched for all endometrial biopsy or curettage specimens. The clinical history provided with the specimen was reviewed. Any case in which the woman was noted to be or could reasonably be presumed to be PM and who was reported to have a thickened endometrium on TVUS was included. A total of 87 cases were thus identified.

**Results:** Three cases were excluded from analysis because no tissue was identified on microscopic examination. Of the 84 remaining patients, 46 had PMB and 38 were ASX. A diagnosis of atrophy was rendered in 43 patients (51%); 15 patients with PMB (33%) and 28 ASX (74 %) patients. A diagnosis of hyperplasia or carcinoma was rendered in 10 patients (12%); 9 patients with PMB (20%) and 1 ASX patient (2.6%). Only two cases of endometrial carcinoma were detected and both were in patients with PMB.

**Conclusions:** TVUS may be useful as a screening method in PM women with PMB to decrease the number of biopsies performed. However, at this time it does not appear to have any use in the screening of ASX patients. In both groups of patients the utility of TVUS could be greatly improved if the paradoxical appearance of atrophic endometrium as thickened on imaging could be resolved.

**941 GLUT-1 Is Preferentially Expressed in Endometrial Hyperplasia and Adenocarcinoma**

*AA Sager, AF Paulino, AM Affy.* University of California, Davis, Sacramento, CA; Genzyme Genetics, New York, NY.

**Background:** The facilitative transport of monosaccharides in human cells is accomplished by a family of transmembrane proteins, GLUT-1 to GLUT-7, which differ in their tissue distribution, affinities for specific monosaccharides, and physiologic regulation. GLUT-1, a high-affinity glucose transporter, is normally expressed in erythrocytes, perineurium, and blood-brain barrier. Although the aberrant expression of GLUT-1 has been reported in a wide spectrum of epithelial malignancies, its possible correlation with the malignant transformation of endometrial epithelium has not been clearly established. The purpose of this study is to evaluate the extent to which benign, hyperplastic, atypical and malignant endometrial epithelia express GLUT-1.

**Design:** We examined the immunohistochemical expression of GLUT-1 (DAKO, Carpinteria, CA, 1:200) in cases of proliferative endometrium (n=12), secretory endometrium (n=10), endometrial polyps (n=10), adenomyosis (n=18), simple

hyperplasia (n=14), complex hyperplasia without atypia (n=14), complex hyperplasia with atypia (n=17), and adenocarcinoma (n=34). Positive staining was defined as distinct, linear membrane staining, particularly at cell-cell borders. Cells that showed only cytoplasmic staining were considered negative. The percentage of positive cells and staining intensity were assessed in a semi-quantitative fashion and scored (1+ to 3+).

**Results:** All cases from proliferative endometrium, secretory endometrium, adenomyosis, and simple hyperplasia and 90% (9/10 cases) of the endometrial polyps were negative for GLUT-1. GLUT-1 was expressed in 57% (8/14 cases) of complex hyperplasia without atypia, 71% (12/17 cases) of complex hyperplasia with atypia and 82% (28/34 cases) of adenocarcinomas. The extent of staining ranged from occasional positive foci to extensive multifocal staining. GLUT-1 positivity increased in intensity as the distance of tumor cells to stromal blood vessels increased.

**Conclusions:** 1) GLUT-1 is preferentially expressed in complex hyperplasia and in adenocarcinoma. 2) GLUT-1 immunostaining may be useful in distinguishing cases of benign hyperplasia from those of hyperplasia strongly associated with malignancy. 3) GLUT-1-mediated glucose transport may allow hypoxic tumor cells distant from stromal blood vessels to survive through glycolysis. Our data suggests that the expression of GLUT-1 transporter may be closely related to the malignant transformation of epithelial endometrial tumors by supporting their increased need for glucose metabolism.

#### 942 Immunohistochemical Staining for p16<sup>INK4A</sup> and p53 in Squamous Cell Carcinomas of the Vulva

M Santos, LM Puig-Tintoré, B Mellado, A Torné, B Lloveras, J Klaustermeier, E Campo, J Ordi. IDIBAPS-Hospital Clínic. University of Barcelona. School of Medicine, Barcelona, Spain; Institut Català d'Oncologia/Hospital de Bellvitge, L'Hospitalet del Llobregat, Spain.

**Background:** Two distinct types of vulvar squamous cell carcinomas have been delineated which differ in terms of clinical presentation and behavior: human papillomavirus (HPV)-associated and HPV-unrelated carcinomas. The former, usually of basaloid or warty histology, account for about one third of cases, are considered to arise in young women and are frequently preceded by the undifferentiated form of vulvar intraepithelial neoplasia (VIN). The second type, generally of keratinizing type, arise in elderly patients, are frequently associated with the differentiated form of VIN as well as with lichen sclerosus and squamous cell hyperplasia, and show a high proportion of p53 mutations. Technical difficulties in confidently detecting and typing HPV in paraffin-embedded tissues have prevented its widespread use in many laboratories and both types of carcinomas are currently classified according to their histologic characteristics. The aim of our study is evaluate a large series of infiltrating vulvar carcinomas in order to determine whether p16 immunostaining could be a good discriminator between the two major types of vulvar carcinoma.

**Design:** All vulvar squamous cell carcinomas diagnosed at our institution from 1995 to August 2004 were included in the study. All tissues were fixed in 10% formalin and paraffin embedded. Immunohistochemical detection of p53 and p16<sup>INK4A</sup> (Biocare Medical CA) was performed in all cases. PCR detection of HPV sequences using the GP5+/GP6+ primers was conducted in a series of cases.

**Results:** 79 cases were included in the study. Histologically, 63 (79.7%) cases were of the keratinizing type whereas 16 (20.2%) were of HPV-related type (10 basaloid, 6 warty). No significant differences in age were observed between both groups (79.6±12.8 vs. 76.1±13.0). p16 staining was diffuse and intense in 15/16 (93.7%) cases with basaloid or warty histology and only in 3/63 (4.8%) of keratinizing carcinomas. In contrast, p53 was intensely positive in 12.5% of basaloid or warty and in 66.6% of keratinizing carcinomas. HPV sequences were detected in 60% of p16 positive carcinomas and in 0% carcinomas negative for p16.

**Conclusions:** p16 immunostaining is a good discriminator between HPV-associated and HPV-unrelated vulvar carcinomas.

#### 943 Prognostic Significance of Tumor Infiltrating Lymphocytes (TILs) in Ovarian Cancer and Their Relationship to Cancer-Testis (CT) Antigen Expression

E Sato, S Olson, AA Jungbluth, O Kunle, LJ Old. Memorial Sloan-Kettering Cancer Center, New York, NY; Roswell Park Cancer Institute, Buffalo, NY.

**Background:** Tumor infiltrating lymphocytes (TILs) are considered an immunological host reaction to the tumor. Epithelial ovarian carcinoma (EOC) is frequently accompanied by a prominent lymphocytic infiltration though its prognostic significance is still debated. Also, tumor antigens potentially triggering these immuneresponses are poorly defined. CT antigens such as MAGE, NY-ESO-1 elicit autologous T cell responses in tumor patients and are expressed in various types of cancers including EOC and in testicular germ cells as the only normal adult tissue. In the present study, we analyzed the prognostic significance of the lymphocytic infiltration in a series of EOC and examined its relation with CT antigen expression.

**Design:** IHC was done on 117 EOC cases using standard archival paraffin tissues. The lymphocytic markers CD3, CD4, CD8, CD20, and CD57 were employed and their intraepithelial and stromal localization were distinguished. The following CT antigens were analyzed: NY-ESO-1, MAGE-A1, and MAGE-A4 using previously generated mAbs ES121, MA454, and 57B respectively. Statistical analysis was performed with SPSS and SAS software.

**Results:** Among the lymphocytic subtypes, only the presence of intraepithelial CD8+ TILs showed a favorable prognostic significance. A high intraepithelial CD8/CD4 ratio was also found to be a favorable prognostic variable suggesting the immunosuppressive properties of CD4+ TILs perhaps due to a subpopulation of regulatory T cells. None of the CT antigens showed any prognostic significance. A combinational analysis of CT antigen expression and TILs showed no apparent

contribution of CT antigen specific TILs to prognosis. However, most intraepithelial TILs were CD8+ while CD57+ cells were infrequent indicating the presence of a specific rather than an unspecific (NK cell-based) immune response.

**Conclusions:** Our study shows the prognostic significance of CD8+ TILs in EOC and the importance of their intraepithelial localization. The expression CT antigens NY-ESO-1, MAGE-A1 and MAGE-A4 has no prognostic significance in our EOC series. Though our study suggests the presence of a specific immune response, this immune response appears not to be directed to any of the CT antigens analyzed.

#### 944 HBME1, Galectin3, and CITED1: Markers of Malignancy in Struma Ovarii

J Schmidt, R Rucker-Schmidt, C Quigley, W Welch, K Lee, C Crum, V Nosé. Brigham & Women's Hospital, Harvard Medical School, Boston, MA.

**Background:** Struma ovarii (SO) are ovarian teratomas predominately composed of thyroid tissue. A small subset of SO are malignant, the majority of which have the histologic features of papillary thyroid carcinoma (PTC). However, definitive histologic diagnostic criteria of malignancy in SO are not well defined. Antibodies to HBME1, Galectin3, and CITED1 are often positive in PTC, and are therefore useful in differentiating benign thyroid proliferations from PTC. These markers have not been previously investigated in benign (BSO) or malignant (MSO) struma ovarii.

**Design:** The purpose of this study was to investigate the utility of HBME1, Galectin3, and CITED1 antibodies in identifying MSO with PTC features. We evaluated the 3 antibodies in 6 cases of MSO (4 follicular variants (FVPTC), 1 classical, 1 metastasis (classical) that metastasized) and 11 cases of BSO using traditional immunostaining techniques on paraffin embedded tissue.

**Results:** The immunostain results are reported in Table 1. 100% of the MSO were positive for HBME1 and either Galectin3 or CITED1. The staining pattern of MSO correlated with histologic subtype: Galectin3 staining correlated with classical PTC, and CITED1 staining correlated with FVPTC. Rare BSO were positive for either HBME1 or Galectin3, but not both markers.

**Conclusions:** Distinguishing malignant tumors in an ovarian teratoma with abundant thyroid tissue can be extremely difficult, especially if the nuclear changes of PTC are minimal and/or focal. These study results suggest that combined immunostains for HBME1, Galectin3, and CITED1 may be useful in identifying malignancy within SO.

Table 1: Immunohistochemical staining patterns of Malignant Struma Ovarii

MSO	Histopathology	HBME1	Galectin3	CITED1 <sup>1</sup>
MSO 1	FVPTC	+ (S, D)	- (C)	+ (S N; D Y)
MSO 2	FVPTC	+ (S, D)	- (C)	+ (weak N; D Y)
MSO 3	FVPTC	+ (S, D)	- (F)	+ (S N; D Y)
MSO 4	FVPTC	+ (D)	- (F)	+ (S N; D Y)
MSO 5	PTC	+ (S, D)	+ (S, D)	- (D Y)
MSO 6	PTC, metastatic	+ (S, D)	+ (S, D)	- (D Y)
Summary of MSO (+/total)		6/6	2/6	4/6
Summary of Benign Struma Ovarii (+/total)		1(very focal, BSO 4)/11	1(focal, BSO 5)/11	0/11 <sup>2</sup>

Key: FVPTC: features of follicular variant papillary thyroid carcinoma; PTC: features of classical papillary thyroid carcinoma; S-strong; D-diffuse; C-scattered cells; F-focal; N-scattered nuclei; Y-cytoplasm. <sup>1</sup> Nuclear staining was interpreted as positive. <sup>2</sup>All cases of BSO demonstrated weak diffuse cytoplasmic staining, but no nuclear staining was detected.

#### 945 BRAF, RAS, and RET Mutations in Malignant Struma Ovarii: A Comparative Study with Benign Struma Ovarii

JF Schmidt, M Heinrich, VDerr, CL Corless, JA Fletcher, V Nosé. Brigham & Women's Hospital, Harvard Medical School, Boston, MA; Oregon Health & Sciences University, Portland, OR.

**Background:** Malignant struma ovarii (MSO) are rare tumors that arise from teratomatous thyroid tissue of the ovary. Case reports of MSO suggest that papillary histology is more common than follicular histology. Activating point mutations in either BRAF (35-69%) or RAS (10%) and activating RET rearrangements (5-30%) are mutually exclusive oncogenic mechanisms in papillary thyroid carcinoma (PTC). These alternate mutation targets correlate with tumor subtypes, patient age, and clinical behavior. Intriguing relationships with mutation type are also seen in ovarian tumors, where BRAF mutations are found in up to a third of low-grade serous neoplasms, K-RAS mutations in both low and high grade neoplasms, and RET rearrangements in a subset of serous surface papillary carcinomas. Based on these observations, we hypothesized that BRAF, RAS, RET mutations might have pathogenic roles in malignant and benign struma ovarii.

**Design:** We analyzed genomic DNA from 6 paraffin embedded cases of MSO with histopathologic features of PTC (4 follicular variants, 1 classical, and 1 metastasis of a classical) and 10 benign counterparts (BSO) for mutations in BRAF, N-RAS, K-RAS, and RET. BRAF, N-RAS, and K-RAS mutations were evaluated using a combination of PCR, denaturing high performance liquid chromatography, and automated sequencing. Screening for RET mutations was performed by FISH with multicolor probes to detect RET rearrangement generally and H4-RET fusion specifically. Where available, benign elements, either teratoma or ovary, were evaluated in the malignant cases with mutations.

**Results:** BRAF mutations were present in 4 of 6 MSO, but were not found in 10 BSO. The BRAF mutations included V599E (2 cases), K600E, and deletion/substitution TV598-599M. Benign elements of these tumors, available in 3 cases, were found to be wild-type for BRAF. Neither MSO or BSO had mutations in N-RAS, K-RAS, or RET.



**Conclusions:** The development of papillary-type carcinomas in struma ovarii is associated with *BRAF* mutations that are similar to those commonly observed in PTC, suggesting that MSO is histologically and genetically related to primary PTC. In contrast, mutations in the *RET/RAS/RAF* pathway are not found in benign struma ovarii. Additional studies are needed to determine if *BRAF* mutation status predicts aggressive behavior in MSO as it does in primary PTC.

#### 946 Over-Expression of the Human Septin *SEPT9* in Borderline and Malignant Ovarian Epithelial Tumours

*M Scott, SEH Russell, PA Hall.* Queen's University Belfast, Belfast, Northern Ireland, United Kingdom.

**Background:** Mutational analysis of ovarian epithelial tumours suggests that two distinct types of tumour can be defined i.e. type I progressive tumours exhibiting *KRAS/BRAF* mutations (benign, borderline and low-grade serous carcinoma) and type 2 *de novo* tumours demonstrating *TP53* mutations (high-grade serous carcinoma). The novel cytoskeletal septin *SEPT9* was recently shown to map to a region of allelic imbalance on chromosome 17q25.3 in sporadic ovarian carcinomas. Several lines of evidence indicate that *SEPT9* may be implicated in neoplasia as a type II cancer gene where alterations in levels of expression are key. Similar to other septins, *SEPT9* has a complex genomic architecture with 18 splice variants and 15 isoforms. However, information on expression patterns of *SEPT9* mRNA in human tissue is sparse.

**Design:** A semiquantitative splice variant-specific RT-PCR strategy was optimised using anonymised formalin-fixed paraffin-embedded tissues. A quantitative real-time RT-PCR assay applicable to archival tissue samples was also developed using intron-spanning primer pairs to generate amplicons <100bp in length. Laser microdissection was coupled with qRT-PCR to quantify expression of *SEPT9* splice variants in epithelial and stromal compartments of ovarian tumours.

**Results:** Expression of *SEPT9* mRNA was ubiquitous in a panel of normal adult archival tissues. Quantitative analysis of a series of ovarian epithelial tumours showed statistically significant over-expression of two splice variants in borderline and malignant epithelial tumours (low- and high-grade) with highest expression in serous borderline tumours ( $p < 0.05$ ). Expression in low-grade serous carcinomas was higher than in high-grade serous carcinomas. Microdissection-based qRT-PCR demonstrated increased expression of both splice variants in epithelial compartments within borderline and malignant ovarian tumours.

**Conclusions:** Although ubiquitously expressed, *SEPT9* demonstrates consistent patterns of over-expression of specific splice variants in ovarian neoplasms, particularly borderline tumours. Expression of these splice variants is predominantly epithelial in ovarian tumours. These observations provide further support for a dichotomous molecular classification of ovarian epithelial tumours and strengthen the implication of *SEPT9* in neoplasia.

#### 947 The Recurrence Rate of Ovarian Serous Borderline Neoplasms with Noninvasive Implants Is Time Dependent

*EG Silva, DM Gershenson, A Malpica, MT Deavers.* M D Anderson, Houston, TX.

**Background:** Ovarian serous borderline neoplasms with noninvasive implants have been considered by most authors to be non-aggressive tumors with an excellent prognosis. We designed this study to test our hypothesis that this is a misconception based on the study of cases with short follow-up.

**Design:** The files of our Pathology department were searched for cases of serous borderline tumor, high stages, with noninvasive implants that had a minimum follow-up of 5 years (yrs). We excluded the following cases: patients (pts) treated with cystectomy, pts who died of other causes, pts who developed other tumors, pts with only a positive second look operation, and pts who were lost to follow-up.

**Results:** Eighty pts were included in the study. The age of the pts ranged from 17 to 67 yrs (median 36 yrs). Twenty-nine pts had stage II disease, 50 had stage III, and one pt had stage IV. Fifty-eight pts were treated with chemotherapy, seven with radiotherapy and one with hormonal therapy. The follow-up ranged from 5 to 31 yrs (median 15.7 yrs). Thirty-five pts (44%) developed recurrences. Only 10% of pts recurred in less than 5 yrs, 19% recurred between 5 and 10 yrs, 10% between 10 and 15 yrs, and 5% in more than 15 yrs after resection of the primary neoplasm. There were no clinical or pathologic features strongly associated with recurrence; however, in the cases that recurred, 70% had stage III and 26% had micropapillary pattern, while in the cases that did not recur, 56% had stage III and 4% had micropapillary pattern. Of the 35 pts who had recurrences, 2 were diagnosed clinically, both are alive with progressive disease at 1 and 5 yrs after recurrence; 6 had recurrent serous borderline tumors, all are without evidence of disease between 3 to 14 yrs after recurrence (median 9 yrs); and in 27 pts the disease recurred as low grade serous carcinoma, 7 of these pts are alive with progressive disease between 2 to 12 yrs (median 4 yrs) and 20 died of disease between 1 to 18 yrs after recurrence (median 3 yrs).

**Conclusions:** (1) The true recurrence rate of serous borderline tumors with noninvasive implants can only be obtained with long follow-up; 77% of recurrences occur after 5 yrs and 34% occur after 10 yrs. (2) It is very important to document the type of tumor in the recurrence. All pts who recurred with borderline tumor are without evidence of disease. However, 77% of the pts recurred with low-grade serous carcinoma, and 74% of them had progressive disease and ultimately died of the disease.

#### 948 Dedifferentiated Endometrioid Carcinoma

*EG Silva, MT Deavers, D Bodurka, A Malpica.* M D Anderson Cancer Center, Houston, TX.

**Background:** Low-grade endometrioid carcinoma (ca) usually has an excellent prognosis. The association of this type of tumor with undifferentiated carcinoma is rare with no documentation of this event in the literature thus far.

**Design:** Thirty-four cases of undifferentiated carcinoma associated with endometrioid carcinoma, grades 1 or 2 were obtained from our consultation files over a period of 6 years. In nine cases the clinical or pathology material was incomplete. The remaining 25 cases are the basis of this study; all had complete clinical information and pathology material. In 15 cases immunohistochemical studies were performed for keratin and EMA.

**Results:** The age of the patients (pts) ranged from 30 to 82 years (median 51). Eleven pts had stage I disease, one stage II, 7 stage III, and 6 pts stage IV. The endometrioid ca involved the endometrium in 14 cases, and the endometrium and one or both ovaries in 11 cases. High grade undifferentiated ca was found at presentation, associated with grade 1 or 2 endometrioid ca, in 19 cases (14 in the endometrium and 5 in the ovary), and following resection of the endometrioid ca in 6 cases, involving the retroperitoneum, pelvis, or abdominal wall. The undifferentiated ca was composed of solid nests of epithelioid cells in 10 cases; isolated foci of keratinization were seen in 9 cases, and groups of rhabdoid cells with myxoid changes were seen in 6 cases. Immunohistochemistry demonstrated keratin expression in 13 of 15 cases and EMA was positive in all 15 cases. After resection of the tumor, 15 pts were treated with chemotherapy, four with radiotherapy, one with Tamoxifen, and five received no further treatment. Follow-up showed that 15 pts died of disease in 1 to 60 months (median 6 months) and six pts are alive with progressive disease. Three are recent cases, and only one patient is alive with no evidence of disease at 104 months.

**Conclusions:** It is very important to recognize this extremely aggressive type of previously unreported ca in order to treat the pts accordingly. In asynchronous cases, being aware of the concept of dedifferentiation can explain the absence of another primary. In synchronous cases, foci of dedifferentiation may be confused with solid endometrioid adenocarcinoma erroneously leading to the diagnosis of a significantly less aggressive grade 2 endometrioid ca.

#### 949 Patterns of p53 Mutations Separate Ovarian Serous Borderline Tumors, Low and High-Grade Carcinomas and Provide Support for a New Model of Ovarian Carcinogenesis

*G Singer, RJ Kurman, R Dehari, I-M Shih.* Johns Hopkins Medical Institutions, Baltimore, MD.

**Background:** The infrequent association of serous borderline tumors (SBTs) with invasive serous carcinoma has led to the view that SBTs are unrelated to invasive serous carcinoma. Previous immunohistochemical studies and mutation analysis evaluating mutational status have reported that p53 overexpression and mutations are infrequent in SBTs and occur in as many as 50-80% of invasive serous carcinomas. The different methodologies for determining p53 status and the failure to correlate the findings with tumor grade make these studies difficult to interpret. The current study was undertaken to overcome these deficiencies and to reconcile the relationship of SBTs to invasive serous carcinoma by performing a morphologic and molecular genetic analysis.

**Design:** The molecular genetic analysis employed a highly stringent, carefully designed nucleotide-sequencing method. A total of 96 sporadic serous tumors including 25 SBTs (11 atypical proliferative serous tumors and 14 intraepithelial low-grade serous carcinomas [non-invasive micropapillary serous carcinomas (MPSCs)]), 12 low-grade serous carcinomas (invasive MPSCs) and 59 high-grade serous carcinomas were analyzed for their p53 mutational status of exons 5-9.

**Results:** Functional mutations were detected in 30 of 59 (50.8%) high-grade serous carcinomas and one (8.3%) of 12 low-grade invasive serous carcinomas compared to 2 (8%) of 25 SBTs, both of these in intraepithelial low-grade serous carcinomas (non-invasive MPSCs). The similar frequency of p53 mutations in SBTs and low-grade invasive serous carcinomas in contrast to the significantly higher frequency of p53 mutations in high grade serous carcinomas ( $P < 0.0005$ ) suggests a common lineage for SBTs and low-grade invasive serous carcinomas and supports the view that SBTs are unrelated to the usual type of invasive serous carcinoma which is a high-grade neoplasm.

**Conclusions:** The above findings confirm our hypothesis of dual pathways of serous carcinogenesis based on previous analyses of *KRAS* and *BRAF* mutations on the same set of cases in which *KRAS* and *BRAF* mutations were found in 60% of SBTs and low-grade serous carcinoma but not in high-grade serous carcinomas. Based on these studies we have proposed a model of serous carcinogenesis in which SBTs are the precursors of low-grade serous carcinomas whereas the usual type of invasive serous carcinoma is a high-grade neoplasm that develops "de novo" from in situ alterations in epithelial inclusion cysts.

#### 950 Retrograde Transtubal Spread in Extra-Uterine Metastasis of Uterine Serous Carcinoma

*MJ Snyder, RC Bentley, C Lutman, SJ Robboy.* Duke University Medical Center, Durham, NC.

**Background:** Most endometrial carcinomas metastasize by invading myometrial lymphatics and spreading to regional lymph nodes. Uterine serous carcinomas, however, frequently metastasize to peritoneal surfaces even when only minimally invasive. This study examines the potential role of retrograde transtubal spread.

**Design:** 87 endometrial serous carcinomas treated by hysterectomy were identified, excluding cases with significant ovarian involvement. The presence of metastasis was compared with the presence of lymphatic/vascular (LV) invasion, depth of myometrial invasion and presence of tumor clusters in fallopian tube lumen.

**Results:** 62% (54/87) had extra-uterine spread at hysterectomy, most commonly to peritoneum, lymph nodes, and ovary. 20% (11/54) of patients with peritoneal metastases lacked both myometrial and LV invasion. Three of these patients had tumor clusters in the fallopian tube lumen ( $p < 0.01$ ). Another 13 cases with myometrial or LV invasion also had clusters of tumor within the fallopian tube lumen, and all 16 cases had extra-uterine spread ( $p < 0.001$ ). LV invasion correlated highly with extra-uterine spread ( $p < 0.001$ ), but not with the presence or depth of myometrial invasion.

**Conclusions:** Retrograde transtubal spread is an important mechanism by which uterine serous carcinoma metastasizes, evidenced by all cases with tumor in the tube lumen having extra-uterine spread. This appears independent of LV invasion, which in the hysterectomy specimen is a strong predictor itself of having extra-uterine spread, regardless of the depth of myometrial invasion.

### 951 The Distribution of Low and High Risk HPV Types in Vulvar Intraepithelial Neoplasia (VIN)

*M Srodon, MH Stoler, GB Baber, RJ Kurman.* The Johns Hopkins Medical Institutions, Baltimore, MD; University of Virginia Health System, Charlottesville, VA.

**Background:** It has been proposed that VIN 1 lesions are flat condylomas and should be designated as such. Moreover, their relationship to high grade vulvar intraepithelial neoplasia (VIN 3) is unclear. Accordingly this study was undertaken to address these issues by comparing the distribution of HPV types in VIN 1 and VIN 3.

**Design:** Cases of VIN 1 and VIN 3 were identified from The Johns Hopkins Hospital surgical pathology archives from 1989 to 2003. 33 cases of VIN 1 and 34 cases of VIN 3 were reviewed independently by two of the investigators (RJK and MHS). Blocks were chosen for PCR using both the Roche and SPF 10 systems. An H&E from each block was made before and after the sections taken for PCR in order to assure that lesion analyzed by PCR was present.

**Results:** VIN 1 cases with extensive koilocytic atypia (11 cases) versus those with minimal koilocytic atypia (22 cases) showed no statistical difference in the distribution of HPV types and therefore they were combined. Of the VIN 1 cases, 30 (91%) of 33 had detectable HPV. Low risk virus was seen in 22 (67%). Among these, HPV 6 or 11 accounted for 14 (42%), while the remainder included HPV's 32, 40, 44, 54, 61, 70, 72, 84, and 91. High risk virus was detected in 14 (42%) of VIN 1. Only 2 (6%) had HPV 16, while the remainder contained HPV's 31, 33, 51, 52, 53, 58, 59, 66, and 68. Of the VIN 1 cases, 23 (70%) had a single HPV virus and 7 (21%) had multiple HPV types. All 34 cases of VIN 3 contained high risk HPV's. One of these also had a low risk virus (HPV 11). The high risk types were 16, 18, 33, 35, 51, 52, and 68 of which 31 (91%) of 34 cases contained HPV 16. In VIN 3, 30(88%) cases were associated with a single HPV type and 4 (12%) contained multiple types. When comparing VIN1 and VIN 3, statistical significance was noted for multiple factors using Fisher's Exact Test, including the number with low risk virus, high risk virus, HPV16 and HPV's 6 or 11 ( $p < 0.0001$ ). The number of cases with a single HPV type or multiple HPV types was not statistically significant.

**Conclusions:** VIN 1 and VIN 3 are distinct lesions with little overlap of HPV types. Only 2 cases (6%) of VIN 1 had HPV 16 in contrast to 32 (94%) of VIN 3 which contained HPV 16. The findings argue against the progression of VIN 1 to VIN 3 lesions. Nonetheless, since 42% of VIN 1 contained other high risk HPV types, these lesions should be designated low grade VIN rather than flat condyloma.

### 952 The Distribution of Low and High Risk HPV Types in Vaginal Intraepithelial Neoplasia (VaIN)

*M Srodon, RJ Kurman, GB Baber, MH Stoler.* The Johns Hopkins Medical Institutions, Baltimore, MD; University of Virginia Health System, Charlottesville, VA.

**Background:** It has been proposed that VaIN 1 lesions are flat condylomas and should be designated as such. Moreover, their relationship to high grade vaginal intraepithelial neoplasia (VaIN 3) is unclear. This study was undertaken to clarify these two issues by comparing the distribution of HPV types in VaIN 1 and VaIN 3.

**Design:** Cases of both VaIN 1 and VaIN 3 were identified from The Johns Hopkins Hospital surgical pathology archives from 1989 to 2003. 17 cases of VaIN 1 and 16 cases of VaIN 3 were reviewed independently by two of the investigators (RJK and MHS). Blocks were chosen for PCR using both the Roche and SPF 10 systems. An H&E from each block was made before and after the sections taken for PCR in order to assure that lesion analyzed by PCR was present.

**Results:** All 17 cases of VaIN 1 had detectable HPV. Low risk virus was detected in 6 (35%) including types 42, 43, 54, 62, 67, and 81. HPV 6 and 11 was not found. High risk virus was seen in 13 (76%), of which HPV 16 was identified in 1 (6%) and HPV 18 was identified in 4 (24%). Additional high risk HPV types included 39, 51, 52, 56, 58, 66 and 67. When comparing multiple versus single viral infections, 12 (71%) of the VaIN 1 lesions contained a single HPV type and 5 (29%) contained multiple HPV types. In VaIN 3, HPV was detected in 15 (94%) of 16. All had high risk virus and one also contained a low risk HPV type (CP6108). Eight (50%) contained HPV 16. Additional types included 31, 35, 51, 52, 58, and 66. HPV 18 was not found. Of the VaIN 3 lesions, 13 (81%) contained a single HPV type and 2 (13%) contained multiple HPV types. There were no striking differences comparing VaIN 1 and VaIN 3 for multiple features, including the presence of low risk virus, high risk virus, single infections and multiple infections. Using Fisher's Exact Test, the number of cases associated with HPV 16 was statistically significant ( $p = 0.0066$ ).

**Conclusions:** The proportion of high risk HPV in the vagina more closely resembles the distribution in the cervix compared to the vulva. Although this suggests that VaIN 1 may progress to VaIN 3, the 6% prevalence of HPV 16 in VaIN 1 and the 50% prevalence of HPV 16 in VaIN 3 does not support this conclusion. The reciprocal distribution of HPV 18 in VaIN 1 (24%) and VaIN 3 (0%) is also puzzling. As in the cervix and vulva, the presence of high risk HPV types in low grade lesions supports their designation as low grade VaIN rather than flat condyloma.

### 953 Increased Expression of the p110alpha Catalytic Subunit of PI3K and Genomic Gain of PIK3CA Have Different Impact on Clinical Prognosis, and Are Associated with Different Morphological Subgroups of Ovarian Serous Neoplasia

*A Staebler, O Buchweitz, B Karberg, J Behm, H Schmidt.* University of Muenster, Muenster, Germany.

**Background:** Phosphatidylinositol 3'-kinase (PI3K) has been implicated as an oncoprotein in ovarian carcinogenesis by several studies based on in-vitro experiments and the genomic gains in the region of chromosome 3q26. However, the prognostic significance of these parameters in serous carcinomas and association with different subgroups of serous neoplasia of the ovary has not been determined.

**Design:** 99 cases of serous tumors of the ovary (11 borderline, 10 low-grade, 78 high-grade invasive carcinomas) were analyzed by immunohistochemistry in a tissue microarray for expression of p110alpha, phosphoAkt (pAkt, downstream target of PI3K) and proliferation marker Ki67. DNA was extracted after microdissection. Gene dose of PIK3CA was determined by Taqman PCR. Comparative genomic hybridization (CGH) was used to determine the frequency of chromosomal gains and amplifications in 3q26 and other chromosomal aberrations. Clinical follow up was available in 87 cases (max. 114 months, median 30 months after time of operation).

**Results:** Increased expression of p110alpha protein (score 2 or 3) was observed in 5 of 11 cases of borderline tumors, 9 of 10 low-grade carcinomas, 48 of 60 high-grade carcinomas. Strong and diffuse expression (score 3) was observed in none of the borderline tumors, 3 of 10 low-grade carcinomas and 11 of 60 high-grade carcinomas. It was associated with expression of pAkt and a shorter disease free survival for patients with invasive carcinomas in Kaplan Meier Analysis (mean 14 versus 46 months,  $p = 0.015$ ). Gains in PIK3CA by gene dose PCR showed a significant correlation with chromosomal gains in 3q26, with proliferative index and tumor grade (none of 11 borderline, one of 10 low-grade and 29 of 78 high grade carcinomas). However, there was no correlation with expression of p110alpha and no impact on disease free survival or overall survival.

**Conclusions:** Increased p110alpha protein expression occurs in borderline tumors, low-grade and high-grade serous carcinomas, independently of genomic gains, and is a potential prognostic marker in invasive serous carcinoma. However, genomic gains of the corresponding gene PIK3CA, do not influence clinical outcome. Nevertheless, they are significantly associated with high-grade carcinomas, suggesting a specific role for genomic gains of PIK3CA in the tumorigenesis of this group of highly malignant tumors.

### 954 The Frequency and Biology of Multiple HPV Infection in Vulvar Neoplasia

*MH Stoler, M Srodon, GB Baber, RJ Kurman.* University of Virginia Health System, Charlottesville, VA; Johns Hopkins Medical Institutions, Baltimore, MD.

**Background:** The frequency of finding multiple human papillomavirus (HPV) types in a single lesion varies with the method of sampling and detection method. A small biopsy exhibiting a single pathology might be expected to have only a single virus present. When more than one virus is detected in a lesion, are both viruses active? If so, are they fused lesions or is there more than one virus in a single cell? How does the presence of more than one virus influence the pathology?

**Design:** To address these questions, 100 vulvar and vaginal biopsies were analyzed by PCR for multiple HPV DNA types. Most lesions were discrete single areas of abnormality with consensus diagnosis of vulvar or vaginal intraepithelial neoplasia (VIN or VaIN) by two independent observers. PCR included line blot typing using both the PGMY and SPF 10 systems. In situ hybridization (ISH) for HPV messenger RNA was performed to detect viral gene expression in the context of morphology.

**Results:** 18/100 (18%) of biopsies had evidence of more than one HPV DNA type by PCR using the combined results of both amplification methods. This included 7/33 (21%) VIN1, 4/34 (12%) VIN3, 5/17 (29%) VaIN1 and 2/16 (13%) VaIN3. There were 11 double infections, 3 triples and 3 cases with 4 HPV types detected. Overall, 21 different HPV's were detected. All cases had at least one high risk HPV type present, regardless of lesion grade. 13/18 cases had adequate tissue for ISH and probes for HPV 6, 11, 16, 18, 31, 33 and 59 were available. A single HPV RNA type was expressed in 4 of 5 evaluable cases. One case had either co-expression or weak cross reactivity between type 18 and type 33. The expression patterns did not support an interpretation of lesion fusion.

**Conclusions:** Even using sensitive broad-spectrum HPV DNA typing methods, multiple infection of discrete vulvar lesions is a relatively rare event occurring in less than one fifth of lesions. The frequency of multiple infection is higher in grade I than grade III lesions. When multiple infection is present, most resultant lesions are not fused lesions. Rather, the data suggest that more than one virus is in the cell but only one type is transcriptionally active and pathogenic.

### 955 Quality Control of Cervical Biopsy Diagnoses: A Report from the Merck Vaccine Trials

*MH Stoler, K Liaw, B Ronnett, A Ferenczy, RJ Kurman, B Cai, D Sadov, F Alvarez, E Barr.* University of Virginia Health System, Charlottesville, VA; Johns Hopkins Medical Institutions, Baltimore, MD; McGill University, Montreal, QC, Canada; Merck Research Laboratories, Blue Bell, PA.

**Background:** Within clinical trials, end point determination is crucial to establishing efficacy. In the human papillomavirus (HPV) vaccine trials, the critical end point is the development of HPV type specific cervical intraepithelial neoplasia (CIN). This diagnosis is determined by an expert panel review of all biopsy tissues. To monitor expert panel performance over time, a quality control (QC) program was established. This report describes the process and establishes its efficacy and validity.

**Design:** A total of 250 QC slides were selected from a non-clinical trial protocol, prepared identically as in the clinical trials. A gold standard diagnosis had been established for each QC slide based on each of the 4 panelists reaching unanimous agreement on the diagnosis for each slide. A small minority of slides without unanimous agreement diagnosis were reviewed at a consensus meeting where the gold standard was jointly determined by all panelists. A different batch of about 30 QC slides was interspersed among clinical trial slides each quarter for review. The panelists were completely unaware of which slides were the quality control slides. Because of the pre-established gold standard, validity (sensitivity and specificity) of each panelist's diagnosis can be evaluated. Reproducibility is also evaluated by comparing each panelist's pre- and post-gold standard diagnoses.

**Results:** The distribution of diagnoses in the QC slides included 38.6% normal, 10.8% CIN1, 18.3% CIN2 and 33.3% CIN 3. Compared to the distribution in the clinical trial, this slide set was enriched in abnormal and problematic diagnoses. Agreement between individual panelists vs. the gold standard ranged from 89.3 to 95.7% for a cutpoint of CIN 2 and 91.4 to 97.9% for CIN 1. Sensitivity, specificity were similarly high ranging from 85-100%. Intra-observer reproducibility ranged from 90-99%. At all levels there was a slightly higher tendency to upgrade vs. downgrade slides by each individual. **Conclusions:** It is possible to achieve high reproducibility and consistency in cervical biopsy diagnosis. Masked and seeded gold standard slides permit objective QC evaluation of ongoing diagnostic performance in clinical trials. A similar system might be applicable to QC of clinical practice

### 956 Reproducibility of Cervical Biopsy Diagnoses: A Report from the Merck Vaccine Trials

*MH Stoler, K Liaw, B Ronnett, A Ferenczy, RJ Kurman, B Cai, D Sadow, F Alvarez, E Barr.* University of Virginia Health System, Charlottesville, VA; Johns Hopkins Medical Institutions, Baltimore, MD; McGill University, Montreal, QC, Canada; Merck Research Laboratories, Blue Bell, PA.

**Background:** Previous studies on reproducibility of cervical neoplasia diagnosis are limited in size and methodology. Diagnostic reproducibility has important implications in a variety of settings, including routine care, clinical trials and medicolegal cases. The present study examines the degree of reproducibility between multiple observers utilizing cervical biopsies from patients in the human papillomavirus (HPV) vaccine trials.

**Design:** 1960 cervical bxs. were analyzed at a central laboratory (CL) as well as by an expert pathology panel of four pathologists (QC). While clinical management was dictated by CL interpretation, endpoint classification was determined by QC. This required masked diagnostic agreement by at least two panelists. Hierarchical review of QC disagreements led to ultimate truth determination for every case. Rates of agreement and kappa statistics were analyzed. Interpretations were correlated with trial results and HPV testing.

**Results:** The overall agreement between QC and CL was 54.5%. The least reproducible categories included cervical intraepithelial neoplasia grade 1 (CIN 1), atypical immature metaplasia (AIM) and CIN 2 with 21% (179/852), 1.5% (1/66) and 36% (47/132) of diagnoses respectively being supported by QC. Average number of diagnoses to reach consensus was higher for CIN2 (2.9) compared to CIN1, CIN 3 or normal (2.1-2.4). There was significantly less variability within QC than between QC and CL. Mean QC kappas ranged from 0.53 to 0.69. In contrast, kappas comparing QC to CL were significantly lower and more variable. Although there is variation in both groups, HPV typing data and trial outcomes provided independent validation of the QC interpretations.

**Conclusions:** Interpretation of cervical biopsies can be quite variable. Diagnoses of CIN 1 are problematic with a strong tendency for this diagnosis to be used on cases that are biologically normal. AIM is a highly variable category. Defining CIN 2 is also difficult as most cases biologically represent CIN 3 or CIN 1. Although individual interpretations are subjective, some are obviously more valid than others and can be applied with excellent reproducibility in that they correlate better with independent biological assessments such as HPV typing and vaccine response.

### 957 Expression of ERK1/2 and EGFR and Their Relationship with Survival: A Study of 90 Cases of Ovarian Epithelial Tumors

*G Toledo, JI Echeveste, M Collantes, A Martinez-Penuela, A Panizo, J Pardo.* Clinica Universitaria. Universidad de Navarra, Pamplona, Navarra, Spain.

**Background:** Ovarian carcinoma is the leading cause of death among all gynecologic malignancies, with a 5-year poor survival rate. Activation of the extracellular-regulated kinase (ERK1/2) pathway is involved in malignant transformation of cells. Little is known about the role of activated ERK1/2 in ovarian carcinomas. Epidermal growth factor receptor (EGFR) overexpression is usually described as linked with a worse prognosis in a variety of tumours of epithelial origin. However, its role in ovarian cancer is still controversial. The purpose of this study was to characterise the extent of the activation of ERK1/2 and EGFR expression by immunohistochemistry in a series of 90 ovarian cancer, and to determine their role in the biology of ovarian carcinoma, and their correlation with clinicopathological variables.

**Design:** Specimens from 90 patients with ovarian carcinomas with stages I-IV (51 serous, 8 mucinous, 11 endometrioid, 4 clear cells and 2 mixed epithelial tumor) and 14 borderline tumors (6 serous type, 6 mucinous, 1 endometrioid and 1 clear cells tumor) were stained for antibody against ERK1/2, EGFR and ki67. Survival analysis was performed in all cases.

**Results:** In all, 33.3% of the tumour specimens showed activation for ERK1/2. EGFR expression was observed in 65.6% of the cases. EGFR and ERK expression were significantly less common in borderline tumors (14.3% and 1%) than in carcinomas (40.0% and 14.3%) ( $p < 0.05$ ). There was a statistical correlation between ERK staining

and advanced stages ( $p < 0.05$ ). No correlation was found between EGFR expression and clinical parameters. We did not find correlation of ERK staining with either EGFR or ki-67 expression. Statistical analysis did not show significant survival difference between tumors with ERK or EGFR expression.

**Conclusions:** Our results indicate that ERK1/2 activation positively correlates with stage, and both EGFR and ERK are associated with more invasive tumors. However, EGFR and ERK overexpression had no prognostic impact on survival in this series of ovarian tumors.

### 958 Endometrial Calcifications: Histopathologic and Clinical Background

*AM Truskinovsky, EO Gerscovich, CR Duffield.* University of California, Davis, Sacramento, CA.

**Background:** Endometrial calcifications are uncommon, with alleged clinical implications ranging from innocuous to ominous. The histopathologic and clinical background of the endometrial calcifications discovered incidentally during pelvic ultrasonography has not been characterized.

**Design:** Histologic slides of the available uterine specimens of the patients diagnosed with endometrial echogenic foci by pelvic ultrasound were reviewed. The extent of calcifications in each specimen was graded on a semiquantitative scale from 0 to 3. The patients' clinical notes were reviewed.

**Results:** During a period of 3 years, 63 patients were found to have endometrial echogenic foci on pelvic ultrasonography. Of these, 29 patients (46%), with a mean age of 54 years (range 34-81), had a total of 43 uterine histopathologic specimens, including biopsies, curettages, and hysterectomies. Most of them (83%) presented with abnormal vaginal bleeding. Fifteen patients (51.7%) were postmenopausal, 10 (34.5%) were premenopausal, the rest perimenopausal. The most frequent endometrial types were atrophic (39.5%), inactive (23.3%), and proliferative (14%). Six specimens (14%) showed benign endometrial polyps. One patient had well differentiated endometrioid carcinoma of the endometrium without myometrial invasion. Specimens from sixteen patients (55.2%) were found to have calcifications. The patients with calcifications were older than those without calcifications (mean age 60 vs. 47 years, respectively,  $p = 0.004$ ). The extent of calcifications positively correlated with the presence of endometrial polyps ( $p = 0.00004$ ), postmenopausal state ( $p = 0.00008$ ), atrophic endometrium ( $p = 0.001$ ), and tubal metaplasia of the endometrium ( $p = 0.04$ ). The calcification score did not correlate significantly with the presence of endometrial stromal breakdown or the type of procedure used to obtain the specimens. The endometrial calcifications were concentric or amorphous, intraglandular or stromal. They were focally associated with minute papillary epithelial projections or with degenerated glands. Unusual findings included a fragment of mineralized plant material, calcified degenerated blood, and a minute fragment of apparent bone. Follow-up was available on 26 patients (89.7%). Except for the patient with endometrioid carcinoma, none has developed uterine, adnexal, or peritoneal malignancy.

**Conclusions:** Endometrial calcifications are histologically heterogeneous. Those found incidentally by pelvic ultrasonography, in the experience of this study, usually did not portend malignancy.

### 959 Beta-Catenin Expression in Endometrial Carcinoma (EC) in Patients with Estrogen Stimulation Secondary to Ovarian Hyperthecosis or Tamoxifen Therapy

*J Turbiner, C Sanchez, S Dahiya, G Moreno, D Hardisson, J Palacios, E Oliva.* Massachusetts General Hospital, Boston, MA; Centro Nacional de Investigaciones Oncologicas, Madrid, Spain; Hospital Universitario La Paz, Madrid, Spain.

**Background:** Estrogen stimulation is a known risk factor for the development of endometrioid endometrial carcinoma (EEC) while  $\beta$ -catenin has been found to be involved in the pathogenesis of EEC with mutations ranging from 14 to 44%. *In vitro* experiments have shown that the expression of  $\beta$ -catenin is upregulated by estrogen, however, their relationship *in vivo* remains controversial. The aim of our study was to seek any possible correlation between estrogens and  $\beta$ -catenin expression in patients with EC with known estrogen stimulation of the endometrium related to ovarian hyperthecosis (OH), adult granulosa cell tumor (AGCT), or tamoxifen therapy.

**Design:** Thirty one cases of EC were selected; 15 associated with OH, 1 with an AGCT and 15 from patients treated with tamoxifen for breast cancer. IRB approval was obtained from the institution. Formalin-fixed, paraffin-embedded tissues were immunostained with  $\beta$ -catenin, microdissected, DNA extracted and amplified by PCR with primers for the  $\beta$ -catenin gene. Sequence analysis of exon 3 was performed.

**Results:** Patients ranged in age from 39-84 (mean 63) years; 39-84 (mean 60) years in the OH group, 53-84 (mean 66) years in the tamoxifen group, while the patient with an AGCT was 65 years old. In the tamoxifen group, treatment lasted from 6 to 72 months; there were 12 EECs (9 grade 1, 2 grade 2 and 1 grade 3), 1 EEC + serous carcinoma, 1 serous, and 1 clear cell carcinoma. All patients with OH had EEC (11 grade 1 and 4 grade 2). The patient with an AGCT had a grade 1 EEC. Immunohistochemical analysis for  $\beta$ -catenin showed nuclear staining in 3/12 informative EECs in the tamoxifen group (2 grade 1 and 1 grade 2), 6/15 EECs in the OH group (3 grade 1 and 3 grade 2), and in the EEC associated with AGCT, the rest showed membranous staining.  $\beta$ -catenin mutations were found in 2/10 informative EECs in the tamoxifen group (both grade 1 and with nuclear staining), in 3/13 EECs in the OH group (1 grade 1 and 2 grade 2, all with nuclear staining), and in the EEC associated with the AGCT.

**Conclusions:** The frequency of  $\beta$ -catenin mutations in this selected group of patients is similar to that seen in random studies of patients with EC. These findings indicate that there is no definitive correlation between estrogen stimulation secondary to OH or tamoxifen therapy and mutational status of  $\beta$ -catenin.

**960 C-Met Expression in Different Types of Ovarian Epithelial Tumors**

*M Turkyilmaz, M Tretiakova, T Krausz, E Lengyel, A Montag.* University of Chicago Hospitals, Chicago, IL.

**Background:** The hepatocyte growth factor (HGF) receptor, c-met is a tyrosine kinase which plays an important role in tumor proliferation and invasion. Oncogenic c-met is overexpressed in several human cancers and ovarian cancer cell lines. The goal of this study was to evaluate the expression of c-met in ovarian epithelial tumors and extraovarian peritoneal serous carcinoma.

**Design:** 89 tissue cores including 80 ovarian epithelial tumors (table), 4 controls and 5 ovarian cancer cell lines were assembled into a tissue microarray block. Immunohistochemistry was performed using the Envision+ avidin-biotin free detection system. Two different antibodies (monoclonal and polyclonal, Zymed) recognizing the cytoplasmic domain of the molecule were used. Immunostaining intensity was scored as 0 (negative), 1+ (weak), 2+ (strong). Immunostaining patterns: cytoplasmic, membranous or both cytoplasmic and membranous were evaluated.

**Results:** 84% of ovarian epithelial tumors expressed c-met (19% weak, 65% strong). Results with both antibodies correlated (r=0.82). All tumor types with the exception of mucinous tumors showed either positive membranous or cytoplasmic and membranous staining, whereas mucinous tumors exhibited only cytoplasmic positivity. The expression pattern was diffuse in 85% of positive cases. The highest expression levels were seen in clear cell carcinoma (78%) followed by endometrioid type (56%). While the majority of ovarian serous cancers were strong (30.5%) or weakly (30.5%) positive, primary peritoneal serous carcinomas were in general c-met negative (86%) or only weakly positive (14%) (p<0.05). There were no differences in expression between primary tumors and metastases.

**Conclusions:** The very low expression of c-met in primary peritoneal cancer and the high expression in serous papillary carcinoma points to a different tumor biology of these cancer subtypes. Interestingly, clear cell carcinoma has the highest c-met expression making it a potential target for molecular therapy.

c-met expression in epithelial ovarian tumors

Tumor type	n=	n=	negative=	weak=	strong=
	primary	metastases	primary	primary	primary
clear cell	9	5	1 (11%)	1 (11%)	7 (78%)
papillary serous	13	6	5 (39%)	4 (30.5%)	4 (30.5%)
primary peritoneal serous	7	4	0	1 (14%)	6 (86%)
endometrioid	9	5	0	4 (44%)	5 (56%)
mucinous	3	1	0	1 (33.3%)	2 (66.6%)
borderline, mucinous	10	0	0	0	10 (100%)
borderline, serous	7	1	2 (29%)	1 (14%)	4 (57%)
total	58	22	8	12	38

**961 Ovarian Atypical Proliferative (Borderline) Mucinous Tumors: Gastrointestinal and Seromucinous (Endocervical) Types Are Immunophenotypically Distinctive**

*R Vang, AM Gown, TS Barry, D Wheeler, B Ronnett.* Johns Hopkins Hospital, Baltimore, MD; PhenoPath Laboratories, Seattle, WA; Quest Diagnostics, Inc., Las Vegas, NV.

**Background:** Ovarian atypical proliferative mucinous tumors (APMTs) of gastrointestinal (GI) and seromucinous (SM) types are grossly and microscopically distinctive. Immunophenotypic differences have not been extensively investigated.

**Design:** Immunohistochemical studies were performed to compare the expression patterns in 28 cases of APMT-GI and 9 cases of APMT-SM. Cases were scored based on the percentage of positive cells rather than intensity: negative (-) = ≤ 5%; low positive (low+) = 6-50%; high positive (high+) = > 50%.

**Results:** Percentages of cases (-/low+/high+) for each marker:

	CK7	CK20	CDX2	ER	PR	CA-125	Mesothelin
APMT-GI	7/21/71	14/54/32	61/36/4	100/0/0	100/0/0	89/11/0	93/7/0
APMT-SM	0/0/100	100/0/0	100/0/0	0/44/56	44/44/11	11/0/89	22/22/56

**Conclusions:** APMT-GI and APMT-SM are immunophenotypically distinctive tumors. They share expression of CK7, but APMT-GI are characterized by expression of additional gastrointestinal-type markers (CK20, CDX2) which are lacking in APMT-SM, whereas APMT-SM are characterized by expression of "mullerian-type markers" (ER, PR, CA-125, mesothelin) which are generally lacking in APMT-GI. The expression of the latter markers in APMT-SM, combined with their morphologic features, supports the concept that this subtype exhibits serous-type differentiation.

**962 CDX2 Versus CK20 and CK7 for Distinction of Primary Ovarian Mucinous Tumors from Metastatic Mucinous Carcinomas Involving the Ovary**

*R Vang, AM Gown, TS Barry, D Wheeler, B Ronnett.* Johns Hopkins Hospital, Baltimore, MD; PhenoPath Laboratories, Seattle, WA; Quest Diagnostics, Inc., Las Vegas, NV.

**Background:** Recent studies have demonstrated conflicting results regarding the value of CDX2 for distinguishing primary ovarian mucinous tumors from metastatic mucinous carcinomas in the ovary.

**Design:** Immunohistochemical studies were performed to compare the expression patterns of CDX2, CK20, and CK7 in 35 cases of primary ovarian mucinous tumors (OV; 28 atypical proliferative mucinous tumors of gastrointestinal type and 7 mucinous carcinomas) and 42 cases of metastatic mucinous carcinomas of gastrointestinal tract origin involving the ovary (upper GI [UGI]: stomach [4], pancreas [11], biliary tract [1]; lower GI [LGI]: colorectum [24], appendix [2]). Rigorous criteria were used to distinguish primary and metastatic tumors. Cases were scored based on the percentage of positive cells rather than intensity: negative (-) = ≤5%; positive (+) = >5%; low positive (low+) = 6-50%; high positive (high+) = >50%.

**Results:**

	CDX2+	CK20+	CK7+
OV (n=35)	43%	83%	94%
UGI (n=16)	75%	88%	81%
LGI (n=26)	85%	88%	12%

Using coordinate expression, OV were most often CK20+/CK7+ (77%) and CDX2-/CK7+ (57%); UGI were most often CK20+/CK7+ (69%) and CDX2+/CK20+ (69%) followed by CDX2+/CK7+ (63%); LGI were most often CDX2+/CK20+ (85%) followed by CK20+/CK7- (81%) and CDX2+/CK7- (77%). When positive, CK7 expression was most often high+ in OV and UGI, CK20 expression was most often low+ in OV but high+ in UGI and LGI, and CDX2 expression was most often low+ in OV but high+ in LGI and UGI. All combinations of coordinate expression were encountered, with the exception of CDX2+/CK20- in any group, CK20-/CK7- in UGI and OV, and CDX2-/CK7- in OV.

**Conclusions:** CDX2 appears to offer some advantage in distinction of OV from LGI and UGI compared to CK20 in that CDX2 is more often negative in OV than CK20. CK20 expression is nonspecific in general but is useful for distinction of OV from LGI when it is negative or low+ in conjunction with CK7 expression. CK7 provides the best distinction of OV from LGI (but not UGI). Some overlap in expression patterns in all 3 groups limits the specificity of these markers. Variant results for CDX2 in some studies might be related to inclusion of deceptive metastases in the primary ovarian mucinous tumor category.

**963 Estrogen (ER) and Progesterone Receptor (PR) Expression in Ovarian Mucinous Tumors: Utility for Distinction of Primary Tumors from Metastases**

*R Vang, AM Gown, TS Barry, D Wheeler, B Ronnett.* Johns Hopkins Hospital, Baltimore, MD; PhenoPath Laboratories, Seattle, WA; Quest Diagnostics, Inc., Las Vegas, NV.

**Background:** ER and PR expression in primary ovarian mucinous tumors and the utility of these markers for distinguishing mucinous carcinomas metastatic to the ovary from primary ovarian mucinous tumors have not been extensively investigated.

**Design:** Immunohistochemical studies were performed to compare the expression patterns of ER and PR in 44 cases of primary ovarian mucinous tumors (28 atypical proliferative [borderline] mucinous tumors of gastrointestinal type [APMT-GI], 9 APMT of seromucinous type [APMT-SM], 7 invasive mucinous carcinomas) and 60 cases of metastatic mucinous carcinomas involving the ovary (primary sites: colorectum [24], pancreas [11], endocervix [6], stomach [4], appendix [2], biliary tract [1], and unknown [12]). Cases were scored based on the percentage of positive cells: negative, ≤ 5%; 1+, 6-25%; 2+, 26-50%; 3+, 51-75%; and 4+, 76-100%.

**Results:** All APMT-GI, primary ovarian mucinous carcinomas, and metastatic mucinous carcinomas were negative for ER and PR with the exception of 2 cases of metastatic endocervical adenocarcinoma which showed only weak expression of ER without PR. All APMT-SM expressed ER to some degree (ER scores: 0, n=0; 1+, n=2; 2+, n=2; 3+, n=2; and 4+, n=3), and 5 had some expression of PR (PR scores: 0, n=4; 1+, n=3; 2+, n=1; 3+, n=0; and 4+, n=1).

**Conclusions:** Among primary ovarian mucinous tumors, ER/PR expression is limited to APMT-SM. Hormone receptor expression is of no value in distinguishing primary ovarian APMT-GI and invasive mucinous carcinomas from mucinous carcinomas metastatic to the ovary.

**964 TTF-1 Staining in Carcinomas of the Female Genital Tract**

*FB Vice, MM Weir.* London Health Sciences Centre and University of Western Ontario, London, ON, Canada.

**Background:** The identification of the primary site of origin for an adenocarcinoma in a malignant effusion or biopsy sample is often challenging, since the morphologic features of adenocarcinoma from different sites frequently overlap. TTF-1 is recognized as a specific immunohistochemical marker which is typically positive in pulmonary and thyroid carcinomas. Several retrospective studies have tested for TTF-1 expression in malignant effusions; however, only two histologic studies have tested for TTF-1 expression in cases of female genital tract (FGT) malignancy. Two studies have reported infrequent TTF-1 positivity: 1/16 ovarian carcinomas and 1/18 endometrial papillary serous carcinomas were positive.

**Design:** Our objective was to assess TTF-1 expression across a range of primary carcinomas of the FGT by retrospective immunohistochemical analysis. From our files, 55 malignant tumors were selected from a two year period, including: 20 ovarian carcinomas (13 serous, 3 endometrioid, 3 clear cell, 1 metastatic); 31 endometrial carcinomas (21 endometrioid, 8 serous, 1 clear cell, 1 mixed); 1 serous carcinoma of fallopian tube; and 3 peritoneal serous carcinomas. One block from each case was used for TTF-1 immunohistochemical staining (avidin biotin peroxidase technique); and each slide was graded semi-quantitatively for nuclear staining (0- none; 1- weak; 2- strong staining).

**Results:** No tumor showed any significant TTF-1 expression. The normal background tissue was negative for TTF-1. Both positive and negative controls stained appropriately.

**Conclusions:** Although pathologists need to remain aware that rarely, FGT carcinomas may show positive staining for TTF-1, our negative findings should increase confidence that FGT malignancies typically do not show TTF-1 immunopositivity.

**965 Prognostic Value of Cervical Involvement in Endometrial Carcinoma: Clinicopathologic Study of 36 Cases**

*M Vilar, S Bague, P Ramalingam, S Ghamande, J Prat.* Hospital de la Santa Creu i Sant Pau. Autonomous University of Barcelona, Spain; Medical College of Georgia, Augusta, GA.

**Background:** The prognostic value of distinguishing between stage cervical gland (stage IIA) and cervical stroma (stage IIB) is unclear. This study analyzes clinicopathologic data of 36 patients with stage II endometrial carcinomas in an attempt to determine the prognostic differences between stage IIA and IIB tumors.

**Design:** The clinicopathologic records of 36 patients with stage II tumors retrieved from a series of 490 patients with endometrial carcinomas accessioned at two general hospitals over a 14 year period (1988-2002) were reviewed. All available H-E slides were examined in each case.

**Results:** Most patients (96%) presented with metrorrhagia. Two patients had a previous history of breast cancer treated with tamoxifen, and two had synchronous uterine and ovarian endometrioid carcinomas, stages IA and IC each. Their ages ranged from 34 to 86 (mean, 63) years. The tumors measured 1 to 10 (mean, 5) cm. Eighteen tumors (50%) were stage IIA, 14 (39%) stage IIB, and in 4 (11%) cases the type of endocervical involvement was equivocal. Histologically, 28 (78%) tumors were endometrioid carcinomas, 4 mixed (2 endometrioid-serous, and 2 endometrioid-clear cell carcinomas), and clear cell carcinoma, undifferentiated carcinoma, carcinosarcoma, and mucinous adenocarcinoma, one case each. Twelve (33%) tumors were grade 1, nine (25%) grade 2, and 15 (42%) grade 3. Myometrial invasion: inner third of the myometrium, 3 cases; middle third, 12 (33%), and outer third, 17 (47%). Four (11%) tumors showed no myometrial invasion. Seven (26%) patients underwent surgery, 26 (72%) had surgery and radiotherapy, and two had surgery, radiotherapy, and chemotherapy. In one patient treatment was unknown. Twenty-nine (83%) of 35 patients with available follow-up were alive without disease after a mean interval of 8 years (range, 1-15 years), and three (8%) died of other causes. Three (8%) patients who had grade 3 endometrioid carcinomas with > 50% myometrial invasion (one stage IIA and two stage IIB), one with vascular invasion, died of tumor at 5, 6, and 6 years postoperatively.

**Conclusions:** Stage II endometrial carcinomas are not necessarily associated with adverse prognosis; our preliminary data suggest that subclassifying stage II tumors into IIA and IIB is not justified.

### 966 Effect of Tamoxifen on Endometrial Histology and Hormone Receptors: A Prospective Study with Follow up

SA Walter, KK Leslie, JK Stephens, M Singh. University of Colorado Health Sciences Center, Denver, CO; University of New Mexico, Albuquerque, NM; Emplia Saint Joseph Hospital, Denver, CO; UCHSC, Denver, CO.

**Background:** Tamoxifen is used to treat breast cancer, however a side effect is the development of endometrial carcinoma (ECa). Why only some women develop it is not known. Estrogen (ER) and progesterone receptors (PR) may play an important role. The latter has two isoforms, PR-A and PR-B. Knowing whether these receptors and isoforms are differentially influenced by Tamoxifen could help understand the mechanism of development of ECa in these patients. Our Aim was to study changes in ER, PR-A and PR-B in serial endometrial biopsies (Ebs) from patients on Tamoxifen and to correlate this with histopathologic abnormalities and Pap smear (PS) cytology and maturation index (MI).

**Design:** 42 patients who were to be started on 20mg/day of Tamoxifen for breast cancer or malignant melanoma underwent a pre-treatment Eb and Pap smear (PS). Follow up biopsies and PSs at 6 month and 1 year intervals were performed for a maximum of 6 biopsies per case. ER, PR (A+B) and PR-B immunostains were performed. Follow up data is available over a period of 10 years.

**Results:** 36% of the total biopsies (n=150) showed an inactive endometrium, of which 80% were post-treatment biopsies. Disordered proliferative endometrium was seen in 3%, dysynchronous endometrium in 3% and benign polyps in 5%. Two cases had atypical endometrial cells. The Pap smears from these patients were normal. No patient developed ECa. Epithelial staining for ER and PR(A+B) was more prominent than stromal staining. The staining for PR-B was different, with stromal staining being more prominent than epithelial staining. Tamoxifen treatment induced a more consistent decrease in PR-B compared to ER or PR(A+B). The endometrial activity was decreased (i.e it became atrophic, inactive or weakly proliferative) in 36% of patients over the course of treatment, with 67% of these showing a decrease in PR-B. This was accompanied by a change in the MI with a decrease in superficial squamous cells in the PSs in 40% of these cases. Atypical squamous cells were seen in 5% PSs, but were not accompanied by atypical cells in the Ebs.

**Conclusions:** 1. Tamoxifen treatment produces an inactive endometrium in many cases and is therefore not always an Estrogen agonist. 2. Tamoxifen has an inhibitory effect on the expression of PR-B isoform. 3. Pap smear cytology has no direct correlation with the presence of atypical cells in the endometrium and vice versa.

### 967 Expression Profile of the Tumorigenic Factors in Association with Tumor Size and Sex Steroid Hormone Status in Uterine Leiomyomata

JJ Wei, L Chiriboga, K Mittal. New York University, New York, NY.

**Background:** Leiomyomata are sex steroid hormone driven neoplasms. It is unclear as to why some uterine leiomyomata grow large while others remain small in patients with the same sex hormone status. Patients at their age of later forties tend to have larger leiomyomata and worse morbidity than those in other age groups. We proposed that the difference in tumor sizes might be a result of the dysfunction of the other molecular changes in addition to sex steroid hormone status.

**Design:** Hysterectomy specimens (60 cases) with uterine leiomyomata and the matched myometrium were randomly selected from a broad range of patients' ages (37 to 82 yrs) and of tumor sizes (1.5 to 19 cm). One third of cases coexist with adenomyosis. Tissue cores (0.6 mm) of the tumors and the matched myometrium were arrayed on a paraffin block. Twenty-one selected potentially tumorigenic factors, including the female sex steroid and the non-sex steroid hormone factors were examined by immunohistochemistry. Expression of the markers in association with the different tumor sizes, patients' ages, cycling phases and presence or absence of adenomyosis were analyzed by their mean values and by the dendrogram cluster TREEVIEW.

**Results:** Expression of ER and PR were upregulated in smaller fibroids and down in larger fibroids. Up regulations of some factors (HMGI-C, steroid receptor cofactors, proteins in insulin pathway and CD24) were identified in a group of patients at ages

of later forties, were associated with large fibroids, and were weakly affected by the sex steroid hormone status (illustrated by endometrial phases and menopause). Down regulations of tuberin and glucocorticoid receptor was mostly isolated in a second group of women in their late reproductive age. The occurrence of adenomyosis in patients with leiomyomata was found in one third of patients. The patients with adenomyosis tended to have smaller fibroids and to have less altered expression of non-sex hormone factors.

**Conclusions:** Expression analyses of the sex steroid hormone receptors and the non-sex steroid hormone factors in leiomyomata and the matched myometrium showed different patterns in different tumor sizes and patients' ages. A group of patients with the larger leiomyomata at late 40s contributes largely by the up regulations of the non-sex steroid hormone factors. Adenomyosis is a protective factor preventing from the large leiomyomata. An up regulation of estrogen and progesterone receptors is reversely associated with the tumor size.

### 968 Ethnic Differences in Expression of Nuclear Receptors and Co-Factors in Uterine Leiomyomata

JJ Wei, L Chiriboga, AA Arslan, J Melamed, H Yee, K Mittal. New York University, New York, NY.

**Background:** Ethnic background is considered to be a risk factor for uterine leiomyomata, as black women have a higher incidence than white women. The reasons for ethnic differences in incidence of uterine leiomyomata are largely unknown. The differential expression of the female steroid hormones and their receptors was suggested. The objective of this study was to examine the expression of various nuclear receptors and cofactors in leiomyomata and normal myometrium among different ethnic groups.

**Design:** Hysterectomy specimens (120 cases) with uterine leiomyomata and the matched myometrium were randomly selected from 4 groups of different ethnic origin (30 cases in each group), including African (AA), Chinese (CH), Hispanic (H) and Caucasian (C) Americans women. Tissue cores from normal myometrium (2 cores) and leiomyomata (3 cores) were arrayed. ER, PR, GCR, RARa and RXRa, and cofactors AIB1, SRC1 and GRIP1 were examined by immunohistochemistry, scored by semiquantitation and analyzed using paired *t* test for matched data, analysis of variance test for differences between different ethnic groups, and Dendrogram cluster analysis.

**Results:** The average age of women undergoing hysterectomy for leiomyomata was younger in AA (45.8 yrs) and H (45.6 yrs) than CH (47.4 yrs) and C (47.8 yrs). The mean tumor size was larger in AA (6.7 cm) and H (7.6 cm) than CH (6.1 cm) and C (6.4 cm) patients. AA women had higher ER expression in myometrium and leiomyomata than women of other ethnic groups. Compared to the myometrium, a significant up-regulation of PR in leiomyomata was observed in AA (mean, +2.2 fold), compared with other ethnic groups. Significant down-regulation of GCR in leiomyomata was observed among all ethnic groups. Leiomyomata from AA women had no change of RXRa and a down-regulation of RARa. In contrast, leiomyomata from other ethnic groups showed up-regulations of both RARa and RXRa. Up-regulations of cofactors AIB1, GRIP1 and SRC1 were present in leiomyomata samples of all ethnic groups. There were no significant differences in these cofactors between four ethnic groups.

**Conclusions:** Analyses of nuclear receptors and cofactors in leiomyomata and matched myometrium reveals substantial differences in the expression patterns between four ethnic groups. The distinct expression patterns of ER, PR, RARa and RXRa in leiomyomata from African American women may explain a higher incidence, earlier development and larger size of fibroids in this population.

### 969 Endocervical Adenocarcinoma In Situ (AIS) Confined to the Surface ("Early AIS"): Evidence for De Novo Transformation of the Endocervical Surface Mucosa

AK Witkiewicz, KR Lee, A Cviko, CP Crum. Brigham and Women's Hospital, Boston, MA.

**Background:** Because of the increasing frequency of both endocervical adenocarcinoma and its precursor adenocarcinoma in situ (AIS), accurate diagnosis is critical to early removal. Lesions confined to the surface mucosa may be particularly challenging and have not been studied in detail. This report addresses the morphology, biomarker expression patterns, viral status and proposed origin of AIS confined to the surface epithelium (early AIS).

**Design:** Ten cases of superficial AIS from the in-house and consultation practices were examined histologically, immunostained for MIB-1 and p16, and tested for HPV by PCR.

**Results:** The patients ranged in age from 17 to 42 (mean 25) years. All cases of AIS affected surface epithelium without extension into underlying crypts; five were associated with co-existing CIN. In four cases, AIS predominately involved the endocervical papillae; in another early villoglandular change was present. Nuclear hyperchromasia, pleomorphism and apoptosis were identified in all cases, however, the degree of atypia varied, including foci with orderly, pseudo-stratified epithelium. MIB-1 (>50%) staining was present, but varied, with some lesional epithelia containing low proliferative indices (<20%). HPV 16 and/or 18 DNA was detected in 5 of 7 (71%) analyzed cases.

**Conclusions:** The younger mean age for superficial AIS is consistent with an early phase of preinvasive cervical glandular neoplasia. The small size of some lesions and the high nuclear grade in at least a portion of all of these lesions suggests further that AIS is not derived from a long-standing precursor of lesser grade (dysplasia); however, heterogeneity in morphologic appearance and MIB-1 staining may cause diagnostic confusion. Because small AISs are confined to the surface, their distribution supports a direct transformation of the endocervical surface mucosa by human papillomavirus. Whether the squamous component of these lesions is derived from the same or different clone of HPV-transformed cells remains to be determined.

### 970 Her-2/neu Status in Endometrial Carcinomas: Comparison of Quantitative Immunohistochemistry by Automated Cellular Imaging and Fluorescence In Situ Hybridization

B Xu, J Wallace, C Li, B Woda, A Khan. UMass Medical School, Worcester, MA.

**Background:** Overexpression of Her2/neu oncoprotein is through gene amplification and has been documented in a variety of malignant neoplasms, including breast, ovary and lung. The status of Her2/neu overexpression in endometrial carcinomas, however, is not entirely clear. In this study, we compared two detection methods, automated cellular imaging system (ACIS) for Her2/neu oncoprotein overexpression, and fluorescence in situ hybridization (FISH) for gene amplification to analyze Her2/neu status in endometrioid and serous carcinomas of the endometrium.

**Design:** 82 consecutive hysterectomy specimens with a diagnosis of endometrioid or serous carcinoma at UMass Memorial Hospitals from December 2001 to July 2003 were included in this study. In addition, 30 cases of endometrial serous carcinoma were also included in this study. Representative blocks were selected for immunohistochemical stain and ACIS scoring. FISH analysis with the PathVysion dual color probe system was done on all cases with an ACIS score of 2.0 or higher. The Her2/neu and CEP 17 signals were counted in 60 cells and a Her2/CEP17 ratio of 2 or greater is considered positive for gene amplification.

**Results:** This study included 112 cases, comprising 71 endometrioid carcinoma, 34 serous carcinoma, and 7 mixed carcinoma with a serous component. 41 of 112 cases showed an ACIS score of 2.0 or higher with a range of 2.0 to 4.2, corresponding to 20% (14/71) of endometrioid and 66% (27/41) of serous carcinoma. Only 6 cases of serous carcinoma showed gene amplification by FISH analysis with a Her2/CEP17 ratio of 2.5 to 6.5. None of the endometrioid carcinoma showed gene amplification by FISH analysis.

Her2/neu Status in Endometrial Carcinomas

	ACIS $\geq$ 2	FISH+
Endometrioid Carcinoma (n=71)	20% (14/71)	0% (0/71)
Serous Carcinoma (n=41)	66% (27/41)	15% (6/41)

**Conclusions:** Her2/neu gene amplification was observed only in a small percentage of endometrial serous carcinoma and does not seem to correlate with the intensity of immunohistochemical staining assayed by ACIS. Her2/neu gene amplification was not detected in endometrioid carcinoma by FISH analysis. Our data suggests that the Her2/neu oncogene might not play a significant role in tumorigenesis and tumor progression in endometrioid carcinoma. However, a subset of serous carcinoma does show Her2/neu gene amplification, providing further support for the divergent pathogenesis of endometrioid and serous carcinomas of the endometrium.

### 971 Expression of Multidrug Resistance-Related Proteins P-gp, MRP1, and LRP in Uterine Sarcomas

E Yakirevich, I Naroditsky, E Sabo, O Lavie, Y Sova, MB Resnick. Carmel Medical Center, Haifa, Israel; Rhode Island Hospital, Providence, RI.

**Background:** Uterine sarcomas are malignant mesenchymal tumors with a poor prognosis. Multidrug resistance (MDR) to chemotherapy-induced apoptosis presents a major obstacle in attempts to improve clinical outcome. The MDR phenotype is associated with overexpression of drug transporters such as P-glycoprotein (P-gp), multidrug resistance protein 1 (MRP1), and lung resistance protein (LRP). The aim of this study was to evaluate the frequency and prognostic significance of MDR-related protein expression in uterine sarcomas.

**Design:** Fifty seven cases of uterine mesenchymal neoplasms, including 16 leiomyomas (LM), 15 endometrial stromal sarcomas (ESS), 12 leiomyosarcomas (LMS), and 14 carcinosarcomas (CS), were studied. The expression of P-gp, MRP1, and LRP was assessed immunohistochemically on paraffinized sections. P-gp expression was analyzed with 2 MAbs (C494 and JSB-1). The level of protein expression was scored semiquantitatively based on staining intensity and extent.

**Results:** Expression of P-gp was observed more frequently in the CS group as opposed to the LMS, ESS, and LM groups (85.7%, 33.3%, 33.3%, and 0%, respectively,  $P < 0.001$ ). MRP1 expression was seen most frequently in the CS group followed by LMS, ESS, and LM (93%, 66.7%, 33.3%, and 18.75%, respectively). Although weak MRP1 positivity was observed in the LM group, the extent of staining was limited to less than 50% of the cells. The extent of P-gp and MRP1 expression was highest in the CS group. In this group, a significant proportion of cases showed immunoreactivity with these antibodies in both the carcinomatous and sarcomatous components. The extent of P-gp and MRP1 expression was significantly greater in high grade as opposed to low grade sarcomas ( $P < 0.0001$ , OR=26, and  $P < 0.0001$ , OR=17, respectively). No significant difference was found in LRP expression between the different groups (42.9%, 25%, 46.7%, and 56.3% for CS, LMS, ESS, and LM, respectively). Univariate analysis of survival revealed a significant inverse correlation between MRP1 expression ( $P = 0.032$ ), high stage ( $P = 0.05$ ), high grade ( $P = 0.01$ ) and patient survival. A combined score of MRP1, stage, and grade was the strongest predictor of survival in univariate as well as in multivariate analysis ( $P = 0.002$ , and  $P = 0.003$ , OR=2.5, respectively).

**Conclusions:** Strong MRP1 and P-gp expression is characteristic of the vast majority of uterine carcinosarcomas and to a lesser degree ESS and LMS. MRP1 expression may also provide important prognostic information.

### 972 The Kallikrein Proteins: New Potential Biomarkers for Ovarian Cancer

GM Yousef, D Katsaros, EP Diamandis. Mount Sinai Hospital, Toronto, ON, Canada; University of Turin, Turin, Italy.

**Background:** kallikreins are 15 proteases clustered on chromosome 19q13.4; an area non-randomly rearranged in ovarian cancer. In addition to prostate specific antigen, other kallikreins are differentially regulated in malignancies, including ovarian cancer. The aim of this study was to examine kallikrein expression, at the mRNA and protein levels, in normal and ovarian cancer tissues, and to assess their potential diagnostic/prognostic value in ovarian cancer.

**Design: A) In-silico analysis:** We utilized the Serial Analysis of Gene Expression (SAGE) and Expressed Sequence Tag (EST) databases of the Cancer Genome Anatomy Project to perform an in silico analysis of the 15 human kallikrein genes in normal and cancerous ovarian tissues and cell lines. Different analytical tools were used, including Virtual Northern blotting, Digital Differential Display and X-profiler.

**B) Ovarian tissue cytosols and immunofluorometric assays:** Extracts were prepared from normal and cancerous ovarian tissues (10 samples per category). Kallikrein protein levels were measured by specific immunofluorometric assays.

**Results:** Seven kallikreins (*KLK5-8*, *KLK10-11* and *KLK14*) are up-regulated in ovarian cancer. Probing two normal and 10 ovarian cancer SAGE libraries with gene-specific tags indicated that while no expression was detected in any of the normal libraries, they were found to be expressed with moderate density (103-408 "tags per million", tpm) in 40-60 % of the ovarian cancer libraries analyzed. This was verified by screening the independent EST databases, where all mRNA clones isolated were from ovarian cancer libraries. X-profiler comparison of the pools of normal and cancerous ovaries further verified the significant difference in expression levels.

To verify the in-silico mRNA overexpression and to examine whether these mRNA up-regulations reflect changes at the protein level, we compared their protein levels in normal, benign and cancerous ovarian tissues. A step-wise increase was found between normal, benign and cancer. These differences were statistically significant for hK11 ( $p < 0.001$ ), hK5, 6 and 10 ( $p$  values of 0.048, 0.044 and 0.027, respectively) but not for hK7 and hK8. Moderate to strong correlations were observed between kallikreins with high statistical significance ( $r_s$  0.45 - 0.74 and  $p < 0.001$ ).

**Conclusions:** Seven kallikreins are overexpressed in ovarian cancer and have the potential of being diagnostic/prognostic markers. Large scale studies are needed to establish the clinical utility of kallikreins.

### 973 Vulvar Seborrhic Keratosis, Is It Indeed Related to HPV Infection?

H Zhang, K Storthz, A Malpica. UT M.D. Anderson Cancer Center, Houston, TX; UT Dental Branch, Houston, TX.

**Background:** Some authors have postulated that seborrhic keratoses in the vulva are related to HPV infection. Others believe that the HPV-related seborrhic keratoses in the vulva should be strictly classified as condyloma accuminata. The latter cases can be interpreted correctly once the histological features of this type of lesion are recognized on the examination of hematoxylin-eosin stained sections. In this study, we are trying to determine if vulvar seborrhic keratosis is indeed associated with HPV infection.

**Design:** Seventeen cases of vulvar seborrhic keratosis, two cases of seborrhic keratosis-like VIN (Vulvar Intraepithelial Neoplasia), fifteen cases of vulvar fibroepithelial polyp, and sixteen cases of non-genital seborrhic keratosis were retrieved from the files of the Department of Pathology at our institution. Hematoxylin-eosin stained slides were reviewed in all cases and the diagnoses were confirmed. The DNA was extracted from tissue sections from paraffin-embedded blocks. Real time PCR was performed on twelve out of seventeen cases of vulvar seborrhic keratosis, two cases of seborrhic keratosis-like VINs, and on all cases of vulvar fibroepithelial polyps, and non-genital seborrhic keratosis using consensus primers (MY9 and MY11) which can detect over 20 types of the most common HPVs. Ki-67 and p16 immunostaining were performed on all cases.

**Results:** Results of real-time PCR, immunoperoxidase studies for Ki-67, and p16 in cases of vulvar SK, vulvar FEPs, SK-like VINs, and non-genital SKs. Positive cases only.

	vulvar SK (17)	vulvar FEP (15)	non-genital SK (16)	SK-like VIN (2)
Real time PCR	0	0	0	1
Ki-67	6	0	2	1
p16	6 (3 F; 3 D)	5 (F)	11 (10 F; 1 D)	1 (D)

D, diffuse; F, focal; FEP, fibroepithelial polyp; SK, seborrhic keratosis; VIN, vulvar intraepithelial neoplasia

**Conclusions:** Real time PCR reveals no evidence of HPV DNA in vulvar seborrhic keratosis, non-genital seborrhic keratosis or vulvar fibroepithelial polyps. Ki-67 positivity can be seen either in vulvar or non-genital seborrhic keratosis. The p16 reactivity is variable and can be seen in either vulvar seborrhic keratosis, non-genital seborrhic keratosis, and also in vulvar fibroepithelial polyps. VIN can have a seborrhic keratosis-like appearance, especially in those cases in which the chromatin pattern is still open. However, attention to the cytological features will allow the correct classification of these lesions. The study of additional cases is necessary to confirm the findings of this study.

### 974 Large Uterine Leiomyomata: Spatial Distribution of the Tumorigenic Factors

XM Zhang, K Mittal, L Chiriboba, H Yee, JJ Wei. New York University School of Medicine, New York, NY.

**Background:** Although the incidence of uterine leiomyomata can be as high as 40% in reproductive age women, only a small proportion of them with large leiomyomata complains of severe clinic symptoms and eventually seeks a surgical intervention. It is poorly understood why some leiomyomata grow large whereas others remain small. A large cohort study by monitoring the tumor growth in reproductive age women is underway. In this study, we developed a different approach to explore the tumor growth behaviors by examining the spatial distributions of tumorigenic factors in the large leiomyomata.

**Design:** Seven hysterectomy specimens with large uterine leiomyomata (10-13 cm), matched myometrium and matched small leiomyomata (1-2 cm) were collected. Tissues from the large leiomyomata were dissected in 3 dimensional axes of X, Y and Z. Each axis was further orderly divided into 6 zones from zone 1 of the periphery to zone 6

of the center. One section from each zone of each axis, 2 sections from small leiomyomata (1-2 cm) and 2 sections from matched myometrium were arrayed on one block (0.6 mm tissue cores). Expression of the tumor markers, including ER, PR, MIB1, RXR, GCR, HMGA2, EGFR, F8 and CD24 was scored by semi-quantitation.

**Results:** All tissue sections were reviewed on H&E stained slides. Large leiomyomata had varied amount of hyalinization, accounting for approximately 25 % of the tumor volume. The distribution of hyalinization tended to be higher in the center of the tumors. Tissue cores for microarray were selected from the cellular area. The large leiomyomata showed minimal changes of ER and PR overall, compared with matched myometrium. However, a significant up regulation of ER and PR was noted in zone 2 with scores of 1.2 and 1.8 in comparison with the mean scores of 0.4 and 0.5 in the large leiomyomata. Up regulation of CD24, HMGA2 and RXR was constantly highest in zone 2, followed by zone 3 and 4. Scores of MIB1 were higher in zone 1, 2 and 4, and lower in zone 3, 5 and 6. There was a deep down regulation of GCR in zone 4, 5 and 6, where many fewer capillary vessels (detected by F8 staining) were counted.

**Conclusions:** Spatial distribution of the selective tumorigenic markers in the large uterine leiomyomata presents a distinct pattern. Zone 2 (next to periphery) is the most biologically active area. The expression of the markers in the small leiomyomata is similar to zone 2 of the large leiomyomata. The findings suggest that central areas of hyalinization or infarcts may not slow down the tumor growth if zone 2 is still viable.

### 975 Examination of Phosphatidylinositol 3-Kinase (PI3K) and Its Associated Signaling Proteins in Endometrial Carcinoma (EC)

CC Zhu, JJ Wei, L Chiriboga, S Goswami, K Mittal. New York University School of Medicine, New York, NY.

**Background:** Cell signaling mediated through PI3K plays a pivotal role in regulating cell growth, proliferation and apoptosis. PI3K has a catalytic subunit, p110, which is tightly controlled by its associated regulatory subunit p85. The biological activities of PI3K are counter-balanced by PTEN, a PIP3 phosphatase. Activation of PI3K eventually turns on several down stream target molecules including b-catenin to exert its functions. Aberrant expression of PI3K, due to mutations involving either p110, or p85, is associated with colon, cervical, ovarian and lung carcinomas. However, their role in EC has not been assessed. In the current study, the expression levels of p110 and p85 were examined along with PTEN and b-catenin in EC.

**Design:** A tissue microarray was assembled from formalin-fixed and paraffin-embedded tissue blocks of 22 cases of EC, endometrioid type, seen at NYU hospitals between 1999 and 2004. The average age of the patients at diagnosis was  $62 \pm 12.1$  yr (43 – 85). Of the 22 cases, 18 were graded as FIGO I, 3 FIGO II, and 1 FIGO III. Two 1-mm cores of tumor tissue, the accompanying simple (SH) or complex hyperplasia (CH) as well as normal endometrium (EM), when they are present, were taken from each case. The immunoreactivity to p110, p85, PTEN and b-catenin were examined by immunohistochemical staining on the tissue array.

**Results:** PI3K p110 immunoreactivity was shown predominantly in the cytoplasm in both benign and malignant endometrial tissues. The nuclear stains tend to be seen in CH and EC. The expression levels of p110 increased along the spectrum of normal EM ( $0.66 \pm 0.7$ ) to SH ( $1.06 \pm 0.8$ ) to CH ( $1.23 \pm 0.6$ ) to EC ( $1.86 \pm 0.7$ ,  $p < 0.0001$  vs. normal EM, Table 1). Interestingly, we didn't observe immunoreactivity for p85 or the loss of PTEN in any of our cases. Nuclear translocation of b-catenin was shown in 8 cases of EC or CH, but not in normal EM or SH.

**Conclusions:** Our study provides the first piece of evidence suggesting a role of PI3K in EC, presumably functioning as an oncogenic protein. Since its elevation is seen in pre-malignant endometrial hyperplasia, it may suggest that PI3K participates in the early events of the tumorigenesis of EC.

Table 1: The immunoreactivity of PI3K p110 in EC

	Number of Cases	0+ Cases (%)	1+ Cases (%)	2+ Cases (%)	3+ Cases (%)
endometrium	9	4 (44.4%)	4 (44.4%)	1 (11.2%)	0
simple hyperplasia	15	4 (26.7%)	6 (40.0%)	5 (33.3%)	0
complex hyperplasia	17	2 (11.8%)	9 (52.9%)	6 (35.3%)	0
endometrial carcinoma	22	0	8 (36.4%)	9 (40.9%)	5 (22.7%)

### 976 Up Regulation of Retinoid Acid Receptor X (RXR $\alpha$ ) in Uterine Leiomyosarcomas

H Zhu, K Mittal, J Melamed, S Goswami, L Chiriboga, JJ Wei. New York University School of Medicine, New York, NY.

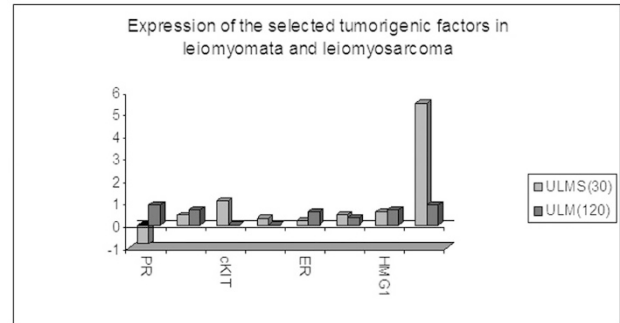
**Background:** Uterine leiomyosarcomas (ULMS) are rare type of malignant smooth tumors. The tumor pathogenesis is largely unknown. Studies suggested that ULMS may be associated with or progressed from uterine leiomyomata. However, there is no convinced evidence to establish the link between the two diseases. In this study, we intended to examine some selected tumorigenic factors by comparing the expression patterns between leiomyosarcomas and leiomyomata.

**Design:** A total of 30 uterine leiomyosarcomas, matched leiomyomata and matched myometrium were collected. 0.6mm tissue cores from ULMS (2 cores), leiomyoma (1 core), and myometrium (2 cores) were arrayed on one block. Selected immunomarkers, including SMA, ER, PR, bcl-2, Ki-67, RXR $\alpha$ , HAM-1 GCR, HMG1 and c-Kit were stained and analyzed by semi-quantitation. The data of the immunomarkers obtained from ULMS were compared with data of the same group of markers from 120 uterine leiomyomata (in the separate study).

**Results:** Patient's mean age was 59.2 years old (ranged from 38 to 85yrs). A total of 26 cases showed validate data from all markers. Among them, 11 cases had concurrent leiomyomas (42%). Considering the possible variation of the immunoreactivity between the cases due to no biological factors, we calculated the net values of gain or loss of immunocores with an internal myometrial control. A significant up regulation of RXR $\alpha$  had been found in almost all ULMS, with an average of 5 fold increase

compared with myometrium. There were slightly up regulations of bcl-2, c-kit, cyclin D1, hamartin and HMGA2. Minimal changes of ER and down regulation of PR were noted. By comparing the mean value of the selected markers from 120 leiomyomata, up regulation of RXR $\alpha$  and down regulation of PR were remarkable in ULMS.

**Conclusions:** There is a substantial difference of RXR $\alpha$  expression between leiomyomata and leiomyosarcoma. Our finding is the first time to show an up regulation of RXR $\alpha$  to be a factor in the pathogenesis of ULMS. A similar expression pattern of other selected tumorigenic factors between leiomyomata and ULMS indicates a possible connection in the tumorigenesis.



## Head & Neck

### 977 Leber Hereditary Optic Neuropathy Mutations in Head and Neck Cancer

LB Ai, LW Li, P Mukunyadzi, MS Kokoska, JY Suen, M Scott, BR Smoller, CY Fan. University of Arkansas for Medical Sciences, Little Rock, AR; Central Arkansas Veterans Healthcare System, Little Rock, AR.

**Background:** Leber Hereditary Optic Neuropathy (LHON) is a specific mitochondrial disease, in which a primary role for mitochondrial dysfunction is confirmed by strict maternal inheritance and association with specific mutations in the mitochondrial DNA. LHON is characterized by early onset of visual loss (younger than 30 years of age), which is aggravated by the use of tobacco and alcohol. Previously, we sequenced the entire 16.6 kb mitochondrial DNA genome in 13 primary head and neck cancer and found that two secondary LHON mutations at 4216, and 13708 were present in multiple head and neck cancer. In this study, we analyze these two LHON mutations in head and neck cancer in order to identify 1) whether these two mutations are associated with increased risk of developing head and neck cancer; and 2) whether these two mutations affect tumor behavior and survival of head and neck cancer patients.

**Design:** One hundred and thirty three (133) head and neck cancer and 107 cases of normal skin of age-matched control subjects were obtained from the Department of Pathology at John L. McClellan Memorial Veterans Hospital in Little Rock. DNA samples from head and neck cancer and normal skin specimens were subjected to PCR-based restriction fragment length polymorphism (RFLP) analysis.

**Results:** T4216C and G13708A mutations were detected in 15/133 (11.3%) and 26/107 (19.5%) cases of head and neck cancer and in 12/107 (11.2%) and 20/103 (19.4%) cases of normal skin derived from control subjects. There is no statistical significant difference in the prevalence of these two mutations between head and neck cancer patients and control subjects. Using Kaplan-Meier Survival analysis. G13708A mutation was found to be significantly correlated with increased 2-year disease-free survival (decreased tumor recurrence) ( $p = 0.03$ ) and increased overall patient survival ( $p = 0.03$ ). T4216C mutation was not significantly correlated with tumor recurrence ( $p = 0.59$ ) or patient survival ( $p = 0.40$ ).

**Conclusions:** 1) G13708A Mitochondrial LHON mutation is significantly correlated with increased 2-year disease-free and 5-year overall patient survival. 2) The presence of T4216C and G13708A LHON mutations does not seem to increase an individual's risk of developing head and neck cancer.

### 978 Hierarchical Cluster Analysis of Several Myoepithelial Markers in Adenoid Cystic Carcinoma and Polymorphous Low Grade Adenocarcinoma Shows Expression of Smooth Muscle Actin, Calponin, Metallothionein and Smooth Muscle Myosin Heavy Chain To Be Most Discriminative

C Barbacioru, YB Rawal, O Husein, P Wen, ML Prasad. The Ohio State University, Columbus, OH; UMass Memorial Health Center, Worcester, MA.

**Background:** Morphologic similarity between adenoid cystic carcinoma (ACC) and polymorphous low-grade adenocarcinoma (PLGA) of the salivary glands frequently requires additional studies for their differentiation. We performed hierarchical cluster analysis to evaluate the expression of several myoepithelial / basal cell markers in ACC and PLGA in order to identify the most useful marker or combination of markers in their differential diagnosis.

**Design:** Archival tissues from 23 ACCs (10M: 13F; age range 23-82 years, median age 52) and 24 PLGAs (6M: 18F; age range 32-94 years, median age 57) were studied by immunohistochemistry for the expression of smooth muscle actin (SMA), calponin, metallothionein (MT), smooth muscle myosin heavy chain (SMMS-1), maspin, and p63. The expression was interpreted as negative (no expression or expression in <10% tumor cells), focal (10-33% tumor cells) and diffuse (>33% tumor cells). The