

**788 Glypican 3: A Novel Marker in Testicular Germ Cell Tumors**

DL Zynger, ND Dimov, C Luan, XJ Yang. Northwestern University, Chicago, IL.

**Background:** Glypican-3 (GPC3) is a membrane-bound heparin sulfate proteoglycan which is postulated to regulate cell division in certain tissues. GPC3 is mutated in Simpson Golabi-Behmel syndrome, an overgrowth syndrome characterized by an increased risk of embryonal tumors, including Wilm's tumor, neuroblastoma, hepatoblastoma, and testicular germ cell tumors. Recently, GPC3 was reported as one of the overexpressed genes in testicular yolk sac tumors by gene expression microarray analysis. The purpose of the study was to elucidate the expression of GPC3 in the different histological components of testicular germ cell tumors by immunohistochemistry.

**Design:** Specimens from 71 patients with testicular germ cell tumors were subjected to immunohistochemical study using monoclonal antibody specific for GPC3. The histological components were analyzed independently (42 seminomas, 36 embryonal carcinomas, 23 yolk sac tumors, 17 mature teratomas, 17 immature teratomas, and 6 choriocarcinomas). Cytoplasmic and membranous immunoreactivity was semiquantitatively evaluated as negative (< 5% of cells stained), focally positive (5-10% of cells stained), or positive (>10% of cells stained).

**Results:** All yolk sac tumor and choriocarcinoma components were immunoreactive for GPC3 while there was no immunoreactivity in residual benign testicular tissues (see table). The majority of embryonal carcinomas as well as all seminomas and mature teratomas did not express GPC3. Approximately 70% of immature teratomas were also negative for this marker.

**Conclusions:** We report a novel immunohistochemical marker, GPC3, which is differentially expressed in the histological components of testicular germ cell tumors, suggesting its possible role in tumor cell differentiation. GPC3 was expressed in all yolk sac tumors and choriocarcinomas, but was infrequently identified in embryonal carcinomas, teratomas and seminomas. Based on our data, GPC3 may be a useful marker in pathological diagnosis.

	YST	CC	Imm TER	EC	SEM	Mat TER
Positive	22 (96%)	5 (83%)	5 (29%)	2 (6%)	0	0
Focally Positive	1 (4%)	1 (17%)	0	3 (8%)	0	0
Negative	0	0	12 (71%)	31 (86%)	42 (100%)	17 (100%)
Total	23	6	17	36	42	17

## Gynecologic

**789 Volume of Borderline Change in Ovarian Neoplasms: Do Cystadenomas with Focal Borderline Change Warrant a Full Operative Staging?**

KA Allison, EM Swisher, RL Garcia. University of Washington Medical Center, Seattle, WA.

**Background:** Intra-operative evaluation of ovarian neoplasms helps determine the need for a full staging procedure at the time of surgery. However, the volume of borderline change in an otherwise benign cystadenoma can be quite variable. We sought to determine what volume of borderline change would justify a full surgical staging.

**Design:** Primary ovarian neoplasms with at least focal borderline change in the final diagnosis were identified in the University of Washington pathology database between 1995 and 2003 and available pathology reviewed. Estimates of the amount of borderline change were recorded based on histologic examination and the gross description (scored as 1-4 microscopic foci (40X field), 1-2cc, 2-4 cc or >4cc as well as percent of the total tumor volume). Comparison of the frozen section and final diagnoses were made. Staging data and clinical follow-up were reviewed.

**Results:** 59 cases with a final diagnosis of at least focal borderline change between 1995 and 2003 were identified in the pathology database and were available for review. Patient ages ranged from 18 to 84 years (median = 45). Ovarian masses ranged in size from 0.4 – 33 cm (median = 10) and were 67% serous (40/59), 29% mucinous (17/59), 2% endometrioid (1/59) and 2% mixed (1/59). 72% were stage 1 and 28% stage 2-3. 19% (11/59) had only 1-4 microscopic foci of borderline change, 13% (8/59) had 1-2cc, 24% (14/59) had 2-4 cc and 44% (26/59) had > 4cc. Of 19 cases with <2cc of borderline change, only one case (5%) was upstaged by a positive wash (all cases with <2cc were stage 1a-c). In contrast, 21 of 39 cases (54%) with >2cc of borderline change had positive cytology (13% stage 1c) or extra-ovarian disease (41% stage 2-3). Thus, cases with more than 2cc of borderline change in the ovary were significantly more likely to have extra-ovarian disease (p=0.0001, two-tailed, Fishers Exact). Clinical follow-up was available on 34 cases with a range of 6-108 months (median=28.5). There were no recurrences in the <2cc group. The >2cc group recurred in three cases, all of which had stage 3 disease. There were no deaths due to disease.

**Conclusions:** The volume of borderline change in an otherwise benign ovarian neoplasm significantly predicts final surgical stage. If intra-operative examination reveals less than 2cc of a papillary or solid component to a borderline neoplasm, then surgical staging appears unnecessary.

**790 p16 Staining Profile of Biopsy Negative High Risk HPV Positive Women**

SR Anderson, L Simmons-Arnold, ML Harmon. University of Vermont College of Medicine, Burlington, VT.

**Background:** p16(INK4A) is a well recognized biomarker of high-grade squamous intraepithelial lesion (HSIL). p16 protein levels increase with viral DNA integration and binding of the E7 protein to the retinoblastoma (Rb) gene and gene product. The staining pattern of HSIL shows high intensity, full thickness staining of the cell nucleus and cytoplasm while low-grade lesions shows cytoplasmic and nuclear staining within the basal layers. To the best of our knowledge, no p16(INK4A) staining studies have been reported for women who have had negative coloscopically obtained biopsies

with a positive high-risk HPV status. Our study attempts to determine the p16(INK4A) staining pattern in high-risk HPV infected women with morphologically benign biopsies.

**Design:** 31 women, aged 18 to 63 years (mean age 32), were identified in a four month period following a diagnosis of ASC-US on Pap test and a positive high-risk HPV result by hybrid capture. Each patient had a subsequent morphologically negative, colposcopically obtained, cervical biopsy and/or endocervical curettage. The negative control group consisted of 36 age-matched women who underwent hysterectomy between the dates of 05/04 to 06/04 for benign disease and who had no history of SIL on Pap testing. The samples were stained with the p16(INK4A) protein (CINtec histology kit by Dako at a 1:25 dilution, modified by use of Dako high pH 9.0 retrieval solution) to determine the amount of protein present in morphologically negative biopsies in women with known high-risk HPV infection. p16(INK4A) staining was considered positive with moderate to strong staining of squamous nuclei and cytoplasm.

**Results:** Four of thirty-one morphologically benign specimens showed basal cytoplasmic and nuclear staining, suggesting HPV infection in a LSIL pattern. No biopsies showed intense, full thickness staining, as would be seen in HSIL (p = 0.03). None of the thirty-six control specimens showed significant p16(INK4A) staining.

**Conclusions:** The increased level of p16(INK4A) protein in the morphologically benign biopsy specimens would suggest active HPV infection. The lack of morphologic changes has two possible explanations. First, this could represent an evolving infection with viral DNA integration and little morphologic change. The second possibility is a resolving infection with clearing of the virus and normalization of morphologic features. Both conditions would explain increased p16(INK4A) protein levels with little or no morphologic changes to the epithelium.

**791 Biphasic Tumors of the Uterus and Breast with Malignant Mesenchymal Component: A Comparative Immunohistochemical Study**

S Andre, A Felix, J Soares. Instituto Portugues de Oncologia Francisco Gentil, Lisboa, Portugal.

**Background:** Biphasic tumors of the uterus and breast composed by benign epithelial and malignant mesenchymal components are very rare neoplasms which share similar histologic features. Our aim was to compare hormonal receptors and HER2 status, differentiation, proliferative activity, and tumor suppressor genes expression of biphasic tumors of the breast and uterus with malignant mesenchymal component.

**Design:** Representative samples (3 cores of each tumor) of 9 adenosarcomas of the uterus and 11 cases of malignant phyllodes tumors, with both mesenchymal and epithelial components, were used in a tissue microarray construction. Three cores of normal breast and endometrial tissue were used as controls. An immunohistochemical staining for ER, PR, HER2, p53, Ki-67, beta catenin, bcl2, CD10, CD34, CD99, CD117, collagen IV, HHHF35, calponin (Dako), and laminin  $\gamma$ 2 (Chemicon) was performed.

**Results:** Benign epithelial component shows the same immunophenotype of normal epithelium. Table 1 and 2 show the immunoprofile of the sarcomatous component. CD117, CD10, laminin  $\gamma$ 2, HER2, and CD99 were negative in all the tumors.

**Conclusions:** 1) Biphasic tumors of the uterus and breast (adenosarcoma and malignant phyllodes tumor) beside morphology also share similar immunophenotype. 2) Different expression of estrogen and progesterone receptors in malignant mesenchymal components of adenosarcomas and malignant phyllodes tumors may be related to the expression of these hormonal receptors in the normal stroma of the uterus and breast.

Tumor type	ER	PR	Ki-67 >10% and <50%	p53 $\geq$ 50%	$\beta$ catenin cytoplasmatic	nuclear
Phyllodes Tumors	0/11	0/12	6/11	1/11	7/11	5/11
Adeno-sarcoma	9/9	8/9	3/9	1/11	4/9	4/11

Tumor type	CD 34	Collagen IV	HHF 35	Calponin
Phyllodes Tumor	1/11	3/11	6/11	0/11
Adenosarcoma	1/9	3/11	7/9	1/9

**792 Identification of Cell Cycle Regulatory Molecules as Biomarkers in Cervical Cancer Using Gene Expression Profiling**

K Astbury, CM Martin, P Smyth, JJ O'Leary. Coombe Women's Hospital, Dublin 8, Ireland; Trinity College Dublin, Dublin 2, Ireland.

**Background:** Biomarker discovery has enhanced diagnostic accuracy in many diseases including cervical cancer. Immunohistochemistry has demonstrated that disease biomarkers can also be used to aid in diagnosis of premalignant disease conditions such as cervical intraepithelial neoplasia. Gene expression profiling has revolutionised the process of biomarker discovery, allowing assessment of thousands of potential biomarkers simultaneously. In addition, it facilitates identification of interactions between genes, thus providing new insight into pathways of disease development.

**Design:** CaSki, C33A and HeLa cell lines, obtained from the ATCC, were grown in recommended media with 10% fetal bovine serum and underwent serial passages. Cells were harvested for RNA extraction at each passage. Total RNA was extracted using the RNeasy Minikit from Qiagen, with on-column DNA digestion. RNA quality was confirmed by gel electrophoresis. Normal cervical total RNA was obtained from BioChain. 5 $\mu$ g total RNA from 3 passages of each cell line and 5 $\mu$ g total normal cervix RNA in triplicate was labelled with digoxigenin using a 2 step RT-IVT approach and hybridised to Applied Biosystems human genome survey microarrays as per the manufacturer's protocol. Gene expression profiles were validated by RT and quantitative real time PCR using ABI Gene Expression TaqMan assays.

**Results:** Data analysis was performed using Spotfire software. All samples were normalised and p values were calculated using t tests. 6325 genes were found to be significantly differentially expressed on comparison of malignant (CaSki, C33A, HeLa)

to normal datasets, with 1285 being upregulated (fold change>2) and 5040 downregulated (fold change<0.5). Several cell cycle regulatory molecules such as p16INK4a, cdc6, mcms 3,4,5,8 and 10, geminin, cyclins A2 and B2 as well as components of the origin of recognition and anaphase promoting complexes were found to be significantly upregulated. Expression levels of a number of these targets, including p16INK4a, cdc6, mcm10 and Topo2a were confirmed by TaqMan PCR.

**Conclusions:** Disruption of normal cell cycle regulatory pathways is a common phenomenon in cervical cancer. While increased expression of several of these biomarkers has previously been demonstrated by immunohistochemistry, gene expression profiling identifies significant numbers of related molecules which are differentially expressed but whose roles as biomarkers remain to be elucidated.

### 793 Expression of the Steroid Receptor Coactivator AIB1 in Endometrial Carcinoma, Hyperplasia and Normal Endometrium Using Tissue Microarrays: Correlation with Clinicopathologic Parameters, Steroid Receptors and Her-2/neu

N Balmer, P Lyle, N Spoelstra, K Torkko, J Richer, M Singh. UCHSC, Denver, CO; Penrose Hospital, Colorado Springs, CO.

**Background:** The p160 steroid receptor cofactor (SRC) family, which includes AIB1, is of interest in endometrial carcinoma as hormonal therapy is a treatment option. Our aim was to analyze AIB1 expression in carcinoma, hyperplasia and normal endometrium and to compare this with the expression of ER-alpha, PRA, PRB and Her 2 neu and clinico-pathologic parameters.

**Design:** We performed immunohistochemistry (IHC) using two sources for the AIB1 antibody (AIB1 (Santa Cruz) and AIB1(BD Bio)). Steroid receptor and Her-2/neu IHC was also performed: ER-a (#M7047, Dako), PR-A (#M3569, Dako), PR-B (HPRab Neomarker, Labvision), Her-2/neu (A0485, Dako). In the tissue arrays, biopsy material from 88 patients diagnosed with endometrial carcinoma at our institute was included.

**Results:** There is a higher expression of AIB1 (with both antibodies) in endometrial carcinoma than hyperplasia (p<0.001 and 0.007) or normal endometrium (p<0.001 and <0.001). AIB1 (Santa Cruz) is lower in endometrioid (Type I) than non-endometrioid carcinomas (Type II) (p=0.03). AIB1 (BD Bio) expression correlates significantly with older age (p=0.003) and peri- or postmenopausal status (p=.002) and with higher grade (grade II and III) carcinomas (p=0.04). ER and PR exhibited higher expression in normal endometrium than carcinoma (p<0.0001 and 0.003), in stage I (p=0.02 and 0.004) and grade I tumors (p=0.01 and 0.03). PR expression was higher in <50 years (p=0.04). PR-B expression was higher in normal endometrium than carcinoma (nuclear: p<0.0001; cytoplasmic: p=0.014). Her-2/neu had higher expression in carcinoma than normal endometrium (p=0.0002) or hyperplasia (p=0.036). AIB1 (BD Bio) expression weakly correlated with ER (r = 0.30, p = 0.006). The strongest correlation was between ER and the PRB-nuclear scores (r = 0.52, p<0.0001).

**Conclusions:** We show 1) a strong correlation of AIB1 expression with endometrial carcinoma 2) a correlation between AIB1 (BD Bio) and ER in endometrial carcinoma, but no significant correlation between AIB1 and PRA or PRB. 3) AIB1 expression is associated with clinicopathologic parameters of poor prognosis. Future studies correlating AIB1 expression with response to hormonal therapy could further clarify the role this may play in guiding treatment for endometrial carcinoma.

### 794 Comparison of Inter and Intra-Observer Reproducibility of Evaluating Cervical Dysplasia in HE Stained and p16 Immunostained Sections

B Behmaram, P Kotov, Z Basir, AF Cafaro, L Novoa-Takara, VB Shidham. Medical College of Wisconsin, Milwaukee, WI.

**Background:** The histomorphological features that are used to evaluate cervical dysplasia are limited by their subjective nature. As reported before, grading of cervical dysplasia, especially in problematic cases, improves with the usage of p16. The impact of p16 on intra-observer and inter-observer reproducibility as compared to only hematoxylin-eosin (HE) stained sections, however, has not been evaluated.

**Design:** The HE and previously immunostained p16<sup>INK4A</sup> [Clone 16P04 (JC2), Cell Marque, Hot Springs, AR; dilution 1:40 using citrate buffer (PH: 6.0) 30 min. water bath 98-100°C] slides from 40 formalin fixed paraffin embedded cervical biopsies were reviewed. Each biopsy's HE and corresponding p16 slides were separated and randomized into two groups. Five pathologists reviewed each group three times over a period of several months. The established diagnostic categories (Negative, HPV, CIN1, CIN2 and CIN3) were used for HE. Only nuclear (+/-cytoplasmic) immunoreactivity for p16 was considered positive. The p16 was interpreted as follows: Negative, CIN1: positive in the lower 1/3, CIN2: up to mid 1/3, CIN3: extending to superficial 1/3 of the mucosa. If p16 immunoreactivity was associated with immature metaplasia, only strong, full thickness positivity was interpreted as CIN3, otherwise it was interpreted as CIN1. Kappa analysis was used to measure the strength of agreement between matched pairs of observations within and between observers. A Sign test was performed on the differences in paired Kappa between HE and p16.

**Results:** Both intra- and inter-observer reproducibility were greater for p16 than for HE, as shown by higher Kappa values for p16.

Intra-observer reproducibility			
	Kappa*	SD	Complete agreement (40 cases & 5 observers)
HE	0.366	0.0265	39%
p16	0.700	0.0225	68.5%

\*p=0.0002 (Sign test). Kappa for p16 greater than HE in 14/15 pairs

Inter-observer reproducibility			
	Kappa*	SD	Complete agreement (40 cases & 3 replicates)
HE	0.171	0.0153	8%
p16	0.461	0.0166	31%

\*p<0.0001 (Sign test). Kappa for p16 greater than HE in all 30 pairs

**Conclusions:** p16 immunoreactivity improves intra-observer and inter-observer reproducibility of interpretation and grading of cervical biopsies.

### 795 AKT Phosphorylation and PIK3CA Amplification Are Common in Cervical Neoplasia

BI Bertelsen, SJ Steine, R Sandvei, A Molven, OD Laerum. Haukeland University Hospital, Bergen, Norway; University of Bergen, Bergen, Norway.

**Background:** Cellular genetic impairment additional to high-risk HPV DNA integration in the epithelial cell genome is considered necessary for neoplastic development in the uterine cervix. Gain of chromosome 3q24-29 is commonly observed in cervical neoplasia. The putative oncogene PIK3CA located in this region at 3q26.3 encodes a phosphatidylinositol 3-kinase (PI3K). In a process reversed by PTEN, PI3K generates inositol phospholipids triggering AKT phosphorylation, which in turn effects tumor driving signals.

**Design:** We studied 46 specimens of formalin fixed, paraffin embedded cervical neoplastic tissue. The activation state of the PI3K-AKT pathway was assessed immunohistochemically using an antibody with specificity towards serine 473 phosphorylated AKT. In order to determine the possible molecular basis for changes in AKT phosphorylation, we assessed PIK3CA gene copy number using real-time polymerase chain reaction and examined the state of PTEN through immunohistochemistry and sequencing of all nine exons.

**Results:** AKT phosphorylation at serine 473 was found in 39 out of 46 examined specimens. PIK3CA gene copy number was 3 or more in 28 out of 40 successfully examined cases. Except of one case with an exon 9 V369I heterozygosity in a metastasis, all cases showed normal sequence of the PTEN coding regions. Immunohistochemical staining for PTEN was strong in all lesions.

**Conclusions:** We report an increased activation state of AKT kinase in cervical carcinogenesis. It may be accounted for by PIK3CA amplification, whereas PTEN mutation seems to be of little importance.

### 796 Tissue Expression of p16 in Benign and Malignant Endometria

R Bhargava, E Elishaev. Magee-Womens Hospital of University of Pittsburgh Medical Center, Pittsburgh, PA.

**Background:** p16 is strongly and diffusely expressed in endocervical adenocarcinoma. A few studies have suggested the usefulness of p16 in distinguishing endocervical from endometrial adenocarcinomas (Int J Gynecol Pathol. 2003;22:231-5 and Am J Surg Pathol. 2004;28:160-7). However, systematic studies analyzing benign and malignant endometrial tissues for p16 staining are lacking.

**Design:** Fifty-five endometrial carcinomas (39 endometrioid and 16 non-endometrioid), 5 complex atypical hyperplasias (CAH), and 10 benign endo-myometrial tissues were evaluated for p16 (Cell Marque, Hot Springs, AR) staining using a tissue microarray. Three tissue cores were sampled from each case. Based on intensity and amount of cellular staining, the results for p16 were categorized as follows: 0 (no staining), 1+ (weak staining or staining of <30% cells), 2+ (moderate to strong staining of 30-60% cells), 3+ (moderate to strong staining of 61-99% cells) and 4+ (strong staining of 100% of cells). In addition, a p53 (Ventana Medical Systems, Tucson, AZ) staining was also performed and the staining was categorized as positive (diffuse strong staining) or negative (less than diffuse staining).

**Results:** All benign tissues, CAH, majority of endometrioid and occasional non-endometrioid carcinomas showed 0 to 2+ staining with p16.

	p16 (score 0)	p16 (score 1+)	p16 (score 2+)	p16 (score 3+)	p16 (score 4+)	Total
Benign endo-myometrium	1	7	2	0	0	10
Complex atypical hyperplasia	0	3	2	0	0	5
Endometrioid adenocarcinoma	0	25	9	3	2	39
Non-endometrioid adenocarcinoma	1	2	0	4	9	16
Total	2	37	13	7*	11*	70

\*Includes 2 endometrioid FIGO grade 2, 1 endometrioid FIGO grade 1, 1 serous, 1 clear cell, 1 malignant mixed tumor, and 1 undifferentiated carcinoma.\*Includes 6 serous, 1 mixed serous and clear cell, 1 clear cell, 1 undifferentiated carcinoma, and 2 endometrioid FIGO grade 3 carcinomas.

Among the p16 3+ and 4+ positive cases, p53 positivity was seen in all serous carcinomas except one. All other non-serous carcinomas were negative for p53. p53 staining was seen in 2 endometrioid carcinomas with 1+ staining for p16.

**Conclusions:** Diffuse strong (4+) staining with p16 is seen predominantly in non-endometrioid carcinomas with serous morphology; however, occasionally other tumor types including endometrioid adenocarcinomas can also show 4+ staining. Caution is advised in diagnosing a tumor as endocervical primary based on p16 staining alone. P53 positivity is limited to serous carcinoma and occasional high grade non-serous carcinomas and *per se* has no correlation with p16 staining.

### 797 Adenofibroma of the Fallopian Tube: A Common Neoplasm Arising from the Fimbria

V Bossuyt, F Meeiros, CP Crum. Brigham and Women's Hospital, Boston, MA.

**Background:** Fallopian tube (FT) adenofibromas (AF) are considered rare; the majority are incidental findings. The true incidence of these benign neoplasms is not known due to the fact that the FT is not routinely completely sampled. To determine a more precise estimate of the histologic spectrum and prevalence of these neoplasms, we retrieved a series of tubal AF and determined the frequency of these tumors in a consecutive series of completely sampled FTs.

**Design:** The histology of all tubal AF diagnosed in a 1 year period was reviewed. The departmental pathology database was searched for specimens in which the FTs were submitted and examined in toto. Cases associated with tubo-ovarian malignancy or inflammatory disorders and with ovarian neoplasia were excluded. Cases associated with ovarian AF were evaluated separately. All hematoxylin and eosin-stained sections were reviewed. The diagnosis of AF was based on the presence of dense, interlacing

bundles of collagen, which contrasted with the organized sub-epithelial collagen of the plica and the orderly smooth muscle in the muscularis and round ligament, associated with an epithelial component. Findings were subdivided into 2 categories. The 1st consisted of tubal AF measuring at least 3 mm. The 2nd consisted of localized sub-epithelial stromal changes, in an area less than 3 mm, characterized by hypercellularity and dense, interlacing bundles of collagen, with or without small glands.

**Results:** Our search yielded 6 tubal AF diagnosed over a 1 year period. The mean age of these patients was 56 (range 49 to 67). The tubal AF were incidental findings ranging in size from 3 to 7 mm, all located in the fimbria. Only 1 was associated with an ovarian AF. Ninety consecutive cases were reviewed, of which 26 (29%) contained one of the above described changes. All were confined to the fimbria. AF measuring at least 3 mm were identified in 9 (10%) cases. Only 3 (12%) tumors exceeded 1 cm. Subtle lesions less than 3 mm were present in 20 cases. In 7 cases these lesions were bilateral, in 10 they were multiple, and in 3 they were associated with a larger AF. Three of 12 cases of ovarian AF (25%) were associated with tubal AF measuring at least 3 mm.

**Conclusions:** Tubal AF arise distinct from ovarian AF and predominate in the fimbria. The more subtle sub-epithelial stromal changes that typify some tubal AF are also limited to the fimbria. The latter observation underscores the differences between the fimbria and remainder of the FT mucosa and identifies a tumor pathway (AF) that the fimbria shares with the ovarian cortex.

#### 798 Osteopontin (OPN) Is Colocalized with the Adhesion Molecule CEACAM1 in the Extravillous Trophoblast of the Normal Placenta and in Gestational Trophoblastic Diseases and Enhances Invasion of CEACAM1-Expressing Placental Cells

J Briese, M Oberndorfer, C Petschnik, HM Schulte, A Makrigiannakis, T Loning, AM Bamberger. University Clinic Hamburg-Eppendorf, Hamburg, Germany; Hamburg, Germany; University Crete, Heracleon, Greece.

**Background:** The human placenta is a complex tissue with multiple endocrine functions and a unique capacity for rapid proliferation but tightly controlled invasion. The extracellular glycoprotein osteopontin (OPN) could be implicated in regulating implantation and placentation by promoting cellular migration and invasion in a placenta-specific fashion and has been shown to contribute to tumorigenesis in several types of cancers. CEACAM1 is an adhesion molecule, which we have recently found to be expressed at the maternal-fetal interface with a localization to the extravillous trophoblast (EVT) and to be potentially implicated in trophoblast invasion.

**Design:** In the present study, immunohistochemistry and immunofluorescence with specific antibodies were performed to investigate the expression pattern and cell-type specific localization of OPN in the human placenta and gestational trophoblastic diseases (GTD) and to correlate it with the expression of CEACAM1. In addition western blot was performed on isolated trophoblast cell populations and matrigel invasion assays were used for an in vitro model of hybridoma cells.

**Results:** All placentas presented very strong expression of OPN in the EVT, where it is colocalized with CEACAM1 and in cytotrophoblast (CT) of the first trimester. In GTD OPN in correlation with CEACAM1 could be found in hydatidiform molar samples, PSN, as well as in PSTT but only partially in choriocarcinomas. Western blot analysis also demonstrated strong OPN expression in the EVT cells with invasive phenotype in primary culture. To investigate the regulation of trophoblast invasion, EVT hybridoma cells transfected with CEACAM1 have been treated with OPN and shown increased invasiveness in comparison to those without treatment.

**Conclusions:** The present study shows the OPN expression pattern in the human placenta and in trophoblastic lesions. Colocalisation of OPN and CEACAM1 in both indicates that they might act as a functional complex to regulate invasiveness. Using an in vitro model with CEACAM1-expressing EVT-based hybridoma cells we could demonstrate increased cellular invasiveness after OPN treatment and could find a confirmation for a probable functional link between OPN and CEACAM1 in regulating trophoblast invasion.

#### 799 Methylation of p16: A Possible Very Early Event in Endometrial Cancer Development

R Broadus, S Xie, G Mutter. MD Anderson Cancer Center, Houston, TX; Brigham and Women's Hospital, Boston, MA.

**Background:** We have previously shown that methylation of a number of genes, including known tumor suppressor genes, is a common event in endometrioid and non-endometrioid endometrial cancer. Women with anovulatory cycles and women taking Tamoxifen are two populations with a slightly increased risk of developing endometrial cancer, most likely due to abnormal estrogenic stimulation of the endometrium. Currently, there are no tissue biomarkers to indicate which individuals in these populations at risk may be particularly susceptible to endometrial cancer development. We hypothesized that endometrial gene methylation would be present in at least a subset of these at-risk patients.

**Design:** DNA was extracted from formalin-fixed, paraffin-embedded sections of endometrioid and non-endometrioid endometrial cancer (n=118), endometrial biopsies from women with anovulatory cycles (n=28), and endometrial biopsies from women taking Tamoxifen for the prevention/treatment of breast cancer (n=26). The anovulatory endometrium was characterized microscopically by a disordered proliferative pattern in which proliferative-type glands were cystically dilated and irregularly shaped. The endometrial biopsies from women taking Tamoxifen were small, benign endometrial polyps or normal endometrium. Methylation-specific PCR was performed for the genes p16, MINT31, COX2, and DAPK (death associated protein kinase, a pro-apoptotic gene).

**Results:** Methylation of p16, which was present in 44.9% of endometrial cancers, occurred in a similar percentage (35.7%, p=0.4) of the anovulatory endometrial biopsies. However, methylation of p16 in the Tamoxifen biopsies occurred in only 19.2% of cases (p=0.02). MINT31, COX2, and DAPK were methylated in 33.1%, 43.2%, and 33.9%,

respectively, of endometrial cancers. These genes were only occasionally methylated in both the Tamoxifen and anovulatory groups.

**Conclusions:** Methylation of p16, MINT31, COX2, and DAPK were all relatively common in endometrioid and non-endometrioid histotypes of endometrial cancer. However, only p16 was methylated in the endometrial biopsies from women with anovulatory cycles. Interestingly, there was significantly less frequent methylation of p16 in the Tamoxifen-treated endometrial biopsies, even though Tamoxifen is known to be an estrogen agonist in the uterus. For patients with anovulatory cycles, analyzing p16 methylation status may potentially provide clues as to individuals who are at risk for developing endometrial cancer.

#### 800 Expression of Poly(ADP-ribose) Polymerase (PARP) in Ovarian Serous Carcinoma

H Brustmann. Thermenklinikum Moedling, Moedling/Vienna, Lower Austria, Austria.

**Background:** Poly(ADP-ribose) polymerase (PARP) is mainly located in the nucleus, catalyzes poly-ADP-ribosylation, and is associated with a variety of biological events such as DNA repair, cell proliferation and malignant transformation. The aim of this study was to evaluate PARP immunoreactivity in a cohort of ovarian serous carcinomas (OSC) by immunohistochemistry, and to compare it with MIB-1 as well as p53 immunoreactivity and clinicopathologic variables.

**Design:** Formalin fixed, paraffin-embedded tissue sections of 50 OSC were immunostained with monoclonal antibodies against PARP (Novocastra) as well as MIB-1 and p53 (DAKO) using a standard immunohistochemical method (Vectastain Universal Elite ABC Kit, Vector Laboratories, CA). Immunostaining for PARP was scored concerning approximate percentage of tumor cells and relative staining intensity, and categorized as negative and weak, moderate or strong. MIB-1 and p53 were evaluated in 1000 nuclei; MIB-1 labeling indices (LIs) were expressed as the percentage of reactive nuclei, p53 was considered positive if at least 10% of cells showed positive nuclear staining.

**Results:** All cases displayed PARP immunoreactivity; 12 cases (24%) were scored as moderate, and 38 cases (76%) as strong. PARP immunoreactivity increased with FIGO stage (P=0.0075, chi-square test), but not with grade (P=0.1495, chi-square test). Strong PARP immunoreactivity was related with high MIB-1LIs (P=0.0102, unpaired t-test), p53 positivity (P=0.0141, Fisher's exact test), FIGO stage III (compared with stage I and II taken together, P=0.002, Fisher's exact test), and poor outcome (P=0.0196, logrank test). High MIB-1LIs were correlated with dismal prognosis (P=0.0002, logrank test), p53 positivity was not (P=0.3835, logrank test).

**Conclusions:** PARP immunoreactivity is frequently upregulated in OSC, correlated with prognosis, high FIGO stage, proliferation and p53 positivity. PARP expression may serve as a marker of aggressive tumor behavior in OSC.

#### 801 HNPCC-Related Endometrial Carcinomas Show a High Frequency of Non-Endometrioid Types and of High FIGO Grade Endometrioid Carcinomas

ML Carcangiu, T Dorji, P Radice, L Bertario, P Sala. Istituto Nazionale Tumori, Milan, Italy.

**Background:** Although endometrial carcinoma represents the extracolonic malignancy most frequently detected in HNPCC women, the histopathologic features of these tumours have not yet been well characterized.

**Design:** HNPCC-related endometrial carcinomas were diagnosed in 126 women from 133 HNPCC families (Amsterdam Criteria I/II and suspected HNPCC) enrolled in the Hereditary Colorectal Tumours Registry at the National Cancer Institute of Milan. Histologic slides were available for review in 41 cases (mean age, 49.6 years). These tumors were evaluated for the following pathologic features: tumour histologic type, FIGO grade and stage, mucinous differentiation, vascular invasion and chronic inflammatory infiltrate.

**Results:** We identified 22 (53.6%) pure endometrioid carcinomas (EC) and 19 (46.3%) non-endometrioid carcinomas (NEC) with or without an associated endometrioid component. The NEC group was composed of 11 clear cell carcinomas (6 associated with an EC component), 6 serous carcinomas, 1 MMMT, and 1 small cell neuroendocrine carcinoma admixed with an endometrioid component). Among the pure EC, there were 5 FIGO grade I, 10 grade II, and 7 grade III tumors. Mucinous differentiation was seen in 3 EC and 2 NEC. Vascular invasion was present in 5 EC and in 13 NEC. FIGO stages for the pure EC were 5 (23%) Stage IA, 14 (64%) Stage IB, 1 Stage IC and 2 Stage IIB, whereas FIGO stages for NEC were 6 (31%) Stage IB, 2 Stage IC, 1 Stage IIA, 3 Stage IIB, 3 Stage IIIA, and 4 Stage IIIC. In 13 patients (8 with EC and 5 with NEC), the uterine tumor showed an association with colorectal cancer. Among these, the detection of the uterine cancer had preceded the diagnosis of colorectal cancer in 6 cases.

**Conclusions:** 1) The frequency of NEC (pure or admixed with EC) is higher among uterine tumors in HNPCC women than among women with sporadic uterine tumors, despite the tendency of HNPCC-related tumors to occur in younger patients, an age group in which NEC are distinctly rare; 2) Pure EC occurring in HNPCC women tend to be of higher FIGO grade than their sporadic counterparts; 3) Both EC and NEC in HNPCC women show FIGO stage distributions similar to those seen in the corresponding sporadic cases; 4) As a group, HNPCC-related uterine carcinoma is more likely to exhibit microscopically aggressive features than its sporadic counterpart (greater number of cases with a NEC component and higher FIGO grades among the pure EC), but from this study it does not emerge as a distinct pathologic subtype of uterine carcinoma.

#### 802 Microsatellite Instability by Immunohistochemistry in Mucinous Endometrial Metaplasia and Mucinous Endometrioid Adenocarcinoma

HP Cathro, NM Taylor, MT Galgano. University of Virginia, Charlottesville, VA.

**Background:** While ~20-30% of endometrioid adenocarcinomas (EAC) demonstrate microsatellite instability (MSI), only ~1% of normal/anovulatory endometria do. Within endometrial curettings, many mucinous metaplasias (MEM) are extensive in volume

with moderate architectural complexity but mild cellular atypia. Predicting which of these intermediate variants of MEM are associated with EAC is often problematic, even when unaccompanied by atypical hyperplasia (AEH). The aim of this study was to better characterize the relationship between MEM, AEH and mucinous EAC.

**Design:** Eleven MEM (7 associated with AEH) and 30 EAC (10 with MEM on biopsy and 19 mucinous EAC without previous MEM) were examined with antibodies directed towards HSMH2 and HMLH1. Positive internal controls such as adjacent normal endometrium or stromal cells were used wherever possible. MSI markers were scored negative if no or only rare metaplastic or tumor nuclei stained. Staining was assessed in areas of MEM and not AEH, as determined histologically.

**Results:** Of 7 total MEM-associated carcinomas with AEH on curettings, 3 lacked myometrial invasion (43%). Loss of HSMH2 expression was not identified in any MEM or mucinous EAC and in only 1/10 MEM-associated carcinomas (10%). Loss of HMLH1 expression was identified in 1/11 MEM (9%), in 4 MEM-associated carcinomas (40%) and in 7/19 mucinous EAC (37%). Two MEM-associated carcinomas with and 2 without AEH were among this group, and one of the latter had >50% myometrial invasion. This was the only tumor to lose expression of both MSI markers. None of 6 curettings taken prior to diagnosis of mucinous EAC had MEM on review. 5/7 (71%) mucinous EAC having lost HMLH1 expression had <50% myometrial invasion, in contrast to only 5/12 (42%) with normal expression of HMLH1.

**Conclusions:** The percentage of MEM with loss of expression of MSI markers was intermediate between that expected for normal endometrium and EAC. The percentage of MEM-associated carcinomas and mucinous EAC with apparent MSI was higher than expected for all types of EAC. Given the relative insensitivity of immunohistochemistry for detecting MSI, these figures are likely to be underestimated. Mucinous EAC with MSI appear to have lower rates of myometrial invasion than those without MSI. MSI may play an especially important role in the tumorigenesis of MEM-associated carcinomas and mucinous EAC, regardless of the presence of AEH.

### 803 Phosphorylated H2AX Expression in Cervical Neoplasia

T Chang, A Fahey, A Khramtsov, S Chmura, AG Montag. University of Chicago, Chicago, IL; Marquette University, Milwaukee, WI.

**Background:** H2AX is a unique isoform of the histone H2A that is phosphorylated by the kinases ATM, ATR and others in response to double stranded DNA (dsDNA) breaks. Phosphorylated H2AX (pH2AX) co-localizes with and provides a scaffolding for many of the components of DNA damage response, including BRCA1. Immunostaining for pH2AX is stoichiometrically proportional to the number of dsDNA breaks present, and has been used to approximate dsDNA breaks from radiation. Since genetic instability is a feature of tumors, it is likely that precancerous lesions and their tumors may harbor dsDNA breaks. The present study examines a series of untreated cases representing the spectrum of cervical carcinogenesis for evidence of dsDNA breaks by pH2AX staining.

**Design:** Biopsies and cervical cone specimens were retrieved from patients with no prior history of chemotherapy or radiation therapy, including reactive atypia (4), cervical dysplasia (4), CIS (15), and invasive squamous cell carcinoma (9). Five micron paraffin sections underwent microwave retrieval and were immunostained with antibody to phosphorylated H2AX (Cell Signalling). Controls included irradiated mouse tissue and a mouse embryonic fibroblast tumor xenograft previously knocked out for H2AX expression. Staining was scored as 0: absent, 1+: focal staining on 200x, 2+: staining recognizable on 100x, 3+: Staining easily recognized on 40X.

**Results:** Normal endocervical glands and unremarkable ectocervical epithelium were negative for pH2AX. Reactive atypia displayed focal pH2AX staining in the basal or parabasal layer. Dysplasia revealed nuclear foci in the mid-epithelium, with strong staining foci in the upper epithelium in cases with overt HPV changes. CIS varied from 1+ to 3+, with strong granular foci in nuclear chromatin as well as scattered nuclei with extensive staining in all layers of the epithelium. Invasive carcinoma had numerous nuclear foci staining 2 to 3+ in all nine cases.

Phospho H2AX expression in cervical neoplasia, staining intensity

	0	1	2	3	n=
Reactive atypia	2	2	0	0	4
Low grade dysplasia	0	1	2	1	4
Squamous CIS	0	9	5	1	15
Invasive carcinoma	0	0	4	5	9

**Conclusions:** pH2AX staining reveals a progressive increase of foci from dysplasia to invasive carcinoma, correlating with an increase in dsDNA breaks. The findings suggest genomic instability, initially from the effects of HPV proteins, and later possibly from accumulated mutations in other genes regulating cell cycle and apoptosis.

### 804 The Origin and Spatial Distribution of Chromosome 7q Deletion and Its Association with Tumor Growth in Large Uterine Leiomyomata

H Chen, ZM Budimlija, XM Zhang, MK Prinz, MA Perle, JJ Wei. New York University School of Medicine, New York, NY; Medical Examiners Office, New York, NY.

**Background:** Large uterine leiomyomata (L-ULM) are the major reason for hysterectomy due to unbearable symptoms and complications. L-ULM tend to grow faster and to contain more chromosomal anomalies than small ULM. The association of cytogenetic alteration with tumor growth is poorly understood. 7q deletion [del(7q)] is one of the most common non random chromosomal anomalies in ULM. In this study, the spatial distribution of del(7q) in association with the regional tumor activity was analyzed.

**Design:** A L-ULM (13 cm) with karyotype: 46,XX,del(7)(q22-q32)/46,XX was selected for the study. Tumor tissue sections from three dimensional axes of X, Y and Z, matched myometrium and a small leiomyomata (2 cm) were collected. Each axis is further serially divided into six zones from zone 1 of the periphery to zone 6 of the center. Duplicated tissue sections were prepared for 1) immunohistochemistry including the selected gene products ER, PR, MIB1, BCL2, VEGF and F8; and 2) genomic DNA to map del(7q) in 3 dimensions with the mapping pair primers of D7S479, D7S501 and D7S518. The

fluorescent labeled PCR products were visualized by an ABI 3700 sequencer and analyzed by genotype 2.0 software.

**Results:** The cytogenetic analysis revealed the abnormal cell population with del(7q), and also karyotypically normal (46, XX) cells. Molecular genetic analysis by DNA markers from the 7q21-31 region illustrated that most tissue sections from the central tumor and one tissue section from the peripheral y axis had del(7q). All other regions were negative for del(7q). By comparing the del(7q) tumor zones with the selected gene activity, there was moderate negative correlation of del(7q) with vessel density, VEGF and ER/PR ( $r = -0.32 \sim -0.46$ ). There was no correlation of del(7q) with MIB1 and BCL2. **Conclusions:** The presence of del(7q) cell clones in a specific portion of the tumor suggests a late event during the tumor genesis. These cells were largely mapped to the central zone, where high level of hypoxia stress is evident. The del(7q) clones can survive in a stringent hypoxia environment and seem to have lower proliferation activity.

### 805 Expression of p14, p16 and E2F Proteins in Benign and Malignant Uterine Smooth Muscle Tumors: An Immunohistochemical Study

L Chen, AM Bunch, L Yerian, B Yang. The Cleveland Clinic Foundation, Cleveland, OH.

**Background:** The p16 and p14, two alternatively spliced genes sharing the same promoter, have been identified as tumor suppressor genes and act as negative cell cycle regulators. E2F is a downstream oncogenic protein of p16-Rb pathway. Disruption of the p16-Rb-E2F pathway has been reported in a variety of human cancers. Although p16 overexpression in uterine leiomyosarcoma has been reported recently, alteration of other elements in this signaling pathway has not been well assessed. Therefore, we have studied the expression of p16, p14, E2F and Ki67 proteins in 60 cases of benign and malignant uterine smooth muscle tumors.

**Design:** Expression of p16, p14, E2F, and Ki67 proteins were evaluated by immunohistochemistry, with Ventana automated benchmark, from hollandes-fixed and paraffin-embedded tissues in 13 leiomyomas (LM), 11 bizarre leiomyomas (BLM), and 35 leiomyosarcoma (LMS) and 1 smooth muscle tumor of uncertain malignancy (STUMP). The distribution, staining intensity and percentage of positive neoplastic cells were recorded.

**Results:** Overexpression of P16 was seen in all 35 cases of LMS, with 83% (29/35) cases displaying diffuse (>75%) and strong (+++) staining pattern. Diffuse and strong p16 immunoreactivity was also observed in 36% (4/11) of BLM. Although p16-positive stain was seen in 46% (6/13) of LM, 83% (5/6) cases showed focal (<5%) and lighter (+ -++) staining pattern. Different Ki67 labeling index exists among different smooth muscle tumors. Moderate to strong Ki67 staining was seen at least focally (>25%) in 40% (14/35) of LMS and 18% (2/11) BLM, but in none of LM cases. The difference is statistical significant between LMS and LM in Ki67 labeling index ( $p < 0.01$ ). One STUMP case showed strong and diffuse positivity for both p16 and Ki67. Strong and diffuse expression of p14 was not only observed in all the LMS, but also seen in majority of BLM and LM, despite the intensity was lighter in the latter. There is no significant difference in E2F immunostaining frequency and intensity among LM, BLM and LMS. **Conclusions:** Our study indicates that p16-Rb-E2F pathway is disrupted in the majority of LMS. Although strong and diffuse p16 immunostain is a hallmark of LMS relative to LM, it alone does not distinct LMS from BLM. Therefore, integration of p16 and Ki67 immunoprofiles with morphologic features is crucial in diagnostic interpretation. Overexpression of p14 and E2F in LM and BLM indicates that both p14 and E2F may be involved early in uterine smooth muscle tumorigenesis.

### 806 Immunohistochemical Expression of p16 and p53 in Uterine Serous Carcinoma and High-Grade Ovarian Serous Carcinoma

AG Chiesa, A Malpica, MT Deavers, RR Broaddus, EG Silva. MD Anderson Cancer Center, Houston, TX.

**Background:** p16 is of value in the distinction between usual endometrial and endocervical adenocarcinomas in biopsies, as part of a panel that includes vimentin, estrogen receptor, and carcinoembryonic antigen. However, its expression has not been studied in uterine serous carcinoma (USC) or ovarian high-grade serous carcinoma (O-HGSC). In this study, we analyze the immunohistochemical expression of p16 in such cases, and compare it with the expression of p53.

**Design:** Eleven cases of uterine serous carcinoma (USC) and 10 cases of ovarian high-grade serous carcinoma (O-HGSC) were retrieved from our files. H&E stained slides were reviewed in all cases. Immunohistochemical studies for p16 (clone 16P07, dilution 1:25, Neomarkers, Fremont, CA) and p53 (CONFIRM™ Anti-p53, clone DO7, prediluted, Ventana Medical Systems, Tucson, AZ) were performed using the avidin-biotin method. Percentage of positive cells and intensity of staining (strong vs weak) were recorded. p16 and p53 immunoreexpression results were compared.

**Results:** p16 was strongly expressed by 100% of tumor cells in 11/11 USC and in 5 / 10 O-HGSC. Lesser degrees of staining, ranging from 20 to 50% of tumor cells, some of them with weak intensity, were observed in 5 O-HGSC. p53 strongly stained 100% of tumor cells in 6/11 USC and in 3/10 O-HGSC. Lesser degrees of staining, ranging from no staining to 95% of tumor cells stained, although weak in some cases, were observed in 5/11 USC and in 7/10 O-HGSC. Results are summarized and compared in Table 1.

Tumor, # cases	p16: 100% cells, strong		p53: 100% cells, strong	
	p16 expression > p53	p53 expression > p16	p16 expression > p53	p53 expression > p16
USC, 11	11/11	6/11	5/11	0/11
O-HGSC, 10	5/10	3/10	5/10	2/10

**Conclusions:** 1) p16 diffusely stained all USC and 5/10 O-HGSC. 2) Because of the diffuse expression of p16 in USC, p16 should not be used to determine endocervical or endometrial origin in biopsies that contain serous carcinoma. 3) Awareness of these findings will also be helpful to avoid misinterpretation of immunoresults when attempting to use them to differentiate carcinomas of cervical origin from those of ovarian

origin. 4) The overexpression of p16, a tumor suppressor gene, is paradoxical. Although this is similar to observations made in carcinomas of other organs, the mechanism of p16 overexpression in serous carcinomas is not known.

### 807 Expression of D2-40 in Primary Peritoneal Serous Carcinomas, Ovarian Serous Carcinomas, Uterine Carcinomas and Sex Cord Stromal Tumors

*M Chivukula, M Kapali.* Magee-Womens Hospital of University of Pittsburgh Medical Center, Pittsburgh, PA.

**Background:** Primary peritoneal serous carcinomas (PPSC) are difficult to differentiate from metastatic ovarian serous carcinomas (OSC) histologically. Earlier on WT-1 or Wilms tumor gene has been shown by some studies as strongly expressed by OSC as well as by PPSC. D2-40 is a monoclonal sialoglycoprotein expressed in variety of tissues. It had gained importance recently as a marker for lymphatic invasion in malignant neoplasms. It is also expressed in mesothelial cells. It's utility in mesotheliomas was addressed by one study and found to be strongly expressed in these tumors (96%). In the same study, 65% of OSC expressed D2-40. The aim of our study is to determine if D2-40 immunostain can help to differentiate the PPSC from OSC. We also looked into its expression in other ovarian sex-cord stromal tumors (SST), Endometrial endometrioid carcinomas (EEC) and Uterine papillary serous carcinoma (EPSC) as well.

**Design:** We retrieved 59 cases of PPSC, 60 cases of OSC, 12 cases of endometrioid adenocarcinomas, 1 uterine papillary serous carcinoma and 2 sex-cord stromal tumors. 2 pathologists reviewed H&E slides separately; blocks were selected and stained with D2-40 immunostain (using Monoclonal mouse anti-human D2-40, Dako, clone: D2-40). D2-40 is a membranous as well as cytoplasmic stain. Scoring index was given as follows: 0 - No staining in 100% of tumor cells, 1+ - Weak cytoplasmic/membrane staining in 0-50% cells, 2+ - moderate cytoplasmic/membrane staining in 50-75% cells, 3+ - A strong complete membrane staining in 75%-100% cells.

**Results:** Our analysis based on D2-40 immunostaining pattern are shown in table-1  
**Conclusions:** 1) A majority of PPSC, EEC, EPSC and SST do not express D2-40 immunostain 2) About a half of OSC express D2-40. 3) Based on our results, we propose that D2-40 might be a useful marker to distinguish PPSC from OSC, along with other clinical parameters. 3) In future studies, molecular markers might serve as supportive tools along with immuno markers to distinguish these tumors. 4) Since majority of PPSC are negative, this marker may be helpful in distinguishing PPSC from mesotheliomas.

Immunostaining of D2-40 in PPSC, OSC, EEC, EPSC and SST

	0 (#/%)	1+ (#/%)	2+ (#/%)	3+ (#/%)
PPSC(N=59)	43 (73)	9 (15)	3 (5)	4 (7)
OSC(N=60)	33 (55)	5(8.3)	14 (23.3)	8 (13.3)
EEC(N=12)	10 (83.3)	1 (8.3)	0 (0)	1 (8.3)
EPSC(N=1)	1 (100)	0 (0)	0 (0)	0 (0)
SST(N=2)	2 (100)	0 (0)	0 (0)	0 (0)

### 808 Uterine Carcinosarcoma: Immunohistochemical Studies on Tissue Microarrays with Focus on Potential Therapeutic Targets

*D Cimbaluk, J Scudiere, J Rotmensch, AM Gown, P Bitterman.* Rush University Medical Center, Chicago, IL; PhenoPath Laboratories, Seattle, WA.

**Background:** Carcinosarcoma of the uterus is a highly aggressive tumor. Because of their rarity, investigations into the expression of potential therapeutic targets are limited. The aim of this study was to determine the expression of therapeutic targets in both the epithelial and mesenchymal components in 30 carcinosarcomas using tissue microarrays, for potential treatment strategy.

**Design:** We collected formalin-fixed, paraffin-embedded tissue blocks of carcinosarcoma of the uterine corpus resected from 30 patients who had undergone total abdominal hysterectomies at our institution between 1985 and 2005 (ages 38 - 83 years, mean 65.9 years). All hematoxylin-eosin stained sections from each tumor were reviewed to confirm the pathologic diagnosis. Two or three tissue cores from the paraffin-embedded tissue blocks were constructed into a tissue microarray. Sections were stained with monoclonal antibodies against HER-2, VEGF, c-KIT, COX-2, and EGFR. Unequivocal staining of at least 5% tumor cells was considered positive. For 2 cases, the HER-2 amplification was also examined by fluorescence *in situ* hybridization (FISH).

**Results:** Expression of HER-2, VEGF, c-KIT, COX-2, and EGFR in epithelial and mesenchymal components of uterine carcinosarcoma are summarized in the following table:

Therapeutic Target	# of Cases with Positive	
	Epithelial Components (%)	Mesenchymal Components (%)
HER-2	2 (6%)	0 (0%)
VEGF	30 (100%)	28 (93%)
c-KIT	0 (0%)	0 (0%)
COX-2	21 (70%)	5 (16%)
EGFR	9 (30%)	20 (67%)

By FISH, one of the two cases with HER-2 expression showed gene amplification (2.62).

**Conclusions:** High expression of VEGF suggests that novel drug therapies designed to inhibit angiogenesis could be effective to perhaps inhibit the growth and progression of both epithelial and mesenchymal components of uterine carcinosarcoma. The expression patterns of COX-2 and EGFR differed between the epithelial and mesenchymal components, indicating caution must be exercised in using these therapeutic modalities since only one component of the tumor expresses these markers. However, in combination these agents might offer greater therapeutic utility. HER-2 and c-KIT are poor therapeutic targets for uterine carcinosarcomas.

### 809 Chromosome 12p Abnormalities in Dysgerminoma of the Ovary and Its Biological and Diagnostic Implications

*P Cossu-Rocca, S Zhang, LM Roth, JN Eble, W Zheng, FW Abdul Karim, H Michael, RE Emerson, TD Jones, EM Hattab, L Cheng.* Indiana University, Indianapolis, IN; Universita di Sassari, Sassari, Italy; Yale University, New Haven, CT; Case Western Reserve University, Cleveland, OH.

**Background:** Dysgerminoma is the most common malignant ovarian germ cell tumor and shares histological and immunophenotypical features with its testicular counterpart, seminoma. Chromosome 12p abnormalities are genetic hallmarks of testicular seminomas. Little is known about these genetic changes in dysgerminoma.

**Design:** We performed dual color fluorescence *in situ* hybridization (FISH) analyses with a centromeric  $\alpha$ -satellite probe for chromosome 12 and a subtelomeric probe for 12p on paraffin-embedded tissue sections from 21 dysgerminomas and two gonadoblastomas.

**Results:** Chromosome 12p abnormalities were detected in 81% of dysgerminomas. 57% of cases had only isochromosome 12p and 5% had only 12p overrepresentation. 19% had both isochromosome 12p and 12p overrepresentation. Gonadoblastomas were negative for isochromosome 12p or 12p overrepresentation.

**Conclusions:** Chromosome 12p abnormalities are common in dysgerminoma of the ovary. FISH analyses for chromosome 12p abnormalities may be a useful diagnostic adjunct for confirming the diagnosis of dysgerminoma and for distinguishing it from non-germ cell malignancies that enter into the differential diagnosis.

### 810 PIK3CA Mutations in Endometrial Carcinoma: Correlation with KRAS and CTNNB1 ( $\beta$ -catenin) Mutations

*F Cruz III, MC Heinrich, C Le, T Bainbridge, CL Corless.* Oregon Health & Science University, Portland, OR.

**Background:** A number of gene alterations have been identified in endometrial carcinomas, but the oncogenesis of these tumors has not been fully elucidated. In the endometrioid variant, loss of PTEN function has been reported in up to 83% of cases. Mutations of *KRAS*, *BRAF* and *CTNNB1* ( $\beta$ -catenin) have also been identified. Activating mutations in *PIK3CA*, which encodes phosphatidylinositol-3 kinase (PI3K), have recently been described in carcinomas of the colon, breast and ovary. As PI3K and PTEN both regulate the AKT signaling pathway, we investigated the frequency of *PIK3CA* mutations in endometrioid carcinomas arising in the endometrium. *KRAS* and *CTNNB1* were also examined for comparison.

**Design:** Genomic DNA from 50 paraffin-embedded cases of primary endometrial carcinoma (45 endometrioid, 5 serous papillary) was screened for mutations in *PIK3CA* exons 9 and 20, *KRAS* exons 1 and 2, and *CTNNB1* exon 3, using a combination of PCR, denaturing high-performance liquid chromatography and direct sequencing. A tissue microarray containing 43 of the carcinomas was stained for  $\beta$ -catenin by routine immunohistochemistry.

**Results:** Among the endometrioid-type carcinomas, 22% contained a *PIK3CA* mutation (9/41; 2 in exon 9, 7 in exon 20), 14% had a *KRAS* mutation (6/44; all exon 1), and 13% had a *CTNNB1* mutation (6/46). Interestingly, there was no overlap between the *PIK3CA*, *KRAS*, and *CTNNB1* mutations. By immunohistochemistry, 33% (14/43) of the endometrioid tumors showed nuclear staining for  $\beta$ -catenin, including 5 of 6 *CTNNB1*-mutant tumors. No *PIK3CA*, *KRAS*, or *CTNNB1* mutations were detected in 5 serous papillary carcinomas.

**Conclusions:** Our findings suggest that mutations in PI3 kinase play a role in the development of a significant fraction of endometrioid carcinomas. Correlation with PTEN function will be of interest in these tumors. Alterations in *KRAS* and  $\beta$ -catenin may provide alternative oncogenic signals in smaller subsets of endometrioid carcinoma. *CTNNB1* mutations were found in less than half of tumors with nuclear  $\beta$ -catenin staining; therefore, other genes may be important in activating the WNT pathway in these cancers. Screening for mutations in *BRAF*, another kinase recently implicated in endometrial carcinogenesis, is underway and will be reported.

### 811 Endometrial Hyperplasia in Endometrial Polyps: Clinico-Pathologic and Follow-Up Findings

*D da Costa, K Mittal.* New York University School of Medicine, New York, NY.

**Background:** Endometrial polyps are a frequent cause for uterine bleeding. Often there are hyperplastic changes identified within the polyp. Whether these findings in polyps mirror findings in the non-polypoid endometrium is not well documented. The objective of this study was: 1) to evaluate findings in follow-up hysterectomy specimens following a diagnosis of complex atypical hyperplasia in endometrial polyps for possible significance in management strategies. 2) To identify findings that are predictive of the presence of endometrial hyperplasia in subsequent hysterectomy.

**Design:** All cases of endometrial polyps with hyperplasia were retrieved from the files of New York University Medical Center from 1993-2005. Those cases with follow up hysterectomy were selected for the study.

**Results:** The patient age ranged from 39-76 years. There were 31 cases of endometrial polyps with hyperplasia and follow up hysterectomy. Of these, 29 cases had complex hyperplasia with atypia while 2 cases had simple hyperplasia in the polyp. Of the 29 cases of complex hyperplasia, 8 cases had focal adenocarcinoma *in situ* (AIS). AIS is defined as foci of back to back glands (cribriform) involving an area of less than 2.1mm in diameter. In 12 out of 31 (38.7%) cases there was non-polypoid endometrium included with the polyp. In 6 of these 12 (50%) cases the endometrium showed evidence of either simple or complex hyperplasia. Of the 29 cases of complex hyperplasia within the polyp, 21/29 (72.4%) cases had hyperplasia of the non polypoid endometrium in hysterectomy specimens and adenocarcinoma was seen in 9/29 (31%) cases. Of the 8 cases with AIS within the polyp 3 (38 %) had myoinvasive adenocarcinoma, in contrast, in cases without AIS 4/21 (19%) had myoinvasive adenocarcinoma.



**Conclusions:** Vast majority of cases where hyperplasia was initially seen in a polyp have hyperplasia of non-polypoid endometrium on hysterectomy hence it is important to carefully search for areas of hyperplasia within a polyp. AIS within a polyp translates into a diagnosis of myoinvasive endometrial carcinoma in about 40% of cases on follow up hysterectomy. The presence of benign endometrium included with the polyp does not rule out carcinoma or hyperplasia on subsequent hysterectomy. Of the 6 such cases 2 had adenocarcinoma and 1 had atypical complex hyperplasia. The above findings also reinforce the need for hysterectomy especially in postmenopausal women with atypical complex hyperplasia in endometrial polyps even if the hyperplasia appears confined to the polyp.

### 812 Uterine Tumors Resembling Ovarian Sex-Cord Tumors: A Study of 14 Cases Showing a Diverse Phenotypic Profile

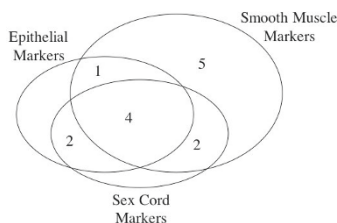
*L de Leval, D Waltregny, LM Dupuis, J Boniver, E Oliva.* CHU Sart-Tilman, Liège, Liège, Belgium; Massachusetts General Hospital, Boston, MA.

**Background:** Uterine tumors resembling ovarian sex cord tumors (UTROSCTs) are rare neoplasms of putative endometrial stromal origin solely composed of sex cord elements. The purpose of this study was to characterize the immunohistochemical profile of UTROSCTs in order to delineate whether this morphology reflects true sex cord-like differentiation and/or may represent other pathways of differentiation.

**Design:** Representative paraffin blocks from 14 UTROSCTs were selected after evaluation of H&E slides. All tumors had cords or trabeculae, tubules were seen in 9 and 2 had a retiform pattern. The cases were stained for smooth muscle markers (smooth muscle actin (SMA), desmin, smooth muscle myosin heavy chain (SMMHC), h-caldesmon, and histone deacetylase 8 (HDCA8)); epithelial markers (KL1 and EMA); sex cord markers (inhibin, calretinin, WT1); CD10, HMB45, Melan-A, S-100, and CD117. Intensity (1+,2+,3+) and percentage of stained tumor cells were recorded.

**Results:** Smooth muscle markers: SMA: 12/14 (mostly 2 to 3+ and >60%); desmin: 11/14 (mostly 2 to 3+ and >40%); SMMHC: 3/14 (1 to 2+, from 5 to 90%); h-caldesmon: 4/14 (2 to 3+ and mostly <10%); HDCA8: 9/14 (mostly 1 to 2+ and >40%). Epithelial markers: KL1: 7/14 (mostly 2 to 3+ and >40%); EMA: 3/12 (mostly 1+ and <30%). Sex cord markers: Inhibin: 4/14 (mostly 1+ and <5%); calretinin: 5/14 (mostly 2 to 3+ and up to 75%); WT1: 3/14 (mostly 1 to 2+, up to 70%). Others: CD10: 7/14 (mostly 2 to 3+ and >50%); HMB45: 0/12; Melan A: 3/12 (mostly 1 to 2+ and in vacuolated cells); S-100: 2/12 (1 to 3+ from 5 to 100%); CD117: 4/14 (1 to 2+, up to 100%).

**Conclusions:** UTROSCTs showed a diverse immunohistochemical profile. In some UTROSCTs the morphologic appearance may represent early smooth muscle differentiation as it is well known that sex cord areas are seen side by side to smooth muscle differentiation in endometrial stromal tumors. In others, stromal cells may have undergone true sex cord differentiation, thus expressing inhibin, calretinin and even melan-A. Negative HMB45 expression excludes a relationship to PEComa. Finally, of note, some UTROSCTs expressed CD117.



### 813 WT1 Expression May Differentiate Mullerian from Non-Mullerian Smooth Muscle Tumors

*MT Deavers, EG Silva, ED Euscher, J Liu, RB Broaddus, A Malpica.* The University of Texas MD Anderson Cancer Center, Houston, TX.

**Background:** While they are histologically similar, the diagnostic criteria for mullerian (in particular uterine) and non-mullerian smooth muscle tumors (SMTs) differ. Currently, there are no known markers that distinguish mullerian from non-mullerian SMTs. This can present a diagnostic problem when a patient presents with an extra-uterine SMT. Recently, WT1 expression in uterine leiomyomas (LM) has been reported. We undertook this study to determine the expression of WT1 in a variety of mullerian and non-mullerian SMTs.

**Design:** 42 cases of mullerian and 25 cases of non-mullerian SMTs with available blocks were retrieved from the files of our department (1985-2005). The mullerian cases included 16 LMs (11 uterine, 5 broad ligament/pelvic), 3 smooth muscle tumors of uncertain malignant potential (STUMP) (1 uterine, 1 vaginal, 1 pelvic), 3 benign metastasizing LM (lung), and 20 leiomyosarcomas (LMS) (11 uterine, 2 pelvic/adnexal, 7 metastases from the uterus). The non-mullerian cases included 2 LM, 1 STUMP, and 22 LMS (17 retroperitoneal, 5 lower extremity); the patients were 18 women and 7 men. The H & E slides were reviewed in all cases. WT1 immunohistochemical staining (6F-H2, 1:40, DAKO) by the ABC method was performed on sections of paraffin embedded tissue. Nuclear staining was scored semi-quantitatively: 0=negative, focal=<5%, 1+=6-25%, 2+=26-50%, 3+=51-75%, 4+=76-100%.

**Results:** All 16 of the mullerian LM (100%) were positive for WT1 (4+5, 3+3, 2+6, 1+2). All 3 mullerian STUMPs (100%) and all 3 benign metastasizing LM (100%) were positive (4+3, 3+0, 2+1, 1+2). The majority of mullerian LMS (12/20, 60%) were also positive: 5/11 uterine, 2/2 pelvic/adnexal, 5/7 metastases (4+3, 3+2, 2+2, 1+3, focal -2). None of the non-mullerian SMTs expressed WT1.

**Conclusions:** 1. WT1 is expressed by the majority of mullerian SMTs. While all of the LM, STUMP, and benign metastasizing LM cases were positive (100%), there was a

loss of expression in some of the LMS (60% positive). 2. None of the non-mullerian SMTs expressed WT1. 3. The differential expression of WT1 may be used to distinguish mullerian from non-mullerian SMTs. This may be of utility in women who present with SMTs at extra-uterine sites.

### 814 An Immunohistochemical Comparison of Ovarian Cancers Tested for Germline BRCA1/BRCA2 Mutations

*B Djordjevic, A Tone, H Begley, J Murphy, B Rosen, J McLaughlin, S Narod, PA Shaw.* University of Toronto, Toronto, ON, Canada.

**Background:** Ovarian carcinomas in *BRCA1/2* mutation carriers are predominantly serous, and high grade with frequent p53 overexpression. However, distinction of mutation-associated carcinomas from non-hereditary serous carcinoma is not possible using morphologic criteria only. This study aims to further characterize *BRCA1/2* tumors by immunohistochemical (IHC) expression of cell cycle regulators.

**Design:** Tissue microarrays using triplicate 0.6 mm. cores were created from paraffin blocks of 104 tumors with known germline mutation status. IHC was performed, and percentage of positive cells, staining intensity, and histoscores determined. Differences in expression were assessed for each antibody, comparing *BRCA1/2* tumors to tumors negative for mutations.

**Results:** All *BRCA1/2* tumors (n=37) and 43 *BRCA* negative cases (61%) were serous type. Positive IHC results for *BRCA1/2* EOC were: p53 81%; p27 89%; BAX 70%; Bcl-2 14%; p-p53 54%; MIB1 89%. Results for p53 (p=0.0008), p27 (p=0.029) and p-p53 (p<0.0001), but not BAX, Bcl-2, or MIB1, significantly differed from the non-carrier staining patterns. The differences in p27 (p=0.017) and p-p53 (p=0.0011) remained significant when compared to only serous cancers in non-carriers.

**Conclusions:** Ovarian tumors in *BRCA1/2* mutation carriers are more likely to be serous, and, when compared to the non-carrier group, have significantly increased p53 and p-p53 expression, and decreased p27 staining as assessed by immunohistochemistry. These differences cannot be entirely attributed to differing histologic types in the non-carrier group, as the increased expression of p-p53 and decreased expression of p27 remains significant when compared to only serous carcinomas in non-carriers.

### 815 Atypical Immature Metaplasia: p16 and Ki67 Immunoprofiling

*MA Duggan, M Akbari, AM Magliocco.* University of Calgary, Calgary, AB, Canada.

**Background:** The term Atypical Immature Metaplasia (AIM) is misleading as some of the atypical proliferations of immature squamous epithelium are actually a low or high grade squamous intraepithelial lesion (LSIL and HSIL). Using, strict pathology criteria, 35% of lesions reported as AIM in the Calgary Health Region (CHR) were corroborated (true AIM), the rest were either an SIL (32%) or negative-benign (33%). Evaluation of p16 and Ki67 expression as markers of HPV and cell proliferation respectively may assist in the assessment of these atypical proliferations and allow classification using standard reporting terminology.

**Design:** All cases reported as AIM from the CHR regional colposcopy service in the year 2000 were retrieved from the files of the regional laboratory. The AIM slides were stained with P16INK4a Ab-7 Clone 16P07 (Lab Vision Corporation, CA, U.S.A.) and MIB1 (Dako, Ont. Ca.) using standard immunoperoxidase techniques. The atypical area was reviewed and marker expression of positive or negative, focal or diffuse and level of epithelial staining was evaluated. Ki67 index was calculated. The immunoprofile of each antibody both separately and combined was correlated with the review diagnoses.

**Results:** From 172 cases, 163 had sufficient tissue for p16, and 153 for MIB1 staining. A review diagnosis of HSIL correlated with high rates (80%) of diffuse p16 positivity or a high (51.6%) Ki67 index and benign diagnoses had low (35%) rates of focal p16 positivity or a low (10.6%) Ki67 index (p<0.05). Lesions reviewed as HSIL were more frequently positive with both antibodies, whereas those revised to benign were more frequently negative (p<0.05). The profiles of the remaining diagnoses were not significantly different. Negative showed no p16 staining or a low (3%) Ki67 index. The AIM and LSIL profiles were similar. They showed moderate (53%) rates of focal p16 positivity or a low (8%) Ki67 index. With both antibodies, the profile was mixed and encompassed all possible staining combinations.

**Conclusions:** Amongst lesions reported as AIM in this health region, p16 and Ki67 immunoprofiling are useful in the characterization of atypical proliferations that are an HSIL or benign. The similarity of the immunoprofile of LSIL with lesions revised to AIM suggests true AIM is a type of LSIL and should be classified as such.

### 816 Atypical Immature Metaplasia: Longitudinal Follow up and Outcome Predictors

*MA Duggan, M Akbari, AT Magliocco.* University of Calgary, Calgary, AB, Canada.

**Background:** The term Atypical Immature Metaplasia (AIM) is misleading as some of the atypical proliferations of immature squamous epithelium are actually a low or high grade squamous intraepithelial lesion (LSIL and HSIL). Additionally some are associated with SIL and some may progress to SIL. Correlates of outcome have not been described.

**Design:** All cases reported as AIM from the Calgary Health Region's colposcopy service in the year 2000 as well as all follow up cervical pathology over the ensuing 2 years were retrieved from the files of the regional laboratory. The slides were reviewed and the AIM reclassified using published criteria. The AIM slides were stained with P16INK4a Ab-7 Clone 16P07 (Lab Vision Corporation, CA, U.S.A.) using standard immunoperoxidase techniques. The frequency of coincidental SIL and progression to SIL of lesions reclassified as AIM was determined and the p16 status was correlated with outcome.

**Results:** From 172 cases, 163 had sufficient tissue for p16 staining. The review diagnoses were 3 (1.7%) normal, 54 (31.3%) benign, 60 (34.8%) AIM, 43 (25%) LSIL, 10 (5.8%) HSIL, and ungradeable SIL in 2 (1.1%). Amongst the 60 AIM, 43 had AIM as the only pathological abnormality. LSIL and HSIL were coincidental in 13 (21.7%) and 4

(6.7%) cases respectively. Follow up was available for 32 (74.4%) of the 43 AIM. The follow up was 4 (9.3%) negative, 4 (9.3%) benign, 3 (6.9%) AIM, 16 (37.2%) LSIL and 5 (11.6%) HSIL. P16 positivity correlated with development of SIL within two years (p<0.05).

**Conclusions:** AIM in this health region is over reported as only 35% satisfied the published criteria. Approximately 28% of AIM is associated with SIL and 49% progresses to SIL within two years. P16 staining is useful in identifying the subset of AIM that will progress.

### 817 Molecular Genetic Evidence Supporting the Neoplastic Nature of the Leydig Cell Component of Ovarian Sertoli-Leydig Cell Tumor

*RE Emerson, M Wang, LM Roth, W Zheng, FW Abdul-Karim, F Liu, TM Ulbright, JN Eble, L Cheng.* Indiana University School of Medicine, Indianapolis, IN; Yale University, New Haven, CT; Case Western Reserve University, Cleveland, OH; Women & Infants Hospital and Brown Medical School, Providence, RI.

**Background:** Sertoli-Leydig cell tumors (SLCT) comprise less than 1% of ovarian tumors. The nature of the Leydig cells has been a subject of controversy and it is unclear whether they are clonally related to the neoplasm or instead proliferate as a non-neoplastic response to the Sertoli-cell component.

**Design:** Eleven ovarian SLCT were identified and hematoxylin and eosin and unstained sections were prepared from formalin-fixed, paraffin-embedded tissue blocks. Tissue samples were microdissected from normal tissue, the Sertoli cell component, and the Leydig cell tumor component using the laser capture microdissection method. If present, tissue was also obtained from any heterologous component. Genomic DNA was extracted from the samples and polymerase chain reaction was used to amplify polymorphic sites at 5 loci: D16S402, TP53, IFNA, D17S855, and D11S1318. X-chromosome inactivation (HUMARA) analysis was also performed.

**Results:** LOH and/or nonrandom X-chromosome inactivation was observed in at least 1 of the 5 amplified loci in the Leydig cell component of 10 of the 11 tumors. LOH and nonrandom X-chromosome inactivation patterns of the Sertoli cell component and Leydig cell component were compared. Concordant allelic loss and/or matching X-chromosome inactivation patterns were observed in 8 (73%) of the 11 tumors. In 3 of these tumors similar LOH or X-chromosome inactivation was observed at 1 site. In 5 tumors similar LOH and/or X-chromosome inactivation was observed at 2 sites. Three tumors had heterologous components. The heterologous components similarly shared LOH/X-chromosome inactivation with the Sertoli cell components at 1 site in 1 case and 2 sites in 2 cases.

**Conclusions:** These data suggest Leydig cell component of SLCT is neoplastic rather than reactive in nature, and shares a common clonal origin with its coexisting Sertoli cell component.

### 818 Molecular Genetic Evidence of Independent Origin of Serous Low Malignant Potential Implants and Lymph Node Inclusions in Patients with Ovarian Serous Tumors of Low Malignant Potential

*RE Emerson, M Wang, F Liu, WD Lawrence, F Abdul-Karim, L Cheng.* Indiana University School of Medicine, Indianapolis, IN; Women & Infants Hospital and Brown Medical School, Providence, RI; Case Western Reserve University, Cleveland, OH.

**Background:** Patients with ovarian serous tumors of low malignant potential (LMP) commonly, at the time of oophorectomy, are found to have LMP peritoneal implants. Less commonly, similar lesions are seen in pelvic or other lymph nodes, sometimes in association with endosalpingiosis. We compared these lesions to the ovarian LMP tumors in the same women to determine whether they are clonally related to the ovarian neoplasm.

**Design:** Fifteen patients with ovarian serous LMP tumors were identified and hematoxylin and eosin and unstained sections were prepared from formalin-fixed, paraffin-embedded tissue blocks. Tissue samples were microdissected from normal tissue, the ovarian LMP tumors, peritoneal LMP implants, and LMP inclusions within lymph nodes. Genomic DNA was extracted from the samples and polymerase chain reaction amplification was performed. X-chromosome inactivation (HUMARA) pattern analysis was performed.

**Results:** The pattern of X-chromosome inactivation could be determined in 13 of the 15 cases and nonrandom X-chromosome inactivation was observed in all but 1 of these cases. In 6 of these 12 cases, the LMP tumor at all sites shared a similar pattern of nonrandom X-chromosome inactivation. In these cases the shared inactivation pattern was seen at 2 sites (3 cases), 3 sites (1 case), four sites (1 case), or 7 sites (1 case). In 4 cases, shared patterns of nonrandom X-chromosome inactivation were seen at some, but not all sites (2 of 3 sites in 2 cases, 2 of 4 sites in 1 case, and 8 of 10 sites in 1 case). In the remaining 2 cases, opposite patterns of nonrandom X-chromosome inactivation were seen.

**Conclusions:** These data suggest that, in at least some cases, serous LMP tumor implants and lymph node inclusions arise independently from associated ovarian serous LMP tumors.

### 819 Clinicopathologic Features of Malignant Mixed Mullerian Tumors in Patients with and without Prolonged Survival

*ED Euscher, MT Deavers, L Ramondetta, A Malpica.* The University of Texas MD Anderson Cancer Center, Houston, TX.

**Background:** Uterine malignant mixed mullerian tumors (MMMT) are uncommon and are associated with a poor prognosis. This study presents the clinicopathologic features of patients (pts) living five years or more after diagnosis, and compares them to pts surviving less than five years.

**Design:** Cases of uterine MMMT from the surgical pathology files at M.D. Anderson Cancer Center (1970 to 1997) were reviewed. From review of the H&E slides, the subtype and percentage of carcinoma (CA), subtype and percentage of sarcoma (SA),

and composition of myoinvasive component as well as the presence/absence of vascular invasion (VI), extrauterine disease, and recurrent disease were recorded. Pts' ages, race, FIGO stage, time to recurrence, and follow up were obtained from the clinical record.

**Results:** Pathology material from 21 pts, average 66 yo, lived  $\geq$  5 yrs after diagnosis (107 mos follow up) and 21 pts, average 68 yo, treated over the same time period living < 5 yrs after diagnosis (26 mos follow up) was reviewed. There were 13 stage I, 3 stage II, 4 stage III, and 1 stage IV pts living  $\geq$  5 yrs and 8 stage I, 3 stage II, 5 stage III, 4 stage IV, and 1 unstaged pts living < 5 yrs. Composition of the primary tumor, metastases (mts), and recurrences for both groups is summarized in Tables 1, 2. For both groups, mixed CA was most frequent with serous carcinoma and grade 2/3 endometrioid carcinoma the most common subtypes. SA was most commonly homologous in both groups. Nine pts ( $\geq$  5 yrs) and 8 pts (< 5 yrs) had heterologous elements with rhabdomyosarcoma and chondroid differentiation most common. 38% pts living  $\geq$  5 yrs and 62% pts living < 5 yrs recurred with the average time to recurrence 48 mo and 11 mo, respectively.

**Conclusions:** Pts living  $\geq$  5 yrs after diagnosis had a lesser percentage of SA in the primary tumor, less frequent SA in the myoinvasive component, less frequent SA in the mts, no SA in the recurrences, fewer recurrences, and a longer average time to recurrence.

	Features of Cases $\geq$ 5-yr Survival			
	Carcinoma	Sarcoma	Both	Unknown
Avg % tumor	59	41	—	—
Myoinvasion	13 (62%)	1 (5%)	3 (14%)	4 (19%)
Metastases (n=5)	3 (60%)	0	2 (40%)	—
Recurrence (n=8)	6 (75%)	0	0	2 (25%), no bx

	Features of Cases with < 5-yr Survival			
	Carcinoma	Sarcoma	Both	Unknown
Avg % tumor	49%	51%	—	—
Myoinvasion (n=19)	6 (32%)	0	11 (58%)	2
Metastases (n=9)	4 (44%)	1 (11%)	4 (44%)	—
Recurrence (n=13)	5 (39%)	0	3 (23%)	5 (48%), no bx

### 820 Are There Morphologically Recognizable Precursor Lesions of Endometrial Clear Cell Carcinoma?

*O Fadare, SX Liang, W Zheng.* Yale University School of Medicine, New Haven, CT; State University of New York, Stony Brook, NY; Fudan University, China.

**Background:** In contrast to endometrioid and serous carcinomas of the endometrium, very little is known about the potential precursor lesions of endometrial clear cell carcinomas. In our routine practice, we have noted the presence of a spectrum of atypical glandular changes in the endometria adjacent to endometrial carcinomas with a clear cell component, which, based on current criteria, would not qualify for any specific designation. We hypothesize that these lesions represent the earliest morphologically identifiable precursor lesion to endometrial clear cell carcinomas and systematically characterize their clinicopathologic characteristics herein.

**Design:** Thirty archived cases of pure clear cell carcinomas (n=14) or mixed endometrial clear cell carcinomas with a >10% clear cell component (n=16) were retrieved and the "normal" endometria adjacent to the malignancies were evaluated in detail. Putative precursor lesions (PPL) were selected and the immunohistochemical expression of ki-67, Estrogen receptor (ER), Progesterone receptor (PR), and p53 was evaluated on all foci.

**Results:** 27 (90%) of the 30 cases showed atypical foci which were morphologically evident. These foci were typically isolated glands or surface epithelium (within an otherwise normal endometrial region) that displayed cytoplasmic clarity and/or eosinophilia, a spectrum of varying degrees of nuclear atypia, and whose totality of morphologic features conferred upon these foci a striking distinctiveness from the adjacent benign glands. The surrounding endometria were inactive in 25 of the 27 cases. The comparative immunoprofile of the PPL are outlined below:

Mean Values	p53 score (0-9 weighted scale; n=27)	Ki-67 (% cells; n=27)	ER (% cells; n=13)	PR (% cells; n=13)
Benign endometria	0	15	90	80
PPL	4.5	45	21.54	4.61
Carcinoma	6.2	63	11	4

**Conclusions:** The PPL described herein have a morphologic and immunophenotypic profile which appears to be distinct from both the benign endometria in which they reside and the adjacent malignancies. The high frequency of association of these lesions with endometrial carcinomas with a clear cell component, their frequent occurrence as isolated lesions within otherwise benign endometria, and their comparatively low degree of cytologic atypia in contrast to their associated invasive clear cell malignancies, argues in favor of our hypothesis that these may represent precursor lesions. Further research is required to more conclusively define the nature of these lesions.

### 821 Comparative Immunohistochemical Analysis of ER/PR Expression in Ovarian Sertoli Cell Tumors (SCT) and Adult Granulosa Cell Tumors (AGCT)

*MA Farinola, AM Gown, TS Barry, S Movahedi-Lankarani, R Vang.* The Johns Hopkins Hospital, Baltimore, MD; PhenoPath Laboratories, Seattle, WA.

**Background:** Immunohistochemical data on ER/PR expression in ovarian sex cord tumors, particularly Sertoli cell tumor, is limited and conflicting. Accurate immunohistochemical data may be helpful for the distinction from endometrioid tumors which commonly express ER/PR.

**Design:** Immunohistochemical staining for ER (clone SP1) and PR (clone SP2) was performed in 34 ovarian sex cord tumors: 16 SCT (2 pure Sertoli cell tumors, 2 well differentiated Sertoli-Leydig cell tumors [SLCT], 6 intermediate differentiation SLCT, 4 poorly differentiated SLCT, and 2 retiform SLCT) and 18 AGCT. Extent of expression was scored based on the percentage of positive cells: 0,  $\leq$  5%; 1+, 6-25%; 2+, 26-50%; 3+, 51-75%; and 4+, 76-100%. Intensity of staining was scored as weak or moderate to strong.

**Results:** ER and PR was expressed in SCT (56%, 75%) and AGCT (72%, 100%). Intensity of staining for ER in positive cases was weak in 69% AGCT vs. 11% SCT ( $p=0.01$ ); in the entire group of ER-positive cases, the same percentages of AGCT and SCT also showed ER and PR coordinate expression profiles in which the intensity of staining of ER was weaker than PR ( $p=0.01$ ). 89% AGCT vs. 31% SCT showed 3+ or 4+ staining for PR ( $p=0.001$ ). A coordinate expression profile of ER and PR showing PR>ER (extent of staining) was seen in 94% AGCT vs. 44% SCT ( $p=0.002$ ).

Table 1: Extent of staining in SCT

	0	1+	2+	3+	4+
ER	7 (44%)	1 (6%)	5 (31%) [1W]*	2 (13%)	1 (6%)
PR	4 (25%)	4 (25%) [1W]*	3 (19%)	2 (13%)	3 (19%)

Table 2: Extent of staining in AGCT

	0	1+	2+	3+	4+
ER	5 (28%)	5 (28%) [4W]*	5 (28%) [4W]*	2 (11%) [1W]*	1 (6%)
PR	0%	0%	2 (11%)	6 (33%)	10 (56%)

Key (Tables 1 and 2): \*, number of positive cases showing weak (W) intensity of staining

**Conclusions:** Both ovarian SCT and AGCT commonly express ER/PR although staining for ER is usually not diffuse; however, intensity of ER expression is stronger in SCT compared with AGCT, and intensity of staining for ER is weaker than PR more frequently in AGCT than SCT. Expression of PR is more common than ER in both tumors; however, the extent of PR expression is greater in AGCT than SCT. Also, coordinate ER/PR expression showing more extensive staining for PR than ER is more frequent in AGCT compared with SCT. These findings may be helpful in the distinction of AGCT and SCT in problematic cases and raise additional questions regarding fundamental differences in the possible role of ER/PR in the pathogenesis of both tumors.

## 822 Prognostic Features of Surgical Stage I Uterine Carcinosarcoma

SE Ferguson, C Tornos, RR Barakat, RA Soslow. Memorial Sloan Kettering Cancer Center, New York, NY.

**Background:** Uterine carcinosarcoma (CS) are aggressive neoplasms with overall survival rates of less than 30%. They are customarily separated into types harboring either heterologous or homologous mesenchymal elements, but this is not thought to be prognostically informative. There are no universally accepted clinical or pathologic prognostic factors other than tumor grade and stage; however, most CSs are high grade tumors that present at high stage. Our goal was to study clinicopathologic features of possible prognostic relevance in surgical stage I uterine CS.

**Design:** A retrospective clinical and histopathologic review was performed on all women with stage I uterine CS. Women were included if they had comprehensive surgical staging, including pelvic and paraortic lymph node dissection, and contained the classic histologic features of CS as described in the 2003 WHO classification of tumors.

**Results:** There were 47 women identified with uterine CS who were comprehensively surgically staged. The mean age at diagnosis was 66 years. The stage distribution was as follows: stage Ia, 6 (12.8%); Ib, 35 (74%); and Ic, 6 (13%). There was an even distribution of patients with heterologous (54%) versus homologous (46%) mesenchymal components. Mesenchymal elements included rhabdoid, chondroid and osteoid components. Forty percent of tumors were associated with lymphovascular space invasion (LVSI). The median progression-free survival (PFS) for the entire cohort was 32 months (95% CI, 7-57). There was a significantly worse PFS in women with heterologous compared to homologous CSs with a median time to recurrence of 15 versus 59 months ( $P = 0.002$ ). In addition women with heterologous CSs had significantly worse disease-specific survival compared to women with homologous CSs ( $P = 0.2$ ). The presence of LVSI was not prognostically significant.

**Conclusions:** Although patients with stage I CS fare better than those with advanced disease, survival rates in stage I CS remain significantly worse than historical survival rates for patients with other histologically high grade endometrial carcinomas. In contrast to those reported in earlier studies, many of which included suboptimally staged and/or high stage patients, our data indicate that the presence of heterologous sarcomatous elements is a powerful negative prognostic influence in stage I uterine CS.

## 823 Reevaluation of Cervical Biopsies Diagnosed as Low Grade SILs by H&E and HPV In Situ Hybridization

RL Fleshman, D Schubert, GJ Nuovo. Ohio State University Medical Center, Columbus, OH.

**Background:** Squamous intraepithelial lesions (SILs) of the cervix are due to infection by human papillomavirus (HPV), and represent the most common form of viral sexually transmitted disease (STD). The histologic features of low grade (LG) SILs can overlap with the histologic features of its mimics which can lead to an overdiagnosis of this STD.

**Design:** We examined 67 consecutive cervical biopsies that were diagnosed as LGSIL from the surgical files of Ohio State University Medical Center. We included 10 LGSIL cervical biopsies from the consult files of GJN that were documented by HPV in situ and 10 normal cervical tissues as documented by negative PCR for HPV. These were reevaluated blinded to the original diagnosis by H&E examination. Serial sections were also tested for HPV DNA (low risk and high risk) using the automated Ventana Medical Systems Benchmark system, which can detect most genital HPV and has a detection threshold of 10 copies/cell. Selected cases were studied by PAS stain for glycogen.

**Results:** Of the 67 case tissues, 47 (70%) were HPV positive by in situ hybridization. Reevaluation of the H&E findings led to a diagnosis of negative for SIL in 20/67 cases (29%), LGSIL in 30/67 (46%) and HGSIL in 17/67 (25%); many of the latter cases were considered to show areas of both LG and HGSIL. HPV DNA was detected in 30/30 cases called LGSIL on reevaluation, 16/17 (94%) of those cases called HGSIL, and 3/20 (15%) of the cases called negative for SIL. A PAS stain confirmed that most of the cases called negative for SIL on reevaluation that were HPV negative had halo-like cells strongly positive for glycogen. Thus, when combining the PAS/HPV and

reevaluation H&E results, 17/67 (25%) of the cases initially called LGSIL were not, but rather mimics. Each of the 10 LGSILs and 10 negative for dysplasia control cases were read the same on reevaluation and had an HPV detection rate of 10/10 and 0/10, respectively.

**Conclusions:** LGSIL can be overread on cervical biopsies. In this study prominent halo-like cells due to glycogen-effect of the surface keratinocytes was the most common cause. HPV in situ hybridization, which is both sensitive and specific for HPV detection, especially in low grade SILs due to their high HPV copy number, as well as the PAS stain can aid the pathologist in differentiating LGSILs from their mimics.

## 824 A Multicentric Study of Hormonal Therapy for Atypical Endometrial Hyperplasia and Endometrial Carcinoma in Young Women: Central Pathologic Review and Treatment Outcome

M Fukunaga, K Ushijima, H Tsuda, T Kamura, H Yoshikawa, A Sakamoto, T Kaku. Jikei University Daisan Hospital, Komaeshi, Tokyo, Japan; Kurume University, Kurume, Fukuoka, Japan; National Defense Medical University, Tokorozawa, Saitama, Japan; Tsukuba University, Tsukuba, Ibaraki, Japan; Kyorin University, Mitaka, Tokyo, Japan; Kyushu University, Fukuoka, Japan.

**Background:** Standard treatment for endometrioid adenocarcinoma, grade 1 (EA-G1) is abdominal hysterectomy with bilateral salpingo-oophorectomy in even in young women. Medroxyprogesterone acetate (MPA) is one of the options for patients who want to preserve childbearing potential. This therapy is based on its ability to inhibit DNA synthesis and induce regression of abnormal endometrial proliferation.

**Design:** Multicentric prospective study was carried out by 16 institutions in Japan. 29 patients with EA-G1 without myometrial invasion (stage Ia) and 14 with atypical endometrial hyperplasia (AEH) under 40 years of age were given MPA 600mg orally daily. Treatment was continued for 26 weeks. Endometrial tissue was histologically assessed every 8 weeks. All 112 specimens underwent a central pathological review by 3 pathologists using ISGP/WHO criteria. This study investigated the histologic effects and efficacy of treatment.

**Results:** Complete response, defined as the absence of any EA or hyperplasia, was initially observed in 15 patients with EA-G1 (52%) and 10 with AEH (71%). Partial response, defined as regression to non-atypical hyperplasia, was observed in 1 with EA-G1 (3%). Many cases showed also various metaplasia, decreased N/C ratio of epithelial cells and persistent glandular structures, leading to difficulties in the histologic evaluation of lesions. Kappa value of overall agreement in the central review was 0.51. To date, 9 pregnancies and 6 deliveries have been recorded after the therapy. 2 patients with EA-G1 and 2 with AEH developed recurrence between 9 to 16 months after the therapy.

**Conclusions:** The efficacy of fertility-sparing treatment using MPA for AEH and EA-G1 was proven by the prospective trial. Reproducibility of the histologic diagnosis must be improved and new diagnostic criteria applicable to hormonally affected EA or AEH are needed for the precise evaluation of fertility-sparing treatment outcome. Even in the responders, close follow up is required because of their substantial recurrence rate.

## 825 Reproducibility of the Diagnosis of Atypical Endometrial Hyperplasia (AEH) and Endometrioid Adenocarcinoma (EA) and Histologic Effects of Hormonal Therapy of Medroxyprogesterone Acetate (MPA)

M Fukunaga, H Tsuda, A Sakamoto, T Kaku, K Ushijima, T Kamura, H Yoshikawa. Jikei University Daisan Hospital, Komae, Tokyo, Japan; National Defense Medical University, Tokorozawa, Saitama, Japan; Kyorin University, Mitaka, Tokyo, Japan; Kyushu University, Fukuoka, Japan; Kurume University, Kurume, Fukuoka, Japan; University of Tsukuba, Tsukuba, Ibaraki, Japan.

**Background:** A Japanese multicentric group initiated a protocol to assess the efficacy of hormonal therapy of MPA with AEH and EA, grade 1 (EAG1). This study prospectively investigated the reproducibility of the diagnosis of lesions with or without hormonal effects by a referral hospital pathologist and a panel of 3 gynecologic pathologists.

**Design:** 52 women under 40 years of age with referral hospital diagnosis of AEH or EAG1 (stage Ia) based on biopsy or curettage were entered into this protocol. Available slides were assessed independently and interpreted by each panel pathologist using ISGP/WHO criteria. 44 patients of these were given MPA 600mg orally daily. The treatment continued for 26 weeks. Endometrial tissue was histologically assessed every 8 weeks by the panel. A total of 112 specimens were examined.

**Results:** In screening for the enrollment, the hospital diagnosis of AEH or EAG1 was supported by the majority of the panel in 9/17 and 25/35 cases, respectively. 7 cases with a hospital diagnosis of AEH were reclassified as EAG1, 1 was as non-atypical hyperplasia (NAH). 7 EAG1 were reclassified as AEH, 2 as EA, grade 2, and 1 as NAH. For the panel, pairwise kappa values for any diagnosis ranged from 0.59 to 0.76 with an overall kappa value of 0.59. Among hormonally-affected cases, unanimous agreement for any diagnosis was reached among the panel in 68 specimens. Pairwise kappa values ranged from 0.54 to 0.77 with an overall kappa value of 0.51. Diagnostic problems identified included those related to application of diagnostic criteria including the presence or absence of architectural change or cellular atypia, complicated metaplastic changes and those related to small quantity of tissue.

**Conclusions:** The reproducibility of the diagnosis of the endometrial lesions with or without histologic effects of MPA therapy is not sufficient. New diagnostic criteria applicable for hormonally-affected EA or AEH are needed for the precise evaluation of fertility-sparing treatment.



**826 Cell Signaling Transduction Pathways in Carcinomas of the Uterine Cervix**

V Fumana, A Garcia, J Castellvi, C Ruiz-Marcellan, R Verges, J Giral, S Ramon y Cajal. Hospital San Pere de Ribes, San Pere de Ribes, Barcelona, Spain; Vall Hebron University Hospital, Barcelona, Spain.

**Background:** Very few studies of cell signaling factors in cervix carcinoma have been made. PI3K/AKT and MAPK pathways can be activated by itself or through oncogenic activation of growth factor receptors. 4EBP1 is a mTOR effector that can be activated by both pathways and others as yet not well – identified. RACK1 is an adaptor protein associated with several cellular proteins including protein kinase C. The aim of this study is to analyze the role of the PI3K/AKT, MAPK, 4EBP1 and RACK1 pathways in carcinomas of uterine cervix and to correlate them with clinic – pathological characteristics.

**Design:** A total of 180 invasive carcinomas of uterine cervix (110 squamous cell carcinomas; 70 adenocarcinomas) which FIGO. stages higher than IB1, have been studied. In all of them, the histological type and grade were evaluated and an immunohistochemical study with different molecular signaling markers, such as p4EBP1, pAKT and RACK1 were performed. 66 Patients were treated with external pelvic radiotherapy and 46 of them with concomitant chemotherapy. Statistical analysis was made by means of cross-tabulation by Chi – squared test.

**Results:** 1) 22% carcinomas expressed nuclear pAKT but without significant differences between low and high grade tumors. 2) In high grade carcinomas there was a higher p4EBP1 expression (p=0.02), cytoplasmic pAKT (0.046) and RACK1 (p=0.048). 3) A higher expression of RACK1 was observed in squamous cell carcinomas than in adenocarcinomas (p<0.0001). 4) In the follow-up, after chemo and radiotherapy, there was correlation between pAKT expression and p4EBP1 with local recurrence (p=0.042).

**Conclusions:** High grade carcinomas of uterine cervix express higher levels of p4EBP1 and RACK1 than low grade carcinomas. Levels of expression of pAKT and p4EBP1 associates with local recurrence and maybe potential markers to predict response to chemo – radiotherapy in carcinomas of uterine cervix.

**827 Adequacy and Follow-Up in Patients with Indeterminate Endometrial Sampling**

MA Galan, YB Kim, JL Hecht. Beth Israel Deaconess Medical Center, Boston, MA.

**Background:** To assess the sensitivity of endometrial sampling for detecting neoplasia in the setting of extensive glandular and stromal breakdown.

**Design:** Surgical pathology records between 1996 and 2003 at Beth Israel Deaconess Medical Center (Boston, MA) were searched for endometrial samples with diagnoses containing the keywords “menstrual” or “extensive breakdown.” Hospital records for these women were parsed for demographics, clinical indications and follow-up, including subsequent tissue sampling or clinic notes spanning 18 months or more. Age cutoffs were used to enrich the population for women at higher risk for carcinoma. A control group was composed of 569 women from the same time period who had more than one diagnostic endometrial sample, were more than 40 yo, and did not have extensive breakdown or neoplasia on presentation.

**Results:** 211 cases were identified. Of the primary biopsy reports, three noted evidence of simple hyperplasia, and the remainder had benign descriptive diagnoses (i.e. proliferative, secretory, polyp). Follow-up biopsies were reported in 71, and clinical follow-up after 18 months without resampling was available in 85. 55 women either had no additional information in our system, or only had clinical follow-up less than 18 months after the initial biopsy. Significant endometrial pathology was found in 5 of these 71 follow-up cases. The remaining cases had either specific benign conditions (leiomyomas, endometrial polyps, or chronic endometritis) or were medically managed without subsequent bleeding. In the control group, 3/565 women developed endometrial cancer, 2 of whom had an initial biopsy showing simple hyperplasia.

**Conclusions:** Extensive breakdown or menstrual-pattern endometrium rarely, if ever, masks significant pathology.

**828 Tissue Microarray Analysis of Immunohistochemical Profiles in Leiomyosarcomas and Leiomyomas**

BR Gannon, TJ Childs. Kingston General Hospital, Kingston, ON, Canada.

**Background:** Leiomyomas of the uterus are benign smooth muscle neoplasms that have been subclassified into numerous different morphological variants. Some of these variants, such as symplastic or atypical leiomyomas, can be difficult to distinguish from their malignant counterpart, leiomyosarcoma. In an attempt to further aid in their classification, we examined a series of these tumors with an extended panel of specific immunohistochemical stains.

**Design:** A tissue microarray was constructed using paraffin-embedded, formalin-fixed tissues from 54 hysterectomy specimens. Triplicate 0.6-mm cores were obtained from 9 uterine leiomyosarcomas, 35 leiomyoma variants and 10 normal myometrium specimens. Tissue array sections were immunostained with 13 commercially available antibodies [Bcl-2, caldesmon, CD10, c-kit, cyclin D1, desmin, estrogen receptor (ER), Ki-67, lysozyme, p53, progesterone receptor (PR), smooth muscle actin and ubiquitin]. Supervised and unsupervised hierarchical clustering analysis of the tumors was performed on the immunostaining results.

**Results:** Only ER (p<0.005), PR (p<0.001), c-kit (p<0.001), Ki-67 (p<0.001) and desmin (p<0.001) showed a significantly different frequency of staining in leiomyosarcoma relative to the leiomyoma variants and normal myometrium. Interestingly, the significance analysis of microarrays algorithm produced the same panel of immunohistochemical stains when the false discovery rate was minimized (D=0.73). ER, PR, desmin, and c-kit were more likely to be expressed in leiomyomas whereas Ki-67 was more likely to be expressed in leiomyosarcomas.

**Conclusions:** Using these five significant immunohistochemical stains, we were able to identify three distinct profiles that were highly specific for leiomyosarcoma: 1) ER<sup>+</sup>, PR<sup>+</sup>, desmin<sup>+</sup>, c-kit, Ki-67<sup>+</sup>, 2) ER<sup>+</sup>, PR<sup>+</sup>, desmin<sup>+</sup>, c-kit, Ki-67<sup>+</sup> and 3) ER<sup>+</sup>, PR<sup>+</sup>, desmin<sup>+</sup>,

c-kit, Ki-67<sup>+</sup>. However, these patterns accounted for only 67% (6/9) of the leiomyosarcomas and we recommend further studying these immunoprofiles in a larger sample population.




Figure 1. Heatmap showing unsupervised hierarchical clustering analysis with 13 immunostains. Each row represents a single case and each column represents a single immunostain. The relatedness of the immunostains is depicted by the dendrogram on the left. The longer the horizontal dendrogram arm, the less related are the immunostains between individuals inside a cluster. The strength of the immunostaining is depicted as follows: ■, negative; ■, equivocal / uninterpretable; ■, weak; ■, moderate; ■, strong.

**829 Cell Signaling Pathways in Endometrial Carcinoma: Immunohistochemical Study Reveals 4EBP1 as a Pivotal Factor**

A Garcia, J Castellvi, F Rojo, C Ruiz-Marcellan, A Gil, S Ramon y Cajal. Vall Hebron University Hospital, Barcelona, Spain.

**Background:** Alteration of cell signaling pathways is one of the hallmarks of cancer. mTOR pathway regulates cell growth controlling protein translation and, thus, it has become a major focus of interest of many studies. 4EBP1 is a mTOR effector but it can be activated by several pathways including PI3K/AKT and MAPK and other factors yet unknown. PI3K/AKT pathway has been implicated in endometrial carcinogenesis since the defective PTEN function has been found in a number of endometrial carcinomas, mostly endometrioid or type I carcinomas. The aim of this study is to analyze the role of these pathways in endometrial carcinoma evaluating downstream factor expression and to correlate them with clinic-pathological characteristics.

**Design:** Tissue microarrays of 102 endometrial neoplasias were constructed, including 86 (84.3%) type I carcinomas and 16 (15.7%) type II carcinomas. Immunohistochemistry for PTEN (6H2.1 antibody) and with phospho-antibodies for AKT, 4EBP1 and MAPK was done. Positivity was semiquantitatively scored, including intensity (0 to 3) and percentage of cells. Data were analyzed using SPSS 11.0 software.

**Results:** 75% of tumors were positive for PTEN; 69.9% for pAKT; 12.6% for pMAPK and 48.5% for p4EBP1. Type I carcinomas showed more frequently loss of PTEN expression (30%) than type II carcinomas which were mostly positive. pAKT expression was higher in those cases with loss of PTEN expression (p=0.031) and it was also significantly higher in type I carcinomas (75%) comparing type II carcinomas (49%) (p=0.04). Interestingly, p4EBP1 was expressed in 44% type I carcinomas and in 70% type II, suggesting that in the latter is activated by AKT independent pathway. On the other hand, pMAPK was expressed in 30% of type II carcinomas while it was only expressed in 9% of type I carcinomas (p=0.038).

**Conclusions:** In endometrial carcinoma, loss of PTEN activity is associated with pAKT over-expression and with increase of 4EBP1 phosphorylation in type I endometrial carcinomas. Type II carcinomas show 4EBP1 expression through PI3K/AKT dependent and independent pathways. With these results, we conclude that 4EBP1 can be a central factor in cell signaling pathways in endometrial carcinoma, regardless the oncogene alteration upstream and that 4EBP1 associates with high grade tumors and worse prognosis.

**830 Myeloid Sarcoma Involving the Gynecologic Tract. A Report of 11 Cases and Review of the Literature**

M Garcia, MT Deavers, RJ Knoblock, W Chen, AM Tsimberidou, JT Manning, Jr, LJ Medeiros. University of Texas MD Anderson Cancer Center, Houston, TX.

**Background:** Myeloid sarcoma occurs most often in patients with a history or simultaneous evidence of acute myeloid leukemia (AML). Infrequently, myeloid sarcoma occurs as an isolated finding. Myeloid sarcoma can develop at any anatomic site but involvement of the gynecologic tract is uncommon. We describe 11 cases of myeloid sarcoma involving the gynecologic tract.

**Design:** The clinicopathologic features of each patient were obtained from the medical records or by contacting the patient’s physicians. Hematoxylin-eosin, cytochemical, and immunohistochemical stains were reviewed. Additional immunostains were performed for this study.

**Results:** There were 11 women ranging in age from 17 to 60 years. Six patients initially presented with an isolated mass in the gynecologic tract, and five patients had a history or simultaneous myeloid neoplasm elsewhere. The anatomic sites involved were the

uterine cervix (3 patients), uterus with unilateral involvement of fallopian tube or ovary (3 patients), ovary (2 patients), uterus and bilateral ovaries (1 patient), uterus alone (1 patient), and clitoris (1 patient). Histologically, each neoplasm had a diffuse pattern and infiltrated normal structures and most tumors were poorly differentiated. Naphthol AS-D chloroacetate stain was positive in all 6 neoplasms assessed. Immunohistochemical stains performed in 9 cases showed that all neoplasms were positive for myeloperoxidase and lysozyme and were negative for B-cell and T-cell antigens supporting myeloid lineage. CD117 was positive in 7 of 8 cases assessed. All patients received chemotherapy or radiotherapy alone (n=1). Clinical follow-up was available for all patients ranging from 1 month to 31 years. At last follow-up, 8 patients were alive (2 months-31 years) and 3 died (2-15 months). Three living patients had recurrences that were treated with subsequent complete remission.

**Conclusions:** Myeloid sarcoma involving the female genital tract is uncommon. In this series, the uterus (corpus or cervix) was the most frequently involved anatomic site, often in association with other gynecologic tract sites of disease. Six patients initially presented with myeloid sarcoma as an isolated mass involving the gynecologic tract. With appropriate therapy, long-term remission can be achieved with one patient alive 31 years after diagnosis.

### 831 Villin Expression Does Not Distinguish Primary Mucinous Ovarian Tumors from Metastatic Mucinous Tumors of the Ovary

*K Garg, LW Browne, CJ Zaloudek, JT Rabban.* University of California, San Francisco, San Francisco, CA.

**Background:** Classification of mucinous ovarian tumors as primary versus metastatic can be difficult and immunostaining for CK7, CK20, and CDX2 is of limited value in many cases. Villin is a brush-border protein that binds actin filaments and supports assembly of the actin core bundles of microvilli. Gene expression profiling of human cancer cell lines and limited immunohistochemical studies identify villin as a candidate marker to distinguish colorectal carcinoma from ovarian carcinoma. Detailed evaluation of villin immunoreactivity and its diagnostic value compared to that of current markers has not been well described in mucinous ovarian tumors.

**Design:** Immunohistochemical staining for villin, CDX2, CK7 and CK20 was performed on a tissue microarray containing duplicate 0.1 cm cores from 34 mucinous ovarian tumors, including 16 primary ovarian mucinous tumors (5 borderline tumors, 11 carcinomas) and 18 metastatic tumors (14 colorectal, 4 gastric and 2 pancreaticobiliary carcinomas). Positive expression of villin (Immunotech, 1:1000) was defined as staining of cell membranes, usually predominantly on the apical surface of the tumor cells.

**Results:** Overall, 69% of primary ovarian mucinous tumors and 80% of metastatic tumors expressed villin. Among primary ovarian mucinous tumors, villin was expressed by all 5 borderline tumors (100%) and by 6 of 11 carcinomas (55%). Among metastatic tumors to the ovary, villin was expressed by 13 of 14 colorectal carcinomas (93%), 3 of 4 gastric carcinomas (75%) and 1 of 2 pancreaticobiliary carcinomas. The villin staining pattern of signet ring carcinomas was challenging to interpret as cytoplasmic versus membranous. Among 7 CK7+CK20- primary ovarian tumors, villin was positive in 3 (43%) but CDX2 was negative in each (0%). Overall, CDX2 was expressed by 19% of primary ovarian tumors (2 of 5 borderline tumors, 1 of 11 carcinomas) and 75% of metastatic tumors (12 of 14 colorectal carcinomas, 3 of 4 gastric carcinomas, 0 of 2 pancreaticobiliary carcinomas).

**Conclusions:** Membrane staining for villin does not appear specific for metastatic ovarian mucinous tumors of gastrointestinal origin. It is also seen in the majority of primary borderline and malignant mucinous ovarian tumors. Villin is not helpful as a diagnostic marker to separate primary from metastatic mucinous ovarian tumors, and staining for villin does not add significant information beyond that obtained by staining for established markers.

### 832 Diagnosis of Chronic Endometritis in Biopsies with Focal Stromal Breakdown

*HL Gilmore, D Fleischhacker, JL Hecht.* Beth Israel Deaconess Medical Center, Boston, MA.

**Background:** Biopsy diagnosis of chronic endometritis requires detection of plasma cells, but is also associated with focal stromal breakdown (FSB) and weakly proliferative glands. These secondary features are also seen in disordered proliferative and anovulatory patterns. We have evaluated biopsies with FSB using the histochemical stain methyl green pyronin (MGP) stain to determine a false negative rate for endometritis.

**Design:** We looked retrospectively at endometrial biopsies with FSB over a two year period to determine if chronic endometritis had been overlooked on H&E. Cases were excluded if tissue was not available, the women over the age of 50, on hormone replacements, or with diagnoses of secretory, menstrual endometrium or polyps. Forty-three cases were compared to 4 normals and 17 with chronic endometritis. MGP was used to highlight plasma cells. Biopsies were graded on the number of plasma cells (0 = none, 1 = rare single plasma cell, 2 = rare cluster or more than five single plasma cells, 3 = more than five clusters of plasma cells). Additional cases will be reviewed prior to presentation.

**Results:** The majority of disordered proliferative endometrium had plasma cells (67% grade 1, 17% grade 2) seen on MGP staining not seen on H&E. Almost one third of other proliferative endometrium with focal breakdown showed plasma cells (17% grade 1, 30% grade 2, 13% grade 3). Plasma cells were not seen in inactive or normal proliferative endometrium controls.

**Conclusions:** MGP staining may be useful in establishing the diagnosis of chronic endometritis in disordered proliferative endometrium or proliferative endometrium with focal breakdown.

### 833 Increasing Prevalence of Uterine Serous Carcinoma: Trends over Time in a Non-Referral Primary Practice Institution

*N Goldstein, S Weiner.* William Beaumont Hospital, Royal Oak, MI.

**Background:** The prevalence of uterine serous carcinoma (USCa) reported from community practice is approximately 1% and 10% at referral institutions. It has been our anecdotal experience that its prevalence has been recently increasing among the general population of patients seen at our institution. To study this issue further, we studied the distribution of carcinoma types in hysterectomy specimens during 2000-2005.

**Design:** 344 cancer hysterectomy specimens (hyst) received by the pathology department during 1/1/2000 - 9/19/2005. Although non-myometrial invasive USCa were included in the study, non-myometrial invasive grade 1 endometrioid Cas were excluded. The mean number of hyst/year was 74.2. 47 hyst have been examined during 2005. Carcinomas were divided into endometrioid (pure or with mucinous component), pure USCa, carcinoma with any USCa (>1%), and other types of carcinoma. Cases with small components of USCa were confirmed by demonstrating strong p53 nuclear immunoreactivity. Depth of myometrial invasion was recorded and grouped as <10%. **Results:** The proportion of carcinomas that were pure USCa increased from less than 10% before 2004 to 17% in 2005 and the proportion with any USCa component increased from a mean of 14.2% / year during 2000-2003 to 17.1% in 2004 and 25.5% in 2005. Among the pure USCas, the proportion with <10% myometrial invasion was 23.0%/ year during 2000 - 2003 and was 33.0% in 2004 and 62.5% in 2005. No change in the grade distribution among endometrioid carcinomas occurred over this time.

**Conclusions:** The proportion of uterine tumors that were pure or had a component of USCa has increased over recent years and currently represent approximately 25% of all uterine carcinomas seen at our institution. The proportion of pure USCas with no or minimal myometrial invasion has also increased. Although these results need to be confirmed in larger studies, they suggest that USCa may not be an uncommon neoplasm in contemporary populations and that prior approaches to the treatment of uterine carcinoma, which was most often endometrioid may no longer be valid.

YEAR	ENDOMETRIOID CA	Uterine CA Type by Year		
		PURE SEROUS CA	ANY SEROUS CA	OTHER TYPES
2000	43 (69.3%)	5 (8.0%)	11 (17.7%)	8 (12.9%)
2001	33 (84.6%)	1 (2.6%)	5 (12.8%)	1 (2.5%)
2002	60 (85.7%)	4 (5.7%)	6 (8.6%)	4 (5.7%)
2003	40 (80.0%)	3 (6.0%)	9 (18.0%)	1 (2.0%)
2004	54 (71.4%)	9 (11.8%)	13 (17.1%)	8 (10.5%)
2005	33 (70.2%)	8 (17.0%)	12 (25.5%)	2 (4.2%)

### 834 CD10 Immunostaining Aids in Distinguishing Trophoblastic Lesions from Squamous Epithelium in Endocervical Curettage

*JM Hall, BL Strauss, JC Shaw.* Wilford Hall Medical Center, San Antonio, TX.

**Background:** Placental site nodules and other lesions of trophoblasts are occasional findings in endocervical curettages. Usually their differentiation from squamous epithelium is not problematic. However, the hyperchromatic and enlarged nuclei seen in trophoblastic processes are occasionally concerning for an atypical squamous lesion, particularly in patients with a diagnosis of cervical dysplasia. We therefore examined endocervical curettages performed for dysplasia and containing trophoblasts with a panel of immunostains, to determine which if any could aid in the differentiation of squamous from trophoblastic lesions.

**Design:** Case files were searched for endocervical curettage specimens with trophoblastic lesions and a recent diagnosis of ASCUS or dysplasia. Twenty cases were retrieved, all containing placental site nodules. Thirteen contained sufficient remaining tissue for immunostaining and evaluation. Patient age ranged from 21 to 39 years old. The cases were immunostained for pan-cytokeratin, CK903, CK5/6, CD10, hCG, hPL, and inhibin. Immunohistochemical staining was evaluated for intensity (0-3) and extent (0-3).

**Results:** CD10 immunostaining was strongly and diffusely positive in trophoblasts of all specimens (average intensity, 2.9/3.0; average extent, 2.8/3.0); it did not stain squamous epithelium where present. While hCG, hPL, and inhibin also stained trophoblasts, staining was only weak and focal (average intensity and extent of hCG, 1.3/3.0 and 1.0/3.0; hPL, 1.0/3.0 and 0.5/3.0; inhibin, 1.2/3.0 and 1.2/3.0). Pan-cytokeratin, CK903, and CK5/6 stained both trophoblasts and squamous epithelium.

**Conclusions:** Trophoblastic lesions are occasionally present in endocervical curettage specimens, and their differentiation from atypical squamous epithelium can be problematic. For cases in which histologic features alone are insufficient to differentiate trophoblastic from squamous epithelial processes, CD10 may be useful in reaching the correct diagnosis, and is more helpful than other trophoblastic markers such as hCG, hPL, and inhibin.

### 835 Increased Activity of IGF Signaling in Uterine Leiomyomas

*EY Han, L Chiriboga, H Yee, K Mittal, JJ Wei.* New York University School of Medicine, New York, NY.

**Background:** Uterine leiomyomas (ULM) are sex steroid hormone driven neoplasms in reproductive age women. Global gene expression profile illustrates complex and heterogeneous gene dysregulation, involved in intracellular and extracellular activities. Among them, up regulation of IGF2 has been constantly identified in many independent studies. In this study, we examined and characterized IGF2 mediated PI3K/AKT signaling pathway for cell survival and proliferation in ULM.

**Design:** One hundred and eighty hysterectomies with uterine leiomyomas were selected for the study. Tissue cores from tumors and matched myometrium were collected for tissue microarray analysis (TMA). Antibodies included IGF2, IGF1Rb, PI3K subunits P110, P85, p-AKT (Sser473), tuberin, hamartin, p-S6P (Ser235/236), p-S6K (Thr389) and bcl-2. To validate our finding from immunohistochemistry, Western blot analysis was further conducted in 5 ULM and matched myometrium.

**Results:** Up regulation of IGF2 was identified in more than two third of ULM (126/180). There was minimal up regulation of IGF1Rb and PI3K. Immunoreactivity for pAKT (ser473) was increased in 26% of ULM (14/54). Tuberin was down regulated in 58% of ULM (94/163). There was minimal change of hamartin in ULM due to close numbers of over and under expression in 120 cases examined. Down regulation of hamartin was clustered in ULM with over expression of EGFR. Immunoreactivity for p-S6P (Ser235/236) was identified in 34% of ULM (38/113), but <5% in the matched myometrium. Increased Bcl2 was present in 52% of ULM (57/110). Western blots further confirmed an up regulation of phosphorylated AKT, S6P and S6K-70 in 3 out of 5 randomly selected ULM.

**Conclusions:** 1) Up regulation of IGF2 is present in most of ULM. The level of IGFs is closely associated with sex steroid hormone status, indicating a functional interaction between sex steroid hormones and IGF signaling; 2) there are significant numbers of ULM showing increased activities of the IGF signaling. Although the tumors with dysregulation of the IGF proteins tend to cluster together, the linear correlation of each IGF protein in individual ULM has not been established. 3) Down regulation of hamartin is associated with over expression of EGFR, suggestive of a functional link between IGF signaling and TGF signaling.

### 836 Small Cell Carcinoma of the Ovary of the Hypercalcemic Type: A Highly Aggressive Neoplasm without CGH Aberrations

*S Hauptmann, H Schmidt, U Bilkenroth, M Köbel, B Czernobilsky, L Roth, G McCluggage, RE Scully, E Oliva.* Martin-Luther-University Halle-Wittenberg, Halle (Saale), Germany; Patho-Lab Ltd, Nes-Ziona, Israel; Indiana University Medical Center, Indianapolis, IN; Royal Group of Hospital Trusts, Belfast, North-Ireland, United Kingdom; Massachusetts General Hospital, Boston, MA.

**Background:** Small cell carcinoma of the ovary of hypercalcemic type (Ov-SSCHT) affects typically young woman and is one of the rarest but most lethal ovarian malignancies. Malignant tumors in general and in particular poorly differentiated, highly aggressive ones are characterized in almost all instances by an unstable karyotype leading to large-scale chromosomal abnormalities. In Ov-SSCHT, however, several reports have shown that these tumors are essentially diploid by DNA image cytometry. This finding has two possible explanations: a) the degree of chromosomal abnormalities is below the detection threshold of DNA image cytometry, or b) there are only structural or balanced chromosomal aberrations.

**Design:** We selected representative paraffin blocks from 19 Ov-SSCHT from eight institutions. After histologic confirmation of the diagnosis the tumor tissue was microdissected. DNA image cytometry was performed using smears of single cell preparations. Chromosomal aberrations were investigated by comparative genomic hybridization (CGH). From each case 10-15 metaphases/karyogram were evaluated by computation of CGH sum-karyograms.

**Results:** All tumors had diploid DNA histograms. Repeatedly performed CGH analysis did not revealed any chromosomal aberration.

**Conclusions:** Although CGH may miss minor changes it was intriguing to recognize that one of the most lethal gynecological malignancy does not have significant chromosomal abnormalities. This unique feature distinguish these tumors from undifferentiated ovarian carcinomas and small cell neuroendocrine carcinomas which both are characterized by complex chromosomal abnormalities.

### 837 Comparison of Immunohistochemical Expression of MUC1, MUC2, MUC4, MUC5AC and MUC6 in Ovarian Mucinous Adenomas, Borderline Tumors and Adenocarcinomas

*K Hirabayashi, H Kajiwara, M Yasuda, YR Osamura.* Tokai University School of Medicine, Isehara, Kanagawa, Japan.

**Background:** Mucins are high molecular weight glycoproteins with oligosaccharides attached to the apomucin protein backbone by O-glycosidic linkage and are synthesized by a variety of secretory epithelial cells. Mucins are classified into membrane-associated type and secretory type. MUC1 and MUC4 are membrane-associated mucins, and MUC2, MUC5AC and MUC6 are secretory mucins. The aim of this study is to analyze and compare the expression of MUC1, MUC2, MUC4, MUC5AC and MUC6 in mucinous adenomas (MAs), mucinous borderline tumors (MBs) and mucinous adenocarcinomas (MCs) of ovary.

**Design:** Formalin-fixed paraffin-embedded tissue sections from 29 MAs, 29 MBs and 26 MCs were immunostained using antibodies for MUC1 (Novocastra), MUC2 (Novocastra), MUC4 (Zymed), MUC5AC (Novocastra) and MUC6 (Novocastra). Cases were scored based on the percentage of positive cells: 0 (negative), 1+ (<10%), 2+ (10-50%), or 3+ (>50%).

**Results:** MUC1 and MUC2 were more frequently expressed in MBs and MCs than MAs. (MUC1:  $p < 0.0001$ , MUC2:  $p = 0.0012$ ). MUC4 was strongly expressed in the cytoplasm in MAs. In contrast, MUC4 strongly labeled the apical membrane of tumor cells in MCs. The expression of MUC5AC in MCs was lower than that of MAs and MBs ( $p < 0.0001$ ). MUC6 expression was low in MBs (24%) ( $p = 0.0225$ ). In most ovarian mucinous tumors, the percentage of positive cells of MUC6 was less than 10% (MAs: 69%, MBs: 86%, MCs: 71%).

**Conclusions:** MUC1, MUC2 and MUC5AC expression pattern significantly differed among MAs, MBs and MCs. The localization of MUC4 expression was altered according to the tumor grade. Malignancy was considered to be characterized by high expression of MUC1 and MUC2 and low expression of MUC5AC, and strong MUC4 expression at cell surface also suggested malignancy. It was concluded that mucin expression is a useful diagnostic and prognostic indicator for ovarian mucinous tumors.

	Results of Immunohistochemical Expression		
	MA(n=29)	MB (n=29)	MC (n=26)
MUC1	4 (14%) 2: 1+, 2: 2+, 0: 3+	12 (41%) 4: 1+, 8: 2+, 0: 3+	20 (77%) 5: 1+, 6: 2+, 9: 3+
MUC2	4 (14%) 3: 1+, 0: 2+, 1: 3+	15 (52%) 10: 1+, 3: 2+, 2: 3+	15 (58%) 6: 1+, 4: 2+, 5: 3+
MUC4	14 (48%) 5: 1+, 5: 2+, 4: 3+	16(55%) 10: 1+, 5: 2+, 1: 3+	15(58%) 8: 1+, 3: 2+, 4: 3+
MUC5AC	29 (100%) 0: 1+, 3: 2+, 26: 3+	29 (100%) 1: 1+, 0: 2+, 28: 3+	21 (81%) 4: 1+, 5: 2+, 12: 3+
MUC6	16 (55%) 12: 1+, 4: 2+, 1: 3+	7 (24%) 6: 1+, 1: 2+, 0: 3+	14 (54%) 10: 1+, 3: 2+, 1: 3+

### 838 Ovarian Metastases of Appendiceal Tumors with Goblet Cell Carcinoid-Like Features: Limited Expression of Neuroendocrine Markers and Clinicopathologic Features of Aggressive Invasive Carcinoma Support Designation as Adenocarcinoma Rather Than Goblet Cell Carcinoid Tumor

*AC Hristov, R Vang, RH Young, JD Seidman, BM Ronnett.* The Johns Hopkins Hospital, Baltimore, MD; Massachusetts General Hospital, Boston, MA; Washington Hospital Center, Washington, DC.

**Background:** Appendiceal tumors exhibiting goblet cell carcinoid-like features are often designated as goblet cell carcinoid tumors or "adenocarcinoids", suggesting they are indolent neuroendocrine tumors or mixed tumors with behavior intermediate between carcinoid and adenocarcinoma. However, those infiltrative appendiceal tumors metastatic to the ovary have demonstrated clinicopathologic features more characteristic of aggressive invasive adenocarcinomas (Am J Surg Pathol 1997;21:1144-1155).

**Design:** Immunohistochemical analysis of neuroendocrine marker expression was performed on 9 ovarian tumors and 8 of the corresponding primary appendiceal tumors.

**Results:** All ovarian tumors were bilateral and exhibited a goblet cell carcinoid-like pattern, which was pure in 7 tumors and admixed with glandular and/or signet ring cell carcinoma in 5 tumors. Chromogranin was expressed in 3 of 9 ovarian tumors (percentage of positive tumor cells: 10-20%) and synaptophysin was expressed in 1 of 8 of these (15% of tumor cells positive). Chromogranin was expressed in 3 of 8 appendiceal tumors (percentage of positive tumor cells: 10-50%) and synaptophysin was expressed in 2 of 7 of these (percentage of positive tumor cells: 20-25%). Of 8 ovarian tumors evaluated with both markers, none of the 3 positive cases expressed both and 5 expressed neither. Of 7 appendiceal tumors evaluated with both markers, 1 of 3 positive cases expressed both and 4 expressed neither. Of 7 tumor pairs evaluated with both markers, only 2 pairs had expression in both tumors (1 only chromogranin, 1 only synaptophysin) and 4 pairs were negative for both markers.

**Conclusions:** Some infiltrative appendiceal tumors may arise from pre-existing goblet cell carcinoid tumors and could represent mixed carcinoid/adenocarcinomas but limited to absent expression of neuroendocrine markers combined with clinicopathologic features of aggressive carcinoma support designation of these tumors as invasive adenocarcinomas. The ovarian tumors should be labeled as metastatic adenocarcinomas to reflect their clinicopathologic features and distinguish them from the rare true primary ovarian goblet cell carcinoid tumors of germ cell origin.

### 839 Nuclear Size Distinguishes Low- from High-Grade Ovarian Serous Carcinoma and Predicts Outcome

*CY Hsu, RJ Kurman, R Vang, TL Wang, J Baak, IM Shih.* Taipei Veterans General Hospital, Taipei, Taiwan; National Yang-Ming University School of medicine, Taipei, Taiwan; Johns Hopkins Medical Institutions, Baltimore, MD; Central Hospital in Rogaland, Stavanger, Norway.

**Background:** A dualistic model for ovarian serous carcinogenesis based on morphological and molecular genetic studies has recently been proposed. This model divides serous carcinoma into low- and high-grade tumors, which develop along distinct molecular pathways. Distinction between low- and high-grade serous carcinoma was based primarily on nuclear grade and mitotic activity. We evaluated computerized morphometry to determine its utility in distinguishing low- and high-grade serous carcinoma.

**Design:** A total of 93 high-grade serous carcinomas, 16 low-grade serous carcinomas, 21 serous borderline tumors were randomly selected and placed on tissue microarrays. Sections were stained with hematoxylin-eosin for morphometric measurement including the volume percentage of epithelium (VPE) and the mean nuclear area (MNA).

**Results:** Both MNA and VPE were significantly higher in high-grade serous carcinoma compared with low-grade serous carcinoma and serous borderline tumors ( $P < .001$  and  $P = .02$ , respectively). There was no significant difference in MNA and VPE between low-grade carcinoma and serous borderline tumors ( $P > .3$ ). Among high-grade serous carcinomas, those with an  $MNA \geq 46 \mu m^2$  had a poorer survival ( $P = .035$ ) than those with an  $MNA < 46 \mu m^2$ . In contrast, VPE and tumor grade (moderately versus poorly differentiated) had no significant prognostic value.

**Conclusions:** The morphometry findings lend further support to the dualistic model of ovarian serous carcinogenesis and suggest that MNA is an excellent adjunctive tool for distinguishing low- from high-grade serous carcinomas. In addition, MNA is an independent prognostic factor for high-grade serous carcinoma.

### 840 P16 Immunostaining in Atypical Immature Squamous Metaplasia of the Uterine Cervix – Correlation with Human Papillomavirus Detection

*L Iaconis, E Hyjek, LH Ellenson, EC Pirog.* Beth Israel Hospital, New York, NY; Weill Medical College of Cornell University, New York, NY.

**Background:** Atypical immature squamous metaplasia (AIM) of the cervix is a loosely defined entity characterized by immature metaplastic cells with mild cytologic atypia. Since recognition of "mild atypia" is poorly reproducible, the cases carrying the diagnosis of AIM were shown to include a spectrum from bona fide high grade squamous intraepithelial lesion (HSIL) to benign reactive changes or atrophy. Cases of AIM that

are negative for Human Papillomavirus (HPV) are thought to represent benign changes of the epithelium, however those associated with high risk HPV (hrHPVs) are thought to represent either HSIL or a potential precursor of HSIL. Immunostaining for p16 has been shown to correlate with detection of hrHPVs in HSIL and thus p16 was suggested to be a surrogate marker of infection with hrHPVs. None of the previously published reports correlated p16 staining with the presence of hrHPV in AIM. The goal of this study was to examine if positive p16 immunostaining in AIM correlates with detection of hrHPVs and if the staining therefore could be used to separate benign cases from atypia that may potentially progress to a squamous intraepithelial lesion. **Design:** The study consisted of 37 cases of AIM, 23 cases of benign cervical mucosa with reactive or atrophic changes (NEG), and 16 cases of HSIL. All cases were tested for the presence of hrHPVs using SPF10 PCR and Line Probe Assay and stained for p16 using DAKO antibodies.

#### Results:

diagnosis	n	hrHPV+ p16+ (%)	hrHPV+ p16- (%)	hrHPV- p16- (%)
AIM	37	15 (41)	5 (13)	17 (46)
NEG	23	1 (4)	3 (13)	19 (83)
HSIL	16	16 (100)	0 (0)	0 (0)

Overall, the immunostaining for p16 correlated well with the detection of hrHPV, however, there were few NEG and AIM cases that were positive hrHPV, but negative for p16. In almost all of these cases there was a concurrent squamous intraepithelial lesion present in another specimen. The sensitivity of p16 for detection of hrHPV was 0.8 and the specificity was 1, for all the cases combined.

**Conclusions:** P16 immunostaining may be useful for distinguishing reactive atypia of the immature squamous epithelium from the cases with hrHPV infection that may potentially progress to dysplasia.

#### 841 Expression of Mesothelial Markers in Ovarian Cancers: A Tissue Microarray Based Study of 471 Cases

*DN Ionescu, H Masoudi, S Leung, AM Gow, CB Gilks.* Vancouver General Hospital, Vancouver, BC, Canada; PhenoPath, Seattle, WA.

**Background:** Ovarian carcinomas are believed to originate from the ovarian surface epithelium, a layer of coelomic mesothelium, in most cases, although for some subtypes, in particular, there is some uncertainty about cell of origin. Therefore mesothelial markers may represent possible markers for cell type differentiation. This study assesses the immunoreactivity of ovarian carcinomas for 6 mesothelial markers using tissue microarray (TMA) and immunohistochemistry technology in a large population-based series.

**Design:** 471 cases of ovarian surface epithelial carcinomas (OSEC) diagnosed in British Columbia from 1984-2000 were collected. TMA blocks were made using duplicate 0.6-mm-diameter tissue cores from each marked paraffin block. Immunohistochemistry for Calretinin, CK5/6, WT1, Mesothelin, D2-40-defined antigen and HBME was performed. Immunostaining was scored as positive if 5% or more of tumour cells showed immunoreactivity, and negative otherwise. Tumor cases were grouped by similarity of staining pattern using hierarchical clustering (Cluster software from Eisen lab). Statistical analysis was performed using SPSS 13.0 statistical software package.

**Results:** Hematoxylin-eosin stained sections of were reviewed and were subclassified as follows: 179 serous carcinoma (SC), 116 endometrioid carcinoma (EC), 130 clear cell carcinoma (CCC), 32 mucinous carcinoma (MC) and 14 other (transitional, squamous, undifferentiated and adenocarcinomas NOS). The expression of mesothelial markers in individual OSEC is summarized in the table below:

Mesothelial markers in various ovarian surface epithelial tumors (%)

	CALRETININ	CK5/6	WT1	HBME	MESOTHELIN	D2-40-DEFINED ANTIGEN
SEROUS	1.7	5	80.1	59.8	79.1	9.6
ENDOMETROID	2.6	17.5	3.5	45.6	25.2	7.9
CLEAR CELL	2.3	1.5	6.2	67.4	34.8	21.8
MUCINOUS	0	3.1	0	6.2	0	0
OTHER	0	7.1	53.8	21.4	42.8	7.1

**Conclusions:** 1. Mesothelial differentiation is more often seen in SC as compared to the other OSEC. 2. Double positivity for WT1 and Mesothelin is a highly specific indicator for SC (124/140, 88.6%). 3. Negativity for mesothelial markers, with only rare positivity for CK5/6 and HBME, is typical of MC.

#### 842 Adenomyosis Involved by Endometrial Adenocarcinoma Is a Significant Risk Factor for Deep Myometrial Invasion

*N Ismail, G Rasty, Z Ghorab, S Nofech-Mozes, I Ackerman, G Thomas, A Covens, M Khalifa.* Sunnybrook & Women's College Health Sciences Centre, Toronto, ON, Canada.

**Background:** Adenomyosis is commonly present in association with endometrial adenocarcinoma where it may or may not be involved by malignant cells. When adenomyosis is positive for adenocarcinoma, the tumor may remain within its confines or may progress to invade the adjacent myometrium. This study of grade 1 endometrioid adenocarcinoma investigates whether patients with cancer-positive adenomyosis are at a different risk for deep myometrial invasion compared to those with cancer-negative adenomyosis.

**Design:** Ninety-three hysterectomy specimens with FIGO grade 1 endometrial endometrioid adenocarcinoma associated with adenomyosis were accessioned in the Department of Pathology at Sunnybrook and Women's College Health Sciences Centre from July 1999 to June 2005. Four experienced gynecologic pathologists retrieved the cases and retrospectively reviewed all hematoxylin and eosin-stained sections. In questionable cases, myometrial invasion was confirmed by CD10-negative staining around glands with jagged outline surrounded by inflamed desmoplastic stroma.

**Results:** Adenomyosis was involved by adenocarcinoma in 46 cases while it was carcinoma-negative in 47 cases. Myometrial invasion was found in significantly more carcinoma-positive adenomyosis cases (n = 43, 93.5%) than with carcinoma-negative adenomyosis cases (n = 30, 63.8%) ( $\chi^2 = 12.10$ , p = 0.0005). In 16 cases of the former

group, the invasion only occurred from foci of adenomyosis. Moreover, myometrial invasion in the outer half was also seen in significantly more carcinoma-positive adenomyosis cases (n = 16, 34.8%) than with carcinoma-negative adenomyosis cases (n = 3, 6.4%) ( $\chi^2 = 11.53$ , p = 0.0007).

**Conclusions:** Among all cases of FIGO grade 1 endometrial endometrioid adenocarcinoma associated with adenomyosis, the ones which extend in adenomyosis gain more invasive potential, probably through increasing the surface area of its interface with the adjacent myometrium. When compared with tumors which do not involve adenomyosis, these tumors are not only more likely to invade the myometrium, but are significantly more prone to achieve deep invasion into the outer half.

#### 843 Microsatellite Instability in Ovarian Cancer Subtypes and in Synchronous Ovarian and Endometrial Cancers: The Stanford Experience

*KC Jensen, GV Putcha, IM Otani, I Schrijver, J Zehnder, TA Longacre.* Stanford University, Stanford, CA.

**Background:** Despite several studies of microsatellite instability in ovarian and endometrial tumors in recent years, published results of the frequency of microsatellite instability in these tumors have yielded inconsistent results, ranging from 8 to over 50% with variability among carcinoma subtypes. The frequency of hereditary disease in gynecologic malignancies in women under 50 years of age is not known and currently not well tested. This study aimed to investigate the utility of current screening methodology in identifying patients with possible hereditary gynecologic malignancy.

**Design:** The Surgical Pathology files at Stanford University Hospital were searched for ovarian and endometrial tumors in patients less than 50 years of age who might be candidates for immunohistochemical and molecular screening followed by referral for genetic testing. This yielded 50 tumors (see table). Tumors were studied for evidence of microsatellite instability using both immunohistochemistry (antibodies to mismatch repair proteins MLH1, MSH2 and MSH6) and molecular analysis (for the NCI reference panel of loci, which consists of BAT25, BAT26, D2S123, D5S123, D5S346 and D17S250).

**Results:** Only one tumor (poorly differentiated carcinoma of the ovary) was found to be microsatellite unstable (see table). The overall incidence of microsatellite instability in ovarian and endometrial tumors (2%) was lower than previously reported in the literature.

**Conclusions:** Formalin-fixed, paraffin-embedded tumor and normal material from a single institution using standardized and consistent fixation, processing, immunohistochemical and molecular techniques yielded a very low rate (2%) of microsatellite instability, despite the young age of affected patients. An expanded panel of loci may be necessary in order to perform adequate screening for patients with gynecologic malignancies who may be candidates for additional genetic testing.

Tumor type	Number of cases	Microsatellite instability
Clear cell, ovary	12	0
Serous, ovary	18	0
Endometrioid, ovary	3	0
Undifferentiated, ovary	4	1 (MSI-L)
Mixed types, ovary	3	0
Endometrioid, uterus	3	0
Mixed types, uterus	3	0
Poorly differentiated, uterus	1	0
Synchronous ovary/uterus	3	0

#### 844 Correlation of Endometrial Pathology between Hysterectomy and Preoperative Endometrial Sampling

*H Ji.* The Johns Hopkins Hospital, Baltimore, MD.

**Background:** Diagnostic accuracy is essential for proper clinical management of patients with endometrial disease. However, studies have shown a considerable rate of diagnostic discrepancy between hysterectomy and preoperative endometrial sampling. There is as high as 42% concurrent endometrial carcinoma in patients with biopsy diagnosis of atypical endometrial hyperplasia (AEH).

**Design:** Computerized surgical pathology database was searched to retrieve all hysterectomy cases performed at our institution from 7/1/2002 to 6/30/2005. Included in the analysis were patients underwent endometrial biopsy or curettage within one-year prior to hysterectomy. The endometrial pathology was categorized as 1) benign, 2) simple or complex endometrial hyperplasia without atypia (SH/CH), 3) AEH, and 4) carcinoma. Kappa statistical analysis was applied to evaluate the correlation of the diagnosis.

**Results:** A total of 1357 hysterectomies were performed in the 3-year period. Of those, 340 patients underwent endometrial sampling within one year prior to hysterectomy. The mean age of the patients was 51 years (23-88 years) and the mean interval from endometrial sampling to hysterectomy was 74 days (0-352 days). Eighteen of 19 patients with insufficient endometrium at biopsy showed benign endometrium at hysterectomy, whereas one 81-year-old patient was diagnosed of endometrioid carcinoma. Diagnostic discrepancy including all diagnostic categories was identified in 30 of remaining 321 (9.4%) cases. Down-grading by hysterectomy was in 18/321 (5.6%) cases, and up-grading in 12 (3.7%) cases. Six cases were up-graded from AEH suspicious for carcinoma to endometrioid carcinoma, with 4 cases showing evidence of myometrial invasion. Incidental SH/CH in polyps was noted in 2 cases at hysterectomy, while 2 other cases showed small foci of AEH at hysterectomy that was not identified in endometrial biopsies. The remaining two patients, both in their 80s, were diagnosed of serous and clear cell carcinoma at hysterectomy, while biopsy diagnoses were atypical metaplasia and proliferative endometrium, respectively. All other 291 patients had corresponding diagnosis both at biopsy and hysterectomy. There is excellent correlation between the diagnosis at hysterectomy and that at endometrial biopsy (kappa: 0.820).

**Conclusions:** Our institutional experience demonstrates that endometrial pathology at hysterectomy highly correlates with that at preoperative endometrial sampling.

Although only occasional carcinomas were missed in endometrial biopsies, the error is likely to occur in elderly postmenopausal patients.

#### 845 Endometrioid Adenocarcinoma Involving the Endometrium and the Cervix: One Tumor or Two Independent Tumors?

*L Jiang, A Malpica, M Deavers, G Nuovo, M Merino, EG Silva.* MD Anderson Cancer Center, Houston, TX; Ohio University, Columbus, OH; National Cancer Institute, Bethesda, MD.

**Background:** The majority of endometrial endometrioid adenocarcinomas (EEA) Stage II have a similar tumor in the endometrium (endom) and the endocervix (endocx). However, in some cases the carcinoma (Ca) in the endocx is different or more invasive than the Ca in the endom; or the invasion occurs only in the endocx without myometrial invasion.

**Design:** Our goal was to investigate by H&E, immunohistochemistry (IHC), HPV in situ hybridization and PCR analyses, and DNA clonality studies if the Cas in the endom and the endocx are similar or two independent primaries. We selected 14 cases of EEA involving the cervix with complete pathology material from 1968 to 2004. IHC for vimentin, carcinoembryonic antigen, estrogen receptor, progesterone receptor, and P16 was performed in 12 cases; HPV analyses in 6 cases; and clonality studies (Human Androgen Receptor Assay) in 10 cases.

**Results:** The patient's (pts) age ranged from 42 to 81 years (mean 62 years). Different histologic features between the Cas in the endom and the endocx were identified in 8 cases; 5 of these cases had a microcystic pattern in the cervix, 2 had a different grade, and 1 had squamous metaplasia only in the Cx. Six cases showed similar histologic features between the cas in the endom and the endocx. IHC showed that the staining pattern in 11 out of 12 cases favored endometrial origin regardless of the different or similar histology. HPV testing in 6 of the cases (3 with similar and 3 with different histologies) showed that the cas in the endocx were positive and in the endom were negative. Clonality studies revealed differences between the ca in the endom and the endocx in 7 cases, which included 5 cases that had different histologies. Of the 5 cases with similar histology, 2 had different clonality, and 3 cases were clonal.

**Conclusions:** 1. When the coexisting cas in the endom and endocx have different histologic features, most probably they are independent neoplasms. This was confirmed by HPV analyses and clonality studies. 2. When the cas in the endom and endocx have a similar appearance, they may represent either the same neoplasm or independent primaries; HPV analyses and clonality tests should be performed. 3. IHC is very helpful when a pt has a ca in either the endom or the endocx, but it may not be helpful when a pt has synchronous endometrial and endocervical ca, endometrioid type. 4. These results raise questions concerning the classification of some cases of stage II EEA.

#### 846 Diagnostic Limitation of D2-40 in Separating Ovarian Serous Carcinoma from Other Metastatic Carcinoma of the Abdomen

*DL Jones, KL Denning, RS Saad, YL Liu, X Lin, M Tung, JF Silverman.* Allegheny General Hospital, Pittsburgh, PA.

**Background:** Accurate identification of abdominal metastatic carcinoma of unknown origin can be occasionally challenging in the absence of clinical history; therefore, a panel of immunohistochemical studies is usually performed. D2-40, a monoclonal antibody to an O-linked sialoglycoprotein that reacts with a fixation resistant epitope in lymphatic endothelium, has recently been described as a sensitive immunohistochemical marker for ovarian serous papillary carcinoma. However, the specificity of D2-40 expression in separating ovarian serous papillary carcinoma versus other abdominal carcinomas has not been studied.

**Design:** A total of 100 cases of abdominal malignancy were retrieved from the computer hospital database, including, 20 cases of ovarian serous carcinoma, 20 endometrioid endometrial carcinoma, 20 pancreatic, 20 gastric and 20 cases of colonic adenocarcinoma. Immunostaining with antibody to D2-40 were performed on paraffin-embedded tissue on an automated immunostainer with appropriate positive and negative controls. Two pathologists reviewed the cases and report the staining on 2-tiered scale (positive or negative).

**Results:** D2-40 immunoreactivity was demonstrated in 4/20 (20%) of ovarian serous carcinomas, 3/20 (15%) in colon adenocarcinoma, 3/20 (15%) in gastric adenocarcinoma. None of the pancreatic carcinomas or endometrial carcinomas showed immunoreactivity for D2-40. There was not a significant statistical difference for D2-40 expression by ovarian serous papillary carcinoma, colonic adenocarcinoma and gastric adenocarcinoma ( $p > 0.05$ ).

**Conclusions:** Our results suggest that D2-40 is neither sensitive nor a specific immunohistochemical marker for ovarian serous papillary carcinoma since D2-40 expression was also observed in 15% gastric and colonic adenocarcinomas. Therefore, D2-40 expression has limited value in separating ovarian serous papillary carcinoma from other abdominal metastatic carcinomas of unknown origin.

#### 847 Immunohistochemical Expression of DNA Mismatch Repair Gene Products -MLH1 and MSH2, Metastasis Suppression Gene nm-23 and Beta-Catenin in Synchronous and Metastatic Endometrioid Adenocarcinomas of Ovary and Endometrium

*MW Jones, N Esposito, M Kapali.* Magee-Women's Hospital of the University of Pittsburgh, Pittsburgh, PA.

**Background:** The treatment and prognosis of patients with synchronous adenocarcinomas of endometrium and ovary and adenocarcinoma of endometrium with ovarian metastasis varies significantly. Since in many instances the distinction between these two groups of tumors cannot be made on histologic grounds we analyzed the expression of several immunohistochemical markers that may prove useful in differentiating synchronous and metastatic tumors

**Design:** Nine cases with simultaneous endometrioid adenocarcinomas of the ovary and endometrium were retrieved from the archives of the Department of Pathology, Magee-Women's Hospital, UPMC. Tumor histopathologic characteristics, including laterality, size, depth of myometrial invasion, and grade were recorded. Endometrioid adenocarcinomas associated with small and superficial and/or bilateral ovarian tumors were considered metastatic (5/9) while endometrial cancers associated with unilateral and large ovarian tumors were considered to be synchronous (4/9). Five patients had metastatic disease in pelvis and abdomen. The tumors were studied with antibodies against MLH1, MSH2, NM23 and beta-catenin.

**Results:** Similar staining pattern was observed in endometrial, ovarian and metastatic tumors. MLH1 was negative in 6/9 cases, including all metastatic carcinomas. Three synchronous tumors were positive with MLH-1 (one showed strong diffuse staining and 2 weak and focal staining). MSH2 stained strongly and diffusely in all synchronous and metastatic tumors. nm-23 showed strong diffuse cytoplasmic staining in all tumors and metastatic tumor. Membranous immunostaining for beta-catenin was present in all tumors but 4/5 synchronous tumors showed nuclear staining in addition to the membrane staining. Areas of squamous metaplasia showed positive nuclear staining with beta-catenin.

**Conclusions:** Significant reduction of MSH1 expression in ovarian and endometrial carcinomas and pelvic metastasis indicates involvement of DNA mismatch gene alteration in the origin of both synchronous and metastatic tumors. The presence of nuclear staining for beta-catenin in the majority of synchronous tumors and its absence in all metastatic tumors suggests two different pathways in their pathogenesis and may help in their histologic distinction. MLH2 and nm-23 does not play a significant role in development of synchronous or metastatic ovarian and endometrial carcinomas.

#### 848 Retained Ezrin Expression in Endometrial Carcinomas Is Related to Poor Prognosis

*M Köbel, T Langhammer, S Hauptmann.* Martin-Luther-University, Halle, Germany.

**Background:** As a cortical cytoskeletal protein, ezrin adapts the cytoplasmic tail of CD44 to actin-based cytoskeleton and is functionally involved in migration and adhesion that are prerequisites for metastasis. In endometrial carcinoma, however, the significance of ezrin expression as prognostic indicator has not yet been investigated nor was its expression compared with that of the associated protein osteopontin.

**Design:** To assess the importance of ezrin and osteopontin for endometrial carcinoma progression, we analyzed paraffin-embedded endometrial carcinoma samples from 208 patients for the expression of both by immunohistochemistry and compared these data with clinicopathological parameters.

**Results:** Ezrin was expressed at least focally in the majority of carcinomas. The mean expression level for ezrin and osteopontin was determined at 14.5% and 8.5% of tumor cells, respectively. Strong ezrin expression, but not osteopontin expression, correlated with a reduced overall survival in univariate analysis ( $p = 0.003$ ). In multivariate analysis, which included FIGO stage, grade and histological type, ezrin was still found to be an independent risk factor (relative risk 2.48, confidence interval 1.08 – 5.69,  $p = 0.031$ ).

**Conclusions:** As shown for other tumor entities, ezrin is also associated with aggressive behaviour of endometrial carcinomas.

#### 849 Alterations of the Tumor Suppressor Gene FHIT in Vulvar Cancer

*ME Kahn, G Ambartsumyan, C Aoyama, S Natarajan, RL Balwin, BY Karlan, CH Holschneider.* Cedars-Sinai Medical Center, Los Angeles, CA; Oliveview - UCLA Medical Center, Sylmar, CA; UCLA Medical Center, Los Angeles, CA.

**Background:** Epidemiologically, vulvar cancer shares certain risk factors with cervical cancer, such as infection with the human papillomavirus and cigarette smoking. While the putative tumor suppressor gene FHIT (fragile histidine triad gene) is known to be frequently altered in cervical cancer and lung cancer, it is unknown whether it is affected in vulvar cancer. We therefore undertook the current study to characterize the extent of FHIT alterations in squamous cell carcinomas of the vulva and in tumor-adjacent severe dysplasia.

**Design:** Archival tissues of 68 patients treated with primary surgery for invasive squamous cell carcinoma of the vulva were identified at the three participating institutions. Data on patient age, race, tumor grade, size, depth of invasion, lymphovascular space involvement and stage were recorded. Pathology slides were reviewed by two gynecologic pathologists and sections of tumor, adjacent non-dysplastic epithelium and VIN III (if present) were identified. FHIT protein expression was evaluated by immunohistochemistry using a polyclonal rabbit anti-human FHIT antibody. Intensity and distribution of FHIT staining was graded by two independent examiners who were blinded to the epidemiological data.

**Results:** Reduced or lost FHIT expression was observed in 48 of the 68 vulvar cancers (71%) compared to adjacent non-dysplastic epithelium. Tumor-adjacent VIN was present in 44 cases, 24 of which (55%) had reduced FHIT expression. There was a progressive reduction in average FHIT expression scores from non-dysplastic epithelium (2.67; 95% CI 2.50-2.85) to VIN III (2.13; 95% CI 1.84-2.42); to invasive carcinoma (1.90; 95% CI 1.65-2.15). When comparing tumors with loss of FHIT versus those with unaltered FHIT expression, there was no significant difference in patient age, race, tumor grade, size, depth of invasion, lymphovascular space involvement or stage.

**Conclusions:** Reduction or loss of expression of FHIT occurs frequently in squamous cell carcinoma of the vulva with a progressive loss paralleling progressive neoplasia. Our data suggest that the putative tumor suppressor gene FHIT may be a target in vulvar carcinogenesis and deserves further study.



**850 Immunohistochemical Analysis of Intermediate Trophoblastic Tumors**

*N Kalhor, P Ramirez, M Deavers, A Malpica, EG Silva.* MD Anderson Cancer Center, Houston, TX; University of Texas Health Science Center at Houston Medical School, Houston, TX.

**Background:** We have noted that a significant number of Intermediate Trophoblastic Tumors (ITTs) do not have the immunohistochemical pattern that has been described. Therefore, subclassification of these neoplasms, strongly supported by immunohistochemistry, as placental site trophoblastic tumors (PSTT) and epithelioid trophoblastic tumors (ETT) can be very difficult. Although subclassifying ITTs is a challenge, distinguishing them from non-trophoblastic tumors is more crucial, since the therapeutic approaches for these entities are different. We designed this study to investigate the immunophenotype of the ITTs and to determine the most useful markers to differentiate ITTs from carcinomas of the cervix.

**Design:** Immunohistochemistry was performed on 15 ITTs and 10 carcinomas of cervix (5 moderately and poorly differentiated squamous cell carcinomas and 5 adenocarcinomas) using a panel of hPL, CK18, hCG, HLA-G, CEA, vimentin, MEL-CAM, inhibin, p63, keratin cocktail, (CAM 5.2 and AE 1/3), and p16. The results were reported as positive or negative, and the proportion of cells showing positivity graded as 0 <5% 1+: 5-25%; 2+: 25-50%; 3+: 50-75%; 4+: >75%.

**Results:** Immunohistochemistry results are demonstrated in Table 1.

	Results = Table I. Immunohistochemistry results (25 cases)					
	HLA-G	CK18	hPL	p63	CEA	p16
ITTs	13/15	15/15	7/15	6/15	0	0/15
CAs*	1/10	3/10	0/10	8/10	8/10	10/10

\*CAs: Carcinomas

	Table I (continuation)				
	hCG	MEL-CAM	Pan- K	Vimentin	Inhibin
ITTs	9/15	9/15	15/15	14/15	3/15
CAs	1/10	2/10	8/10	9/10	2/10

**Conclusions:** 1) The best panel to identify ITTs consists of: HLA-G, CK18 (++++), hPL, hCG and MEL-CAM. 11/15 (73%) cases were positive for 3 or more of these markers, 4/15 (27%) cases were positive for 2 markers. 2) The previously described panel of +++ p63 or hPL for subclassification of ITTs to PSTT and ETT was not helpful, because 3 cases were negative for both markers and the most common combination was 1+ for one marker and negative for the other marker (6 cases). 3) The best panel to distinguish ITTs from CAs consists of HLA-G, hCG, CEA and p16 (++++). It correctly separated all CAs from ITTs. 4) Inhibin, pan-keratin and vimentin are not contributory in the subclassification or differential diagnosis of ITTs. 5) hCG previously reported mainly in multinucleated cells and rarely in ITTs was found in 60% of our cases mainly in mononuclear cells.

**851 Endometrial Adenocarcinoma in Premenopausal Women: A Clinicopathologic Study**

*M Khalifa, G Rasty, N Ismiil, I Ackerman, G Thomas, A Covens, R Osborne, S Nofech-Mozes.* Sunnybrook & Women's College Health Sciences Centre, Toronto, ON, Canada.

**Background:** Endometrial cancer is the most common cancer of the female genital tract affecting mainly postmenopausal women. It is not clear whether its outcome in premenopausal patients is different from that of older women. This issue is particularly significant since fertility-preserving treatment strategies have been proposed for younger patients. In this study, we summarize our experience with endometrial adenocarcinoma in premenopausal women.

**Design:** Between 2000-2004, 912 hysterectomy specimens were diagnosed with endometrial adenocarcinoma (EEA) in our department; of which, we identified 43 patients 45 years old or younger who were premenopausal as per their clinical history. Pathology review of all slides was undertaken and the clinical data were retrieved from the patients' electronic charts.

**Results:** Patients ranged from 30 to 45 years old (median = 40 years). Associated neoplasia was noted in the family history of 11 cases and in the same patient in 6 cases (3 invasive mammary carcinomas, 2 endocrine tumors and 1 small cell lung carcinoma). Other common risk factors included: nulliparity (15 patients), obesity (7 patients), and hormonal treatment (6 patients). Thirty tumors (69.8%) were FIGO grade 1, 8 (18.6%) grade 2, and 5 (11.6%) grade 3. In 11 (25.6%) cases the tumor was confined to the endometrium, in 24 (55.8%) myometrial invasion was limited to the inner half, and in 8 (18.6%) invaded the outer half. Cervical involvement was found in 11 (25.6%) cases. Metastases were present in 4 patients (9.3%) at the time of their initial diagnosis (3 ovarian and 1 to pelvic lymph nodes). Four patients (9.3%) have had recurrences, one distant and 3 pelvic, with 24 months mean time to recurrence. Recurrent tumors were originally grade 1; however, in 2 cases poor histological prognosticators such as deep myometrial invasion, vascular invasion and cervical involvement were present in the original resection. At present, all patients are alive.

**Conclusions:** In our experience, EEA in premenopausal patients exhibits clinicopathologic features and outcome similar to that of older women. The high incidence of neoplasia in their family history and that of non-gynecologic malignancies in the same patients is noted.

**852 Pathological Study of Endocervical Gland Involvement by Cervical Intraepithelial Neoplasia and Microinvasive Squamous Cell Carcinoma: MIB-1 Immunostaining Is a Useful Marker for Pathological Diagnosis from the Gland Involvement Site**

*M Kimura, T Matsumoto, H Sonoue, D Ogishima, K Kinoshita, K Suda.* Juntendo University, Tokyo, Japan.

**Background:** Cervical intraepithelial neoplasia (CIN) frequently shows gland involvement (GI) in the cervix, but little information is available regarding GI in CIN.

Also, GI in microinvasive squamous cell carcinoma (MiSCC) has not been studied. Recently, several studies indicated that MIB1 antibodies are promising antibodies for the reliable assessment of CIN from the mucosal surface areas of CIN. Thus, pathological features of GI in CIN and MiSCC as well as diagnostic usefulness of MIB1 immunostaining from GI site were examined.

**Design:** Cervical conization specimens from 120 patients, including 110 cones with CIN (CIN1, 2 cases; CIN2, 21 cases; CIN3, 87 cases) and 10 cones with MiSCC were pathologically examined using conventional stains and MIB1 immunostaining. Statistical examinations were performed using statistical package (SPSS, version 11)

**Results:** The linear extent of mucosal lesion ( $P < 0.001$ ), lateral extent of mucosal lesion ( $P < 0.001$ ) and depth of GI ( $P = 0.001$ ) significantly increased from CIN1 to MiSCC group, but statistical significance in the frequency of GI was not found. Statistical significance was found between linear extent and lateral extent ( $P < 0.001$ ), between linear extent and depth of GI ( $P < 0.001$ ), and between lateral extent and depth of GI ( $P < 0.001$ ). These indicated that the size of mucosal lesion and the depth of GI in CIN gradually increased in accordance with the grade of CIN and that GI became deeper according to the increase of the size of mucosal lesion. The surface MIB1 labeling index (LI) ( $P < 0.001$ ) and GI MIB1 LI ( $P = 0.005$ ) gradually increased from CIN1 to MiSCC. A significant correlation between surface MIB1 LI and GI MIB1 LI was found ( $P < 0.001$ ). Logistic regression analysis indicated that the linear extent of mucosal lesion ( $P < 0.001$ ), surface MIB1 LI ( $P = 0.003$ ) and GI MIB1 LI ( $P = 0.005$ ) were significantly related to the difference between the CIN1 plus CIN2 group and the CIN3 plus MiSCC group. Cut-off values for these factors were 7mm in the linear extent of mucosal lesion, 40% in surface MIB1 LI and 40% in GI MIB1 LI.

**Conclusions:** This study clarified pathological features of GI in CIN and MiSCC and indicated that MIB1 immunostaining is a useful marker for pathological diagnosis of CIN from GI sites.

**853 Coexisting Tubal Intraepithelial Carcinoma (TIC) and Ovarian Serous Carcinoma: Frequency and Implications for the Fallopian Tube as a Source of "Ovarian" Serous Neoplasia**

*DW Kindelberger, Y Lee, C Feltmate, M Callahan, E Garner, RS Berkowitz, MG Muto, CP Crum.* Brigham and Women's Hospital, Boston, MA.

**Background:** The finding of fallopian tube intraepithelial carcinoma (TIC) in BRCA+ women suggests that the tube may be a source of pelvic (tube, ovary, peritoneum) serous cancer in some patients. However, the frequency of TIC in sporadic pelvic serous carcinomas is unclear, largely due to non-uniformity in both pathology reporting and fallopian tube sampling. This study examined consecutive prospective and retrospective data to address this question.

**Design:** TIC was assessed in two groups: 1) in 100 consecutive archived samples of serous carcinoma with non-uniform sampling of the tubes.; 2) in 43 consecutive prospectively accrued samples with complete tubal exam, by a protocol that includes sectioning and extensively examining the fimbriated end (SEE-FIM). TIC was documented by report and pathologic review and correlated with the distribution of ovarian involvement (surface vesus intra-parenchymal).

**Results:** 24 percent of retrospectively analyzed pelvic serous carcinomas contained TIC. 25 and 17 percent of tumors with and without ovarian surface involvement respectively exhibited TIC. In contrast, 54 percent of prospectively analyzed serous carcinomas with complete examination of the fallopian tubes contained TIC. TIC was identified in 74 and 22 percent of tumors with and without ovarian surface involvement respectively.

**Conclusions:** The data from this study indicate that TIC is 1) associated with a significant percentage of pelvic serous carcinomas, 2) is found at much higher frequency in tubes that are thoroughly examined and 3) is present in higher frequency in cases with surface ovarian involvement. Coupled with prior studies of BRCA+ women, these observations indicate that the entire fallopian tube should be examined in all cases of "ovarian" serous carcinoma or those considered at risk for this disease. Although TIC has not been established as the cause of ovarian surface serous carcinoma, it could not be excluded in 68% of cases with thorough tubal examination. Taking this into account, a model for "ovarian" cancer pathogenesis, which accounts for both molecular mechanisms and multiple sites of origin, is proposed.

**854 Fragile Histidine Triad Gene (FHIT) and p16 Expression in Endocervical Glandular Neoplasia**

*E Kling, G Jockle, OB Ioffe.* University of Maryland School of Medicine, Baltimore, MD; Mercy Medical Center, Baltimore, MD.

**Background:** The fragile histidine triad gene (FHIT) is a tumor suppressor gene, which is frequently inactivated in cancers. Absent protein expression has been identified in a variety of precancerous and cancerous lesions, including cervical squamous intraepithelial lesions and squamous cell carcinoma, with some studies showing loss of FHIT expression in association with high-risk HPV infection and worse prognosis in cervical squamous carcinoma. However, there have been virtually no studies addressing FHIT status in endocervical glandular neoplasia. The aim of this study was to ascertain a possible role of FHIT in endocervical glandular carcinogenesis, and to correlate its expression with p16(INK4a), a specific marker of cervical glandular and squamous neoplasia.

**Design:** Paraffin-embedded tissue blocks from 22 adenocarcinomas in situ (AIS) and 9 invasive adenocarcinomas (adenoCa) were selected from the 1995-2005 files. FHIT and p16 immunohistochemical stains were performed. Two observers graded FHIT and p16 expression in the glandular lesions. The expression was also recorded in adjacent benign glandular (n=24) and squamous mucosa (n=23), and associated squamous intraepithelial lesions (SIL) (n=7).

**Results:** The FHIT expression did not differ significantly between neoplastic and benign glandular epithelium: FHIT was negative in 4 of 24 (16%) benign endocervical mucosa, 6 of 22 (27%) AIS and 2 of 9 (22%) adenoCa. However, FHIT expression was absent in



a significantly higher proportion of SIL, 5 of 7 (71%), compared to 2 of 23 (8.7 %) in benign squamous mucosa,  $p=0.001$ . FHIT expression was negative in intestinal glandular metaplasia, and positive in atypical and usual tubal metaplasia. In concordance with previous reports, p16 was negative in 22 of 23 (96%) benign squamous, all 24 (100%) benign glandular epithelia, and was strongly positive in 100% of AIS, adenoCa and SIL,  $p<0.0001$ .

**Conclusions:** Unlike squamous neoplasia, endocervical glandular preinvasive and invasive malignant lesions did not show a significant reduction in FHIT expression, and there was no correlation between FHIT and p16 expression in glandular epithelia. These results suggest that FHIT gene inactivation may not be a factor in endocervical glandular carcinogenesis; however, further studies are needed to elucidate this mechanism.

### 855 High Throughput Tissue Microarray for Analysis of Slug and E-Cadherin in Ovarian Serous Neoplasia

LA Kubba, T Do, TK Woodruff, KW Lannert, R Orr, H Du, LW Klatzco, G Rodriguez, CD Sturgis. Evanston Northwestern Healthcare, Evanston, IL; Northwestern University Feinberg School of Medicine, Chicago, IL; ENH, Evanston, IL; Northwestern University, Evanston, IL.

**Background:** There is growing evidence that epithelial mesenchymal transformation (EMT) plays an important role in both embryogenesis and carcinogenesis, and that this process is mediated by transcriptional repression mechanisms such as down regulation of E-cadherin. Several E-cadherin transcriptional repressors have been characterized, including Snail and Slug, and are thought to interact with the E-cadherin promoter. Little is known, however, regarding EMT in ovarian carcinogenesis. In this study, we examined the expression and relationship of Slug and E-cadherin in the spectrum of ovarian serous neoplasms.

**Design:** High throughput tissue microarrays were created from 38 non-consecutive primary resection cases of benign serous cystadenoma (BSC) (mean age=56 yrs), 36 cases of borderline serous papillary neoplasm (BSPN) (mean age=52 yrs) and 40 cases of serous carcinoma (SC) (mean age=62 yrs). (Study period 1996-2005). Multiple 0.6 mm cores of paraffin-embedded tissue were harvested. Slides from the arrays were studied by immunohistochemistry (IHC) with antibodies to Slug and E-cadherin. IHC was reviewed by two pathologists (CDS, LAK). Clinical outcomes were assessed for BSPN and SC cases.

**Results:** Nuclear and cytoplasmic reactivity were detected in Slug IHC. Statistically significant non-equal distributions for Slug (nuclear reactivity) ( $p<0.0001$ ) and E-cadherin ( $p<0.0001$ ) were seen in comparing BSC vs BSPN vs SC by Fisher's exact test. There was a non-significant distribution of Slug (cytoplasmic reactivity) ( $p<0.08$ ) across the three groups of serous neoplasms. As tumor differentiation decreased BSC->BSPN->SC, a significant decrease in nuclear Slug reactivity was noted ( $p<0.0001$ ). E-cadherin demonstrated an increase in reactivity with decreasing differentiation ( $p<0.0001$ ). Nuclear Slug reactivity was not independently associated with survival in SC.

**Conclusions:** Recent investigations have shown that Slug is a major determinant of ovarian cancer invasiveness at the transcription level. Our results indicate that serous ovarian neoplasms demonstrate greater E-cadherin immunoreactivity and diminished nuclear Slug reactivity as tumor differentiation decreases. This novel finding supports a role for Slug during ovarian serous tumorigenesis at various levels of differentiation.

### 856 Molecular Profiling of Primary Versus Recurrent Ovarian Serous Papillary Adenocarcinomas

A Laios, SA O'Toole, BL Sheppard, NC Gleeson, T D'Arcy, EPJ McGuinness, M Ring, O Sheils, JJ O'Leary. Trinity College Dublin, Dublin, Ireland; Coombe Women's Hospital, Dublin, Ireland.

**Background:** Treatment of ovarian cancer includes surgery and combination chemotherapy with platinum and taxane drugs. Unfortunately, even with an initial 80% response rate, most women relapse and are resistant to chemotherapy, as indicated by less than 20% long term survivors. Previous studies using single gene biomarkers to predict tumour response have been inconclusive. Patterns of gene expression for sensitivity and resistance are likely to involve multiple gene pathways. We hypothesised that differences in gene expression between primary and recurrent tumours could identify patients that would relapse.

**Design:** The study group consisted of 10 serous papillary ovarian adenocarcinomas, 5 primary, stage 3, grade 3 and 5 recurrent tumours. Frozen sections were cut to ensure that samples included >70% tumour cells. RNA was extracted using the Qiagen kit and processed into Digoxigenin labelled cRNA by reverse transcription-in vitro transcription (RT-IVT). Gene expression analysis was performed using the chemiluminescence based Applied Biosystems array 1700 system which has 31,077 probes and targets a complete annotated and fully curated set of 27,868 human genes from the public and Celera databases. Technical replicates were performed for each sample. Bioinformatics was performed using spotfire and R.

**Results:** 436 genes were differentially expressed between primary and recurrent tumours ( $p<0.01$ ). 145 genes were upregulated and 291 downregulated in recurrent compared to primary. Numerous pathways mediated by PIK3CG and PRKCG were upregulated, such as angiogenesis, hypoxia, endothelin signalling pathway, EGF receptor and FGF signalling pathways. Some components of the signalling pathways were downregulated as were genes involved in apoptosis, glycolysis and the plasminogen activating cascade.

**Conclusions:** Significant differences were found in gene expression between primary and recurrent ovarian tumours. Further investigation of the signalling pathways mediated by PIK3CG and PRKCG is needed to determine their role in recurrence of ovarian cancer. Further analysis and validation of these expression profiles may identify panels of genes that correlate with chemosensitivity or chemoresistance. It is likely

that some of the differentially expressed genes will have potential therapeutic value in the recurrence of ovarian cancer.

### 857 Residual/Recurrent Disease after Loop Electrosurgical Excision Procedure of Low-Grade Cervical Intraepithelial Neoplasia (CIN 1)

S Landolfi, I Alonso, A Torné, LM Puig-Tintoré, R Esteve, L Quinto, E Campo, J Ordí. IDIBAPS-Hospital Clínic, Barcelona, Spain.

**Background:** Most reported series evaluating human papillomavirus detection in the follow-up of patients treated of cervical intraepithelial neoplasia (CIN) are focused on high grade (CIN 2-3) lesions. However, loop electrosurgical procedure (LEEP) is currently being used to treat some low-grade cervical intraepithelial neoplasia (CIN 1), particularly in patients with endocervical extension, large or long-time persistent lesions and in old women. The aim of this study was to evaluate the predictive capacity of pre-treatment factors as well as the ability of current diagnostic tools to identify residual/recurrent disease in the follow-up of patients with CIN 1 treated by LEEP.

**Design:** Fifty-five women (mean age  $36.7 \pm 9.4$  years, range 20-59) with histologic diagnosis of CIN 1 treated by LEEP and confirmed in the conization specimen attending a follow-up control were included in the study. Pre-treatment clinical factors, particularly age and high-risk human papillomavirus (HR-HPV) load detected by Hybrid Capture 2 (in relative light units, RLU), as well as cone margins were evaluated as predictors of residual/recurrent disease. Cytology and HR-HPV detection and viral load during follow-up were analyzed as diagnostic tools of recurrence.

**Results:** Positive cone margins were identified in 15/55 patients (27.3%). Pre-treatment HR-HPV was positive in 94.1% of women. Persistent/recurrent disease was identified in 19 patients (34.5%); two of them recurred as high-grade lesions. Mean pre-treatment HPV load of cases developing persistent/recurrent disease was significantly higher than patients showing no recurrence ( $2226.8 \pm 3620.2$  vs.  $717.5 \pm 949.2$ ,  $p<0.05$ ). Fifty percent of cases with >100 RLU at the pre-treatment HPV test developed persistent/recurrent disease, contrasting with 16.7% of cases below 100 RLU. Sensitivity, specificity, positive and negative predictive values of HR-HPV detection during follow-up (100%, 84%, 79% and 100% respectively) were slightly higher than those of cytology (95%, 86%, 78% and 97%) and much better than those of cone margins (37%, 78%, 47% and 70%).

**Conclusions:** The inclusion of HR-HPV testing in conjunction with cytology may be helpful in follow-up protocols for monitoring patients treated of CIN 1. Patients with high pre-treatment HR-HPV load should be considered at risk for developing persistent/recurrent disease.

### 858 MicroRNA Profiling Reveals Distinct Signatures in Uterine Leiomyomas

L Laura Obijuru, T Wang, P Soteropoulos, JJ Wei. New York University, New York, NY; Public Health Research Institute, Newark, NJ.

**Background:** MicroRNAs (miRNAs) are a class of small, non-coding RNAs. They regulate about 1/3 of functional genes in transcription and translation levels. They are normally involved in various biological processes, including cell proliferation and cell death during development and are aberrantly expressed in certain types of cancers. Human uterine leiomyomas (ULM) are the most common neoplasms of women with lifelong incidence up to 80%. Current knowledge of tumorigenesis can not explain such a high incidence of ULM. We hypothesized that the fibroid uteri may have developmental defects involved by dysregulation of miRNAs.

**Design:** 20 hysterectomies for ULM were selected. Patients were selected from different races, endometrial phases, ages and tumor sizes. miRNAs enriched RNAs were prepared from ULM and matched myometrium. miRNA microarrays were prepared including 206 well-characterized human miRNAs and 4 control oligos, and spotted in triplicate on the chip. miRNA probes were fluorescently-labeled with dye Cy3 (normal myometrium) and Cy5 (ULM). The processed slides were scanned using an Axon GenePix 4000B scanner. Data extraction and global normalization were performed by GenePix Pro 5.1. Unsupervised cluster analysis was performed using Cluster and TreeView. The significance for up or down regulation of miRNA were analyzed by SAM.

**Results:** A global analysis of 206 miRNAs in 17 ULM and matched myometrium reveal homogenous but distinctive expression profiles from each tumor by unsupervised hierarchical clustering. The 10 miRNAs with the greatest level of over or under expressed in normal uterus studied by Ambion Inc, correlated well with the data from this study. Of 206 miRNAs, 17 were up regulated and 35 down regulated in ULM with statistical significance ( $p<0.001$ ). Six of 10 *let7* family members were significantly up regulated in ULM. There are two groups of ULM with distinct expression profiles. One of these (13 cases) exhibited up-regulation of most of the *let7* family of miRNAs and the other (4 cases) showed minimal changes in these miRNAs.

**Conclusions:** There are distinct miRNA signatures in ULM in our study which compare favorably with the miRNA profiles in other normal and neoplastic tissues described in the literature. Up regulation of *let7* family members is substantial in contrast to studies from some malignant neoplasms, such as lung cancer. Expression profiling also separates two distinct groups of ULM, which differ in their expression of the *let7* family of miRNAs.

### 859 High Prevalence of Cutaneous HPV in Spontaneous Abortions

HW Lee, JS Ross, A Rohwedder, JA Carlson. Albany Medical College, Albany, NY; Bio-Med-Mol-Serv, Kalkar, Germany.

**Background:** To determine the role of human papillomaviruses (HPV) in spontaneous abortions (SAB).

**Design:** DNA was retrieved from 109 products of conception (POC) [54 placenta and umbilical cords from Cesarean section deliveries (CSD)(26) and spontaneous vaginal deliveries (SVD)(28); 55 placental/fetal parts from elective abortions (EAB)(27) and SAB (28)]. Nested polymerase chain reaction (PCR) with multiple degenerate consensus and type specific primers and direct sequencing of PCR products was

performed. Samples were considered positive if HPV type was confirmed by second independent PCR.

**Results:** Overall, 76% of all POCs were found to harbor HPV DNA. Twenty-three different HPV types were identified, including 7 putative new types. Epidermodysplasia verruciformis (EV) associated types were the most frequent HPV types (59%), followed by cutaneous HPV types (35%), and genital-mucosal HPV types (16%). Multiple HPV DNAs were found in 43% of all POCs. Increasing gestational age significantly correlated with increasing number of HPV types detected as well as with the presence of HPV 3 DNA ( $r=0.24/0.27$ ,  $P\leq 0.04$ ). The most common HPV types were HPV 3 (35%), HPV 17 (34%), HPV 16 (13%), HPV 20 (8%) and HPV 6 (6%). Comparing classes of POC, SVD had the highest frequency of HPV DNA at 86% followed by CSD (77%), SAB (75%) and EAB (67%). Comparing SAB versus EAB, and SVD vs. CSD revealed a significantly higher frequency of HPV 3 in SAB (36% vs. 7%) and SVD (68% vs. 27%) ( $P\leq 0.01$ ). No differences in frequency of other HPV DNAs between classes was detected.

**Conclusions:** HPV is now being considered part of the commensal microflora of human epithelia; HPV becomes clinically manifest (activated from a latent state) by local or systemic immunosuppressive conditions. The fact that the majority of POCs harbored HPV supports the contention that HPV is commensal and transmission occurs early life, in utero or at time of delivery (vertical transmission). However, the significantly higher rate of cutaneous HPV 3 found in SAB compared to EAB suggest the possibility that HPV types may be an etiologic agent in at least some SAB.

### 860 Expression of Carbonic Anhydrases in Patients with Uterine Cervix Cancer: An Immunohistochemical Analysis and Correlation with Lymph Node Metastases

S Lee, EK Hong, SS Seo, SY Park, JY Kim. National Cancer Center, Goyang-si, Gyeonggi-do, Republic of Korea.

**Background:** Uterine cervical cancer is a highly curable disease with radiotherapy but its propensity to spread via lymphatic chain is largely the cause of treatment failure. We pursued whether carbonic anhydrase 9 and 12 (CA9/CA12) expression of the primary cervical tumor can predict such lymph node (LN) metastases.

**Design:** Seventy-five patients were laparoscopically explored for their LN status before definitive radiotherapy was given. Immunohistochemical study was performed for CA9 and CA12 for primary cervical tumor samples of the patients and the results were matched to the LN status, either any positive LN (pelvic +/- para-aortic) or distant LN (PAN+common iliac LN). The expression of CA9 was graded as 0-3, and CA12 as positive or negative. Statistical analysis was made using SPSS software, version 10.0.

**Results:** The follow-up period ranged from 2 to 47 months (median = 23 months). CA9 and CA12 expression was detected in 60% (45/75) and 39% (29/74) of tumors, respectively. There was only 20% (15/75) of the patients whose tumors expressed both CAs, but their expression did not co-localize in most of those cases. CA9 expression was significantly associated with the tumor-positive LNs either among any LN-positive group or in para-aortic LN (PAN)-positive group ( $p=0.05$ , Pearson chi-square test). The expression of CA9 was also strongly associated with the development of distant metastases ( $p=0.04$ ). As opposed to this, CA12 expression was inversely associated with such LN metastases although it did not reach statistical significance. Interestingly, CA12 expression was linked to more differentiated histology ( $p=0.02$ ) while CA9 did not show any relationship with differentiation of the tumors. Univariate analysis revealed the expression of CA9 unfavorably affected disease free survival (DFS) ( $p=0.04$ , Kaplan-Meier log rank test), whereas CA12 expression tended to show better DFS ( $p=0.65$ ). On multivariate analysis of the clinicopathologic factors, CA9 expression remained as the single most important factor for predicting the patients' prognosis.

**Conclusions:** Our study strongly suggests that CA9 expression may be used as a predictive marker for LN metastasis as well as development of distant failures during follow up in patients with uterine cervix cancer. Although known to be hypoxia-inducible as CA9, CA12 may play additional functions in tumor microenvironment and affects the treatment response of the tumors.

### 861 Discrete and Intense p53 Immunostaining in Morphologically Normal Fallopian Tube Epithelium: Frequency, Cell Phenotypes and Comparison to Serous Carcinoma

Y Lee, F Medeiros, FD McKeon, MG Muto, D Cramer, CP Crum. Brigham and Women's Hospital, Boston, MA; Harvard Medical School, Boston, MA.

**Background:** From 5-10% of prophylactic tubo-oophorectomies in BRCA+ women reveal occult tubal cancer, and recent evidence suggests the fimbriated end of the fallopian tube (FT) is a preferred site of origin. p53 mutations and p53 immunopositivity correlate strongly with these tumors as well as sporadic pelvic serous carcinomas. However, no precursor epithelial lesion has been defined for these tumors. The purpose of this study was to characterize discrete foci of intense p53 staining in the normal FT mucosa and compare them to serous neoplasia.

**Design:** We analyzed cases of normal-appearing FT mucosa from BRCA+ (31) and negative (59) women for discrete and intense p53 immunostaining, using a protocol for sectioning and extensively examining the fimbriated end (SEE-FIM). Age, location and cell type (ciliated versus secretory) were recorded. Cell type was determined by immunostaining for markers that highlighted ciliated (p73, LhS28) and secretory (HMFG2) cells. A positive score for p53 required intense nuclear staining in over 80% of at least 12 consecutive nuclei.

**Results:** 35 and 34 percent of BRCA+ and normal tubes scored positive and overall, 73, 16 and 11 percent were found in the fimbria alone, fimbria and proximal tube, and proximal tube alone. The mean age of p53+ was significantly higher than p53- cases in both

BRCA+ women (55 vs 45 yrs) and controls (61 vs. 55 yrs.). p53+ cells were predominately secretory, as determined by positive immunostaining for HMFG2 and negative staining by p73 and LhS28. Locus size ranged from 12 or more cells to over 100; none involved an entire plica. Virtually all loci contained low MIB-1 index.

**Conclusions:** This study has demonstrated, for the first time, the existence of p53-positive epithelial foci in non-neoplastic tubal mucosa. Although common and typically non-proliferative, they share certain features with tubal serous cancer; which include a staining distribution consistent with a clonal process, intense positivity for p53 in over 80% of cell nuclei, higher frequency in older women, preference for the fimbriated end of the tube, and localization to non-ciliated (secretory) cells. The relationship of these p53+ foci to genetic alterations in p53, and their connection to other events that lead to serous neoplasia merit investigation.

### 862 A Unifying Concept of Trophoblastic Differentiation That Is Based on Inductive Epithelial-Stromal and Epithelial-Fibrin Interactions and Highlighted by Localization of $\Delta$ Np63

Y Lee, CP Crum, FD McKeon, A Yang, MM Parast. Brigham and Women's Hospital, Boston, MA; Harvard Medical School, Boston, MA.

**Background:** Several trophoblast (t-blast) phenotypes, including pre-villous, cyto and syncytial t-blast, extra-villous (intra-placental and membraneous) and implantation site t-blast are observed in the placenta and uterus throughout development. Expression of p63 highlights a subset of these cells, but localization of p63 varies. We profiled p63 localization in placental tissue using antibodies to the full-length (TA) and dominant negative ( $\Delta$ N) isoforms.

**Design:** Placental tissues were immunostained for antibodies specific for TAp63 and  $\Delta$ Np63, signifying the full-length and truncated dominant-negative isoforms respectively. Staining was correlated with t-blast type and in some, MIB-1.

**Results:** 75 placentas from 6 weeks gestational age to term were analyzed. In early gestation, p63 was localized principally to the villous cyto t-blast, consistent with induction of p63 following contact of the pre-villous t-blast with the villous mesenchyme. In the mature placenta, deposition of intraplacental perivillous fibrin was associated with loss of the cyto t-blast phenotype and emergence of extra-villous p63+ vacuolated ("transitional t-blast") that matured into mature extravillous (so-called intermediate) t-blast. In the membranes, t-blast displayed these phenotypes; vacuolated (transitional) t-blast localized nearer the stroma. MIB-1 and p63 did not co-localize, indicating that the two were not interdependent. All p63-positivity in t-blast was attributed to  $\Delta$ Np63, including membraneous trophoblast.

**Conclusions:** The p63 immunoprofile in placental trophoblast is consistent with the concept that t-blast differentiation, like other epithelia, is influenced by the tissues with which the t-blast are juxtaposed. These interactions determine whether cytotrophoblast evolves into syncytiotrophoblast (villous stroma), intermediate trophoblast (intervillous fibrin) and membraneous trophoblast (chorionic mesenchyme). In the latter two, a specialized p63-positive vacuolated t-blast (so-called transitional trophoblast) marks the transition from cytotrophoblast to mature (intermediate) trophoblast. Because of overlap in t-blast phenotypes between different placental regions, normal and abnormal (neoplastic) trophoblast differentiation is more accurately defined according to individual induction pathways than specific locations.

### 863 Expression of the Selected Gene Products in Uterine Adenomyosis Is Inversely Associated with That in Uterine Leiomyomata

M Levy, L Chiriboga, X Zhang, K Mittal, JJ Wei. St Joseph's Hospital and Medical Center, Phoenix, AZ; New York University Medical Center, New York, NY.

**Background:** Uterine adenomyosis (ADM) is a common disease in women of the reproductive age. It often coexists with uterine leiomyoma (ULM). The cause of ADM is largely unknown. Several genes, including IGF2, are dysregulated in hormone induced ADM in animal models. We found previously that ULM with ADM have negative effects on gene expression and tumor size in comparison to those without ADM. We initiated this study to further characterize the gene expression patterns in ADM.

**Design:** 46 hysterectomies with both ADM and ULM were collected. All patients were of reproductive age (mean age 42 yrs) and the endometria were all in the follicular phase. Tissue cores from the endometrium, myometrium, ADM and ULM were microarrayed (TMA), and the protein markers ER, PR, RXR, IGF2, IGF1R, PDGF, EGFR and Bcl2 were examined by semiquantitation immunohistochemistry. Normal endometrium and myometrium were used as matched controls for ADM and ULM. Expression of IGF2 was further examined by cRNA in situ hybridization (ISH) and RT-PCR. The net gain or loss of gene products from all cases was analyzed by non-supervised cluster analysis.

**Results:** The mean expression levels of ER, RXR, IGF2, IGF1R, PDGF and EGFR were down regulated in ADM in comparison to the matched endometrium. Down regulation of IGF2 and IGF1R in ADM was more prominent within the stromal component. Down regulation of IGF2 was also evident in mRNA levels detected by ISH and RT-PCR. When compared to those in the matched myometrium from the same group of patients, all of these gene products were up regulated in the ULM. Bcl2 and PR were the only markers that demonstrated slight up regulation in ADM. Cluster analysis separated ADM and ULM as two distinct groups, indicating a completely different transcription profiling between these two diseases.

**Conclusions:** 1) There is significant down regulation of the selected gene products in ADM in comparison to those in the normal endometrium, indicating low gene activity in ectopic endometrial tissue. 2) ULM in uteri coexisting with ADM have lower level of the gene expression and smaller tumor sizes. 3) Down regulation of IGF2 in human ADM is consistent with the findings in animal models.

### 864 Metastatic Colorectal Adenocarcinoma with Ovarian Involvement and Elevated Serum CA125: A Potential Diagnostic Pitfall

MR Lewis, ED Euscher, MT Deavers, EG Silva, A Malpica. U of Vermont, Burlington, VT; UT MD Anderson Cancer Center, Houston, TX.

**Background:** Gynecologic oncologists use serum levels of CA125, a glycoprotein produced by ovarian surface epithelial cells and mesothelial cells, as a marker of neoplastic disease. In a woman with a pelvic mass and an elevated CA125, clinical suspicion of a primary ovarian epithelial neoplasm rises, and a histopathologic diagnosis of metastatic carcinoma may elicit surprise on the part of the clinician. The overlap in gross and histologic features between primary ovarian tumors and metastases may render diagnosis even more challenging. We have determined the frequency of serum CA125 elevation in a series of women with ovarian involvement by metastatic colorectal adenocarcinoma (MetCRCa) and compared the features of cases with and without elevated CA125.

**Design:** We reviewed 88 cases of MetCRCa in the ovary diagnosed since 1995. Clinical data were recorded, including preoperative CA125 level when present. Gross features were obtained from pathology reports; H&E slides were reviewed in all cases.

**Results:** 14 of 88 patients (16%) had an elevated serum CA125 level (>35 U/mL) preoperatively (39.0-556.3, median 177.7, mean 216.6). Patients ranged in age from 34 to 85 years (median 52); 5 of 14 (36%) were ≤40 years of age. Abdominopelvic pain was the most common presenting symptom (7/14); 3 patients were asymptomatic. In 11 of 13 cases, an ovarian mass was the first manifestation of the disease; only 2 patients had a history of colorectal adenocarcinoma. In 7 cases, no preoperative CEA level was recorded. Ovarian involvement was bilateral in 9 cases; in 4 cases there was a unilateral ovarian mass ≥10 cm. Clinical, gross, and histologic features, including frequency of surface involvement, were similar to those in cases with no associated CA125 elevation. In 2 cases, the tumor was initially diagnosed as an ovarian primary (endometrioid, 1 case; papillary serous, 1 case); these patients were treated with chemotherapy suited for ovarian primaries.

**Conclusions:** 16% of women with ovarian involvement by MetCRCa have an elevated serum CA125 level prior to oophorectomy; this confirms that even in a woman with an ovarian mass, elevated CA125 should not be interpreted as a specific indicator of primary ovarian epithelial neoplasia. The possibility of metastasis from the intestinal tract, particularly if raised by gross or histologic features at intraoperative consultation, should not be dismissed on the basis of elevated CA125, even if clinical suspicion of metastatic involvement is low.

### 865 Comparison of p16 and KOC Expression in Benign Glandular Epithelium and Adenocarcinoma in Situ of the Uterine Cervix

C Li, L Kordunsky, A Fischer, K Dresser. University of Massachusetts Medical School, Worcester, MA.

**Background:** Adenocarcinoma in situ (AIS) of the uterine cervix can be diagnostic challenge in some cases. The cyclin-dependent kinase inhibitor p16 protein has been shown to be overexpressed in cervical intraepithelial neoplasia (CIN) and adenocarcinoma. KOC, also known as L523S, is a newly identified oncofetal protein, which was discovered by using PCR-based cDNA library subtraction in conjunction with high throughput microarray screening techniques. The aim of this study was to evaluate the potential of p16 and KOC as biomarkers for uterine cervical AIS.

**Design:** We identified twenty cases of AIS (n=20) and twelve cases of benign cervical specimens removed for non-malignant uterine lesions from the surgical pathology files of UMMHC. All 12 cases of cervix had benign endocervical glandular epithelium (BEG; n=12). Of these 12 cases of BEG, nine showed focal tubal metaplasia (TM; n=9). Sections were cut at 5 microns and immunostained using p16 or KOC antibodies on an automated immunostainer. Positive p16 or KOC staining was scored as negative, 1+ (<25% of cells positive) or 2+ (>25% of cells positive).

**Results:** As shown in Table 1, all 12 cases of BEG were negative for both p16 and KOC. Twenty out of 20 (100%) and 16 out of 20 (80%) AIS cases showed 2+ staining for p16 and KOC, respectively. All nine TM cases were negative for KOC, but positive for p16.

Table 1. Immunohistochemical Staining Results for p16 and KOC (Expressed as the Percentage of Cases in Each Category)

Diagnosis	Negative p16	Negative KOC	1+ p16	1+ KOC	2+ p16	2+ KOC
BEG	100 (12/12)	100 (12/12)	0.0 (0/12)	0.0 (0/12)	0.0 (0/12)	0.0 (0/12)
TM	0.0 (0/9)	100 (9/9)	11.1 (1/9)	0.0 (0/9)	88.9 (8/9)	0.0 (0/9)
AIS	0.0 (0/20)	10 (2/20)	0.0 (0/20)	10 (2/20)	100 (20/20)	80 (16/20)

**Conclusions:** Our findings demonstrate significant expression of p16 and KOC in AIS as compared with benign endocervical glands, suggesting that p16 as well as KOC expression may be helpful in the distinction of AIS from BEG, particularly in difficult cases. However, due to the fact that p16 positive staining was also identified in TM cases, p16 as a biomarker for the diagnosis of AIS must be used with caution.

### 866 Histologic Evidence of Endometrial Tissue Implant/Ingrowth at Cesarean Section Site: A Probable Mechanism for Late Complications

M Li, R Madan. Montefiore Medical Center/Albert Einstein College of Medicine, Bronx, NY.

**Background:** Catastrophic rupture of pregnant uterus and placenta previa/accreta are major late complications of Cesarean section (CS). Presence of a uterine scar, impaired decidualization and failure of "differential growth" at the CS site have been proposed as possible mechanisms. However, unequivocal histologic evidence supporting these hypotheses is lacking.

**Design:** Five hysterectomy specimens from patients with prior histories of CS were studied histologically. The first case, a woman with a history of CS eight years ago, had a uterine rupture at the prior CS site following vaginal delivery. The second hysterectomy was performed for placenta previa/percreta at 28 weeks of gestation from a patient with a history of multiple CS. The remaining three hysterectomies were performed for irregular bleeding or leiomyomas from patients with histories of CS. Multiple transmural sections, from endometrium to serosa, from the CS sites of the hysterectomies were examined

microscopically. Immunohistochemical stains for cytokeratins were performed to confirm the presence of epithelial glands.

**Results:** Endometrial tissue, including both glands and stroma, was found at the CS sites in all five cases. In the case with rupture, endometrial tissue lined the ruptured site. In the case with previa/percreta, endometrial tissue was present between the myometrium and chorionic villi at the percreta site. In both cases, penetration of endometrial tissue through the full thickness of the myometrium, from the submucosa to the subserosa, was demonstrated. In the remaining three cases, a wedge-shaped defect lined by endometrium was noted at the endometrial aspect of the CS site, extending approximately one third into the myometrium.

**Conclusions:** 1. We demonstrated for the first time that endometrial tissue may grow into CS sites. 2. We propose that it may arise from tissue implantation during surgery or penetrating growth into the CS wound during healing. The presence of endometrial tissue may impair healing process, resulting in potential rupture in following pregnancies, and may facilitate implantation by embryos and placental growth into the myometrium, resulting placental previa/accreta. 3. Histologic evidence may be overlooked since it requires meticulous examination of multiple sections from CS sites. 4. Further studies are necessary to confirm the current findings and to determine the incidence.

### 867 Clonality of Borderline and Serous Carcinoma of the Ovary: Molecular Studies Identify a Monoclonal Origin for Primary Tumors and Their Implants

EML Li Ning, LS Teller, RSJ Ricketts, C Otis, M Sobel, MJ Merino. National Cancer Institute/National Institutes of Health, Bethesda, MD; Baystate Medical Center Tufts University School of Medicine, Springfield, MA.

**Background:** It is still controversial whether the peritoneal implants that develop in association with ovarian serous tumors represent spread from a single ovarian site or whether such tumors represent synchronous primaries, and therefore originate from different cell clones. Serous borderline tumors of the ovary (SBT) frequently have an excellent prognosis even when there is involvement of multiple intraabdominal foci. Consequently, peritoneal implants of SBT are often not considered true metastases, especially if they are of the noninvasive type. We here used the Human Androgen Receptor Assay (HUMARA) in a group of SBTs and serous carcinomas to evaluate whether bilateral ovarian neoplasms and their peritoneal implants derived from the same clone.

**Design:** Forty three synchronous tumors obtained from 12 patients with bilateral serous ovarian tumors (7 invasive serous carcinomas and 5 serous borderline tumors) and their implants were studied. Bilateral tumors were present in 9 patients (5 carcinomas and 4 SBTs). Peritoneal implants were available for HUMARA in all 7 carcinomas and 3 SBTs. Formalin-fixed paraffin-embedded blocks were obtained for each of the tumors studied. Normal and tumor cells were manually microdissected and lysed in proteinase K buffer. DNA was purified by phenol/chloroform extraction and precipitated with Pellet Paint NF Co-Precipitant (Novagen). Two DNA aliquots were digested with either HhaI or RsaI and a third aliquot was not digested. DNA was then subjected to PCR and analyzed on the ABI PRISM® 310 Genetic Analyzer.

**Results:** Three serous carcinomas were noninformative for HUMARA, 2 of these cases were homozygous and the third presented overlapping alleles. Within each of the other cases, right and left ovarian tumors, as well as the peritoneal implants, presented the same nonrandom methylation pattern suggestive of a monoclonal origin.

**Conclusions:** Our X-inactivation analysis confirms a common clonal origin for bilateral ovarian SBTs and for advanced stage bilateral serous carcinomas with peritoneal metastases. Our finding of a same methylation pattern in both ovarian SBTs and their noninvasive implants, suggests that the peritoneal lesions could be the result of metastatic spread rather than independent synchronous tumors.

### 868 PDGFR $\alpha$ and PDGFR $\beta$ Are Expressed in Endometrial Stromal Sarcoma: A Potential Therapeutic Target for Tyrosine Kinase Inhibitors?

B Liegl, O Reich, FF Nogales, S Regauer. Medical University of Graz, Graz, Austria; University of Granada, Granada, Spain.

**Background:** Endometrial stromal sarcomas (ESS) are rare hormone sensitive tumors occurring in premenopausal women. Treatment is primarily surgical with salpingo-oophorectomy, which induces surgical menopause but recurrence rates are high. Adjuvant chemotherapy, radiation hormonal therapy are ineffective or have severe side effects. Little is known about the etiology and genetic mechanisms in the oncogenesis of endometrial stromal tumors, quite in contrast to stromal tumours in the gastrointestinal tract (GIST) in which activating somatic mutations of the transmembrane tyrosine kinase receptor proto-oncogene c-KIT have been identified. GISTs respond to therapy with tyrosine kinase inhibitors, which exert an inhibitory activity on multiple class III receptor tyrosine kinase members such as c-KIT, platelet-derived growth factor receptor alpha and beta (PDGFR $\alpha$ , PDGFR $\beta$ ).

**Design:** We investigated the expression of PDGFR $\alpha$  and PDGFR $\beta$  in 37 archival ESS with antibodies against PDGFR $\alpha$ , PDGFR $\beta$  and c-KIT according to standardized procedures. Staining was scored as negative (<10% positive tumor cells), weakly positive (10-50% positive cells) and strongly positive (>50% positive cells).

**Results:** All ESS were negative for c-KIT. PDGFR $\alpha$  was expressed strongly by 17/37 ESS and weakly by 5/37 ESS in a cytoplasmic / membranous pattern and PDGFR $\beta$  showed strong cytoplasmic and nuclear staining in 4/37 ESS, and weak cytoplasmic staining in 4/37 cases. Furthermore, there was strong staining of endothelial cells.

**Conclusions:** Patients with PDGFR positive ESS may benefit from treatment with tyrosine kinase inhibitors. At present, we do not know if PDGFR mutations are responsible for the observed overexpression. Alternative mechanisms which result in increased immunoreactivity of tumour cells for PDGFR include activation of tyrosine kinase receptors due to auto- and paracrine stimulation loops, loss of phosphatase activity, cross activation by another kinase, promoter activation by methylation.

PDGFRs are expressed in endothelial cells, are involved in pericyte recruitment to capillaries and development of vascular smooth muscle cells. Tyrosine kinase inhibitors have been shown to decrease micro vessel density in ovarian carcinomas and they may also reduce tumor growth in ESS or recurrence rates in women with ESS. A clinical trial may be indicated for women with persistent, recurrent or metastasizing ESS

### 869 Intestinal and Endocervical-Like Ovarian Mucinous Neoplasms Are Immunophenotypically Distinct Entities

*X Lin, YL Liu, RS Saad, JF Silverman.* Allegheny General Hospital, Pittsburgh, PA. **Background:** Ovarian mucinous neoplasms (OMN) are traditionally classified as either intestinal or endocervical-like subtypes. Separation of the two subtypes is important since they differ in clinical presentation, prognosis and the response to treatment. However, the two subtypes of OMNs can occasionally be difficult to be histologically separated. In addition, the immunophenotype of the two subtypes of OMN has not been adequately investigated. In this study, we compared the immunophenotypic profiles of the two subtypes of OMN by examining some organ specific transcriptional factors and conventional epithelial immunohistochemistic (IHC) markers.

**Design:** A total of 28 ovarian mucinous neoplasms were retrieved from the hospital computer system, consisting of 14 intestinal, 12 endocervical-like and 2 mullerian subtypes. 10 cases of ovarian endometrioid type adenocarcinomas were included as the control group. Immunostaining for PDX-1, CA-125, CK7, CK20, CDX-2, WT-1, D2-40 and TTF-1 were performed on an automated immunostainer with appropriate positive and negative controls. The statistical analysis was performed with Chi-Square method. **Results:**

Immunohistochemical findings of a panel of IHC markers in ovarian neoplasms						
Types	No.	PDX-1	CA-125	CK7	CK20	CDX-2
OMN						
Intestinal	14	100.0%*	14.3% <sup>^</sup> *	100.0%	100.0%*	28.6%*
Endocervical	12	0.0%	100.0%	100.0%	16.7% <sup>^</sup>	0.0%
OMN						
Mullerian	2	50.0%*	50.0%*	100.0%	0.0%	0.0%
OMN						
Endometrioid	10	0.0%	90.0%	100.0%	10.0% <sup>^</sup>	0.0%

\*: P < 0.01; <sup>^</sup>: Focal positive.

All the intestinal OMNs, endocervical-like OMNs, mullerian OMNs and endometrioid adenocarcinoma were negative for WT-1, D2-40 and TTF-1.

**Conclusions:** Our results demonstrated that the intestinal and endocervical-like OMNs are immunophenotypically distinct entities with the intestinal subtype showing positive immunostains for PDX-1 and CK20, and negative staining for CA-125. In contrast, the endocervical-like subtype expressed CA-125, with negative immunoreactivity for PDX-1 and CK20. In the work-up of metastatic mucinous carcinoma of unknown origin, caution should be exercised in interpreting the immunophenotype regarding possible OMN.

### 870 Hepsin Expression in Surface Epithelial Carcinomas of the Ovary. An Immunohistochemical Tissue Microarray Analysis of 70 Cases

*E Lopez-Varela, AF Fuller, S Orsulic, J Miao, KU Parks, E Oliva.* Massachusetts General Hospital, Boston, MA.

**Background:** Hepsin, an extracellular membrane-anchored serine protease, is required for cell growth. It also activates the extrinsic blood coagulation pathway on the cell surface leading to thrombin formation. Hepsin has been recently shown to be overexpressed mainly in prostate but also in ovarian cancer (one study), and abnormal expression has recently been shown to promote cancer progression and metastases in mouse models. The goal of this study was to study hepsin expression in different subtypes of ovarian cancer and correlate hepsin expression with clinicopathological parameters. **Design:** Two tissue microarrays were constructed from paraffin-embedded blocks including 26 serous, 17 endometrioid, 17 clear cell, 6 mucinous, and 4 transitional cell carcinomas from patients with available clinicopathological information. Percentage of positive cells, localization and intensity (1+, 2+, 3+) of staining were recorded.

**Results:** All but two clear cell carcinomas showed strong membranous staining which was seen in >70% of the cells in 12/15 cases. Fourteen serous carcinomas showed predominant membranous staining (mostly >70% and 2 to 3+) and 12 had predominant cytoplasmic staining, 8 of them with membranous reinforcement (mostly >70% and 2 to 3+) and one showed membranous staining (100% and 3+). Mucinous and transitional cell carcinomas showed cytoplasmic staining (15-100% and 2 to 3+ and >90% and 2 to 3+ respectively). However, neither the pattern nor the intensity of staining correlated with tumor grade, stage or survival. Of interest one of the patients with clear cell carcinoma presented initially with deep venous thrombosis and associated strokes.

**Conclusions:** Even though hepsin seems to be implicated in the pathogenesis of ovarian cancer, in contrast to prostate cancer where abnormal expression is associated with worse prognosis in a subset of localized cancers, the functional significance in the ovary does not seem clear from these results. It is noteworthy that most clear cell and serous carcinomas showed a membranous staining which may relate to the more intrinsic aggressive nature of these tumor cell types. Finally, there might be a link between membranous hepsin expression and the development of vascular thrombotic events in clear cell carcinoma or other types of ovarian cancer.

### 871 Endocervical Curetting vs. Endocervical Brushing as Case Finding Methods

*JA Maksem, DG Bostwick.* Gynecor, Division of Bostwick Laboratories, Orlando, FL.

**Background:** The comparative performance characteristics of endocervical curetage (ECC) and intensive endocervical brushing (ECB) (comprising 2 or more brushings of the endocervix with liquid-based cytology and cell block examination) is uncertain in

the course of colposcopic examination for abnormal gynecological cytology. We examine the accuracy of ECC and ECB as case-finding procedures in relation to (1) the original cytological diagnosis and (2) the highest (most abnormal) histological diagnosis of colposcopy examination. Our purpose was to determine whether ECB can replace ECC. **Design:** We reviewed the outcomes of 1,824 colposcopic biopsy collections from women who had an index cytology diagnosis of LSIL or higher. A total of 1507 cases of LSIL or higher included an ECC along with two or more colposcopic biopsies, and 317 also included an ECB. ECB specimens were collected into a liquid fixative and processed as both cytology and cell block specimens, whereas, ECC specimens were processed according to standard histological techniques.

**Results:** We found that intensive ECB yields the highest diagnosis of the colposcopy study about 5-to-8 times as often as ECC. Moreover, when calculating the proportion of positive outcomes, we found that cases examined with biopsy and ECC discovered fewer women with CIN 2 or greater among both LSIL and HSIL index cytologies as compared to cases examined with biopsy and ECB (9.2% vs. 16.8% for LSIL and 63.7% vs. 72.2% for HSIL cases); and, more negative outcomes were seen among women evaluated with biopsy plus ECC than with biopsy plus ECB (11.3% vs. 8.1% for LSIL and 4.7% vs. 1.4% for HSIL cases).

**Conclusions:** Colposcopic study is optimized when it is performed in conjunction with ECB rather than ECC. ECB is superior to ECC as an adjunct to colposcopic examination and cervical biopsy.

### 872 High-Grade Sarcoma in Endometrial Stromal Sarcoma: Dedifferentiated Endometrial Stromal Sarcoma

*A Malpica, MT Deavers, EG Silva.* The University of Texas MD Anderson Cancer Center, Houston, TX.

**Background:** Endometrial stromal sarcoma (ESS) is a low-grade neoplasm characterized by the presence of small-to-medium-sized uniform cells and distinct small, arteriole-like vessels. The synchronous or metachronous association of this type of tumor with a high-grade sarcoma (dedifferentiation) is rare with only a few cases reported thus far. In this study, we present the clinicopathologic features of 15 such cases.

**Design:** Fifteen cases of ESS with synchronous or metachronous high-grade sarcoma (HGS) were retrieved from the files of the Department of Pathology at MD Anderson covering a period of 10 years (yrs) (1996-2005). H&E stained slides were reviewed in all cases (ranging from 1 to 22 slides per case, median 6). Immunoperoxidase studies were performed as follows: CD10 (6 cases), and progesterone receptors (PR) (10 cases). Clinical information was obtained from the patients' (pts') charts. Follow-up (F/U) was obtained for 13 pts.

**Results:** The pts' age ranged from 35 to 63 yrs (mean 50 yrs). Two pts had received radiotherapy either for cervical cancer or for uterine ESS. The combination of ESS and HGS was detected in the primary uterine tumor in 8 cases and in the recurrent tumors in 5 cases (4 in the pelvis and 1 in the lung). In 2 cases, the tumor arose in extrauterine ESS (vagina and abdomino/pelvic soft tissue). Using the FIGO system, the uterine cases were staged as follows: stage I (2 cases), stage II (2 cases), stage III (3 cases), and stage IV (1 case). In all cases but two, ESS and HGS were present together, the latter component representing anywhere from 10% to 95% of the tumor examined. In 2 cases, the HGS comprised the entire tumor (one case, represented a recurrence in the lung 19 yrs after hysterectomy, radiotherapy, and chemotherapy for uterine ESS; another case, represented a recurrence in the pelvis 8 yrs after hysterectomy, hormone therapy, and chemotherapy for uterine ESS). The expression of CD10 and/or PR by the neoplastic cells of ESS and HGS could be compared in 6 cases and they were both equally expressed in 1 case and decreased or absent in the HGS in 5 cases. F/U is as follows: 7 pts DOD (interval ranging from 13 to 48 mos), 4 pts are AWD (at 14, 21, 23, and 72 mos), and 2 pts are NED (both at 36 mos).

**Conclusions:** The synchronous or metachronous association of ESS with HGS (dedifferentiation) is a rare event and is correlated with an aggressive behavior. Its recognition is important for prognosis and may have therapeutic implications.

### 873 Rsf-1 Is Significantly Expressed in High Grade Ovarian Serous Carcinoma

*TL Mao, RJ Kurman, TL Wang, IM Shih.* The Johns Hopkins University School of Medicine, Baltimore, MD.

**Background:** Ovarian surface epithelial tumors encompass a large group of tumors ranging from benign, borderline and malignant and also include tumors of different histology. Our previous study has shown that Rsf-1, a chromatin remodeling gene, was a novel amplified oncogene in ovarian cancer. To better elucidate the role of Rsf-1, we studied the expression of Rsf-1 protein in various types of ovarian tumors.

**Design:** 295 cases of ovarian tissues including ovarian surface epithelium (OSE) (n=19), serous cystadenoma (n=23), serous borderline tumor (SBT) (n=13), low grade serous carcinoma (n=32), high grade serous carcinoma (n=100), endometrioid carcinoma (n=44) and clear cell carcinoma (n=64) were included in the study. Formalin-fixed, paraffin-embedded tissues were arranged onto tissue microarrays. Immunohistochemistry using a monoclonal antibody against Rsf-1 was performed. The staining intensity was scored 0 to 4+. Based on our previous study, intense immunoreactivity (3+ to 4+) correlated with high fold gain in DNA copy number as demonstrated by FISH. So, we stratified cases into two groups as low level of expression (0 to 2+ staining) and high level of expression (3+ to 4+ staining).

**Results:** High level of Rsf-1 expression was seen predominantly in high grade serous carcinomas (25/100 cases) and only rarely in low grade serous carcinomas (2/32 cases) and endometrioid carcinomas (2/44 cases) but not in other types of tumor (Table 1). A trend of increasing immunoreactivity was seen from benign serous tumors to low grade serous carcinomas and high grade serous carcinomas.

**Conclusions:** Our study demonstrated that overexpression of Rsf-1 was significantly associated with high grade serous carcinoma. A differential expression of Rsf-1 in high

grade versus low grade carcinomas and benign tumors suggests a pathogenetic role of Rsf-1 in progression of ovarian serous carcinomas.

	Immunohistochemical stain of Rsf-1 in ovarian tumors					p value*
	total cases	0	1+	2+	3+	
serous, HG	100	5	15	55	20	5
serous, LG	32	5	11	14	2	0.015
SBT	13	1	9	3	0	0.03
serous cystadenoma	23	10	9	4	0	0.0029
OSE	19	7	11	1	0	0.007
endometrioid	44	23	9	10	2	0.002
clear	64	13	29	22	0	<0.00001

\*p value calculated between high grade serous carcinoma and other types of ovarian tumors

#### 874 miRNA Expression Signatures in Cervical Cancer

CM Martin, K Astbury, R Henfrey, O Sheils, M Gallagher, C Heffron, C Logan, JJ O'Leary. Trinity College, Dublin, Dublin, Ireland; Coombe Women's Hospital, Dublin 8, Ireland; Applied Biosystems, Warrington, Cheshire, United Kingdom; OLHSC, Dublin, Ireland.

**Background:** MicroRNAs (miRNA) are a recently discovered family of short non-protein-coding RNA's with diverse functions, including regulation of cellular differentiation, proliferation and apoptosis. To date, 222 human miRNA's have been identified, however, evidence suggests the total number of human microRNAs may be much larger (closer to 800). Studies have indicated that differential expression of miRNA's in cancer and normal tissues with general down regulation of miRNA's in tumours. The interaction between miRNA's and specific oncogenes and cell cycle regulatory genes is not well understood. In this study we examine expression of 180 of these miRNA's in cervical cancer using a novel technique, that uses stem loop primers for reverse transcription followed by TaqMan PCR.

**Design:** miRNA was purified from C33A (HPV negative) and CaSki (HPV 16 and 18 positive) cervical cancer cell lines using Ambion's mirVana™ miRNA isolation system. RNA extracted from histologically normal cervical tissue was used as a calibrator. miRNA expression profiles were examined using the Applied Biosystems TaqMan® MicroRNA Assays Human Panel - Early Access Kit. TaqMan PCR data was analysed by relative quantitation using the delta delta CT method. miR 16 and let 7 miRNA's were used as endogenous controls.

**Results:** Compared to normal cervical tissue, cervical cancer cell lines C33A and CaSki showed distinct miRNA expression signatures. A large proportion of miRNA's demonstrated reduced expression (> 2 fold) in the cervical cancer cell lines while a number of miRNA's were differentially expressed in the HPV positive CaSki cell line compared to the HPV negative C33A cell line. Increased expression (> 2 fold) of a number of miRNA's including, miR-7, miR-15b, and miR-96, and reduced expression of miR-142, miR-26a, miR-24 and miR-125a was observed in C33A and CaSki cell lines. These targets are predicted to interact with a number of cell cycle regulatory molecules including CDKN2a, CDK 6 and 8, Cyclin D2, Cdc14, E2F and Rb.

**Conclusions:** These findings highlight the potential importance of miRNA molecules in cervical cancer. We speculate that abnormalities in miRNA expression in cervical cancer cell lines contribute to dysregulation of the cell cycle regulatory pathway in cervical cancer. Further work will potentially establish miRNA's as biomarkers of pre-invasive cervical disease and potential therapeutic targets.

#### 875 Paranglioma of the Ovary: Three Cases of an Extremely Rare Primary Ovarian Neoplasm, Including Two Exhibiting Inhibin Positivity

WG McCluggage, RH Young. Royal Group of Hospitals Trust, Belfast, United Kingdom; Massachusetts General Hospital, Boston, MA.

**Background:** Paranglioma is one of the rarest ovarian neoplasms with only two previous reports.

**Design:** We describe three examples that occurred in patients aged 22, 58 and 68 years. Two of them had hypertension and in one the tumour was discovered during pregnancy.

**Results:** Two tumours involved the left ovary and one the right ovary; they ranged from 8 to 22 cm, were predominantly solid and were tan, brown or yellow. One tumour was confined to the ovary, in one case there were also tumour deposits on the posterior surface of the uterus and the contralateral ovary and in the other case there was peri-aortic lymphadenopathy and peritoneal deposits. In all cases, radiological investigations did not reveal an alternative primary site. On microscopic examination all three tumours showed a predominantly nested, "zellballen", pattern with groups of cells surrounded by a vascular stroma. Tumour cells largely had abundant granular eosinophilic cytoplasm with in two cases focal clear cell areas. In one case, bizarre tumour giant cells were present. Immunohistochemically, all neoplasms were cytokeratin negative and diffusely positive with neuroendocrine markers. In one case, there was a S-100 positive population of sustentacular cells. Two cases were positive with inhibin, one focal and one diffuse. Electron microscopy performed in two cases revealed dense core neuroendocrine granules. One patient has been followed up for 15 years and is alive and well.

**Conclusions:** Although metastatic spread from an undetected primary outside the ovary cannot be totally excluded for the two cases with extraovarian disease, we believe the neoplasms most likely represent primary ovarian parangliomas. Since various neoplasms in the sex cord-stromal and steroid categories are likely to enter into the differential diagnosis, inhibin positivity represents a significant potential diagnostic pitfall. The differential is broad and may include many other ovarian tumors, particularly those with an oxyphilic cell type. Possible theories of histogenesis of primary ovarian paranglioma include an origin from extra-adrenal paranglia in the region of the ovary or unidirectional differentiation within a teratoma.

#### 876 A Proposed Protocol for Sectioning and Extensively Examining the Fimbriated End of the Fallopian Tube (SEE-FIM): Implications for Detecting Tubal Epithelial Abnormalities in Women with and without BRCA Mutations

F Medeiros, Y Lee, MG Muto, JA Elvin, EM Prusak, CP Crum. Brigham and Women's Hospital, Boston, MA.

**Background:** Approximately 10% of women with BRCA mutations (BRCA+) are found to have an occult serous carcinoma of the fallopian tube in prophylactic salpingo-oophorectomy specimens. This finding has increased attention on the fallopian tube as a source of pelvic serous carcinoma, both sporadic and familial. This study describes a protocol for maximizing exposure of the fallopian tube by sectioning and extensively examining the fimbriated end (SEE-FIM).

**Design:** The SEE-FIM protocol involved the following: 1) initial fixation of the tubes for 2-4 hours; 2) amputation of the fimbriated end and the proximal one cm of tube; 3) longitudinal sectioning of the fimbriated end and 4) sectioning the remaining tube at 2mm intervals. To determine the relative increase in exposure of the fimbriated mucosa for pathologic examination, the number of low power (40X) fields of fimbrial mucosa were recorded and compared to controls.

**Results:** To date we have examined over 200 consecutive fallopian tubes from women with non-neoplastic ovarian conditions, BRCA mutations and sporadic ovarian epithelial neoplasms. When compared to conventional sectioning, the SEE-FIM protocol provided exposed an average of 16.9 40X fields (range 9-30) versus 11 (range 8-16) and highlighted the tubal-mesothelial junction. In the first 15 cases from BRCA+ patients analyzed by the SEE-FIM protocol, one case (7%) of early tubal cancer (tubal intraepithelial carcinoma) was identified in single fimbrial plica. A range of non-neoplastic but architecturally complex epithelial alterations were also highlighted by examination of the fimbria.

**Conclusions:** The SEE-FIM protocol maximizes exposure of the fimbria mucosa and permits a thorough assessment of the fallopian tube in BRCA+ women. Because the fallopian tube -specifically the fimbriated end - has been implicated in the pathogenesis of pelvic serous carcinoma, this or a similar protocol should be followed for any study that addresses potential sites of origin for these tumors. The specifics of the SEE-FIM protocol, including pitfalls in the interpretation of tubal intraepithelial carcinoma and non-neoplastic epithelium, are illustrated.

#### 877 Aggressive Angiomyxoma: Frequency of HMG2 Rearrangements and Characterization of the Chromosomal Translocation t(1;12)(p32;q15)

F Medeiros, M Erickson-Johnson, GL Keeney, AC Clayton, X Wang, AM Oliveira. Mayo Clinic, Rochester, MN.

**Background:** Aggressive angiomyxoma is a locally recurrent mesenchymal neoplasm that affects the vulvovaginal region of middle aged women. Rearrangements of the HMG2 locus on chromosome 12q13-15 have been described in a few cases. Herein we report the frequency of HMG2 rearrangements in these tumors and the cloning of the chromosomal translocation t(1;12)(p32;q15).

**Design:** Twelve cases of aggressive angiomyxoma with typical histopathologic features diagnosed at the Mayo Clinic were studied for rearrangements of HMG2 by fluorescence in situ hybridization (FISH) using a custom designed probe for paraffin-embedded tissues. An average of 200-400 cells was scored in each tumor. Fresh tissue material was available for standard cytogenetic analysis in one case. Cloning of the translocation breakpoint was performed by 3' Rapid Amplification of cDNA Ends - Reverse Transcriptase Polymerase Chain Reaction (3'RACE RT-PCR).

**Results:** FISH analysis of 12 aggressive angiomyxomas revealed rearrangements of the HMG2 locus in 4 cases (33%). HMG2 rearrangements were found in 60-90% of the stromal spindle cells but no rearrangement was observed in the endothelial cells. FISH signals consistent with a balanced rearrangement of HMG2 were found in 3 (of 4) cases. Standard cytogenetic analysis was performed in one of these 3 cases and showed the balanced chromosomal translocation t(1;12)(p32;q15). 3'RACE RT-PCR revealed that sequences derived from clone RP1-158P9 located on chromosome 1p32 were fused to the 3' untranslated sequences of HMG2 exon 5. The fusion breakpoint occurred 82 bp downstream to the HMG2 stop codon. In the fourth case, an unbalanced rearrangement was observed with loss of genomic sequences downstream to HMG2 intron 3.

**Conclusions:** HMG2 rearrangements occur in approximately 33% of aggressive angiomyxomas and are restricted to the stromal spindle cells. The chromosomal translocation t(1;12)(p32;q15), which has been previously described in some lipomas, also occurs in aggressive angiomyxomas. In the present case, the fusion breakpoint occurred downstream to the HMG2 stop codon and likely leads to an aberrant expression of this gene.

#### 878 Cytomorphologic Features of Endocervical Cells in HPV Positive Women

C Meroueh, KJ Jabbar, MZ Sharaf El-Dean, MM El-Fakharany, PF Mazzara. St John Hospital & Medical Center, Detroit, MI.

**Background:** The cytologic features of human papillomavirus (HPV) infection of the squamous epithelium of the uterine cervix are well established, and help to identify patients at risk for cervical squamous carcinoma. HPV has also been implicated in cancers of the endocervix, but its characteristic cytologic features have not been described in the glandular epithelium. Our study is aimed at identifying cytologic features in endocervical cells of patients with documented HPV infection.

**Design:** We searched our database and identified 203 patients between January, 2002 and May, 2004 that had both HPV testing by hybrid capture and cervical biopsy (161 HPV positive and 42 HPV negative). The biopsies were retrospectively reviewed for the presence or absence of nuclear enlargement (NE), irregular nuclear contours, increased nuclear to cytoplasmic (N/C) ratio, ground glass nuclei, nuclear hyperchromasia, perinuclear clearing, bi/multinucleation and mitotic figures. NE was arbitrarily defined as 2.2 times the size of normal endocervical cells. The reviewers were blinded to the results of HPV testing.

**Results:** Of all the parameters studied, we found statistically significant differences in frequency of NE ( $p=0.009$ ),  $\uparrow$  N/C ratio ( $p=0.035$ ), irregular nuclear contours ( $p<0.0005$ ) and ground glass nuclei ( $p=0.009$ ) between HPV+ and HPV- patients. There was no statistically significant difference in frequency of bi/multinucleation, nuclear hyperchromasia, perinuclear clearing or mitotic figures between the two groups.

	HPV + (n=161)	HPV - (n=42)	p value
Nuclear enlargement 2.2-3 X normal	57.1% (92)	30.9% (13)	0.009
Increased N/C ratio	47.8% (77)	28.6% (12)	0.035
Irregular nuclear contours	57.1% (92)	26.2% (11)	<0.0005
Ground glass nuclei	29.8% (48)	9.5% (4)	0.009
Binucleation	15.7% (25)	16.7% (7)	0.817
Multinucleation	5.6% (9)	4.8% (2)	1
Nuclear Hyperchromasia	14.3% (23)	7.1% (3)	0.302
Perinuclear clearing	3.7% (6)	0% (0)	0.348
Mitoses	4.3% (7)	4.8% (2)	1

Percentage is calculated by dividing number of positive cases by n. Only the number of positive cases for studied features are listed.

**Conclusions:** We found certain cytomorphologic features were more common in cervical biopsies from patients with HPV+ testing than those who tested negative for HPV. These included NE,  $\uparrow$  N/C ratio, irregular nuclear contours and ground glass nuclei. Whether these features have the same significance as koilocytic atypia in squamous cells remains to be studied.

### 879 Expression of 14-3-3 $\sigma$ Protein in Endocervical Glandular Lesions

Y Mikami, T Kiyokawa, H Katsushima, T Suzuki, T Manabe. Kyoto University Hospital, Kyoto, Japan; Jikei University Medical School, Minato-ward, Tokyo, Japan; Tohoku University Graduate School of Medical Science, Sendai, Miyagi, Japan.

**Background:** 14-3-3 $\sigma$ , a major G2/M checkpoint control gene, is inactivated in a variety of cancers mainly by epigenetic hypermethylation. Expression of the protein encoded by this gene in benign and neoplastic endocervical glandular lesions and its diagnostic significance remain to be elucidated.

**Design:** A variety of endocervical glandular lesions, including invasive adenocarcinoma (n=55), adenocarcinoma in situ (AIS)(n=30), endocervical hyperplasia (n=26), tunnel cluster (n=2), tubal metaplasia (n=11), and microglandular hyperplasia (n=4), were examined immunohistochemically to determine the expression of the 14-3-3 $\sigma$  protein using affinity-purified polyclonal rabbit antibody against human 14-3-3 $\sigma$  protein (1:100 dilution, Immuno-Biological Laboratories Co. Ltd., Fujioka, Japan).

**Results:** The moderate to strong nuclear and cytoplasmic immunoreactivity for 14-3-3 $\sigma$  protein with more than 50% distribution was observed in 85%(47/55) of invasive adenocarcinoma and 93% (28/30) of AIS, respectively. Both poorly differentiated and minimal deviation adenocarcinomas frequently showed strong staining, and no correlation between immunoreactivity and degree of differentiation was confirmed. Positive staining was not identified in the normal glands in control cases (0/32) and tunnel clusters (0/2). Only focal (less than 10%) and weak staining was observed in endocervical glandular hyperplasia, NOS and lobular endocervical glandular hyperplasia, with rates of 19%(3/16) and 70%(7/10), respectively. In addition, 82%(9/11) of tubal metaplasias showed diffuse (more than 50%) but weak immunoreactivity. All four cases of microglandular hyperplasia harbored basally located reserve cells positive for 14-3-3 $\sigma$  protein without any staining in luminal mucus-secreting columnar cells. The identical basal pattern of staining was identified in occasional glands adjacent to squamous metaplasia, SIL, or AIS.

**Conclusions:** The 14-3-3 $\sigma$  protein immunohistochemistry can be a novel adjunctive tool for recognizing invasive and in-situ adenocarcinoma of the uterine cervix, but the interpretation of the result should be combined with morphology since a variety of benign endocervical glandular lesions and reserve cell population can be also positive.

### 880 Evaluation of the Utility of Immunohistochemistry (IHC) in Predicting Microsatellite Instable (MSI) Phenotype in Endometrial Carcinoma

I Modica, J Shia, D Black, M Asher, J Boyd, I Linkov, RA Soslow. Memorial Sloan Kettering Cancer Center, New York, NY.

**Background:** The utility of immunohistochemical detection of DNA mismatch repair (MMR) proteins in identifying hereditary or sporadic colorectal tumors has been investigated extensively, and the results suggest that immunohistochemical detection of the two commonly affected MMR proteins, MLH1 and MSH2, has an overall sensitivity of 92% in predicting MSI phenotype with a specificity of >99%. On the other hand, the role of IHC in predicting MSI in endometrial carcinoma, another disease in which the frequency of MSI phenotype is as high as 17-32%, is poorly defined.

**Design:** IHC for MLH1 (clone G168-728, PharMingen) and MSH2 (clone FE11, Oncogene Research Products) was performed on 90 endometrial carcinomas whose MSI status had been detected by a standard PCR method using the 5 NCI recommended markers. Case selection: 47 MSI-H and 43 non-MSI-H were matched for FIGO grade, stage and histologic type (all endometrioid).

**Results:** Of the 90 tumors, 47 were MSI-H, 43 non-MSI-H. IHC results and their correlation with MSI status are listed in tables 1 and 2.

Table 1. Results of immunohistochemistry

	Total number	Negative staining (%)	Normal staining (%)	Focal weak staining (%)	Stain not interpretable (%)
MLH1	90	24 (27%)	52 (58%)	9 (10%)	5 (5%)
MSH2	90	7 (8%)	81 (90%)	2 (2%)	0

Table 2. Correlation of IHC with MSI status

	MSI-H	Non-MSI-H	Sensitivity of IHC in predicting MSI	Specificity of IHC in predicting MSI
IHC negative MLH1 or MSH2	31	0	69%	100%
Positive staining for MLH1 and MSH2*	14	40		

\* including cases with focal weak staining

Five MLH1 IHC stains were not interpretable due to lack of internal positive control. 9 MLH1 and 2 MSH2 stains showed only focal weak staining with weak internal control. Concurrent loss of MLH1 and MSH2 protein was not observed in any of IHC abnormal cases.

**Conclusions:** This study systematically explored the utility of IHC in predicting MSI phenotype in endometrial carcinoma. The study shows that limitations to IHC clearly exist, such as poor staining (particularly with MLH1 antibody) and difficulty in interpreting focal staining and distinguishing staining in carcinoma from background hyperplasia. Nonetheless, IHC detects a significant proportion of endometrial carcinomas with a MSI phenotype. Given its simplicity and easy availability, it should be used as a complementary screening tool to PCR MSI testing for identifying hereditary and/or sporadic MSI endometrial cancers.

### 881 Gonadotropin- Releasing Hormone Agonist Treatment on Uterine Leiomyomas Increases the Number of Mast Cells

M Nakayama, T Mitsuhashi, S Ban, Y Shimizu, F Ogawa, O Ishihara, M Shimizu. Saitama Medical School, Moroyama-machi, Saitama, Japan.

**Background:** Gonadotropin-releasing hormone agonist (GnRH-a) therapy is frequently applied to reduce leiomyomas and uterine volume, especially before a surgical procedure. However, the pathological changes of uterine leiomyomas treated with GnRH-a have not been fully described.

**Design:** Uterine leiomyomas treated with and without GnRH-a (formalin-fixed, paraffin-embedded tissues from 127 patients) were morphologically reviewed. They were classified into two groups: A) 40 cases untreated with GnRH-a and B) 87 cases treated with GnRH-a. We specifically paid attention to 15 pathological parameters (myxoid change, necrosis, calcification, hemorrhage, edema, the number of mast cells, hyalinization, cystic degeneration, vacuolar change, lipomatous component, vascular change, cellularity, nuclear atypia, mitosis and inflammation). The data were analyzed using unpaired t-test and Mann-Whitney U-test when comparing differences in mean values between the two groups.

**Results:** Among the 15 parameters, only the number of mast cells was significantly observed in the B) group by using unpaired-test ( $p<0.05$ ) as well as Mann-Whitney U-test ( $p<0.01$ ). That is, the number of mast cells in uterine leiomyomas frequently increased after the GnRH-a therapy. Other parameters did not show any significance between the two groups.

**Conclusions:** Our findings suggested that GnRH-a therapy on uterine leiomyomas is associated with an increase of the number of mast cells. So far, other recent reports have indicated that GnRH-a is really associated with a decrease in insulin-like growth factor (IGF-I) receptor expression in leiomyoma cells (Andrea Di Lieto et al. Am J Obstet Gynecol. 2003), and that IGF-I plays an important role in the growth of uterine leiomyomas (Wolanska M et al. Eur Cytokine Netw. 2004). To our knowledge, however, no reports have been described regarding the relationships among mast cell, IGF-I and IGF-I receptor in GnRH-a-treated uterine leiomyomas. Immunohistochemical study using IGF-I and IGF-I receptor is now under investigation in the current study.

### 882 Potential Predictors of Chemotherapy Response in Ovarian Cancer – How Do We Define Chemosensitivity?

SA O'Toole, A Laios, BL Sheppard, NC Gleeson, TD Arcy, EPJ McGuinness, J Bonnar, O Sheils, JJ O'Leary. Trinity College Dublin, Dublin, Ireland.

**Background:** The aim of this study was to assess, CD31 (a measure of microvessel density), VEGF (vascular endothelial growth factor) and MDR1 (multidrug resistance) to determine if they could predict the response to chemotherapy in ovarian cancers or act as prognostic factors. Microvessel density (MVD) counting techniques have been widely used to assess the degree of angiogenesis in tumours. VEGF has been shown to play a major role in the proliferation and migration of endothelial cells, providing nourishment to the growing tumours. MDR1, thought to be associated with acquired resistance, codes for P-glycoproteins (P-gps), which are a homologous family of integral membrane proteins and function as an energy-dependent drug efflux pump that reduces intracellular drug accumulation.

**Design:** 79 ovarian specimens were analysed by immunohistochemistry. Pearson correlation, 1-way ANOVA and Chi Square were used for univariate analysis. Kaplan Meier survival curves were used, log rank and Cox proportional hazards regression model were used for analysis. Response to chemotherapy was assessed after 6 months and again after 1 year. Sensitive was defined as remaining disease free and resistant as having recurred.

**Results:** Quantifying VEGF proved to be a valuable independent prognostic indicator in PFS ( $p<0.05$ ) and OS ( $p<0.0001$ ). VEGF fails to provide an adequate measure for resolving the response to chemotherapy drugs in ovarian cancer at the 1 year interval but was useful in predicting resistance at the 6 month interval. Increased staining with CD31 was associated with decreased PFS ( $p<0.01$ ) and OS ( $p<0.01$ ) in univariate but not multivariate analysis. CD31 offered no indication as to which patients might best respond to chemotherapy. MDR1 expression was detected in previously untreated ovarian tumours but failed to act as a prognostic marker or as a predictor of response to chemotherapy.

**Conclusions:** VEGF can predict the response of tumours to chemotherapy at the 6 month but not the 12 month interval; what should our criteria be for determining sensitivity to chemotherapy? MDR1 is not exclusively related to acquired resistance. CD31, VEGF and MDR1 do play a role in some ovarian malignancies but other factors are likely to be involved. VEGF and MDR1 may be regulated by hypoxia and this will be further investigated. Molecular profiling of tumours in the future may identify which factors will be important for the response of the various tumours to chemotherapy.



**883 Interphase FISH Detection of JAZF1-JJAZ1 Gene Fusion in Endometrial Stromal Tumors with Smooth Muscle Differentiation**

*E Oliva, L de Leval, C De Ceuninck, V Augenbron, RA Soslow, C Herens.* Massachusetts General Hospital, Boston, MA; CHU Sart-Tilman, Liège, Belgium; Memorial Sloan Kettering Cancer Center, New-York, NY.

**Background:** The most common cytogenetic alteration found in low-grade endometrial stromal tumors is the t(7;17)(p15;q12) translocation resulting in the fusion of JAZF1 and JJAZ1 genes. By RT-PCR, the translocation has been detected overall in one third of endometrial stromal tumors, but only rarely in its variants. The goal of this study was to develop a FISH assay for detection of this translocation on archival samples, and assess the nature of the smooth muscle component of these tumors.

**Design:** Representative paraffin blocks of 9 endometrial stromal nodules and 1 low-grade endometrial stromal sarcoma with smooth muscle differentiation were collected. In one case, the block selected also contained sex cord-like differentiation. A probe set was designed to detect the t(7;17)(p15;q12) on tissue sections by means of fluorescence in situ hybridization (FISH). Seven bacterial artificial chromosomes (BACs) covering a region of about 1.2Mb including the JAZF1 gene on 7p15.1-15.2 and a contig of 5 BACs of a total size of about 954 Kb flanking the JJAZ1 gene on 17q12 were selected from the library of P. de Jong and labelled with spectrum green or spectrum orange fluorescent dyes respectively. The probes were tested on metaphase preparations of normal peripheral blood cells and generated signals localized to the expected chromosomal regions. FISH was performed on 5 µm-thick paraffin-embedded tissue sections according to standard procedures.

**Results:** Six out of ten collected cases were assessable. Fusion signals were detected in 3 out of 6 cases (50%). In all cases, the fusion signal was detected in both the conventional component as well as the smooth muscle component of the tumors. The tumor sample with conventional endometrial stromal neoplasia, smooth muscle and sex cord-like differentiation harbored the fusion signal in all three components.

**Conclusions:** This study shows a high frequency of the JAZF1-JJAZ1 fusion gene in both conventional endometrial stromal and smooth muscle components. This finding supports the contention that both components of these tumors share the same cytogenetic abnormality and that they have the same origin, either from a common precursor cell with pluripotential differentiation or from endometrial stromal cells undergoing smooth muscle metaplasia.

**884 Expression of Melanocytic ("PEComa") Markers in Smooth Muscle Tumors of the Uterus: An Immunohistochemical Analysis of 86 Cases**

*E Oliva, WL Wang, P Branton, S Logani, GF Zannoni, I Linkov, M Asher, RA Soslow.* Massachusetts General Hospital, Boston, MA; Inova Fairfax Hospital, Falls Church, VA; Emory University, Atlanta, GA; Università Cattolica, Rome, Italy; Memorial Sloan Kettering Cancer Center, New York, NY.

**Background:** Whether uterine PEComas represent a distinct entity or are part of the spectrum of smooth muscle tumors (SMTs) has been debated. Their morphologic and immunophenotypic similarity to each other and to normal myometrium (including variable expression of HMB-45 and smooth muscle markers) suggest that they are related. However, the frequent expression of keratin in SMTs but not in PEComas, the association of PEComas with tuberous sclerosis and lymphangiomyomatosis and the restriction of microphthalmia transcription factor (MiTF) and melan A expression to PEComa would favor that they are different entities. The goal of this study was to evaluate the expression of melanocytic markers in a variety of uterine SMTs.

**Design:** Representative paraffin blocks were selected from 9 leiomyomas (LMs), 9 epithelioid smooth muscle tumors (ESMTs) and 68 leiomyosarcomas (LMSs) after histologic confirmation of the diagnosis. The immunohistochemical panel included HMB-45, Melan A, MiTF and S-100. Percentage and intensity (+1, +2, +3) of staining were recorded.

**Results:** LMs: 1/9 expressed HMB-45 (+1 and 10%), 2/9 were Melan A positive (+1, and ≤ 20%), and 5/5 expressed MiTF (+1 to 2; from 15 to 90%). ESMTs: 5/9 expressed both HMB-45 (mostly +1; from 5 to 80%) and Melan A (mostly +1; from 5 to 40%), and 2/9 expressed MiTF (+1 and 5 to 25%). LMSs: 21/67 were HMB-45 positive (13 tumors 1 to 2+ and mostly < 40%; 8 tumors 2 to 3+ from 5 to 80%), 22/68 expressed Melan A (11 tumors 1+ and ≤ 20%; 2 tumors 1 to 2+ from 5 to 60%; 9 tumors 2 to 3+, from 5 to 80%) and 31/54 expressed MiTF (22 had 2 to 3+ frequently in >30%). Tumors frequently coexpressed HMB-45 and Melan A. All SMTs were scored as S-100 negative.

**Conclusions:** All subcategories of SMTs expressed HMB-45 and Melan A, with the strongest staining seen in LMSs; this suggests a relationship between PEComas and SMTs. However, many cases show staining of limited intensity and/or distribution, which might be non-specific and therefore worthy of additional study. In contrast, MiTF expression was found in most SMTs, although least frequently in ESMTs, tumors that most closely resemble PEComas.

**885 PTEN Mutation in Endometrial Stromal Sarcomas**

*B Ologun, MR Quddus, CJ Sung, MM Steinhoff, H Bai, JM Kasznica, WD Lawrence.* Women & Infants Hospital, Brown Medical School, Providence, RI.

**Background:** PTEN, a tumor suppressor gene, has been reported to be altered/inactivated in a wide variety of human carcinomas including endometrial carcinomas and endometrial pre-cancers where no morphologic changes are appreciated. About 66% of endometrial carcinomas have been reported to be PTEN null. PTEN alteration has also been linked to the development of hamartomas in Cowden's disease and to neoplastic progression in glioblastoma and prostatic carcinomas. PTEN expression has been observed in benign endometrial stromal cells but, to our knowledge, alteration of PTEN in endometrial stromal tumors has not been studied. The current study investigates the alteration/mutation of PTEN in high and low grade endometrial stromal sarcomas.

**Design:** PTEN, a tumor suppressor gene, has been reported to be altered/inactivated in a wide variety of human carcinomas including endometrial carcinomas and endometrial pre-cancers where no morphologic changes are appreciated. About 66% of endometrial

carcinomas have been reported to be PTEN null. PTEN alteration has also been linked to the development of hamartomas in Cowden's disease and to neoplastic progression in glioblastoma and prostatic carcinomas. PTEN expression has been observed in benign endometrial stromal cells but, to our knowledge, alteration of PTEN in endometrial stromal tumors has not been studied. The current study investigates the alteration/mutation of PTEN in high and low grade endometrial stromal sarcomas.

**Results:**

PTEN	High grade endometrial sarcomas (n=11)		Low grade stromal sarcomas (n=5)	
	Null	Positive	Null	Positive
	9	2	3	2

**Conclusions:** Although 75% of endometrial stromal sarcomas of all grades show the PTEN mutation, the PTEN null phenotype is more common in high grade endometrial sarcoma as compared to low grade endometrial stromal sarcoma (81% to 60%). The percentage of PTEN null tumors appears to be higher in endometrial stromal sarcomas (75%) than that reported in endometrial carcinomas and pre-cancers (66%). Our study suggests that PTEN mutation may play a role in the pathogenesis of most, predominantly high grade, endometrial stromal sarcomas, although a larger series is needed to validate these findings.

**886 Mammaglobin Expression in Benign and Neoplastic Endocervix and Endometrium**

*K Onuma, DJ Dabbs, R Bhargava.* Magee Womens Hospital of University of Pittsburgh Medical Center, Pittsburgh, PA.

**Background:** Mammaglobin (MGB) is a secretory protein closely related to the uteroglobin gene family, and expressed in breast carcinomas. A single study has shown MGB expression in normal and malignant tissues of female genital tract by RT-PCR (Lab Invest. 2002;82:1147-53). A systematic analysis of MGB expression in cervical and endometrial tissues by immunohistochemistry (IHC) has not been performed. MGB IHC of our pilot cases showed no significant expression in endocervical adenocarcinoma, which triggered this study.

**Design:** Thirty-three endocervical adenocarcinoma in situ (AIS) and 13 invasive endocervical carcinomas (12 adeno and 1 adenosquamous carcinoma) from 40 patients were studied by whole tissue section IHC. Adjacent normal endocervical glands were also evaluated. Fifty-five endometrial carcinomas (39 endometrioid and 16 non-endometrioid), 5 complex atypical hyperplasias (CAH), and 10 benign endo-myometrial (EM) tissues were also evaluated by using a tissue microarray. MGB expression was evaluated in a semiquantitative fashion from 0 (non-reactive) to 3+ (diffuse strong reactivity).

**Results:**

Score	Mammaglobin Expression in endometrial tissue			
	Benign EM	CAH	Endometrioid CA	Non-endometrioid CA
Score 0	2/10 (20%)	1/5 (20%)	9/39 (23%)	14/16 (88%)
Score 1	4/10 (40%)	2/5 (40%)	14/39 (36%)	1/16 (6%)
Score 2	1/10 (10%)	0/5 (0%)	14/39 (36%)	1/16 (6%)
Score 3	3/10 (30%)	2/5 (40%)	2/39 (5%)	0/16 (0%)

Score	Mammaglobin expression in endocervical tissue		
	Benign endocervix	AIS	Endocervical CA
Score 0	1/33 (3%)	14/33 (42%)	9/13 (69%)
Score 1	3/33 (9%)	17/33 (51%)	0/13 (0%)
Score 2	12/33 (36%)	2/33 (6%)	1/13 (8%)
Score 3	17/33 (52%)	0/33 (0%)	3/13 (23%)

Significant MGB staining (2+ and 3+) was seen in 16 of 39 (41%) endometrioid endometrial CA compared to only 6 of 46 (13%) AIS/Endocervical adenocarcinoma.

**Conclusions:** MGB expression decreases from intense staining of normal endocervical glands to patchy weak staining of AIS and being predominantly negative in invasive endocervical carcinomas. This reduced expression with tumor progression may be diagnostically useful. Within endometrium, MGB expression is seen in endometrioid carcinoma and may be useful in distinction from non-endometrioid carcinomas. MGB expression alone cannot distinguish endocervical from endometrial primary in a curettage specimen, but may be included in the panel with other markers.

**887 Spontaneous Regression and Progression of Low-Grade Squamous Intraepithelial Lesions of the Uterine Cervix. A Follow-Up Study**

*J Ordí, LM Puig-Tintoré, L Quinto, R Esteve, M Solé, E Campo.* IDIBAPS-Hospital Clínic, Barcelona, Spain.

**Background:** The natural history of cervical cancer involves a premalignant phase characterized by reversible abnormalities in the cervical epithelium. This sequence forms the premise on which screening methods for cervical cancer are based. Infection by high-risk human papillomavirus (HR-HPV) is etiologically associated in the development of both premalignant lesions and invasive cervical carcinoma. Low-grade squamous intraepithelial lesions (L-SIL) may progress to high grade SILs (H-SIL) and invasive carcinoma or may regress to a normal status. However, few studies on cervical neoplasia have evaluated both cytologic and virologic regression, persistence or progression over time. The aim of this study was to evaluate the spontaneous evolution of both HR-HPV and cytologic abnormalities in a group of women with L-SIL followed over a long period.

**Design:** 264 women (mean age 34.5±11.1, range 15-72) with L-SIL were followed-up for 3 to 59 months (mean 17.5±11.7). No treatment was administered during the follow-up period. Colposcopy, Pap smear and HR-HPV detection using Hybrid Capture II were conducted at the first diagnostic visit as well as in every follow-up control. At diagnosis all cases had at least two cytologies of L-SIL. Additionally, 105 cases had a confirmatory biopsy. HR-HPV was detected in 233 (88.3%) at diagnosis.

**Results:** Both cytology and HR-HPV became negative in 131 women (49.6%). Mean time to negativization was 15.3±9.7 months for cytology and 15.9±10.3 for HR-HPV. Progression to H-SIL occurred in 14 patients (5.3%). Mean time to progression was 17.0±10.3 months. Persistence of both abnormal cytology and positive HR-HPV

occurred in 84 (31.8%) women. In 35 women only one of the two tests became negative, whereas the other continued positive. Neither age nor HR-HPV load were related to progression.

**Conclusions:** Most women with L-SIL spontaneously negativize both cytology and HR-HPV and only a minimal proportion of them progress to H-SIL. Neither age nor HR-HPV load can predict progression.

#### 888 Persistence of an Identical Human Papillomavirus High Risk Type before and after Conization: It Is an Alarm for Progressive Disease. A Retrospective Study

*BC Padberg, DR Zimmermann, N Kurzen, S Welti.* University, Zurich, Switzerland.

**Background:** Human papillomavirus (HPV) persistence after surgical removal of cervical intraepithelial neoplasia (CIN) may be associated with residual lesions or risk of disease recurrence. The presence of HPV-infection by type specific PCR-HPV testing was evaluated before/at time and after conization. The objective of this study was to find out, whether differences in the outcome could be observed in patients with an identical pre- and post-treatment HPV type versus patients with different HPV types. **Design:** The retrospective study included 66 women, median 35 years of age, submitted to loop electrosurgical excision procedure (LEEP) or cone knife conization. Only women with at least one follow up-visit and confirmed CIN 2-3 or persistent CIN 1 were considered. The status of resection margins was recorded. PCR-detection of papillomaviral DNA was done before/at time and shortly after conization using two different primer sets (MY09/11 and L1C1/2). Typing was performed by directly sequencing the PCR products.

**Results:** Histological evaluation of the conizate showed 22 women with CIN 1, 15 with CIN2 and 29 with CIN3. Conization margins were compromised in 29% of the cases. Of the 66 patients 95% were HPV-positive before/at time of conization and 48% remained positive after the excision. Of the patients with positive post-treatment HPV 61% showed CIN 1-3 lesions within median 4 months after conization compared to 26% when the post-treatment test had been negative. 26% of the patients displayed identical and 20% different pre- and post-treatment HPV types; CIN lesions were seen equally in both groups at the first visit after conization (10% versus 9%). However, only patients with persistence of the identical high risk-HPV type developed progressive CIN lesions, whereas none of the patients with different pre- and postoperative HPV types or with negative tests showed progressive disease.

**Conclusions:** Post-treatment follow up of patients subjected to conization helps to identify those at high risk of progressive CIN. Pre- and post-treatment type specific HPV testing could be useful in the follow-up of these patients. In case of different pre- and postoperative high risk-HPV types and in case of negative post-treatment HPV status patients are at low risk of progression. Secondary surgical treatment could be avoided. Persistence of an identical high risk-HPV type is the single best predictor of progression.

#### 889 Low Grade Squamous Intraepithelial Lesions of the Cervix with Marked Cytologic Atypia – Histologic Follow up and Human Papillomavirus (HPV) Genotyping

*K Park, D Hileeto, LH Ellenson, EC Pirog.* Memorial Sloan-Kettering Cancer Center, New York, NY; Weill Medical College of Cornell University, New York, NY.

**Background:** The majority of low grade squamous intraepithelial lesions (LSILs) of the cervix regress spontaneously, however, a small proportion of LSILs progresses to high grade squamous intraepithelial lesion (HSIL), if the lesion is not excised. In addition, a small fraction of patients with LSIL diagnosed on Pap test or punch biopsy are diagnosed with HSIL upon excision of the lesion with a cone biopsy. The guidelines of which patients with LSIL should be treated and which may be followed safely are not well established. The goal of this study was to identify a subgroup of patients with LSIL who may require treatment. We hypothesized that patients with LSILs with marked cytologic atypia (LSILma) may be at higher risk for subsequent HSIL. In addition, we were interested if LSILma was associated with specific HPV genotypes.

**Design:** Consecutive patients with punch biopsy diagnosis of LSIL (n=30) and LSILma (n=30) were identified. Marked atypia was defined as 5 or more cells with nuclear enlargement of at least 5-times the size of an intermediate cell nucleus or multinucleation with 5 or more nuclei. Cases with concurrent HSIL were excluded. The patients' follow up for up to 18 months was recorded. HPV genotyping was performed using SPF10 PCR and Line Probe Assay.

**Results:** The diagnosis of HSIL on a follow up was significantly higher in patients with LSILma (30%, 9 of 30 patients) than in patients with LSIL (7%, 2 of 30 patients), and negative follow up was significantly more common in patients with LSIL (50%) than LSILma (16%). Cases of LSIL and LSILma showed similar spectrum and distribution of HPV genotypes.

**Conclusions:** Marked cytologic atypia in LSILs of the cervix identifies a subset of patients with a high rate of HSIL on the follow up. In such patients an excisional cone biopsy should be strongly considered.

#### 890 Loss of Methylation Responses for over Expression of IGF2 Sense and Antisense mRNA in Uterine Leiomyomas

*L Peng, JJ Wei.* New York University School of Medicine, New York, NY.

**Background:** Over expression of IGF2 is identified in most uterine leiomyomata (ULM). IGF2 transcribes through a parental allele-specific fashion and silencing of maternal allele by a genomic imprinting mechanism. Loss of imprinting (LOI) responds for over expression of IGF2 in most neoplasms, but not in ULM. We found that over expression of IGF2 mRNA is largely contributed by high usage of IGF2 promoter P1. To identify the relationship between IGF2 over-expression and gene methylation status, we conducted the following study.

**Design:** Fifteen hysterectomies for ULM were collected for the study. Total RNA and genomic DNA were prepared from fresh ULM and matched myometrium. Primers designed from IGF2 promoter P1 and antisense promoter (AS-P) were used for genomic methylation analysis. Primers for IGF2 antisense mRNA were designed for RT-PCR test. Genomic DNA were treated by bismuth, amplified with promoter primers of IGF2 P1, AS-P, and digested with MspI and HaeIII separately. Methylation status was visualized by gel electrophoresis.

**Results:** By RT-PCR, IGF2 antisense mRNAs were detected in most ULM (14 out of 15 cases), but only in 2 normal myometrium with minimal cDNA product. Among 15 cases, 8 of them were selected to further examine including one large (>10 cm) and one small (<2cm) ULM from each case. There was no difference of IGF2 antisense mRNA expression between large and small ULM. Five cases were further selected for methylation analysis in promoters of P1 and AS-P. The preliminary data showed biallelic methylations of IGF2 promoter P1 and AS-P in normal myometrium, but loss of methylation in one allele in ULM.

**Conclusions:** There is substantial difference of IGF2 antisense mRNA expression between ULM and matched myometrium. Over expression of IGF2 sense and antisense mRNA is largely contributed by loss of methylation from one allele of IGF2 promoter P1 and AS-P. The findings of demethylation of IGF2 P1 and antisense promoter demonstrate a different transcription regulation mechanism in ULM.

#### 891 The Utility of HPV Testing in Cases of Carcinomas That Involve the Endocervix and Endometrium

*JA Plaza, GJ Nuovo.* The Ohio State University Medical Center, Columbus, OH.

**Background:** Carcinoma of the cervix is strongly associated with HPV infection. However, endometrial carcinoma is not associated with infection by this virus. In cases where a tumor involves both cervix and endometrium, HPV detection can be useful in determining the site of origin. This is particularly relevant in cases of synchronous and distinct carcinomas of the cervix and endometrium with the tumors are not confluent (Stage IIA).

**Design:** We studied 6 cervical cancers that directly invaded the endometrium, 6 endometrial cancers that directly invaded the endocervix, and 8 cancers where separate tumors were evident in the cervix and endometrium. All cases were tested by in situ hybridization using the automated Ventana Benchmark system as well as by RT in situ PCR for the E6 and E7 open reading frames of HPVs 16 and 18.

**Results:** Of the endometrial cancers that had invaded the cervix, 0/6 of the tumors in the endometrium and in the endocervix were positive for HPV DNA by in situ hybridization. Of the endocervical cancers that had invaded the endometrium, 5/6 of the tumors in the endometrium and in the endocervix were positive for HPV DNA by in situ hybridization. In the other 8 cases, 6/8 of the tumors in the cervix were HPV positive by in situ hybridization compared to 0/8 of the corresponding tumors in the endometrium. Using RT in situ PCR, we found HPV RNA in 8/8 of the cervical tumors and 0/8 of the corresponding tumors in the endometrium. In 6 of these 8 cases, the histologic findings (adenosquamous carcinoma) was similar in the cervix and endometrial tumors; in 2 cases, a small cell carcinoma was present in the cervix and adenocarcinoma in the endometrium.

**Conclusions:** We conclude that synchronous tumors of the cervix and endometrium are actually two separate tumors, one (cervical ) HPV positive and the other (endometrial) HPV negative, demonstrating that the woman typically has a lower stage of disease. Further, our results demonstrate the utility of HPV testing in cases of one tumor involving both the endocervix and endometrium where the primary source, usually obvious with the gross examination of the hysterectomy specimen, may not be clear prior to surgical removal of the uterus.

#### 892 Negative Sentinel Lymph Nodes Accurately Predict Negative Status of Pelvic Lymph Nodes in Uterine Cervical Carcinoma

*I Popa, M Plante, M-C Renaud, M Roy, B Tett.* Laval University, Quebec, QC, Canada.

**Background:** Over the last few years, evaluation of sentinel lymph node (SLN) status proved to be important in the staging and treatment of melanoma and a few other cancers. However, in uterine cervix carcinoma, the significance of SLN is controversial and recent studies suggest that negative SLN may be associated with presence of metastasis in non-sentinel lymph nodes (NSLN). Our study was aimed at correlating the SLN status in cervical carcinoma with NSLN, in an uniform and well controlled population.

**Design:** This study includes 30 consecutive patients operated at l'Hôtel-Dieu de Quebec between 1998 and 2004 for an early cervical carcinoma. The inclusion criteria were a tumor limited to cervix and bilaterally negative sentinel lymph nodes. SLN were identified using blue dye and radioisotopic techniques. Frozen section examination was performed for all SLN; the remainder tissue was formalin fixed and paraffin embedded. The protocol used for SLN was also applied for NSLN. For each block, six 4 µ m thick sections were cut at 40 µ m intervals and were stained with H&E; an additional section taken between the 3<sup>rd</sup> and 4<sup>th</sup> levels was immunostained using an AE1/AE3 cytokeratin antibody (Dako, Carpinteria, CA). Slides were examined independently by 2 pathologists.

**Results:** The mean age for the study population was 37 years (range 25-76); the number of SLN ranges from 2 to 6, the number of NSLN excised varied between 8 and 49 per case (mean 22.3). The stage distribution was: 3 patients 1a2, 23 patients 1b1, 2 patients 1b2, 2 patients 2a. All SLN and NSLN were free of metastasis by step sections and IHC.

**Conclusions:** Our study demonstrates that negative SLN accurately predicts the negative status of NSLN. The result contradicts other studies, where as much as 10% of NSLN contain micrometastases. The strength of our study is the exhaustive method of SLN examination and strict inclusion criteria (bilaterally negative SLN).

**893 Validation of Potential Chemoresistance Markers in Ovarian Cancer by IHC**

*I Popa, S L'Esperance, M Bachvarova, B Tetu, D Bachvarov.* Laval University, Quebec, QC, Canada.

**Background:** Combination chemotherapy with taxol and a platinum compound is the current regimen of choice for the treatment of advanced epithelial ovarian cancer. Although a significant proportion of ovarian cancer patients respond to chemotherapy, the majority of them eventually relapse. Using DNA microarray technology we have developed a 12-gene predictive model that could be used as prognostic determinant of treatment outcome. In the present study we tried to validate some of the gene expression by immunohistochemistry (IHC).

**Design:** Our cohort included 166 women who were operated and received chemotherapy for an advanced serous papillary ovarian carcinoma (FIGO IIIc and IV). Two response groups were defined according to the disease-free interval (DFI) evaluation. The DFI was defined as the number of months without evidence of disease after the completion of initial chemotherapy. The responder group included patients with a DFI  $\geq$  6 months after the complete response, whereas the non-responder group included patients with a DFI < 6 months. IHC was performed on three tissue microarray blocks containing all cases. For each case, three 0.6 mm in diameter, 3-4 mm in depth cores from paraffin-embedded tumors were placed in a recipient block using a specific instrument (Beecher Instruments, WI). Our panel of antibodies included: mouse monoclonal anti-GST (ab856-6, Abcam, MA), mouse monoclonal anti-MMP1 (sc-21731, SCBT, CA), mouse monoclonal anti-FosB (sc-8013, SCBT, CA), rabbit polyclonal anti-pan cathepsin (sc-25537, SCBT, CA), rabbit polyclonal anti-HSP10 (sc-20958, SCBT, CA), and mouse monoclonal anti-CD36 (sc-21772, SCBT, CA). We included in our panel p53 and Ki67 (Dako, CA). Appropriate positive and negative controls were used in each case.

**Results:** The Mann-Whitney U test was used to assess the difference between the two response groups. A significant association with better response to chemotherapy was found with low MMP1 ( $p=0.045$ ), high HSP 10 ( $p=0.065$ ), high Ki67 index ( $p=0.051$ ) and high p53 expression ( $p=0.091$ ).

**Conclusions:** Our study demonstrated that gene expression analysis coupled with IHC represents a promising approach to identify prognostic markers in ovarian carcinoma. We found that the responders express more HSP10, p53 and Ki67b and less MMP1 than the non-responders.

**894 Expression of Potential Biologic Therapeutic Targets in Uterine Serous Carcinoma**

*M Prasad Hayes, D Hileeto, LH Ellenson.* Weill Medical College of Cornell University, Mount Sinai School of Medicine, New York, NY.

**Background:** Uterine serous carcinoma (USC) is an aggressive type of endometrial cancer associated with a poor prognosis despite comprehensive surgical staging and adjuvant chemotherapy and radiation therapy. Biologic targets have yet to be fully explored in this disease and research on such targets could lead to clinical trials utilizing a new class of therapeutics. This study sought to evaluate primary USC tumors for the expression of proteins known to be targeted by small molecule therapeutic agents.

**Design:** Paraffin-embedded archival tissue from 25 primary USC tumors was used for immunohistochemical analysis. Expression of C-KIT, HER2/neu, and epidermal growth factor receptor (EGFR) was studied. In addition, p53 expression was determined to confirm the serous nature of the tumors. Immunostains were scored independently by M.P.H. and D.H., with discordant scores decided by L.H.E. A score of 0 to 12 was calculated as the product of staining intensity (0 to 3+) and the percentage of positively stained cells (0-4), with 1=1-25%, 2=26-50%, 3=51-75%, and 4=76-100%. A combined score was defined as having negative (score=0), weak (score=1-3), moderate (score=4-7), or strong (score=8-12) positivity.

**Results:** C-KIT stained negatively or weakly in 22/25 (88%) of cases and only 3/25 (12%) showed moderate staining. HER2/neu also displayed negative to weak staining in 21/25 (84%) of cases, while only 4/25 (16%) of the USC cases had moderate HER2/neu staining. In contrast, there was moderate or strong EGFR membranous staining in 15/25 (60%) of the cases and negative or weak staining in 10/25 (40%). In addition, 20/25 cases displayed moderate or strong nuclear staining for p53, with 5 cases exhibiting a complete absence of staining, consistent with aberrant p53 protein products.

**Conclusions:** Since optimal treatment of uterine serous carcinoma remains unknown, novel therapeutic approaches need to be actively pursued. In the current study of 25 primary USC tumors, EGFR stained positively in the majority of cases, suggesting a possible target protein. These findings warrant further investigation and suggest a potential role for therapeutic agents targeting EGFR, such as gefitinib and erlotinib, in the treatment of uterine serous carcinoma.

**895 The Presence of Endosalpingiosis and Proliferative Endosalpingiosis May Predict a Higher Risk of Recurrence in Ovarian Borderline Tumors: A Clinicopathologic Study of 254 Cases**

*MR Quddus, CJ Sung, MM Steinhoff, C Zhang, F Liu, R Moore, WD Lawrence.* Women & Infants Hospital, Brown Medical School, Providence, RI.

**Background:** Endosalpingiosis (ES) is commonly encountered on the surfaces of the pelvic peritoneum, fallopian tubes, ovaries, and less so on the pelvic parietal peritoneum, omentum and bladder and bowel serosa. ES is lined by single layer of tubal-type epithelium, whereas, proliferative endosalpingiosis (PES) exhibits papillarity, tufting, or intracystic detachment of cell clusters as defined by Bell and Scully (1990). In the above-noted extra-ovarian tissues, benign serous epithelia often, and mucinous epithelia rarely, accompany borderline ovarian tumors (BOTs). We investigated any association of ES, PES, or ECV with evidence of recurrence in BOTs.

**Design:** Endosalpingiosis (ES) is commonly encountered on the surfaces of the pelvic peritoneum, fallopian tubes, ovaries, and less so on the pelvic parietal peritoneum, omentum and bladder and bowel serosa. ES is lined by single layer of tubal-type epithelium, whereas, proliferative endosalpingiosis (PES) exhibits papillarity, tufting,

or intracystic detachment of cell clusters as defined by Bell and Scully (1990). In the above-noted extra-ovarian tissues, benign serous epithelia often, and mucinous epithelia rarely, accompany borderline ovarian tumors (BOTs). We investigated any association of ES, PES, or ECV with evidence of recurrence in BOTs.

**Results:**

Borderline Tumor Type	Serous or mixed serous		Mucinous	Total
	Recurrence	No Recurrence		
No ES	0	56	46	102
ES	11 (8.7%)	95	20	126
PES	6 (23%)	20	0	26

Statistical evaluation showed the following significance: ES vs. no ES with recurrence  $p < 0.025$ ; PES vs. no ES with recurrence  $p < 0.001$  and ES vs. PES with recurrence  $p = NS$ . All recurrent tumors were BOTs and none represented carcinomas.

**Conclusions:** Our study reveals that the presence of ES and PES pose a statistically significant higher risk of recurrence in ovarian serous BOTs as compared to the absence of ES. Such may indicate the presence of an underlying serous "field effect" with "recurrence" actually representing new serous disease. No statistically significant difference in recurrence was observed between the presence of ES and PES, but study of a larger number of cases may provide further information.

**896 Ewing's/PNET Differentiation in High Grade Uterine Papillary Serous Carcinomas**

*L Rashid, MR Quddus, CJ Sung, C Zhang, MM Steinhoff, WD Lawrence.* Women & Infants Hospital, Brown Medical School, Providence, RI.

**Background:** The association of Ewing's sarcoma/peripheral neuroectodermal tumor (ES/PNET) and endometrioid type endometrial carcinoma has been reported relatively recently. The ES/PNET component is often an undifferentiated spindle and round cell tumor and may be mistaken for a component of mixed müllerian tumor, especially on biopsy specimens. The prognosis of ES/PNETs is regarded to be worse than that of classic high grade endometrioid carcinomas. We have recently identified ES/PNET differentiation in uterine serous carcinomas and undertook this study to evaluate the frequency of serous carcinomas expressing ES/PNET differentiation.

**Design:** Seventy cases of uterine papillary serous carcinomas were retrieved from the archival files of our institution. Four  $\mu$ m sections were cut and stained with antibodies to CD99, CD99 (O13), a nonspecific IHC marker for ES/PNET and product of the MIC2 gene, that reacts with the cell membrane of neoplastic epithelium in 90% of cases of Ewing's/PNETs. Positive and negative control slides were run with each staining batch. The presence of perinuclear dot-like and/or membranous staining was regarded as positive. The frequency of ES/PNET in 446 endometrioid endometrial carcinomas including 56 FIGO grade 3 endometrioid carcinomas was also determined using the same methods just for comparison.

**Results:** Typical perinuclear dot-like and/or diffuse membranous CD99 staining was found in 5 of 70 uterine serous carcinomas supporting a component of ES/PNET differentiation. Focal positivity in small areas was identified in 5 other cases but was less than 10% in each case and interpreted as non-specific findings.

**Conclusions:** In our institution, immunohistochemically proven ES/PNET differentiation was found in 7% of uterine papillary serous carcinomas as opposed to ~10.7% of high grade endometrioid carcinomas. It appears that the frequency of CD99 expression in UPSCs is slightly lower than high grade endometrioid carcinomas at our institution. Nonetheless, the current study identifies the very existence of these tumors, which may represent a new subset of UPSCs.

**897 Extramammary Paget's Disease – A Proliferation of Adnexal Origin?**

*S Regauer.* Medical University Graz, Graz, Austria.

**Background:** Extra-mammary Paget's disease (EPD) is a predominantly intraepidermal tumor of hair bearing skin with rare dermal invasion. Although the association of underlying visceral malignancies has been reported, it is believed that EPD is a primary cutaneous carcinoma. EPD shows extensive involvement of adnexal structures, e.g. hair follicles, sweat glands and sebaceous glands suggesting a follicular stem cell origin. At least two different types of stem cells are involved in epidermal (re)generation: long-lived, slow cycling and short-lived, fast cycling (transiently amplifying) stem cells located in clusters i) within basal cell layer of the interfollicular epidermis and ii) within the bulge region of the hair follicle. Follicular stem cells produce progeny that differentiate into hair follicle lineages, but also into sebocytes, sweat glands and epidermis. Follicular stem cells of the bulge region are characterized by CK15 and CK19 expression. CK15 & 19 are also expressed in trichogenic tumors, and are considered markers for derivation from follicular stem cells.

**Design:** In search for a potential follicular origin of EPD, excisions of 12 patients with EPD without underlying malignancies were analyzed immunohistochemically. Formalin-fixed, paraffin-embedded tissues of 12 primary EPD (3 anal, 9 vulvar) were incubated with antibodies to CK 7, 15, 19 and 20.

**Results:** All EPD showed polygonal Paget cells in the interfollicular epidermis, hair follicles, sebaceous and apocrine glands distributed individually, in nests and displaying occasional glandular differentiation. The polygonal Paget cells were intimately associated with small, flat, mitotically active, "compressed" keratinocytes. The large Paget cells uniformly expressed CK7 and 19 in 12/12 EPD. The small "compressed" keratinocytes showed strong cytoplasmic CK15 staining in 9/12 EPD with focal accentuation, while the polygonal Paget cells were negative. CK20 showed specific but patchy staining in 50% of EPD.

**Conclusions:** The histological and immunohistochemical observations allow the following conclusions: 1) The small, flat "compressed" keratinocytes are most likely an integral part of EPD and may serve as potential stem cells. 2) As both cell types express CK typical for follicular differentiation, EPD may be a proliferation of adnexal stem cells residing in the infundibulo-sebaceous unit of hair follicles. 3) The complex histological and immunohistochemical phenotype of EPD (CK 7, 15, 19, 20, Muc-1,

Her-2 neu, androgen receptor positivity) speaks against an origin of EPD from intraepidermal Toker cells, but is rather reminiscent of sebaceous gland differentiation.

### 898 Immunohistochemical Evaluation of Endometrial Adenocarcinoma with Emphasis on the Differential Diagnosis with Endocervical Adenocarcinoma

MD Reid-Nicholson, P Iyengar, A Ali, RA Soslow. Memorial Sloan-Kettering Cancer Center, New York, NY.

**Background:** It remains a diagnostic challenge to discriminate between some endometrial and endocervical adenocarcinomas, especially in biopsy material. Endocervical adenocarcinomas have been reported to express p16 and CEA whereas endometrial adenocarcinomas, particularly those of endometrioid type, show ER, PR and vimentin expression.

**Design:** We tested large numbers of endometrial cancers, enriched for high-grade tumors, to determine whether this reported immunophenotype was valid. Immunohistochemical stains were performed on the following types of endometrial cancers using established methodology: FIGO grade 1-2 endometrioid (n=42), FIGO grade 3 endometrioid (n=40), serous (n=24), clear cell (n=11), and carcinosarcoma (n=9).

**Results:** The results of the statistical analysis are summarized in Table 1.

	p16 (+) (%)	ER (+) (%)	PR(+)(%)	mCEA(+)(%)	Vimentin (+)(%)
FIGO 1 and 2 Endometrioid	7	45	57	7	N/A
FIGO 3 Endometrioid	25	19	19	2.5	N/A
Serous	92	38	50	13	93
Clear cell	45	9	45	18	100
Carcinosarcoma	67	11	11	0	N/A
p-value	<0.001	0.03	0.003	0.28	0.44

N/A= not available

**Conclusions:** Many of the markers traditionally used for the distinction of endometrial and endocervical adenocarcinomas are not site-specific; they are instead related to different factors, including histologic subtype, grade and possibly pathogenesis. Since p16 staining has been found in high grade endometrial carcinoma, particularly in serous and clear cell subtypes, it remains a discriminatory marker only for well-differentiated endometrioid adenocarcinomas of endometrium versus endocervical adenocarcinomas of the usual type. Although ER and PR are expressed in many endometrial adenocarcinomas, large percentages of tumors are negative; this argues against the use of these stains for distinction from endocervical adenocarcinomas, especially when the tumor in question is not well-differentiated. mCEA and vimentin remain useful markers. Since large percentages of endometrial serous and clear cell carcinomas express p16, this immunostain might also be useful in the differential diagnosis of diagnostically problematic endometrial cancers; this should be validated in further studies.

### 899 Promoter Hypermethylation of $p16^{INK4A}$ Is a Frequent and Early Event in Vulvar Carcinogenesis and Correlates with p16 Expression in Squamous Cell Carcinoma

A Ribe, E Lerma, LI Catusas, J Prat. Hospital Sant Pau, Autonomous University, Barcelona, Spain.

**Background:** Tumor suppressor gene inactivation by promoter hypermethylation plays a role in carcinogenesis. Overexpression of p16 has been associated with high-risk human papillomavirus (HPV) in preinvasive and invasive cervical cancer. However, only a small subset of vulvar carcinomas are HPV-related.

**Design:** The 39 selected cases included: 26 keratinizing squamous cell carcinomas (SCC), 3 verrucous SCC, 8 classic vulvar intraepithelial neoplasia (VIN), and 2 differentiated VIN. Immunohistochemical expression of p16 was performed using the avidin-biotin-peroxidase complex method and evaluated as positive or negative. DNA methylation patterns in the CpG islands of  $p16^{INK4A}$  was investigated by methylation-specific polymerase chain reaction. Statistical analysis was done using the Kappa test.

**Results:** Promoter hypermethylation or abnormal p16 protein expression were detected in 38/39 cases (97.4%). In SCC, hypermethylation was found in 23/28 tumors, 5 of which showed p16 overexpression. Of the 5 non-methylated SCC, 4 had p16 overexpression. Hypermethylation was encountered in 8/10 VIN, 5 of which showed p16 overexpression. The 2 non-methylated VIN also showed p16 overexpression. Concordance index between  $p16^{INK4A}$  promoter and p16 overexpression was low (0.292).

**Conclusions:** p16 is frequently altered in vulvar SCC and VIN.  $p16^{INK4A}$  promoter hypermethylation is an early event in vulvar carcinogenesis. Discordance between  $p16^{INK4A}$  promoter hypermethylation and p16 protein expression in VIN suggests that the first hit involves promoter hypermethylation with preserved protein expression. Subsequently, a second hit would be responsible for loss of p16 expression in invasive SCC. Further studies are needed to characterize the second hit which most likely results from LOH and/or gene mutation.

### 900 Brenner Tumors but Not Transitional Cell Carcinomas of the Ovary Show Dysregulation of Cell Cycle G1-S Phase Transition

A Ribe, CV Larrosa, LI Catusas, J Palacios, J Prat. Hospital de Sant Pau, Autonomous University, Barcelona, Spain.

**Background:** Transitional cell tumors (TCT) of the ovary include Brenner tumors (BT) (benign, borderline, and malignant) and transitional cell carcinomas (TCC). To gain insights into the molecular alterations underlying TCT we have conducted an immunohistochemical study of selected proteins involved in the main pathways of carcinogenesis, such as cell cycle and proliferation, apoptosis, cell signalling, and cell adhesion.

**Design:** The study included 5 benign BT, 6 borderline BT, 1 malignant BT, and 6 TCC. Immunohistochemical expression of p16, p21, pRb, Cyclin D1, p53, CK7, CK20, Ki-67, ER, PR, vimentin, CEA, PTEN, AKT, Fas, BAX, Bcl-2, EGFR, neu, B-catenin, E-cadherin and N-cadherin was studied in all cases.

**Results:** BT and TCC differed mainly in the expression of pRb, p16, and p53. Benign BT were characterized by lack of pRb (100%), expression of p16 (100%), and negative immunostaining for p53 (100%). Borderline BT not only lacked pRb (100%) and p53 immunoreaction, but also p16 expression (85%). The malignant BT lacked pRb and p16 immunoreaction and was positive for p53. In contrast, most TCC exhibited a strong p53 immunostaining (66%) but frequently normal pRb (66%) and p16 (100%) immunoreaction.

**Conclusions:** Our study suggests that BT and TCC of the ovary follow 2 different carcinogenic pathways. Dysregulation of cell cycle control, particularly at the G(1)-S-phase transition, seems to play a role in the pathogenesis of BT of the ovary: early loss of expression of pRb would be followed by loss of p16 expression. p53 alterations would occur late in the progression of BT. In contrast, p53 alterations, present in most TCC, probably represent an early carcinogenic event which occurs in the absence of pRb and p16 alterations.

### 901 Histological and Immunohistochemical Phenotypes of Atypical Leiomyoma Like Areas within Uterine Leiomyosarcomas

K Rijhwani, J-J Wei, H Zhu, L Chiriboga, H Yee, K Mittal. New York University Hospital, New York, NY.

**Background:** Uterine leiomyosarcoma (LMS) is a rare malignant smooth muscle tumor identified in about 1-2% hysterectomies for uterine leiomyomata (ULM). Due to lack of precursor lesions, development of LMS from either normal myocytes or existing ULM has not been established. Searching for premalignant lesions of LMS is of great interest. We have LMS mixed with areas of "atypical" leiomyoma (cytological atypia, low mitoses). To characterize the molecular differences between malignant and histological "atypical" areas in these mixed tumors, we examined the selected gene products from each component of these mixed LMS.

**Design:** Nine mixed LMS were selected for this study. Each mixed LMS contained histological "atypical" and malignant components. The "atypical" components had low count of MIB1 and weak P53 stains. Triplet tissue cores from "atypical" and sarcomatous areas as well as normal matched myometrium and separate leiomyomata (ULM) were collected and arrayed in tissue microarray. Gene markers of ER, PR, RXR, RAR, BCL2, CD10, CD34, EGFR, PDGF and P27 were selected for the study. Semiquantitative immunoscores were scaled and analyzed from each component.

**Results:** The level of net gain or loss of the immunoreactivity for the selected gene products from each component of 9 mixed LMS were scored against the matched myometrium. The mean immunoscores for the same group of gene products from pure leiomyomata (60 cases) and pure leiomyosarcomas (26 cases) were used as reference values. The overall expression levels of ER, PR, RAR, RXR, MIB1, CD10 and P53 were significantly different between separate ULM and LMS. By comparing the immunoscores from tissue cores of "atypical" and malignant areas, they were similar in the mean scores of PR, CD10 and significantly different for MIB1 and RXR. The mean values of ER, RAR and P53 in "atypical" tissue cores fell in between ULM and LMS.

**Conclusions:** Atypical ULM like areas identified within LMS have their characteristic immunoprofile for the selected gene products. The levels of net gain or loss of immunoreactivity for the markers largely fell in between benign ULM and malignant LMS. The presence of areas resembling atypical ULM in LMS suggests the existence of premalignant lesions in mixed LMS cases.

### 902 Molecular Analysis of Bilateral Mature Cystic Ovarian Teratoma

AG Rivenbark, BK Buckley, KK White, WB Coleman, DB Thomas. University of North Carolina School of Medicine, Chapel Hill, NC.

**Background:** Mature cystic teratoma (dermoid cysts) presents with bilateral neoplasms in 12% of cases, but it is not known whether these tumors represent multiple primary neoplasms or the result of tumor spread. Genetic analysis to determine the relationship between bilateral mature teratomas has not been previously performed. In this study, we have performed a molecular analysis of a group of bilateral mature teratomas to address tumor relatedness and lineage.

**Design:** Five patients (17-45 years-old, obese, 80% nulliparous) with lymph node-negative bilateral mature teratoma (dermoid cysts) were identified. Histologically, tumors were composed of skin, lacking distinguishing features. Genomic DNA was isolated from paraffin-embedded tissues representing right and left ovarian tumors. Microsatellite PCR analysis was performed to genetically characterize these tumors, exploiting the unique genetic differences (allelic variation) between tumors that result from divergent natural histories among multiple tumors in a single patient. Twelve microsatellite markers were employed and at least 5 microsatellites were evaluated for each tumor.

**Results:** The bilateral tumors from two patients exhibited identical genetic fingerprints: Patient 1 was heterozygous for 10 markers with retention of both alleles, and Patient 4 was heterozygous for 4 markers with retention of both alleles. In contrast, the bilateral tumors corresponding to Patients 2, 3, and 5 exhibited genetic variations reflective of allelic loss, producing distinct allelotypes for the multiple tumors. No mutually exclusive genetic differences were observed, preserving the possibility of a lineage relationship between the tumors (where one is derived from the other). Patient 2 exhibited allelic loss of 3/8 informative markers in one tumor, Patient 3 exhibited allelic loss of 4/7 informative markers in one tumor, and Patient 5 exhibited allelic loss in 1/4 informative markers in one tumor.

**Conclusions:** Our findings suggest that the bilateral tumors arising in these patients are genetically identical in 2 cases, and distinct in 3 cases. Genetically identical tumors might reflect direct spread of a single tumor between the ovaries, and genetically distinct tumors may be the result of genetic evolution concurrent with spread from a single primary tumor. Alternatively, both groups of tumors could result from a common tumorigenic pathway affecting a susceptible cell population through a field effect.

### 903 Expression Profile of Novel Membrane Progesterone Receptors in Epithelial Ovarian Tumors

M Romero-Sanchez, S Peiper, B Evans, Z Wang, A Ribe, Ll Catusas, J Prat, J Giri. Medical College of Georgia, Augusta, GA; Hospital de la Santa Creu i Sant Pau, Barcelona, Spain.

**Background:** The recently discovered membrane progesterone receptors (mPRs) are members of the larger protein family of Progesterin and AdipoQ Receptors (PAQR) and are distinct in sequence and structure from nuclear hormone receptors. The human mPRs alpha, beta and gamma (corresponding to PAQR 7, 8, and 5) were originally identified as homologues of a fish mPR required for oocyte maturation. The identification of a novel class of membrane receptors, possibly coupled to the G-proteins, may provide an explanation for the observed rapid, non-genomic effects of steroid hormones. We analyzed expression of four members of the PAQR family, the three mPRs (PAQR 7, 8, and 5) and PAQR4, a novel, yet uncharacterized member of the family.

**Design:** A panel of 20 tumors were investigated: 16 ovarian carcinomas (4 endometrioid, 4 mucinous, 4 serous, 4 clear cell carcinomas), and 4 adenomas. Total RNA from clinical specimens was extracted with High Pure RNA tissue kit (Roche) and quantitated with Quant-iT RiboGreen RNA reagent. RNA standards were synthesized from the mPR genes with T7 RNA polymerase using a pcDNA3 construct as template. The transcription level of the receptors was assessed by two step quantitative RT-PCR and densitometry. The GAPDH house-keeping gene was used as control.

#### Results:

	Membrane Receptors expression profile for tumor types			
	PAQR-7(mPR-a)	PAQR-8(mPR-b)	PAQR-5(mPR-g)	PAQR-4
Endometrioid (n=4)	+++	+	++	++
Clear cell (n=3)	+++	+	++	+
Serous (n=4)	+++	+	++	+
Mucinous (n=3)	+++	++	+	+
Adenomas (n=4)	+++	+	-	-
Normal (n=3)	+++	+	-	+/-

+++high; ++intermediate; +low; +/-very low but discernable; -undetectable

**Conclusions:** Distinct expression profiles were observed for the four genes in different tumors. Consistent high levels of mPR alpha expression were observed in all normal and tumor tissues, whereas mPR beta, gamma and PAQR4 showed variable expression. The expression of mPR gamma was elevated in endometrioid and clear cell carcinomas, closely related neoplastic counterparts of hormone responsive tissues. Our results are the first demonstration of mPR expression in human tumors and, suggest a potential role for these receptors in the pathogenesis of ovarian cancer.

### 904 Glucose Transporter-1 Expression in Endocervical Neoplasia

SA Rosen, S Lathrop, A Chakerian, NE Joste. University of New Mexico School of Medicine, Albuquerque, NM.

**Background:** Malignant cells exhibit increased glycolytic metabolism and often increased gene expression of glucose transporter proteins, such as Glut-1. Cervical squamous cell neoplasia demonstrates increased Glut-1 expression that increases with severity of dysplasia and is thought to represent an early step in tumor progression. We hypothesize that Glut-1 protein may be similarly upregulated in endocervical neoplasia with increasing expression along a continuum from normal endocervix to invasive endocervical adenocarcinoma (IA).

**Design:** Glut-1 immunostaining was analyzed in 16 cases of benign endocervix, 15 reactive endocervical atypia, 15 low grade cervical glandular neoplasia (LCGIN), 23 adenocarcinoma in-situ (AIS), and 16 IA. Noted was the percentage of cells with membranous staining (negative, low (1-24%), intermediate (25-49%), high (50-100%) and stain intensity (weak, moderate, strong).

**Results:** Positive staining was noted in 2 of 16 benign endocervix (12.5%), 1 of 15 reactive endocervix (6.7%), 1 of 15 LCGIN (6.7%), 14 of 23 AIS (60.8%), and 14 of 16 IA (87.5%). There was no significant staining difference between AIS and IS (p=0.08) nor between the groups of benign, reactive, and LCGIN, but significant differences were seen between the latter 3 groups and AIS (p=0.0012) and IS (p<0.00001). An intermediate to high percentage of cell staining was seen in 11 of 14 IA (78.6%) and 7 of 14 AIS (50.0%); and all 14 IA (100%) and 11 of 14 AIS (78.5%) had moderate to strong stain intensity. All benign, reactive, and LCGIN cases had a low percentage of cell staining and all had weak staining intensity.

**Conclusions:** Glut-1 expression is strongly associated with neoplastic progression in endocervical tissue, with AIS positivity suggesting that it is an early event in tumorigenesis. Low level staining in benign, reactive, and LCGIN is similar to that seen in cervical squamous neoplasia. Increased expression may coincide with other molecular events thought to occur early in cervical squamous neoplasia, such as viral transcription and E6 and E7 protein expression. These results may be useful in distinguishing benign atypical endocervix from neoplastic.

### 905 Histopathologic Criteria for Assessment of Treatment Response and Tumor Regression in Advanced Ovarian Cancer after Neoadjuvant Chemotherapy

S Sassen, F Fend, W Kuhn, N Avril, B Schmalfeldt, R Busch, H Hoefler, J Naehrig. Technical University Munich, Munich, Germany; University of Bonn, Bonn, Germany.

**Background:** The aim of this study was to establish histopathologic criteria for tumor regression and response to treatment in advanced ovarian cancer following neoadjuvant chemotherapy (nCTX).

**Design:** We retrospectively reviewed the surgical specimens of 49 patients with advanced stage (FIGO IIIc and IV) ovarian cancer who had undergone nCTX. 35 patients treated with primary surgery followed by postoperative CTx served as an age and stage matched control group. Assessment of histopathologic tumor regression was performed on specimens from tumor debulking surgery. Seven parameters of regressive changes potentially related to nCTX were evaluated and graded semiquantitatively, including hyaline fibrosis, necrosis, inflammation, foamy macrophages, isolated psammoma bodies,

hemosiderin, and giant cells of foreign-body type. The size of residual viable tumor was defined as the largest diameter of a single tumor focus. Survival analysis was based on a median follow-up of 49 months.

**Results:** A significant correlation was observed between the size of residual tumor after nCTX and overall survival (OS). Patients with residual tumor  $\leq 5$  mm (n=7) after 3 cycles of nCTX had a median OS of 45.6 months compared with 27.3 months in patients with tumors  $> 5$  mm (n=42; p=0.03). In the control group, no correlation was found between initial tumor size and OS. The occurrence of multiple foci of hyaline fibrosis, foamy macrophages, psammoma bodies and hemosiderin showed a high degree of specificity (range 89-100%) but a low sensitivity (18-22%) for previous treatment with nCTX. There was no correlation between the size of residual tumor and the extent of regressive changes. No correlation was found between the presence and amount of any type of CTx associated regressive changes and OS.

**Conclusions:** Residual tumor size after nCTX is an important prognostic factor for overall survival and should be mentioned in the histopathologic evaluation of ovarian cancer. Although regressive changes associated with nCTX can be identified in neoadjuvantly treated ovarian carcinomas, they failed to show prognostic relevance.

### 906 5'-Inositol Phosphatase 2 (SHIP2) Is Over-Expressed in Endometrial Cancer

M Sever, M Tandon, N Prasad, S Badve. Indiana University, Indianapolis, IN; Purdue University, West Lafayette, IN.

**Background:** Deregulation of phosphatidylinositol 3'-kinase (PI3K) due to loss of expression of the 3'-inositol phosphatase, PTEN (Phosphatase and Tensin Homologue Deleted on Chromosome 10), is a genetic anomaly seen in majority of endometrial carcinomas. PTEN functions as a negative regulator of PI3K signaling converting active PI 3,4,5 trisphosphate into inactive PI 4,5 bisphosphate. The SH2-containing 5'-inositol phosphatase 2 (SHIP2) is believed to have similar function as PTEN, however the product generated by SHIP2, PI 3,4 bisphosphate, retains the capacity to activate AKT (PKB) *in vitro* and is required for full activation of AKT *in vivo*. We have noted high levels of SHIP2 protein in certain cancer cell lines; which led us to hypothesize a unique role for SHIP2 in oncogenic signaling of cancer cells. Our previous experiments suggest a role for SHIP2 in the control of cell adhesion, cell spreading and endocytic down-regulation of membrane receptors such as EGFR (Mol Cell Biol. 2001; J Cell Sci. 2002; J Biol Chem. 2005). This study was designed to analyze the role, if any, that SHIP2 plays in endometrial carcinoma.

**Design:** Cases surgically treated for endometrial carcinoma were selected. Immunohistochemical staining was performed on archival paraffin sections, with a polyclonal anti-SHIP2 antibody (J Biol Chem.1998). Antigen retrieval with citrate buffer pH 6.0 (Dako) and TSA amplification system (Elmer Perkins) was used. AEC was used as the chromogen.

**Results:** Eighteen cases of endometrial carcinoma were examined from patients with an age range of 37 to 89 years (mean 66 years) and FIGO stage of range Ia to IIIa. Strong cytoplasmic staining was seen in 14 of the 18 cases. These include endometrioid, papillary serous, villoglandular, poorly differentiated carcinomas and adenocarcinoma with squamous differentiation with high and low histologic grades. The cases that showed weak or no staining were: 2 cases of low grade endometrioid carcinoma and a case each of papillary serous carcinoma and clear cell carcinoma.

**Conclusions:** Persistent activation of AKT (PKB) is a critical event in the development of endometrial carcinoma. This is classically thought to be due to loss of PTEN. SHIP2 over-expression was seen in majority of cases examined. This provides for a possible alternative mechanism for the AKT activation. Additional studies exploring the mechanisms of regulation of SHIP2 and their relationship with AKT are being carried out.

### 907 Gene Expression Profiles of Ovarian Serous Carcinoma after Neoadjuvant Chemotherapy

PA Shaw, M Agochiya, M Sharma, J Murphy, B Rosen, TJ Brown, H Begley, I Jurisica. University of Toronto, Toronto, ON, Canada.

**Background:** Standard treatment of advanced stage ovarian carcinoma includes debulking surgery followed by chemotherapy. Neoadjuvant chemotherapy (Neo) has become an important approach in some centers. Although the morphology of tumors after Neo has been described, little is known about the resulting molecular changes or the histologic/ molecular features that might predict which patients benefit from this therapeutic approach. Our aim is to determine gene expression changes induced by Neo in advanced stage serous carcinoma. Further characterization of any tumour remaining after treatment may be valuable in designing treatment approaches and predicting chemoresistance.

**Design:** Snap-frozen tissues (n=44) were selected using the following criteria: serous histology, stage III-IV, tumour content >75%, completion of full course of combined taxol/platinum chemotherapy (n=22 neoadjuvant [Neo], n=22 adjuvant [Adj] only). Histological sections representative of snap-frozen tissue were reviewed. RNA was extracted, and expression profiling completed on Affymetrix GeneChip Arrays. After data normalization, a two-class SAM analysis was performed to elucidate the differences between the adjuvant and neo-adjuvant samples. BTSVQ (Binary Tree- Structured Vector Quantization) was used to perform unsupervised clustering. To determine if tumor profiles showed any genetic differences reflecting the differences in outcome, the survival analysis method provided in SAM was used.

**Results:** There was no significant difference between the two groups with respect to either the relapse of disease (p=0.13), or the survival time (p=0.39). After BTSVQ clustering of the whole data set, more appropriate sample groups were identified, and the subsequent SAM analysis identified 66 genes differentially expressed at a median False Detection Rate (FDR) of 4.09%. Morphological features of chemotherapy was seen in 59% (13) of the Neo samples. After repeating BTSVQ using only expression data for the 66 genes, only 1 of 3 Neo samples clustering with Adj showed chemotherapy

effect. Preliminary SAM analysis did not reveal differential gene expression according to outcome at a FDR less than 17%.

**Conclusions:** Gene expression analysis of residual carcinoma post-chemotherapy reveals differential gene expression between samples with and without morphological evidence of chemotherapy. Study of these genes may reveal markers predictive of response to chemotherapy, and assist in the determination of individualized tumor management.

### 908 Smoking Increases the Risk of High-Grade Vaginal Intraepithelial Neoplasia in Women with Oncogenic Human Papillomavirus

*JF Sherman, MF Evans, SL Mount, J Skelly, GH Eltabbakh.* Fletcher Allen Health Care, Burlington, VT; University of Vermont, Burlington, VT; S. Burlington, VT.

**Background:** Women smokers are at an increased risk for cervical intraepithelial neoplasia (CIN) and/or vaginal intraepithelial neoplasia (VAIN). It is unclear whether tobacco usage increases the risk of high-grade CIN/VAIN among women with oncogenic human papillomavirus (HPV) type infections. In a retrospective study, we investigated the association of smoking with HPV type and VAIN grade.

**Design:** A SNOMED search was performed for vaginal biopsy or resection specimens diagnosed as VAIN over an 11-year period. The diagnosis of VAIN grade was confirmed by histological review. VAIN I was considered low grade VAIN (LGVAIN) and VAIN II and III as high-grade VAIN (HGVAIN). HPV type was determined by GP5+/6+ PCR and dot blot hybridization with type-specific oligonucleotide probes. HPV types were divided as high-risk (HR) or other. The other category included unknown risk, low risk and negative specimens. Smoking history was obtained by chart review. A positive smoking history was defined as current smokers as well as those who reported quitting. Statistical analysis was performed using chi-square test.

**Results:** We identified specimens from 111 patients (age range 15-84); 64% (n=71) were diagnosed with HGVAIN and 36% (n=40) with LGVAIN. HR HPV types were identified in 83% (n=92), other types in 17% (n=19); 21 different HPV types were detected in total. Smoking history was available for 81% (n=90) and included 28% (n=31) with a positive smoking history. The mean age for smokers and non-smokers was 36.7 and for non-smokers was 37 years. There was no significant difference in infection with HR vs. other types (p=0.92) among smokers. In patients with HR HPV types, smokers were at an increased risk of developing HGVAIN lesions than patients who had never smoked (83% vs. 59%, p=0.02).

**Conclusions:** These data indicate an increased risk for HGVAIN in HR HPV positive women who smoke compared to HR HPV positive non-smokers. Further studies are required to determine whether the increased risk is a result of smoking related immune system impairment, and/or aggravation of HR HPV induced genetic instability.

### 909 Fli-1 in Uterine Mesenchymal Neoplasms

*J Shutter, CL van Sant, MR Wick, KA Atkins.* University of Virginia, Charlottesville, VA.

**Background:** Endometrial stromal sarcomas and cellular leiomyomas potentially share histologic characteristics, making their separation challenging in some cases. Because the biological properties of these lesions differ, a diagnostic distinction between them is important. CD10 and smooth muscle actin (SMA) immunostaining may be helpful in that regard but those markers can, in fact, be seen in both neoplasms. Fli-1—a nuclear transcription factor known to react with endothelia, hematopoietic elements, and selected soft tissue tumors—is present in normal myometrium but has not been assessed in mesenchymal tumors of the uterus. This analysis was initiated to undertake that evaluation.

**Design:** Eight endometrial stromal tumors and a tissue microarray of 27 smooth muscle tumors of the uterus were immunostained for Fli-1 using standard biotin-avidin technique and antibody clone SC356 (Santa Cruz, Inc). Frozen tissue whole-cell lysates of 6 normal myometria, 3 leiomyomas, and 3 leiomyosarcomas were also subjected to Western immunoblotting for Fli-1.

**Results:** Fli-1 was absent in 75% (6/8) of the endometrial stromal tumors. Of the two positive cases, one was focally positive (<10% of cells) and one was diffusely positive. Fli-1 was present globally and strongly in all leiomyomas. Normal myometrium was diffusely positive for Fli-1 in each instance. 75% (9/12) of leiomyosarcomas lacked Fli-1. Of the 3 that labeled for this marker, 2 were only focally positive in 5-10% of cells (the other was diffusely reactive). Western immunoblotting showed increased Fli-1 levels in all leiomyomas when compared with normal myometrium.

**Conclusions:** Fli-1 immunostaining is potentially helpful in distinguishing between endometrial stromal tumors and leiomyomas of the uterus. Fli-1 was absent in most leiomyosarcomas in this study, and could aid in separating benign from malignant smooth muscle tumors; that eventuality must await further study.

### 910 Spindle-Cell Alteration of Endometrial Stroma as a Predictor of Plasma Cell Infiltration

*MA Siddiqui, RW Lieberman.* University of Michigan, Ann Arbor, MI.

**Background:** The hallmark of chronic endometritis is the presence of plasma cells within the endometrium. Their identification, however, can be hindered by a number of variables including low numbers, plasmacytoid-stromal cells and other mononuclear cells. Routine immunohistochemical staining is not cost-effective and detailed "high-power" examination is frequently a daunting and time-consuming task. Here, we investigate whether the phenomena of spindle-cell alteration of the stroma, often times seen in chronic endometritis can be a surrogate "marker" for the presence of plasma cells.

**Design:** Standard histologic sections of 150 endometrial biopsies/curettings were independently examined for spindle endometrial stroma by the 2 authors. The specimens that were in agreement between both of the authors were subsequently assessed for plasma cells using CD138 immunohistochemistry (IPOX); non-spindled controls were also stained. Specimens were excluded if they were inadequate, lacked surface epithelium,

contained any form of hyperplasia or malignancy, composed predominantly of lower uterine segment or were fragments of true polyps.

**Results:** 15 H&E sections were randomly chosen to serve as preliminary data. Mean age was 43 (range: 29-54); 12 patients were biopsied for abnormal uterine bleeding, 1 for family history of breast and ovarian cancer, 1 for endometrial polyp and 1 for previous atypical endometrial biopsy. All of the biopsies showed proliferative-phase endometrium. No plasma cells were identified with routine H&E staining. Of these initial 15, 5 were excluded, 3 for inadequacy and 2 for true polyps. Of the remaining 10, 7 showed stromal spindling (4 were diffuse and 3 were focal). After CD138 IPOX, all of the spindled-stroma specimens contained at least 5 plasma cells per section with a mean of 10. Of the 3 non-spindled stroma controls, 2 did not contain any plasma cells, while one had 5.

**Conclusions:** With this preliminary data, spindle-cell alteration of the stroma appears to be a useful surrogate marker for the presence of endometrial plasma cells. Additional specimens will be included to support this impression.

### 911 Serous Borderline Tumors with Peritoneal Implants: Clonal Analysis Favors a Monoclonal Origin

*NLG Sieben, GMJM Roemen, J Oosting, GJ Fleuren, MV Engeland, J Prat.* University of Maastricht, Maastricht, Netherlands; Leiden University Medical Centre, Leiden, Netherlands; Hospital Sant Pau, Autonomous University, Barcelona, Spain.

**Background:** Most serous borderline tumors (SBTs) of the ovary behave in a remarkably indolent manner even in the presence of peritoneal implants and/or lymph node involvement. Progressive disease is characteristically associated with invasive implants. The pathogenesis of the implants is currently unknown. Two major hypotheses have been proposed: the first favors a monoclonal origin arguing that the peritoneal lesions derive from neoplastic cells that are shed from the primary ovarian tumor. The alternative hypothesis favors a polyclonal origin as a result of a field defect of susceptible Mullerian cells from which multiple independent tumors would arise.

**Design:** We have employed a genome wide allelotyping and B-RAF/K-RAS mutation analysis to assess clonality in 26 metachronous multifocal tumors from 10 patients, using 23 microsatellite markers. We included 4 noninvasive and 6 invasive peritoneal implants, 3 lymph nodes containing SBT deposits, and 3 invasive ovarian (auto-)implants.

**Results:** Concordant LOH was observed for 1-5 microsatellite markers in all tumor sites in 5 of the 10 patients (4 with invasive implants and one with noninvasive implants). No discordant LOH was found. In addition, 3 of the 5 patients with LOH had identical K-RAS mutations (two had invasive implants and one noninvasive implants) and one (who had invasive implants) identical B-RAF mutations in all tumor sites. Of the 5 patients without LOH, 2 (with invasive and noninvasive implants respectively) exhibited identical K-RAS in all tumor sites.

**Conclusions:** LOH profiling and K-RAS/B-RAF mutation analysis showed concordance of genetic changes in all sites in 22 tumors from 8 patients that were informative; thus, strongly favoring a common origin. This was indicated by a Likelihood Ratio (Possibility Common Origin/Possibility Independent Origin) ranging from 11.9 to 1.06x10<sup>7</sup>. Our results strongly support that SBT-related noninvasive and invasive implants arise as a result of spread from a single ovarian site.

### 912 D2-40 Expression in Ovarian and Endometrial Adenocarcinomas: A Tissue Microarray Study

*AE Sienko, D Coffey, NA Singhal, L Garza.* The Methodist Hospital, Houston, TX.

**Background:** D2-40 is a monoclonal antibody that reacts with a fixation-resistant epitope on lymphatic endothelium and has recently been shown to be a useful marker for epithelial malignant mesothelioma. In a previous report evaluating D2-40 in 404 primary lung carcinomas, we found no staining in primary lung adenocarcinomas with 50% of squamous cell carcinomas demonstrating weak focal positivity. Several other studies have reported positive staining in primary ovarian and primary endometrial carcinomas. We evaluated D2-40 in ovarian and endometrial adenocarcinomas to determine its utility in the differential diagnosis of epithelial malignant mesothelioma versus metastatic carcinomas of gynecologic origin.

**Design:** Tissue microarrays (TMA) were prepared in triplicate 1 mm punches from 50 primary ovarian carcinomas that included 37 serous papillary tumors and 13 other histological types (endometrioid, mucinous, clear cell) and 59 primary endometrial carcinomas of which 54 were endometrioid, 4 serous papillary and 1 mucinous tumor. The TMA's were stained by usual immunohistochemical technique for D2-40 (1:75 dilution pretreated with T.9, Signet) and scored for percentage cell staining (scale 0-3, <33% = 1, 33-66% = 2, >66% = 3) and intensity (0 = negative, 1 = weak, 2 = moderate, 3 = strong).

**Results:** No staining (0%) was seen in the ovarian carcinomas. Only 2 endometrioid adenocarcinomas with squamous differentiation (2/59 = 3%) showed focal positive cytoplasmic staining. The positive staining occurring only in the areas demonstrating squamous differentiation.

**Conclusions:** D2-40 has been found to be expressed in epithelial malignant mesothelioma. We have previously reported D2-40 to be also expressed focally and weakly in primary squamous cell carcinomas of lung but not in primary adenocarcinomas. The current study shows D2-40 to be a useful marker that could be included in a panel to differentiate metastatic ovarian or endometrial adenocarcinoma from epithelial malignant mesothelioma.

### 913 WT-1 Expression in Tissue Microarray (TMA) of 50 Ovarian Carcinomas and 59 Primary Uterine Adenocarcinomas

*AE Sienko, D Coffey, NA Singhal, L Garza.* The Methodist Hospital, Houston, TX.

**Background:** Recent studies have shown that WT-1 is expressed in a majority of ovarian serous carcinomas and only occasionally in uterine serous carcinomas but not in endometrioid adenocarcinomas. WT-1 has been suggested to be a useful marker in helping



to differentiate and distinguish primary ovarian from primary uterine serous carcinomas in disseminated cases. We evaluated WT-1 expression in 50 primary ovarian and 59 primary uterine carcinomas.

**Design:** TMA were prepared as 1mm triplicate sample punches from 50 ovarian carcinomas and 59 primary uterine carcinomas and stained for WT-1 (1:100 dilution pretreated with T.9, Dako Cytomation, Carpinteria, CA). Percent of cells showing nuclear staining was scored 0-3 (0 = <33%, 1 = 33-66%, 3 = >66%) and intensity of staining was recorded as a scale from 0-3 (0 = negative, 1 = weak, 2 = moderate and 3 = strong).

**Results:** Of the 50 primary ovarian carcinomas, 74% (37/50) were serous papillary and 26% (13/50) included other epithelial ovarian tumors such as endometrioid, mucinous and clear cell. Only 7 of the 37 serous ovarian papillary tumors (19%) showed moderate (+2) WT-1 staining in <33% of cells. No staining was seen in the other histological types of ovarian carcinoma. The endometrioid carcinomas which included 53 endometrioid (53/59 = 90%), four serous papillary (4/59 = 7%) and mucinous (2/59 = 3%) revealed no staining of the endometrioid or mucinous types of tumor. All four of the uterine papillary serous carcinomas showed moderate nuclear staining (+2) in <33% of the cells.

**Conclusions:** WT-1 may be a useful marker in the differential to distinguish between primary serous ovarian and primary serous endometrioid carcinomas but caution should be used in interpreting the staining results. In contrast to previous studies that reported diffuse WT-1 immunopositivity in ovarian serous tumors versus focal staining in uterine serous tumors, we found focal positive staining of similar intensity and frequency in both ovarian and uterine serous carcinomas. No staining was seen in endometrioid tumors, mucinous or clear cell tumors of ovarian or endometrioid origin.

#### 914 Invasive Implants of Serous Borderline Ovarian Neoplasms – A Multiinstitutional Study

*E Silva, R Vang, R Kurman, R Soslow, J Prat, T Longacre.* MD Anderson Cancer Center, Houston, TX; Armed Forces Institute of Pathology, Washington, DC; The Johns-Hopkins Hospital, Baltimore, MD; Memorial Sloan-Kettering Cancer Center, New York, NY; Hospital de la Santa Crei Sant Pau Autonomous, University of Barcelona, Barcelona, Spain; Stanford University, Stanford, CA.

**Background:** Limited information exists in the literature about invasive implants of serous borderline ovarian neoplasms because these are rare lesions, different authors use different criteria and the studies have a short follow-up (FU).

**Design:** We reviewed H&E sections of invasive implants of 61 cases from 6 different centers. One to 29 slides (average 5) per case were reviewed. A minimum follow-up of 48 months (m) was obtained in all patients (Pts).

**Results:** The age of the patients (Pts) ranged from 20 to 79 years (median 50). Nine Pts had stage II disease, 51 stage III and 1 stage IV. The invasive implants were divided in three types: 1- Destructive invasion of underlying tissue by micropapillae (M) or groups of cells (GC) (DIM), 21 cases. 2- Destructive invasion of underlying tissue by glands (DIG), 10 cases. 3- Questionable destructive invasion and M or GC within clefts in omental septae or involving the surface of the tissue (QDI-M-GC) 30 cases. The FU of the Pts showed that 23 Pts (38%) are with no evidence of disease (NED) median FU 80 m, 10 Pts (16%) are alive with disease (AWD) median FU 70 m, and 28 Pts (46%) died of disease (DOD) median FU 74 m. The only clinical or pathologic feature associated with survival was stage. Nine Pts had stage II, 7 (78%) are NED, and 2 (22%) are AWD (1) or DOD (1). Fifty-one Pts had stage III, 16 (31%) are NED, and 35 (69%) are AWD (8) or DOD (27). FU of the Pts according to the type of implant:

	# of Pts	NED	AWD	DOD
DIM	21	5(24%)	2(9.5%)	14(66.5%)
DIG	10	5(50%)	3(30%)	2(20%)
QDI-M or G	30	13(43%)	5(17%)	2(40%)

**Conclusions:** 1- Invasive implants are aggressive lesions, 62% of Pts are AWD or DOD. 2- Invasive implants with destructive invasion are more aggressive than other types, 76% of Pts are AWD or DOD. 3- Invasive implants with destructive invasion by glands have not been previously recognized, 50% of these Pts are AWD or DOD. 4- Invasive implants by M or GC of cells in clefts without destructive invasion are aggressive lesions, 57% of the Pts are AWD or DOD. Based on the invasive features and the aggressive behavior, the possibility that invasive implants might represent low grade serous carcinoma needs to be considered.

#### 915 The Spectrum of Clear Cells in Endometrioid Neoplasms (Other Than Secretory Type)

*EG Silva, RH Young.* MD Anderson Cancer Center, Houston, TX; Massachusetts General Hospital, Boston, MA.

**Background:** Focal areas of clear cells (CCs) unrelated to secretory change are not unusual in endometrioid tumors but their spectrum has not been well documented, and often creates significant diagnostic problems.

**Design:** We reviewed 21 endometrioid tumors that had extensive areas of CCs. Additional studies included PAS, mucicarmine (MUC), and Alcian Blue (AB) in 10 cases, and immunocytochemistry (IMC) for Keratin cocktail, Keratin 7, Keratin 18, EMA, ER and LEUM1 in 6 cases. Eighteen cases were seen in consultation by the authors, reflecting the diagnostic difficulties posed.

**Results:** The age of the patients (pts) ranged from 27 to 88 (median 64) years. Most had an adnexal mass (13) or abdominal swelling (4), but 4 had as initial findings vaginal bleeding. One tumor involved the right Fallopian tube, one the endometrium, and 19 the ovary. One case was a cystadenofibroma, one was a borderline tumor and 19 were adenocarcinomas. Twelve pts had stage I, 4 stage III, 1 stage IV and 4 unstaged. All were treated with abdominal hysterectomy and salpingoophorectomy. In all cases at least one-third of the cells were CCs and three tumors were composed of only CCs. The cytoplasm of the CCs varied from foamy to empty and the nuclei had a variable location, basilar, central, and apical. Classic endometrioid foci were present in all cases; tubulocystic, solid, and papillary patterns of clear cell carcinoma were absent. Follow-

up was obtained for 11 pts. Five are free of disease at 12 to 84 months (m), median 27 m, 1 pt died of other causes at 84 m, 1 is alive with progressive disease at 24 m, and 4 died of disease at 17 to 52 m median 27 m. PAS, Muc and A B showed positive material in the lumen of glands in all 10 cases. PAS was focally positive in the cytoplasm in 5 cases. By IMC, all the stains were only focally positive in most cases but in some cases one or more of these immunohistochemicals were negative.

**Conclusions:** Endometrioid tumors can have extensive areas with CCs which range from foamy to empty and have a variable location of the nuclei. The distinction from clear cell carcinoma depends on awareness of this cellular aspect of some endometrioid tumors and a lack of the distinctive patterns of clear cell carcinoma; at this time, special studies, including IMC, do not aid. There are prognostic and therapeutic implications in the differentiation with clear cell carcinoma.

#### 916 HMB-45 Reactivity in Conventional Uterine Leiomyosarcomas

*KW Simpson, KS Carrick, J Albores-Saavedra.* Louisiana State University Health Sciences Center, Shreveport, LA; University of Texas Southwestern Medical Center, Dallas, TX.

**Background:** It has recently been reported that epithelioid leiomyosarcomas with clear cells of the uterus express HMB-45 in the clear cells (Am J Surg Pathol 2004;28:244-249). However, the expression of HMB-45 by conventional leiomyosarcomas has not been investigated. In the recent past, the former tumors have been included in the controversial group of perivascular epithelioid cell tumors (PEComas).

**Design:** We reviewed 25 cases of uterine leiomyosarcomas, which included 23 conventional and 2 myxoid variants. Epithelioid leiomyosarcomas were excluded from the study. Eleven leiomyosarcomas were interpreted as poorly differentiated and fourteen as well to moderately differentiated. Only one poorly differentiated leiomyosarcoma contained clusters of clear cells. Immunohistochemical stains for HMB-45 (Ventana, Tucson, AZ), smooth muscle actin (Cell Marque Corporation, Hot Springs, AK) and desmin (Ventana, Tucson, AZ) were performed in all cases. The percentage of cells that expressed HMB-45 was estimated in each case.

**Results:** The patients' ages ranged from 24 years to 66 years (mean 50 years). The tumors ranged in size from 2cm to 22cm. All of the tumors were positive for smooth muscle actin and desmin. Six poorly differentiated and three well differentiated leiomyosarcomas labeled with HMB-45. The HMB-45 staining was detected in 10% or less of the malignant cells especially those with large nuclei or those which contained more than one nucleus. The clusters of clear cells present in one of the poorly differentiated leiomyosarcomas were HMB-45 negative.

**Conclusions:** Our study indicates that 36% of conventional leiomyosarcomas focally express HMB-45. HMB-45 reactivity was more common in the poorly differentiated than in the well differentiated group of leiomyosarcomas. In light of our findings and of those recently reported in the literature, we believe that the term PEComa should not be used for uterine leiomyosarcomas with clear cells or for conventional leiomyosarcomas that stain positively with HMB-45.

#### 917 Extra-Axial Ependymomas Are Distinct from Central Nervous System Ependymomas

*RA Soslow, XJ Wei, K Park, M Rosenblum, J Woodruff, M Edgar.* Memorial Sloan-Kettering Cancer Center, New York, NY.

**Background:** Extra-axial ependymomas (EAEs) are very uncommon tumors that have a predilection for presenting in the pelvis, particularly in the broad ligament. Their morphologic features overlap with several more commonly occurring gynecologic tumors, including those with papillary and tubulo-glandular morphologic patterns.

**Design:** We describe the clinicopathologic features of 4 EAEs (1 of which has been reported previously) and undertook an immunohistochemical comparison between those and 11 central nervous system ependymomas (CNSEs), putting emphasis on markers of therapeutic and diagnostic importance.

**Results:** All EAE patients were women whose tumors exhibited mixtures of papillary and tubuloglandular morphology with minor components of solid areas and at least focal ependymal pseudorosettes. In comparison, CNSEs displayed more architectural uniformity.

Age	Site	EAE clinical summary	
		Original diagnosis	Follow up
13 yrs	Broad ligament	Serous neoplasm	AWD—multiple recurrences
24	Rectovag septum	Ependymoma	AWD—multiple recurrences
31	Presacral	Serous carcinoma	AWD—multiple recurrences
48	Ant mediastinum	Thymoma	NED

AWD: alive with disease; NED: no evidence of disease

All EAEs expressed GFAP. In addition, 4/4 expressed estrogen receptor (ER) strongly, 3/4 expressed progesterone receptor (PR) moderately-to-strongly and 1/4 expressed WT1. In contrast, only 2/11, 3/11 and 2/11 CNSEs expressed the same markers, mostly in a weak fashion.

**Conclusions:** The rarity of EAEs and their resemblance to serous tumors, in particular, have resulted in diagnostic difficulties. Clinical follow up information indicates that these are low grade malignant tumors prone to multiple recurrences over decades. The morphologic and immunophenotypic features suggest that EAEs and CNSEs likely differ in fundamental ways. ER and PR expression are characteristic of EAEs (but not of CNSEs), which could be exploited for therapeutic purposes.

#### 918 Mullerian Adenosarcomas: An Immunophenotypic Analysis of 35 Cases

*RA Soslow, A Ali, E Negron, I Linkov, M Asher, E Oliva.* Memorial Sloan-Kettering Cancer Center, New York, NY; Massachusetts General Hospital, Boston, MA.

**Background:** Mullerian adenosarcomas are rare mixed mesenchymal and epithelial neoplasms most commonly occurring in the uterus, where the mesenchymal component is responsible for their behavior. The differential diagnosis usually includes

adenofibroma, carcinosarcoma, embryonal rhabdomyosarcoma and endometrial stromal sarcoma, especially in small samples. The mesenchymal component of most adenocarcinomas morphologically resembles endometrial stromal sarcoma. The objective of this study was to delineate the immunophenotypic profile of these tumors.

**Design:** Representative sections from 35 Mullerian adenocarcinomas with sarcomatous overgrowth (n=7 [MA-SO]) and without (n=28 [MA]) were selected and immunostained for AE1/3 cytokeratin, CD34, desmin, smooth muscle actin (SMA), CD10, inhibin, ER, PR and androgen receptor (AR). 30 cases were uterine, 3 were pelvic, 1 was gastrointestinal and the origin of another was uncertain.

**Results:**

		Expression in mesenchymal compartment						Ki-67 mean, median (range)	
Desmin	SMA	CD 10	WT1	ER	PR	AR			
11/34	9/12	25/35	27/34	22/34	25/33	12/34	10%	12%	(<5-40%)

There was no significant expression for c-kit or inhibin. 3/12 cases expressed cytokeratin in the mesenchymal compartment and 8/34 expressed CD34, mostly in a focal and weak pattern. Desmin, CD10, WT1, PR and AR were found in both MA-SOs and MAs. Significant ER expression was encountered predominantly in MAs (without stromal overgrowth). Strong ER expression did not correlate with strong PR expression, but strong ER expression was associated with strong AR expression. The Ki-67 labeling index was highest in periglandular stromal cuffs where the index exceeded 50% in approximately one-quarter of cases and in MA-SOs. The Ki-67 labeling index was not tightly linked to mitotic rate. The epithelial compartment demonstrated expression for ER (24/32 cases) and PR (23/31 cases), but there was no significant expression of markers other than these and Ki-67.

**Conclusions:** In summary, the immunophenotype of most Mullerian adenocarcinomas resembled that of endometrial stromal sarcomas (ER, PR, WT1, CD10 positive, with variable muscle marker, AR and cytokeratin expression). The proliferative rate was variable and related to sarcomatous overgrowth, where significant ER expression was lacking.

**919 Routinely Assessed Morphologic Features Correlate with Microsatellite Instability Status (MSI) in Endometrial Cancer**

RA Soslow, D Black, A Hummer, J Boyd, J Shia. Memorial Sloan-Kettering Cancer Center, New York, NY.

**Background:** Microsatellite instability (MSI) has been shown to be important in the molecular pathogenesis of both sporadic and inherited endometrial carcinomas (ECs) of the endometrioid type. In a recent study of 473 endometrial cancers, we showed that MSI in EC was independently associated with endometrioid histologic subtype, lower stage disease, greater myometrial invasion, and a more favorable clinical outcome as compared to endometrial cancers without MSI. This suggests that the identification of MSI or any correlate thereof is clinically relevant. The aim of this study was to determine whether there are specific morphologic features that characterize microsatellite unstable ECs.

**Design:** We studied the morphologic features of 102 ECs with known MSI status. These included 50 MSI-high and 52 non-MSI-high ECs that were matched for age, race, stage, grade and histologic subtype (all Caucasian, all endometrioid). The following morphologic features were evaluated: density of peritumoral lymphocytes (PL), tumor infiltrating lymphocytes (TIL) and tumor infiltrating neutrophils; presence of atrophy, hyperplasia and endometrial polyp; metaplasia types, presence of necrosis and tumor architectural growth patterns; cytologic grade; myometrial invasion patterns and presence of lymphovascular invasion (LVI).

**Results:**

	Significant associations		
	MSI-high	non-MSI-high	p-value
TILs per 10 hpf (range)	94.5 (2-745)	60 (3-390)	0.002
Brisk PLs	54%	24%	0.004
Associated hyperplasia	56%	34%	0.03
Papillary architecture	17%	36%	0.04
Architectural heterogeneity	21%	6%	0.06

Tumors with greater than 37 TILs/10 hpf were at increased risk of being MSI-high (p=0.002). LVI was seen more commonly in non-MSI-high tumors (p=0.09). None of the other morphologic patterns approached statistical significance.

**Conclusions:** Compared to non-MSI-high tumors, MSI-high ECs are more likely to be associated with endometrial hyperplasia, more architecturally heterogeneous and more densely infiltrated by lymphocytes (both peritumoral and intratumoral). Analogous features are encountered in MSI-high colorectal cancers, suggesting a similar relationship between tumor phenotype and DNA mismatch repair abnormality. Awareness of morphological patterns associated with MSI will help pathologists identify this subset of ECs, which appear to have clinical/prognostic distinctions from non-MSI-high tumors.

**920 Tissue Microarray Analysis of Annexin I, Gelsolin, p53, and BRCA1 Supports the Two-Pathway Theory of Ovarian Serous Carcinoma**

P Soung, J Chan, D Seligson, J Berek, J Rao. UCLA Medical Center, Los Angeles, CA.

**Background:** Recently, data from clinical and molecular studies support the hypothesis that there are two types of ovarian serous carcinomas. Type I follows a slow progression from a borderline lesion, and Type II is highly aggressive, arising *de novo* from surface epithelium. The Type I carcinoma is usually associated with KRAS mutations whereas the Type II carcinoma is not (Kurman, *Int J Gynecol Pathol*, 2003). The goal of our study is to perform tissue microarray analysis on tumor suppressor proteins including Annexin I, Gelsolin, p53, and BRCA1 in an attempt to further characterize the molecular pathogenesis of Type I and Type II carcinomas. Annexin I and Gelsolin are novel tumor suppressor proteins associated with cytoskeletal actin remodeling, as identified by us and others.

**Design:** 35 cases of ovarian serous carcinoma (23 Type I and 12 Type II), 23 borderline serous tumors, 27 serous cystadenomas, and 64 normal fallopian tube

controls were retrieved from the archival files. Tissue cores from formalin-fixed, paraffin-embedded blocks (3 cores per block) were constructed into a tissue microarray of 0.6 mm cores. Immunohistochemical staining with monoclonal antibodies against Gelsolin, Annexin I, p53, and BRCA1 was performed on the tissue sections. For each marker, the maximum staining intensity (Max), the percent positive stain (Pos), and the product of both intensity and percent positivity (MaxPos) were analyzed.

**Results:** There was significantly decreased expression of actin remodeling proteins in borderline tumors and Type I carcinomas compared to normal controls and benign cystadenomas (49% and 59% decrease in MaxPos for Gelsolin and Annexin I, p<0.0001 for both). However, the expression was markedly increased for Gelsolin in Type II carcinomas compared to Type I carcinomas (48% increase in Max for Gelsolin, p=0.015, and 31% increase in Max for Annexin I, p=0.21). p53 showed gradual increased expression with progression to cancer, but the most significant increase of expression occurred in Type II carcinomas compared to Type I carcinomas (70% increase in MaxPos, p=0.025).

**Conclusions:** The finding of distinctive expression patterns of actin remodeling proteins and p53 in Type I and II carcinomas further supports the two pathway theory of ovarian serous carcinoma. Our findings may have significant impact in designing actin pathway specific targeting agents for ovarian cancer.

**921 Primary Adenocarcinoma (Other Than Clear Cell Type) of the Vagina: A Clinicopathologic Study of 31 Cases**

PN Staats, PB Clement, RH Young. Massachusetts General Hospital, Boston, MA; Vancouver General Hospital, Vancouver, BC, Canada.

**Background:** Vaginal adenocarcinoma is uncommon, representing 15% of vaginal carcinomas. Clear cell carcinoma, with its relation to vaginal adenosis and *in utero* exposure to diethylstilbestrol (DES), has been well documented. Other types of vaginal adenocarcinoma, in contrast, have received little attention, and the spectrum of cell types and frequencies of precursor lesions are not well established.

**Design:** Thirty-one primary vaginal adenocarcinomas were retrieved from our consultation files, clear cell carcinomas and metastatic disease being excluded.

**Results:** Patients ranged in age from 13 to 82 (mean 61) years. Of the cases for which detailed history could be retrieved, the most common presenting symptoms were vaginal bleeding or a mass on vaginal examination. The carcinomas were classified as: mucinous in 13 cases (enteric-type in 5 cases and mucinous unspecified in 8 cases); endometrioid in 12 cases; serous in 2 cases; and mesonephric in one case. Three cases were not classifiable, as they had a non-specific appearance. The unspecified mucinous cases frequently had an endocervical-like appearance. Endometriosis was identified in the background of eight of the endometrioid carcinomas, but not in any other subtypes. One endometrioid carcinoma arose in a patient with endometriosis and a history of unopposed estrogen use. Vaginal adenosis was present in two mucinous carcinomas, and there was a documented history of adenosis in one case of endometrioid carcinoma. Patient age did not vary between types, with the exception of the mesonephric carcinoma, which occurred in a 13-year-old.

**Conclusions:** Endometriosis appears to be the source of the majority of vaginal endometrioid carcinomas, but not other subtypes. Adenosis likely represents a precursor lesion for some other non-clear cell adenocarcinomas, but in the majority of cases, a precursor lesion is not identifiable. A diagnosis of vaginal adenocarcinoma should prompt careful exclusion of metastatic disease, particularly from elsewhere in the female genital tract. Some vaginal adenocarcinomas resemble usual-type endocervical adenocarcinoma and should be carefully distinguished from them by clinical evaluation. The diagnosis of enteric-type carcinoma should additionally prompt a search for metastasis or direct extension of an intestinal primary. The presence of a precursor lesion, either endometriosis or adenosis, should be documented, as this supports the diagnosis of primary cancer.

**922 The Significance of Neuroendocrine Differentiation in Non-Small Cell Undifferentiated Carcinoma of the Endometrium**

S Tarai, M Deavers, A Malpica, E Silva. MD Anderson Cancer Center, Houston, TX.

**Background:** Carcinomas with neuroendocrine (NE) differentiation have been associated with poor outcome in different organs. However, information regarding NE differentiation in endometrial non-small cell undifferentiated carcinoma is limited. The purpose of this study was to evaluate the presence and significance of NE differentiation in 46 of such cases.

**Design:** We studied 46 cases of endometrial non-small cell undifferentiated carcinomas diagnosed between 1988 and 2005. NE differentiation was studied by immunohistochemistry including synaptophysin, chromogranin and/or CD56. Any immunoreactivity for one or more markers was considered positive. Survival time was evaluated for all patients. Student's t-test was used for comparison of means.

**Results:** The patients' age range from 30 to 84 years (mean 55 years). Staging information was available for 38 patients, 18 had stage I, 3 stage II, 8 stage III and 9 stage IV disease. NE differentiation was present in 19/46 (41.3%) and absent in 27/46 (58.7%) cases. Only 4/19 cases with NE differentiation demonstrated immunoreactivity in >50% of the cells. The overall survival is demonstrated in table 1.

NE differentiation	DOD/AWD	NED	Total
Present	16 (84.21%)	3 (15.79%)	19
Absent	23 (85.2%)	4 (14.8%)	27
Total	39	7	46

DOD, died of disease; AWD, alive with disease; NED, no evidence of disease  
The survival time is demonstrated in table 2.

Survival (Months)	Table2. Survival time			
	NED, NE differentiation present	NED, NE differentiation absent	DOD/AWD, NE present	DOD/AWD, NE absent
Mean	22.33	13.67	12.50	6.83
Range	5-48	9-18	1-51	1-31
Standard Deviation	±22.68	±4.51	±12.87	±6.25

NED, no evidence of disease, DOD, died of disease; AWD, alive with disease  
 The difference in the mean survival of patients who died of disease or who were alive with disease with and without NE differentiation approaches a statistically significant value ( $p = 0.0748$ ).

**Conclusions:** 1- NE differentiation is common in non-small cell undifferentiated carcinoma of the endometrium. It was present in 41.3% of our cases. 2- In most cases, NE differentiation is focal (<50% of the cells). 3- There is no difference in overall survival in patients with or without NE differentiation. However, although the difference is not statically significant, it appears that patients with NE differentiation survived slightly longer than patients without NE differentiation.

**923 Clinicopathologic Comparison of Tris-Acryl Gelatin Microspheres (TGM) and Polyvinyl Alcohol Particles (PVA) Following Uterine Artery Embolization for Leiomyomas**

V Thonse, K Judson, HS Kim, R Vang. The Johns Hopkins Hospital, Baltimore, MD.

**Background:** Uterine artery embolization (UAE) has traditionally been performed with PVA. TGM (Embospheres) have been recently introduced as a successful embolization agent.

**Design:** 400 patients underwent UAE from the years 2000 to 2005, of which 333 patients were treated with TGM and 67 with PVA. Of patients who failed, slides of surgical specimens were available from 19 patients who were treated with TGM (n=13) or PVA (n=6). Specimens were evaluated histologically, and clinicopathologic features associated with TGM and PVA UAE were compared.

**Results:** The clinical failure rates were 4.2 % (TGM) and 8.96% (PVA) [p=0.12]. The mean time from embolization to surgery was 28.8 weeks for TGM and 82.4 weeks for PVA. TGM were pale, eosinophilic, had a folded appearance similar to colloid, and were associated with a mild lymphocytic inflammatory reaction. PVA were blue-gray, had fibrotic septae, and were associated with a moderate multinucleated giant cell inflammatory reaction. The mean sizes of the particles in tissue sections were 0.43 mm for TGM and 0.75 mm for PVA.

**Conclusions:** In our institution, UAE with PVA was associated with higher surgical reintervention than with TGM although this difference was not significant; however, TGM causes more tumors per patient to undergo infarction than PVA, and TGM results in a greater degree of infarction compared with PVA. TGM and PVA show some differences in patterns of microcystic degeneration in infarcted tumors, as well as anatomic distribution of particles. Qualitatively and quantitatively, TGM and PVA particles each have unique histologic appearances. A thorough understanding of the different clinicopathologic features associated with TGM and PVA UAE is important for recognizing the alterations that are produced in surgical specimens.

	Leiomyomas (mean values)			
	Size of largest leiomyoma per case	Percentage of leiomyoma(s) showing any amount of infarction per case	Percentage of total tumor volume showing infarction per case	Percentage of total infarcted tumor volume showing substantial microcystic change per case
PVA	6.5 cm	75%	47%	67%
TGM	5.8 cm	100%	87%	15%

	Mean Number Of Particles Per Case			
	Leiomyoma(s)	Myometrium	Cervix	Adnexae
PVA	3.0	3.0	0.3	0
TGM	32.9	12.4	1.5	8.2

**924 Population Based Epidemiology Complements Pathological Data in Gynecological Cancers**

A Tilara, DE Henson, A Schwartz, P Grimley, WF Anderson. The George Washington University, Washington, DC; Uniformed Services University of the Health Sciences, Bethesda, MD; NCI, Bethesda, MD.

**Background:** Graphical analysis of most epithelial cancers produces a linear slope when the logarithm of the age specific incidence rate is plotted against the logarithm of the age of diagnosis. We have used these log-log plots, known to epidemiologists since 1954, to compare the incidence of endometrioid ovarian carcinomas and uterine endometrial carcinomas to assess whether primary tumors with similar histopathologic features have similar incidence patterns.

**Design:** Data were obtained from NCI's SEER Program from 1973 - 2002. There were 5000 cases of ovarian endometrioid carcinoma and 67,636 cases of uterine endometrial carcinoma. We used ICD-O codes 8380 for ovarian endometrioid carcinoma, and 8380 and 8140 for uterine endometrial carcinomas. We also compared the rate pattern of endometrial stromal sarcoma (938 cases, codes 8930, 8931) with those of the ovarian and uterine carcinomas.

**Results:** Except for a transient increase in 1974-1976 for endometrial carcinomas, there has been no change from 1977 - 2002 in incidence of endometrial type carcinomas of the ovary or uterus. Endometrial carcinomas of the uterus (19.5 cases/100,000 women) were more common than endometrioid carcinomas of the ovary (1.5 cases/100,000 women) and endometrial stromal tumors in all age groups. In log-log plots, the rates for ovarian endometrioid, uterine endometrial, and endometrial stromal tumors increased in parallel until age 50, when rates for ovarian endometrioid carcinomas and endometrial

stromal tumors flattened, while rates for endometrial carcinomas of the uterus continued to rise linearly until age 70. Log-log plots of age specific incidence rates by histologic grade for uterine endometrial carcinomas revealed parallel patterns until age 70 at which time rates of low-grade tumors relative to high-grade tumors diminished.

**Conclusions:** Although uterine endometrial carcinomas are most common, the rate of tumor development until menopause is the same for all three tumors. The incidence of ovarian endometrioid carcinomas and endometrial stromal tumors plateau at age 50 suggesting that their etiology depends on endocrine activity. A flattening of the rate after age 50 suggests that age dependent postmenopausal cellular events are not operative in ovarian related endometrial and in uterine stromal tissues.

**925 Staining for p16 of Cervical Mesonephric Remnants and Hyperplasia: A Potential Diagnostic Pitfall**

AM Truskinovsky, EB Stelow, J Jessurun, SE Pambuccian. University of Minnesota, Minneapolis, MN; University of Virginia, Charlottesville, VA.

**Background:** Cervical mesonephric remnants are usually incidental findings in cone biopsies performed for squamous or glandular lesions but can sometimes mimic endocervical adenocarcinoma in-situ (AIS) or invasive adenocarcinoma (ADCA). While evaluating p16 immunostaining in the diagnosis of AIS we observed that the mesonephric hyperplasia underlying the AIS lesion stained for p16, potentially leading to a misdiagnosis of invasive ADCA. We have therefore assessed the frequency and pattern of p16 staining of mesonephric lesions of the cervix.

**Design:** Stains for p16INK4A (CMA811, Cell Marque), Ki67 (Ventana) and CD10 (Ventana) were performed on 16 cases (10 cone/LEEP and 6 hysterectomy specimens) showing mesonephric remnants (n=8) or hyperplasia (n=8) of the cervix from women aged 20-48 (mean 36). Three of these also showed AIS. A control group made of 118 cervical specimens (93 cervical biopsies, 17 LEEP/cone and 6 hysterectomy specimens) including 41 with squamous lesions (CINI-3) and 39 from women positive for high risk HPV on their preceding Pap test was also stained for p16 and Ki67. All control cases included normal endocervical glands and some showed glandular lesions such as cervical endometriosis (n=1) tubal metaplasia (n=3), and microglandular hyperplasia (n=5), AIS and ADCA (one each).

**Results:** Normal endocervical glands, microglandular hyperplasia, endometriosis and tubal metaplasia showed no or only weak focal staining of individual cells for p16 and Ki-67. In contrast, strong, diffuse staining was seen in all cases of AIS and ADCA. Mesonephric remnants and mesonephric hyperplasia showed moderate to strong diffuse cytoplasmic staining of 10%-100% of glands in 14/16 cases. Some of these glands had a striped appearance due to alternating stained and unstained cells. CD10 stained at least some of the mesonephric glands with a luminal pattern in all cases that were interpretable. Ki67 showed staining of only 1 to 5% of mesonephric gland nuclei, except in cases with associated AIS, in which up to 20% staining was present. In contrast, there was almost universal nuclear staining of AIS and ADCA glands.

**Conclusions:** Mesonephric remnants and hyperplasias may show diffuse and strong staining for p16 and may therefore represent potential pitfalls for the diagnosis of neoplastic glandular lesions. Concomitant staining for Ki-67 is useful to avoid misdiagnosis, since it shows only weak proliferative activity in the mesonephric glands.

**926 Pathogenetic Pathways in Ovarian Endometrioid Adenocarcinoma: A Molecular Study of 29 Cases**

J Turbina, C Sanchez, D Sarrjo, G Moreno, I Franceschetti, J Palacios, E Oliva. Massachusetts General Hospital, Boston, MA; CNIO, Madrid, Spain.

**Background:** In recent years, several new mechanisms have been proposed for the pathogenesis of ovarian carcinomas. It has been suggested that serous carcinoma follows a dualistic pathway with low-grade carcinomas arising from borderline tumors and high-grade carcinomas originating *de novo*. Similarly, our group has shown that based on their molecular profile endometrioid borderline tumors could present low-grade endometrioid carcinomas (Ov-EC). It is not clearly understood if low-grade Ov-EC is in turn related to high-grade Ov-EC, or if high-grade Ov-EC may also arise *de novo*. The aim of our study was to compare the molecular profile of grade 1, 2 and 3 Ov-ECs.

**Design:** Twenty nine Ov-ECs were selected including 10 grade 1 (G1), 11 grade 2 (G2), and 8 grade 3 (G3). Selected blocks were immunostained with  $\beta$ -catenin and p53, and microdissected, DNA extracted and amplified by PCR with primers for the exon 3 of  $\beta$ -catenin gene and codons 12 and 13 of KRAS. The length of BAT-26 and BAT-25 was analyzed to determine microsatellite instability (MSI).

**Results:** Patients with G1 Ov-EC ranged from 21-71 (mean 52) years, those with G2 tumors ranged from 43-66 (mean 56) years, and patients with G3 Ov-EC ranged from 41-67 (mean 57) years. Immunohistochemical analysis for  $\beta$ -catenin showed nuclear staining in 14 cases (7 in G1 group, 5 in G2 and 2 in G3 group), the rest showed membranous staining.  $\beta$ -catenin mutations were found in 3, all of which were G1. p53 overexpression was present in 6 cases (5 in G3 group and 1 in G2 group). KRAS mutation was seen in 4 cases (two G1 and two G2). MSI was detected in one G1 and one G2. Cases showing p53 mutation were negative for other markers. There was no overlapping expression of MSI,  $\beta$ -catenin or KRAS mutations.

**Conclusions:** It appears from our results that  $\beta$ -catenin mutations are strongly associated with low-grade Ov-EC. Furthermore, KRAS mutations and MSI were also present exclusively in low grade Ov-ECs, even though the number of positive cases was limited. On the other hand, p53 overexpression was exclusive of high-grade Ov-ECs. Based on these results, we suggest that there may be a dual pathogenetic pathway for Ov-ECs; a stepwise progression from borderline endometrioid tumors to low-grade and possibly to some high-grade Ov-ECs associated to  $\beta$ -catenin and KRAS mutations and MSI as opposed to *de novo* high-grade Ov-ECs associated with p53 mutations.

### 927 Expression of CK7 and CK20 in Ovarian Mucinous Tumors Arising in Association with Teratomas: A CK7+/CK20+ Subset Can Cause Confusion with Metastatic Lower Gastrointestinal (GI) Tract Mucinous Tumors

R Yang, AM Gown, C Zhao, TS Barry, BM Ronnett. The Johns Hopkins Hospital, Baltimore, MD; PhenoPath Laboratories, Seattle, WA; AFIP, Washington, DC.

**Background:** Most primary ovarian mucinous tumors are of surface epithelial-stromal origin and have a CK7+/CK20-variable immunoprofile that distinguishes them from most lower, but not upper, GI tract metastases. The immunoprofiles of those uncommon mucinous tumors of germ cell (teratomatous) origin have not been extensively evaluated to determine the utility of these markers for distinguishing these tumors from metastatic GI tract mucinous tumors.

**Design:** Immunohistochemical expression of CK7 and CK20 was assessed in 39 ovarian mucinous tumors associated with a teratoma. Staining in >5% of cells was considered positive.

**Results:** All tumors had gastrointestinal-type mucinous differentiation (with or without pseudomyxoma ovarii [PO]), with epithelium ranging from purely cystadenomatous, goblet cell carcinoid-like, or low-grade adenomatous (resembling atypical proliferative/borderline tumors [AP/BT]) to invasive carcinoma.

Tumor pattern	CK7+/ CK20-	CK7+/ CK20+	CK7-/ CK20+	CK7-/ CK20-
Cystadenoma-like without PO (n=15)	27%	27%	20%	27%
AP/BT-like without PO (n=8)	13%	88%	0%	0%
Cystadenoma-like with PO (n=7)	0%	0%	100%	0%
AP/BT-like with PO (n=4)	0%	0%	100%	0%
Invasive carcinoma with PO (n=4)	25%	50%	25%	0%
Goblet cell carcinoid-like with PO (n=1)	0%	0%	100%	0%

**Conclusions:** A subset of primary ovarian mucinous tumors of apparent germ cell origin has a CK7-/CK20+ immunoprofile, suggesting origin from lower GI tract type elements; when combined with morphologic features and scant teratomatous elements, this can lead to misclassification as a metastatic lower GI tract tumor. Those mucinous tumors having a CK7+/CK20-variable immunoprofile may be derived from upper GI tract type elements of the teratoma; other markers are required to distinguish them from metastatic upper GI tract tumors and molecular genetic analysis is required to exclude coexistent independent mucinous tumors of surface epithelial origin.

### 928 p16 Expression in Primary Ovarian Mucinous and Endometrioid Tumors and Metastatic Adenocarcinomas in the Ovary: Utility for Identification of Metastatic HPV-Related Endocervical Adenocarcinomas

R Yang, AM Gown, TS Barry, DT Wheeler, K Judson, BM Ronnett. The Johns Hopkins Hospital, Baltimore, MD; PhenoPath Laboratories, Seattle, WA; AFIP, Washington, DC.

**Background:** Diffuse moderate to strong p16 expression is characteristic of HPV-related endocervical adenocarcinomas (AC) which exhibit mucinous and/or endometrioid differentiation and can simulate primary ovarian tumors when metastatic to the ovary. The specificity of this expression pattern for distinguishing metastatic endocervical AC in the ovaries from primary ovarian tumors and other metastatic AC having mucinous and/or endometrioid-type or endometrioid-like differentiation has not been evaluated.

**Design:** Immunohistochemical expression of p16 was assessed in 132 ovarian tumors, including 53 primary ovarian tumors (atypical proliferative [borderline] tumors and invasive AC of mucinous and endometrioid types), 14 endocervical AC of known HPV status (12 HPV+, 2 HPV- minimal deviation type), and 65 other metastatic mucinous and endometrioid-like AC (origins: colorectum [29], pancreas [12], stomach [4], appendix [4], biliary tract [3] and unknown [13]). Expression was scored based on the percentage of moderately to strongly positive cells: 0, ≤ 5%; 1+, 6-25%; 2+, 26-50%; 3+, 51-75%; and 4+, 76-100%.

#### Results:

Tumor type	0	1+	2+	3+	4+
Ovarian atypical proliferative tumors (n=34)	29	3	2	0	0
Primary ovarian invasive AC (n=19)	10	4	4	1	0
Endocervix AC-HPV+ (n=12)	0	0	0	3	9
Endocervix AC-HPV- (n=2)	2	0	0	0	0
Colon AC (n=29)	13	11	0	3	1
Pancreas AC (n=12)	12	0	0	0	0
Stomach AC (n=4)	2	0	2	0	0
Appendix AC (n=4)	3	1	0	0	0
Biliary tract AC (n=3)	3	0	0	0	0
Unknown origin (n=13)	10	0	1	0	2

**Conclusions:** Diffuse (3+ to 4+) moderate to strong p16 expression has good sensitivity (100% for 3+ or 4+, 75% for 4+) and specificity (96% for 3+ or 4+, 99% for 4+) for identifying HPV-related endocervical AC metastatic to the ovary among the primary ovarian tumors and metastatic AC from other sites that are in the differential diagnosis of ovarian tumors having mucinous and/or endometrioid or endometrioid-like differentiation. P16 is useful as part of a panel of immunohistochemical markers for distinguishing primary ovarian tumors from metastases and when diffusely positive can suggest the cervix as a potential primary site for metastatic AC of unknown origin.

### 929 Ovarian Non-Small Cell Neuroendocrine Carcinoma: A Clinicopathologic and Immunohistochemical Study of 11 Cases

E Veras, EG Silva, MT Deavers, A Malpica. UT-Houston Medical School, Houston, TX; MD Anderson Cancer Center, Houston, TX.

**Background:** Non-small cell neuroendocrine carcinoma (NSCNC) of the ovary is a rare tumor (tu) that usually occurs in the background of a surface epithelial-stromal tu or teratoma. In this study, we present the clinicopathologic and immunohistochemical features of 11 such cases.

**Design:** Eleven cases of ovarian NSCNC were retrieved from the files of the Pathology Department at MDAnderson from a period of 15 years (yrs) (1990 – present). Macroscopic information was obtained from the pathology reports. H & E slides were reviewed in all cases. Immunohistochemical studies for CD56 (3 cases), synaptophysin (8 cases), and chromogranin (11 cases) were performed. Clinical information was retrieved from the patients' (pts') charts. Follow-up (F/U) was obtained in all cases. IRB approval was obtained prior to initiation of this study.

**Results:** Pts' age ranged from 22 to 63 yrs (mean, 46.7 yrs). The most common presenting symptom was abdominal pain (6), followed by ascites (2), vaginal bleeding, bloating, and pelvic mass (1 each). Grossly, tus were unilateral in 10 cases, and bilateral in 1 case; either cystic (6), solid/cystic (4), or solid (1), and ranged in size from 4 to 26 cms (mean, 14.8). The tus were associated with a mucinous neoplasm, either mucinous carcinoma (Ca) or LMP4 cases; mucinous/endometrioid Ca, 2 cases; endometrioid Ca, 2 cases, and mature teratoma, 2 cases. In a single case the tu was pure, although there was a teratoma in the contralateral ovary. NSCNC represented 10% to 90% (mean: 60%) of the tus. In all cases but one, the NSCNC was characterized by the presence of large or intermediate oval cells arranged in sheets, nests, or cords. In a single case there were also small cells. Mitoses were numerous. Immunohistochemical studies demonstrated CD56 positive in 3/3 cases, synaptophysin in 8/8 cases, and chromogranin in 8/11 cases. FIGO staging was known in 10 cases as follows: stage I, 3 cases; stage III, 3 cases; and stage IV, 4 cases. All pts received chemotherapy after surgery. After F/U, 4 pts DOD (at 2, 3, 9, 36 months), 2 pts were AWD (at 8 and 16 months), and 5 pts were NED (11 to 66 months).

**Conclusions:** NSCNC of the ovary is a rare tumor with an aggressive behavior, 7/11 (64%) of the pts present with high stage disease and 71% of these are AWD or DOD within an interval of 2 to 36 months after diagnosis.

### 930 Histological Findings of the Uterine Blood Vessels during the Early Postpartum Course

TH Wakasa, K Wakasa, N Obatake, Y Kubo. Osaka City University Graduate School of Medicine, Osaka, Japan.

**Background:** Histological changes in the uterine blood vessels during pregnancy are well known. To increase placental perfusion, mononuclear trophoblasts invade through the vessel wall, splaying apart and destroying muscular and elastic fibers. Then, the vessels become dilated markedly toward the second trimester of pregnancy. However, there have been few reports on involution of the uterine blood vessels during the postpartum period. In this study, we report the process of uterine vascular involution in the resected uterus.

**Design:** Twelve patients with severe cervical laceration and uterine rupture were included in this study. The interval between delivery and hysterectomy ranged from 30 minutes to 456 hours. The uterine specimens were stained with HE, EVG, CD34, α smooth muscle actin, oxytocin receptor, and laminin.

**Results:** Changes in the uterine blood vessels varied substantially based on the location of the vessels. In blood vessels on the serosal side, elastic fibers were hardly detected in the arcuate veins and slightly detected in the arcuate arteries at 0 hours after delivery. At 4 hours, the arteries became tortuous. In the veins, the eccentric thickening of the intima were observed. Elastic fibers were scarcely found in the veins at 5 hours after delivery. At 19 days postpartum, there were double or triple layered internal elastic membrane in the veins. At 60 days postpartum, florid elastic fibers were arranged radially in the venous wall. These elastic fibers will persist for many years. In the blood vessels on the endometrial side, there were many sinusoidal vessels devoid of the smooth muscle layer at 0 hours after delivery. Some of these sinusoidal vessels disappeared within 4 hours, and smooth muscle layers and elastic fibers developed in the remaining vessels, and such vessels then became ordinary veins. At 5 hours, sparse elastic fibers appeared in the arteries, and marked thickening of the intima was observed and it reached a maximum at 110 hours. At 60 days postpartum, the intima had thinned, and the arteries had become smooth and rounded. Regarding the oxytocin receptor, at 0 hours after delivery, only the myometrium was positive. At 5 hours after delivery, both the myometrium and smooth muscles of vascular wall were positive for oxytocin receptor.

**Conclusions:** Within 110hours after delivery, the uterine arteries on the endometrial side rapidly narrowed by developing increased intimal thickening and regenerating elastic fibers. Two months after delivery, the intimal thickening was reduced to normal.

### 931 Epigenetic Alteration of RASSF1a Distinguishes High Grade from Low Grade Ovarian Serous Carcinoma

L Wang, P Hui, W Liu, X Zhang, WR Hart, B Yang. Cleveland Clinic Foundation, Cleveland, OH; Yale University, New Haven, CT; Case Western Reserve University, Cleveland, OH.

**Background:** RASSF1a (Ras association domain family protein) is a Ras effector with pro-apoptotic function. Methylation of RASSF1A promoter is the mainsaty mechanism in silencing its function in variety of human malignancies. There are two histopathologic types of ovarian serous carcinoma with distinct morphology and clinical behavior. High grade ovarian serous carcinoma (HG-OSC) occurs de novo with frequent p53 mutations and dismal 5-year survival, while low grade papillary serous carcinoma (LG-OSC) has frequent Ras mutations, associates with papillary serous borderline tumor (SBT) and favorable prognosis. Epigenetic profiling between these two types of OCS has not yet been reported. We have studied the methylation profiles of RASSF1a and six other tumor suppressor genes in 52 cases of ovarian serous tumors.

**Design:** Fifty-two cases of primary ovarian serous tumors include 34 cases of HG-OSC, 12 cases of LG-OSC and 6 cases of SBT. Genomic DNA was extracted from formalin-fixed and paraffin-embedded tissues and was chemically converted by bisulfite treatment. Methylation of RASSF1a and six other genes (hMLH-1, p14, p16, SOCS-1, ER, and BRCA-1) was analyzed by methylation-specific PCR.

**Results:** Promoter methylation of RASSF1a was detected in 65% (22/34) of HG-OSC, but was seen only in 16% (2/12) of LG-OSC. Among HG-OSC group, methylation of

*RASSF1a* was mainly seen in those of early recurrence within 12 months (71%) than those of late recurrence after 36 months (38%). Methylation of *RASSF1a* was not seen in SBT (0/6). The difference in *RASSF1a* methylation frequency between two types of OSC is statistically significant ( $p=0.005$ ), but not significant between LG-OSC and SBT ( $p=0.53$ ). Among six other genes tested, there is no significant difference ( $p>0.05$ ) for methylation of *hMLH1*, *p14*, *p16*, *SOCS-1*, *ER*, and *BRCA-1* between HG-OSC and LG-OSC and between LG-OSC and SBT.

**Conclusions:** Our study indicates that distinct methylation profiles of *RASSF1a* exist between HG-OSC and LG-OSC. Our data further suggests that epigenetically silencing of *RASSF1a* not only may play an important role in development of HG-OSC, but may also confer the aggressive biological behavior of HG-OSC. Further study of the relationship between *RASSF1a* methylation and chemotherapeutic response in HG-OSC could provide better understanding of its frequent chemoresistance.

### 932 The Utility of Tumor Cell Necrosis in the Diagnosis of Primary Leiomyosarcoma of the Uterus: An Analysis of 77 Cases

WL Wang, RA Soslow, GF Zamoni, P Branton, D Nonaka, E Oliva. Massachusetts General Hospital, Boston, MA; Memorial Sloan Kettering Cancer Center, New York, NY; Università Cattolica, Rome, Italy; Inova Fairfax Hospital, Church Falls, VA.

**Background:** Leiomyosarcomas (Ut-LMSs) are the most common uterine sarcomas. Features diagnostic of Ut-LMS include two of the following: tumor cell necrosis (TCN), marked cytologic atypia, and greater than 10 mitoses per 10 high power fields (HPFs). However, TCN is not a common finding in these tumors and not infrequently it is difficult to distinguish infarct type necrosis (ITN) from TCN. The goal of this study was to evaluate the utility of TCN in the routine diagnosis of Ut-LMSs.

**Design:** The clinicopathologic features of 77 unselected Ut-LMSs cases from 4 hospitals were studied from 1974-2005. H and E slides were specifically analyzed to evaluate the diagnostic utility of TCN as defined by the Stanford group.

**Results:** The tumors occurred in patients from 45-83 (mean age=56) years of age. They ranged from 2 to 25 (mean 12) cm and most of them had one dominant mass with a tan-white to pink cut surface and visible necrosis. At least four tumors showed multinodular growth into the myometrium. Forty four tumors were predominantly spindle, 22 were predominantly epithelioid, 6 had a prominent myxoid component and 5 had equal spindle and epithelioid components. In the spindle group, clear-cut TCN was seen in 19 tumors, all had grade 2 or 3 atypia and all but one had greater than 10 mitoses/10 HPFs. Three spindle tumors showed minimal atypia and no TCN but they had 16, 32 and 77 mitoses /10 HPFs. Among the epithelioid tumors, 6 had TCN, all had high-grade atypia and greater than 10 mitoses/10 HPFs. Only 1/6 myxoid Ut-LMSs had TCN but also displayed high-grade atypia and greater than 10 mitoses/10HPFs. Degenerated malignant cells were present in TCN but they were also seen in the surrounding viable areas. Infarct type necrosis (ITN) was seen in 47 spindle, 12 epithelioid, 5 myxoid, and 3 mixed Ut-LMSs. In 18 tumors, the mummified tumor cells were associated with a variable acute inflammatory infiltrate. All cases with TCN also had ITN areas and in sixteen cases TCN and ITN areas appeared to merge with each other.

**Conclusions:** Tumor cell necrosis, when present, typically coexists with cytologic atypia and greater than 10 mitoses/10 HPFs. Thus, it appears that TCN is not essential to establish a diagnosis of Ut-LMS in the vast majority of cases.

### 933 Different Usage of the Promoters Responds for IGF2 over Expression in Human Uterine Leiomyomas

JJ Wei. New York University, New York, NY.

**Background:** Uterine leiomyomata (ULM) are most common neoplasms in reproductive age women. In addition to the sex steroid hormones, many local growth factors contribute to the rapid tumor growth. Among them, IGF2 seems to be especially critical, as it is the only growth factor constantly up regulated in human ULM. It has been demonstrated that maternally imprinted IGF2 maintains imprinting (MOI) in all ULM. We hypothesized that the different usage of 4 promoters may be responsible for over expression of IGF2 in ULM.

**Design:** Twenty hysterectomies with ULM were selected, all of which were from menopause women. Tissues from large (>10cm), small (<2cm) ULM and matched myometrium were collected from each case. Total RNAs were prepared from fresh frozen tissues. Primers from 4 alternating splicing first exons were designed and IGF2 isoforms were amplified by semiquantitative multiplex RT-PCR. The abundance of each transcript was normalized by internal control G3PDH with the aid of density photometry. The levels of IGF2 gene products were further examined by immunohistochemistry from 180 ULM and matched myometrium with the aid of tissue microarray.

**Results:** Up regulation of IGF2 mRNA was identified in 90% (18/20) of ULM. There were no significant differences in total IGF2 mRNA between large and small ULM. Of 20 cases, ten cases were selected for further analysis for different usage of IGF2 promoters. IGF2 transcripts from 4 promoters were detectable in all ULM. The level of IGF2 transcripts from promoter P1 was moderately expressed in all ULM, including large and small ULM, but was minimal or not detectable in the matched myometrium. Differential expression of IGF2 mRNA from promoters P2, P3 and P4 were also identified between ULM and matched myometrium. The level of up regulations from IGF2 P2, P3 and P4 in ULM were much smaller than that from IGF2 P1. The levels of IGF2 gene products were examined 180 patients with ULM and its association with different age groups, menstrual cycles and tumor sizes were analyzed. The levels of IGF2 up regulation were more prominent in premenopausal women, peak in lutein phase and larger tumor sizes.

**Conclusions:** Over expression of IGF2 mRNA and its gene products is constantly present in most ULM. Up regulation of IGF2 is largely contributed by a high usage of IGF2 promoter P1. Up regulation of IGF2 is strongly associated with the sex steroid hormone status and tumor sizes.

### 934 Stromal Signatures in Ovarian Serous Tumors of Low Malignant Potential and Serous Carcinomas

RB West, CB Gilks, M van de Rijn, TA Longacre. Stanford University Medical Center, Stanford, CA; British Columbia Cancer Agency, Vancouver, BC, Canada.

**Background:** Ovarian serous carcinomas (S-Ca) are distinguished from serous tumors of low malignant potential (S-LMP) by the presence of destructive stromal invasion. To evaluate the epithelial-stromal interactions in these two biologically distinct tumors, we examined the gene expression profiles of a series of S-Ca and S-LMP for possible differences in stromal expression patterns using a previously identified gene set derived from solitary fibrous tumor (SFT) and desmoid-type fibromatosis (DTF) gene expression profiles. This gene set was chosen because it previously defined two groups of breast carcinomas with significant differences in overall survival (RBW & MVDR).

**Design:** We examined a previously published DNA array data set of 23 ovarian S-LMP and S-Ca on 43,000 spot microarrays. This data set was analyzed with the previously reported gene set of SFT and DTF comprising 786 gene spots.

**Results:** Hierarchical clustering of the DNA microarray gene expression data from 10 cases of S-LMP and 13 cases of S-Ca demonstrated high levels of expression of a gene cluster highly enriched for genes that are found in DTF in the majority of S-LMP (7 of 10). In contrast, only one of 13 S-Ca demonstrates this gene expression pattern.

**Conclusions:** We have identified a stromal gene expression pattern that is present in a majority of S-LMP and nearly absent in S-Ca. This pattern of gene expression, previously identified in DTF, has also been shown to correlate with a favorable prognosis in breast carcinoma. The presence this stromal signature in S-LMP suggests that epithelial-stromal interactions in S-LMP are fundamentally different from those of S-Ca and have similarities to those seen in good prognosis invasive carcinomas.

### 935 Overexpression of S100A4 Is Associated with Adverse Prognostic Indicators for Endometrial Cancer

R Xie, D Loose, G Shipley, R Broaddus. MD Anderson Cancer Center, Houston, TX; UT Houston Medical School, Houston, TX.

**Background:** Advanced endometrial cancer is essentially incurable using standard chemotherapy, hormonal therapy, and radiation therapy paradigms. Molecular markers associated with the more invasive endometrial cancers can potentially provide for the development of novel, targeted therapies and clinically useful prognostic markers.

**Design:** To identify candidate biomarkers of invasiveness, a screening cDNA microarray analysis was performed using RNA from 5 non-invasive and 5 deeply invasive grade 2 endometrioid adenocarcinomas. Microarray results were verified using qRT-PCR analysis of a larger, separate set of endometrial cancers (n=108), including endometrioid tumors, UPSC, and MMMT. Immunohistochemistry to confirm protein expression was performed. Gene expression was analyzed in four different endometrial cancer cell lines that we have characterized for *in vitro* invasiveness in a modified Matrigel assay.

**Results:** The cDNA microarray screen indicated that several members of the S100 gene family were increased in the invasive tumors compared to the non-invasive tumors. Specific qRT-PCR assays were designed for S100A2, S100A4, S100A6, S100A10, and S100A11, and these genes were analyzed in a larger set of endometrial cancers. Only S100A4 was found to be significantly associated with clinicopathological indicators of endometrial cancer aggressiveness, including high endometrioid tumor grade, non-endometrioid histology, deep myometrial invasion, lymphatic/vascular invasion, and extra-uterine metastasis. S100A4 expression was independent of tumor estrogen receptor or progesterone receptor status. IHC confirmed strong expression of S100A4 in the endometrioid grade 3 tumors, UPSC, and MMMT. S100A4 RNA and protein expression was high in the HEC-1A endometrial cancer cell line, the most invasive cell line in the *in vitro* Matrigel assay.

**Conclusions:** We have identified S100A4 as a unique molecular marker associated with endometrial cancer invasiveness. The S100 gene family is composed of about 20 members, a number of which have been associated with other cancer types. These genes encode calcium binding proteins, but their exact role in tumor invasion and metastasis is unknown. Quantitative analysis of S100A4 in endometrial biopsies can potentially provide prognostic information that can aid in surgery planning. Furthermore, S100A4 may provide a novel molecular target for the directed therapy of advanced endometrial cancer.

### 936 S100P Is a Novel Progesterone-Induced Gene and a Candidate Tumor Suppressor Gene in the Endometrium

R Xie, S Xie, D Loose, J Richer, A Malpica, K Lu, R Broaddus. MD Anderson Cancer Center, Houston, TX; UT Houston Medical School, Houston, TX; University of Colorado Health Science Center, Denver, CO.

**Background:** Identification of genes induced by hormones gives clues to the molecular mechanisms of action of their growth regulation, which is important for hormone-dependent cancers such as cancers of the prostate, breast, and uterus. A large number of estrogen-induced genes have been characterized, but there are relatively few progesterone-induced genes described. Because progesterone inhibits endometrial proliferation, genes induced by progesterone may be possible tumor suppressor genes in endometrial cancer. We characterized the expression of S100P, a gene encoding a calcium binding protein, which was previously shown to be up-regulated by progesterone treatment of breast cancer cell lines *in vitro*.

**Design:** S100P expression was measured quantitatively using qRT-PCR in benign endometrium (n=18) that was microscopically classified as proliferative, early secretory, or mid-late secretory phase. Expression was also characterized in baseline and 3 month post-treatment endometrial biopsies from premenopausal women with HNPCC (n=10) taking Depo-Provera for the chemoprevention of endometrial cancer. Then, expression of S100P was quantified in endometrioid and non-endometrioid endometrial cancers (n=96).

**Results:** S100P expression was extremely low in proliferative phase and early secretory phase endometrium. In mid-late secretory phase, the phase associated with the highest levels of circulating progesterone, S100P was significantly induced about 5-fold. A similar induction of S100P was observed 3 months post-treatment in women taking Depo-Provera. For all grades of endometrioid adenocarcinoma, UPSC, and MMMT, the expression of S100P was very low, comparable to that of proliferative and early secretory endometrium.

**Conclusions:** These results suggest that S100P is a progesterone-induced gene in the endometrium. Because expression was low in all histotypes of endometrial cancer, S100P may act as a tumor suppressor gene in the uterus. Overexpression of S100P as an oncogene has been associated with several cancer types, especially pancreatic cancer. However, S100P has also been recently described as an inducer of differentiation for leukemia. Therefore, S100P may have dual roles, oncogenic and tumor suppressor, depending on the tissue of cancer origin.

### 937 Claudins-3 and 4 and Matrix Metalloproteinases 7 and 9 Expression in the Histologic Subtypes of Endometrial Carcinoma

*J-J Xiong, CE Sheehan, JS Ross.* Albany Medical College, Albany, NY.

**Background:** Claudin proteins have been identified as major structural components of tight junctions. Abnormal claudin expression has not been studied in endometrial carcinomas. MMPs are associated with tumor invasion and metastasis and have been linked to progression in endometrial cancer. In this study, we correlated claudin-3 and 4 protein expression with histological subtypes, MMP expression and clinicopathologic variables in endometrial carcinoma.

**Design:** Formalin-fixed, paraffin-embedded tissue sections from 134 endometrial carcinoma, including 104 endometrioid carcinoma (EC), 17 uterine papillary serous carcinoma (PSC) and 13 malignant mesoderm mixed tumor (MMMT), were immunostained by automated methods (Xmatrix/BioGenex Laboratories, Inc. San Ramon, CA and ES/Ventana Medical System, Tucson, AZ) using rabbit anti-human claudin-3 and mouse anti-human claudin-4 antibodies (Zymed Laboratories, San Francisco, CA), mouse anti-human antibodies against MMP-7 and MMP-9 (NeoMarkers, Fremont, CA). Immunoreactivity of claudins and MMPs was semiquantitatively scored based on staining intensity and distribution.

**Results:** Claudin-3 and claudin-4 expression was 77% (80/104) and 53% (55/104) in EC, 82% (14/17) and 41% (7/17) in PSC, and 46% (6/13) and 46% (6/13) in MMMTs, respectively. Overexpression of claudin-3 inversely correlated with tumor grade in endometrioid carcinoma ( $p < 0.01$ ), and correlated with histological subtypes of endometrial carcinoma ( $p < 0.05$ ). Claudin-4 expression significantly correlated with the depth of myometrial invasion ( $p < 0.001$ ). Significant co-expressions were identified between claudin-3 and claudin-4 ( $p < 0.01$ ), claudin-4 and MMP-7 ( $p < 0.005$ ), claudin-4 and MMP-9 ( $p = 0.06$ ) and MMP-7 and MMP-9 ( $p < 0.05$ ). Overexpression of MMP-7 and MMP-9 correlated with depth of myometrial invasion ( $p < 0.001$  and  $p = 0.008$ ), tumor grade ( $p < 0.003$  and  $p < 0.001$ ) and stage ( $p < 0.005$  and  $p < 0.005$ ) in EC.

**Conclusions:** Loss of claudin-3 expression correlates with increasing grade of EC and is lowest in MMMTs. Increased expression of Claudin-4 correlated with MMP-7 and MMP-9 overexpression with all 3 markers associated with increasing depth of myometrial invasion. The claudin and MMP proteins may be co-expressed, but appear to play different roles in tumor differentiation and invasion in endometrial carcinoma.

### 938 Evaluation of an Automated Enhanced Sensitivity HPV In Situ Hybridization Assay in Cervical and Vulvar Squamous Dysplasia (CIN/VIN)

*B Yang, N Prescott, JD Pettay, R Arciaga, RR Tubbs.* Cleveland Clinic Foundation, Cleveland, OH.

**Background:** CIN/VIN is the most common female genital tract neoplasm closely associated with HPV infection. Although in situ hybridization (ISH) in tissue sections was the earliest HPV detection system developed, suboptimal sensitivity of ISH has led to the preferred use of PCR by some investigators. However, recent studies have suggested problems with false positive PCR results, and PCR lacks morphologic correlation. A morphologically based ISH detection system, if improved in sensitivity and specificity, may play a role in the evaluation of CIN/VIN.

**Design:** We evaluated an enhanced sensitivity third generation HPV ISH detection system (Ventana) and compared assay performance to PCR using family specific HPV primer pairs and sequence confirmation, and p16 immunohistochemistry (IHC), in 8 cases normal (31), immature squamous metaplasia (4), CIN I (10), CIN II (13), CIN III (23), and VIN III (6).

**Results:** HPV was detected in 100% (36/36) of CIN2/CIN3 cases by ISH and 84% (27/32) by PCR. Four cases failed PCR due to insufficient DNA. All 36 CIN II/CIN III lesions with positive ISH-HPV displayed a diffuse cytoplasmic and nuclear IHC staining pattern for p16. The pattern of HPV distribution by ISH was very similar to p16 IHC staining. Among CIN I lesions, HPV was detected by ISH in 4 cases and in 7 cases by PCR. All 4 CIN I lesions with positive ISH-HPV and 5/7 CIN I lesions with positive PCR-HPV had synchronous CIN2/CIN3 lesions. Focal and patchy cytoplasmic p16 staining was also seen in the CIN I lesions with positive ISH-HPV. All 35 normal cervix with or without immature squamous metaplasia demonstrated negative ISH-HPV. However, 17% (6/35) of normal cervix had positive PCR-HPV. All 6 VIN III lesions were positive for ISH-HPV, PCR-HPV and p16 immunostain.

**Conclusions:** The third generation ISH-HPV detection system has high sensitivity in the detection of oncogenic HPV in tissue; 2) The overlapping stain distribution areas shared by ISH-HPV and p16 IHC staining reflects ISH-HPV high specificity; 3) ISH-HPV has fewer false-positive results as compared with PCR-HPV in normal cervical mucosa. Our preliminary study suggests this enhanced sensitivity ISH-HPV system is sensitive and specific for the detection of HPV in cervical and vulvar lesions. By integrating morphology and molecular characterization, ISH can be a useful ancillary assay in the clinical detection of HPV-associated lesions.

### 939 Expression of Hypoxia-Related Markers, GLUT-1 and HIF-1 $\alpha$ , in the Ovarian Tumors: Association with Histology and Tumor Grade

*M Yasuda, M Miyazawa, T Minematsu, K Hirabayashi, H Kajiwara, T Iida, YR Osamura.* Tokai University School of Medicine, Isehara, Kanagawa, Japan.

**Background:** Hypoxia induces hypoxia-inducible factor-1 (HIF-1)  $\alpha$  which upregulates transcription of various hypoxia-resistant proteins. Glucose transporter-1 (GLUT-1) is such a protein, playing a key role in a facilitative transportation of glucose. GLUT-1 expression is usually strengthened according to malignant transformation. In this study, we attempted to clarify the relationship between [GLUT-1 and HIF-1 expression] and [histology and tumor grade] in the ovarian tumors.

**Design:** 1) Diseases: 125 cases with ovarian epithelial tumor as follows: benign, serous(se)=12 cases, mucinous(muc)=16 cases; borderline, se=10 cases, muc=21 cases; malignant, se=19 cases, muc=16 cases, endometrioid(end)=13 cases, clear=18 cases. 2) Immunohistochemistry: Using indirect peroxidase method, routinely-processed sections were incubated with GLUT-1 antibody (DAKO) and HIF-1  $\alpha$  antibody (Santa Cruz). The expressions were semi-quantitatively evaluated as follows: - negative; +, <10%; 2+, 10-50%; 3+, 50%<. 3) Western blotting: Membranes containing total proteins were incubated overnight at 4 $^{\circ}$  with GLUT-1 antibody and HIF-1  $\alpha$  antibody. 4) Real-time PCR: GLUT-1 and HIF-1  $\alpha$  expression levels were assessed with ABI prism 7700 system (Applied Biosystems) using Assay-on-Demand primers and probe sets Hs00197884ml and Hs00153153ml.

**Results:** 1) According to up-grading, expressions of GLUT-1 and HIF-1  $\alpha$  tended to be enhanced: GLUT-1(3+), benign, se=14%, muc=0%, borderline, se=30%, muc=0%, malignant, se=76%, muc=37%; HIF-1  $\alpha$ (3+), benign, se=0%, muc=1%, borderline, se=10%, muc=5%, malignant, se=53%, muc=19%. 2) Among malignant tumors, GLUT-1 expression was relatively weak in mucinous tumors: 3+, se=76%, muc=37%, clear=79%, end=74%, and HIF-1  $\alpha$  expression was most distinct in serous tumors: se=53%, muc=19%, clear=37%, end=38%. 4) These immunohistochemical expression profiles were consistent with results of Western blotting and Real-time PCR.

**Conclusions:** GLUT-1 expression and HIF-1  $\alpha$  expression corresponded to each other and reflected biological behaviors of ovarian epithelial tumors. Thus, both markers were expected as a prognostic indicator. However, these expressions were considered to vary among different histological types. Mucinous tumors may be characterized by relatively lower expression of these markers.

### 940 $\beta$ -Catenin Is a Highly Sensitive and Specific Marker for the Detection of Endometriosis: An Immunohistochemistry Study

*H Yaziji, A Renshaw, D Rubin, R Shah, N Cartagena, E Gould.* Baptist Hospital of Miami, Miami, FL.

**Background:**  $\beta$ -catenin, a member of the catenin family, is an adhesion molecule normally present in the sub-plasmalemmal cell membrane. It is abnormally transferred to the nuclei when the adenomatous polyposis coli pathway, on which it depends, is altered. Abnormal  $\beta$ -catenin expression is documented in fibromatosis, intestinal polyps and endometrial carcinoma. The diagnosis of endometriosis is usually straightforward. However, it may be difficult to distinguish between endometriosis and other entities when the epithelial component is scarce. CD10, commonly used for that purpose, is not highly sensitive nor specific. There is currently no other marker that helps support the diagnosis of endometriosis.

**Design:** This study aimed at: (a) determining whether  $\beta$ -catenin can identify normal endometrial stroma, and (b) validating the potential utility of  $\beta$ -catenin in identifying the stroma in endometriosis. In addition to 10 cases of normal endometrial tissue, we tested 35 cases of endometriosis using  $\beta$ -catenin antibody (clone 14, Transduction Labs) via immunohistochemistry. 19 cases of fibromatosis were used as positive controls for the nuclear signal, and internal vascular endothelia were used as positive controls for the membranous signal.

**Results:** 32 out of 35 cases of endometriosis (91.4%) showed co-expression of  $\beta$ -catenin on both the glands (membranous pattern) and stroma (either nuclear or membranous pattern). In the remaining 3 cases,  $\beta$ -catenin's expression was only focal. The stroma in 4 out of 10 cases of normal endometrium was detected by  $\beta$ -catenin, showing either a membranous or nuclear signal. In only 3 cases, the signal distribution was very focal. All cases of fibromatosis expectedly expressed  $\beta$ -catenin in a nuclear fashion. None of the internal negative controls tissues (ovarian stroma, fallopian tube stroma, myometrium, appendix wall, peritoneal soft tissue, abdominal wall muscle) showed any significant levels of  $\beta$ -catenin expression.

**Conclusions:** This study shows that  $\beta$ -catenin can successfully detect the glandular and stromal components of endometriosis, with a striking contrast to surrounding (negative control) tissue, resulting in a very 'clean' background.  $\beta$ -catenin, thus, has the potential of identifying these lesions in morphologically equivocal situations. The mechanisms of abnormal expression of  $\beta$ -catenin on the stroma of endometriosis is unclear, and warrants further investigations.

### 941 Diffuse p16 Expression Distinguishes Uterine Serous Carcinoma (USC) from Uterine Endometrioid Carcinoma of Endometrial Origin (UEC) but Not HPV-Related Endocervical Adenocarcinoma (ECC)

*A Yemelyanova, H Ji, BM Ronnett.* Johns Hopkins Hospital, Baltimore, MD.

**Background:** USC typically has a characteristic morphology (papillary architecture, high-grade nuclei) and immunoprofile (diffuse strong p53 expression, loss of hormone receptor expression) that distinguishes it from most UECs. However, pure glandular variants of USC can simulate FIGO grade 2 UEC and some USCs lack p53 expression and retain hormone receptor expression, making classification difficult. P16 expression patterns distinguish UEC (patchy) from HPV-related ECC (diffuse) but utility for distinction of USC from both UEC and ECC has not been evaluated.

**Design:** Immunohistochemical expression of p16 was evaluated in 7 typical USCs and compared to expression in 24 typical UECs of endometrial origin (20 FIGO grade



1, 3 FIGO grade 2, 1 FIGO grade 3) and 14 HPV-positive ECCs. All tumors were from hysterectomy specimens.

**Results:** All USCs demonstrated diffuse, moderate to strong p16 expression, with percentage of positive tumor cells ranging from 90-100% (mean/median, 96%/100%). In contrast, UECs exhibited less diffuse and less intense expression, with percent of positive tumor cells ranging from 5-70% (mean/median 36%/30%; staining intensity ranging from weak to strong). All ECCs exhibited moderate to strong p16 expression, with percentage of positive tumor cells ranging from 90-100% (mean/median, 96%/100%).

**Conclusions:** USC is characterized by diffuse, strong p16 expression which is distinct from the patchy pattern of expression seen in UEC. P16 can serve as an additional diagnostic marker of USC and can be added to an immunohistochemical panel including p53, Ki-67, ER, and PR for distinction of USC from UEC, particularly those USCs lacking p53 expression (those with p53 mutations leading to lack of immunoreactive p53 protein) and those retaining hormone receptor expression. Both USCs and HPV-related ECCs share diffuse expression of p16, precluding use of this single marker for their distinction.

#### 942 A Proposed Classification of Invasive Patterns in Vulvar Squamous Carcinoma and Their Influence on the Depth of Tumor Invasion and Disease Recurrence

*BJ Yoder, NA Massoll, EJ Wilkinson.* University of Florida, Gainesville, FL.

**Background:** While the importance of tumor depth of invasion has been established, the relationship of different patterns of invasion and multicentricity (more than one focus of invasion in a solitary lesion) to the depth of invasion, disease recurrence, and lymph node metastasis remain unknown.

**Design:** In this pilot study, 17 stage 1A and 15 stage 1B cases of vulvar squamous cell carcinoma were reviewed and the depth of invasion, horizontal spread, number of invasive foci, and pattern of invasion was recorded and correlated with clinical outcome.

**Results:** The 32 patients had a mean of 70 months follow up. Of the 17 stage 1A tumors, 14 (82%) had multicentric invasion, compared to 14/15 (93%) of the stage 1B tumors. Four histologic patterns of invasion were reproducibly identified. Pushing (P) lesions have broad, smooth fronts of invasion along the tumor-dermal interface. Finger-like (F) lesions show a finger-like pattern of invasion with bands of tumor attached to the tumor mass and within the dermis. Small group (G) lesions are similar to F lesions but with small groups of neoplastic cells detached from the tumor surface and infiltrating into the dermis. Single cell (S) lesions, consists of sharply angulated foci of invasion with single tumor cells along the tumor-dermal interface. Using these criteria, 7 cases were classified as P, 12 as F, 10 as G, and 3 as S. There were no lymph node metastases in this series. Nine of the 10 recurrences were stage 1B, 5 F patterns, 2 G patterns, and 2 S patterns. Six of the 7 P patterns were stage 1A and 3 of 3 S patterns were stage 1B. The mean number of invasive foci per tumor was 5.0, which did not differ between patients with recurrence, and those without recurrence ( $p = 0.473$ ). All 10 recurrent cases had two or more foci of invasion. Tumors with greater than one focus of invasion and finger-like patterns of invasion, while showing a trend towards decreased disease free survival, were not statistically different from tumors with a single focus of invasion on Kaplan-Meier survival analysis ( $p = 0.19$ ).

**Conclusions:** Multicentric invasive foci are relatively common in stage 1A and 1B vulvar squamous cell carcinoma. While no statistical significance was achieved, a lesion with a finger-like pattern of invasion and multiple foci of invasion might correlate with disease recurrence. How the disease pattern of invasion relates to the depth of invasion and multifocality remains poorly understood. Further study with increased case numbers is warranted.

#### 943 Does Micropapillarity in Ovarian Serous Borderline Tumors Represent a Transition between Typical Ovarian Serous Borderline Tumors and Low Grade Serous Carcinoma? Finding Answers Using the Level of Selenium-Binding Protein Expression in 64 Ovarian Tumors

*C Zhang, YE Wang, P Zhang, F Liu, CJ Sung, MR Quddus, MM Steinhoff, WD Lawrence.* Women & Infants Hospital of Rhode Island, Providence, RI.

**Background:** Micropapillary serous borderline tumors of the ovary (M-SBOT) are defined as serous borderline tumors (SBOT) exhibiting at least one 5-mm focus of micropapillary or cribriform growth. Clinical studies indicate that M-SBOT, compared with the typical SBOT, is more frequently associated with bilaterality, surface ovarian involvement, advanced stage, invasive implants, and recurrence. It is believed that M-SBOT may represent a transition between ordinary SBOT and a low-grade invasive serous carcinoma (LGSC). The significance of SBOTs showing smaller foci of micropapillary morphology (m-SBOT) is not well known. Also, little information is available concerning the molecular differences among these lesions. Our previous work has shown a significantly lower expression of SBP in ovarian serous carcinoma than in the serous epithelia of benign fallopian tubes. In this study, we examined the expressions of SBP in SBOT, M-SBOT, m-SBOT, and LGSC of the ovary.

**Design:** We studied 25 cases of SBOT, 10 cases of M-SBOT, 16 cases of m-SBOT and 13 cases of LGSC. Immunohistochemistry was performed on paraffin sections using a monoclonal antibody against human SBP. The intranuclear and cytoplasmic immunostains were scored using a 4-point scale (0-3+) system, based on the number of cells stained and the intensity of the staining. The differences in scores among various lesions were analyzed by Kruskal-Wallis and the post hoc test.

**Results:** SBOT showed stronger SBP immunopositivity in the nuclei (3+) than in the cytoplasm (2+). Compared to SBOT, the micropapillary foci of M-SBOT ( $p < 0.001$ ) and m-SBOT ( $p < 0.001$ ) exhibited significantly lower levels of both nuclear and cytoplasmic stainings. No difference, however, was found in the SBP stainings between the micropapillary foci in M-SBOT and m-SBOT. LGSC showed a significantly lower staining than either SBOT ( $p < 0.001$ ), M-SBOT ( $p < 0.001$ ), or m-SBOT ( $p < 0.001$ ).

**Conclusions:** The finding that the expression of SBP in M-SBOT is lower than in SBOT but higher than in LGSC provides molecular evidence supporting the role of M-SBOT as an overt transition between SBOT and LGSC. The similarity of SBP expression between the micropapillary foci in m-SBOT and in the more typical M-SBOT may support m-SBOT as an early event in the histogenesis of micropapillary SBOT.

#### 944 DNA Methylation of Tumor Suppressor Genes Associates with Chemoresistance and Early Recurrence in Patients with Ovarian Serous Carcinoma

*X Zhang, L Wang, A Green, B Yang.* Cleveland Clinic Foundation; Cleveland Clinic Foundation, Cleveland, OH.

**Background:** Acquired chemoresistance and recurrence are the main features of ovarian serous carcinoma (OSC) which contributes to its dismal 5-year survival rate. Recent studies indicated that epigenetic alterations might link to the chemoresistance of ovarian cancer cells cultured in vitro. However, this hypothesis has not been tested in clinical setting. We have studied DNA methylation profiling of 10 candidate tumor suppressor genes (TSG) and correlated the association between the methylation status and chemoresistance/recurrence in 34 OSCs.

**Design:** All 34 cases were stage III OSCs treated with surgical debulking and received platinum-based post-operative chemotherapy after cytoreduction. Based on 5-year follow up and recurrent data, 34 OSCs were divided into two groups: 21 cases of early recurrence cancer whose disease recurred within 12 months and 13 cases of late recurrence cancer whose disease recurred greater than 36 months. Genomic DNA from paraffin-embedded tissue blocks of primary cancers was extracted and chemically converted by bisulfite treatment. Methylation status of ten TSGs (*p14*, *p15*, *p16*, *p73*, *hMLH-1*, *RASSF1a*, *ER*, *MGMT*, *BRCA-1* and *FANCF*) was analyzed with methylation-specific PCR.

**Results:** Methylation of at least one TSG promoter was seen in approximately 88% (30/34) cases. The most frequently methylated TSGs were: *BRCA-1* (74%), *hMLH-1* (68%), *RASSF1a* (62%), *p15* (62%), *p16* (56%), and *ER* (44%). Different methylation profiles exist between early recurring OSC and late recurring OSC. Methylation of *hMLH-1*, *RASSF1a*, *BRCA-1*, and *ER* was significantly higher in early recurring OSC (62-91%) than late recurring O (15-46%,  $p < 0.01$ ). There was also significant difference in cumulative methylation index between two groups. Methylation of five or more TSGs was seen in 71% of early recurring OSC and 31% of late recurring OSC ( $p = 0.03$ ). In contrast, no detectable methylation of any TSG was seen in 0% (0/21) of early recurring OSC, but 31% (4/13) of late recurring OSC ( $p = 0.02$ ).

**Conclusions:** Our study demonstrated the differential epigenetic alterations between early recurring and late recurring OSCs. Methylation of *hMLH-1*, *RASSF1a*, *BRCA-1* and *ER* and concurrent methylation of multiple TSGs was seen significantly more frequent in early recurring than late recurring OSC. Our study suggests that detection of TSG methylation profiling may be a useful molecular tool in predicting chemoresistance of ovarian serous carcinoma.

#### 945 Spatial Difference of Insulin Like Growth Factors in Large Uterine Leiomyomas

*X Zhang, K Mittal, J-J Wei.* New York University School of Medicine, New York, NY.

**Background:** Large uterine leiomyomata (L-ULM) tend to grow faster than small ULM, although L-ULM have some disadvantages over small ones, including higher hypoxia stress, hyaline degeneration and lower vessel density. In addition to a slightly higher rate of cytogenetic alterations, little is known for a rapid growth nature in L-ULM. We previously described a spatial difference of the selected gene products and hypoxia gradient in L-ULM. We hypothesized that some local growth factors, such as insulin like growth factors (IGFs) may play a critical role in regulation of cell proliferation in L-ULM.

**Design:** Five patients with L-ULM (>12 cm in diameter) and small ULM (<2 cm) were included in this study. Fresh tissues from peripheral, mantle and central zones of L-ULM, as well as small ULM and myometrium, were dissected. Total RNAs and cDNAs were prepared. A semiquantitative RT-PCR was conducted to evaluate the mRNA expression for IGF1, IGF2, CTGF, COL4A2 and CYR61 (the last 3 are angiogenic factors). Actin  $\beta$  was used as an internal control.

**Results:** Upregulation of IGF1 and IGF2 mRNA were evident in all (large and small) ULMs in comparison to matched myometrium. The level of IGF2 mRNA in ULM was much higher than that of IGF1. There was no spatial difference of IGF1 expression in L-ULM. In contrast, a distinct spatial expression of IGF2 mRNA was noted in all L-ULM with its highest level in mantle zone. Small ULM and mantle zone in L-ULM had similar levels of IGF2 mRNAs. Expression of H19 (IGF2 associated imprinting gene) displayed a similar expression pattern as IGF2. The expression of the dysregulated angiogenic genes (CTGF, COL4A2 and CYR61) was higher in small ULM than in large ones. However, there was no significant spatial difference of the genes in L-ULM.

**Conclusions:** The high level of IGF2 mRNA in ULM indicates an important tumorigenic role of IGF2 in ULM. Up regulation of IGF2 and its associated gene H19 is more prominent in mantle zone and small ULM, indicating a differential regulation mechanism spatially and it is likely correlated with up regulation of ER/PR expression as we reported before. The current observations provide additional support for our hypothesis that there is a spatial difference of gene expressions in large ULM.

#### 946 Immunohistochemical (IHC) Analysis of Sox9 in Ovarian Sertoli Cell Tumors and Other Tumors in the Differential Diagnosis (DDx)

*C Zhao, GL Brattbauer, R Barner, R Vang.* Armed Forces Institute of Pathology, Washington, DC; LAC+USC Medical Center, Los Angeles, CA; Johns Hopkins Hospital, Baltimore, MD.

**Background:** Sox9 is involved in Sertoli cell differentiation in the testis. The role that this molecule plays in the pathogenesis of ovarian sertoli cell tumors (SCTs), as well as the potential utility for DDx, has not been thoroughly investigated.

**Design:** Immunohistochemical staining for Sox9 was performed in 152 ovarian tumors: pure SCT, endometrioid borderline tumor (E-BT), sertoliform endometrioid carcinoma (SEC), FIGO grade 1 endometrioid carcinoma (E-CA), and carcinoid tumor (CT). Extent of staining was based on the percentage of positive cells: 0, <5%; 1+, 6-25%; 2+, 26-50%; 3+, 51-75%; and 4+ 76-100%. Intensity of staining was scored as weak (W), moderate (M), or strong (S).

**Results:** SOX9 was expressed in the nucleus in 45%, 55%, 39%, 65%, and 10% of SCT, E-BT, SEC, E-CA, and CT, respectively. [Table 1]

**Conclusions:** Sox9 is expressed in only a subset (45%) of ovarian SCTs, and it is not certain whether Sox9 plays the same role in the pathogenesis of ovarian SCT as it does in Sertoli cell differentiation in normal testes. Sox9 is variably expressed in other ovarian tumors that are in the DDx of SCT and, thus, is not helpful in the IHC distinction of SCT from its histologic mimics.

Table 1. Expression of Sox9 in Ovarian Tumors

Tumors	0*	1+*	2+*	3+*	4+*
SCT (n=36)	56%	11%(3W,1M,0S)	6%(1W,1M,0S)	14%(0W,4M,1S)	14%(0W,1M,4S)
E-BT (n=38)	45%	13%(1W,4M,0S)	21%(1W,4M,3S)	18%(0W,3M,4S)	3%(0W,0M,1S)
SEC (n=13)	62%	23%(0W,3M,0S)	15%(0W,2M,0S)	0%	0%
E-CA (n=26)	35%	4%(0W,1M,0S)	15%(0W,4M,0S)	15%(0W,2M,2S)	31%(0W,2M,6S)
CT (n=39)	90%	3%(0W,1M,0S)	3%(0W,1M,0S)	3%(0W,0M,1S)	3%(0W,0M,1S)

Key: \*, result listed as percentage of cases showing each immunoscore for extent of staining (number of cases showing each grade of intensity in parentheses)

**947 Comparative Analysis of Alternate Immunohistochemical (IHC) Markers for the Distinction of Ovarian Sertoli Cell Tumors from Endometrioid Tumors and Carcinoid Tumors: A Study of 160 Cases**

*C Zhao, R Vang, GL Bratthauer, R Barner.* Armed Forces Institute of Pathology, Washington, DC; LAC+USC Medical Center, Los Angeles, CA; Johns Hopkins Hospital, Baltimore, MD.

**Background:** Although traditional IHC markers (e.g., pan-cytokeratin, EMA, inhibin, calretinin, etc.) can be useful, they can occasionally have limitations in the distinction of ovarian sertoli cell tumor (SCT) from endometrioid and carcinoid tumors. Alternate markers (e.g., ER, PR, CD10, CK7, etc.) may have potential diagnostic advantages, but their role has not been extensively investigated in this differential diagnosis.

**Design:** Immunohistochemical stains were performed in the following ovarian tumors: SCT (n=40), endometrioid borderline tumor (E-BT) [n=38], sertoliform endometrioid carcinoma (SEC) [n=13], FIGO grade 1 endometrioid carcinoma (E-CA) [n=27], and carcinoid tumor (CT) [n=42]. Expression in >5% of cells was considered positive.

**Results:**

Markers	Immunohistochemical Results				
	SCT	E-BT	SEC	E-CA	CT
CK7	15%	100%	85%	100%	24%
ER	8%	87%	85%	89%	2%
PR	13%	84%	77%	93%	2%
CD99	68%	16%	23%	33%	41%
CD10	25%	40%	31%	37%	10%
Synaptophysin	35%	8%	8%	22%	98%
Chromogranin	13%	3%	15%	11%	100%
CD56	48%	16%	15%	30%	57%

The IHC results of Pan-CK, CK8/18, EMA, inhibin and calretinin were not listed in the table.

**Conclusions:** When traditional IHC markers are problematic in a given case of ovarian SCT versus an endometrioid or carcinoid tumor, adding CK7, ER or PR, and synaptophysin or chromogranin to a panel of markers may be helpful. CD99 and CD10 are neither sensitive nor specific for SCT. In the distinction from CT, use of CD56 should be avoided.

## Head & Neck

**948 Heparanase Expression in Nasopharyngeal Carcinoma Is Inversely Correlated with Patient Survival**

*O Ben-Izhak, N Ilan, I Vlodosky, G Bar-Sela.* Rambam Medical Center, Haifa, Israel; Technion, Haifa, Israel.

**Background:** Heparanase is an endoglycosidase that cleaves heparan sulfate side chains of the major proteoglycans in the extracellular matrix and cell surfaces. Heparanase plays a role in angiogenesis and cancer metastasis and its upregulation was correlated with reduced survival in various malignancies. Heparanase expression was not previously examined in nasopharyngeal carcinoma (NPC).

**Design:** Immunohistochemical staining for heparanase was performed on sections of 46 NPC patients and correlated with clinical and pathological data. We used the polyclonal antibody which was raised in our laboratory and preferentially recognizes the 50kD active heparanase subunit (J Cell Sci 117:2249,2004).

**Results:** Positive staining was found in 35% of the cases. Heparanase positive cases had a cumulative 10 years survival of 25%, compared to 70% 10 years survival for heparanase negative cases (p=0.03). 35 patients were males and 11 were females. Median age was 42. Most patients (73%) were diagnosed with stage IV, and most (73%) had undifferentiated carcinoma. 89% were EBV positive (EBER ISH). Median follow up was 7 years. 21 of the 46 patients died of the disease. No significant correlations were found between heparanase staining and gender, age, EBV status, tumor stage and tumor histology (keratinizing, non-keratinizing and undifferentiated carcinoma).

**Conclusions:** Heparanase expression is associated with decreased survival rate of NPC patients. Heparanase may serve as a prognostic factor in NPC and can be considered as a target for development of specific anti-cancer drugs.

**949 Frozen Section Evaluation of Head and Neck Margins**

*C Black, E Zarovnyaya, J Marotti, J Paydarfar.* Dartmouth Hitchcock Medical Center, Lebanon, NH; Beth Israel Deaconess Medical Center, Boston, MA.

**Background:** A surgeon's goal is to completely resect a tumor with negative margins. Frozen section (FS) margin evaluation allows a positive margin to be corrected prior to closure and any reconstruction. A final report is later issued following examination of all resected tissues. The final margin status may have prognostic and treatment implications for the patient. FS are costly, they require many resources and are high priority. To analyze how FS is being used and how well it is fulfilling its mission, we reviewed the current practice at medical centers where head and neck cancer surgery is performed and FS are utilized for margin evaluation.

**Design:** 200 pathologists were surveyed (verbally or by mail- 2 question survey) about their center's process of FS margin evaluation. The survey asked 1:How tissue is procured and evaluated intra-operatively, and 2:How the final pathology margin status is then determined post-operatively from the resected specimen. Our responders represent 100 medical centers (48 states and 4 international). We utilized the membership log of the North American Society of Head and Neck Pathology and the list of the top 50 US Cancer Centers according to US News and World Report (2004 Best Hospitals). Our response rate was 50% (100% for top 50 centers). We analyzed the different methods utilizing the Toyota principles of systems improvement by working backwards from the final product (an adequately resected tumor) stepwise, to reveal possible flaws.

**Results:** There were no significant trends regarding the first question. Many surgeons send small fragments of tissue from the defect cavity (40%) or from the specimen proper (27%). The second question revealed that most respondents who received small tissue fragments re-sampled all margins for the final pathology report and that there was no indication where the tissue was procured from in relation to the resected specimen (44%). Others did not re-sample margins at all and some were not comfortable with this practice.

**Conclusions:** There may be more than one ideal method for FS margin evaluation. Many system failures occur in the report of final margins. Most failures are due to lack of anatomic correlation at hand offs between the surgeon and the tissue processor. Over and under sampling of margins may be occurring. Many respondents expressed frustration in the current system at their institution. There is currently no consensus on how to best submit tissue for FS evaluation.

**950 Immunohistochemical Detection of p16<sup>INK4a</sup> in Dysplastic Lesions of the Oral Cavity**

*KT Bradley, SD Budnick, S Logani.* Emory University Hospital, Atlanta, GA.

**Background:** Mutations in the tumor suppressor gene CDKN2A/p16 have been documented in preneoplastic lesions of the oral mucosa, but whether this corresponds to altered expression of the gene product p16<sup>INK4a</sup> (p16) is unclear. Furthermore, whether expression of p16 could be a useful marker of dysplasia for use in routine practice remains to be evaluated.

**Design:** One-hundred twenty biopsy specimens representing various oral cavity sites and degrees of dysplasia were retrieved from the pathology files of Emory University Hospital. Formalin-fixed, paraffin-embedded sections were stained with H&E and with a monoclonal antibody to p16 (Lab Vision Corporation, clone JC2, 1:40 dilution). A blinded review of the H&E slides and the pattern and degree of p16 expression was independently performed by 2 experienced pathologists. A consensus was obtained when diagnoses differed. Morphologic diagnoses were then compared to p16 immunohistochemical expression.

**Results:** Overall, 62/120 (52%) cases showed no p16 immunoreactivity while the remainder showed p16 expression limited to the basal/suprabasal nuclei and generally confined to the lower one-third of the epithelium (Table). p16 expression was found to be dependent on severity of dysplasia ( $\chi^2$  test, p=0.02) with a significant trend toward decreased expression with increasing severity of dysplasia (logistic regression model, p=0.002). However, 12/33 (36%) cases of non-dysplastic squamous mucosa were also negative for p16 expression.

	p16 Expression			Total number of cases
	Negative	Focal Basal Staining	Basal and Suprabasal Staining	
Consensus Grade				
No Dysplasia	12 (36%)	16 (55%)	3 (9%)	33 (100%)
Mild Dysplasia	11 (39%)	12 (43%)	5 (18%)	28 (100%)
Moderate/Severe Dysplasia	39 (66%)	15 (25%)	5 (8%)	59 (100%)

**Conclusions:** Decreased immunohistochemical expression of p16 protein in dysplastic lesions, as found in this study, may reflect the biologic events involving loss of p16 gene function in the pathogenesis of oral cancer. However, since a significant proportion of non-dysplastic mucosa also showed no p16 expression, we conclude that p16 immunohistochemistry using a monoclonal antibody is not a useful marker of dysplasia.

**951 Ezrin Localization in Head and Neck Squamous Cell Carcinoma. A Tumor Microarray Validation Project**

*M Brandwein-Gensler, N Schlect, A Thielken, R Mahmood, H Huang, T Belbin, R Smith, M Prystowsky.* Montefiore Medical Center/Albert Einstein College of Medicine, Bronx, NY.

**Background:** Ezrin-Radixin-Moesin (ERM) are linker proteins that connect cell membranes with cytoskeletal actin, regulating cell shape, motility, and proliferation. Our previous microarray expression studies have demonstrated that ERM upregulation are among changes seen with tumor progression. Our previous tissue microarray (TMA) pilot study confirmed that strong ezrin cytoplasmic localization is significantly associated with decreased overall survival. Our aim is to validate this correlation between ezrin expression and tumor progression in a new tumor data set.