

by dysfunction of the allograft. **Hypothesis:** Activation of complement in cardiac allograft recipients without allograft dysfunction may indicate that a protective mechanism exists.

Design: Endomyocardial biopsies from 8 patients with complement deposition were compared. Four patients survived these episodes of AMR and 4 did not. Immunofluorescence staining of the endomyocardial biopsies was performed with the following markers: CD35 (Complement receptor 1, CR1), CD46 (Membrane Cofactor Protein, MCP), CD55 (Decay Accelerating Factor, DAF) and CD59 (Protectin). These markers are complement regulatory proteins which play a role in controlling and silencing complement activation and tissue injury or in removing complement complexes. **Results:** Patients with good response to therapy and resolution of the AMR episode showed intense tissue expression of these complement regulatory proteins in the endothelium of the allograft. Patients with poor outcome had low or absent tissue expression of complement regulatory proteins.

Conclusions: Local expression of complement regulatory proteins on the endothelial cell surface plays a role in controlling the deleterious effects of complement activation during episodes of AMR. Identification of these regulatory proteins in tissue and understanding of the mechanisms that control their expression will be a useful tool to predict outcome

221 Allograft Inflammatory Factor-1 (AIF-1) Immunohistochemistry Stain in Biopsies of Human Heart Transplants

X Zhou, Z He, J Henegar, S Bigler, B Allen. University of Mississippi Medical Center, Jackson, MS.

Background: Allograft inflammatory factor-1 (AIF-1) is a 143-amino acid, Ca⁺⁺-binding protein originally identified in rat models of cardiac allograft rejection, and subsequently identified in a variety of chronic inflammatory conditions in humans. Immunohistochemistry was used to investigate the distribution of AIF-1 expression in endomyocardial biopsies of transplanted and native human hearts.

Design: Endomyocardial biopsy samples during the period of 2003-2005 from 36 transplanted and 17 native hearts were studied. The median age of the transplant patients was 42 (range, 14-64 years), the non-transplanted patient median age was 29 (range, 7-68 years), and the median time post-transplantation was 12 months (range, 1 week-11 years). Rejection was graded according to ISHLT criteria in the transplanted hearts, with 5 grade 0, 8 grade 1, 7 grade 2, and 16 grade 3 cases. The 17 native hearts showed a variety of findings including idiopathic dilated cardiomyopathy, hypertrophic cardiomyopathy, amyloidosis, endocarditis, or no diagnostic findings. Immunohistochemistry was performed using paraffin-embedded, formalin fixed tissue sections with a primary mouse monoclonal antibody, purchased from ABcam (clone #1022-5) using standard avidin biotin conjugate techniques with peroxidase and DAB substrate (Vectastain ABC Kit from Vector Laboratories). The primary antibody was diluted to a concentration of 2 µg/ml. Immunostaining was graded in mononuclear cells and cardiac myocytes: 0 (no staining), 1 (focal, few cells staining), 2 (patchy staining less than 50% of cells), and 3 (extensive staining, more than 50% of cells).

Results: Infiltrating mononuclear cells in transplanted hearts expressed AIF-1. In hearts with worse rejection, the infiltrates were more extensive, and there was greater reactivity of the cells (p<0.00001, ANOVA with F=19). Perinuclear staining of cardiac myocytes was also observed and correlated with the degree of rejection (p<0.013, ANOVA with F=3.534). There was no significant difference between the staining of lymphocytes in Quilty lesions and infiltrating parenchymal mononuclear cells associated with myocyte damage. The non-transplanted hearts had very few parenchymal mononuclear cells, and showed little to no expression of AIF-1.

Conclusions: AIF-1 expression is common in cellular rejection of transplanted hearts, involving both infiltrating mononuclear cells and cardiac myocytes.

Cytopathology

222 The Role of Peroxisome Proliferator Activated Receptor Gamma (PPAR γ) Staining in the Cytopathological Diagnostic Value in Follicular Neoplasm's of the Thyroid Gland

M Abdelbaqi, Y Dancer, E Turbat-Herrera. Louisiana State University, Shreveport, LA.

Background: The PAX8 gene belongs to a family of genes that plays a critical role in the formation of tissues and organs, such as kidney and thyroid gland during embryonic development. It is also important for maintaining the normal function of certain cells after birth. PAX8 proteins act as transcription factors by binding to specific area of DNA. The peroxisome proliferator activated receptors (PPARs) are ligand-dependent transcription factors that belong to a nuclear hormone superfamily. It is created by somatic tumor genetic translocation between chromosome arm 2q and 3p. This translocation t (2; 3)(q13; p25), leading to the formation of a chimeric PAX8-PPAR receptor oncogene. This leads to fusion of the the entire coding region of the nuclear transcription factor gene PPAR in-frame with the first six to nine exons of the PAX8 gene, which encodes for a thyroid specific-paired box transcription factor. Several reports have indicated that PAX8-PPAR γ is detected in follicular thyroid carcinomas (FTC), but not in follicular thyroid adenomas (FTA), papillary thyroid carcinomas (PTC), or multinodular hyperplasias. However, to our knowledge there have been no reports that have studied this problem using cytology. In this study we propose to compare the IHC for PPAR γ in surgical and FNA specimens to improve the diagnosis and classification.

Design: A total of 34 fine needle aspirates cases of follicular neoplasm, including 10 cases of FTA, 12 cases of classical FTC/follicular variant of PTC, and 12 cases of nodular hyperplasias. Including the corresponding surgically resected specimens and cell blocks. Immunostaining with PPAR γ (mouse monoclonal antibody, Santa Cruz, Ca)

was performed. The staining pattern was assessed by two independent pathologists. Cases were graded as positive if nuclear membranes stain is detected.

Results: Our results have showed a positive nuclear staining pattern in cases of follicular thyroid carcinoma, while the cases of follicular thyroid adenoma and nodular hyperplasia have tested negative.

Conclusions: PPAR γ nuclear immunostaining can be useful as an adjunct to the FNA of the thyroid. PPAR γ immunostaining can help differentiate between Follicular thyroid carcinoma and Follicular thyroid adenoma.

223 Correlation of Cytologic Examination with ELISA Assays for Hyaluronan and Soluble CD44v6 Levels in Evaluation of Effusions

A Afffy, L Lynne, L Howell. University of California Davis Medical Center, Sacramento, CA.

Background: Hyaluronan (HA) and its major cell surface receptors, CD44 play an important role in tumor growth, neovascularization, and invasion. CD44 is an integral transmembrane protein and exists in standard form as well as variants isoforms (CD44v1-v10). Functional fragments of the CD44 can be released from the cell membrane by proteolytic cleavage of extracellular domain producing soluble CD44. Although studies have proposed the use of serum HA and soluble CD44 specifically CD44v6 levels as a tumor markers, its diagnostic utility in body fluid samples has not been established. The purpose of this study was to correlate HA and soluble CD44v6 levels in effusions with the cytology diagnosis and to assess their usefulness in differentiating malignant from non-malignant effusions.

Design: In this prospective study we evaluated HA and soluble CD44v6 contents in 20 effusions from cytologically positive samples (18 metastatic adenocarcinomas and 2 lymphomas) and 10 effusions from cytologically negative samples. Corresponding cytopathology slides were reviewed to confirm the diagnosis. The level of HA and soluble CD44v6 were measured using a sandwich enzyme-linked immunoadsorbent assay. For HA we used Hyaluronic Acid Quantitative Test kit (Corgenix, Denver) and for soluble CD44v6 we used Human sCD44v6 Instant ELISA (Bender MedSystems, Vienna, Austria). HA concentrations (ng/L) and soluble CD44v6 concentrations (ng/mL) were calculated and correlated with clinical data as well as cytodiagnosis.

Results: The mean concentration of HA (22.42±5.04 ng/L) and soluble CD44v6 (99 ±132 ng/mL) in the cytologically positive samples was significantly higher than those in the cytologically negative samples for HA (5.5 ±5.04ng/L, P<0.01) and soluble CD44v6 (17 ±10 ng/mL, p= 0.013). Using benign effusions as control and the upper limits of its mean levels for HA (10.5 ng/L) as positive boundary value, HA level exceeded the boundary line in 17 out of 20 malignant effusions cases and 2 out of 10 benign effusions cases. Meanwhile CD 44v6 exceeded the boundary line (27 ng/mL) in 18 out of 20 malignant effusions cases and 3 out of 10 benign effusions cases. The calculated sensitivity and specificity of this assay to the diagnosis of malignant effusions were 85% and 80% for HA and 90% and 70% for CD44v6 respectively.

Conclusions: We conclude that the HA and soluble CD44v6 levels in body fluids correlate with the cytology diagnosis and could be used as an ancillary study in cytology to differentiate non-malignant from malignant effusions.

224 Diagnostic Utility of CD44 Standard, CD44v6, and CD44v3-10 Expression in Adenocarcinomas Presenting in Serous Fluids

A Afffy, L Pang, L Howell. University of California Davis Medical Center, Sacramento, CA.

Background: CD44 is an 85-90 kDa integral transmembrane protein encoded by a single 20 exon gene. In the standard form (CD44s) ten of the 20 exons are transcribed. Multiple variant isoforms exist (CD44v1-v10) which arise from alternate mRNA splicing of the remaining 10 exons. In contrast to the standard form of CD44, which is almost ubiquitously expressed, splice variants are highly restricted in their expression in normal or malignant tissues. The purpose of this study was to evaluate the extent to which adenocarcinomas express CD44s, CD44v6 and CD44v3-10 in fluids and to assess their diagnostic utility in distinguishing reactive mesothelial cells from adenocarcinomas in body cavity fluid.

Design: Archival paraffin-embedded cell blocks of serous fluids from 23 cases of benign effusions containing reactive mesothelial cells and 45 cases of malignant effusions with metastatic adenocarcinoma (18 ovarian, 11 pulmonary, 9 gastrointestinal, and 7 breast) were retrieved from the cytopathology files. The cytopathology of all cases was reviewed to confirm the diagnosis. Immunohistochemistry was performed on all cases using antibodies for CD44s, CD44v6 and CD44v3-10 (Bender MedSystems, CA). Positive staining was defined as distinct linear membrane staining. Strong staining in at least 10% of the tumor cells was required in order to consider the case positive for the particular marker.

Results: In benign effusions mesothelial cells expressed CD44s in 22 cases (96%), CD44v6 in 2 cases (9%) and CD44v3-10 in 2 cases (9%). In contrast neoplastic cells in malignant effusions expressed CD44s in 14 cases (31%), CD44v6 in 21 cases (47%), and CD44v3-10 in 34 cases (76%). Meanwhile malignant cells demonstrated either or concurrent reactivity for CD44v6 and CD44v3-10 in 38 cases (84%).

	The IHC results of adenocarcinomas		
	CD44s	CD44v6	CD44v3-10
Ovarian Aca (n=18)	2(11%)	4(22%)	14(78%)
Lung Aca (n=11)	7(64%)	9(82%)	7(64%)
GI Aca (n=9)	2(22%)	4(44%)	8(89%)
Breast Aca (n=7)	3(43%)	4(57%)	5(71%)
Total(n=45)	14 (31%)	21(47%)	34 (76%)

ACa:adenocarcinomas; GI:gastrointestinal

Conclusions: CD44s, CD44v6 CD44v3-10 are useful markers that can be applied to cytologic specimens. CD44s immunostaining can be used as a reliable marker to identify reactive mesothelial cells while the combination of CD44v6 and CD44v3-10 immunostaining can detect majority of adenocarcinomas in malignant effusions.

Therefore an antibody panel of CD44s, CD44v6, and CD44v3-10 can be helpful in distinguishing benign from malignant effusions.

225 What Is the Utility of Repeat HPV Testing on ASCUS / LSIL Cases Followed with Repeat Pap Tests?

NP Agaram, M Austin, A Amortegui, M Kapali. UPMC-Magee Women's Hospital, Pittsburgh, PA.

Background: Reflex HPV testing on PAP tests diagnosed as Atypical Squamous Cells of Undetermined Significance (ASC-US) has currently become a standard of care with the increasing use of liquid based cytology. Depending on the clinical situation HPV DNA testing is also requested regardless of the Pap smear diagnosis. We noticed HPV testing being repeated in the follow up Pap smears in a substantial number of cases regardless of the result of the initial HPV test. In this study, our objective was to see if repeating the HPV DNA test was helpful in the subsequent management of the patients in addition to the Pap smear diagnosis.

Design: Pathology files of UPMC-Magee Women's Hospital were searched for all PAP tests sent for HPV testing between March and May 2005. From this list, cases that had a previous HPV test within the previous 12 months were selected. The initial and current diagnosis and the initial and the current HPV test results were recorded for each of the cases.

Results: 227 cases that had a previous HPV test within the past 12 months were identified. 207 / 227 (92%) cases had an initial diagnosis of ASC-US, 9 were LSIL and 10 were Negative (NILM). The HPV DNA test results for these cases are as follows:

	ASCUS	LSIL	NILM
Initial HPV (-) and repeat HPV (-)	117 / 207 (56%)	1 / 9 (11%)	5 / 10 (50%)
Initial HPV (-) and repeat HPV (+)	11 / 207 (5%)	0 / 9 (0%)	0 / 10 (0%)
Initial HPV (+) and repeat HPV (-)	22 / 207 (11%)	3 / 9 (33%)	2 / 10 (20%)
Initial HPV (+) and repeat HPV (+)	57 / 207 (28%)	5 / 9 (56%)	3 / 10 (30%)

ASCUS Cases	Repeat PAP Diagnosis			
	NILM	ASCUS	LSIL	HSIL
Initial HPV (-) and repeat HPV (-) (n = 117)	11	106	-	-
Initial HPV (-) and repeat HPV (+) (n = 11)	-	10	1	-
Initial HPV (+) and repeat HPV (-) (n = 22)	1	21	-	-
Initial HPV (+) and repeat HPV (+) (n = 57)	1	52	3	1

Conclusions: 93.7% of cases in the ASCUS group would have been referred to colposcopy as per ASCCP guidelines based on the repeat Pap smear diagnosis alone, regardless of the result of the repeat HPV DNA testing. In the remaining 6.3% of cases where colposcopy was not indicated based on the repeat Pap smear diagnosis the HPV DNA test was either negative in the initial and repeat tests or turned negative in the repeat test. In the LSIL group the patients would have been referred to colposcopy regardless of the HPV DNA results. Based on the data repeating the HPV DNA testing at the time of follow up Pap smear adds additional cost but does not seem to contribute to subsequent patient management.

226 Cytologic Diagnosis of Infectious Agents in Bronchoalveolar Lavages from Immunosuppressed Patients

AM Al-Za'abi, W Geddie, SL Boerner. University Health Network, Toronto, ON, Canada.

Background: Bronchoalveolar lavage is frequently performed in immunosuppressed patient during the investigation for pulmonary infiltrates for infectious agents. However, the effectiveness of cytologic examination and the optimum method for agent detection remains under debate.

Design: 336 BAL samples were collected over six months from immunosuppressed, solid organ and bone marrow transplant patients in which both cytologic examination and microbiologic studies were performed. The cytologic samples were split with one half processed into 2 direct smears (1 GMS and 1 Pap stain). The second half was processed into 2 Pap stained ThinPrep slides. The detection of infectious agents on the cytologic samples were compared to microbiologic studies with attention paid to the method of cytologic preparation that demonstrated the presence of the agent.

Results: 24 BAL samples contained infectious agents, including Cytomegalovirus (CMV), Aspergillus and Pneumocystis carinii (PC). Cytologic examination had a sensitivity of 34.6% for detection of infection and found 6/15 (40%) cases of Aspergillus and 3/4 (75%) cases of PC but none of the cases of CMV. In 3 cases of Aspergillus, only the cytology sample showed the organism. The organisms were evident on both direct smears and ThinPrep slides with only two cases in which the GMS staining aided in the cytologic diagnosis. In 4 samples, cytologic examination found cells suspicious for malignancy including 3 cases suspicious for leukemic blasts and one case suspicious for non-Hodgkin's lymphoma.

Conclusions: Although cytologic examination has a low sensitivity for detection of infectious agents it remain useful in evaluation of pulmonary infiltrates from immunocompromised patients because of its ability to detects organism that may be undetected by microbiologic examination and finding of a potential malignant process. However, routine GMS staining does not substantially aid in the detection of an infectious process.

227 Cytomorphologic Features of Paraganglioma Using Crush Preparation during Intraoperative Assessment of CNS Tumors: Review of Five Cases

OM Alassi, J Gutierrez, SR Kini. Henry Ford Hospital, Detroit, MI.

Background: Paragangliomas (PG) are rare tumors of neural crest origin arising from paraganglia. They are reported in different locations and the majority are benign. The utility and cytologic features of PG of nervous system in crush preparation have not been previously well studied. We are reporting the cytomorphologic findings in five cases of PG using crush preparation for intraoperative assessment (IO) with histologic correlation.

Design: The pathology files in our institution were searched for PG between 1990 and 2005; PG involving the nervous system with available crush preparations and

corresponding histologic specimens were selected. Slides were evaluated for the following criteria: cellularity, cell size and shape, nuclear morphology (size, shape, chromatin pattern, nucleoli, mitosis, karyorrhexis, nuclear molding and inclusions), characteristics of stroma and background features. Review of histologic sections was performed for correlation. Patient demographics including age, sex, tumor size and location were obtained.

Results: The search generated 75 cases of PG in different sites, there were 5 cases of nervous system origin with crush preparation for IO assessment. The patients were 3 females, 2 males, age ranges from 32 to 69 yrs (Av=49). The sites included cauda equina(2), temporal fossa (1), jugular foramen(1), and paraspinous(1), tumor size ranges from 2 to 7 cm (average=3.9). The IO interpretation was PG in four cases and adenocarcinoma in one. The histologic diagnosis was PG in all cases. Cytologic features were similar in 4 cases and included: high cellularity, medium sized cells with well defined cell borders and cytoplasmic tailing. The nuclei were remarkably uniform, round with salt and pepper chromatin, lacking nuclear molding or inclusions, occasional nucleoli were seen. The background was clean with folded fragments of stroma rich in capillaries. Cytologic diagnosis was adenocarcinoma in one case which represented metastatic PG to paraspinous region from adrenal primary, and showed moderate pleomorphism, larger nuclei with higher N/C ratio, prominent nucleoli, karyorrhexis, and necrosis.

Conclusions: PG's show distinctive cytomorphologic features in crush preparations allowing distinction from other tumors at these sites including: ependymoma, oligodendroglioma, metastatic carcinoid, central neurocytoma. This method can be utilized to evaluate PG during (IO) assessment of CNS tumors. A malignant PG may be considered if there is necrosis, karyorrhexis, prominent pleomorphism and higher N/C ratio.

228 Fine- Needle Aspiration Cytology of Salivary Duct Carcinoma: Cytomorphologic Features of Six Cases

OM Alassi, SR Kini. Henry Ford Hospital, Detroit, MI.

Background: Salivary duct carcinoma (SDC) is a rare high-grade salivary gland tumor showing striking resemblance to ductal carcinoma of the breast. We sought to characterize the cytologic features in fine needle aspiration (FNA) of six cases of histologically proven SDC.

Design: The pathology files in our institution were searched for lesions diagnosed as SDC between 1980 and 2005. Six cases were selected with available FNA cytology and histology slides. The cytology slides were evaluated for the following criteria: Cellularity, architectural patterns, cell size and shape, nuclear morphology (size, shape, chromatin pattern, nucleoli, mitosis, karyorrhexis), and background features. Review of histologic sections was performed for correlation

Results: Patients age range from 46 to 77 years (4 males, 2 females). Five tumors involved the parotid gland and one was submandibular. One patient had history of pleomorphic adenoma in the same parotid gland twenty years ago. Mean size of tumors was 2.7 cm (range 1-5 cm). Follow up data was available for 5/6 cases. One patient developed bone metastasis 6 months after diagnosis, one deceased 9 month later of unknown cause. The other three had no recurrence or metastasis on follow up of 1, 8 and 10 years. Cytologic diagnosis of two cases suggested SDC; three cases were diagnosed as high-grade adenocarcinoma, one case as high-grade papillary neoplasm due to presence of many tight clusters of malignant cells reminiscent of papillae. The smears were cellular (5/6). Malignant cells were seen singly, in loosely cohesive clusters, and syncytial tissue fragments. Larger fragments showed striking branching and cribriform patterns (3/6). Cells were large with high N/C ratio; cytoplasm was scant to abundant, some cells were vacuolated. Cellular membrane was sharply outlined. Nuclei were large with smooth nuclear membranes chromatin was finely granular. Nucleoli were inconspicuous (4/6); one case had multiple prominent nucleoli. In general, all cases displayed unmistakable stigmata of malignancy.

Conclusions: The distinct and multiple morphologic patterns seen in SDC may not be always reflected in FNA cytology due to sampling, precluding a specific and accurate cytologic typing. The presence of solid sheets with cribriform and papillary patterns and background necrosis with cells showing obvious malignant cytologic features is suggestive of SDC.

229 Are Cell Block (CB) Preparations Useful in the Interpretation of Atypical Glandular Cells (AGC)?

M Alsharif, DM McKeon, HE Gulbahce, SE Pambuccian. University of Minnesota, Minneapolis, MN.

Background: AGC is a diagnostically challenging category of the 2001 Bethesda System (2001 BS). Diagnostic problems in AGC include differentiating reactive from dysplastic changes, squamous from glandular and occasionally endocervical from endometrial abnormalities. Previous reports and our anecdotal experience suggest that CB prepared from the residual sample of liquid-based Pap tests may be useful in further classifying AGC. Our study critically evaluated the usefulness of CB prepared from residual SurePath samples in cases diagnosed as AGC by 2001 BS criteria.

Design: 42 cases diagnosed as AGC between 10/27/2003-04/19/2005 where residual sample was available were prospectively collected and CB were prepared by the histogel method. CB were also made from the residual samples of 65 cases diagnosed as negative for intraepithelial lesion or malignancy (NILM) (n=31), endometrial cells in a woman 40 (EMC) (n=16), squamous (n=12) and glandular (n=6) abnormalities. Patient data (age, Pap diagnosis, clinical history, HPV tests, previous abnormal Paps/ biopsies) were extracted and tabulated next to data on follow-up (FU) Pap tests and biopsies. 3 H&E stained sections were blindly reviewed by two pathologists without knowledge of cytologic diagnosis or clinical data. Overall cellularity and cell groups ("microbiopsies") were semiquantitated on a scale of 0-3+ and diagnoses similar to 2001 BS categories were made and then correlated to the histologic FU that was available in 70 cases. CB were considered informative when they had a cellularity $\geq 1+$, and useful

if they allowed further classification as to reactive or neoplastic, squamous or glandular that corresponded to the available FU.

Results: Of the 107 CB from patients aged 21-83 years (mean 46) 87 were informative. The most informative CB had more than 5 cell groups and also allowed evaluation of architectural features.

Pap Diagnosis	n=107	Informative CB n=87 / With Cell groups n=49	Informative CB with FU	All CB Diagnosis	Useful CB (% of CB informative with FU)
AGC	42	34 / 22	34	22 NILM, 12 neoplastic	23(67%)
Glandular abnormalities	6	3 / 3	3	3 neoplastic	1(33%)
Squamous abnormalities	12	10 / 6	8	3 NILM, 7 neoplastic	5(62%)
NILM, EMC	47	40 / 18	12	26 NILM, 14 neoplastic	12(100%)

Conclusions: Our study shows that CB are useful in further classifying liquid-based Pap tests diagnosed as AGC. CB predicted the nature of the glandular process i.e. reactive versus neoplastic in 14/34 (41%) and squamous versus glandular lesion in 12/34 (35%) of AGC cases.

230 Comparison of Mammaglobin (MG) and Gross Cystic Disease Fluid Protein-15 (GCDFFP-15) as Specific Immunocytochemical (ICC) Markers of Metastatic Mammary Carcinoma (MMC) in Effusion Cytology Specimens

M Assaad, D Stevens, R Cartun, A Ricci, S Mandavilli. Hartford Hospital, Hartford, CT. **Background:** MMC can be difficult to distinguish from other metastatic carcinomas in malignant effusions. Commonly used ICC markers in this differential diagnosis include CK7/CK20 antibodies, gross cystic disease fluid protein-15 (GCDFFP-15) and ER (estrogen receptor). Mammaglobin (MG) is a glycoprotein that is highly expressed in human breast cancers. The aim of this study was to evaluate utility of MG in diagnosis of MMC in effusion cytology by comparison with other established ICC markers of MMC.

Design: A computer search from Hartford Hospital pathology files for patients with metastatic breast carcinoma in pleural effusion specimens between 2000 and 2005 generated 32 patients in whom cell blocks were available. These cases were immunostained for MG, GCDFFP-15, ER, PR (progesterone receptor) and Her-2/neu protein.

Results: MG was positive in 16 of 32 cases (50%) and GCDFFP-15 was positive in 8 of 32 patients (25%). The positivity of both MG and GCDFFP-15 was quite variable ranging from focal (<10%) to diffuse (100% of tumor cells positive). 5 of the cases co-expressed GCDFFP and MG. (Table 1). 14 of 16 cases (87.5%) positive for mammaglobin were also positive also for ER, PR and Her-2-neu expression in these 14 cases was variable. Of the 13 cases that were negative for MG and GCDFFP-15, 7 were positive for ER. (Table 2)

All cases (n=32)	Mammaglobin negative	Mammaglobin positive
GCDFFP-15 negative	13 (40.6%)	11 (34.4%)
GCDFFP-15 positive	3 (9.4%)	5 (15.6%)

All cases (n=32)	MG+ve, G*-ve	MG-ve, G+ve	MG+ve, G+ve	MG-ve, G-ve
ER positive	10	2	4	7
ER negative	1	1	1	6
Total	11	3	5	13

*G= GCDFFP-15

Conclusions: MG appears to be a useful addition to a panel of ICC in establishing diagnosis of metastatic mammary carcinoma raising the sensitivity of detection to 81.2% (using a panel including MG, GCDFFP-15, ER). This is an improvement when compared to GCDFFP-15 and ER combination.

231 The Frequency and Rationale of Fine Needle Aspiration Biopsy Conversion to Core Biopsy as a Result of Onsite Evaluation

S Bandyopadhyay, V Pansare, J Feng, R Ali-Fehmi, R Bhan, M Husain, MA Al-Abbadi. Wayne State University and Karmanos Cancer Institute, Detroit, MI.

Background: Fine needle aspiration (FNA) is a well-established cost effective diagnostic technique. The sensitivity depends on multiple factors one of which is the availability of immediate adequacy and triage by a pathologist. In some cases the triaging pathologist may advise a core biopsy to assure a diagnostic procedure. The aim of this study is to find out the frequency of these cases with analysis of their indication and usefulness in resolving diagnostic dilemmas. Each core biopsy was also evaluated on site by touch imprint studies.

Design: Retrospective review of all the FNA material with onsite evaluation between July 2004 and September 2005 at our institution was carried out. The frequency of conversion to core biopsy was calculated. Analysis of these cases was conducted taking into consideration the indication for conversion at the time of onsite evaluation and whether addition of core biopsy provided any more specific diagnostic information.

Results: During this period, the onsite triaging cytopathologist recommended additional core biopsy for 31 (4%) of 821 specimens. In 3 FNA procedures core biopsy could not be performed due to patient and technical factors. Rationale for conversion in the remaining 28 of 821 (3%) cases were a), either scant aspirated material in 9 (32%) or b), an anticipated need for additional histologic material to further characterize the lesion in 19 (68%). Upon review, 27 of 28 (96%) cases the rationale for conversion was appropriate. In 3 of 27 (11%) cases, additional core specimen resulted in change of initial FNA interpretation but not in the remaining 24 (89%) procedures. In 12 of 27 (44%) patients, core specimen yielded additional significant diagnostic information. Overall, core biopsy provided relevant and satisfactory results in all 27 patients.

Conclusions: Additional core biopsy is rarely recommended in patients undergoing FNA biopsy procedure by the on-site cytopathologist at our institution. In almost all of our patients, rationale for core biopsy was judged to be appropriate. Appropriate

utilization of this approach may help add important diagnostic information and eliminate an additional patient visit and health care cost.

232 FNA Diagnosis as Salivary Gland Neoplasm, Not Otherwise Specified (NOS) Has a High Association with Malignancy

AA Bashir, L Dahmouh, CS Jensen, RA Robinson. University of Iowa College of Medicine, Iowa City, IA.

Background: Salivary gland FNA is used to determine initial management of patients with salivary gland masses. Not infrequently FNA's are interpreted as "salivary gland neoplasm, not otherwise specified (NOS)" without a specific subtype of tumor being assigned. We wished to determine whether this less precise diagnosis altered patient management or outcome and determine whether specific lesions were more difficult to classify.

Design: 49 salivary gland FNA's between 1991 and 2005 in our institution were diagnosed as salivary gland neoplasm, NOS. All had histologic follow up. All FNA's were reviewed by the authors blinded to the outcome.

Results: 42 masses were in the parotid, 5 in the submandibular gland, and 2 in minor salivary glands. On histologic followup 26 aspirates were from primary carcinomas (mucoepidermoid carcinoma = 7, acinic cell carcinoma = 5, adenoid cystic carcinoma = 5, salivary duct carcinoma = 2, adenocarcinoma nos = 3, carcinoma ex pleomorphic adenoma = 1, carcinosarcoma = 1, polymorphous low grade carcinoma = 1, epimyoepithelial carcinoma = 1). 1 case represented the first presentation of renal cell carcinoma. 15 aspirates were from benign tumors (pleomorphic adenoma = 6, monomorphic adenoma = 4, Warthin's tumor = 4, myoepithelioma = 1) and 7 aspirates were from non-neoplastic lesions (sialadenitis = 5, sialosis = 1, hamartoma = 1). Three observations were drawn from blinded review and histologic correlation. 1) The sialadenitis aspirates revealed scant, small clusters of cells with darkly staining nuclei and paucity of acini which led to their overdiagnosis as neoplasm in spite of background inflammation. 2) Tumors with abundant basaloid cells and minimal stroma (adenoid cystic carcinoma, basal cell adenoma and cellular pleomorphic adenoma) were difficult to separate due to overlapping cytologic features. 3) Aspirates showing clusters or sheets of cells with round nuclei and abundant eosinophilic granular cytoplasm represented a spectrum of neoplasms including acinic cell carcinoma, mucoepidermoid carcinoma, salivary duct carcinoma and adenocarcinoma, NOS.

Conclusions: 1) An FNA diagnosis of salivary gland neoplasm, NOS, is frequently associated with a malignant tumor (26/49 = 53%). 2) Consideration of sialadenitis on FNA should be given when scant cellularity and aggregates of small, clumped ductal cells are seen with even minimal background inflammation. 3) Given the frequent association with malignancy (53%) resection is the most appropriate management.

233 Evaluation of the New Cytyc ThinPrep® Imaging System™ for Cervical Cytology

N Bolger, CCBB Heffron, IE Regan, M Sweeney, S Kinsella, M McKeown, G Creighton, J Russell, JJ O'Leary. Coombe Women's Hospital, Dublin 8, Ireland; Trinity College, Dublin, Ireland.

Background: The ThinPrep® Imaging system consists of an Image Processor and one, or more, Review Scopes (RS). It assists in the primary screening of ThinPrep® slides by identifying 22 fields of interest for review by cytotechnologists (CT).

Design: In this study we compared the RS screening result with independent manual primary screening of 12000 routine ThinPrep® slides. With the first 6000 cases, the RS screening results from the 22 fields of view (FOV) only, as presented by the Autolocate mode of the RS, were compared to independent manual primary screening using British Society for Clinical Cytology (BSCC) guidelines for reporting. These cases were used as part of the learning curve with this technology. In the second set of 6000 cases, any abnormality detected in the 22 FOV resulted in full manual screening on the CT own microscope. Sensitivity and specificity together with their 95% Confidence Intervals were calculated for each method. Differences in both methods were analysed for statistical significance using a chi-square test (p < 0.005). Correlation of all high grade squamous and glandular cytology cases with their associated biopsy was also performed.

Results: With the first 6000 cases the diagnostic sensitivity of the Imager was 84.9% and diagnostic specificity 96.8%. The diagnostic sensitivity of primary screening was 87.3% and diagnostic specificity 98.5%. With the next 6000 cases the diagnostic sensitivity of the Imager increased to 91.5% with diagnostic specificity 98.0%. The diagnostic sensitivity of primary screening increased to 93.5% with diagnostic specificity 98.8%. There was no significant statistical difference between either set of results. Biopsy analysis showed a PPV of 83% for the first set of data and 84% for the second set.

Conclusions: The results from our study show that the sensitivity and specificity of the imager technology is equivalent to that of manual primary screening. The system is ideally suited to the rapid triage of negative cases allowing increased laboratory productivity and greater throughput of cases on a daily basis.

234 Cytomorphologic Features of Poorly Differentiated Thyroid Carcinoma: A Statistical Analysis of 35 Cases

M Bongiovanni, L Bloom, JF Krane, CN Powers, S Hintermann, J-C Pache, WC Faquin. Hopitaux Universitaires de Geneve, Geneva, Switzerland; University of Tennessee Health Science Center, Memphis, TN; Brigham and Women's Hospital, Boston, MA; Virginia Commonwealth University, Richmond, VA; CYPA Laboratoire, Lausanne, Switzerland; Massachusetts General Hospital, Boston, MA.

Background: Poorly differentiated thyroid carcinoma (PDTC) is an uncommon malignancy with an aggressive clinical behavior and poor prognosis. The classic form is insular carcinoma, but trabecular and solid histologic types are also recognized. The cytomorphologic features of these tumors have not been well defined despite significant

clinical implications. The objective of this study is to apply statistical analysis to the diagnosis of this subset of tumors in fine-needle aspiration biopsies (FNAB).

Design: A total of 35 thyroid FNABs diagnosed histologically as PDTC from 5 institutions comprised the study. 18 of these cases were insular carcinomas and 17 were non-insular PDTCs. A control group of 29 well differentiated (WD) thyroid neoplasms were selected for comparison. All FNABs were reviewed by 2 cytopathologists and scored for a series of 35 cytomorphologic features. Statistical analysis was performed using the Chi square test and the Fisher's exact test.

Results: PDTCs were characterized by a solid cytoarchitecture ($p < 0.001$), single cells ($p < 0.0001$), severe crowding ($p < 0.0001$), high N:C ratio ($p = 0.0002$), nuclear atypia including nuclear pleomorphism ($p = 0.0151$), anisokaryosis ($p < 0.0001$), mitotic activity ($p = 0.0011$), and apoptosis ($p < 0.0001$). Relative to WD thyroid neoplasms, they lacked papillary and prominent follicular architectures, colloid, nuclear grooves and intranuclear pseudoinclusions. In 78% of cases, the insular carcinoma subset was indistinguishable from other PDTCs; however, 4 insular carcinomas were recognized by the presence of a prominent insular pattern with endothelial wrapping ($p = 0.0423$). Based upon our findings, 63% ($N = 22$) of the PDTCs studied could be diagnosed as "malignant" while 37% ($N = 13$) could not, and were "suspicious for a follicular neoplasm."

Conclusions: PDTCs have characteristic cytomorphologic features (solid cytoarchitecture, single cells, severe crowding, high N:C ratio, nuclear atypia, mitotic activity, and apoptosis) and lack well defined papillary and follicular architectures that allow them, in many cases, to be recognized by FNAB as "malignant" and suggestive of a PDTC.

235 Epidermal Growth Factor Receptor (EGFR) Mutations in Lung Carcinomas Are Associated with Distinct Cytomorphological Features

EF Brachtel, AJ Iafate, EJ Mark, V Deshpande. Massachusetts General Hospital, Boston, MA.

Background: The initial diagnosis of lung carcinoma is frequently made by fine needle aspiration biopsy (FNAB). Novel therapeutic strategies of this disease include tyrosine kinase inhibitors (TKI) such as gefitinib, which target the kinase domain of EGFR. Somatic mutations of this region have been shown to predict a therapeutic response of lung carcinomas to TKI. EGFR mutations have been described in adenocarcinomas of the lung, especially the bronchioloalveolar subtype (BAC), which has both cytopathologic and histopathologic definitions. This study investigates if tumors with EGFR mutations display a characteristic phenotype on FNAB.

Design: We identified 37 FNAB of lung masses on which molecular analysis for EGFR mutations was available. Molecular analysis was performed on DNA isolated from formalin-fixed, paraffin-embedded tissue of the corresponding core biopsies/cell blocks or resection specimens followed by PCR with primers for the tyrosine kinase region exons 18-24 and nucleotide sequence analysis by gel electrophoresis. Two observers who were blinded to the mutational data assessed several cytomorphologic parameters. A semiquantitative analysis included predominant tissue pattern (flat or overlapping), nuclear features (nucleoli, intranuclear inclusions, grooves), cytoplasmic qualities and extracellular material.

Results: All cases were adenocarcinomas primary in the lung. 13 cases showed EGFR mutations in exons 18, 19, 20 or 21 of the tyrosine kinase domain. The 24 cases negative for the relevant mutation served as the control group. Tumors with EGFR mutations were statistically more likely to demonstrate a predominantly flat, monolayer architecture ($p = 0.03$) with nuclear inclusions ($p = 0.014$) and lack macronucleoli ($p = 0.001$). The predominance of flat monolayers in conjunction with the absence of extracellular mucin and macronucleoli indicated the presence of EGFR mutations with a positive predictive value of 69% and a negative predictive value of 92%. All four cases with extracellular mucin were negative for the examined mutations.

Conclusions: Some of the traditional cytomorphological features of BAC, i.e. flat monolayers, intranuclear inclusions and the absence of macronucleoli, statistically correlated with the presence of mutations within the tyrosine kinase region of EGFR. Cytomorphological features could serve as a predictive marker of response to tyrosine kinase inhibitors and possibly other new therapies in development.

236 Assessing and Improving Knowledge in Cytopathology Training

WK Brix, J Jackson, KA Atkins. University of Virginia, Charlottesville, VA.

Background: Knowledge based assessment is one of the six domains of competency for residency training developed by the Accreditation Council for Graduate Medical Education (ACGME) Outcome Project. The American Society of Cytopathology and Association of Directors of Anatomic and Surgical Pathology have outlined expectations for fund of knowledge for cytology at three skill levels. However, no universal testing is currently available aside from the annual Residency In-Service Exam. At our institution resident knowledge and diagnostic ability are graded by faculty on a 5 point scale. This study is designed to: 1) correlate faculty assessment of resident knowledge with objective test scores and 2) evaluate the utility of a midrotation test and a mandatory study slide set in improving knowledge.

Design: A web based test of 26 questions was developed for a beginning skill level residents, covering general topics in medical, gynecologic, and FNA cytology. The test was composed of multiple choice questions similar to the pathology boards. Seven residents rotating for the first 2 months on cytology participated in the study. Four residents took the end of the rotation test (ERT) after rotating as usual on the service. Three residents were given a mid rotation test (MRT) and a mandatory study slide set composed of 20 commonly encountered lesions. They also took the ERT. Faculty evaluations were recorded and compared to the test results.

Results: The average score on the end of the rotation test for residents with no MRT was 54%, while the average score for residents with MRT was 73% (a difference of 5 questions). The average score for the mid rotation test was 50%. Faculty evaluations ranged from 3 to 5 for all residents.

Conclusions: In this preliminary study, a mid rotation test and mandatory slide study set improved performance on the ERT by an average of 20%. Although there were no overlapping questions on the two tests, residents report that they were more attentive to discussions involving topics they had seen on the MRT. There was little correlation between faculty evaluation and test performance. While this does not inherently mean the faculty opinions are invalid, it does support the utility of triangulating evaluations. As more residents take the exam, the questions will be analyzed for discrimination of knowledge base and level of difficulty. It is anticipated that a pool of questions will be available to other programs for knowledge assessment.

237 Immunolocalization of CD57 and GLUT-1 in Cell Blocks: Role in Fine Needle Aspiration Diagnosis of Papillary Thyroid Carcinoma

VS Chandan, WC Faquin, D Wilbur, KK Khurana. State University of New York - Upstate Medical University, Syracuse, NY; Massachusetts General Hospital, Harvard Medical School, Boston, MA.

Background: CD57 (Leu-7), a marker for natural killer lymphocytes and glucose transporter-1 (GLUT-1), a facilitative cell surface glucose transport protein are expressed in a wide spectrum of epithelial malignancies. The purpose of this study was to determine the utility of CD57 and GLUT-1 immunostaining as an adjunct to the diagnosis of papillary carcinoma in fine-needle aspirations of the thyroid.

Design: Using a monoclonal antibody to CD57 and GLUT-1 and a standard avidin-biotin complex technique, immunostaining was performed on paraffin-embedded cell blocks of 50 thyroid FNA cases with the following cytologic diagnoses: (1) papillary carcinoma (15 cases); (2) atypical cytology, cannot exclude papillary carcinoma (14 cases); and (3) nonneoplastic thyroid (21 cases). Histologic follow-up was available in all cases.

Results: Fourteen of 15 cases with an unequivocal diagnosis of papillary carcinoma were positive for CD57 and 1 case was negative for CD57. Tissue follow-up confirmed papillary carcinoma in all 15 cases. Of the 14 cases with a diagnosis of atypical cytology, cannot exclude papillary carcinoma, 6 cases were positive for CD57 and subsequent excision confirmed papillary carcinoma in all 6 cases. The remaining 8 cases negative for CD57 included surgically confirmed goiter (5 cases), adenoma (2 cases), and papillary carcinoma (1 case). The follicular cells in all 21 cases with a cytologic diagnosis of nonneoplastic thyroid were negative for CD57. Histologic follow-up of these cases confirmed the non-neoplastic cytologic diagnoses. The sensitivity and specificity for CD57 was 91% and 100% respectively. GLUT-1 was negative in all cases.

Conclusions: CD57 immunostaining is a useful adjunct for the diagnosis of papillary thyroid carcinoma in cell block material. While negative staining for CD57 does not exclude papillary carcinoma, positive staining aids in the accurate diagnosis of malignancy in cytomorphologically equivocal cases of papillary carcinoma. GLUT-1 did not prove to be a useful marker in distinguishing papillary carcinomas.

238 The Prevalence of Critical Values in Cytopathology

AC Clayton, TC Pereira, HD Tazelaar, YL Liu, ME Leon, JF Silverman. Mayo Clinic, Rochester, MN; Allegheny General Hospital, Pittsburgh, PA.

Background: Certain anatomic pathology diagnoses could prompt immediate treatment of the patient, analogous to critical values (CVs) in clinical pathology. The concept of critical values in surgical pathology has recently been presented, and it has been proposed that national guidelines be considered. In this study we evaluate the prevalence of CVs in cytology.

Design: 2000 cytology reports were retrieved at two large academic medical centers including per institution: 200 consecutive gynecologic smears (gyn), 400 consecutive non-gynecology (non-gyn) specimens and 400 consecutive fine-needle aspirations (FNAs). Cases considered CV included unexpected malignancy (no previous malignancy in the pathology computer record and no clinical history that infers suspicion of malignancy), disagreement between immediate interpretation and final diagnosis in FNAs, and finding bacteria, fungi, mycobacteria or viral cytopathic effect in non-gyn and FNA specimens. The reports were also reviewed for documentation of a phone call to the clinician.

Results: Among the 2000 reports, there were 52 CV cases (2.6%), including 0.25% (1/400) gyn, 1.88% (15/800) non-gyn, and 4.5% (36/800) FNA. Most of these (42 cases) were unexpected malignancies. Five cases constituted disagreement between immediate interpretation and final diagnosis in FNAs, and 5 cases were the presence of microorganisms in non-gyn specimens. For the majority of the CVs there was documentation of physician notification (30/52). Among the 22 cases without documentation, 9 were FNAs in which there was an immediate interpretation in the report, and the final was in agreement.

Conclusions: Based on our definition of cytology CV, the most common critical value was the occurrence of an unexpected malignancy. In as many as 25% of the CV cases which were not FNAs with immediate interpretation in the report, a pathologist did not call or the phone call was not documented. Notification and documentation of notification is required for CV in Clinical Pathology, and it is part of the College of American Pathologists Laboratory Accreditation Program checklist. With the increasing emphasis on patient safety since the recent Institute of Medicine report, we believe that consensus guidelines should be developed on CV in cytology, including type of cases that need notification, timeliness and documentation.

239 Robustness of Validation Criteria in the College of American Pathologists Interlaboratory Comparison Program in Cervicovaginal Cytology
TJ Colgan, AA Renshaw, DR Mody, B Blond, M Walsh, AT Moriarty. Mount Sinai Hospital, Toronto, ON, Canada; Baptist Hospital of Miami, Miami, FL; The Methodist Hospital, Houston, TX; College of American Pathologists, Northfield, IL; Ameripath Indiana, Indianapolis, IN.

Background: Field validation of slides used in gynecologic cytology proficiency testing (PT) has surfaced as an important issue. Although precision of diagnoses in peer reviewed educational programmes has been examined, the robustness of the validation criteria for specific types of interpretations used in PT has not been previously studied.

Design: Data from 16,948 slides in the College of American Pathologists Interlaboratory Comparison Program in Cervicovaginal Cytopathology (CAP-PAP) were examined to identify the number of cases that would achieve validation after 5, 10, 15, and 20 reviews. Validation required 90% correct responses to four separate diagnostic series [unsatisfactory (UNSAT), negative for intra-epithelial lesions or malignancy (NILM), low-grade squamous intra-epithelial lesion (LSIL), and high-grade squamous intra-epithelial lesion and carcinoma (HSIL+)] and a standard error of <5%.

Results: Trichomonas, herpes, adenocarcinoma and squamous carcinoma cases were robust with an error rate of <5% within five reviews. Conversely, UNSAT, NILM-not otherwise specified, LSIL and HSIL+ required at least fifteen reviews to achieve the same error rate and were not robust.

Conclusions: There are two different levels of robustness in the CAP-PAP four category selection series. Fair PT must consider the number of reviews for validation. Validation criteria that do not include a relatively high number of reviews and a specified level of precision will fail to identify reproducible cases. Attempts to shortcut the evaluation of these cases prior to use in PT will result in a test that does more to measure the inadequacies of the material than the performance of the participants.

240 Molecular Archiving of Liquid Based Gynecologic Cytology Specimens in Paraffin with the Xpress Tissue Processor

DJ Dabbs, N Mauser, RM Austin. Magee-Womens Hospital of UPMC, Pittsburgh, PA.

Background: The Pap test has always afforded the potential as a rich source of material to study the natural history of cervical disease. The move from conventional Pap smears to liquid based preparations (LBP) has revolutionized the laboratory testing utility of the Pap test for microbiological (sexually transmitted disease) and molecular studies (human papilloma virus). The LBP has a defined shelf life for molecular testing according to proprietary manufacturer specifications. We and others have demonstrated that specimens processed through the formalin-free, molecularly-friendly Xpress tissue processor (Sakura) have good preservation of protein, RNA and DNA. We performed preliminary testing on LBP specimens to ascertain preservation of morphology and antigenicity using the Xpress Tissue Processor.

Design: Nine LBP Paps, comprising 3 normals, 3 LSILs and 3 HSILs were utilized. The specimens were centrifuged in PreservCyt into a cell pellet. The pellets were processed through the Xpress device that employs proprietary, alcohol-based fluids without exposure to formalin. Cell pellets were stained with standard hematoxylin/eosin stains and the Papanicolaou stain. P16 and MIB-1 were examined by the immunohistochemical method, and the specimens were examined with high-risk probes to human papilloma virus with automated in situ hybridization (Ventana, Tuscon AZ).

Results: Squamous epithelial and endocervical cells populated the pellets. Red blood cells were lysed. The morphology of the cell pellets from a cytology point of view was superior with the Papanicolaou stain and was comparable to the LBP. The H/E stained pellets were comparable to an endocervical curettage specimen. Immunohistochemical tests showed expected elevated nuclear staining for MIB-1 and P16 in SIL lesions and was negative in normal cases. HPV high risk probes showed brilliant nuclear staining only in SIL lesions.

Conclusions: (1) Xpress tissue processing of gynecologic LBP cell pellets provides cytologic detail with the Papanicolaou stain comparable to LBP thinlayer slides. (2) Immunohistology with molecular markers is well preserved. (3) In situ hybridization with HPV high risk probes shows excellent nuclear localization in SIL cases. (4) Paraffin archiving of LBP Pap tests processed with the Xpress processor may offer an easy and economical storage method for cervical samples for research purposes.

241 Semiquantitation of Tumor Cells during Intraoperative Cytologic Evaluation of Sentinel Lymph Nodes: Can It Predict Size of Sentinel Nodal Metastasis and Status of Axillary Node Dissection in Breast Cancer Patients

MN De Peralta-Venturina, MB Amin, NS Goldstein. William Beaumont Hospital, Royal Oak, MI.

Background: It is not well established whether all patients with a positive intraoperative sentinel lymph node (SLN) evaluation should undergo immediate axillary lymph node dissection (ALND). It is the aim of this study to determine if semiquantitation of tumor cells in intraoperative cytologic smears can predict type of SLN metastasis and status of ALND.

Design: Between Jan. 2003 and Aug. 2005, 630 breast cancer patients (522 invasive and 108 in-situ carcinoma) underwent intraoperative SLN evaluation by cytologic scraping. If the cytology of any SLN was positive, ALND was performed at the same time. Subsequent SLN evaluation of permanent sections included 3 H & E levels, and AE1/AE3 for confirmation on negative nodes. The number of tumor cells in the intraoperative cytologic smears were semiquantitated as none, few (1-10 tumor cells/smear), moderate (>10-20) and many (>20) and were correlated with type of SLN metastasis (isolated tumor cells (ITC) vs micrometastasis vs macrometastasis) and status of ALND (positive vs negative).

Results: Of the 630 cases, there were 166 (26%) positive SLN on permanent section. Intraoperative cytology was positive in 118 of these 166 cases (71%) and was negative in 48 (29%) cases. Of the 48 false negative cases, there were 20 (42%) ITC, 21 (44%) micrometastases, and 7(14%) macrometastases. Of the 118 positive cytology cases,

there were 23 (14%) with few, 7 (4%) with moderate and 88 (53%) with many tumor cells on cytology. Almost half of the cases with only few tumor cells on cytology had either ITC or micrometastases. Of the cases with moderate and many tumor cells, 86% and 92% had macrometastases, respectively. Statistical analysis showed significant association between semiquantitation of tumor cells in intraoperative cytology and type of SLN nodal metastasis on permanent section ($p < 0.001$). Increasing number of tumor cells in intraoperative cytology smear was also associated with positive ALND ($p < 0.001$). **Conclusions:** Intraoperative cytologic evaluation of SLN with semiquantitation of tumor cells in positive smears may be helpful in predicting size of SLN metastasis. Further prospective studies may be needed to evaluate the utility of this finding to help further narrow the selection of patients who may need ALND.

242 Intraoperative Cytological Diagnosis of Oligodendrogliomas: Tumor Grade and Diagnostic Accuracy. A Study of 60 Cases

K Donev, OM Allassi, SR Kini, JA Gutierrez. Henry Ford Hospital, Detroit, MI.

Background: Oligodendrogliomas (OD) have a wide morphologic spectrum, which is manifested in intra operative (IO) cytological preparations and makes their histological and cytological diagnosis and grading difficult. Furthermore, there is uncertainty about the rate of accuracy of IO cytological diagnosis of these tumors. We searched for reliable cytological features for grading OD, and determined concordance between IO and final diagnosis of OD.

Design: We analyzed retrospectively (1997-2005) 60 OD that had IO cytologic preparations, imprints and/or smears stained with rapid H&E. The tumors had been graded accordingly to WHO criteria. Each case was evaluated blindly and semi quantitatively for nuclear atypia (low, intermediate, high), and presence/absence of abnormal vessels, mitoses, and minigemistocytes/gliofibrillary oligodendrocytes (MG/GFO). These data were then grouped according to each histological grade. We also determined the concordance between IO diagnosis by the authors (not the original neuropathologists) and the final histological diagnosis. A cytologic diagnosis was considered accurate when rendered as "OD" or "consistent with OD". Diagnoses of glioma, undifferentiated tumor, or other were not considered accurate.

Results: There were 36 GII and 13 GIII OD. There were 11 cases whose atypical features were not enough for upgrading, and were diagnosed as ODG with atypical features (GII intermediate). **1. The table displays the distribution of the cytological features for each histological grade:**

	NUCLEAR ATYPIA	MITOSES	ABNORMAL VESSELS	MG/GFO
GRADE II	18/36 low (50%), 18/36 int. (50%)	absent	12/36 (33%)	2/36 (5.5%)
GRADE II INT.	10/11 int (91%), 1/11 low (9%)	absent	7/11 (63%)	5/11 (45%)
GRADE III	6/13 high (46%)*, 5/13 int (38%), 2/13 low (15%)	3/13 (23%)**	5/13 (38%)	2/13 (15%)

[Table 1].

* p value <0.0001 ** p value <0.001 **2. The agreement between IO diagnosis and final diagnosis of OD (reviewers') for all tumor grades was 78% (47/60).** This accuracy rate was 77% for grade II, 72% for grade II intermediate, and 84% for grade III.

Conclusions: 1. GII OD were characterized by low nuclear atypia, GII intermediate ODG by absent mitoses and frequent GM/GFO and abnormal vessels, and GIII OD by high nuclear atypia and mitoses. 2. High nuclear grade and mitoses had a high predictive diagnostic value for anaplastic OD. Each of the other features had too much overlap between grades to be of diagnostic significance. 3. "Experts'" IO diagnostic accuracy of OD in this series was slightly over 3 out of 4 cases.

243 Prevalence of Cervical Premalignant Lesion in a Rural Nigerian Population

BS Duduyemi, TA Adegbola, J Ezeigwe, FB Abdulkareem, AF Banjo. University College Hospital, Ibadan, Nigeria; St James's Hospital, Dublin, Ireland; Lagos University Teaching Hospital, Lagos, Nigeria.

Background: Cervical cancer is the commonest malignancy and the commonest cause of cancer death among women in Nigeria. With the mounting campaign for introduction of screening program there is need to know the incidence and demographic pattern of the pre malignant lesion. The available data are mainly from hospital based studies, which are generally accepted to be unrepresentative of the true picture. Our objective was to determine the prevalence in the community and compare the figure with hospital based studies and result from other parts of the world.

Design: Cervical smears were collected using conventional Ayre's spatula from 156 women in a rural community of Lagos State of Nigeria and stained with Papanicolaou stains. The women were mobilised by public campaign and home visitation. A simple questionnaire was administered to obtain biosocial data relevant to risk for developing cervical cancer from the subjects.

Results: The ages and parity of the women range between 18 and 66 years (mean 32 years) and 0-12 (mean 3.4) respectively. Sixty-eight (43.6%) had first sexual contact before the age 18 (median 19 years). The number of sexual partner range from 1-10 (mean 2). Seventy-six (48.7%) have only 1 sexual partner and in most of those with more than one they were successive partners. The cytopathological diagnosis are: negative 149 (95.6%), low grade squamous intraepithelial neoplasia 5(3.2%), high grade squamous intraepithelial neoplasia 1(0.6%) and glandular lesion 1(0.6%). The prevalence of squamous intra-epithelial lesion between 20 and 30 years age group was 4.7% compares with the 3.2% of the study population. The woman with high-grade squamous intra-epithelial lesion was in the 4th decade of life, had sexual contact before the age of 18 and in addition multiple sexual partners. Four of those with low-grade lesion have sexual contact between the ages of 16 and 20 years and 2 of them have multiple sexual partners.

Conclusions: The findings are similar to the reported pattern elsewhere in the world and lower than the hospital based figures. We therefore concluded that the high rate of

cervical cancer in this population is due to lack of screening and make case for a concerted effort for institution of screening programme.

244 Cytology of Intraductal Papillary Mucinous Tumors (IPMT) of the Pancreas: Could We Do Better?

AF Durden, JL Carlo-Demovich, RS Hoda, BJ Hoffman, MM Fraig, Medica Univeristy of South Carolina, Chareleston, SC.

Background: IPMT, a rare group of pancreatic neoplasms, commonly present in the head of pancreas. They range from benign neoplasms causing ductal dilatation to malignant tumors associated with invasive adenocarcinoma. Various imaging modalities are used to detect these tumors early and numerous approaches are used to sample them; however, IPMT's remain a challenge to diagnose cytologically. We hereby present our experience with these tumors in the last 5 years.

Design: A search of our databases revealed 33 cases of surgically proven IPMT. All surgical and cytologic material was reviewed and correlated with clinical findings from the patients' charts and with ancillary studies that were performed. The cytologic material included specimens obtained by EUS FNA with and without on site adequacy assessment by cytology personnel, and by pancreatic duct brushings procured through ERCP.

Results: Three of the 33 cases were unsatisfactory for lack of cells. Of the remaining 30 cases, 7 were diagnosed cytologically as adenocarcinoma and 10 as mucinous cyst or as consistent with IPMT. Thirteen cases had benign or negative diagnoses without alluding to IPMT. Of those 13, 3 cases were later diagnosed with carcinoma on the surgical specimen, and the remaining 10 were found to have IPMT. Interestingly, mucin stain with PAS was positive in 5/7 cases. In all of the cases examined, the driving force for surgical intervention was a high suspicion for IPMT on imaging studies. However, in 5/33 cases, clinical suspicion was low and yet the cytology pointed to IPMT in 3/5 cases. In the remaining 2 cases, atypical cells on cytology led to the detection of adenocarcinoma on further biopsies. Aspirate fluid CEA levels were elevated in 8/8 cases. The most common cytological findings include thick mucin (18 cases) and macrophages (8 cases). Three dimensional clusters with fibrovascular cores were only evident in 8 cases.

Conclusions: Integration of clinical findings with ancillary studies is essential in improving the cytological diagnosis this entity. In the majority of cases where malignancy was present, cytological evaluation was accurate in the identification of malignant cells. The presence of thick mucin and macrophages should raise the suspicion for a mucinous cystic neoplasm, warranting further investigation. The identification of PAS-positive mucin and CEA on cyst aspirates may also aid in further detection of these tumors.

245 Internet-Based Gynecologic Telecytology with Remote Automated Image Selection: Results of a First-Phase Development Trial

JH Eichhorn, L Buckner, SB Buckner, DP Beech, BA Crothers, DC Wilbur, Massachusetts General Hospital, Boston, MA; Harvard Medical School, Boston, MA; Walter Reed Army Medical Center, Washington, DC; National Naval Medical Center, Bethesda, MD.

Background: The combination of liquid-based slide preparation, automated screening with field of view (FOV) selection, image capture, internet transmission, and remote interpretation of selected FOV's is a means to allow centralization of gynecologic cytology expertise and improve productivity.

Design: A retrospective set of gynecologic cytology slides (ThinPrep (TP)(Cytyc) and SurePath (SP)(TriPath)) with reference interpretations was run on an automated screening device (FocalPoint (TriPath)) that selects FOV's based on a hierarchical probability of abnormality being present. An interface between the device and a remote server with custom image review software (Consult (Wellovic)) was developed. FOV's were reviewed by 6 cytologists (3 CT, 3 MD) and general categorizations (unsatisfactory/normal, abnormal) and specific interpretations (Bethesda 2001) were rendered. No training prior to FOV review was performed. For this phase, results were tabulated based on correct general and specific categorizations versus the reference interpretation for each case and reported based on how many reviewers achieved the correct interpretation.

Results: 191 cases were included in the analysis (SP-101, TP-90; 99-NILM, 4-ASC-US, 3-ASC-H, 4-AGC, 63-LSIL, 18-HSIL). ≥ 3 reviewers agreed on the correct general categorization for unsatisfactory/normal in 87%, and for abnormal in 83%. For specific Bethesda interpretation, the frequencies at which ≥ 3 reviewers agreed on the correct categorization were as follows: ASC-US - 75%, ASC-H - 100%, AGC - 25%, LSIL - 83%, HSIL - 94%.

Conclusions: Based on comparisons to prior studies of manual screening of slides, the results of this study, in which no prior training was given to reviewers, suggest that this procedure has comparable sensitivity and specificity and would be an effective initial triage to further evaluation by means such as full manual screening, HPV testing, or colposcopy.

246 The Significance of "LSIL, Can Not Exclude HSIL (LSIL-H)" as a Distinct Squamous Abnormality Interpretation in Pap Tests

TM Elsheikh, JL Kirkpatrick, HH Wu, Ball Memorial Hospital, Muncie, IN.

Background: Early cytologic detection and treatment of High Grade Squamous Intraepithelial Lesion (HSIL) is critical to cervical cancer prevention. The terminology of Atypical squamous cells (ASC), can not exclude HSIL (ASC-H) was introduced by The Bethesda System (TBS) 2001, to define changes suggestive, but not diagnostic, of HSIL in the absence of unequivocal SIL. Studies have shown that women with ASC-H cytology are at an increased risk of harboring underlying histopathologic HSIL. TBS 2001, however, did not address the significance of finding ASC-H changes in a background of unequivocal low grade SIL (LSIL). There may be a tendency for cytologists

to lump these changes with either LSIL or HSIL, depending on their level of comfort. We have referred to these changes, in our laboratory, as "LSIL, can not exclude HSIL (LSIL-H)".

Design: All Pap tests, using ThinPrep technique, between July 2001 and July 2003 were retrieved from our computer data base. All categories of squamous cell abnormalities, including LSIL-H, were evaluated for their incidence and followup diagnoses of HSIL and more severe lesions (HSIL+). All cases had a minimum of 2 year followup, by biopsy and/or cytology (range 2-4 years).

Results: LSIL-H comprised 0.15 % (194 cases) of all Pap tests (129,911) evaluated during the study period. Followup (FU) biopsy was available on 59 patients (30.4%), which showed HSIL+ in 40.7% of cases. This rate of associated HSIL+ was significantly different from that of LSIL (13%, $p < 0.001$) and HSIL (74%, $p < 0.001$), but similar to ASC-H (44.6%).

	# (% of Total Paps)	FU Biopsy (%)	HSIL+ on Biopsy
ASC-US	4143 (3.19)	410 (10)	35 (8.5%)
ASC-H	308 (0.24)	110 (35.7)	49 (44.6%)
LSIL	2475 (1.91)	575 (23)	75 (13%)
LSIL-H	194 (0.15)	59 (30.4)	24 (40.7%)
HSIL	578 (0.44)	289 (50)	214 (74%)

Conclusions: This study shows that patients with cytologic diagnoses of LSIL-H have an intermediate risk of harboring histopathologic HSIL+. This risk is similar to ASC-H, but falls between the low risk associated with ACS-US and LSIL, and the high risk associated with HSIL cytologic diagnoses. We believe that LSIL-H should be considered as a cytologic diagnostic interpretation that is separate from LSIL, ASC-US, or HSIL. Although LSIL-H does not represent a unique biologic entity, it has clinical usefulness due to its high positive predictive value for HSIL+ lesions.

247 Cytologic Features of Autoimmune Chronic Pancreatitis

IA Eltoum, M Eloubeidi, DC Chheng, DN Jhala, NC Jhala, DR Crowe, S Varadarajulu, CM Wilcox, University of Alabama at Birmingham, Birmingham, AL.

Background: Autoimmune chronic pancreatitis (AIP) has recently been established as a subtype of chronic pancreatitis that mimics pancreatic neoplasm, but responds adequately to steroids. Thus in subjects suspected of having AIP, a relatively simple diagnostic method such as EUS-FNA averts the need for unnecessary surgery. However, the cytologic features of AIP have not been amply defined. In this study, we describe the cytologic features of autoimmune pancreatitis and discuss whether these findings aid in the diagnostic algorithm of AIP.

Design: We reviewed clinical, radiology and pathology databases searching for patients with AIP. Patients were included in the study if presented with radiological evidence of AIP and had elevated IgG4 or if pancreatic resection or laparoscopic biopsy demonstrated the diagnostic histological features of AIP. All EUS-FNA were reviewed looking for cytologic features that correspond to the known histological features of AIP.

Results: We identified nine patients with AIP, representing 1.4 % (9/650) of patients presented with pancreatic mass/enlargement during the period 7/2000 to 7/2005, mean age (SD) 66 (13.3) yrs and male:female ratio 2:1. In addition to having pancreatic mass, 6 patients had jaundice and 3 had abdominal pain. In 3 patients an elevated level of IgG4 subclass (ranging 232 to 627 mg/dL) supported the diagnosis of AIP. In the remainder six patients, AIP was diagnosed by histologic evaluation of resected or laparoscopic specimens. To exclude neoplasms, EUS-FNA was performed in all 9 patients. EUS-FNA showed fibro-inflammatory tissue fragments in all EUS-FNA. Unsurprisingly, periductal localization of this process on cytologic preparation was demonstrated unequivocally in only one case. Moderate to intense lymphoplasmacytic infiltration was present in 4 cases, venulitis in one case, lymphocytic exocytosis in two cases and granulocytic endothelial lesions in on case. Neoplasms, calcific debris, autodigestive material was not detected in all 9 cases.

Conclusions: Although fibro-inflammatory process and/or moderate to intense lymphocytic infiltrate was present in all cases, the periductal localization of these features, the conclusive diagnostic findings of AIP, were difficult to demonstrate on cytologic smear. Nonetheless, cytoanalysis demonstrates the absence of neoplasm and in the appropriate clinical and radiological context, provides supportive evidence for the diagnosis of AIP.

248 HPV Integration in Abnormal Cervical Cytological Samples Demonstrated by Multiple Displacement Amplification and Southern Blot Hybridization

MF Evans, CS-C Adamson, K Cooper, University of Vermont College of Medicine, Burlington, VT.

Background: Human papillomavirus (HPV) integration into the cell genome is considered a critical step in the progression of cervical neoplasia to invasive disease. However, the investigation of HPV physical status is problematic. Integration assay by Southern blot hybridization analysis of restriction endonuclease fragment patterns has been limited by the requirement for large quantities of high molecular weight DNA. This has been a particular problem for the study of integration in pre-invasive tissues where fresh tissue samples may be unavailable for experimental analysis because of clinical diagnostic requirements. Multiple displacement amplification (MDA) is a technique that supports high-fidelity whole genome DNA amplification, yielding $>40\mu\text{g}$ DNA from $<100\text{ng}$ template. In control tests, we have previously shown equivalence of Southern blot data from cell lines containing integrated HPV with data obtained from MDA product of the cell lines. In this study, MDA has been used to investigate HPV integration in DNA extracts from cervical scrape samples.

Design: DNA from forty-five abnormal cervical cytological samples that tested HPV-16 positive by General-Primer mediated PCR and which had biopsy follow-up were identified. Following MDA, samples were restriction digested with *Hind III* (zero cutter), *BamH I* (1X cutter), *Stu I* (1X cutter), and *Kpn I* (2X cutter) and after gel

electrophoresis and Southern Transfer hybridized with radiolabeled-probe. Fragment patterns that deviated from those predicted for episomal HPV were interpreted as evidence of integration.

Results: Integration was recorded for 0 of 7 ASC-US, 0 of 5 LSIL, 3 (18%) of 17 ASC-H, and 3 (19%) of 16 HSIL samples ($P>0.2$). Integration was recorded for 2 (9.5%) of 21 cytologic samples from patients with subsequent biopsies diagnoses of benign changes, 0 of 2 samples preceding CIN-I, and 4 (18%) of 22 samples preceding CIN-II/III ($P>0.4$).

Conclusions: This study demonstrates for the first time that MDA product from cytological specimens can be used to investigate HPV integration. The detection of integration in samples preceding a biopsy diagnosis of benign changes suggests HPV integration may not be a marker for (irreversible) lesion persistence/progression. However, follow-up is required for patients with benign biopsy diagnoses to exclude the possibility of an occult lesion at the initial colposcopic examination.

249 The Cytologic Diagnosis of Medullary Thyroid Carcinoma on Fine Needle Aspiration Biopsy Processed by Thin-Layer Cytology

G Fadda, ED Rossi, A Miraglia, A Mule', GF Zannoni, C Minimo, FM Vecchio. Catholic University, Rome, Italy; Lankenau Hospital, Philadelphia, PA.

Background: Fine Needle Aspiration Biopsy (FNAB) represents the most important tool in the diagnostic evaluation of the thyroid lesions, mostly in the discrimination between malignant and benign lesions. However, the diagnosis of medullary thyroid carcinoma (MTC) may present some additional problems related to its deceptive morphologic picture. This diagnosis may be confirmed by the immunocytochemistry (ICC) which may be difficult to be carried out on the conventional smears (CS). The efficacy of the ICC carried out on the slides processed by thin-layer cytology (TLC) for the preoperative diagnosis of MTC is evaluated.

Design: In the period January 2001- September 2005, out of 188 FNAB with a diagnosis of carcinoma, 15 (7.9%) resulted as MTC. The samples were processed with both CS and TLC methods. CS were fixed in ethanol whereas TLC slides were processed with the Thin Prep 2000™ method (Cytoc Co., Marlborough, MA). All slides were stained with Papanicolaou. ICC for calcitonin, monoclonal CEA and thyroglobulin were carried out only on TLC slides in all cases. The series included 13 thyroid neoplasms and 2 cervical nodal metastases. Six cases showed elevated calcitonin levels, 2 cases were associated respectively with MEN 2A and 2B and one case presented a familiar history of MTC.

Results: All 15 cytological cases had a ICC study on the TLC slides. In all cases calcitonin and mCEA resulted strongly positive whereas thyroglobulin was not expressed in the neoplastic cells. Nine out of the 13 thyroid carcinomas (69.2%) and both the lymph node metastases underwent surgery and the diagnoses were morphologically and immunohistochemically confirmed.

Conclusions: ICC can be successfully applied on TLC slides, mostly when a neoplastic lesion is preoperatively suspected. The combined results of morphology and ICC is decisive for a correct cytologic diagnosis of MTC on FNAB.

250 Clinical Outcomes of Perimenopausal and Postmenopausal Women with High Risk HPV DNA Positive ASC-US Interpretation: A Retrospective 2 Year Follow-Up Study

J Feng, H Salimnia, S Bandyopadhyay, MA Al-Abbadi, M Husain. Detroit Medical Center, Wayne State University School of Medicine, Detroit, MI; Detroit Medical Center, Detroit, MI.

Background: Reflex testing for high risk HPV DNA by Hybrid capture2 for ASC-US Pap test has become common practice. This practice is based on results of ASCUS-LSIL Triage Study (ALTS), in which about 27 percent of young women (median age 27) with high risk HPV DNA positive ASC-US interpretation had biopsy confirmed CIN 2,3 at initial colposcopy or detected during 2 year follow-up. Epidemiological studies have shown that the median age for CIN3 is around 30 years which develops generally 10 years after initial exposure to oncogenic HPV. Prevalence of HPV DNA in peri- and postmenopausal women has not been well publicized. The purpose of this study to benchmark the risk of development of High Grade SIL / CIN 2,3 in women 45 or older served by our laboratory during 2 year follow up period.

Design: A total 4199 ThinPrep cervical cytology with ASCUS interpretation from January 2002 to December 2003 were retrieved from our database. Among them, 2075 cases (49.4%) were positive for high risk HPV DNA. 191 of 752 (25.4%) peri and postmenopausal women (PM) defined as 45 years or older were positive for high risk HPV DNA. 136 PM women (2002 and 2003) and 463 premenopausal women (44 years old or younger) from 2002 with follow up information were included in the study. The follow up results were categorized into four groups: negative, LGSIL cytology/ CIN1 histology (including repeat ASCUS or positive high risk HPV DNA test), HGSIL cytology /CIN2,3 or worse. Any HGSIL cytology /CIN2-3 or worse biopsy diagnosis was defined as end point of follow up. For remaining women, the results of last follow up were recorded.

Results: The follow up results in these two groups of women are shown in the table 1. The risk of detection of HGSIL/CIN2,3 or worse was significant lower in PM women than that in 44 years or younger group during two year study period. A squamous cell carcinoma was seen in an PM woman.

	Negative	LGSIL/CIN1	HGSIL/CIN2,3	Squamous Ca.
Women <45 (n=463)	257 (55.5%)	157 (33.9%)	49 (10.6%)	0
Women >=45 (n=136)	89 (65.4%)	42 (30.9%)	4(2.94%)	1(0.74%)

Conclusions: Our study showed that 45 years or older (PM) women with HPV positive ASCUS cervical cytology have a lower risk (3.6%) of detection of HSIL/CIN2,3 or worse at initial colposcopy or during two-year follow up period as compared to age 44 or younger women who had a cumulative risk of 10.6%.

251 High Quality Cell Blocks Frequently Allow Diagnosis of Invasion, or Histological Classification of Proliferative Changes in Breast FNAs

AH Fischer, S Istvanic, A Larkin, A Khan. UMass Memorial Health Center, Worcester, MA.

Background: FNA of the breast has many advantages compared to core biopsies, especially decreased morbidity and increased speed. A major limitation is inability to determine whether a cancer is invasive. Classification of proliferative breast lesions is also more difficult by FNA, and cytologic criteria have not generally provided as good a measure of breast cancer risk as the histological classification of ductal hyperplasia. We reasoned that high quality cell blocks could help overcome these limitations.

Design: Since January 2005, the residual needle rinses from breast FNA's (after preparation of smears or monolayers) have been processed at UMASS by a new "rapid cell block" technique that efficiently places tissue fragments at the plane in which a microtome captures histologic sections. 41 consecutive FNA's with rapid cell blocks have had surgical follow-up, with 26 follow-up diagnoses of cancer, and 15 surgical diagnoses of benign or hyperplastic lesions.

Results: Of 26 cancers, carcinoma was diagnosed in 24 FNA's, and of these, unequivocal histologic invasion was identified in the cell blocks in 11 (42%). One case with insufficient cells in monolayer and cell block sections was a lobular carcinoma on resection, and one case diagnosed on cell block as suspicious for cystosarcoma phyllodes was surgically confirmed as such. Lobular neoplasia (LCIS vs ALH) was clearly identifiable in 2 cases. 12 of 15 breast FNA's without carcinoma were able to be assigned a histologic diagnosis of no hyperplasia (1 case, confirmed in a biopsy) and usual hyperplasia (11 cases; 3 cases had insufficient cells for histologic grading of the cell block). The surgical biopsies corresponding to the eleven cases with usual hyperplasia reported no hyperplasia (one case), usual hyperplasia (7 cases), and atypical ductal hyperplasia (3 cases). Specific diagnoses of intraductal papilloma were rendered in 2 FNAs and confirmed in resections.

Conclusions: Histologic evaluation of efficient cell blocks overcomes major limitations of breast FNA. These data also suggest that random periareolar FNA processed with rapid cell blocks could provide a quick, safe and accurate assessment of breast cancer risk.

252 Efficient Technique for Making Paraffin-Embedded "Rapid Cell Blocks" in 12 Minutes

AH Fischer, H Vartanian, BJ Hanc, MP Scott, DM Eaton, NC Fischer, BA Woda. University of Massachusetts, Worcester, MA; Littleton, MA; Stow, MA.

Background: Sections from paraffin embedded cell blocks provide architectural diagnostic criteria that complement the criteria evident in smears or monolayers, and they provide a useful platform for emerging diagnostic techniques. Current cell block techniques require several hours of processing and do not show a substantial proportion of embedded cells in any one 5 micron section. Current techniques are also susceptible to cross-contamination and do not permit complete standardization of processing conditions.

Design: A patented modified tissue cassette and apparatus was designed to capture cells and tissue fragments on a 13 mm diameter circular polycarbonate filter with 12 micron pores. The filter is positioned below the tissue cassette at the plane where a microtome will eventually capture a section. After trapping a sample on the filter, fresh 100% isopropyl alcohol, xylene, and melted paraffin flow sequentially through the sample. The filter is heated and cooled with a Pelletier heater. When the wax hardens, the filter is peeled away, leaving typically a 200-400 micron thick disk of cells embedded in the wax. The processing time, cell yield, preservation, and diagnostic accuracy were compared to the collodion bag technique.

Results: 12 minutes is sufficient for paraffin infiltration such that FNA samples obtained with 18 gauge or smaller needles can be cut into smooth 5 micron ribbons that show crisp cellular preservation comparable to alcohol-fixed smears. To compare cell yield and diagnostic accuracy, excess material from 12 cytology samples were split into equal amounts and processed by the collodion bag technique and the new technique. Two pathologists scored the slides and in 11 of 12 cases, cell yield was considerably greater with the new technique, and with the same or better morphology. The increased cellular yield allowed one definitive diagnosis of carcinoma and one diagnosis of suspicious for carcinoma in two cases for which the collodion bag cell blocks were both negative, and the original monolayer slides from the case were negative and atypical, respectively. Processing conditions can be standardized and the chance of contamination eliminated. Immunohistochemical staining results have been appropriate for 40 antibodies tested to date. More than 500 diagnostic clinical samples have been processed at UMASS since January 2005.

Conclusions: Rapid cell blocks offer considerable advantages over existing cell block techniques.

253 Diffuse Large B-Cell Lymphoma: Accuracy of FNA Diagnosis with Implications for Patient Management

RL Flesherman, PE Wakely, Jr. The Ohio State University College of Medicine, Columbus, OH.

Background: Although studies exist documenting the diagnostic reliability of FNA for malignant lymphoma (ML), this notion continues to be resisted by hematopathologists and most oncologists. Diffuse large B-cell lymphoma (DLBL) is the most common form of adult ML worldwide. Because of this, we wanted to determine whether FNA cytopathology combined with ancillary immunophenotyping (IP) is capable of an accurate diagnosis of DLBL without the need for confirmatory tissue examination.

Design: We reviewed our files for all cases where an outright cytologic diagnosis of DLBL was made. We also searched for cases where a tissue diagnosis of DLBL was preceded by an FNA from the same site, but a less than definitive cytologic diagnosis of DLBL was rendered.

Results: Sixty-seven cases were found that met these criteria. There were 39 men and 28 women (M:F=1.4:1); ages ranged from 25 to 92 yrs. (x=61.4 yrs). Aspirates were from lymph node (30), soft tissue (13), parotid gland (7), thyroid (6), mediastinum (4), lung (2), and 1 each from the adrenal gland, breast, scalp, soft palate, and clavicle. 50/67 (75%) patients had a specific FNA diagnosis of DLBL [72% primary, 28% recurrent lymphoma] of which 30 (60%) were confirmed histologically. One example of blastoid variant, mantle cell lymphoma was misdiagnosed as DLBL. 17/19 cases with no tissue specimen showed supportive light chain restriction by IP, 9 of these were recurrent lymphomas, 4 responded to chemotherapy without a tissue specimen, and 4 were lost to follow-up. 2/19 cases with no IP or tissue specimen did, however, have a prior diagnosis of DLBL and were diagnosed as such by cytomorphology alone. Seventeen tissue cases of DLBL preceded by a less than specific FNA diagnosis were signed out as: malignant neoplasm (1), atypical lymphoid infiltrate (7), malignant lymphoma (2), large cell lymphoma (6), and suspicious for DLBL (1). Reasons for a less than definitive FNA diagnosis in this subset included: unsuccessful IP by flow cytometry (13) and no cells submitted for IP (4).

Conclusions: An accurate diagnosis of DLBL was possible in 45/46 (98%) DLBL cases with clinical or histologic follow-up. In contrast to recent reports, an FNA diagnosis of DLBL is clinically useful and accurate. The major impediment to a specific cytologic diagnosis of DLBL is a lack of confirmatory IP.

254 FNA Biopsy of High Grade Sarcoma with Emphasis on Neoadjuvant Chemotherapy

RL Fleshman, J Mayerson, PE Wakely, Jr. The Ohio State University, Columbus, OH. **Background:** Few studies exist demonstrating the diagnostic reliability of fine-needle aspiration (FNA) biopsy for high-grade sarcomas (HGS). Because of this, many clinicians resist the idea of requesting FNA when a sarcoma is clinically suspected, let alone permit management based solely on such a diagnosis. Our aim is to test the hypothesis that FNA cytopathology is capable of an accurate diagnosis of HGS. A corollary to this is that an FNA diagnosis of HGS is sufficient to administer neoadjuvant chemotherapy in select individuals.

Design: A review of our files from the past 3 years (10/2002 – 8/2005) was made to identify all FNA cases signed out unequivocally as HGS. This included all cases diagnosed as pleomorphic sarcoma, or a specific sarcoma that by definition is high grade, and to determine outcome based on clinical or histological data.

Results: 48 patients (28 men and 20 women; M:F ratio of 1.4:1) ranging from 15 to 90 years of age (x = 55.9 yrs) had a cytologic diagnosis of HGS. Of these, 29 (60%) were primary diagnoses, 14 were from recurrent lesions, and 5 were metastatic lesions. Locations included: lower extremity (26), upper extremity (10), trunk (6), groin (3), and head and neck (3). 44 (91.7%) aspirates had a subsequent surgical procedure. Tissue diagnoses were HGS in 41 of 44 cases. Two cases originally diagnosed as HGS were determined to be low-grade spindle cell sarcomas after excision. One case originally diagnosed as a malignant peripheral nerve sheath tumor was diagnosed as high-grade epithelial neoplasm histologically. Tissue specimens included 26 wide excisions/radical resections, 11 amputations, 6 marginal resections/excisional biopsy, and 1 incisional biopsy. Four (8.3%) aspirates without surgical follow-up were included because the FNA diagnosis was confirmed by comparing the FNA with prior tissue specimens (2), and 2 cases of Ewing sarcoma demonstrated diagnostic translocations by FISH staining of aspirated cells. 7/9 patients receiving neoadjuvant chemotherapy based on FNA diagnosis alone had subsequent tissue that confirmed the FNA diagnosis. Of the remaining 2 chemotherapy-treated individuals only necrotic sarcoma was found in the resected specimen of one patient, and one patient had no subsequent tissue specimen.

Conclusions: A cytopathologic diagnosis of HGS is highly accurate. In the correct clinical setting tissue biopsy is not required to confirm an FNA diagnosis of HGS in order for patients to receive neoadjuvant chemotherapy.

255 The Use of P63 as a Diagnostic Tool in PAP Smears

M Garcia, BC Acar, M Jorda, C Gomez-Fernandez, P Ganjei-Azar. University of Miami, Miami, FL.

Background: Differentiating primary glandular from high-grade squamous lesions involving endocervical glands is not an uncommon diagnostic problem in liquid based gynecological cytology. Both squamous and atypical glandular cell lesions may show similar cytomorphologic features. The aim of this study is to evaluate the use of P63 immunocytochemistry in this differential diagnosis.

Design: Of 50,128 liquid based smears collected over a 2-year-period, 186 (0.37%) were diagnosed as atypical glandular cells of undetermined significance (AGUS) or adenocarcinoma. On histological follow-up, ten cases (6 AGUS and 4 adenocarcinomas) were high-grade squamous intraepithelial lesions (HGSIL) and the remaining cases represented glandular pathology. The abnormal groups of the 10 discrepant cases were etched with diamond pen. We performed immunocytochemistry using the monoclonal P63 antibody (Dako, 1:50, mouse) with the L- SAB detection system (Dako cytometry, Carpinteria California). In addition, we stained 14 control cases (4 adenocarcinomas, 3 HGSIL and 7 negative PAP smears, including atrophic samples).

Results: In all ten discrepant cases, the abnormal groups showed a homogeneous strong nuclear staining for P63. Control slides demonstrated that the nuclei of isolated HGSIL cells and basal cells from atrophic smears were also positive for P63. On the other hand, all benign and malignant glandular cells were uniformly negative. Isolated metaplastic, intermediate and superficial cells were likewise negative for this antibody.

Conclusions: P63 immunostain appears to be useful in differentiating primary glandular pathology from HGSIL. It also detects isolated HGSIL cells ("litigation cells"). This antibody is not helpful in the distinction between AGUS, adenocarcinoma or normal glandular cells. P63 stains basal cells and this may be a diagnostic pitfall in atrophic smears.

256 BK Virus Nephropathy in Renal Transplants Patients. The Role of Urine Cytology, Quantitative PCR, and Electron Microscopy

S Girgis, L PANG, S Cockfield, J Preiksaitis. University of Alberta Hospital, Edmonton, AB, Canada.

Background: BK virus (BKV) is recognized as a cause of failure of renal allografts. Non-invasive diagnostic modalities using urine/blood specimens can be utilized to make this diagnosis. Routine urine cytologic (UC) examination, quantitative PCR, and Electron microscopy (EM) can be utilized effectively to identify this disease.

Design: A total of 256 urine/blood specimens were collected from a prospective cohort of 99 renal transplant patients (43 F, 56 M, range: 3 – 74 years) over a one-year period. UC examination, EM, and quantitative PCR assays were performed on urine and plasma specimens. The presence of decoy cells was reported as positive for BK virus. The presence of increased numbers of renal tubular cells and inflammatory cells was also reported. EM was reported positive if sufficient numbers of cells showed the typical morphologic features. Quantitative PCR assay were reported as viral DNA copies/ml. Renal biopsies results (within six months of urine/blood collection) were available in 10 positive PCR cases.

Results: Quantitative PCR on urine was positive in 50 specimens (28 specimens with $> 10^7$ copies/ml PCR-H, and 22 specimens with $< 10^7$ copies/ml PCR-L). The cut off value of $> 10^7$ copies/ml in urine specimens was selected since no corresponding plasma positive results (clinical threshold level for management) were detected in any of the PCR-L specimens. Seven specimens were positive by all three tests and 2/7 cases had positive renal biopsy results. An additional 17 cases were positive for UC and PCR-H, but negative for EM. Four cases were reported negative by UC but were positive for PCR-H (False negative). Three cases reported positive by UC were negative for PCR (false positive). Two cases were reported suspicious by urine cytology were negative by PCR. All positive PCR-L cases were negative by UC and EM. Three negative renal biopsies were obtained from positive UC/ PCR-H. Five negative renal biopsies were obtained from negative UC/ positive PCR-L.

Conclusions: UC has a definite role in identifying patients with BK viral nephropathy. By using a cut off value for quantitative PCR at $> 10^7$ copies/ml (PCR-H), UC has positively identified 24/28 cases with a sensitivity of 89% and specificity 98%. The vast majority of these cases showed numerous renal tubular cells in keeping with BK virus associated renal tubular cell damage.

Cases	Cases	Cases	UC (n = 256)	Quantitative PCR (n = 243)	EM studies (n = 252)	Positive Renal biopsy (n=2)
7	7	7	+	+	+	2
17	17	17	+	+	-	
3	3	3	+	-	-	
4	4	4	-	+	-	
2	2	2	Suspicious	-	-	

257 Granulomatous Inflammation in Cytopathology: A Review of 154 Cases

LK Green. Houston VAMC and Baylor College of Medicine, Houston, TX.

Background: The diagnosis of granulomatous inflammation can be difficult on specimens from exfoliative cytology and fine needle aspiration (FNA) cytology. The etiologies may be infectious, related to sarcoidosis or found in association with malignancies. The characteristic clusters of epithelioid histiocytes may be subtle and missed or misdiagnosed as malignancies.

Design: All cytology specimens with granulomatous inflammation for the last 15 years were reviewed and the patient characteristics, cultures, subsequent histology or autopsy and all associated special stains were compiled and compared.

Results: There were 154 cases identified with clusters of epithelioid histiocytes on smears and/or in cell block material. Cell blocks were prepared in all washings and fine needle aspirations (FNAs). There were 5 females and 149 males from age 23-81 years. There were 23/154 patients with HIV. There were 80 lymph node FNAs (superficial or Wang-needle) (30 mediastinal, 30 cervical, 8 inguinal, 5 supraclavicular, 4 axillary and 3 other locations) and 54 pulmonary specimens (39 bronchial brush/washes, 12 transthoracic lung FNAs and 3 Wang-needle FNAs). Other FNA specimens included: 6 salivary, 3 soft tissue, 2 liver and 1 thyroid gland. Special stains for organisms (AFB, GMS, Warthin-Starry and PAS) were performed. A possible or definitive etiology was determined in 69% (37 Sarcoidosis, 21 M. tuberculosis, 11 Mycobacterium avium, 7 fungal, 8 "Cat scratch", 15 associated with malignancies, 4 rheumatoid arthritis and 2 ulcerative colitis).

Conclusions: The presence of single and three-dimensional clusters of epithelioid histiocytes with or without associated necrosis on cytology specimens can be diagnosed as granulomatous disease. When cell blocking techniques are used with special stains for detection of infectious etiologies a definitive diagnosis can be made on cytology alone. The diagnosis of sarcoidosis can be made in mediastinal lymph nodes or other lymph node groups and excisional biopsy can be avoided. Granulomatous inflammation in lymph nodes can be seen in lymph nodes draining malignancies and clinical suspicion should be used to direct further tissue diagnosis. In conclusion, cytology alone can be a sensitive method for the diagnosis of granulomatous diseases.

258 Atypical Cytologic Features in Pap Smears with Candida Should Not Be Entirely Attributed to Reactive Cellular Changes

JM Hall, AC Bush, BS Kendall. Wilford Hall Medical Center, Lackland AFB, TX.

Background: General cytology teaching is that the presence of infectious organisms, such as *Candida*, may cause reactive cellular changes in cervicovaginal (Pap) smears that can mimic dysplasia. Therefore, when *Candida* is present, a higher threshold may be set for making a diagnosis of atypia (ASC-US). Although it has been shown that the use of various cytomorphologic criteria are helpful in trying to make this distinction, investigation into the validity of this practice is required.

Design: A computerized search of cytology reports was performed to find Pap smears diagnosed with both ASC-US and *Candida* within a 19 month time period (June 2002-Dec 2003). During this time period reflex high-risk(hr)-HPV testing (HPV DNA Test @, Digene®) was routinely performed on residual ThinPrep specimens. Results, including age and hr-HPV results, were recorded. The hr-HPV rate for ASC-US with *Candida* was compared to our laboratory's overall hr-HPV rate during this same time period. Both the overall rates and rates amongst 5-year age groupings were compared. **Results:** A total of 309 specimens received a diagnosis of ASC-US with *Candida* and had hr-HPV test results available. A summary of the results is shown in Table 1. There was a significantly higher overall rate of hr-HPV detection for specimens diagnosed as ASC-US with *Candida* (44.7%, p<0.001) compared to the overall hr-HPV rate (34.1%). When age stratified, the ASC-US with *Candida* <= 20 and 21-25 age groups (58% of the 309 cases) both had significantly higher rates of hr-HPV detection (65.0% vs. 58.5%, p<0.001 and 61.6% vs. 50.5%, p<0.04 respectively). **Conclusions:** We found a significantly higher rate of hr-HPV detection in specimens diagnosed as ASC-US with *Candida* compared to the overall laboratory hr-HPV rate. It is possible that this higher rate results from the use of a higher threshold for diagnosing atypia (ASC-US) and/or dysplasia (LGSIL) in the presence of *Candida*. This study shows that the presence of *Candida* does not exclude hr-HPV and that atypical cytologic features in the presence of *Candida* should not be entirely attributed to reactive or inflammatory cellular changes, especially in younger women.

Table 1. High Risk-HPV Positivity for ASC-US with *Candida* Compared to the Overall hr-HPV Rate.

Age	High Risk-HPV for ASC-US with <i>Candida</i>			Overall High Risk-HPV for ASC-US				p<0.001
	hr-HPV Pos	hr-HPV Neg	Total %Pos	hr-HPV Pos	hr-HPV Neg	Total %Pos		
<=20	52	28	80 65.0%	442	1054	1496 58.5%		
21-25	61	38	99 61.6%	908	891	1800 50.5%		
26-30	16	16	32 50.0%	385	664	1049 36.7%		NS
31-35	3	18	21 14.3%	207	621	828 25.0%		NS
36-40	3	28	31 9.7%	138	709	847 16.3%		NS
41-45	1	14	15 8.7%	84	552	636 13.0%		NS
46-50	0	14	14 0.0%	62	400	462 13.4%		NS
51-55	1	7	8 12.5%	40	212	252 15.9%		NS
56-60	1	3	4 25.0%	20	149	169 11.8%		NS
>60	0	5	5 0.0%	34	183	217 15.7%		NS
Total	138	171	309 44.7%	2501	4833	7334 34.1%		p<0.001

NS (Not Significant)

259 ASC-US on Pap Test with Reflex HPV Test in Teenagers and Young Women (20-35): A Comparative Study with Follow-Up

RS Hoda, EM Nunnery, SL Czarsky, PM Houser, MM Fraig, Medical University of South Carolina, Charleston, SC.

Background: Reflex HPV test (RHPVT) is the preferred management option for patients with atypical squamous cells of undetermined significance (ASC-US) on Pap test (Pap). Data regarding RHPVT for high-risk (HR) subtypes in teenagers (TA) versus young women (YW, age 20-35) is scant.

Design: Retrospectively reviewed were 4-year (06/01-05/05) data on TA and YW with ASC-US on Pap and subsequent RHPVT-HR (Hybrid Capture II test, Digene Corp, Gaithersburg, MA) performed on residual PreservCyt (Cytoc Corp, Malborough, MA). Equivocal (eqv) RHPVT-HR results were excluded. Cases with follow-up (f/u) biopsy (bx) or Pap within 6 months of ASC-US on Pap were further analyzed.

Results: Results of 661 RHPVT-HR on the study population were reviewed. 136/661 RHPVT-HR were performed in TA, 43 of whom (31.6%) had an ASC-US on Pap. In this group RHPVT-HR was: positive (+), 33 (76.7%); negative (-), 8 (18.6%); eqv, 2 (4.6%). For TA with (+) RHPVT-HR, f/u consisted of: bx, 11; repeat Pap, 16; and in TA with (-) RHPVT-HR f/u, there were only three repeat Pap. 525/661 RHPVT-HR were performed in YW, 248 of whom (47.2%) had an ASC-US on Pap. In this group, RHPVT-HR was: (+), 132 (53.2%); (-), 111 (44.7%); eqv, 5 (2%). For YW with (+) RHPVT-HR, f/u consisted of: bx, 77; repeat Pap, 51; and for YW (-) for RHPVT-HR, f/u was: bx, 4; repeat Pap, 17. Table 1 shows f/u.

HR- RHPVT	RHPVT-HR and F/U Results for Teenagers and Young Women							
	Bx- Benign	Bx- LSIL	Bx- HSIL	Pap- Neg	Pap- ASCUS	Pap- LSIL	Pap- HSIL	
TA (+)	6 (55%)	3 (27%)	2 (18%)	9 (56%)	4 (25%)	2 (13%)	1 (6%)	
TA (-)	0	0	0	3 (100%)	0	0	0	
YW (+)	45 (58%)	21 (27%)	11 (14%)	24 (47%)	14 (28%)	11 (22%)	2 (4%)	
YW (-)	3 (75%)	1 (25%)	0	13 (77%)	4 (24%)	0	0	

On bx f/u, SIL (LSIL+HSIL/CIN I-III) rate was 45% in TA and 41% in YW. On cytology f/u, non-negative (ASCUS+LSIL+HSIL) rate was 44% in TA, and 53% in YW.

Conclusions: In this study, RHPVT-HR positivity was greater in teenagers than in young women (76.7% vs 53.2%, p: 0.002). The morphologically significant changes were relatively more common in teenagers than in young women in biopsy (45% vs 41%) and less common in Pap (44% vs 53%). These findings, if confirmed, may have screening and therapeutic implications.

260 Comparative Study of HIV-Infected Patients with Pneumocystis Carinii Pneumonia in Relationship to Viral Load Levels and CD4-Blood Cell Counts. A Study of 142 Cases

IS Hong, J Marshalleck, W Frederick, Howard University Hospital, Coll Med HU, Washington, DC.

Background: Pneumocystis carinii pneumonia (PCP) remains the most common serious opportunistic pulmonary infection in the human immunodeficiency virus (HIV) infected patients. The plasma viral load levels and CD4-blood cell counts are used to predict progression of disease in early infection. However, their significance in late disease is uncertain.

Design: The bronchoalveolar lavage (BAL) specimens from 142 patients were evaluated with direct smears and cell block preparation. The study population was

divided into three groups: positive, negative, and unsatisfactory for PCP determination. The patients' clinical records were reviewed to obtain HIV-viral load levels, CD4-blood cell counts, and the status of prophylactic therapy.

Results: Of the 142 patients, 33 (23.3%) were positive for PCP, 83 (58.4%) were negative for PCP, and 26 (17.4%) were unsatisfactory for evaluation. The mean viral load levels for the three groups were 381,076 copies/mL in the patients with positive PCP, 562,811 copies/mL in the patients with negative PCP, and 375,200 copies/mL in the patients with unsatisfactory for PCP-determination. The mean CD4+ blood cell counts were 81 cells/mm³ in the patients with positive PCP, 226.75 cells in the patients with negative PCP, and 152.25 cells in the patients with unsatisfactory for PCP-determination. All 142 patients had prophylactic treatments.

Conclusions: Our study revealed that recognition of PCP is not directly related to the status of viral load levels or CD4-blood cell counts. PCP-determination is an independent prognostic indicator to predict progression of disease. At the present, the triple measurements (PCP, CD4-cell counts, and viral load assay) are the most reliable and reproducible indicators to determine prognosis and management of HIV-infected patients.

261 Centrosome Defects Are Present in High Grade Squamous Intraepithelial Lesions in Pap Tests

S Istvanic, M Zhongming, C Powers, S Daxsey, AH Fischer, UMass Memorial Health Center, Worcester, MA; University of Massachusetts Medical School, Worcester, MA.

Background: Centrosomes form the two poles of the mitotic spindle and are essential for normal chromosome segregation. Alteration of the number and/or morphology of centrosomes correlate strongly with aneuploidy, and these abnormalities have been observed in many human epithelial dysplasias and carcinomas, including surgical biopsies of cervical dysplasias. Centrosomes have not been studied in Pap tests. We developed a method to study centrosomes while preserving morphology in cytologic samples and applied it to ThinPrep pap tests to see if centrosomes abnormalities could provide an objective marker for high grade squamous intraepithelial lesions (HSIL).

Design: ThinPrep pap slides fixed in the usual manner in 95% alcohol were post-fixed for 10 minutes at room temperature in 10% zinc-buffered formalin. The slides were subjected to antigen retrieval with citrate and EDTA and immunostained with a rabbit polyclonal anti-pericentrin antibody (developed by S.D.) at 1:2000 dilution with diaminobenzidine development. Slides were counterstained with a Papanicolaou stain. A case was scored positive for centrosome abnormalities if any definite HSIL cell showed three or more centrosomes. Normal endocervical cells and histiocytes served as internal positive staining controls. As a rigorous negative control, 16 cytologically negative Pap tests that were negative by Digene HC2 for high risk HPV were immunostained and a case was scored positive if ANY cell in the entire slide showed more than 2 centrosomes.

Results: Centrosome defects were found in 13/20 (63%) of HGSIL cases. Defects included increased number and abnormal size, and some cells appeared to show an increased diffuse fine punctate cytoplasmic staining. Morphologic preservation was excellent. Centrosome defects were scored in only 5/16 (31.3%, p<.06) normal Pap tests, and in only rare cells per slide in which they could have represented overlapping cytoplasm or stain precipitate. Centrosomes were not observed in superficial cells, intermediate cells, or squamous metaplasia, but normal centrosomes were seen in parabasal cells.

Conclusions: This is the first demonstration of centrosome defects in liquid based Pap tests. Studies are underway to determine whether centrosome defects complement other objective markers of HGSIL in Pap tests, and whether the presence of centrosome defects predicts an aggressive, rapidly evolving subset of precursor lesions to cervical cancer.

262 Can Renal Oncocytomas Be Distinguished from Chromophobe Renal Cell Carcinomas on Fine Needle Aspiration Specimens?

P Iyengar, H Al-Ahmadie, VE Reuter, S Olagac, O Lin, Memorial Sloan-Kettering Cancer Center, New York, NY.

Background: The role of fine needle aspiration (FNA) of renal cortical lesions was controversial in the past as the result did not affect clinical management. However, with the recent advent of neoadjuvant targeted therapies, knowledge of the histological subtype is critical for follow-up strategies. Renal cortical carcinomas (RCC) have distinct subtypes with varying degrees of metastatic potential. An oncocytoma is a benign neoplasm whereas the prognosis for a chromophobe RCC is thought to be intermediate between oncocytoma and conventional RCC. This distinction is important since a diagnosis of oncocytoma might prevent unnecessary surgery in a poor surgical candidate, while all chromophobe carcinomas are subject to resection.

Design: One hundred and thirty-four consecutive cases of renal cortical lesions were submitted to FNA using a 25G needle. An air-dried smear and a ThinPrep® slide were prepared. The slides were Diff-Quik® and Papanicolaou stained, respectively. The FNAs were classified according to the WHO classification, without knowledge of the clinical history or histologic diagnosis. Only cases of histologic proven oncocytoma or chromophobe carcinoma were selected for cyto-morphologic analysis in this study.

Results: Of the 134 specimens, 14 cases were histologically diagnosed as chromophobe RCC (10%) and 11 as oncocytomas (8%). All cases had abundant granular cytoplasm. In all oncocytomas, the cells had round bland nuclei, small nucleoli, fine chromatin pattern and absent perinuclear halos. Chromophobe carcinomas, however, were not as uniform in their appearance. Only half of the cases had the classic features of chromophobe carcinoma (irregular nuclear contours, coarser chromatin pattern and/or perinuclear halos), while others were indistinguishable from oncocytomas. The statistical analysis is summarized in Table 1.

Conclusions: Cytomorphology is relatively inaccurate in subtyping oncocytoma and chromophobe RCC. Although the sensitivity of diagnosing oncocytomas was high (100%), the PPV was low (58%) because several cases thought to be oncocytomas on

cytology, turned out to be chromophobe RCC histologically. Ancillary studies would be of benefit in distinguishing these two entities.

Table 1. FNA diagnosis of Oncocytoma vs. Chromophobe RCC

	Sensitivity (%)	Specificity (%)	PPV (%)	NPV (%)
Oncocytoma	100	93	58	100
Chromophobe RCC	50	100	100	94

RCC = renal cell carcinoma, PPV = positive predictive value, NPV = negative predictive value

263 Celiac Ganglion Cells on Endoscopic Ultrasound Guided Fine-Needle Aspiration: A Possible Diagnostic Pitfall

CJ Johnson, RG Silva, H Gerke, CS Jensen. University of Iowa Hospitals and Clinics, Iowa City, IA.

Background: Endoscopic ultrasound (EUS)-guided fine-needle aspiration (FNA) has been proven to be a valuable tool in the primary diagnosis and staging of both gastrointestinal and abdominal malignancies. Examination of the celiac region during EUS may reveal ganglia that have the appearance of an enlarged lymph node to the endosonographer leading to sampling during staging. The cytopathologist must be able to identify ganglion fragments and distinguish them from a malignant process. Previous studies have described the diagnostic pitfalls when identifying ganglion cells on fine needle aspiration of the prostate, but to date no studies have examined the cytomorphologic features seen on EUS-guided fine needle aspiration of celiac ganglion tissue.

Design: An index case of a 67 year-old male who underwent EUS for staging of esophageal adenocarcinoma of the esophagus was identified in which fragments of celiac ganglion were obtained by fine needle aspiration. To further evaluate the incidence and cytomorphologic features of sampled ganglia, a computerized search of the University of Iowa Hospitals and Clinics' archived files revealed five additional cases in which ganglia were sampled during an EUS procedure. The slides from all six cases were reviewed to determine the characteristic cytomorphologic findings of ganglionic tissue.

Results: Ganglion tissue was confirmed in all six cases. On Diff-Quik stain the ganglion cells were very large epithelioid cells with round to oval contours and abundant blue to purple, granular cytoplasm. Most cells contained a single eccentric nucleus, but multinucleation was also noted. Although the nuclei were very large and contained prominent nucleoli, the nuclear contours were smooth. The ganglion cells were often embedded in a spindle stroma but also occurred as single cells. Papanicolaou stained slides revealed similar epithelioid cells with prominent nucleoli.

Conclusions: 1. Sympathetic ganglia in the celiac region are occasionally sampled by FNA due to their ultrasonographic similarities to lymph nodes. 2. Ganglion tissue has a characteristic cytologic appearance. 3. The cytologic differential diagnosis includes metastatic carcinoma, other epithelioid neoplasms, and spindle cell neoplasms. 4. Recognition of ganglion tissue requires the cytopathologist to be aware of the possibility of celiac ganglion sampling and its characteristic cytomorphologic findings.

264 Cytologic Diagnosis of Atypical Squamous Cells of Undetermined Significance (ASCUS) in Perimenopausal and Postmenopausal Women: Lessons Learned from HPV DNA Testing

El Johnston, S Logani. Emory University, Atlanta, GA.

Background: We and other authors have noted that in cervical smears from perimenopausal and postmenopausal women, ASCUS diagnosis, as defined in The Bethesda System, is often not associated with a clinically evident lesion on follow-up. Reflex HPV testing provides an opportunity to distinguish cytologic features of significance from those within the spectrum of benign cellular change in this age group.

Design: Liquid based preparations (Surepath, TriPath Imaging, Inc., Burlington, NC) diagnosed as ASCUS between January 2003 and July 2005 at Emory University Hospital were identified from the computer files. The results of HPV DNA testing (ARUP Laboratories, Inc.) were recorded. Sixty-eight Pap smears of perimenopausal (n=25, 40-49 yrs) and postmenopausal women (n=43, ≥50 yrs) were reviewed in a blinded fashion.

Results: HPV DNA results were available for 903 of 1044 patients diagnosed as ASCUS [323 (35.8%) positive, 510 (56.6%) negative, and 70 (7.8%) indeterminate]. 73% of ASCUS smears in patients ≥40 years were negative for HPV DNA. Relationship of patient age and HPV detection is shown in figure 1. Data from review of 68 slides from patients ≥40 years is shown in figure 2. Review of HPV negative smears showed squamous cells with random nuclear enlargement and slight hyperchromasia that were likely interpreted as ASCUS (based on original reviewer's dots). Nuclear grooves were frequent in these nuclei and cytoplasmic halos, when present, were sharply perinuclear.

Conclusions: HPV DNA detection has an inverse relationship to patient age. ASCUS diagnosis in perimenopausal and postmenopausal women is likely to result in a benign followup in a significant proportion of patients. Enlarged nuclei with nuclear grooves and slight hyperchromasia are possibly the cause of ASCUS overdiagnosis in this age group.

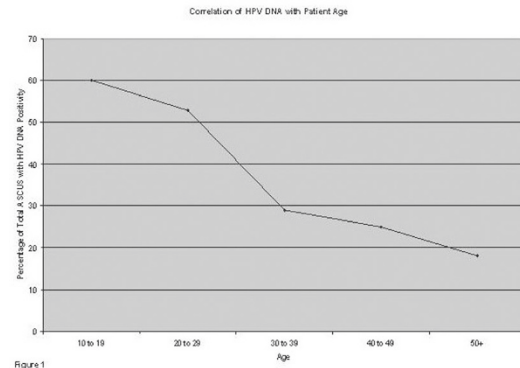


Figure 1

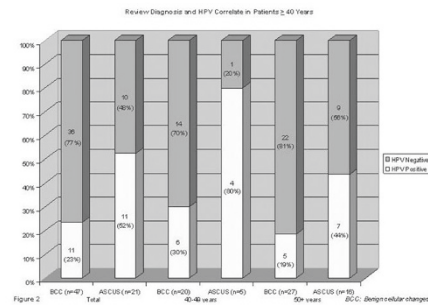


Figure 2

265 Multiparametric Flow Cytometric and EMA Immunocytochemical Analysis To Detect Malignancy in Body Cavity Fluids

M Jorda, P Ganjei-Azar, R Hamelik, I Reis, A Krishan. University of Miami, Miami, FL.

Background: Measurement of electronic volume versus DNA content of nuclei can be used to discriminate between normal and malignant cells. Epithelial membrane antigen (EMA) immunocytochemistry, a helpful ancillary test in body cavity fluids, is not universally accurate for detecting malignancy in effusions. The current study was undertaken to determine if multiparametric flow cytometry (based on simultaneous analysis of light scatter, nuclear volume, DNA and nuclear protein content) in combination with EMA could be used for the detection of malignant cells in peritoneal and pleural fluids.

Design: We studied 130 body cavity fluids (68 peritoneal and 62 pleural fluids) by conventional cytology and multiparametric laser flow cytometry. EMA immunocytochemical analysis was performed using EMA (DAKO) and L-SAB detection system (DakoCytomation, Carpinteria, CA).

Results: Immunocytochemistry for EMA had significantly higher sensitivity than conventional cytology (79% vs 59%, p=0.016) and ploidy (79% vs 38%, p=0.001). Cytology had significantly higher specificity than ploidy (97% vs 82%, p=0.012). The differences in specificity between EMA and ploidy (87% vs 82%, p=0.607) or EMA and cytology (87% vs 97%, p=0.109) were not statistically significant. However, assuming serial testing, sensitivity increased significantly for the combinations of cytology and EMA (79.4%, p=0.016) and cytology and ploidy (73.5%, p=0.004) as compared to cytology test alone (58.8%). Also, the combination cytology and ploidy had a higher sensitivity than ploidy alone (73% vs 38%, p<0.0001). However, the sensitivity associated with the 3 tests used in serial (85.3%) was not significantly different from the sensitivities corresponding to the combination of cytology and EMA (79%) or cytology and ploidy (73%).

Conclusions: Multiparametric flow cytometry analysis of body cavity fluid specimens maybe a valuable tool for rapid identification of malignant cells in combination with cytomorphology. EMA immunocytochemistry is also helpful in this diagnostic problem. This study does not support serial analysis with multiparametric flow cytometry and EMA in fluids.

266 Utility of p16^{INK4A} Immunohistochemistry and High Risk HPV In Situ Hybridization in Liquid Based ASC-H Cases

M Kapali, K Onuma, M Chivukula, DJ Dabbs. Magee-Women's Hospital of University Of Pittsburgh, Pittsburgh, PA.

Background: p16^{INK4A} the product of cyclin-dependent kinase inhibitor is known to be consistently overexpressed in cervical dysplasias. The atypical squamous cells; cannot exclude high grade intraepithelial lesion (ASC-H) category in Pap smear reflects a heterogenous mixture of true high grade dysplasias and it's mimics. The purpose of this study is to ascertain the utility of p16^{INK4A} immunohistochemistry and high risk HPV in situ hybridization (ISH) on ASC-H cases which might be of help in identifying the truly dysplastic cases. The data presented is a preliminary data on the initial 100 cases of a much larger prospective study of 500 cases.

Design: 100 ASC-H diagnosis were included in this study from a Pap caseload that reflects an ASC-H percentage of 0.65%. Additional thin prep slides were prepared from the residual thin prep fluid and stained for p16^{INK4A} and HPV ISH. In this study any nuclear or cytoplasmic staining in an abnormal cell was interpreted as positive p16^{INK4A}. 54 of the 100 cases had follow up tissue diagnosis. In five cases tissue was inadequate.

Results:

p16 INK4A DATA ANALYSIS AND PERCENTAGES			
Case descriptors	% of Total	+P16	-P16
ASC-H stained for P16	100	63/100 (63%)	37/100 (37%)
Follow up	54/100 (54%)	36/54	13/54
Bx Dx of SIL	36/54 (66.6%)	26/36 (72%)	10/36 (28%)
Bx Dx of CIN-1	34/36	24/34 (70.6%)	10/34 (29.4%)
Bx Dx of CIN-2	2/36	2/2 (100%)	0/2 (0%)
Bx Dx Benign	13/54 (24.1%)	10/13 (76.9%)	3/13 (32.1%)

ANALYSIS OF p16 INK4A AND HIGH RISK HPV ISH

Case descriptor	Total + P16	Only P16	P16 & HPV ISH
LSIL	24	10/24	14/24
HSIL	2	0/2	2/2
Benign	10	3/10	7/10

Conclusions: A significant proportion of the ASC-H cases had a positive p16^{INK4A} (63%). Both cases which had a follow up biopsy of high grade had positive p16^{INK4A}. An unexpected finding was the high percentage of cases with low grade follow up with positive p16^{INK4A} (70.6%). This may be due to “early” HSIL lesions morphologically indistinguishable from LSIL since majority of these cases also were positive for high risk HPV probe. A significant proportion of cases with benign follow up had positive p16^{INK4A}. Since most of these cases also were positive for high risk HPV probe the possible explanation for this discrepancy could be sampling error. Immunohistochemical detection of p16^{INK4A} appears to be a sensitive marker for dysplasia. If p16^{INK4A} is negative in a case of ASC-H it is less likely the patient will have a significant intraepithelial lesion.

267 Hematologic Malignancies Involving Body Cavities: Diagnostic and Prognostic Implications in 116 Cases

D Kasuganti, L Green, VB Reddy, L Kluskens, P Gattuso. Rush University Medical Center, Chicago, IL; Houston VAMC, Houston, TX.

Background: Body cavity involvement by hematologic neoplasms is rarely observed. Thus, the prognostic implications of these malignancies have been only sporadically reported in the literature.

Design: All cases of hematologic malignancies involving body cavity effusions from Rush University Medical Center in Chicago and the Houston VAMC occurring between 1980 and 2005 were retrieved from computer files. The Papanicolaou and Diff-Quik® stained slides, cell block, flow cytometric studies, and immunocytochemical stains, when available, were reviewed in conjunction with clinical history and follow-up information.

Results: A total of 116 malignant hematologic malignancies involving the body cavities were recorded in a patient population which included 93 males and 23 females ranging from 22 to 86 years of age. There were 75 malignant lymphomas and 41 non-lymphomatous hematologic malignancies. A definitive diagnosis was rendered in 91 cases (78%) with flow cytometric studies and immunocytochemical stains providing diagnostic confirmation in 52 of these cases. In 25 cases (22%), the presence of a hematologic malignancy was suspected. A summary of the study results is provided in the following table.

Types of hematologic malignancies in body cavity fluids		
Hematologic malignancies	Definitive diagnosis	Suspected diagnosis
Large cell lymphoma	31	5
Acute myeloid leukemia	21	0
Lymphoblastic lymphoma	6	0
Myeloma	5	0
Acute lymphoblastic leukemia	4	0
Small lymphocytic lymphoma	3	7
Small cleaved lymphoma	3	5
Chronic lymphocytic leukemia	3	2
Primary effusion lymphoma	3	0
Mixed follicular lymphoma	2	3
Peripheral T-cell lymphoma	2	0
Mantle cell lymphoma	2	0
Hairy cell leukemia	2	0
Chronic myeloid leukemia	2	0
Hodgkin's lymphoma	2	0
Lymphoma unclassified	0	2
Marginal zone lymphoma	0	1
Total	91	25

Follow-up information was available for 68 patients whose survival rates ranged from 3 days to 4 years. Ninety-three percent (63/68) of patients died within 12 months of the diagnosis.

Conclusions: 1) Large cell lymphoma and acute myeloid leukemia are the most common hematologic neoplasms seen in body effusions. 2) Flow cytometric and immunocytochemical studies are useful ancillary techniques for confirmation of diagnoses in low-grade lymphoproliferative disorders. 3) Body fluid involvement by hematologic malignancies usually occurs in the terminal stages of the disease and carries a poor prognosis.

268 Difference in ASCUS/SIL Ratios by Patient Age

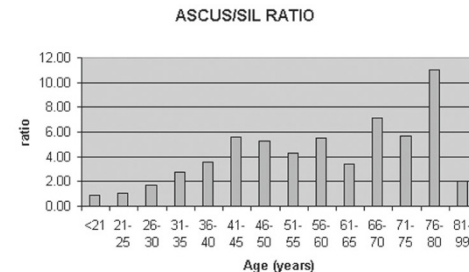
B Kendall, C Olsen, C Zahn. Wilford Hall Medical Center, Lackland AFB, TX; USUHS, Bethesda, MD.

Background: The ASCUS/SIL ratio is thought to be a measure to help assess a laboratory's use of the ASCUS category, since it is somewhat of a correction for the

incidence of dysplasia within the served population. The effect of the ages of patients screened on this ratio has not been examined thoroughly.

Design: Gynecologic cytology reports, all from ThinPrep Pap Tests (Cytoc Corporation, Marlborough, MA), from 2003 and 2004 were queried from pathology records at Wilford Hall Medical Center. Cumulative reports were compiled for cytologic diagnostic categories (negative, atypical squamous cells, atypical glandular cells, LSIL, HSIL, and carcinoma) grouped by age (<21, 81-99, and 5 year increments in between the two). The results were examined descriptively and statistically using logistic regression and chi square tests to estimate trends by age.

Results: There were 106,294 results recorded. The overall ASCUS/SIL ratio was 1.78, varying from 0.88 in women under age 21 up to 11.00 in the 76-80 year group (see figure below).



On average, a five year increase in age was associated with a 35% decrease in the odds of SIL, a 12% decrease in the odds of ASCUS, and a 34% increase in the odds of ASCUS relative to SIL (Odds Ratio 1.342, p<0.001).

Conclusions: Both ASCUS and SIL rates decreased with increasing patient age, but at differing rates; the ASCUS/SIL ratio increases with increasing age within the same cytology lab. ASCUS/SIL ratios are not typically evaluated in relation to the age of the screened population, but such comparison should be considered.

269 Cytologic Features Associated with High-Risk HPV and Abnormal Follow-Up in ASCUS Smears from Elderly Women

B Kendall, C Zahn, D Rosario, C Olsen. Wilford Hall Medical Center, Lackland AFB, TX; USUHS, Bethesda, MD.

Background: Morphologic criteria for ASCUS are sometimes difficult to reproduce in practice, and the predictive value of any of the features, particularly in elderly women, is not well known. The purpose of this study was to analyze a number of morphologic features from cytologic smears interpreted as ASCUS from women over age 50 years to determine if any were associated with detection of high-risk HPV (HRHPV) or abnormalities on subsequent follow-up.

Design: Liquid-based cytologic smears interpreted as ASCUS in women ≥ 50 over a 20-month period were reviewed for a number of cytologic features; the cytologic reviewer was blinded to outcome results. Cytologic features were considered as either dichotomous or graded depending on the morphologic feature analyzed. Individual features were evaluated in relation to the outcome variables (HRHPV and clinical follow-up) using Chi square analysis. Multivariate logistic regression was performed. Statistical significance was set at 0.05.

Results: 125 specimens were reviewed; 60 (48%) were positive for HRHPV. Abnormal follow-up (low or high-grade dysplasia) was present in 29 (48.3%) of these patients; the majority were low-grade (86.2%). The presence of nucleoli was less likely to be associated with abnormalities on follow-up (45% vs 82%, p=0.027). Greater numbers of atypical cells were associated with a lower risk of HRHPV (38% vs 63%, p=0.006), although there was no difference when considering follow-up. Greater nuclear size (>2x normal) was associated with abnormal follow-up (59% vs 29%, p=0.025), as was hyperchromasia (71% vs 40%, p=0.03) and the presence of cytoplasmic halos (67% vs 36%, p=0.02), although none of these variables was associated with HRHPV. Abnormal chromatin was associated with HRHPV (100% vs 45%, p=0.01), but not abnormal follow-up. Multivariate analysis showed a continued significant association with nuclear size, lack of nucleoli, and cytoplasmic halos. The following factors were neither associated with abnormal follow-up nor HRHPV: repair, atrophy, inflammation, presence of organisms (Candida or Trichomonas), hyperkeratosis, parakeratosis, irregular nuclear outlines, nuclear/cytoplasmic ratio, binucleation, polychromasia, or involvement of metaplastic cells.

Conclusions: Features of ASCUS smears in elderly women significantly associated with HRHPV or abnormal follow-up include nuclear enlargement, lack of nucleoli, and cytoplasmic halos. Other morphologic criteria typically associated with ASCUS may be less significant in older women.

270 Comparison of PCR and Hybrid Capture Methodologies for Detection of HPV DNA in a Split-Sample Series of Liquid-Based GYN Pap Specimens

SE Kenyon, LM Barber, JF Happel, BJ Sweeney, DR Schneider. Caritas St Elizabeth's Medical Center, Boston, MA.

Background: Two molecular technologies commonly used for the detection of human papillomavirus (HPV) DNA are polymerase chain reaction (PCR)-based methods and the Hybrid Capture® 2 (HC2) assay of Digene Corporation (Gaithersburg, Maryland). This study compares HPV DNA results of GYN Pap specimens using the PCR-based HPVDetex® method of Esoterix, Inc. (Austin, Texas) with those of HC2.

Design: A series of 200 liquid-based GYN cytology specimens for which reflex HPV testing was requested were processed by the Surepath™ method. Material from each sample was assessed for HPV DNA using both the HPVDetex® PCR test and the

Digene high-risk HC2 panel according to their respective methodologies. The HPV DNA results were compared for concordance.

Results: In seemingly close concordance, PCR resulted in 52 specimens (26.0%) positive for intermediate/high-risk (I/HR) types of HPV as compiled and referenced by Esoterix, Inc., while HC2 testing using the high-risk panel resulted in 53 positive specimens (26.5%). However, 21 of the PCR-positive cases were of I/HR HPV types not present in the HC2 panel. This represents 10.5% of all samples submitted, or 40.4% of all I/HR HPV-positive samples, that theoretically would be missed by the HC2 panel. When the results were analyzed by HPV type, the following was observed: I/HR HPV types undetected by HC2: Thirteen cases, which were positive by PCR for I/HR HPV types not present in the HC2 panel, were negative with HC2 testing. Cross-reactivity: Nine cases tested with the HC2 high-risk panel were positive for I/HR HPV types, as determined by PCR, that were not represented in the HC2 panel. In addition, 3 HC2-positive cases were found to be of low-risk HPV types by PCR and 1 HC2-positive case was positive for an "unspecified" type of HPV.

Conclusions: In this series of split-sample HPV determinations on liquid-based GYN cytology specimens, Hybrid Capture® 2 technology failed to detect 13 cases, or 25% of all I/HR HPV-positive cases, due to lack of probe representation in the test panel. An additional 13 cases (24.5% of all HC2-positive cases) were positive for HPV types not present in the HC2 high-risk panel in apparent cross-reactivity with other HPV DNA. If, as some recommend, specific HPV typing were to be used in the treatment triage of patients with abnormal GYN Pap tests, a more sensitive and specific technology would be necessary than is currently possible with Hybrid Capture® 2.

271 Validation of HPV Testing Using Hybrid Capture II with the Surepath Collection Method

V Ko, RH Tambouret, D Kuebler, WS Black-Schaffer, DC Wilbur. Massachusetts General Hospital, Boston, MA.

Background: Adequate self-validation ("home-brew") of non-FDA approved HPV testing is an important issue given its very large utilization for triage of equivocal Pap tests. We present our validation and followup data for the use of the Hybrid Capture II (HC II) (Digene) with the Surepath (SP) liquid-based collection method (TriPath).

Design: A preinitiation validation study consisted of a dual collection of a SP Pap Test and a Digene STM kit (FDA-approved standard) in a high prevalence patient population. HC II tests for high risk HPV were run in parallel and the results compared. Following initiation of testing, 14 months of data on the results of HPV testing by HC II on SP were collected and analyzed, including ASC-US HPV reflex testing and followup biopsy results for HPV+ and - tests. In addition, cases with squamous intraepithelial lesions (SIL) that had HC II testing performed were analyzed.

Results: The preinitiation validation study showed statistical equivalence between HC II with STM and Surepath methods, although the SP method was numerically more sensitive at 100% (vs. 82% for STM) for all SIL cases (LSIL: SP=28/28, STM=23/28; HSIL: SP=8/8, STM=7/8). In followup there were 1966 ASC-US cases that had SP HC II assays of which 806 were HPV+ and 1160 were HPV-. In the positive group there were 363 biopsies with the following results (CIN I=57(16%), CIN II=32(8.8%), CIN III+=26(7.2%)). In the HPV negative group there were 79 biopsies with the following results (CIN I=10(12.7%), CIN II=2(2.5%), CIN III+=1(1.3%)). In addition, 22 of 23 (96%) HSIL tested for HPV were found to be positive during this period.

Conclusions: By comparison, in the 2-year longitudinal followup data for the detection of CIN III+ in the ALTS study, high risk HPV testing by the FDA approved ThinPrep (Cytyc) HC II method showed a rate of 1.4% on HPV- ASC-US cases. In addition, the ALTS rate of appropriate triage by an initial HPV test for cases found to be CIN2+ was 95% (CI 92-97). The present study has limitations in comparison to ALTS because not all HPV negative ASC-US patients were biopsied, however it is reasonable to assume that the highest risk patients (history, symptoms) were biopsied and hence our proportion of CIN identified is likely to be overstated. With this caveat, a 1.3% CIN III+ and 3.8% CIN II+ rate in the HPV negative ASC-US population, along with the preinitiation data and a 96% positive rate for cytologic HSIL, provide substantial followup validation for the use of HC II by the SP method.

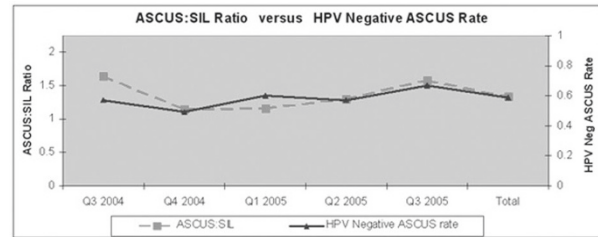
272 Testing for HPV as an Objective Measure for Quality Assurance in Gynecologic Cytology: Positive Rates in Equivocal and Abnormal Specimens

V Ko, SS Nanji, RH Tambouret, DC Wilbur. Massachusetts General Hospital, Boston, MA.

Background: The use of high risk HPV testing has been touted as a quality assurance (QA) tool for equivocal Pap smear interpretation that may be more objective and biologically relevant than the standard method of following an ASC-US:SIL. In order to implement this practice, an understanding of baseline HPV+/- rates for various diagnostic categories, stratified by age groups must be known, and subsequently correlated to standard QA tools. CAP data on ASC-US:SIL has shown a mean of 1.3 (0.4-3.1). We studied results of HPV testing in order to acquire baselines and study correlation to this standard QA marker.

Design: Two years of high risk HPV testing (Hybrid Capture II (Digene) with Surepath (Tripath) collection) were analyzed in comparison to cytologic interpretation. HPV+/- rates were correlated with cytologic interpretation and with patient age. In subset analyses for ASC-US, the HPV+/- rate was compared to the ASC-US:SIL for a 14 month period.

Results: The HPV+ rate by specific cytologic category was as follows: ASCUS 32.6% (n=448), LSIL 89.5% (n=105), and HSIL 96% (n=23). The HPV+ rate stratified by age for all interpretations was: 0-19: 47% (n=123), 20-29: 50% (n=770), 30-39: 34% (n=601), 40-49: 22% (n=399), 50-59: 14% (n=213), 60-69: 15% (n=93), 70+: 52% (n=23). The HPV-:ASCUS rate was found to proportionately closely follow the ASCUS:SIL ratio in absolute value and slope.



Conclusions: As expected, HPV+ rates in SIL cases are high and similar to published data. Age distribution is bimodal with the <30 and >70 populations showing about 50% positivity with rates of 14 to 34% in between. The HPV-:ASC-US is an objective and biologically relevant measure of the risk of abnormality. That this ratio closely parallels the standard ASC-US:SIL lends evidence to support its use as a QA marker for following laboratory and individual cytologist performance. Deviations in this ratio imply over/underuse of the ASC-US interpretive category, with the caveat that age distributions in the population must be closely monitored as shifts may be associated with inherent deviations in HPV+/- rates.

273 The UroVysion Assay for Detecting Papillary Urothelial Neoplasms of Low Malignant Potential (PUNLMPs)

A Kuten, MA Rubin, S Weremowicz, D Sandstrom, E Cibas. Beth Israel Deaconess Medical Center, Boston, MA; Brigham and Women's Hospital, Boston, MA.

Background: The UroVysion assay (Vysis, Inc.) utilizes fluorescent in situ hybridization (FISH) to detect chromosomal abnormalities characteristic of urothelial carcinomas. Based on the WHO (1973) classification of urothelial neoplasms, previous extensive studies have demonstrated that UroVysion's sensitivity to detect urothelial carcinoma is 36%, 76%, and 97% for grades 1, 2, and 3, respectively. The goal of this study was to test UroVysion's lower limit of sensitivity by assaying cytologic samples from patients with histologically confirmed papillary urothelial neoplasms of low malignant potential (PUNLMPs), which according to the WHO (2003)/ISUP classification represent the lower end of the spectrum of the WHO (1973) grade 1 tumors.

Design: Histologically confirmed PUNLMPs were identified by performing an electronic search of the Brigham and Women's Hospital pathology database. Cases were excluded if the patient had other biopsies showing a higher grade lesion or if there was no urine cytology sample in the prior year. FISH was performed on archived cytology slides (alcohol-fixed cytocentrifuge preparations) according to the manufacturer's protocol. FISH results were considered positive if 5 or more cells showed gains of 2 or more chromosomes per cell, or if 12 or more cells had homogeneous deletion of the 9p21 locus.

Results: Five patients with 14 urine samples fulfilled the selection criteria. The histologic slides were reviewed and the diagnosis of PUNLMP was confirmed in all 5 cases. The tumors ranged from 0.1 to 1.0cm. Of the 14 urine samples, 4 had been diagnosed as atypical and 10 negative. FISH was positive in 2 urine samples, both from the same patient. The tumor in this case measured 0.4cm, and the urine samples were cytologically negative. One sample contained 20 abnormal cells with gains of 2 or more chromosomes per cell. The subsequent sample demonstrated 5 abnormal cells with chromosomal gains; 4 of the 5 cells also had loss of both 9p21 signals.

Conclusions: The majority of cases in this study were negative by the UroVysion assay. The detection rate (one in 5 patients, 20%) was lower than that reported for WHO (1973) grade 1 urothelial carcinomas (36%), reflecting the lower malignant potential of these neoplasms.

274 Calretinin Expression in Invasive Breast Carcinoma, a Potential Pitfall in the Diagnosis of Malignant Effusions

A Kyshtobayeva, KJ Bloom, S Chen, A Hii, F Espinoza. CLARIENT Inc, Irvine, CA.

Background: The characterization of malignant cells in effusions has been well studied, however difficulties still arise particularly when sample size is limited. There are many published immunohistochemical algorithms to aid in the differential diagnosis of carcinoma versus mesothelioma, however, we have observed that the ordering patterns of immunohistochemical testing appear to be haphazard. Calretinin is part of most immunoprofiles, where it is used as a positive predictor of mesothelial differentiation. It is well recognized that calretinin may be expressed in a minority of carcinomas, including lung carcinomas, but there are few studies looking at calretinin expression in breast carcinomas. In female patients, breast carcinoma must always be considered when presented with a malignant effusion of unknown origin. The aim of this study was to evaluate the expression of calretinin in invasive breast carcinomas.

Design: Six mm cores were extracted from 257 paraffin embedded blocks of invasive primary breast carcinoma submitted for prognostic testing and a microarray block was created. Five micron sections were obtained and immunostained with antibodies to calretinin (Polyclonal, Zymed), cytokeratin 5/6 (D5/16B4 DakoCytomation), ER PharmDX (DakoCytomation) and mammoglobin(304-1A5+31A5, Zeta)

Results: 257 cores of invasive breast carcinoma were analyzed. Nine cores (3.5%) showed strong cytoplasmic and nuclear expression similar to that seen in mesotheliomas. None of these cores expressed estrogen receptor, mammoglobin or cytokeratin 5/6. An additional 43 cores (16.7%) showed moderate to strong cytoplasmic expression without evidence of nuclear expression. Cytoplasmic expression was equally split between those showing a distinctly granular pattern and those showing a diffuse cytoplasmic pattern.

Conclusions: There are many potential pitfalls in the immunohistochemical work-up of malignant effusions. Calretinin expression may be seen in approximately 20% of invasive breast carcinomas. While concomitant nuclear and cytoplasmic expression is only seen in 3.5% of breast carcinoma, these tumors are negative for estrogen receptor, mammoglobin and cytokeratin 5/6. Calretinin expression without expression of cytokeratin 5/6 should elevate the possibility of an epithelial malignancy. When an epithelial neoplasm shows nuclear and cytoplasmic expression of calretinin, lack of ER or mammoglobin expression does not exclude the possibility of a breast carcinoma.

275 Ultrasound-Guided Fine-Needle Aspiration of Breast Lesions: Cytologic and Histologic Correlations of Atypical/Indeterminate Cytologic Cases

S Lai, N Sneige. The University of Texas, MD Anderson Cancer Center, Houston, TX.
Background: Ultrasound-guided fine-needle aspiration (US-FNA) remains a first line test in the evaluation of breast lesions because of its reliability, rapid turnaround time and low cost compared to biopsy and surgical excision. The National Cancer Institute sponsored consensus cytology reporting system contains five categories for classification of FNA as insufficient, benign, atypical/indeterminate, suspicious/probably malignant, and malignant with post FNA recommendation which includes the triple test and surgical biopsy of indeterminate lesions. While a diagnosis of malignancy on core needle biopsy may not pose any concern about the FNA findings, it is the benign core biopsy diagnosis that will require cyto-histologic and radiologic correlations to ensure that the core biopsy was representative of the lesion in question.
Design: In a series of 1637 cases of US-FNA from January 1, 2002 to December 31, 2003, we identified 77 atypical/indeterminate cases, 69 of which have histologic follow up. The cytologic findings of these cases were correlated with core biopsy/surgical results and radiologic findings to explore the reason for discrepant diagnoses.
Results: Of the 1637 cases, 1165 (71.2%) were categorized as benign, 77 (4.7%) as atypical, 41 (2.5%) as suspicious, 312 (19.1%) as malignant, and 42 (2.6%) as non-diagnostic. The 77 cases in atypical category are further divided into two groups. The first group consisted of atypical cells with papillary features/papillary lesions (22 cases), in which the histology specimens were available for correlation in 18 cases. The tissue diagnosis of these 18 cases are as follows: papilloma (33.3%), benign proliferative epithelium (22.2%), malignancy (22.2%), papillary ADH (11.1%), fibroadenoma (5.6%), and non-diagnostic (5.6%). The second group consisted of all the remaining cases in atypical category (55 cases). Tissue diagnoses were available in 51 cases and were as follows: malignancy (50.9%), fibroadenoma (19.6%), benign proliferative epithelium (19.6%), ADH (7.8%), and papilloma with atypical lobular hyperplasia (2.0%).
Conclusions: Atypical FNA results can be resolved in the majority of cases when the findings are correlated with histologic and radiologic features. Fibroadenoma, papilloma and benign proliferative epithelium are main causes for cytologic diagnosis of atypia. Awareness of lesions resulting in cytologic atypia and correlation with imaging and histologic findings is necessary for appropriate management of breast lesions.

276 Positive UroVysion FISH Due to Gynecologic Malignancies and Precursor Lesions in Evaluation of Patients for Urothelial Carcinoma

PA Lewis, RL Roberts, EJ Milionis, MJ Putzi, JR Oppenheimer, SB Shappell. MOD Lab, Dallas, TX; OUR Lab, Nashville, TN.
Background: UroVysion™ (Vysis) FISH has greater sensitivity and equally high specificity vs. urine cytology for detecting urothelial carcinoma (UC). FISH can also resolve atypical/suspicious urine cytology, as chromosomal changes detected are not present in benign processes that produce atypia. These genetic changes are not necessarily specific for UC vs other malignancies. Whether other neoplastic processes that can present cells in urine could cause positive UroVysion tests is not known.
Design: From Jan 2004 to Feb 2005, 2133 UroVysion tests were performed. Urine was submitted from > 500 Urologists for FISH only, cytology and FISH, cytology/FISH if cytology non-negative, or cytology only, with FISH pathologist initiated for atypical or suspicious cytology. UroVysion FISH uses probes to chromosomes 3, 7, and 17 and 9p21. Criteria for positive were ≥ 4 cells with gains of 2 or more chromosomes (polysomy) or homozygous loss of 9p21 in ≥ 12 cells.
Results: Five FISH cases positive by polysomy were noted that subsequent information indicated were likely due to gynecologic (GYN) carcinomas (cas) or precursor lesions, not recurrent or new UC. A 60 year old (yo) female with hematuria had suspicious urine cytology, followed by positive FISH. A history of ovarian ca was obtained, with invasion of bladder and no evidence of UC at time of positive UroVysion. An 18 yo female with hematuria had positive FISH on voided urine. A cytology prep showed dysplastic squamous cells and no atypical urothelial cells. History confirmed cervical squamous dysplasia (past LEEP). A 45 yo female with UC history had positive UroVysion on voided urine. Positive cells had squamous features. Cytology prep had dysplastic squamous cells and no atypical urothelial cells. She was cystoscopically free of UC, with history of moderate cervical squamous dysplasia (past LEEP). Two other cases (40 yo female, hematuria; 81 yo female, UC history) with positive FISH on voided urines were possibly due to dysplastic squamous cells.
Conclusions: We report cases with positive UroVysion due to GYN ca or precursor squamous lesions. These were < 1% of positives. As detected by subsequent cytology and history, the true incidence is unknown. Pathology is important for morphology and clinical correlation in UroVysion testing. Although rare, it is important to recognize possible GYN causes for positive FISH in female urine specimens, to prevent unnecessary cystoscopy and prompt necessary GYN workup.

277 CISH™ Is a Good Technique To Determine HER2 Gene Amplification in Cytologic Preparations from Breast Carcinomas: Excellent Correlation with FFPE Tissue Analysis

EML Li Ning, MA Palau, C Garcia-Macias, D Allende, A Silva, MJ Merino. National Cancer Institute/National Institutes of Health, Bethesda, MD; Hospital Universitario de Salamanca, Salamanca, Spain.

Background: It is well established that the assessment of HER2 gene amplification has prognostic and predictive implications in patients with breast cancer, and true amplification is particularly important in the selection of patients that will benefit from new modalities of treatment such as trastuzumab. Chromogenic in situ hybridization (CISH™) is an alternate method to FISH that has recently been tested for the evaluation of HER2 in breast cancer tissue. We investigated the role of CISH™ in archived cytological smears and correlated with FFPE tissue analysis.

Design: Sixteen cytological breast cancer smears previously fixed and stained with routine staining were studied. Cases were selected based on the predominance of tumoral cells and absence of fixation defects. The smears were destained in acid alcohol, hybridized with HER2 probe and visualized with CISH™. The slides were reviewed by three independent observers. The results were interpreted following previously established criteria. When available, sections from corresponding formalin-fixed paraffin-embedded tissue (FFPE) were obtained and evaluated with both CISH and FISH for HER2. Immunohistochemistry (IHC) was also performed.

Results: Amplification was found in three (19%) of the cases selected. The remaining thirteen cases did not amplify. FFPE material was available in 13 cases. For these cases, CISH™ and FISH were performed showing an excellent concordance with the results of CISH™ in cytological smears. A case showing 2+ by IHC for c-erbB2 showed no amplification by CISH™ in smears and tissue.

Conclusions: CISH™ is a simple and useful technique for the evaluation of HER2 amplification in archived and previously stained cytological smears. In one of our cases, it was helpful in discriminating a nonamplified tumor that was 2+ by IHC. CISH™ in cytological smears is an invaluable source of information whenever surgical specimens are not accessible.

278 Double Color Immunostaining in the Differential Diagnosis of Mesothelioma Versus Adenocarcinoma with Paired Antibodies Calretinin-CK5/6 and BerEp4-B72.3 on Cytospins and Cell Blocks

GL Lim, AM Takano, R Richards, T Walker, AR Chang. National University of Singapore, Singapore, Singapore; National University Hospital, Singapore, Singapore; Charles Sturt University, New South Wales, Australia.

Background: Differential diagnosis of mesothelial proliferations versus adenocarcinomas in effusions, continues to present a challenge. Diagnosis based on morphology alone may not be possible. Since the inception of immunohistochemical techniques, this difficulty has been significantly reduced. Our study describes the use of combinations of mesothelial and adenocarcinoma markers using double color immunostaining in order to optimize the efficiency of these antibodies.

Design: Cell blocks of 9 benign, 6 atypical and 22 malignant effusions were retrieved from the files of the Department of Pathology of the National University Hospital in Singapore. Malignant cases included adenocarcinomas and mesotheliomas. Cytospins were made from some of the malignant cases. Sections of the cell blocks and the cytospins were stained with a mixture of Calretinin-CK5/6 using the EnVision® system followed by DAB(brown) chromogen. The second part of the process consisted of a mixture of BerEp4-B72.3 using the EnVision® system followed by Fast Red chromogen. The slides were counterstained with Gill's hematoxylin. Immunoreactivity was assessed as follows: 1+ (>1%-25% positive cells) to 4+ (>75%).

Results: All the adenocarcinomas (19/19) showed strong reaction with the red chromogen. None of the mesothelial lesions (9/9) showed reactivity with this chromogen. These combinations of antibodies showed sensitivity, specificity, positive predictive value, and negative predictive value of 100% for the diagnosis of adenocarcinoma. All the cases of mesothelioma (7/7) and mesothelial proliferations (2/2) showed strong reaction with the brown chromogen. These findings resulted in 100% sensitivity, 90.5% specificity, 77.8% positive predictive value, and 100% negative predictive value for the diagnosis of mesothelioma.

Conclusions: The combination of calretinin-CK5/6 and BerEp4-B72.3 with different chromogens is a practical and reliable immunocytological method for the differential diagnosis of adenocarcinoma versus mesothelioma in cell blocks and cytospins with high sensitivity and specificity. Its advantage is the ability to identify multiple antigens on a single slide and to determine the exact phenotype of different cells present on a fluid preparation.

279 Urothelial Carcinomas of the Renal Pelvis. Sensitivity of Instrumented and Voided Urine

O Lin, S Olgac, B Bochner, G Dalbagni, VE Reuter. Memorial Sloan Kettering Cancer Center, New York, NY.

Background: Carcinomas of the renal pelvis represent less than 5% of urothelial carcinomas and approximately 8% of all renal tumors. The clinical impact of a positive urinary cytology in lesions of the renal pelvis is different from bladder lesions. A diagnosis of malignancy indicates a radical nephrectomy, whereas in the bladder, a diagnosis of malignancy leads to a less radical procedure (cystoscopy) for tissue confirmation. The reported diagnostic accuracy of urine cytology in the evaluation of urothelial carcinomas of the renal pelvis ranges from 23-100%, depending on the type of urine specimen analyzed. Most previous studies represent small series focusing in one type of urine specimen. We set out to analyze the experience at a major referral center addressing the sensitivity of different types of urine specimens.

Design: The results of the urine cytology specimens preceding 127 nephrectomies performed for renal pelvis urothelial carcinomas in our institution were analyzed. The specimens were from 121 patients (78 male and 43 female patients) and the urine specimens

were obtained up to 2 months prior to nephrectomy. A total of 166 urine specimens were included in this study (92 voided urine, 48 cystoscopic urine and 26 washings/brushings of the renal pelvis specimens).

Results: The overall sensitivity of urine cytology in the detection of urothelial carcinomas of the renal pelvis was 51%. The sensitivity for voided urine was 51%, 44% for cystoscopic urine and 73% for renal pelvis washing/brushings. The sensitivity for low grade and high grade urothelial carcinoma for each type of specimen is listed in table 1.

	Voided Urine	Cystoscopic Urine	Renal Pelvis Washing
LGUC	29%	41%	50%
HGUC	59%	42%	83%

LGUC: low grade urothelial carcinoma; HGUC: High grade urothelial carcinoma

Conclusions: Renal pelvis washings/brushings represent the most sensitive method to diagnose urothelial carcinomas of the renal pelvis, irrespective of grade. Cystoscopic urine specimens showed the lowest sensitivity for high grade urothelial carcinomas of the renal pelvis. All current detection methods lack sensitivity to detect low grade urothelial carcinomas of the renal pelvis.

280 Circulating Tumor Cells of Prostatic Adenocarcinoma: Cytomorphologic Findings

O Lin, VE Reuter, D Shaffer. Memorial Sloan-Kettering Cancer Center, New York, NY.

Background: The presence of circulating tumor cells (CTC) has been associated with poor survival in patients with metastatic carcinoma. In the past, the isolation of these cells was difficult due to their paucity in the peripheral blood. Technical advances such as the newly developed FDA-approved CellSearch® system (Immunicon Corporation, Huntingdon Valley, PA) have enhanced the detection of CTC. The system relies on immunomagnetic separation of CTCs using ferromagnetic-conjugated antibodies. Although this system is useful for counting of CTCs, it does not allow the molecular profiling of these cells, which would require isolation of individual CTC, as can be done from cytology slides. The proper morphologic identification of CTC is required to optimize this analysis due to the presence of cytologic mimickers, including hematopoietic cells admixed with CTC.

Design: Patients with metastatic prostate cancer, who were being treated with chemotherapy, had two (7.5 ml) tubes of blood drawn at each collection. Both tubes were processed by the CellSearch® system. One tube was used for CTC counts with the CellSearch® analyzer, while the CTC in the second tube were cytospinned into glass slides and Papanicolaou stained for cytological examination. The slides were evaluated for the number CTC and their morphologic characteristics as well as the presence of other cell types. The number of CTC in the cytology slides was compared to the number of CTC obtained through the CellSearch® analyzer.

Results: Eighty specimens analyzed both by CellSearch® analyzer and cytology slides were available for review. Sixty-two cases showed CTC by both methods. Eleven specimens were negative for CTC in both methods. CTC were identified only in the CellSearch analyzer in 7 cases. The mean number of CTC counted by CellSearch analyzer and in the cytology slides was 66 and 6, respectively. In the cytospin preparations, CTC were present mostly as single cells with round nuclei and prominent nucleoli. Cluster formation was noted only in 3 cases. Neutrophils and macrophages were noted in all slides and megakaryocytes were noted in 15 cases.

Conclusions: CTC can be identified consistently in cytology specimens, although in a smaller number when compared to the CellSearch® analyzer. The proper identification should allow microdissection and molecular analysis of CTC. CTC must be distinguished from megakaryocytes and macrophages.

281 B-RAF and 10q23 Loss of Heterozygosity Are Valuable Diagnostic Molecular Markers of Follicular Variant of Papillary Thyroid Carcinoma in Thyroid Fine Needle Aspiration Cytology Initially Classified as Follicular Lesion

X Lin, YL Liu, M Leon, RS Saad, SD Finkelstein, JF Silverman. Allegheny General Hospital, Pittsburgh, PA; RedPath Integrated Pathology, Inc, Pittsburgh, PA.

Background: Fine needle aspiration (FNA) cytology has been extensively used to evaluate thyroid lesions and has been shown to be the best procedure to appropriately identify patients needing surgical treatment. However, the diagnosis of follicular variant of papillary thyroid carcinoma (PTCA-FV) by FNA cytology can be challenging. B-RAF point mutation was reported to be useful for the diagnosis of papillary thyroid carcinoma (J Clin Endocrinol Metab 2004, 89:5175-5180). Using quantitative methods applied to microdissected cell clusters selected based on cytologic features, we investigated the feasibility and efficacy of PCR analysis for diagnosing PTCA-FV utilizing B-RAF and 10q23 (Ret proto-oncogene) loss of heterozygosity (LOH) molecular markers in FNA cases initially interpreted as follicular lesion.

Design: 10 FNA thyroid specimens with cytology diagnoses of follicular lesion and diagnosis of PTCA-FV in the follow-up thyroidectomy were retrieved from the hospital computer system. Clusters of representative follicular cells on Papanicolaou-stained FNA slides were removed under stereoscopic guidance. The resulting DNA from each case was subdivided into aliquots for mutational analysis consisting of loss of heterozygosity (LOH) at 10q in the ret gene locus and point mutation determination in B-RAF. Each aliquot underwent PCR with labeled oligonucleotides followed by automated capillary electrophoresis.

Results: Analysis of all 10 FNA specimens showed 3 cases with single B-RAF point mutation; 2 cases with both B-RAF point mutation and 10q23 LOH, 3 cases with single 10q23 LOH; and 2 cases without either B-RAF point mutation or 10q23 LOH. The sensitivity of the presence of B-RAF point mutation and/or 10q23 LOH was 80% (8/10). When both LOH and point mutation was present, B-RAF mutation preceded LOH.

Conclusions: Our results suggest that the presence of B-RAF point mutation and/or 10q23 LOH can be useful in thyroid FNA specimens initially classified as a follicular lesion, especially if there is a suspicion for the diagnosis of PTCA-FV. Molecular analysis of thyroid FNA with the indeterminate diagnosis of follicular lesion may be a useful procedure to better classify these lesions and thereby, select patients needing surgery.

282 The Utility of D2-40 for the Diagnosis of Malignant Mesothelioma Versus Pulmonary Adenocarcinoma in Pleural Fluid Cytology

JL Lindner, X Lin, YL Liu, RS Saad, P Kaplan, M Tung, JF Silverman. Allegheny General Hospital, Pittsburgh, PA.

Background: Differentiating malignant mesothelioma (MM) from pulmonary carcinoma in pleural fluid cytology can be challenging, requiring immunohistochemical (IHC) staining. Recent studies have suggested that D2-40, a novel lymphatic marker, may be a useful marker for mesothelial differentiation in surgical specimens. However, there is no available data regarding its utility in effusion cytology specimens. We investigated the utility of D2-40 in pleural fluid cytology in differentiating MM from other pulmonary carcinomas.

Design: Fifteen cases of pleural effusion smears of MM with their corresponding cell blocks were retrieved from the database of hospital computer system. Diagnosis of MM was confirmed by surgical decortication or pneumonectomy with immunostaining studies and/or electron microscopy. We also included 10 cases of metastatic pulmonary adenocarcinoma (PA) and 10 cases metastatic squamous cell carcinoma (PSCC) involving the pleural fluid as a control group. Cell blocks were formalin-fixed, paraffin embedded and immunostained for TTF1, CK7, p63, calretinin, WT-1 and D2-40. Intensity was graded from 0-3 with a score 0 for no staining and 3 for maximal intensity. The pattern/distribution of reactivity was recorded as focal (F)(<10%) or diffuse (>10%). Cases scored as 0-1 F were considered negative.

Results: The positive rates for TTF-1, CK7, p63, calretinin, WT-1 and D2-40 respectively were as follows: MM- (0/15,0%), (14/15,93%), (0/15,0%), (13/15,87%), (15/15,100%), (13/15,87%), PA- (8/10,80%), (9/10,90%), (0/10,0%), (3/10,30%), (0/10,0%) and (1/10,10%), and PSCC- (1/10,10%), (4/10,40%), (10/10,100%), (6/10,60%), (0/15,0%), (5/10,50%). The staining pattern for D2-40 was thick membranous staining, similar to epithelial membrane antigen staining in MM. Only one case of PA showed D2-40 positivity, characterized by diffuse cytoplasmic staining pattern.

Conclusions: Our study showed that in differentiating MM from PA, WT-1 and D2-40 have high specificity and good sensitivity for epithelioid mesotheliomas, and therefore are useful IHC markers for the diagnosis of these tumors. Although calretinin is the most sensitive IHC marker for MM, it is less specific since it stained 30% of PA. Conversely, to differentiate MM from PSCC, p63 and WT-1 are the best available markers, since D2-40 is positive in about 50% of PSCC. We recommend a panel of p63, D2-40, and WT-1 in addition to calretinin to differentiate MM from other primary non-small cell lung carcinomas.

283 Adolescents with High Grade Cervical Squamous Intraepithelial Lesions: A Retrospective Cytohistologic Study of 493 Patients

F Liu, C Zhang, CJ Sung, MM Steinhoff, WD Lawrence. Women & Infants Hospital, Brown Medical School, Providence, RI.

Background: Adolescent girls are at high risk for developing cervical squamous intraepithelial lesions (SILs) for well established reasons, including failure to obtain regular Pap tests. We retrospectively studied the frequency of SILs in adolescent girls (defined as 13-19 years old) using histopathology, cytopathology, and HPV DNA testing.

Design: 493 biopsy-proven cases of cervical HSIL in adolescent girls were retrieved from our institutional pathology archives from 1/95 to 3/05 and the following data were recorded: age at first diagnosis with HSIL, age and result of first Pap test, interval and number of Pap tests between the initial Pap and detection of HSIL, and status of high risk HPV (HR-HPV) DNA testing.

Results: Of 493 cases with HSIL, 10 cases (2%) were diagnosed at age 14; 20 cases (4.1%) at age 15; 42 cases (8.5%) at age 16; 78 cases (15.8%) at age 17; 156 cases (31.6%) at age 18; and 187 cases (37.9%) at age 19 (overall mean age of 18±1.2 years). 423 of 493 cases had at least one Pap test in our system and the remaining 70 cases were taken elsewhere. Of 423 cases, the first Pap was taken at the following ages: 13 (4 cases, 0.8%), 14 (40 cases, 8.1%), 15 (54 cases, 11%), 16 (85 cases, 17.2%), 17 (91 cases, 18.5%), 18 (100 cases, 20.3%) and 19 (45 cases, 9.1%). The first Pap tests were HSIL in 50 cases (11.8%), LSIL in 128 cases (30.2%), ASCUS in 67 cases (15.8%) and negative (NIL) in 178 cases (41.5%). The mean interval and number of Pap tests between the first Pap to detect HSIL were 20.2±14 months and 2.9±1.3 tests, respectively. Although 125 patients (25.4%) had had only one Pap test, their biopsies showed HSIL within the first 3 subsequent months; however, the Pap test was HSIL in only 50 cases (40%); LSIL in 55 cases (44%); ASCUS in 17 cases (13.6%); and NIL in 3 cases (2.4%). 66 of 493 with HSIL underwent HPV DNA testing and 60 cases (91%) tested positive for one or more HR-HPV serotypes, whereas 6 cases (9%) tested negative for HR-HPV.

Conclusions: 1) Cervical HSIL occurs as early as age 14 (2% of negatives. 2) frequency of HSIL increases with age in adolescents 3) frequency of HSIL peaks at age 19, although the peak age for the initial screening Pap is 18 4) more than half of adolescents with HSIL showed an abnormality at the initial Pap 5) adolescents with any Pap abnormality, even LSIL and ASCUS, may need more aggressive follow-up 6) >90% of adolescents with cervical HSIL who underwent HPV testing were positive for HR-HPV serotypes.

284 Sensitivity and Specificity of Immunohistochemical (IHC) Detection of ER and PR in Breast Carcinoma on Cell Block Cytology by Quantitative Image Analysis (QIA)

H Liu, F Lin, JW Prichard. Geisinger Medical Center, Danville, PA.

Background: IHC detection of Estrogen (ER) and Progesterone (PR) receptor protein is frequently done on FNA cell blocks. Recent data from QIA of ER using 5% cutoff reported 98.3% agreement between cytologic and surgical specimens (Anal Quant Cytol Histol 2004;25:323). A more recent study comparing hormone receptor analysis to outcomes in NSABP B-09 shows that an "all or nothing" cutoff for either ER or PR is preferable to 5% (Cancer 2005;103:164). Cytologic studies using 1% cutoff and including PR have not been reported. The objective of this study is to evaluate the expression of both ER and PR on cell blocks and matched surgical specimens using QIA comparing cutoff levels, which in turn may provide a useful information on reliability of ER and PR results from IHC on cell blocks.

Design: 48 consecutive cases of invasive breast carcinoma with matching cell blocks and surgical specimens were included. IHC stains with monoclonal antibodies to ER and PR were performed with Envision-HRP kit on formalin fixed, paraffin-embedded sections. Positive nuclear staining of both ER and PR was measured using quantitative Clariant ACIS II system at 1% staining cutoff level. All tumor cells were counted for cell block sections; whereas selected areas with invasive carcinoma were counted on surgical specimens.

Results: Our histology gold standard resulted in 70% positivity similar to previously published rates. The concordance between cytology and surgical specimens was 70% for ER and 82% for PR, respectively, with either ER or PR staining resulting in concordance of 88%. False positive cases were not noted. False negative rate at 5% cutoff is 27% for ER and is 15% for PR, improved to 23% and 10% at 1% cutoff. Specificity and positive predictive value was 100% for ER, and PR; whereas negative predictive value for ER, PR and combined ER-PR at 5% cutoff was 52%, 73% and 63% respectively, which improved with 1% cutoff to 56%, 78% and 67%, respectively.

Conclusions: Our data indicate that IHC detection of ER and PR on cell blocks using QIA is a reliable test when the result is positive. Using combined results of ER and PR assays and cutoff of 1% rather than 5% increases the sensitivity and negative predictive values. Different preparation and fixation, scant material and frequent absence of a positive internal control in cytologic material may contribute to false negative rate for cytologic material. Therefore, repeat testing of subsequent surgical specimens is recommended if cytology result is negative.

285 Critical Values in Cytology – Survey Results from ADASP (Association of Directors of Anatomic and Surgical Pathology)

V Livolsi, TC Pereira, CD Fletcher, WJ Frable, JR Goldblum, PE Swanson, JF Silverman. University of Pennsylvania, Philadelphia, PA; Allegheny General Hospital, Pittsburgh, PA; Brigham and Women's Hospital, Boston, MA; Virginia Commonwealth University, Richmond, VA; The Cleveland Clinic, Cleveland, OH; University of Washington, Seattle, WA.

Background: Analogous to critical values (CVs) in clinical pathology, occasional diagnoses (dx) in cytology could require immediate contact of the physician to initiate treatment.

Design: To propose guidelines on CV in cytology, a survey was sent to 225 ADASP members for grading 18 possible CVs from 1 to 3 as follows: (1) No phone call necessary, (2) The clinician should be called within 24h; (3) A phone call should be made as soon as possible (ASAP). Respondents could also list additional dx they believed constituted a CV.

Results: There were 57 responses; the majority (ranging from 55 to 88%) agreed on the need for a phone call ASAP for the following dx: completely unexpected malignancy, malignancy (suspected or not) in critical anatomic sites (i.e. - risk of spinal cord injury), disagreement between immediate and final interpretation in FNAs, fungi in FNA of an immunocompromised patient, and finding the following microorganisms in any patient: bacteria or fungi in CSF; pneumocystis, fungi or viral cytopathic changes in bronchial lavage, wash or brush; acid-fast bacilli in any specimen. For some dx (bacteria in FNA in any patient and fungi in FNA of immunocompetent patients), there was difference of opinion about the need for a phone call and degree of urgency. For some dx (polyoma virus in urine, new dx of high grade squamous intra-epithelial lesion, new dx of malignancy with clinical suspicion, and new dx of metastasis with known primary malignancy), most participants believed that a phone call was unnecessary. On the free text part of the survey, there was a limited number of additional CV dx/situations suggested. Additional comments also were provided, such as the urgency of the call would vary depending on the clinical setting and details of dx (fungus type, tumor type, if the disagreement between immediate and final interpretation in FNA is major, etc.) 4 of 57 pathologists said they didn't believe in the concept of CVs in cytology, 2 of which expressed concern about medicolegal implications.

Conclusions: Although there was good agreement in many possible CVs, there was difference of opinion for some dx. The results of this survey will help an ADASP committee to develop national guidelines for critical values in cytology.

286 Feasibility of Intraoperative Fine Needle Aspiration as an Alternative to Frozen Section Analysis of Pulmonary Nodules: A Retrospective Pilot Study

MD Lozano, NR Spiteri, JI Echeveste, LM Seijo, GR Toledo, MA Idoate, W Torre, AF Panizo, JJ Zulueta. Clinica Universitaria University of Navarra, Pamplona, NA, Spain.

Background: The International Early Lung Cancer Action Project (I-ELCAP) demonstrated that low dose spiral CT detects lung cancer in early stages. According to the IELCAP algorithm a percutaneous FNA (PFNA) or an intraoperative biopsy (IOB) should be performed in suspicious nodules. PFNA is an efficient and recognized method for the diagnosis of lung cancer, but an expert team of skilled radiologist and cytopathologist is essential. IOB involves atypical resection of the nodule followed

by frozen section analysis (FSA), and definitive surgery (e.g., lobectomy) if a preliminary diagnosis of malignancy is obtained. In the context of IELCAP, a FSA of these very small size tumors precludes the possibility of collecting some tissue for biomarker analysis. We developed on-site intra-operative fine needle aspiration (IFNA) as an alternative to FSA in order to reduce O.R. time and cost, and to preserve tissue for biomarker studies.

Design: We compared a group of 20 patients undergoing thoracic surgery and diagnostic IFNA during the past 16 months at our center with a group of 20 historical controls undergoing FSA. From the first group, 8 were IELCAP patients and 12 did not belong to any screening protocol. The control group included 5 IELCAP participants. Time to diagnosis, cost of the procedure, quality and amount of sample obtained, and diagnostic accuracy were studied.

Results: Mean time to diagnosis with IFNA was 10 min. vs 35 min. with FSA ($p < 0.05$), effectively reducing O.R. time by a mean of 25 minutes. The false positive rate for IFNA was 0. There were no false negatives in either group. Time consumed by the pathologist and cost of IFNA was reduced. Since the diagnostic IFNA dose not requires freezing part of the tumor, the whole lesion can be available for diagnosis and additional studies.

Conclusions: IFNA of pulmonary nodules by an on-site trained cyto-pathologist is a feasible and reliable alternative to FSA. IFNA significantly reduces cost and O.R. time when compared to conventional FSA. It allows presuming quick and adequate surgical decisions. It may be particularly useful in small screening-detected nodules since the entire lesion can be saved for definitive diagnosis and biomarker analysis.

287 The Significance of Koilocytes in Urinary Cytology

S MacDonald, SL Boerner. University Health Network, Toronto, ON, Canada.

Background: Koilocytes are uncommon in urinary cytology and their clinical significance is often unknown. This study was undertaken to elucidate the frequency of koilocytes in urinary cytology and attempt to explain the source of these cells and their association with urothelial lesions.

Design: Cases were selected from voided and instrumented urine samples (catheterized, bladder wash, urethral wash) collected over a 50 month period. Urine samples had been processed into a single Papanicolaou stained ThinPrep slide. Cases reported to contain koilocytes were retrieved and reviewed to confirm the presence and number of koilocytes, document the relative ratio of squamous cells to urothelial cells, number of dysplastic keratinized/non-keratinized squamous cells and abnormal urothelial cells. When available, pathologic follow-up was reviewed.

Results: During the time period 12,142 urine samples were examined from 7,922 patients. 18 samples (15 voided, 3 cystoscopic) contained koilocytes from 10 patients (6 women, 4 men). The mean age was 50 years (range: 25-85). Five patients were organ transplant recipients (kidney – 1 man, 3 women; lung – 1 woman). Slides contained a mean of 9.3 koilocytes (range 1-26). Squamous cells outnumbered urothelial cells in 9 samples, squamous cells = urothelial cells in 4 samples and squamous cells < urothelial cells in 5 samples. 8 cases from 7 patients contained abnormal keratinized squamous cells. 15 cases from 8 patients contained abnormal/malignant urothelial cells. On follow-up, 1 woman had an anal squamous carcinoma and although her urine sample showed koilocytes with dysplastic keratinized squamous cells, there were no abnormal urothelial cells. One man was found to have an invasive urothelial carcinoma and his urine samples showed koilocytes, abnormal keratinized squamous cells and malignant urothelial cells. In the remainder of the patients pathologic documentation of the source of the cells was not available. In 5 of these 8 patients abnormal urothelial cells were identified in the urine in addition to the koilocytes including 4 of the 5 transplant patients.

Conclusions: Although many patients had not been investigated for the source of the urinary koilocytes, the presence of abnormal urothelial cells in many of the cases suggest the possibility of an origin from or coexistence with a urothelial lesion. One half of the patients were immunosuppressed following solid organ transplant and the presence of the HPV in the urine with abnormal urothelial cells may suggest an etiologic role in the development of urothelial neoplasms in these patients.

288 The Diagnostic Effects of Prolonged Storage on Fresh Effusion Samples

F Manosca, M Schinstine, P Fetsch, K Brosky, D Erickson, A Wilder, L Sorbara, M Raffeld, A Filie, A Abati. National Institutes of Health/National Cancer Institute, Bethesda, MD.

Background: The potential for effusion cellular degeneration has led many laboratories to immediately fix samples rather than submit fresh / refrigerated samples for cytologic examination. We sought to examine the effects of delayed processing on morphology, immunocytochemistry (IC) and DNA amplification, all of which may be necessary for an accurate pathologic evaluation.

Design: Specimens received from 10 fresh effusions were kept refrigerated at 4°C. At specific points in time (Days 0, 3, 5, 7, 10, 14) samples were processed for diagnostic evaluation, IC and PCR. For each sample on each day the following were prepared: 2 Diff Quik / 2 Papanicolaou stained cytospins (CS) and a cell block (CB). IC staining for commonly used surface, cytoplasmic, and nuclear markers (AE1/AE3, EMA, calretinin, and LCA) was performed on the CBs. The CS and CB were assessed for cellularity, morphology and IC staining patterns. Amplification of DNA was evaluated via testing for the housekeeping gene, glyceraldehyde phosphate dehydrogenase (GAPDH), on Day 14 in 8 of 10 samples.

Results: Specimens evaluated include 4 pleural (negative (n=3), breast adenocarcinoma (n=1) and 6 peritoneal effusions (ovarian adenocarcinoma(n=2), melanoma(n=1), mesothelioma(n=2), atypical mesothelial cells(n=1). The morphology of the cytologic material from the ten effusions was preserved and interpretable after 14 days of storage at 4°C. Minor morphologic changes observed in the samples from Days 7 and 14 were: an increase in the number of degenerated cells, increase in fibrin and cellular clumping. The IC profile (AE1/AE3, EMA, calretinin, and LCA) was consistent from Day 0 to

Day 14. Amplifiable DNA was present as evidenced by a positive band for GAPDH in 8 of 8 samples tested on Day 14.

Conclusions: The storage of fresh effusions at 4°C yields cytologic material that is well preserved and satisfactory for morphologic, IC and molecular evaluation. The morphology of the cells is interpretable with minor degeneration for up to 14 days. The IC staining pattern is comparable from Days 0 to 14. Amplifiable DNA is present in all samples tested at Day 14. Thus, cytopathologic interpretation remains reliable with refrigeration at 4°C even if processing is delayed.

289 Fine Needle Aspiration (FNA) of the Kidney. Concordance of Cytologic Typing/Grading with Histology in 31 Renal Masses

S Masoom, G Venkataraman, J Jensen, R Flanigan, EM Wojcik. Loyola University Medical Center, Maywood, IL; Edward Hines Jr Hospital, Hines, IL.

Background: Given the advancement of renal imaging modalities in the recent years, a greater number of RCCs with tumor size of <3cm are being detected radiologically. Consequently, there is a pressing need for accurate typing as well as grading of RCC which, in turn, will aid in selection of cases of nephron sparing surgeries, partial nephrectomies or even non-surgical measures like cryoablation.

Design: A total of 31 cases of renal masses with correlating FNA and surgical resection were retrieved from our files. The mean age of these patients was 61.4 years (13.14, SD). The mean size of the renal masses was 7.3 cm (4.2 cm, SD). They included 28 RCCs (17 clear cell, 8 papillary and 2 chromophobe), 1 oncocytoma, 1 liposarcoma, and two benign lesions (1 xanthogranulomatous pyelonephritis and 1 benign cyst). Two investigators blindly reviewed all FNA material. The degree of concordance between cytologic typing/grading and histologic typing/grading was assessed. These revised FNA diagnoses were compared with the original FNA diagnosis. All results were tabulated into an MS Excel Worksheet for examination and analysis of descriptive statistics. Measures of agreement and Kappa Statistics were computed using SPSS 10 (SPSS Inc., Chicago, IL).

Results: There was an excellent agreement between the FNA typing and the final diagnosis on the surgical specimens with correct classification in 28 of 31 cases (87%; Cohen's Kappa = 0.42; p=0.043). In addition, there was excellent concordance between the grade assigned on FNA and the final tumor grade on histopathology. Among the three discordant cases, two of them were RCCs. The first one was a papillary type 1 RCC that was misdiagnosed on FNA as Clear Cell RCC. Another case that was typed as a papillary type 2 RCC on final histopathology was diagnosed as having suspicious cells on FNA. The third case was a xanthogranulomatous pyelonephritis that was misdiagnosed on FNA as a RCC with necrosis.

Conclusions: There is an excellent concordance between renal FNA diagnosis and the final histologic diagnosis, especially in RCCs. There is a tendency for misdiagnosis of papillary RCC. Lesions with extensive necrosis and relatively insufficient diagnostic material on FNA specimens must be interpreted with caution to avoid potential misinterpretation. Better concordance might be observed with more extensive sampling.

290 Comparisons of the Efficacy of 4 Mesothelial Markers in Pleural Fluid Cytology

RS Meara, IA Eltoun, DK Horton, L Whitlow, DC Chhieng. University of Alabama at Birmingham, Birmingham, AL.

Background: The differentiation between metastatic carcinoma and mesothelial cells in pleural fluid specimens based on morphology alone can be a diagnostic challenge. Immunocytochemistry is often used to aid the differential diagnosis. During the past decade, several mesothelial markers have been discovered and used in routine practice. The objective of this study is to compare the efficacy of 4 commercially available mesothelial markers in differentiating mesothelial cells from metastatic carcinoma in pleural fluids.

Design: Forty formalin-fixed, paraffin-embedded cell blocks were retrieved from the archives and immunostained with 4 primary antibodies directed against calretinin (Cal) (clone Z11-E3; prediluted; Ventana, Tucson, AZ), mesothelin (Meso) (clone 5B2; 1:60 dilution; Novocastra, New Castle, UK), cytokeratin (CK) 5/6 (clone D5/16B4; 1:25 dilution; Invitrogen, Carlsbad, CA), and Wilms tumor (WT) 1 (clone 6F-H2; 1:50 dilution; Dako, Carpinteria, CA). Eighteen specimens were benign/reactive effusions. Twenty-one were pleural effusions with metastatic carcinoma from lung, breast, pancreaticobiliary tract, urinary tract, and ovary. We also included a fine needle aspiration of a malignant mesothelioma from a lymph node. Positive staining was defined as the presence of nuclear staining with calretinin and WT-1, cytoplasmic staining with CK5/6, and membranous and/or cytoplasmic staining with mesothelin. Follow up included review of corresponding histology and medical record.

Results: The differences in the staining pattern between carcinomas and mesothelial cells were statistically significant (p<0.05) for each marker. Table 1 summarizes the sensitivity (SEN), specificity (SPEC), positive and negative predictive values (PPV, NPV), and likelihood ratio (LR) for each marker and various combinations in identifying mesothelial cells.

Conclusions: All markers distinguish mesothelial cells from metastatic carcinomas in pleural fluid specimens. Calretinin is the most sensitive and specific mesothelial marker followed by WT-1, mesothelin, and CK5/6. There is no statistically significant difference in the sensitivity and specificity when calretinin is combined with any one of the other markers.

Table 1 Efficacy of various antibodies as mesothelial marker

	Calretinin	WT-1	CK 5/6	Mesothelin	Cal/ WT-1	Cal/ CK5/6	Cal/ Meso
Sensitivity	90%	83%	94%	89%	83%	88%	88%
Specificity	95%	86%	65%	77%	86%	87%	86%
Likelihood ratio	31.2	21.3	16.5	19.2	21.3	24.9	25.2
Positive Predictive Value	95%	83%	67%	76%	83%	83%	84%
Negative Predictive Value	90%	86%	93%	89%	86%	91%	90%

291 Biliary Tract Brush Cytology: Diagnostic Accuracy & Limitations

C Meroueh, KJ Jabbar, B Al-Khafaji. St John Hospital & Medical Center, Detroit, MI.

Background: Despite recent advances in imaging techniques, biliary tract brush cytology remains the cornerstone for providing a definitive diagnosis in the majority of bile duct malignancies. However, several previous studies have evaluated the cytological results without including the atypical diagnostic category when evaluating the tests diagnostic accuracy.

Design: Biliary Tract Brush cytology obtained by ERCP between July 2001- July 2005, were identified through our computerized database. For each brush specimen cytospin slides were prepared. Cytologic diagnoses included four categories: 1) benign, 2) atypical, 3) malignant, and 4) Unsatisfactory for evaluation (including acellular specimens). Surgical biopsy follow-up diagnoses were considered the standard. Sensitivity, Specificity, Positive Predictive Value (PPV), and Negative Predictive Value (NPV), were calculated when atypia was considered 1) in the malignant, and 2) in the benign category.

Results: A total of 124 cases were identified, 69 were male and 55 female (age range of 13-79 yr). Surgical follow-up (SgFu) was available in 82 (66.3%) patients.

Cytology Diagnosis	Surgical Diagnosis				Total
	Benign	Malignant	Unsat	No SgFU	
Benign	39	4	0	11	43.6% (n=54)
Atypical	15	3	0	17	28.2% (n=35)
Malignant	0	10	0	12	17.7% (n=22)
Unsat	4	5	2	2	10.5% (n=13)
					100% (N=124)

Unsat, unsatisfactory.

	Sensitivity	Specificity	PPV	NPV	FP
Atypical included in Benign	58.8%	100%	100%	88.5%	0
Atypical included in Malignant	76.4%	72.2%	46.4%	90.7%	15

FP false positives.

The consideration of the atypical cases as benign demonstrates a perfect PPV, and specificity of 100%, of course to the detriment of a much lower sensitivity of only 58.8%, and a NPV of 88.5%. On the other hand, atypical being equated with malignancy improves the sensitivity to 76.4% with a NPV of 90.7%, while dramatically reducing the specificity (72.2%) and PPV (46.4%). Furthermore, the atypical category represents 28.2% of the total number of cases, with an unsatisfactory rate of 10.5%, which rises the total number of inconclusive diagnoses to an alarming 38.7%.

Conclusions: While the results of this study confirm the role of biliary tract brush cytology in correctly diagnosing the majority of biliary tract malignancies, it highlights the diagnostic limitations of both unsatisfactory samples, plus a high percentage of atypical diagnoses. Further studies are suggested to identify possible cytologic criteria and additional molecular methods to reduce the current diagnostic limitations.

292 Cellular Adequacy for Thyroid Aspirates Prepared by ThinPrep: How Many Cells Are Needed?

CW Michael, Y Pang, RT Pu, F Hasteh, KA Griffith. University of Michigan, Ann Arbor, MI; University of Michigan, Ann Arbor, MI.

Background: Although it is well established that ThinPrep (TP) introduces artifacts to thyroid aspirates, to date no criteria have been established for adequacy of such specimens. This study evaluates the adequate number of cells needed to establish the correct diagnosis based on TP slides alone.

Design: A total of 218 thyroid aspirates prepared by TP with surgical pathology follow-up were reviewed blindly and given a cytologic diagnosis each. The cellularity was calculated in a manner similar to that used for ductal lavages. Adequacy to render a definitive diagnosis was assumed arbitrarily at 6 clusters with 10 cells each. Cytologic diagnoses (CTD) were classified as: Nondiagnostic (ND), cystic contents, thyroiditis, nodular hyperplasia (NH), follicular/Hurthle cell (F/H) lesion, F/H neoplasm, and carcinoma: qualify. Histologic diagnoses (HTD) were classified as: Cyst (colloid or otherwise), thyroiditis, NH, F/H adenoma, F/H carcinoma, and carcinoma: qualify. Appropriate treatment triage was considered to be clinical for the former 4 CTD with ND warranting repeat aspiration and surgical for the latter 3 CTD. The results were subjected to logistic regression analysis and contingency tables correlating the number of cells with the CTD, HTD, and treatment triage for each case. Cellularity was ranked in 10 deciles according to the number of cells. The agreement percentage, for both diagnosis and treatment, was computed for each decile.

Results: 146 (67%) cases had cells and received a diagnosis while 72 (33%) were ND (51 cases were acellular and 21 contained colloid or histiocytes only). Of the 146 cases, 21 contained suboptimal number of cells in addition to histiocytes or colloid and 125 cases were adequate. 91/146 (62.3%) were correctly diagnosed and 123/146 (84.3%) would have been correctly triaged for treatment. Samples with 180 cells or fewer (first 2 deciles) had an agreement rate below 50%. Agreement rate increased to 80% when cellularity was 180-320 (third decile). Above 180 cells agreement rate increased, but not uniformly.

Conclusions: There does appear to be a threshold at the cellular range of 180-320, where the agreement rate increased substantially from 50% to 80%. Although agreement rates were not strictly uniform above 320 cells, they were 72.5% and 85.3% for those cases with diagnoses and treatment respectively.

293 Cyst Fluid Analysis and Endoscopic Features Aid in the Preoperative Grading of Intraductal Papillary Mucinous Neoplasms of the Pancreas

PJ Michaels, SE Rollins, BC Bounds, WR Brugge, MB Pitman. Massachusetts General Hospital, Boston, MA.

Background: Intraductal papillary mucinous neoplasms (IPMN) are increasingly recognized cystic neoplasms of the pancreas. The use of endoscopic ultrasound-guided fine needle aspiration biopsy (EUS-FNAB) allows for simultaneous cytological sampling and detailed radiologic evaluation. In addition, chemical analysis of cyst fluid for biochemical and tumor markers can assist in the diagnosis. We evaluated the

impact of specific endoscopic features and cyst fluid analysis on the cytological diagnosis in a series of confirmed IPMNs.

Design: The study population consisted of 27 patients (11 men, 16 women) with histologically (22) or clinically (5) proven IPMNs who had pre-operative cytological evaluation by EUS-FNAB. IPMNs were evaluated radiologically for the presence of mural nodules, number of septations, and outer wall thickness. Fluid was analyzed for amylase by polyacrylamide gel electrophoresis and for CEA by commercial immunoassay. There were 12 IPM carcinomas (CIS or invasive carcinoma) and 15 low grade IPMNs (adenoma or moderate dysplasia).

Results: Endoscopic evidence of a mural nodule was found in 6 of 12 IPM carcinomas, compared to only one of 15 low grade IPMNs ($p = 0.01$). Multiple septations were identified in the majority of IPM carcinomas (7 of 12) but were seen in only 2 of 12 low grade IPMNs ($p = 0.04$). Thick walls were visualized in 80% of IPM carcinomas but were found in only 20% of low grade neoplasms ($p = 0.01$). Cyst fluid CEA levels ≥ 500 ng/mL were found in 12 of 16 specimens from IPM carcinomas, compared to 7 of 15 low grade IPMNs ($p = 0.01$). Of the 12 patients with IPM carcinoma, only 6 had pre-operative cytologic features that were suspicious or positive for malignancy. Of the remaining 6 cases, all had at least one of the following four features: CEA ≥ 500 ng/mL, mural nodule, multiple septations, or a thick wall. In contrast, only 7 of 15 low grade IPMNs had at least one of these features ($p = 0.02$).

Conclusions: Endoscopic findings of a mural nodule, multiple septations, and/or a thick-walled cyst support the diagnosis of an IPMN with at least carcinoma in situ over a low grade IPMN. Although not specific, an elevated cyst fluid CEA level (≥ 500 ng/mL) suggests the diagnosis of an IPM carcinoma. When taken in conjunction with conventional cytologic evaluation, radiologic features and cyst fluid analysis aid in the grading of IPMNs.

294 Cytology and Flow Cytometric Evaluation of Bone Lesions in Plasma Cell Myeloma

S Momtahan, M Yared, R Glenn, M Gokden. University of Arkansas for Medical Sciences, Little Rock, AR.

Background: Plasma cell myeloma (PCM) is a bone marrow-based, multifocal plasma cell neoplasm. Lytic bone lesions are typically present in PCM and are identified by computerized tomography (CT). In our institution, these patients undergo CT-guided fine needle aspiration biopsy (CTFNA) of their lesions. Here, we analyzed these cases to investigate the diagnostic utility of CTFNA.

Design: In the cytopathology files of the University of Arkansas for Medical Sciences, between 2003 and 2005, 294 consecutive PCM patients, who have undergone CTFNA of their bone lesions, were identified. Cytological diagnoses and the corresponding flow cytometry (FCM) results of the simultaneously submitted material were reviewed. Cytological diagnosis was based on the examination of four air-dried and Diff-Quik-stained cytospin slides from each aspiration. Presence of plasma cells in this group of patients with previously established PCM diagnosis was considered positive. FCM evaluation included cytoplasmic immunoglobulin (CIG), kappa and lambda light chain. Data were analyzed for the correlation of both test results.

Results: Of the 294 consecutive CTFNAs with cytology and FCM results available, 155 (52%) were positive for PCM by both methods, and 62 (21%) were negative by both methods; 48 cases (16%) were positive by CTFNA and negative by FCM, while 29 cases (9%) were positive by FCM and negative by CTFNA. A total of 184 cases were positive, 110 cases were negative by FCM. CTFNA was positive in 203 cases and negative in 91 cases. CTFNA was slightly more sensitive over FCM (84% vs. 76%).

Conclusions: CTFNA and FCM are effective methods in the follow-up diagnosis of bone lesions in PCM, although CTFNA has a slightly higher sensitivity in this setting. When used together, 79% of bone lesions can be diagnosed as positive for PCM, without the need for needle core biopsy.

295 Determination of Specimen Adequacy and the Presence of Transformation Zone Component Using an Automated Internet-Based Telecytology System for Cervical Cytology

JA Nagle, JH Eichhorn, BA Crothers, DC Wilbur. Massachusetts General Hospital, Boston, MA; Walter Reed Army Medical Center, Washington, DC.

Background: In order to implement a newly designed cervical screening system that allows review of only a portion of the slide surface it is necessary to determine if adequacy assessments can be reliably made. We tested our ability to do so using a computerized location guided screening process in which images for review were device-captured and transmitted to review stations via the Internet.

Design: Liquid-based cervical cytology slides (ThinPrep (TP)(Cytyc) and SurePath (SP)(Tripath)) were scanned using an automated screening device (FocalPoint (Tripath)). Up to 30 low resolution black and white images were acquired from each case and transmitted via the Internet to custom reading stations. Two independent reviewers determined if each case was satisfactory or unsatisfactory based on squamous cellularity assessments. The presence of transformation zone components (TZC) (endocervical or metaplastic cells) was also noted as well as the first FOV (arranged hierarchically) in which they appeared. Results were compiled and compared between reviewers, and against device generated adequacy assessments.

Results: In total 189 slides (90 TP, 99 SP) were analyzed. In 3 slides with reference interpretations of unsatisfactory, 2 were labeled as such, and 1 was labeled as satisfactory by both reviewers. Of 378 TZC assessments (2/slide), 316(84%) indicated that TZC was present within the first 10 FOV's, 29(8%) in the second 10 FOV's, 11(3%) in the third 10 FOV's, and 22(6%) showed no TZC present. Reviewers agreed on exact FOV number containing TZC in 44% of cases. In 21% of cases, TZC was noted by both reviewers in the first FOV examined. The screening device indicated lack of endocervical component in 19 cases - in 11(58%) of these cases both reviewers noted the presence of TZC (4 with metaplastic cells only).

Conclusions: The presence of TZC was consistently identified by reviewers primarily within the first, first 10, or 20 FOV's of the review process (44, 84, 92%, respectively). Reviewers agreed on the exact FOV of first evidence of TZC in nearly 1/2 of cases. Accurate identification of unsatisfactory cases (2/3, 67%) may require additional training and experience. Device assessments of endocervical component were judged to be incorrect in greater than 1/3 of cases. The data suggest that this system of limited FOV review may be acceptable for assessments of specimen adequacy.

296 Determining the Effective Cervical Cytology Triage Point Using an Automated Internet-Based Telecytology System with Hierarchical Image Review

SS Nanji, JH Eichhorn, BA Crothers, DC Wilbur. Massachusetts General Hospital, Boston, MA; Walter Reed Army Medical Center, Washington, DC.

Background: Despite the effectiveness of cytological screening, cervical cancer remains one of the most common cancers among women worldwide, primarily due to lack of access to screening programs. Utilization of automated location-guided screening with Internet transmission and remote interpretation may be an effective solution to optimize productivity. The present goal of the study is to determine the number of images that need to be reviewed in order to provide effective specimen triage.

Design: Liquid-based cervical cytology slides (ThinPrep (Cytyc) and SurePath (TriPath)) were scanned using an automated screening device (FocalPoint, TriPath). Up to thirty low-resolution (black and white) fields of view (FOV) from each slide were transmitted to reading stations. The images were hierarchically arranged - the first image had highest probability of abnormality and so forth. FOVs were interpreted independently by 7 cytologists (3 cytotechnologists and 4 physicians) and general (NILM/abnormal) and specific (Bethesda 2001) interpretations rendered. For each abnormal interpretation, the first FOV containing abnormality was recorded, as this would represent the "triage point." Data was compiled to show the percentage of triage points in the 1st 10, 2nd 10 and 3rd 10 FOV's.

Results: 92 slides (92x7=644 interpretations) with general reference interpretations of abnormal (5 AGC, 3 ASC-H, 4 ASC-US, 62 LSIL, 18 HSIL) were analyzed (95 NILM cases were scanned and reviewed but are irrelevant in this analysis). Of the 644 interpretations, 75% were identified as abnormal and of these, the triage point was present in the first 10 FOV's in 93% of cases (ASC-US (100%), ASC-H (82%), HSIL (93%), LSIL (92%), AGC (94%)). In the first 20 FOV's the triage point was noted in 100% of ASC-US, ASC-H, HSIL and AGC cases and in 99% of LSIL cases. The first FOV was the triage point in 50% of the abnormal cases.

Conclusions: The system was found to be very robust in the identification of abnormality in the first FOV (50%), the 10 highest (93%) and the 20 highest (99%) FOV's. These findings suggest that using this system, examination of 20 images may be sufficient as a screening (triage) tool. Implementation of this process has the potential to improve efficiency and accessibility of screening to underserved populations via highly productive and centralized interpretation.

297 Is There a Difference in the Results of High Risk Human Papillomavirus Testing in Cases of Atypical Squamous Cells of Undetermined Significance When Microorganisms Are Reported?

JF Shikle, ES Campenot, TW O'Hara. Naval Medical Center San Diego, San Diego, CA.

Background: When using Thinprep® liquid based cytology, Hybrid Capture II® testing for high risk human papilloma virus DNA (HRHPV) is performed on ASCUS cases. Occasionally, microorganisms such as coccobacilli, candida, and trichomonas are reported as separate findings. Cytoplasmic cavitation and subtle nuclear changes such as hyperchromasia, enlargement, or contour irregularity can occur secondary to these organisms, and may lead to classification of some cases as ASCUS. The presence of these microbes could reflect host factors which render the lower genital tract more susceptible to infection. This study was designed to see if there was a difference in the fraction of HRHPV positive cases in patients diagnosed with ASCUS and microorganisms versus patients with ASCUS as the sole diagnosis.

Design: Pap smears classified as ASCUS with HRHPV testing results from 2004 were reviewed. Age, microorganisms reported, and HRHPV (positive or negative) results were tabulated. Data from patients over 35 years of age and cases where HRHPV results were indeterminate were excluded. Calculations were performed to determine if there was a difference in the HRHPV results in patients with ASCUS and microorganisms versus patients with ASCUS reported as the sole diagnosis.

Results: A total of 1240 Pap smears classified as ASCUS with HRHPV testing results were analyzed. HRHPV was positive (POS) in 47 % (586 of 1240) of women with ASCUS overall. 190 (15 %) women had microorganisms reported, and of these women 51 % (97 of 190) were POS for HRHPV. Of the patients with ASCUS reported as the sole diagnosis, 47 % (489 of 1050) were HRHPV POS. Chi-square analysis demonstrated no statistically significant difference in the rate of HRHPV positivity between the ASCUS with microorganisms reported group versus the ASCUS reported as the sole diagnosis group.

Conclusions: The rate of HRHPV positivity was similar in patients with microorganisms reported (51%) versus patients with ASCUS reported as the sole diagnosis (47%). The similar rates of HRHPV positivity in both groups reflects the utilization of consistent criteria for ASCUS even when other findings are described. This study of women 35 years of age and younger demonstrates that there is no difference in the results of HRHPV testing in cases of ASCUS when microorganisms are reported at our institution.

Microorganisms Reported	ASCUS with Microorganisms Reported	
	HRHPV pos	HRHPV neg
Yes	51%	49%
No	47%	53%

298 A Comparison between Immunocytochemical Staining of Pap Tests with p16^{INK4A} and High-Risk HPV Results: A Review of 70 Cases

K O'Reilly, C Cohen, A Radhakrishnan, MT Siddiqui, A Nassar. Emory University Hospital, Atlanta, GA.

Background: Human papilloma virus (HPV) is known to cause cervical carcinoma (CCA). High-risk HPV types are particularly associated with progression to CCA by assimilation of HPV oncogenes E6 and E7 into DNA, promoting upregulation of the cyclin dependent kinase inhibitor p16^{INK4A}. The p16^{INK4A} antigen is detectable in developing precancerous and cancerous cervical cells. Currently, high-risk HPV (HR-HPV) testing by the Digene Hybrid Capture® (HC) II HPV DNA test is routinely performed on Pap smears demonstrating atypical squamous cells (ASC-US). We compared the results of p16^{INK4A} immunocytochemical staining (IHC) on liquid-based (SurePath™) and/or cytosin prepared cervical cytology specimens to HR-HPV Digene HC II test results (gold standard).

Design: We performed p16^{INK4A} IHC staining and HR-HPV Digene HC II testing on 70 abnormal Pap smears diagnosed as atypical squamous cells (ASC-US) (27), low-grade squamous intraepithelial lesion (LGSIL) (31), and high-grade squamous intraepithelial lesion (HGSIL) (12). Thirty-one (44%) had biopsy follow-up. The cases were prepped by SurePath™ and/or cytosin. IHC staining was performed, after antigen retrieval, with p16^{INK4A} monoclonal antibody (CINtec™ p16^{INK4A} cytology kit for the DakoCytomation Autostainer). Expression of p16^{INK4A} within the nucleus principally, and cytoplasm was considered a positive reaction. The frequency of p16^{INK4A} immunopositivity in the different categories of ASC-US, LGSIL, and HGSIL and the sensitivity and specificity of p16^{INK4A} staining compared to HR-HPV Digene HC II testing were analyzed.

Results:

Diagnosis	p16+	HPV+	Follow-up	Biopsy Results Neg/CINI/CINI-III
ASC-US	14%	29%	6/27 (22%)	6/00
LGSIL	42%	73%	13/31 (42%)	7/51
HGSIL	67%	92%	8/12 (67%)	3/14

Diagnostic Category	p16+	Sensitivity	Specificity
ASC-US	14%	38%	95%
LGSIL	42%	41%	55%
HGSIL	67%	64%	0%

Conclusions: 1) Increased positivity of p16^{INK4A} IHC staining was observed in high-grade versus low-grade disease 2) IHC staining for p16^{INK4A} is not as sensitive as HR-HPV testing for dysplastic lesions (LGSIL and HGSIL) 3) Negative p16^{INK4A} IHC staining in ASC-US is specific for the absence of high-risk disease (specificity is 95%). These results suggest that negative p16^{INK4A} staining in ASC-US lesions is specific for the absence of high-risk disease and may be a useful tool in determining treatment options and triaging patients.

299 Stratifying the Indeterminate Diagnosis in Fine Needle Aspiration Biopsy of Pancreatic Lesions: Multiple Cytomorphologic Parameter Analysis of Atypical and Suspicious Cases

K Onuma, KE Schoedel, NP Otori. University of Pittsburgh Medical Center, Pittsburgh, PA.

Background: Endoscopic ultrasound (EUS) guided fine needle aspiration biopsy (FNA) is widely used as a standard diagnostic approach for pancreatic lesions. The cytologic features for pancreatic adenocarcinoma have high diagnostic specificity but low sensitivity. Accordingly, a subset of cases is diagnosed as indeterminate (atypical or suspicious). The purpose of this study is to quantitate the presence of malignant features in indeterminate cases and correlate the results to pathologic outcome.

Design: Two hundred thirty-two (232) EUS-guided pancreatic FNA specimens were obtained and evaluated from January to December 2003. Cytologic diagnoses consisted of the following: 79 negative for malignant cells, 35 Aty, 12 Susp, 86 positive for malignant cells, 9 positive for neoplasm, and 11 unsatisfactory. Of the 35 atypical and 12 suspicious cases, 22 cases (15 atypical and 7 suspicious) were available for review and had follow-up information for diagnostic outcome. Each case was analyzed by 8 cytomorphologic parameters (1. cellularity, 2. macronucleoli, 3. nuclear molding, 4. enlarged nucleus, 5. anisonucleosis, 6. nuclear membrane irregularity, 7. overlapping and 8. irregular chromatin), and correlated with final diagnosis.

Results: The final outcomes were 13 ductal adenocarcinomas, 1 intraductal papillary mucinous carcinoma, 1 neuroendocrine neoplasm, 1 focal low grade PanIN, 2 mucinous cystadenoma, 3 chronic pancreatitis, 1 sclerosing mesenteritis. The majority of aspirates that yielded a suspicious diagnosis proved to be malignant (6/7, 86%). By comparison, 53% (8/15) of atypical diagnoses proved to be malignant.

Final Dx	Cytology Dx	1	2	3	4	5	6	7	8
Adenocarcinoma	Atypical (8)	7/8	2/8	3/8	5/8	0/8	6/8	7/8	4/8
	Suspicious (6)	6/6	5/6	3/6	5/6	4/6	5/6	6/6	5/6
Benign or Others	Atypical (7)	3/7	0/7	1/7	2/7	1/7	2/7	4/7	0/7
	Suspicious (1)	1/1	1/1	0/1	0/1	1/1	1/1	1/1	0/1

1-8 correspond to cytologic parameters (see "Design")

Average number of parameters in two groups	Score
Atypical or Suspicious Dx with Final Dx of Adenocarcinoma	4.38
Atypical or Suspicious Dx with Final Dx of Benign or Others	1.67*

*P=0.00098

Conclusions: The presence of more than four parameters favors adenocarcinoma over other diagnoses. Of the parameters analyzed, irregular chromatin pattern has the highest predictive value for malignancy.

300 Human Papillomavirus Protein Expression and Its Relationship with Cell Morphologic Features in Low Grade Squamous Intraepithelial Lesions

MO Osorio Peralta, CD Morales, A Garcia Carranca, AM Cano Valdez, R Sotelo-Regil, HR Dominguez Malagon. Instituto Nacional de Cancerologia, Mexico.

Background: Morphologic criteria used to establish Human Papillomavirus (HPV) infection diagnosis in cervicovaginal smears are variable because they include the presence of koilocytes or a combination of "non-classical criteria". Adequate recognition of non-classical criteria may improve the diagnostic value of Papanicolaou test in low-grade squamous intraepithelial lesions (LSIL). Since viral gene expression is closely related to host cell differentiation in productive infections, this study was designed to analyze if there is a correlation between expression of early and late HPV genes and cell morphology in Pap smears.

Design: Analysis of exfoliated cells morphology was done by conventional cytology in 14 women with diagnosis of LSIL. Viral and cellular antigens were detected either with thin-layer preparations or histological sections using specific monoclonal antibodies. HPV typing was achieved by PCR and sequencing from the L1 region. In situ hybridization assays were performed to detect amplification of viral genome. Late genes were studied by direct detection of the L1 protein. Because direct detection of early genes, particularly E7 is difficult, proliferating cell nuclear antigen (PCNA) expression has been used as a surrogate marker.

Results: As marker of E7 viral protein expression, PCNA reactivity was detected in deep and intermediate cells from all cases. Directly immunodetected L1 protein was found only in productive "low" and "high" risk HPV infections; productive infections were associated with koilocytes, dyskeratocytes and keratinization of squamous cells.. Koilocytes were found in 4/6 "low" risk virus infected samples and in only 3/8 "high" risk virus infected samples.

Conclusions: Presence of early and late viral proteins in exfoliated cells from LSIL correlates with koilocytes, dyskeratocytes and keratinized squamous cells, independently of viral type. Koilocytes were more frequently found in "low" risk virus infected lesions.

301 Role of Fine Needle Aspiration Biopsy and Flow Cytometry Analysis in the Diagnosis of CD30+ Anaplastic Large Cell Lymphoma

T Oweity, CZ Liu, A Bazooband, S Ibrahim. New York University, New York, NY.

Background: CD30 + anaplastic large cell lymphoma (ALCL) is a T-cell or null-cell type lymphoma with distinct pathologic and clinical features. Morphologically the differential diagnosis is broad. Accurate diagnosis and classification are essential for prognostic and treatment purposes. As fine needle aspiration biopsy (FNA) is an increasingly recognized tool in diagnosing lymphoma, particularly when complemented with flow cytometry (FC), we attempted to evaluate its role in establishing primary and recurrent diagnosis of ALCL.

Design: We identified 19 patients with histologically proven ALCL, all underwent one or more FNA prior to, or following their histologic diagnoses (total 30 FNAs, 19 primary and 11 recurrent). Samples were submitted for FC in 15 cases. Immunostains were done in 7 cases. We evaluated the cytologic and flow cytometric diagnoses to identify factors negatively affecting accuracy and specificity of FNA.

Results: 21/30 FNAs (70%) were positive for malignancy (13 primary, 8 recurrent), 6 (20%) were atypical or suspicious (4 primary, 2 recurrent), 1 was negative (primary) and two were non-diagnostic (1 primary, 1 recurrent). 17 of the 21 positive cases (81%) were diagnosed as lymphoma: 1 type not-specified, 1 Hodgkin's, 1 large cell, 4 T-cell, and 10 consistent with ALCL. Of the 4 remaining positive cases (all primary) one was reported as a necrotic round cell tumor, and 3 suspected ALCL versus other malignancies. The single case initially reported as negative had prominent necrosis and histiocytic component. In 4 of 6 cases immunostains were performed on the smears, however the results were non-contributory due to necrosis or technical problems, while the immunostains were consistent with T-cell lymphoma in the single case where cell-block was available. Nine of the 15 cases submitted for FC (60%) were negative or had insufficient viable cells, and 6 (40%) were consistent with or worrisome for T-cell lymphoma, 3 of which were from the same patient. Prominent histiocytic component, necrosis and cell fragility limited the diagnostic accuracy and specificity.

Conclusions: Although a malignant diagnosis was rendered on FNA in most cases of ALCL, definitive accurate classification was achieved only in minority of primary diagnoses. The role of FC is limited in supporting cytomorphology. When the diagnosis of ALCL is morphologically suspected, adequate samples should be obtained for immunostaining, preferably on cell block material, in order to achieve a clinically essential accurate classification.

302 Comparison of Cytyc Imager Versus Manual Review of Cervical ThinPrep Slides

MC Pacheco, JW Bishop, RC Conley, DW Pennington. University of Cincinnati, Cincinnati, OH; LabOne of Ohio, Cincinnati, OH.

Background: The Cytyc ThinPrep imaging system is being used in the preliminary evaluation of cervical pap tests. The imager reviews each ThinPrep slide and selects 22 fields based on nuclear to cytoplasmic ratio and nuclear darkness. These field coordinates are recorded. A cytotechnologist reviews the slide using the reviewscope which relocates the selected fields. If the cytotechnologist finds an abnormality in any of the 22 fields, the entire slide is manually reviewed. Our laboratory began using the imaging system in January 2005. We compare agreement of pathologists to cytotechnologists before and after implementation.

Design: The data on final diagnoses in comparison to initial impressions from January to June of 2004 and 2005 was reviewed. n=Workload was 79791 for Jan thru June in 2004, and 76887 in 2005. All slides with a diagnoses of NIL-reactive, AGC, ASCUS, ASCH, LSIL, HSIL, AIS and carcinoma were reviewed by a pathologist along with the slides initially called NIL, NIL with organisms, or unsatisfactory which were upgraded on second cytotechnologist review. The number and type of changes from one diagnosis

to another after review by a pathologist was collected in a 'confusion matrix'. Cases called NIL, NIL-reactive and NIL with organisms were merged, and cases called ASCUS and ASC-H were merged. The sensitivity and specificity of initial impressions for ASCUS+, LGSIL+, and HGSIL compared to final diagnoses were calculated and the significance of the difference between the groups was analyzed using the two tailed student T-test. Daily workload per technologist was also monitored.

Results: For ASCUS+, there was no difference in sensitivity ($p=0.93$) before and after implementation, however there was a slight decrease in average imager aided review specificity, -0.24% , $p=0.017$. For LGSIL+ there was a slight decrease in sensitivity and specificity -2.6% , $p=0.037$, and -0.15% , $p=0.034$ respectively in imager review. HGSIL showed no significant change in sensitivity or specificity ($p=0.55$ and $p=1.0$ respectively). Technologist productivity increased.

Conclusions: We found the sensitivity and specificity for HGSIL unchanged by implementation of imager aided review; a slight decrease in sensitivity and specificity at the LGSIL+ level; and unchanged sensitivity but slightly decreased specificity at the ASCUS+ level. Its utility in increasing case throughput per cytotech cannot be overlooked.

303 Fine Needle Aspiration Biopsy Outcomes of Masses Detected by Positive Emission Tomography: Correlation with Standard Uptake Value

V Pansare, S Bandyopadhyay, J Feng, R Bhan, R Joyrich, M Husain, MA Al-Abbadi. Wayne State University and the Karmanos Cancer Institute, Detroit, MI.

Background: Positron Emission Tomography (PET) scan is an emerging technology for evaluation of neoplasms. It involves assessing tissue uptake of a radioactive form of glucose following intravenous injection. This uptake can be conveniently expressed as a Standard Uptake Value (SUV). Malignancy is generally associated with SUV values of 2.5 or greater. Often, PET positive patients will be referred for fine needle aspiration (FNA). The aim of this study was to identify and characterize the pathology of these cases and correlate FNA diagnosis with the SUV.

Design: We retrieved our FNA database in the period between January 2004 and July 2005, a total of 1076 FNA procedures were found. Out of these cases, 111 (10%) were performed on 96 patients because of a positive PET scan finding as indicated by the corresponding PET scan procedure database. The study was limited to patients who underwent FNA biopsy within 3 months of PET positive lesions located at the same anatomic site. When a range for the SUV was given due to heterogeneity of the suspected neoplasm, the average SUV was recorded.

Results: The organs aspirated included: 30 lung, 20 neck, 16 mediastinal lymph nodes, 5 thyroid, 4 bone, 7 soft tissue, 7 intra-abdominal lesions, 4 mediastinal, 3 axillary lymph nodes, 4 liver, 3 pancreas, 2 kidney, 2 spleen, 1 stomach, 1 adrenal, 1 scalp and 1 groin lesion. Fifty-nine of the 111 cases (53%) proved to be malignant by FNA, 29/111 were (26%) benign / non-neoplastic, 7/111 (6%) suspicious for malignancy, and in 16/111 (14%) the specimens were insufficient. For study purposes, suspicious and positive cases were considered as positive. Eighty of the 111 cases (72%) had $SUV \geq 2.5$, 24/111 (22%) had $SUV < 2.5$, while the SUV was unavailable in 7/111 (6%). Out of the 68 patients with adequate FNA specimens, 53 (78%) had SUV of 2.5 or greater and 15 (22%) had < 2.5 SUV. Conversely, malignancy was detected in 10/21 (48%) patients with adequate FNA specimens with $SUV < 2.5$.

Conclusions: Currently, about ten percent of our FNA biopsy procedures were performed for lesions initially detected by PET with a high positive predictive value of 78 percent and modest negative predictive value. We are currently investigating the impact of various factors on PET-FNA triage algorithms. We anticipate increasing utilization of PET to select patients for FNA biopsy procedure.

304 Soft Tissue Fine-Needle Aspiration Biopsy (ST-FNAB) Interpretation by House Officers: Analysis of Preliminary vs. Final ST-FNAB Diagnoses with Tissue Correlation

NP Patel, WG Ward, KR Geisinger. Wake Forest University Baptist Medical Center, Winston-Salem, NC.

Background: Most palpable soft tissue lesions are accessible via fine needle aspiration biopsy (FNAB). At many academic medical centers, experienced faculty cytopathologists (CPs) interpret FNABs of primary/recurrent soft tissue lesions. At many such centers with pathology residency programs, house officers (HOs) are the on-site pathologists evaluating ST-FNABs. The goals of this retrospective analysis are two-fold: (1) to evaluate the accuracy of preliminary ST-FNAB diagnoses rendered by HOs as compared to CP final diagnoses and (2) to evaluate accuracy of both HO and CP ST-FNAB diagnoses with subsequent histology specimens from the same anatomic site.

Design: From January 2002-December 2004, 395 ST-FNABs were performed. Of these, 271 (69%) had preliminary on-site diagnoses rendered by HOs. The on-site smears were air-dried and stained using Diff-Quik. The second smears were fixed in 95% ethanol and stained using the Papanicolaou method. Saline rinses were obtained in all cases and cell blocks were processed if available. Of the 271 ST-FNABs, 170 (63%) had subsequent histology specimens that were obtained from the same anatomic site and stained using hematoxylin-eosin. Specific diagnoses for both ST-FNABs and tissue specimens were grouped into 3 diagnosis categories (DCs): benign, borderline, or malignant.

Results: Of the 271 ST-FNABs, equivalent diagnoses were rendered by HOs and CPs in 229 (85%), 30 cases (11%) were undercalled and 12 cases (4%) were overcalled by HOs. 100% of the cases undercalled by HOs were within 1 DC. 11 of 12 (92%) overcalls were within 1 DC. Of the 170 cases with subsequent histology, equivalent diagnoses were made by HOs in 106 (62%) and by CPs in 120 (71%). 31 (18%) of diagnoses were undercalls by HOs; undercalls were made by CPs in 19 (11%). Concerning overcalls, 33 (20%) and 31 (18%) were made by HOs and CPs, respectively. Importantly, there were no frank false positive final cytology diagnoses. Overwhelmingly, spindle cell lesions comprised the vast majority of errors.

Conclusions: Our experience shows that HOs can accurately render on-site preliminary ST-FNAB diagnoses and thus effectively triage care for patients with such lesions. In addition, with a slight predilection for overcalling frank benign lesions as borderline, ST-FNAB correlates with subsequent resection histology in primary lesions.

305 Comparison of Endoscopic Ultrasound Guided Fine-Needle Aspiration Cytology vs. Trucut Biopsy

TC Pereira, M Levy, PC Souza, AC Clayton. Mayo Clinic, Rochester, MN.

Background: Endoscopic ultrasound-guided Fine Needle Aspiration (EUS-FNA) is being used increasingly for diagnosis and staging of intra-abdominal and intra-thoracic malignancies. Trucut biopsy (EUS-TCB) is a new technique that allows collection of a tissue core by endoscopic ultrasound. We compared the performance characteristics of EUS-TCB to EUS-FNA.

Design: Cases of patients that underwent both EUS-FNA and EUS-TCB of the same site at the same procedure at our institution from 1999 to January 2005 were retrieved and the slides were reviewed.

Results: 94 cases (from 92 patients), with both aspirate and trucut biopsies were analyzed. 72 cases had touch preps prepared from trucut biopsies as well. The trucut was essential for the diagnosis in 33 cases (the FNAs were negative in 3 cases, non-diagnostic in 14 cases, suspicious in 13 cases, and immunohistochemistry was needed for the definitive diagnosis in 3 cases.) The diagnoses in these 33 cases were: leiomyoma (7), GIST (6), lymphoma (6), spindle cell neoplasm (3), islet cell tumor (3), adenocarcinoma (3), other neoplasm (3) and non-neoplastic (2). The FNA was essential for the diagnosis in 14 cases (the trucut was negative in 6 cases, non-diagnostic in 6 cases, and suspicious in 2 cases). The diagnoses in these 14 cases were: adenocarcinoma (12), spindle cell neoplasm (1), and lymphoma (1). In 47 there was agreement between FNA and TCB: 22 were negative / non-diagnostic, 21 were positive, and 4 were suspicious. In 5 cases of adenocarcinoma the touch preps were better than the histology: the touches were positive in 3 cases where the histology was negative, non-diagnostic or suspicious, and the touches were suspicious in 2 cases where the histology was negative or non-diagnostic. However, in these 5 cases the FNA was diagnostic, so the touch preps added no additional information other than to assist the endosonographer with respect to the necessary number of biopsies.

Conclusions: Our data suggests that EUS TCB provides greater diagnostic accuracy than EUS FNA. The advantage of EUS TCB appears greatest for spindle cell tumors and lymphomas, mostly due to the ability to perform immunostains. We acknowledge that this advantage of the TCB might be smaller in institutions that routinely perform cell blocks in addition to smears in the FNAs. For adenocarcinomas, on the other hand, FNA can be superior than TCB. While touch prep specimens may influence the number of biopsies obtained by endosonographers, they appear to have negligible impact on diagnostic accuracy.

306 Support for Reflex UroVysion FISH in Diagnosing Urothelial Carcinoma. A Six Month Prospective Study Correlating > 1000 FISH and 10,000 Urine Cytology Cases

MJ Putzi, RL Roberts, PA Lewis, EJ Milionis, JR Oppenheimer, SB Shappell. OUR Lab, Nashville, TN; MOD Lab, Dallas, TX.

Background: Urine cytology is highly specific for urothelial carcinoma (UC), but lacks adequate sensitivity. UroVysion FISH (Vysis) has ~85 % sensitivity and 95 % specificity for high grade UC, and performs better than cytology for monitoring for UC recurrence. With higher cost and recent FDA approval for hematuria (no history UC) we hypothesized that experienced GU pathologists could use cytology to triage which cases need FISH. With cytospin cytology and 479 FISH tests, we recently showed significant correlation between cytology diagnosis and FISH results. The current study expands these observations.

Design: From Oct 1, 2004 to Mar 31, 2005, 1052 FISH tests were paralleled by >10,000 urine cytologies. Cases were submitted for FISH only; FISH and cyto; cyto + FISH if cyto non-neg; or cyto only, with FISH pathologist initiated for atypical or suspicious cyto. Cytology and FISH were on equal 15 ml aliquots of fixed urine using 20 mm ThinPrep (Cytyc) slides. FISH used Vysis UroVysion and AI CytoVision Image Analysis on Olympus BX61 fluorescence microscopes. Criteria for positive were ≥ 4 cells with ≥ 3 probe signals for ≥ 2 of CEP3Red, CEP7Green, or CEP17Aqua or homozygous loss of LSI9p21Gold in ≥ 12 cells.

Results: In 416 FISH only cases, FISH was informative in 98.3 %, positive in 28.1 %. For 636 cases with cytology, FISH was informative in 95 %, positive in 32.1 %. Only 1/68 (1.5 %) with negative cytology had positive FISH. In contrast, 102/406 (25.1 %), 78/116 (67.2 %), and 12/12 (100 %) of cases with atypical, suspicious, and positive cytology, respectively, had positive FISH ($p < 0.05$). In 784 cases with history of UC, FISH was positive in 27.7 % FISH only and in 1.8 %, 28.4 %, 64.7 %, and 100 % of cases with negative, atypical, suspicious, and positive cytology, respectively ($p < 0.05$). In 255 cases without a history of UC (>90 % for hematuria), FISH was positive in 0 %, 20.4 %, 57.9 %, and 100 % with negative, atypical, suspicious, and positive cytology, respectively ($p < 0.05$).

Conclusions: With experienced pathologists, urine cytology is useful for triaging which cases need FISH in patients with history of UC or with hematuria. Cases with negative or positive cytology may not need molecular analysis. Cases with diagnoses of atypical or suspicious can be submitted for Reflex FISH, and patients can be managed based on results of this FISH, with high predictive values for cystoscopy findings.

307 Diagnostic Terminology and Reporting of Thyroid Fine Needle Aspiration Biopsy Results: A Survey of Clinicians

R Redman, BJ Yoder, NA Massoll. University of Florida, Gainesville, FL.

Background: Thyroid fine-needle-aspiration-biopsy (FNAB) has proven to be essential in the stratification of patients with thyroid nodules. Published guidelines on the

performing and reporting of thyroid FNAB stress the importance of succinct and unambiguous terminology on the final cytology report in order to maximize treatment options. Clinician understanding of the current diagnostic terminology and how they associate these categories in terms of patient care is unknown.

Design: Surveys were mailed to 382 clinicians (endocrinologists, radiologists, surgeons, and thyroid specialists) who are active members of a national thyroid organization and refer patients for and/or routinely perform thyroid FNABs. The voluntary questionnaires asked how they would correlate the pathologic diagnostic categories of: "Atypical", "Indeterminate", "Suspicious", and "Non-diagnostic" to the patient care options of "Negative FNAB / Follow Up", "Repeat FNAB", and "Proceed to Surgery". The results of the anonymously returned surveys were entered into a spreadsheet and results interpreted.

Results: One hundred thirty-three clinicians (109 endocrinologists, 13 surgeons, and 11 thyroid specialists) returned the survey and up to 129 responded to the posed question. Ninety-eight percent (126/129) stated that they would repeat the FNAB with a pathologic diagnosis of "Unsatisfactory" and 96% (124/129) would opt for surgery with a "Suspicious" diagnosis. A diagnosis of "Indeterminate" would prompt 58% (69/120) to repeat the FNAB and 32% (38/120) to send the patient to surgery. A diagnosis of "Atypical" would lead 37% (42/110) to repeat the FNAB and 52% (57/110) to send the patient to surgery. Chi square analysis revealed no correlation between the different clinical sub-specialties and choice of treatment for any given pathologic diagnosis ($p > 0.05$).

Conclusions: While the majority of clinicians surveyed would correctly interpret and treat pathologic diagnoses of "Suspicious" or "Unsatisfactory", confusion arises with "Indeterminate" or "Atypical". A possible reason for misinterpretation of the category "Indeterminate" is that it is construed as an "Inadequate" specimen so the patient is sent for repeat FNAB instead of surgery. The term "Atypical", on the other hand, is most likely too ambiguous and needs either further clarification or to be excluded from current terminology. Until these issues are resolved, the use of a microscopic description is essential to clarify the thyroid FNAB cytology results so the clinicians may optimize their treatment options.

308 Inadvertent Parathyroid Gland Sampling on Fine-Needle Aspiration of Presumptive Thyroid Nodules: A Potential Diagnostic Pitfall

N Rekhtman, SZ Ali. The Johns Hopkins Hospital, Baltimore, MD.

Background: Due to their close anatomic relationship, accidental sampling of parathyroid (PT) gland can rarely occur during thyroid fine-needle aspiration (FNA) and may present potential diagnostic confusion by simulating primary thyroid neoplasm.

Design: The cytopathology database of a large academic institution was analyzed for a 16-yr period (1989-2005) for thyroid FNAs in which PT tissue was identified. The clinical data, cytologic diagnoses and histopathologic follow-up were reviewed and correlated.

Results: Of the 6907 thyroid FNAs performed, only 24 cases (0.3%) had cells either diagnostic of or suspicious for PT epithelium. The mean age of the patients was 45.8 yrs (age range 26-72 yrs) with a M/F ratio of 1 to 3. Definitive diagnosis of parathyroid epithelium was rendered in 11/24 (46%) cases, often aided by detection of parathyroid hormone (PTH), either by immunohistochemistry or by chemical analysis of the rinse fluid. In all but one of these cases, the FNA diagnosis was confirmed by subsequent surgical resection as enlarged parathyroid gland (n=9) or parathyroid carcinoma (n=1); one patient had no surgical follow-up but was found to have elevated serum PTH. Three of twenty-four (12%) cases were diagnosed as "suggestive of parathyroid cyst" and in only one case, the diagnosis was confirmed on surgical resection. In 9/24 (37%) cases, "indeterminate" diagnoses were rendered: "suspicious of parathyroid epithelium" (n=6, 25%) or "follicular thyroid neoplasm" (n=3, 12%). Surgical follow-up confirmed an enlarged parathyroid gland in four of these cases and elevated serum PTH was found in two additional cases. Clinical follow-up was not known in the three remaining patients. Finally, 1/24 (4%) cases, aspirated PT cells were misdiagnosed as papillary thyroid carcinoma. Hyperplastic PT gland containing a needle track was identified on subsequent thyroidectomy. Cytologic features that led to the misdiagnosis were: hypercellularity with papillary fragments, enlarged nuclei and intranuclear inclusions, characteristics highly unusual for PT cells.

Conclusions: Inadvertent aspiration of parathyroid tissue is rare and occurred in 1 of 300 FNAs of presumed thyroid nodules at our institution. In the majority of cases (58%), a correct diagnosis of PT tissue was rendered on cytologic interpretation. Indeterminate (37%) or, rarely, false positive diagnosis of a thyroid neoplasm (4%) can occur, often due to unusual morphology or unsuspected presence of PT tissue.

309 Clinical Significance of Cytologic Diagnosis of Atypical Squamous Cells Cannot Exclude High Grade in Perimenopausal and Postmenopausal Women

RS Saad, DJ Dabbs, L Kordlunsky, JF Silverman, YL Liu, A Kanbour-Shakir, A Kanbour. Allegheny General Hospital; Magee-Womens Hospital at UPMC, Pittsburgh, PA.

Background: Atypical Squamous Cells- Cannot Exclude High - Grade Squamous Intraepithelial Lesions (ASC-H) is a new category established by Bethesda System 2001. Recent studies has shown that the cytologic diagnosis of ASC-H in Pap smears is usually associated with high grade dysplasia in cervical biopsies in up to 60% of the cases. Previously, studies have reported that squamous atypia (ASC-US) in postmenopausal women is rarely associated with either biopsy-proven dysplasia or HPV DNA detection, in contrast to younger women. However, there is a limited available data addressing the significance of ASC-H in postmenopausal women. The goal of this study was to determine the clinical significance of ASC- H in perimenopausal and postmenopausal women, using cytohistologic correlation.

Design: A computer search identified 250 Pap smears from women older than 45 years with a diagnosis of ASC- H, in two tertiary academic medical centers between January 2003 and December 2004. Cases were divided into two categories: perimenopausal

(ages 45-55, 150 cases) and postmenopausal (older than 55 years, 100 cases). All Pap. smears were prepared using thin-preparation liquid-based technique. Slides and follow-up diagnoses were reviewed by two cytopathologists.

Results: No follow-up data was available in 32 cases and were excluded from the study. The remaining 217 ASC-H cases had surgical or cytologic follow-up within 6 months, consisting of 127 in perimenopausal (45-<55) and 90 in postmenopausal (≥ 55 -) women. Follow-up colposcopic biopsy was available in 174/217 (79%), and cytology follow-up was available in 43/217 (21%).

Results of ASC-H follow-up in peri- and postmenopausal women

	Cases	Negative	Follow-up (Biopsy and cytology)		
			CIN-1	CIN-2	CIN-3
Perimenopausal	127	50/127 (40%)	46/127 (36%)	21/127 (16%)	10/127 (8%)
Postmenopausal	90	46/90 (51%)	39/90 (44%)	4/90 (4%)	1/90 (1%)

Conclusions: In our studied population, only 5% of postmenopausal women who underwent biopsy or cytology follow-up with a diagnosis of ASC-H had high grade cervical intraepithelial lesion. In contrast to younger women, the diagnosis of ASC-H in postmenopausal women is usually associated with histological diagnosis of negative or low grade diagnosis on follow-up. These results suggest a less aggressive surveillance and treatment for postmenopausal women diagnosed as ASC-H in their Pap. smears.

310 Cytomorphologic Features of the Follicular Variant of Papillary Thyroid Carcinoma: A Comparison with Benign Follicular Lesions of the Thyroid in Fine-Needle Aspiration Specimens

F Salem, RJ Cabay, M Guo. University of Illinois at Chicago, Chicago, IL.

Background: The cytologic diagnosis of papillary thyroid carcinoma (PTC) is based on the presence of malignant cells in a papillary arrangement with nuclei displaying enlargement, grooves, inclusions, and fine chromatin. However, the follicular variant of papillary thyroid carcinoma (FVPTC) often creates a diagnostic dilemma in fine-needle aspiration (FNA) due to its frequent lack of discernable papillary architecture and variable presence of nuclear features. Often, FVPTC is difficult to distinguish from benign follicular lesions (BFL) in FNA specimens.

Design: A retrospective study was performed on 16 cases of histologically-proven FVPTC and 10 cases of BFL (8 follicular neoplasms and 2 hyperplastic goiters) obtained from 1999 to 2005. FNA specimens were evaluated using the following criteria: architecture (follicles, papillae, syncytial arrangement, and monolayered sheets), nuclear features (size, shape, grooves, inclusions, nucleoli, and chromatin), and background (colloid, cellularity, squamous metaplasia, and giant cells). The results were analyzed to determine which features were most helpful in distinguishing between FVPTC and BFL.

Results: On the original cytologic diagnosis of the FVPTCs, 6 cases were diagnosed as suspicious for PTC, 2 as thyroid carcinoma, 1 as FVPTC, and 7 as follicular lesions (suspicious for follicular neoplasm or cellular nodule). Of the FVPTCs, cellularity varied from moderate-to-high (7/16) to low (9/16). Follicular pattern (13/16) and syncytial arrangement (15/16) were the most common architectural patterns. Papillae (2/16) and monolayered sheets (4/16) were also seen. Dense colloid was frequent. Squamous metaplasia and giant cells were uncommon. Oval nuclei were detected in 10/16 FVPTCs (62%) and in 2/10 BFL ($P \leq 0.05$). Nuclear grooves were found in 10/16 FVPTCs (62%) and in 2/10 BFL ($P \leq 0.05$). A few nuclear inclusions were noted in 9/16 FVPTCs (56%) and in none of the BFL ($P \leq 0.01$). Nuclear enlargement (13/16) and fine chromatin (10/16) were more common in FVPTCs than in BFL but were not statistically significant.

Conclusions: Nuclear inclusions, nuclear grooves, and oval nuclei are significant features that favor a diagnosis of FVPTC over BFL in FNA specimens. In the absence of nuclear inclusions and grooves, a differential diagnosis of FVPTC should be considered if smears show syncytial arrangement and follicular pattern along with nuclear enlargement, fine chromatin, and oval nuclei.

311 Clinicoradiologic and Cytopathologic Analysis of 'Pleural-Based' Masses of the Lung

F Samad, SZ Ali. The Johns Hopkins Hospital, Baltimore, MD.

Background: 'Pleural-based' masses (PBM) present an interesting spectrum of pathologic entities on fine needle aspiration (FNA). This study analyzed the diagnostic utility of FNA in evaluation of such lesions in light of relevant clinicoradiologic correlation.

Design: On retrospective review, 60 consecutive cases of PBMs were retrieved from the cytopathology files of a large tertiary care center between 1994 and 2005 (11 yrs). The clinical, radiologic and cytopathologic data along with follow-up information was analyzed and correlated.

Results: Mean age of the patient cohort was 55.8 yrs (range 4-82 yrs) with a M/F ratio of 3:2. The chief clinical presentations were pain, dyspnea, cough and weight loss. All FNAs employed a transthoracic approach [ultrasound guided-11 (18%), CT guided-49 (82%).] Of the 60 cases, 5 (8%) were bilateral while the remaining 55 (92%) cases were unilateral lesions. Of the unilateral, 35 (64%) were right sided, while 20 (36%) were localized to the left lung. Of the 60 cases analyzed, FNA was diagnostic in 55 (92%). Of the diagnostic FNAs, 38 (69%) were neoplastic, 13(24%) were non-neoplastic and 4 (7%) were deemed atypical/suspicious. All neoplasms were malignant. Of these, 21 (55%) were primary cancers and 17 (45%) were metastatic/secondary tumors. Primary neoplasms included mesothelioma (6), adenocarcinoma (5), non-small cell carcinoma (3), carcinoma NOS (3), squamous cell carcinoma (2), carcinoid (1) and small cell carcinoma (1). Metastatic (secondary) neoplasms included lymphoma/leukemia (5), adenocarcinoma (5), squamous cell carcinoma (2), non small cell carcinoma (2), metastatic renal cell carcinoma (2) and thymoma (1). Primary site for metastatic tumors included breast (4), ovary (1) kidney (2), and tonsils (1), while in the remainder, the primary sites were unknown (5). Non-neoplastic entities included infections (2)-aspergillus and pneumocystis; sarcoidosis (2) and miscellaneous lesions (9). There was only one false-negative cancer case identified.

Conclusions: FNA of PBM is a highly useful modality with a specificity of 100% and sensitivity of 98% for cancer diagnosis. The most common lesion encountered is a malignant tumor with mesothelioma being the most common primary neoplasm, lymphoma/leukemia being the most prevalent secondary neoplasm and adenocarcinoma as the most common metastatic entity. Non-neoplastic lesions were uncommon with infection being the least common cause of PBM. FNA is an established safe procedure for PBMs as no case was associated with serious pneumothorax in our series.

312 Atypical Glandular Cells (AGC) on ThinPrep Imaging System (TIS) Versus Manual Screening (MS): Correlation with Hybrid Capture 2 (HC2) HPV DNA Testing

A Saqi, M Erroll, A Babiac, M Mansukhani, MF Vazquez. New-York Presbyterian Hospital, Weill Cornell Medical Center, New York, NY; New-York Presbyterian Hospital, Columbia Presbyterian Medical Center, New York, NY.

Background: The TIS is a computer-assisted primary imaging screening system which, utilizing the ThinPrep Stain, detects 'abnormal' cells based on quantitative measurements of nuclear DNA content. Relative to MS, multi-site trials using TIS demonstrated improved sensitivity for atypical squamous cells of undetermined significance (ASCUS) and increased specificity for high-grade squamous intraepithelial lesions (HSIL). The aims of our study were to evaluate the performance of TIS and MS in detecting AGC and correlate the results with HC2 HPV DNA testing.

Design: Records of cervical/endocervical ThinPreps with diagnoses of AGC not otherwise specified/favor endocervical origin were searched. Cases with cytological and/or surgical follow-up and HC2 HPV DNA testing were selected for the study. The cases were divided into the following categories: ASCUS, low-grade intraepithelial lesion (LSIL), HSIL, adenocarcinoma in situ (AIS), microglandular hyperplasia (MGH), endometrial polyp (EMP), endocervical polyp (ECP), malignant-other (MAL) and negative (NEG). ASCUS, LSIL, HSIL and AIS were considered clinically significant HPV-related lesions.

Results: One hundred fifty-two (TIS = 113; MS = 39) ThinPreps with AGC were retrieved. Follow-up data and HC2 DNA testing were available for 109 cases (TIS = 80; MS = 29), which form the basis for this study. Of the 80 TIS cases, 39 (48.8%) were high-risk HPV+ and 41 (51.2%) were HPV-. Of the 29 MS cases, 7 (24.1%) were HPV+ (6 high-risk and 1 low-risk) and 22 (75.1%) were HPV-.

Conclusions: Our study illustrates that TIS and HC2 HPV DNA testing are more likely to detect clinically significant lesions than MS alone. The positive predictive values for detecting HPV-related cervical/endocervical lesions diagnosed as AGC are 41.3% (TIS) and 17.2% (MS) using cytological and/or surgical follow-up as the gold standard and 48.8% (TIS) and 24.1% (MS) employing HC2 HPV DNA test results as the gold standard. Second, most AGC are associated with HSIL rather than AIS.

Results of HPV DNA Testing with TIS and MS

	ASCUS	LSIL	HSIL	AIS	MGH/EMP/ECP	MAL	TOTAL
HPV+/TIS	3	6	22*	1	1	0	39
HPV-/TIS	-	-	1	-	12	2**	41
HPV+/MS	-	-	5	-	-	-	7
HPV-/MS	-	-	-	-	4	4***	22

* = 1 case had concurrent HSIL and endometrial carcinoma; ** = 2 endometrial carcinomas; *** = 1 endometrial carcinoma, 1 lymphoma and 2 Paget's; - = N/A

313 Degree of Atypia in Pancreatic Cytology Correlates with KRAS Mutation and Loss of Heterozygosity in Tumor Suppressor Genes

KE Schoedel, D Caglar, NP Otori, JL Hunt. University of Pittsburgh Medical Center, Pittsburgh, PA.

Background: Preoperative assessment of pancreatic lesions by endoscopic ultrasound guided fine needle aspiration (EUSFNA) has improved patient management. Morphologic cytologic diagnosis is augmented by molecular analysis of known genetic abnormalities associated with tumorigenesis in pancreatic neoplasia. These include KRAS mutations and loss of heterozygosity (LOH) of loci associated with tumor suppressor genes. In this study, we correlate cytologic diagnosis with the presence of KRAS mutation and LOH at selected genetic loci.

Design: Forty-four cytology samples in patients with clinically suspected pancreatic disease were collected for the year 2005, predominantly collected with EUSFNA samples of the pancreas (39/44). A cytologic diagnosis was rendered in each case and sequencing was performed for KRAS. Additionally, LOH analysis was performed for a panel of genetic loci including 15 primer sets for 5q, 6q, 9p, 10q, 12q, 17p, and 18q.

Results: Of 44 cytology cases, 17 were considered negative for malignancy or non-diagnostic. 21 cases were indeterminate (atypical or suspicious) and 6 cases were positive for neoplasm or malignancy. Results are summarized in the table below:

Cyto Dx	# of Cases	KRAS AND LOH IN PANCREATIC CYTOLOGY SAMPLES			
		Pos KRAS	Pos LOH	KRAS+LOH	FAL>15%
Neg/Non-dx	17	1 (6%)	5 (29%)	1 (6%)	0
Atyp/Susp	21	5 (24%)	13 (62%)	3 (14%)	6 (29%)
Pos	6	1 (16%)	5 (83%)	1 (16%)	3 (50%)

Conclusions: Loss of heterozygosity correlates with increasing degree of atypia in the pancreatic cytology samples. A fractional allelic loss > 15% was associated with atypical, suspicious and positive diagnoses and its presence is also correlated with increasing degree of atypia.

314 Correlation of Cytology, Fluorescence In Situ Hybridization (FISH), and Digital Image Analysis (DIA) in the Urine of Renal Transplant Patients (RTP) Infected with BK Polyoma Virus (BKV): Is There a Relationship between Patient Age, Decoy Cell Titer and FISH Abnormalities?

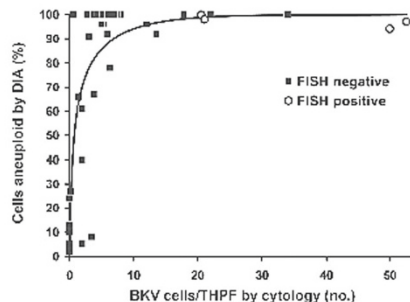
TJ Sebo, BJ Kipp, MD Griffin, JM Ihrke, ME Fealey, KC Halling. Mayo Clinic, Rochester, MN.

Background: BKV is a double stranded DNA virus. RTP are susceptible to reactivation of latent BKV infections and allograft rejection. BKV infected renal tubular cells, decoy

cells, can mimic urothelial carcinoma in urine cytology. These cells have been shown to be aneuploid in previous studies with DIA. The goals of this study were to determine if decoy cells cause FISH abnormalities in BKV infected urine samples; and, if so, categorize the clinical and cytologic findings in these cases.

Design: Thirty-eight urine samples from RTP were collected as part of the workup for renal function and split 3 ways. Decoy cells were quantified by cytology as the number of BKV infected cells per ten high power fields (THPF) using a 40x lens. For FISH, the UroVysion™ probe set consisted of chromosome enumeration probes (CEP) 3, 7, 17, and locus specific identifier (LSI) probe 9p21 (P16 gene). For DIA, cells were acid-hydrolyzed, stained with the Feulgen dye, and evaluated with a CAS 200.

Results: Thirty-two of 38 patients (84.2%) had BKV infection by cytology. The mean number of BKV cells per THPF was 10.7 (range 0.2 – 52.5; median 5.8). DIA and FISH were aneuploid/aneusomic in 30 (94%) and 4 (12.5%) cases, respectively. The 4 FISH positive cases included homozygous 9p21 deletion (2), polysomy (1), and trisomy 7 (1). All FISH positive patients were male, ≥52 years of age, and had BKV urine titers of at least 20/THPF (mean 36; range 20.5 – 52.5). Two samples were DIA diploid with BKV titers of 2/THPF. The 6 specimens without decoy cells were DNA diploid/disomic by DIA and FISH. FISH positive RTP had greater numbers of BKPV urine titers than FISH negative RTP (p=0.002);



No FISH positive RTP has evidence of urinary track malignancy.

Conclusions: Viral infection of renal tubular cells invariably leads to abnormal nuclear DNA content by DIA. On occasion, FISH abnormalities can be detected in RTP who are older males with high titers of urinary decoy cells. These may be spurious findings.

315 Quantitative Nuclear Grade Scores by Image Analysis (IANS) of Cells Collected from Biliary Tree Strictures Assists Routine Cytology in the Diagnosis of Adenocarcinoma (Adca) and Are Associated with Severity of Fluorescence In Situ Hybridization (FISH) Abnormalities

TJ Sebo, EG Barr-Fritcher, BJ Kipp, KC Halling. Mayo Clinic, Rochester, MN.

Background: We compare IA nuclear scores (IANS) and FISH signal patterns from concurrent biliary tract brushings to determine if there are differences in IANS based upon degree of FISH abnormality. We also assessed the role of IANS in increasing the detection rate of adca in biliary strictures.

Design: Cytology, FISH, and IA were performed on 141 biliary tract specimens (82 males, 59 females) with a mean patient age of 57.5 years (range, 9-87). Cytology was classified as negative, atypical/suspicious, or positive. DNA ploidy and morphometry were determined using a CAS 200. Univariate analysis using the Bonferroni correction method identified 13 (of 32) nuclear features that best differentiate malignant from non-malignant specimens (significance based on p<0.05/ 32 < 0.0016). An IANS was calculated for each specimen using the nuclear morphometric features significant to p<0.0016. Values were generated against patients without evidence of disease (reference group with IANS expressed as the number of standard deviations set at 0.0). FISH was conducted on each specimen using the Vysis™ UroVysion© probe set and results were categorized as negative, trisomy 7, or polysomy.

Results: Fifty-nine of 141 patients had clinicopathologic evidence of cancer on follow-up. There were differences (p<0.001) between the IANS of specimens from patients with and without cancer (mean, 4.43 vs. 0.00, respectively). All patients with IANS >4.82 (30.5%) had cancer on follow-up. Of these patients, cytology results were negative in 5 (27.8%), atypical/ suspicious in 6 (33.3%) and positive in 7 (38.9%). 11 (18.6%) more patients were captured as positive for adca using this method. Significant differences (p<0.001) were found between IANS of specimens called negative (mean, 0.58), atypical/ suspicious (mean, 3.94) and positive (mean, 8.49) by cytology. IANS increased as FISH abnormalities increased from disomy to trisomy 7 to polysomy (Table 1).

Conclusions: The data from this study suggests that there were significant differences in IANS based on FISH signal pattern. Furthermore, IANS captures roughly 20% more patients with biliary track adca than routine cytology.

Comparison of IANS by FISH Signal Pattern (p<0.001)

FISH Result	N	Minimum	Maximum	Mean	Median
Negative	95	-4.36	6.81	0.191	0.240
Trisomy 7	19	-1.78	4.51	1.266	1.350
Polysomy	27	-1.69	16.39	6.649	6.360

316 One Sample, Three Diagnoses: Pap Test, DNA-HPV, DNA-Chlamydiae Trachomatis

HP Sevestre, F Daoudi-Hammad, G Le Loup. Centre Hospitalier et Universitaire, Amiens, France.

Background: Liquid based cytology has shown efficiency in the diagnosis of cervical cancer and precancerous lesions of the cervix. It proved useful in allowing to perform

Human Papilloma Virus (HPV) testing either in a "reflex" setting or in routine combination. The present study was undertaken to test the feasibility of routine diagnosis of Chlamydiae trachomatis (CT) infection by Polymerase Chain Reaction (PCR) on residual Preservcyt (Cytoc France, Roissy) material after completion of one Thinprep slide and Hybrid Capture 2 (Digene France, Paris).

Design: 200 women aged 18 to 26 years seeking contraceptive advice in a family planning clinic agreed to enroll, after having given informed consent, in the study. Cervical samples were collected using a cervix brush. An additional sample designed to CT testing was taken with a special brush, either before or after the former. Cytological diagnosis was performed after Thinprep technique (Cytoc France, Roissy) and the diagnosis rendered using the Bethesda 2001 system. Hybrid Capture 2 was then performed using the high risk cocktail probe from the residual material. Available residual material and sampler material were used to perform CT automated PCR (Amplicor, Cobas, Roche Diagnostics). This PCR system detects specific inhibitors when present.

Results: Low grade squamous intraepithelial lesion was observed in 19 women (10%). No ASC or high grade squamous lesion was recorded. No cytoplasmic vacuole suggestive of CT infection was observed, even in a second look directed by CT infection demonstration. HR-HPV testing was positive in 84 women (41%). CT infection was detected in 18 women (8.78%), more often from Preservcyt material than from sampler. PCR inhibitors were present in 22 samples (11%) in the Preservcyt medium and in five (4.5%) of samplers, preventing CT infection molecular diagnosis. Co-infection by HR-HPV and CT was documented in eight women.

Conclusions: CT infection diagnosis was feasible after Pap Test and HC2 HR-HPV in this series in all 200 women. A high proportion of women turned out to have a CT infection. Few studies have appeared on this subject, and have used different methods. In a study CT infection prevalence was 2.2% in 1000 young females, but the CT PCR allowed not to separate inhibitors from true negative cases. As co-infections may precipitate precancerous lesions, the group of co-infected patients has to be carefully followed.

317 GFAP and CD57 Immunolocalization in Cell Block Preparations Is a Useful Adjunct in the Diagnosis of Pleomorphic Adenoma

SS Shah, VS Chandan, DC Wilbur, KK Khurana. SUNY-Upstate Medical University, Syracuse, NY; Massachusetts General Hospital, Harvard Medical School, Boston, MA.

Background: The cytologic distinction between pleomorphic adenoma (PA) and adenoid cystic carcinoma (ACC) can be diagnostically challenging in aspirate smears since both share some common morphologic features. Hence a cytologic diagnosis of 'Atypical cytology' with differential diagnosis including PA and ACC is occasionally rendered in a subset of salivary gland FNAs. Glial Fibrillary Acidic Protein (GFAP) and CD57 (Leu-7) expression in PA is documented in surgical pathology literature. The aim of this retrospective study was to evaluate the expression of GFAP and CD57 expression in cell block material obtained during FNA of histologically proven cases of PA and ACC and to investigate if GFAP and CD57 staining is useful in rendering definitive diagnosis of PA in a subset of aforementioned salivary gland FNAs with cytologic diagnosis of 'Atypical cytology'.

Design: GFAP and CD57 immunostains were performed on formalin-fixed paraffin embedded cell block sections of 26 salivary gland FNA cases with the following cytologic diagnoses: (1) PA (10 cases); (2) atypical cytology, cannot exclude ACC (8 cases); and (3) ACC (8 cases). Histologic follow-up was available in all cases.

Results: All 10 (100%) cases with cytologic diagnoses of PA were positive for GFAP, and 8/10 (80%) cases were positive for CD57; tissue follow-up confirmed the diagnosis of PA in all 10 cases. All 8 (100%) cases with cytologic diagnosis of ACC were negative for both GFAP and CD57; tissue follow-up confirmed the diagnoses of ACC in all 8 cases. Of the 8 cases with diagnoses of atypical cytology, 4 (50%) were negative and 4 (50%) were positive for both GFAP and CD57. Subsequent tissue follow-up in these cases revealed 4 cases of ACC (all negative for GFAP and CD57) and 4 cases of PA (all positive for GFAP and CD57).

Conclusions: Our results show that GFAP and CD57 immunolocalization in cell block preparations serves as a useful adjunct in the diagnosis of PA and their immunoreactivity is consistently negative in cases of ACC. Positive staining for GFAP and CD57 confirms the diagnosis of PA and helps reduce the uncertainty in diagnosis in challenging cases.

318 Cytopathologic Grading of Oligodendrogliomas

CH Shum, PC Burger, SZ Ali. The Johns Hopkins Hospital, Baltimore, MD.

Background: The cytopathologic criteria for the diagnosis of oligodendrogliomas (OD) are well-established, but features distinguishing tumor grade are less well characterized.

Design: Selected cases of OD from a large tertiary care institution's cytopathology and surgical pathology archives in a 15-yr period (1990-2004) were reviewed retrospectively. Six fine needle aspirations (FNA) and 25 surgical pathology resections with associated smears were examined for cytologic features including, but not limited to, cellular necrosis, smear background, cellularity, mitoses/karyorrhexis, nuclear shape, nucleoli, chromatin pattern, tumor vascularity, and calcification. The following entities also were examined as part of the differential diagnosis using the same cytologic criteria; anaplastic astrocytoma (AA, n=8), glioblastoma multiforme (GBM, n=6), primitive neuroectodermal tumor (PNET, n=6), and primary non-Hodgkin lymphoma (NHL, n=4). Features were scored as present or absent.

Results: Mean age was 44 yrs (age range 20 to 70 yrs), with a M:F ratio of 1:1.4. Of the 31 OD, 15 (48%) were grade 2 and 16 (52%) were grade 3. Features that correlated with higher grade (grade 3) OD included; pleomorphism (16/16 grade 3 vs. 4/15 grade 2), prominent nucleoli (4/16 grade 3 vs. 0/15 grade 2), vascular proliferation (7/16 grade 3 vs. 0/15 grade 2), perivascular tumor cells (8/16 grade 3 vs. 1/15 grade 2), and plexiform vessels (5/16 grade 3 vs. 1/15 grade 2). Prominent nucleoli were seen also in astrocytomas (3/8), GBM (3/6), PNET (1/6), and NHL (3/4). Perivascular neoplastic

cells were observed in GBM (1/6). Plexiform vessels were not seen in the non-oligodendroglial entities examined. Necrosis (2/16 grade 3 vs. 1/15 grade 2), calcification (1/16 grade 3 vs. 0/15 grade 2), and mitosis (0/16 grade 3 vs. 0/15 grade 2) were similar between low grade and high grade lesions.

Conclusions: Features that help distinguish higher grade (i.e. grade 3) OD include pleomorphism, prominent nucleoli, vascular proliferation, perivascular neoplastic cells, and plexiform vessels. While none of these features was seen exclusively in grade 3 OD, taken together these features are helpful in the diagnosis of anaplasia.

319 The Morphologic Spectrum and Quantification of Urinary Decoy Cells in the Management of Patients with BK Polyomavirus Nephropathy (BKN): Correlation with Histological Stage and Inter- / Intra-Observer Variability

HK Singh, YJ Shen, V Madden, V Nickleit. The University of North Carolina, Chapel Hill, NC.

Background: The detection and quantification of decoy cells (DC) in urine cytology is important for proper risk assessment of renal transplant recipients for the development of BKN. Different DC phenotypes are recognized: Form 1 (classical amorphous variant) and Form 2 (irregular clumped variants).

Design: 1) Correlate different DC phenotypes with histological stages of BKN (A-early; B-florid) 2) Evaluate potential changes in shedding of different DC phenotypes over time. 3) Investigate inter-/intra-observer variability in DC quantification. 4) Study the ultrastructure of different DC phenotypes. 96 urines from 13 patients with biopsy proven BKN (histologic stages A and B at time of initial diagnosis) were retrospectively reviewed in Papanicolaou stained thin-prep® cytospins. Re-evaluation for total DC counts was done blinded by one cytopathologist for inter- / intra-observer variability. Fresh urines from selected patients were evaluated by electron microscopy.

Results: All urines showed high cellularity. **Table 1:** At time of initial biopsy diagnosis of BKN (stages A and B), all patients showed decoy cell shedding (>10/10hpf) with no significant differences in the total DC numbers. In both histologic stages A and B, form 1 DC shedding predominated. Over an 8 week observation period, a trend towards increased shedding of form 2 DC was noted. The inter-observer variability for quantifying total DC was moderate (0.636) while the intra-observer variability was very good (0.995). Ultrastructurally, form 1 DC showed evenly dispersed nuclear viral particles with peripherally displaced chromatin; form 2 showed crystalloid intra-nuclear virions variably interspersed with chromatin.

Conclusions: 1) It is important to recognize different decoy cell phenotypes for proper quantification and risk assessment of BKN. 2) DC phenotypes do not correlate with the histological stage of BKN (stages A and B). 3) Over time, shedding of form 2 DC increased underscoring the need for proper recognition of different DC phenotypes.

	RESULTS					
	Stage A (n = 9/13) Total DC mean (range)	Form 1 %	Form 2 %	Stage B (n = 4/13) Total DC mean (range)	Form 1 %	Form 2 %
One month prior to biopsy diagnosis of BKN	59 (16-161)	63%	37%	27 (0-52)	96%	4%
At initial biopsy diagnosis of BKN	82 (15-318)	80%	20%	38 (10-75)	92%	8%
One month after biopsy diagnosis of BKN	33 (0-133)	58%	42%	7 (0-14)	86%	14%

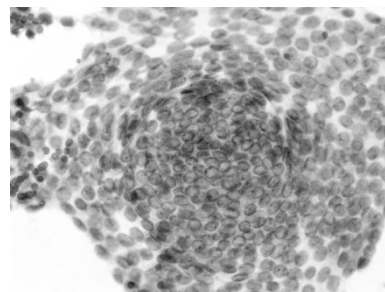
320 Cellular Swirls in Fine-Needle Aspirates of Papillary Thyroid Carcinoma: A New Diagnostic Criterion

AH Szporn, S Yuan, M Wu, DE Burstein. Mount Sinai School of Medicine, New York, NY.

Background: No one cytologic feature is specifically diagnostic for papillary thyroid carcinoma (PTC). The finding of several recognized criteria make the diagnosis of PTC more likely in any given case. We have observed the presence of cellular swirls in FNAs of PTC, but not in other entities. Cellular swirls are defined as concentric organizations of cells in which many of the most peripherally situated cells have ovoid nuclei whose long axes are perpendicular to the radius of the swirl. We propose that these structures be added to the list of diagnostic criteria for PTC.

Design: One hundred thyroid FNAs, Papanicolaou and/or Diff-Quik stained diagnosed as PTC, were reviewed for the presence of cellular swirls. An additional one hundred similarly stained FNAs of thyroid diagnosed as nodular goiter, Hashimoto's thyroiditis and follicular neoplasm were also reviewed for the presence of cellular swirls.

Results: Cellular swirls were easily observed at screening magnification and confirmed at high magnification.



They are readily distinguished from medium-sized follicles. Seventeen of one hundred (17%) FNAs of PTC contained cellular swirls. Nine (9%) contained structures similar

to, but not diagnostic for cellular swirls. No cases (0%) diagnosed as nodular goiter, Hashimoto's thyroiditis or follicular neoplasm contained these structures. Cases of PTC in which cellular swirls were observed were limited to relatively well-differentiated PTC or to areas of relatively well-differentiated PTC admixed with a less well-differentiated component.

Conclusions: Cellular swirls are a finding seen in a significant percentage of PTCs, but not in other thyroid lesions diagnosed by FNA. They are observed in association with well-differentiated PTCs and are easily seen at screening magnification. The presence of cellular swirls may be helpful in cases where classic criteria for PTC are scarce, particularly in well-differentiated tumors. Given the apparent specificity for PTC, we suggest that cellular swirls be added to the list of classic criteria for FNA diagnosis of PTC.

321 Cytologic Features of Medulloblastoma in Intraoperative Smear Preparations

H Takei, AM Adesina. Baylor College of Medicine; Texas Children's Hospital, Houston, TX.

Background: Medulloblastoma (MDB) is a malignant embryonal tumor of the cerebellum. According to the latest WHO classification of CNS tumors, 3 major histologic types have been described: classic, nodular, and large cell/ anaplastic (L/A). Of these, L/A type has been reported to be associated with worse prognosis than non-L/A (NLA) type. In intraoperative consultation (IOC), on frozen tissue sections, it is relatively easy to make a diagnosis of PNET/MDB and to exclude other tumors, however, to make a distinction between L/A and NLA types in MDBs is often difficult. Although the cytologic features of MDB have been previously described, there have been no reports studying the cytologic findings that differentiate between these 2 types.

Design: A total of 74 cases of MDBs diagnosed at Texas Children's Hospital from January 1987 to August 2005 were histologically reviewed and classified. Of these, 41 cases of a pure histologic type, which was defined as more than 80% of the tumor being composed of one of 3 major histologic types, with corresponding cytology slides made from either squash (SP, n=22) or touch (TP, n=19) preparation for IOC were identified. The smears were reviewed and graded semi-quantitatively (0 to 3+) for cellularity, nuclear streaming (Ns), rosette formation (Rf), nuclear cannibalism (NCa), apoptosis (Ap), macronucleoli (Mn), pleomorphism (Pl), mitoses (Mt), paranuclear inclusions (Pni), and intracytoplasmic vacuolation (Icv). The cytologic grades were compared statistically between the 2 histologic groups as well as between the preparation methods. $P < 0.05$ values were accepted as statistically significant.

Results: Hypercellularity (2+ in 24.5%, 3+ in 68.3%), occasional Rf (41.5% of cases), and prominent Ns (2+ in 24.5%, 3+ in 39%) were noted. These features did not show any significant difference between the histologic groups, nor did other uncommon findings including Pni (>2+ in 12.4%) and Icv (>2+ in 7.3%). Ap, NCa, Pl, Mn, and Mt were more significantly observed ($p=0.006, 0.006, 0.0006, 0.02, 0.04$, respectively) in L/A than in NLA types. NCa, Mn, and Pl were more significantly detected in TP than in SP, while Ns was more significantly seen in SP than in TP.

Conclusions: Intraoperative cytologic evaluation of the frequency of Ap, NCa, Pl, Mn, and Mt can allow a distinction between L/A from NLA types of MDB, which can be prognostically useful information during IOC. Rf, histologic hallmark of classic type, is not a discriminator. Given the fewer artifacts and sufficient cellularity, TP is the preferred method of cytologic preparation.

322 The Perception of Clinicians and Pathologists about Critical Values in Cytopathology

HD Tazelaar, TC Pereira, AC Clayton, YL Liu, ME Leon, JF Silverman. Mayo Clinic, Rochester, MN; Allegheny General Hospital, Pittsburgh, PA.

Background: The concept of critical values (CV) is well established in clinical pathology. The concept of CV in surgical pathology has only recently been suggested. Although some laboratories have CV policies, there are no established guidelines. Toward this end, we studied physician perceptions about possible cytopathology CV.

Design: We surveyed 13 pathologists and 13 clinicians at two large academic medical centers, and 9 senior cytopathologists from other tertiary centers. They were asked to grade 18 different possible CVs from 1 to 3 as follows: (1) No phone call necessary, (2) The clinician should be called within 24h; (3) A phone call should be made as soon as possible (ASAP). Participants could also list additional diagnoses (dx) they believed constituted a CV. Clinicians were also asked if calls from the pathologists disturbed their work flow and if there were situations in which they would prefer not to be called.

Results: In many situations e.g. new dx of malignancy (especially if unexpected or in critical places), microorganisms in the immunosuppressed, and disagreement between immediate and final FNA dx, most respondents agreed on the need for a phone call ASAP. For some dx (new metastasis with known primary, organisms in the immunocompetent), there was difference of opinion about the need for a phone call and degree of urgency. For two specific dx (polyoma virus in urine, and new HSIL), most participants thought a phone call unnecessary. Important additional CV suggested included: herpes in pap smear in a pregnant patient, AGUS, amended reports, very unusual tumors, disagreement on review of outside slides, and anticipated delay in dx (e.g. need for consult). Most of the clinicians (with one exception) appreciate calls from pathologists as very helpful, even if it occasionally disturbs workflow. Situations where they would rather not be called included review of outside slides if results will be rapidly available electronically, and deceased patients.

Conclusions: Timely communication between pathologists and clinicians is important. In this study we found good agreement about which situations require contact of clinician, and the degree of urgency, although there were some differences of opinion. Our findings suggest that a consensus conference of leaders in anatomic pathology and clinicians might prove useful to determine which cytology cases would constitute CV, and to propose guidelines.

323 Endometrial Cells on Papanicolaou Tests in Women 40 and over: Do Higher Numbers of Cell Clusters Correspond to a Higher Likelihood of Endometrial Hyperplasia or Adenocarcinoma on Follow-Up Biopsy?

MJ Thrall, K Savik, HE Gulbahce, S Pambuccian. University of Minnesota Medical Center, Fairview, Minneapolis, MN.

Background: The 2001 Bethesda system (2001 BS) mandates that all endometrial cells (EMC) seen in the Papanicolaou tests (PT) in women aged ≥ 40 be reported. A previous study, reviewing conventional PT diagnosed before the introduction of 2001 BS, has found that the presence of large numbers of EMC on PT is associated with endometrial hyperplasia (EMH) or adenocarcinoma (EMAC). We have tested the validity of this finding in liquid-based PT diagnosed according to the 2001 BS, to determine if including information about the number of EMC present may assist clinical decision-making.

Design: We retrieved the slides from 100 women with EMC reported on PT who had follow-up endometrial sampling within 0.5-6 months after a PT collected between 12/01/02 and 11/30/03. Each slide was re-examined and the total number of epithelial EMC clusters per slide was counted. The number of clusters varied from 1 to 2410, with a mean of 60 and a median of 7. We divided the results into 4 grades: Grade 1=1-5; Grade 2=6-25; Grade 3=26-100; Grade 4= ≥ 100 .

Results: We examined a total of 100 PT slides, including 3 with follow-up diagnosis of EMAC, 9 with follow-up diagnosis of EMH, and 88 random controls who had benign findings on follow-up. The results were as follows:

Follow-up Diagnosis	Grade 1	Grade 2	Grade 3	Grade 4
Benign	36 (41%)	25 (28%)	21 (24%)	6 (7%)
EMH	7 (78%)	1 (11%)	0 (0%)	1 (11%)
EMAC	0 (0%)	1 (33%)	0 (0%)	2 (67%)

Analysis with the Mann-Whitney U Test comparing the PT grades of benign vs EMH and EMAC showed no significant difference between the groups ($p=0.57$) when EMH and EMAC were aggregated. The two cases of EMH with atypia fell into Grade 1. Among all women with EMH on follow-up, 3 (33%) had only one EMC cluster present on the preceding PT slide.

Conclusions: While we found a trend towards more significant pathologic findings in women with more numerous EMC clusters in PT, the converse was not true. The presence of small numbers of EMC on a PT did not reduce the likelihood of finding EMH on surgical pathology follow-up. Therefore, in cases with small numbers of EMC clusters, including the number of EMC present in the PT report would not help clinicians to decide whether follow-up endometrial biopsy would be warranted. However, mentioning the presence of large numbers of EMC clusters may alert clinicians to an increased likelihood of EMAC or EMH.

324 Significance of Columnar Cell Hyperplasia (CCH) on FNA of Nonpalpable Breast Masses Detected by Ultrasound and Prepared by Thin Prep Alone

R Vidhum, L Qiu, M Vazquez. Weill Cornell Medical Center, New York, NY.

Background: Breast sonography and biopsy by FNA has aided in the diagnosis of benign and malignant nonpalpable lesions that are not detected by mammography. We have encountered CCH with increased frequency in these aspirates, frequently associated with papillary neoplasms (PN). The significance of CCH in ultrasound detected lesions and the accuracy of the diagnosis on ThinPrep alone is unknown.

Design: To determine the incidence, significance and accuracy of a diagnosis of CCH on ultrasound guided breast FNA, we evaluated 685 consecutive aspirates submitted entirely in Cytolyt by one radiologist, expert in breast imaging, for interpretation by one pathologist, expert in breast cytology. Benign aspirates were followed by ultrasound and mammography at six month intervals for up to 5 years. Excision or core biopsy was performed when the cytology was atypical, malignant or suspicious for PN. A diagnosis of PN with CCH was made when vascular cores were identified on Pap stained ThinPrep or by positive immunostaining with CD34.

Results: There were 48 (7%) cases with prominent CCH of which 40 (83%) had histologic follow-up. Eight cases (17%) followed by imaging alone were stable over 6 months to 5 years. Of the 40 cases with histology, 31 (77%) were benign; 11 (35%) showed fibrocystic changes (FCC) with CCH, 3 (9%) FCC without CCH, 8 (26%) were papillomas and 9 (30%) were fibroadenomas. There were 9 (23%) malignant cases; 4 (44%) papillary carcinomas, 4 (44%) ductal carcinomas, NOS and 1(11%) tubular carcinoma. There were 8 papillomas, 5 confirmed by staining with CD34 (Figures 1 and 2).

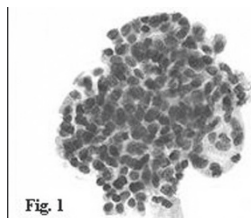


Fig. 1

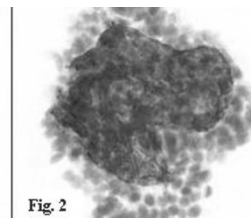


Fig. 2

Conclusions: The incidence of CCH on ultrasound detected breast FNA in this series was 7%. Most lesions are benign and do not require excision. PN with CCH can be accurately identified by Thinprep alone and is aided by immunostaining with CD34.

325 The Utility of Fluorescence In Situ Hybridization (FISH) for the Detection of Neoplastic Cells in Cervical Cytology Specimens

JS Voss, BR Kipp, AC Clayton, MB Campion, IA Sokolova, AX Algeciras-Schminck, LE Morrison, KC Halling. Mayo Clinic, Rochester, MN; Abbott Molecular Inc, Des Plaines, IL.

Background: Recent studies have shown that fluorescence in situ hybridization (FISH) may be useful for detecting both human papilloma virus (HPV) and chromosomal changes in gynecologic cytology specimens. The ability to determine whether patients with detectable HPV infections have concurrent chromosomal abnormalities may assist clinicians in determining proper patient follow-up. In this study, we assess the utility of a multi-probe FISH assay to detect HPV and cervical neoplasia in cytologic specimens to better understand the potential role of FISH in the clinical laboratory.

Design: Seventy-one cervical cytology specimens with same day biopsies results were included in this study. The biopsy results for these specimens were negative (N=22), cervical intraepithelial neoplasia (CIN) 1 (N=37), CIN 2 (N=8), and CIN 3 (N=4). FISH specimens were processed using a Cytoc Thinprep® 2000 processor and hybridized with a cervical probe set consisting of a high-risk HPV probe cocktail and probes to chromosomal loci 8q24 and 3q26. The finding of one or more cells with HPV "staining" was considered evidence of HPV infection (HPV+). The finding of two or more cells with gains of 8q24 and/or 3q26 was considered positive by FISH (CHROM+).

Results:

Biopsy Diagnosis	HPV-/CHROM-	FISH Result		HPV+/CHROM+
		HPV+/CHROM-	HPV-/CHROM+	
Negative	8	1	6	7
CIN 1	2	11	1	23
CIN 2	0	1	0	7
CIN 3	0	0	1	3

Eighty-three percent of the cervical cytology specimens from patients with biopsies showing CIN 2 or 3 and 62% of the cervical cytology specimens from patients with biopsies showing CIN 1 exhibited HPV infection and chromosomal abnormalities by FISH. Interestingly, 7 of the 22 patients with negative biopsies exhibited HPV infection and chromosomal abnormalities by FISH. All seven patient were found to have dysplasia (LSIL (N=4); HSIL, (N=2)), or atypical squamous cells of undetermined significance (ASCUS) (N=1) in the cervical cytology specimens obtained the same day as the biopsy suggesting possible tissue sample failure.

Conclusions: The data from this study suggest that FISH may be able to detect both HPV and chromosomal abnormalities which may assist clinicians in selecting proper clinical follow-up. However, further studies are needed to evaluate whether this assay would be beneficial for the management of patients with an ASCUS or LSIL cytologic diagnosis.

326 DNA Methylation Profiling Distinguishes Low Grade Papillary Urothelial Carcinoma from Reactive Urothelia in Urine

L Wang, D Weber, D Deeds, C Biscotti, B Yang. Cleveland Clinic Foundation, Cleveland, OH.

Background: Bladder urothelial carcinoma is one of the most common urinary tract malignancies. Although high grade flat urothelial carcinoma can be readily detected in urine cytologically, diagnosis of low grade papillary urothelial carcinoma (LGTCC) in urine is challenging due to overlapping morphologic features between LGTCC and benign reactive processes. Recent studies indicate that epigenetic alterations of some tumor suppressor genes (TSG) occurred in LGTCC. To examine if DNA methylation profilings can be used in distinguishing LGTCC from reactive urothelia, we have studied the promoter methylation profiles of 14 tumor suppressor genes (TSG) in 25 urine cytologic samples.

Design: Twenty-five urine samples (11 instrumented and 14 void) includes 13 normal/reactive urothelia and 12 LGTCCs which were confirmed surgically. Reactive urothelia consist of chronic inflammation (5), BKV infection (3), stone (3) and prostate disease (2). Genomic DNA from urine was extracted using Gentra system's Puregene kit and chemically converted by bisulfite treatment. Promoter methylation of 14 candidate TSGs (*APC*, *RAR-beta*, *p14*, *p15*, *p16*, *p73*, *RASSF1a*, *hMLH1*, *DAPK*, *MGMT*, *BRCA1*, *SOCS1*, *GSTP* and *FHIT*) was analyzed by methylation-specific PCR.

Results: In review of cytologic and histologic correlation, all LGTCCs were cytologically diagnosed as either "negative" or "atypical urothelial cells". In reactive category, five cases were cytologically diagnosed as "atypical" and one was misdiagnosed as "highly suspicious for TCC" due to BKV infection. Methylation study showed that reactive urothelium had either no methylation (8/13) or single gene promoter methylation (5/13). In contrast, all LGTCCs had at least two TSG promoters methylated. Methylation of three and more genes was found in 92% (11/12) LGTCC cases, whereas methylation of four and more genes was observed in approximately 67% (8/12) LGTCC cases. The most frequently methylated TSGs were: *DAPK* (75%), *RAR-beta* (59%), *p14* (59%), *p73* (50%) and *MGMT* (50%). No methylation of TSGs was seen in all 3 BKV infection cases.

Conclusions: Our study indicates that concurrent methylation of multiple TSG promoters is a hallmark for urothelial carcinoma, even at the early stage. DNA methylation profiling of a panel of TSGs distinguishes LGTCC from benign urothelia. As diagnosis of LGTCC is notoriously challenging cytomorphologically, our study suggests that DNA methylation profiles in urine can be a useful molecular tool in facilitating early and accurate detection of LGTCC.

327 EGFR Expression as an Ancillary Tool for Detecting Lung Cancer in Cytology Specimens

EX Wei, S Martin, EA Turbat-Herrera, ML Nordberg. Louisiana State University Health Sciences Center, Shreveport, LA.

Background: Lung cancer evolves in a multi-step process, and its early detection portends a better prognosis. Bronchial washing/brushing and fine needle aspiration are often used as early screenings and cytological diagnosis of lung cancer. Sometimes,

it is difficult to differentiate morphologically malignant from reactive cells. Epidermal Growth Factor Receptor (EGFR) is a transmembrane receptor overexpressed in a high percentage of lung carcinomas, and contributes to tumor growth. Assessing EGFR expression levels by fluorescence in situ hybridization (FISH) and immunohistochemistry (IHC) may provide critical information of tumor marker abnormalities, assist the cytological diagnosis, and stratify patients for EGFR inhibitor therapy.

Design: Fifty five patients with bronchial washing/brushing or fine needle aspiration specimens, and corresponding histologically confirmed lung biopsies, if available, were studied for EGFR expression with FISH and IHC. FISH analyses were performed using an EGFR locus specific probe for the EGFR locus on chromosome 7 at 7p12 (LSI® EGFR SpectrumOrange™/CEP® 7 SpectrumGreen™). Copy numbers of the EGFR gene locus were studied. EGFR FISH results were compared with our previous FISH data with combined EGFR, c-myc, 5p15.2 and chromosome 6 probes. Cell blocks, if available, and tissue biopsy sections were used for EGFR IHC (EGFR pharmDx™, Dakocytomation). Quantitation of EGFR expression was initiated using an automated cellular imaging system (ACIS, Chromavision, Inc.).

Results: Mainly aneuploidy of EGFR was identified by FISH. Gene amplification was occasionally detected. The chromosomal abnormalities of EGFR were often accompanied by other chromosomal aneuploidies demonstrated in c-myc (8q24), 5p15.2 or 6p, indicating a general genomic instability. EGFR tended to show aneuploidy in those confirmed specimens with malignancy, correlated well with high protein expression by IHC. Atypical and suspicious cases by cytology had 60% positivity confirmed for malignancy by biopsy. These atypical cases by cytology but negative by biopsy had a much lower percentage of aneuploidy by FISH.

Conclusions: EGFR is overexpressed in a high percentage of lung carcinomas by aneuploidy and occasionally by gene amplification. It is often accompanied with other chromosomal abnormalities. FISH and IHC analysis of EGFR, possibly in conjunction with other tumor markers, may be a useful ancillary tool to classify difficult cytology cases and inform clinicians arranging targeted chemotherapy.

328 Fine Needle Aspiration Cell Block and Excisional Specimen Correlation in Breast Carcinoma: Retrospective Review of Estrogen and Progesterone Receptor Expression as Determined by Immunohistochemistry

AI Wijayanayagam, LJ Esserman, BM Ljung, RL Baehner. University of California, San Francisco, San Francisco, CA.

Background: Fine needle aspiration biopsy (FNAB) is a highly accurate diagnostic method for detecting breast carcinoma. FNAB in experienced hands has a higher sensitivity in detecting malignant breast neoplasms (97.5% vs 90%) than palpation guided core needle biopsy (Ballo M, Cancer 1996). Performance of immunohistochemistry (IHC) for estrogen and progesterone receptors (ER/PR) on formalin fixed, paraffin embedded (FPET) cell block materials has been reported to have a high concordance with excisional specimens. Here we report the concordance between FNAB cell block and excisional specimens from breast carcinomas over a seven year period.

Design: The UCSF pathology database from 1997 to 2004 was searched for breast aspirates rendering a diagnosis of *adenocarcinoma* (AC) or *atypical* and the concomitant presence of cell block material. 244 cases were found. 215 had a FNAB diagnosis of AC and 29 a diagnosis of atypical. A 71 specimen subset had ER/PR on FNAB and excisional biopsy.

Results: Of the 244 FNAB cases, 215 had a diagnosis of AC and 29 a diagnosis of atypical. Of the 71 specimen subset with ER/PR on both FNAB and excisional specimens, 59 showed ER/PR concordance. 12 FNAB (17%) were false negatives with discordance of either ER (6 cases; 9%), PR (3 cases; 4%) or both (3 cases; 4%). However, 6 of the 9 FNAB cell block specimens were noted at diagnosis to have insufficient materials for accurate ER/PR determination by IHC and follow-up core biopsies for repeat evaluation of the ER/PR status were recommended. Thus, there were only 3 ER false negative cases (4%) by FNAB.

Conclusions: FNAB cell block materials from breast adenocarcinomas are useful for determining ER/PR status by IHC. The false negative rate is low and similar to that noted on core needle biopsy specimens. A fine needle aspiration ER or PR negative result requires ER/PR retesting on the excisional specimen.

329 Assessment of Tumor Response to Histone Deacetylase Enzyme Inhibitors In Vivo by Utilizing Fine Needle Aspiration Technique

C Xu, H Mezzadra, R Pili, S Altiook. The Johns Hopkins Hospital, Baltimore, MD.

Background: Histone deacetylase enzymes (HDACs) catalyze the removal of an acetyl group from the lysine residues of proteins and play an important role in the regulation of gene expression. Dysregulation of HDAC activity has been implicated in malignant transformation. In recent years, an increasing number of structurally diverse HDAC inhibitors have been identified that block proliferation and induce differentiation and/or apoptosis of tumor cells in culture and in animal models. Although several of HDAC inhibitors have now entered phase I clinical trials, thus far, no pharmacodynamic tests are available to determine what type of HDAC inhibitor, doses and schedules should be utilized in clinical trials to achieve optimal therapy effect.

Design: Mouse xenografts bearing renal cell carcinoma were treated with a HDAC inhibitor LAQ824 for four days. Tumor FNA samples were collected from each animal before and at the end of the therapy. Whole cell lysates were prepared, protein samples were quantified and the expression levels as well as acetylation status of histone H3 and histone H4 were measured by Western blot analysis. The effect of LAQ824 was assessed by determining relative changes in the histone acetylation in the same animal's tumor FNA extracts prepared before and after the start of the therapy. Additionally, tumors were also analyzed for HDAC activity using a fluorometric histone deacetylase assay.

Results: Tumor FNA samples yielded high quality cellular proteins to evaluate the expression of total and acetylated-histone proteins on Western blot analysis. Treatment of animals with LAQ824 dramatically increased H3 and H4 protein acetylation. As tested by the fluorometric histone deacetylase assay, LAQ824 significantly inhibited HDAC activity in tumors collected by FNA from treated animals. The degree of inhibition of HDAC activity in response to therapy correlated well with enhanced histone acetylation and decrease in tumor volume.

Conclusions: We showed that the efficacy of HDAC inhibitors can be analyzed in cytologic samples obtained through tumor fine needle aspiration technique *in vivo* by assessing therapy-mediated changes in the activity of HDAC enzymes. The results of this study will be validated in upcoming clinical trials.

330 Disseminated Hepatocellular Carcinoma Presenting as Soft Tissue Masses Associated with Underlying Bone Metastases: Fine-Needle Aspiration and Radiologic Study

J Yang, A Oto, V Schnadig. The University of Texas Medical Branch, Galveston, TX.

Background: The incidence of hepatocellular carcinoma (HCC) is increasing in the United States. The extra-abdominal metastases of HCC are becoming more frequent. A significant number of patients with HCC present with bone and soft tissue masses and HCC is not usually the suspected primary neoplasm in those cases. This study reviews the cases of HCC diagnosed by fine-needle aspiration (FNA) at our institution, focusing on the subset that presented as bone and/or soft tissue masses.

Design: A computerized retrospective search of HCC, diagnosed by FNA from 1995 through mid 2005, was performed. The cases of HCC diagnosed by FNA of bone or/and soft tissue masses were selected. Correlation of results of FNA diagnoses with radiologic and clinical findings was done.

Results: Two hundred-eighty seven FNA were diagnosed as primary or metastatic HCC. Twenty-three FNA, from 20 different patients, were performed on bone or soft tissue metastases from the following sites: Bone (7) and soft tissues (16) including 5 from chest wall, 4 from supraclavicular region, 4 from head, 2 from peri-iliac region and 1 from breast. All 20 patients were further confirmed as having HCC by more than one of the following methods: liver biopsy, increased serum alpha fetoprotein, radiological findings consistent with HCC, or autopsy. Most FNA had cytomorphologic features typical of HCC. A few cases manifested features of poorly differentiated malignant neoplasm with isolated and loosely cohesive cells that had abundant cytoplasm, bizarre eccentrically located nuclei and prominent nucleoli. These cases required immunocytochemical studies and clinical correlation in order to differentiate them from other malignancies, especially melanoma. Radiologically, all these patients had TMN stage IV liver mass(es) (single mass > 5 cm or multiple masses in different lobe). Of interest, is the discovery that 9 out of 16 soft tissue masses represented soft tissue extension from underlying bone metastases. Of the remaining 7 cases, 5 had bone metastases documented distant from the soft tissue masses.

Conclusions: Bone metastases are being recognized as not uncommon complications of HCC. The clinician and pathologist should become aware of the presentation of HCC as a soft tissue mass, often indicative of underlying bone metastases.

331 A Rubric Incorporating ACGME Mandated Competency-Based Outcome Assessment and Modified Dreyfus Model of Skill Acquisition – Fine Needle Aspiration Module

N Zafar. University of Tennessee at Memphis, Memphis, TN.

Background: Training program focus for phase 2 (07/02-06/06) of the ACGME outcome project timeline is on improved evaluation processes as needed to obtain accurate resident performance data in all 6 competency domains (patient care, medical knowledge, interpersonal communication skills, practice-based learning and improvement, professionalism, system-based practice). Rubrics, which are a way of describing evaluation criteria based on the expected outcomes and performances, may offer such an opportunity. Dreyfus Model of Skill Acquisition is a progression from rule-based problem solving to a different approach based on matching against past experiences.

Design: The designed rubric matches level of trainee expertise (1-4) against the 6 ACGME competencies. Level 1 (Novice) represents entry-level skills, level 2 (Intermediate) represents increasing knowledge and confidence but limited skills and continued significant dependence on senior trainees and staff. Level 3 (Accomplished) trainee is efficient in tackling complex situations and is ready to enter clinical practice at staff level. Level 4 (Exemplary) trainee has achieved proficiency in cytology, as is expected after a year of cytology fellowship or rarely demonstrated by a very proactive and dynamic senior resident. The evaluator can check appropriate boxes to arrive at cumulative scores for the trainee with space for free text entry for comments

Results: The vertical axis of the tabulated rubric has 6 ACGME competency domains, subdivided into sections, each describing the individual competency/sub-competency and matching it against different levels of skill (Level 1-4) in the horizontal axis. A check box for each section allows for recording of the skill for that competency. The scores thus generated for each competency are added in the vertical axis to produce a cumulative score of 10 (Novice) through 40 (Exemplary) in all competency domains.

Conclusions: A well-designed rubric, based on Dreyfus Model of Skill Acquisition, may offer an improved evaluation process as needed to obtain accurate resident performance data in all 6 competency domains. Better concordance could be expected between the trainer and the trainee with respect to the quality of training and outcome. The rubric offers a powerful tool for assessing the progress of trainees; it assesses the trainee's strength and weaknesses, thus individualizing training itself. The rubric also promotes standardized assessment across trainers.

332 Use of Spectral-Spatial Analysis To Detect Malignancy in Breast Fine Needle Aspiration Specimens

CM Zalles, C Angeletti, DL Rimm. Yale University, New Haven, CT.

Background: Fine needle aspiration (FNA) biopsy of the breast is a safe procedure that is diagnostically superior to physical examination and mammography. However, its use has diminished in part due to the fact that as many as 25% of cases cannot be definitively classified or are called "atypical". In order to find an ancillary test to decrease the frequency of these diagnoses we have begun studies using spectral-spatial analysis. GENetic Imaginery Exploitation (GENIE) is a genetic algorithm-based artificial intelligence system that generates mathematical algorithms used for classifying images using spatial and spectral (color) analysis. This type of analysis has not been used in breast cytology. It has shown potential diagnostic use in detecting malignancy in other cytology specimens (thyroid and urine).

Design: Twenty six benign and 26 malignant (56 total) breast FNAs with surgical follow up were obtained. Initially, 29 images were obtained (from 420nm to 700nm) from a representative cluster from each Papanicolaou stained cytology Thin Prep slide. The image stacks were imported into the GENIE platform using the ENVI image processing system. Using GENIE-PRO a series of 8 images were manually painted green and red indicating "feature" (malignant) versus "non-feature/background" (benign) cells, respectively. The images from this training set were then used to construct diagnostic algorithm sets of which one was chosen for further study. Using this algorithm set, each image is scored as a percent pixels correctly assigned as feature (malignant) or non-feature. A "GENIE INDEX" (GI) was devised as a percentage of total pixels within the selected cluster, with a GI of 1.0 corresponding to 100% of the pixels in the cell/cell cluster being correctly assigned as feature. The algorithm set was the tested on a 20 cluster validation set (8 benign and 12 malignant cases). All fields were unique from those used in the training set.

Results: In the validation set examined with algorithm set #41 we found that benign diagnoses contained GIs that ranged from 0.02-0.48 (mean:0.12) and malignant diagnoses yielded GIs that ranged from 0.52-0.99 (mean: 0.81). An independent t test on this validation data yielded a statistical significance of <0.0001.

Conclusions: Spectral-spatial analysis obtained by GENIE can distinguish morphologically benign from malignant breast epithelial cells with 100% accuracy. Further studies are needed to determine whether this type of analysis can adjudicate equivocal FNA specimens in a manner that might aid in the definitive diagnosis of breast lesions.

333 Comparison of the Third Wave Invader HPV ASR and the Digene Hybrid Capture 2 Assays

EL Zarovnaya, LS Tooke, J Gonzalez, GJ Tsongalis. Dartmouth Medical School and Dartmouth Hitchcock Medical Center, Lebanon, NH.

Background: Infection with the human papillomavirus (HPV) is clearly associated with virtually all cervical cancers. As a result, testing for HPV DNA in conjunction with cervical cytology analysis is now standard of care in the US and several other countries. The increased demand for HPV testing has fostered great interest by molecular diagnostic manufacturers to develop robust and high-throughput means of HPV detection. This study evaluated the performance of a laboratory-developed test for HPV that utilizes the Invader® chemistry (Third Wave Technologies, Madison, WI, USA) along with HPV-specific and human DNA-specific Analyte Specific Reagents (ASR). **Design:** DNA was extracted from 256 cervical epithelium samples (1.0- 2.5 mLs) suspended in SurePath (TriPath Imaging, Inc., Research Triangle Park, NC, USA) liquid-based cytology transport medium. Results from the laboratory-developed test were compared to those generated by the Digene Hybrid Capture® 2 (hc2) High-risk HPV DNA Test™ (Digene Corporation, Gaithersburg, MD, USA) with discordant results resolved by consensus PCR and bi-directional DNA sequencing.

Results: Results from the Invader-based assay using ASR reagents were 94% concordant with results from the hc2 test. Of the 6% discordant samples, over two-thirds of the Invader results were concordant with PCR/sequencing. Indeterminate versus inaccurate results were obtained for specimens from which adequate DNA was not extracted.

Conclusions: The Invader HPV ASR assay is a robust method of identifying HPV in liquid cytology specimens. In addition, this assay offers higher throughput and less labor than the currently used hc2 assay.

334 Can the Combination of Thyroid Fine Needle Aspiration (TFNA) Routine Cytology and Ultrasound (US) Findings Reduce the Need for Surgery of Thyroid Nodules?

J Zhang, TJ Sebo. Mayo Clinic, Rochester, MN.

Background: 50% of thyroid nodules in adults are identified prior to patient death. Most of these patients will undergo TFNA as part of the clinical work-up for the nodule. Although the likelihood of classifying a TFNA as "suspicious for Hurthle cell neoplasm" is low, patients will typically undergo surgery and no more than 15% of thyroids will contain Hurthle cell carcinoma. The purpose of this study is to determine if the combination of cytologic features and ultrasound findings of a nodule classified by FNA as "suspicious for Hurthle cell neoplasm" can reduce the need for unnecessary surgery.

Design: We identified 93 patients who underwent US guided TFNA with cytologic diagnoses of "suspicious for Hurthle cell neoplasm" at our institution between 1/1/2000 and 8/18/05. The TFNA (cellularity, discohesion, presence of lymphoid aggregates and colloid) and US (number of nodules, size of dominant nodule, presence of vascularity and microcalcifications) findings in these patients were correlated with the pathology at surgery.

Results: Surgical pathology diagnoses at follow up included 15% non-neoplastic/adenomatous nodules (NNAN, n=14), 67% Hurthle cell adenomas (HA, n=62), 11% Hurthle cell carcinomas (HCA, n=10), 6% papillary thyroid carcinomas (PTC, n=6) and 1% diffuse large B cell lymphoma (DLBCL, n=1). *US Findings* – the average size (cm)

Dermatopathology

of the nodules aspirated was 1.8 (NNAN), 3.2 (HA), 3.0 (HCA) and 2.9 (PTC). The average numbers of nodules identified by US were 3.3 in NNAN, 2.0 in HA, 1.7 in HCA, and 1.8 in PTC ($p < 0.05$). Furthermore, 40% (4 of 10) and 20% (2 of 10) of HCA were vascularized and microcalcified on US, respectively; and 50% (7 of 14) of NNAN had multiple (5) small nodules in the background thyroid. **FNA Findings** – the Hurthle cell tumors had more cellular smears, discohesive Hurthle cells, few, if any, lymphocytes, and scarce or absent colloid in comparison to the smears from NNAN.

Conclusions: Dominant thyroid nodules 2 cm or less on US without evidence of increased vascularity or microcalcifications in combination with the background thyroid containing multiple (3 or more) smaller nodules and the FNA smears containing some lymphoid aggregates with Hurthle cells in moderately sized sheets are likely to be benign. Communication between clinician and pathologist correlating US and FNA findings in difficult cases may avoid unnecessary surgery.

335 A 12 Year Analysis of 4,121 PAP Tests from 2,326 Adolescents of Southern Rhode Island: An Important Public Health Issue

SL Zhang, J Zhang, C Giampaolo, K Cassin, S Antoni. South County Hospital, Wakefield, RI; South Kingstown High School, Wakefield, RI.

Background: Cervical cancer screening in adolescents is an important public health care issue because of the high risk of Human Papilloma Virus infection in teens. Although the American Cancer Society recently proposed a recommendation, there has been no consensus on when to initiate Pap smear screening, and how to manage teens with abnormal Pap smear due to the limited evidence-based long term studies.

Design: In this study, 4,121 Pap tests from 2,326 adolescents aged 12 to 19 at South County Hospital of Rhode Island from 1992 to 2004 were analyzed. The Bethesda system was used for classification of abnormal Pap smears. The majority of high-grade cases were confirmed by either biopsy or conization procedure. The prevalence of the abnormal Pap tests was compared to those of the general population over the same period from same database.

Results: The abnormal Pap tests in adolescents were significantly higher with 8.0 % atypical squamous cells of undetermined significance (ASCUS), 7.0% low-grade squamous intraepithelial lesions (LGSIL), and 2.2 % high-grade squamous intraepithelial lesions (HGSIL) in comparison with the general population (4.24 % ASCUS, 2.13 % LGSIL, and 0.48 % HGSIL). Of the 43 cases of biopsy confirmed HGSIL, there were seven cases of CIN 3 (carcinoma in situ) (16.3 %), four cases of CIN 2-3 (9.3 %) and 32 cases of CIN 2. Although about 80% of HGSIL occurred at ages 18 and 19, CIN 3 was seen in two 15-year-old teens. The average time between the first screening and detection of HGSIL was 14.8 months.

Conclusions: This study indicates that abnormal Pap smear in teens is a significant health care issue and that Pap smear screening should start early in sexually active teens or at 18 years of age if sexual history is not clear. Once initiated, teens should continue to have annual screen during adolescence regardless of number of previous normal screenings.

336 Suspicious for Malignancy in Fine Needle Aspiration of Breast: Reasons and Clinical Implications

X Zhang, Y Huang, C Solomides. Temple University Hospital, Philadelphia, PA.

Background: Suspicious for malignancy (SFM) in fine needle aspiration (FNA) of breast is a diagnostic category that might cause dilemma in patient management. The diagnosis is rendered for a number of reasons, so its elimination may not be realistic. Its clinical implications need to be fully explored.

Design: To analyze the underline rationale for rendering the diagnosis and its clinical implications, 33 breast FNA specimens from 31 patients with the diagnosis of SFM were retrieved from our file in a 5-year's period from 2000 to 2004. 29 of the 31 patients had follow up histologic diagnosis, forming the basis of this study. The cytologic and histologic materials were reviewed and correlated.

Results: Of the 29 patients, follow up core biopsy, excisional biopsy and/or mastectomy revealed 20 invasive ductal carcinoma, 2 invasive lobular carcinoma, 3 ductal carcinoma in situ (DCIS), 2 atypical ductal hyperplasia, 1 ductal hyperplasia without atypia and adenosis, and 1 intraductal papillomatosis. Review of the cytologic materials identified the following factors that precluded more definitive classification of the lesions: 1. Scanty cellularity; 2. Predominantly cohesive cellular clusters; 3. Presence of myoepithelial cells; 4. Tumor cells in a cystic background with foamy cells; 5. Tumor cells with low nuclear grade; 6. Tumor cells with apocrine differentiation. Further analysis found that the most useful criteria for diagnosing carcinoma were hypercellularity, single cells, loosely cohesive clusters of cells with disorientation and irregular edge, significant anisonucleosis with high N/C ratio, prominent nucleoli and nuclear pleomorphism. When a combination of any four of the criteria was fulfilled, 14 of the 25 cases with carcinoma were correctly diagnosed. However, no reliable criteria were identified for definitive diagnosis of the carcinoma (including DCIS) with low nuclear grade and for recognizing atypical ductal hyperplasia. Therefore not all the cases could be accurately diagnosed cytologically with confidence. Excisional biopsy performed in 19 of the 29 patients provided with definitive diagnosis and the information necessary for proper patient management.

Conclusions: Multiple reasons are found for rendering the diagnosis of SFM in FNA of breast. Although possible to reduce the number of the cases by restrictively applying the identified criteria, it is unrealistic to eliminate the category. It is more important to set the appropriate way to manage the patients, and excisional biopsy is suggested as the next step.

337 CD10 and Ep-CAM Expression in Basal Cell Carcinoma, Classical Trichoepithelioma, and Desmoplastic Trichoepithelioma

TE Abbott, MD Cole, JW Patterson, MR Wick. University of Virginia Health System, Charlottesville, VA.

Background: The distinction between basal cell carcinoma (BCC) and trichoepithelioma (TE) has historically been made on the basis of specific histologic criteria, but it may be difficult when the tumor sample is limited. Recent reports have suggested a utility for CD10 and Ep-CAM immunostaining in recognizing BCC. Accordingly, this study was initiated in order to determine whether those markers might aid in the distinction between BCC and TE variants in small biopsy specimens. **Design:** Paraffin sections of BCC variants, classical TE, and desmoplastic trichoepithelioma (DTE) were retrieved. Antibodies against CD10 (clone 56C6, Abcam, Inc) and Ep-CAM (clone Ber-EP4, Abcam, Inc) were applied using standard immunohistochemical technique. For CD10, the pattern of tumor cell staining was descriptively recorded as peripherolobular, solid, scattered, papillary mesenchymal body (PMB)-accentuated, or combined. Stromal labeling was similarly coded as continuous, discontinuous, or diffuse. Staining for Ep-CAM was categorized as 0 (negative); 1+ (1-20% of cells); 2+ (21-50%); or 3+ ($\geq 51\%$).

Results: CD10 was present in at least a portion of tumor cells in 28 of 30 BCCs, 21 of 22 TEs, and 6 of 28 DTEs. The predominant pattern was peripherolobular in BCCs, PMB-accentuated in TE, and cord-like in DTE. Peritumoral stromal cells were labeled in all BCCs and TEs, and in 27 of 28 DTEs; the dominant pattern was diffuse-discontinuous in BCC, continuous in TE, and diffuse in DTE. Ep-CAM was present in all 40 BCCs, all 29 TEs, and 29 of 30 DTEs, but the mean percentage of immunoreactive tumor cells was 84%, 56%, and 31% respectively. The Ep-CAM staining pattern for both BCC and TE was peripherolobular. When positive, DTE again showed cord-like labeling for that marker. Analysis of immunostaining patterns in various morphologic BCC variants demonstrated no significant differences.

Conclusions: Although trends toward differential staining patterns for CD10 and Ep-CAM were evident in this analysis, those two determinants do not appear to provide practically useful information for the diagnostic separation of BCC from TE or DTE. Histologic criteria remain as the standard for recognition of those tumor types.

338 A High-Throughput Study Identifies Epithelial-Mesenchymal Transition as Major Determinant of the Melanoma Metastatic Capacity

SR Alonso, PL Ortiz, L Tracey, B Perez-Gomez, M Pollan, J Linares, S Serrano, AI Saez, L Sanchez, R Pajares, C Ballestin, MA Piris, JL Rodriguez-Peralta. CNIO (Spanish National Cancer Center), Madrid, Spain; HU 12 de Octubre, Madrid, Spain; ISCIII, Madrid, Spain; HU San Cecilio, Granada, Spain.

Background: Apart from Breslow index there are no histopathological or molecular markers that could consistently predict the metastatic potential for Cutaneous malignant melanoma (CMM) cases.

Design: To identify the genes associated with increased metastasis risk in a group of primary CCM with biological potential to metastasize (Vertical Growth Phase Melanomas cases with more than 1mm of Breslow's index), 36 primary CMM cases were analysed with the c-DNA microarray CNIO Oncochip™ containing 6500 cancer-relevant genes. All patients had a minimum follow-up of 3 years in which 22 cases develop nodal metastatic disease and 14 not. The results were validated using immunohistochemistry in a Tissue Micro Array containing cores for an independent series of 132 primary CMM cases.

Results: Differences in expression between metastatic versus non-metastatic disease identified 116 differentially expressed genes at >2 -fold ratio. Of these genes 91 were up-regulated and 25 were down-regulated. This set of genes included molecules involved in cell cycle regulation, epithelial-mesenchymal transition (EMT), angiogenesis, signal transduction, metabolism and structural genes. A large group of biologically significant genes was related with epithelial-mesenchymal transition (EMT). The validation in an independent series showed that proteins included in this group were associated with metastases development ($p < 0.002$) and with a shorter survival time ($p < 0.009$).

Conclusions: The study identified a specific subset of genes whose expression is related with the development of metastatic disease in patients with CMM. A significant proportion of these genes was related with EMT, the acquisition of a mesenchymal phenotype with migratory and invasive properties. This information could help to better understand the biology of this aggressive tumour and might result in new and more effective therapies or more accurate patient stratification.

339 Intracapsular Melanoma in Sentinel Lymph Node Biopsies

KO Alsaad, NA Obaidat, DM Ghazarian. University of Toronto and Univeristy Health Network, Toronto, ON, Canada.

Background: Sentinel lymph node biopsy (SLNB) is an important and significant independent factor for prognosis and management of patients with melanoma. Pathologically, sentinel lymph node (SLN) involvement by metastatic melanoma can be characterized, based on the location of metastatic foci of malignant cells, into subcapsular (most common), parenchymal, sinusoidal, or mixed. Potential pitfall in the interpretation of SLN for melanoma is the presence of benign nevus cells within the capsule (intracapsular) of the node. These characteristically lack cytonuclear atypia, mitotic activity and are usually immunonegative for HMB-45.

Design: Sentinel lymph node biopsies from two patients with proven cutaneous melanoma were processed using the SLNB protocol (modified from Cochran et al), and examined by routine light microscopy and immunohistochemical study (S-100 protein, Melan A, and HMB-45 in the first case, and Melanoma Cocktail in the second case)