Modern Pathology (2004) 17, 1031–1037

www.modernpathology.org

# The site of infection and ethnicity of the patient influence the biological pathways to HPV-induced mucosal cancer

Wei Li[1,2], Carol H Thompson[2], Yvonne E Cossart[2], Christopher J O'Brien[1], Jihong Liu[2,5], Richard A Scolyer[3], Jonathan R Carter[4], Christopher Dalrymple[4] and Barbara R Rose[1,2]

[1]*Sydney Head & Neck Cancer Institute, Royal Prince Alfred Hospital, Sydney, Australia;* [2]*Department of Infectious Diseases, University of Sydney, Sydney, Australia;* [3]*Department of Anatomical Pathology and* [4]*Department of Gynaecologic Oncology, Royal Prince Alfred Hospital, Sydney, New South Wales, Australia and* [5]*Department of Gynaecological Oncology, Cancer Centre of Sun Yat-sen University, Guangzhou, China*

**High-risk human papillomaviruses are the causative agents of cervical cancer and are also believed to be aetiologically involved in a subset of squamous cell carcinomas of the head and neck region, especially the tonsil. Cervical cancers arise through disruption of the pathways of p53 and the product of the retinoblastoma gene by the human papillomavirus oncoproteins E6 and E7. It is generally assumed that the same pathways are involved in human papillomavirus-induced carcinogenesis at other mucosal surfaces. However, the patterns of expression of cell cycle proteins targeted by human papillomavirus *E6* and *E7* in cancers from different anatomic sites have been inconsistent, due to either biologic or technological factors. In this study, 73 human papillomavirus, 16-positive cervical squamous cell carcinomas (35 from Australian and 38 from Chinese women) were analysed for the expression of p53, pRb, p16$^{INK4A}$, p21$^{CIP1/WAF1}$, p27$^{KIP1}$ and cyclin D1 by semiquantitative immunohistochemistry. Cervical cancers from Chinese women were found to be significantly more likely to overexpress p53, pRb, p21 and p27 than their Australian counterparts. These findings were compared with those from 31 human papillomavirus 16-positive tonsillar squamous cell carcinomas, all of Australian origin, tested using the same methodology. Comparisons of the tonsillar and combined cervical data showed that tonsillar cancers were significantly more likely to be p53-positive, whereas cervical cancers were significantly more likely to overexpress pRb, p16 and p27. When the tonsillar data were compared with cervical data from Australian women, the associations for p53 and pRb remained. These findings represent new evidence that the molecular pathways to human papillomavirus-induced mucosal cancer may be influenced by anatomic location and ethnicity.**
*Modern Pathology* (2004) **17,** 1031–1037, advance online publication, 14 May 2004; doi:10.1038/modpathol.3800155

**Keywords:** Human papillomavirus; cervical cancer; tonsillar cancer; cell cycle proteins; *E6*/*E7*

High-risk human papillomaviruses (HPV)s, most notably types 16 and 18, are regarded as the causative agents for cervical cancer worldwide.[1] There is now convincing evidence that HPV 16 is also aetiologically involved in a subset of cancers of the head and neck region, particularly those of the tonsil.[2–5] It is accepted on the basis of studies of cervical cancers that expression of the HPV *E6*/*E7* oncogenes disrupts the key cell cycle controllers p53 and the product of the retinoblastoma gene (pRb).[1] The HPV oncogenes also affect the expression of other proteins operating in the p53 and pRb pathways, such as cyclin D1 and the cyclin-dependent kinase inhibitors (CDKI) p21$^{CIP1/WAF1}$ (p21), p16$^{INK4A}$ (p16) and p27$^{KIP1}$ (p27) either directly or indirectly.[6–8]

It is generally assumed that the molecular pathways involved in HPV-induced carcinogenesis of the head and neck region are the same as those in the cervix. However, patterns of expression of cell cycle proteins targeted by HPV *E6* and *E7* observed in studies of cancers from these different anatomic sites have not always supported this hypothesis, and there has even been variation between the different studies of cervical cancers.[2,9,10] Inconsistencies in p53 positivity rates in cervical as opposed to head and neck cancers

Correspondence: Dr BR Rose, Sydney Head & Neck Cancer Institute, PO Box M 142, Missenden Road, Camperdown, NSW 2050, Australia.
E-mail: b_rose@infdis.usyd.edu.au
Received 8 March 2004; revised and accepted 6 April 2004; published online 14 May 2004

can be explained by differences in the rates of p53 mutation. p53 mutations have rarely been detected in HPV-positive cervical cancers[11] but appear to coexist with HPV in some head and neck cancers.[12] The detection of p53 protein in cervical cancers by immunohistochemistry has mainly been attributed to the use of antibodies which detect stabilization of wild-type protein resulting from ongoing stress or disruption to proteins involved in p53 degradation, such as MDM2[11] in addition to mutations.

The p16/pRb/cyclin D1 cascade mediates progression through the G1 phase of the cell cycle.[13] Phosphorylation of pRb releases the E2F transcription factor leading to the expression of proteins needed for S phase induction. The cyclin-dependent kinase inhibitor p16 down regulates cyclin D1 through interaction with cyclin-dependent kinases 4 and 6. Although the results of recent studies suggest that the mere presence of HPV in head and neck cancers does not necessarily indicate an aetiologic role,[5] our studies and those of others,[2,5,14,15] have shown that HPV 16-positive head and neck cancers are consistently characterized by reduced expression of pRb and cyclin D1 in conjunction with upregulated p16, supporting a causal relationship. There is evidence for a similar scenario in HPV 16-positive anorectal cancers.[16] The processes in cervical cancer seem more complex. Strong diffuse p16 staining with concomitant loss of cyclin D1 have been widely associated with cervical dysplasia and cancer and/or the presence of high-risk HPVs,[6,17,18] but there is no consensus on the expression of pRb in relation to the presence of HPV; some studies have reported loss of pRb,[19] but in others, pRb has either been conserved[20] or overexpressed.[21]

The p21 and p27 proteins are also involved in G1 transition and both are targeted by HPV *E7*.[6–8] Studies of expression of these markers in cervical cancers have produced inconsistent results.[6,9,10,22] Less is known of the relationships between HPV status and p21 and p27 expression in tonsillar cancer, but no associations were identified in our recent series.[15]

Since there have been few, if any, studies of the expression of these cell cycle proteins in HPV-positive cancers at different mucosal sites from patients with different ethnic backgrounds where the same experimental conditions have been used throughout, the observed discrepancies may reflect biological issues such as ethnicity or HPV type, or technical factors such as the specificities of the various antibodies or experimental protocols. In this study, the relative expressions of p53, p21, p16, pRb, cyclin D1 and p27 were examined in HPV 16-positive cervical squamous cell carcinomas from Australian and Chinese women. The findings were compared with those from our previous study of Australian HPV 16-positive tonsil squamous cell carcinomas using the same methodology.[15,23]

## Materials and methods

Initial investigations were carried out on HPV 16-positive cervical squamous cell carcinomas from 73 women, 35 from Australia and 38 from China. The 35 Australian women received treatment for the disease between 1990 and 2001 at the Royal Prince Alfred Hospital (RPAH), Sydney, Australia. The 38 Chinese patients were recruited from two hospitals in southern China between 1998 and 2001; 24 from The Cancer Centre, Sun Yat-Sen University of Medical Science, Guangzhou in Guang Dong (Canton) Province and 14 from the Provincial Tumor Hospital, Changsha in Hunan province. The demographics and tumour characteristics for both groups are presented in Table 1. Patients from both countries had previously undergone HPV investigations complementary to this study[24] (and MS submitted). The only selection criteria for the initial investigations were the availability of clinicopathologic data and tumour material. The only additional criteria for the present study were a pathologic diagnosis of squamous cell carcinoma and the presence of HPV 16 in the tumours (as determined by sequence analysis of polymerase chain reaction (PCR) products generated using consensus primer combinations MY09/MY011,[25] GP5+/6+[26] and CPI/IIG[27]). Adequate tumour cells were shown to be present in H&E-stained sections cut from the corresponding tissue blocks.

Data on the expression of these cell cycle proteins in the cervical cancers were then compared with those from a previous study of 31 HPV 16-positive tonsillar squamous cell carcinomas from Australian patients treated at RPAH or Westmead Hospital, Sydney between 1979 and 2002.[23] The demographics and tumour characteristics of the group with tonsillar cancer are presented in Table 1.

### Immunohistochemistry

*Cervical cancers*

Immunohistochemistry was performed on 5 $\mu$m thick tissue sections cut from formalin (Chinese) or formalin–acetic acid–alcohol (FAA) (Australian) fixed paraffin-embedded tissue blocks and placed on Silane (Sigma-Aldrich, St Louis, MO, USA)-coated slides as described for our tonsillar cancer studies.[15,23,28] For p53, p21, p27 and cyclin D1, the same monoclonal antibodies were used—PAb240 (mutation-specific), SX118, SX53G8 and DCS-6 all from DAKO, Carpintaria, CA—and p16 (Ab-4, Clone 16p04 Neomarkers, Fremont, CA, USA). For pRb, monoclonal antibody Rb1 (Novacastra Laboratories, Newcastle, UK) replaced Rb1 (DAKO) since, in preliminary experiments, the DAKO antibody proved unsuitable for use with FAA-fixed tissues. The Rb1 antibody was diluted 1/80 and sections incubated overnight at 4°C; all other protocols were as previously described. Negative controls performed for each antibody included omitting the primary antibody and the substitution of the

**Table 1** Demographics, tumour characteristics and protein expression in HPV 16-positive Australian and Chinese cervical cancers and Australian tonsillar cancers

| | *Cervical cancer* | | *Tonsillar cancers* | P-*value* | | |
|---|---|---|---|---|---|---|
| | *Australian* *N = 35* | *Chinese* *N = 38* | *Australian* *N = 31* | *p1* | *p2* | *p3* |
| *Demographics and tumour characteristics* | | | | | | |
| Mean age | 45.4 (s.d. 13.4) | 41.66 (s.d. 10.59) | 52 (s.d. 10.5) | NS | 0.001 | 0.028 |
| Range | 28–71 | 26–80 | 35–72 | | | |
| Stage[a] | | | | | | |
| Early stage | 28/35 (80%) | 19/38 (50%) | 10/31 (32%) | 0.007 | 0.001 | <0.001 |
| Advanced stage | 7/35 (20%) | 19/38 (50%) | 21/31 (68%) | | | |
| Node status | | | | | | |
| Positive | 9/35 (26%) | 8/38 (21%) | 20/31 (65%) | | | |
| Negative | 15/35 (43%) | 15/38 (39%) | 7/31 (23%) | NS | 0.002 | 0.008 |
| Unknown | 11/35 (31%) | 15/38 (39%) | 4/31 (13%) | | | |
| Grade | | | | | | |
| I | 5/35 (14%) | 7/38 (18%) | 4/31 (13%) | | | |
| II | 22/35 (63%) | 22/38 (59%) | 15/31 (48%) | NS | NS | NS |
| III | 8/35 (23%) | 9/38 (24%) | 12/31 (39%) | | | |
| *Protein expression* | | | | | | |
| p53 positive | 1/35 (3%) | 8/35[b] (23%) | 16/31 (52%) | 0.028 | <0.001 | <0.001 |
| p16 Up | 34/35 (97%) | 38/38 (100%) | 27/31 (87%) | NS | 0.012 | NS |
| pRb Up | 19/34[b] (56%) | 34/38 (89%) | 6/31 (19%) | 0.001 | <0.001 | 0.002 |
| Cyclin D1 Up | 1/35 (3%) | 4/33[b] (12%) | 4/31 (13%) | NS | NS | NS |
| p21 Up | 22/35 (63%) | 37/38 (97%) | 20/31 (65%) | <0.001 | NS | NS |
| p27 Up | 12/35 (34%) | 34/38 (89%) | 13/31 (42%) | <0.001 | 0.047 | NS |

N = number patients; NS = not significant; Up = upregulated expression; *p1* = Australian *vs* Chinese cervical cancers; *p2* = combined Australian and Chinese cervical cancers *vs* tonsillar cancers; *p3* = Australian cervical cancers *vs* Australian tonsillar cancers.

[a]Early stage for tonsillar cancer = Stage I, II (1997 American Joint Committee on Cancer Staging criteria).[41] Early stage for cervical cancer < Stage IIb (SGO Handbook Staging of Gynecologic Malignancies, Chicago, 1994 Society of Gynecologic Oncologists).

[b]missing data due to technical difficulties.

primary antibody with normal serum. A positive control comprising a section from the same cancer block previously shown to be positive for the particular marker was incorporated in each run.

Immunostaining was evaluated semiquantitatively as previously by at least three of the four independent observers (WL, RS, BR, CT) without knowledge of the clinical or pathological data. At least 1000 tumour cells were evaluated for each section. Two evaluation methods were used; the first, used for all proteins, categorised expression as up- or downregulated according to the percentage of tumour cells stained.[29] 'Cut-off' values using this method traditionally have varied with the sensitivities and specificities of the particular antibodies. In this study the cutoffs for p53 and pRb were 10 and 30%, respectively, and for cyclin D1, p21 and p27 were each 5%. Staining of p16 in cervical and tonsillar cancer cells was essentially 'all or none' so that a specific cut-off was not required. The second method was used for sections containing normal epithelium. Account was taken of the intensity of staining (graded + to + + +) and the proportion of stained cells (graded + to + + +) using normal epithelium as reference essentially as described by Erber *et al.*[30] Tumours scored as 'downregulated' showed a greater than 20% reduction in numbers of cells staining and/or a reduced intensity of staining compared with normal epithelium, those scored as 'unchanged' had less than a 20% difference from normal; while those designated as 'upregulated' showed greater than 20% increase in numbers and/or intensity of staining. This method was unsuitable for p16 and p53 antibodies which rarely stained normal epithelium.

*Tonsillar cancers*

Tonsillar cancers had originally been tested using the DAKO pRb1 antibody were retested with the Novacastra Rb1 antibody.

### Statistical Analyses

Overall, data from the Australian and Chinese cohorts were compared using the Mantel–Haenszel method[31] and the Pearson's $\chi^2$ test. Only *P*-values of $<0.05$ were considered significant. Comparisons of mean age were carried out using Student's *t*-test.

## Results

### Cervical Cancers

*Demographics and tumour characteristics*

There were no significant differences in mean age, node status and tumour grade between the Australian and the Chinese groups (Table 1). However, the Chinese women were more likely to have

advanced disease (>Stage IIa) than their Australian counterparts.

*Expression of proteins*

The distribution and intensity of staining of pRb, cyclin D1, p21 and p27 in normal cervical epithelium from both countries were similar to those found previously in our study of normal tonsillar epithelium.[15] p53 did not stain normal epithelium and p16 rarely did so. Nuclear staining only was considered positive for all markers except p16 which stained both nucleus and cytoplasm. Representative staining for pRb and p16 is shown in Figure 1.

p53: Intensity and distribution of staining of tumour cells were variable.

pRb: In normal cervical epithelium, staining was generally evident throughout the entire epithelium, but most intense staining was evident in the suprabasilar layers. Staining in the tumour cells was frequently strong and widely distributed especially in the Chinese tumours. Background staining was evident in some FAA-fixed tissues.

p16: In the normal cervical epithelium rare suprabasilar squamous cells showed weak nuclear staining. Strong diffuse staining was evident in both the nucleus and cytoplasm of a high proportion of tumour cells from most cases.

cyclin D1: Focal weak nuclear staining could be seen in the basal and parabasal layers. Staining of malignant cells was diffuse and variable in distribution and intensity.

p21: Expression of p21 in normal cervical epithelium was uniformly low and confined to basal cells and the parabasal cell layers. The level of staining in tumour cells was frequently strong, particularly in tumours from Chinese patients, and distribution was variable.

p27: In normal cervical epithelium, staining was mainly confined to the upper two-thirds of the epithelium. In tumour cells, intensity and distribution of staining were variable. Lymphocytes stained strongly and served as an internal positive control.

*Comparisons of protein expression in cervical tumours from Australia and China*

Comparison of the expression of the proteins evaluated by the percentage of positive tumour cells is shown as p1 values in Table 1. The findings comparing expression in tumour and normal cells in the same section were entirely consistent (data not shown). The overwhelming majority of cervical

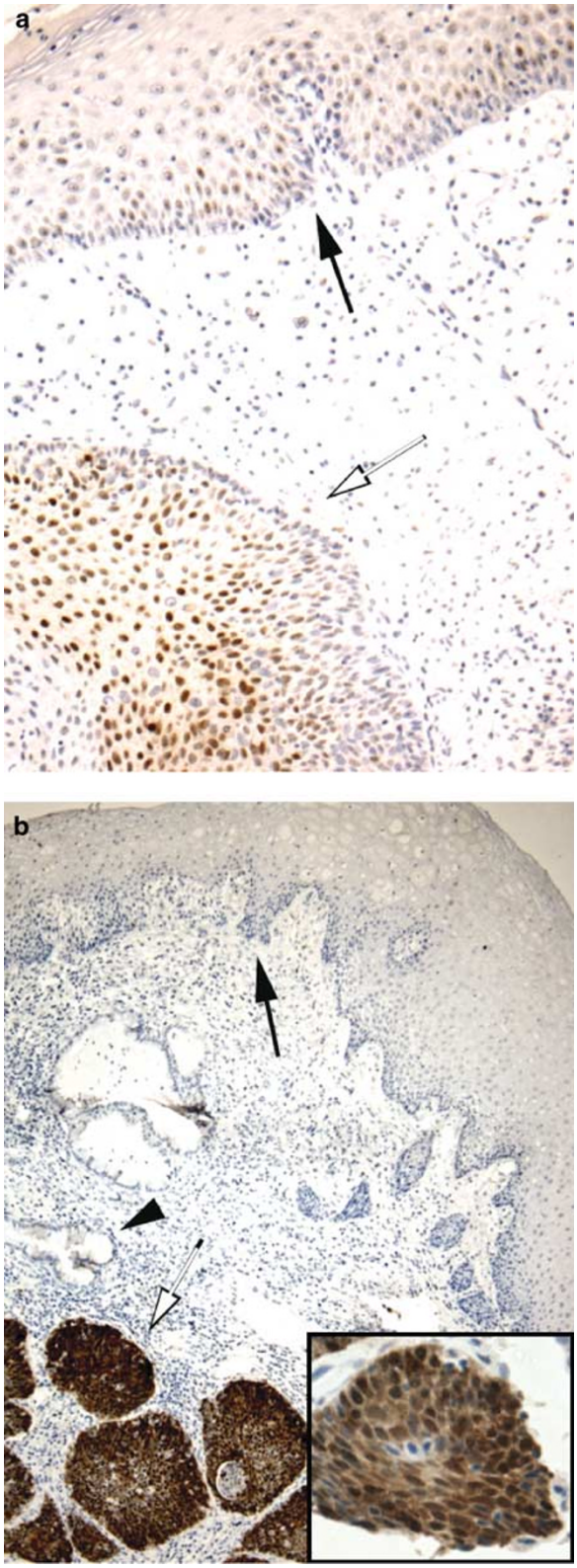


**Figure 1** HPV-positive cervical squamous cell carcinomas. (**a**) Upregulation of pRb expression. The majority of the tumour cells show intense nuclear staining as indicated by hollow arrow, whereas only a few positive nuclei are seen in the parabasal cells of normal epithelium. The basal cells of the native squamous mucosa are indicated by the black arrow (×200). (**b**) Upregulation of p16. Strong diffuse staining is shown in a high proportion of tumour cells as indicated by the hollow arrow. The inset close up view (×400) shows staining throughout the nucleus and cytoplasm. The overlying mucosa (basal cells indicated by the black arrow) is negative. The black arrowhead alone indicates a mucous endocervical gland (×100).

tumours from both countries showed strong diffuse staining for p16 and little or no expression for cyclin D1. Notably, expression of pRb was also upregulated in the majority of cancers from both countries, but the rate of overexpression was higher in the Chinese group. Tumours from Chinese patients were significantly more likely to be positive for p53 and to have upregulated p21 and p27 than their Australian counterparts.

*Comparisons between cervical and tonsillar cancers*
A comparison of combined data from the 73 cervical tumours (35 Australian and 38 Chinese) with the 31 HPV-16-positive Australian tonsillar tumours showed that patients with cervical tumours tended to be younger, and were significantly less likely to have advanced disease and positive nodes than those with tonsillar cancers (p2 values Table 1). There was no significant difference in tumour grade. The p53-positivity rate among the tonsillar cancers (52%) was significantly higher than that in cervical cancers (13%). The most notable finding among the other markers was for pRb: only 19% of tonsil cancers showed upregulated expression compared with 74% of cervical cancers. Cervical cancers were also significantly more likely than tonsillar cancers to have upregulated p16 and p27.

Comparison of the tonsillar data with the cervical data from Australian women is shown in Table 1 (p3 values). The p53 positivity rate in the tonsillar cancers was significantly higher than in the cervical cancers; in contrast, upregulation of pRb was significantly higher in cervical than in tonsillar cancers.

## Discussion

This study extends and clarifies previous investigations by comparing the expression of key cell cycle markers in tumours of known HPV status from different anatomic sites of patients with different ethnic backgrounds under the same experimental conditions. The studies focussed on two sites—cervix and tonsil—where oncogenic HPVs are frequently detectable and were confined exclusively to HPV 16-positive squamous cell carcinomas to control for the effects of tumour histology and HPV type.

This study provides evidence that the complex interlocking pathways of HPV-induced oncogenesis at mucosal sites may be influenced by ethnic factors and anatomic location as well as recognised exposures to risk factors such as smoking and alcohol. The higher p53 positivity rate in Chinese relative to Australian cervical cancers was of particular interest. The p53 antibody used has been designated as mutation-specific so this finding is likely to reflect the effects of environmental or occupational mutagens. Although smoking is a candidate as a cofactor for HPV in cervical carcinogenesis,[32] our epidemiological data show that these Chinese women were significantly less likely to smoke cigarettes than their Australian counterparts (MS submitted). The higher p53 positivity rate in tonsillar compared with cervical cancer was consistent with previous reports[33] and has been linked to differences in direct exposure to tobacco and alcohol. The biological implication of mutant p53 in the context of oncogenic HPV infection is unknown.

Disruption to the p16/pRb/cyclin D1 pathway in HPV 16-positive tumours also appears to vary in some respects with ethnicity and anatomic site. Studies of HPV 16-positive tonsil cancers including our own[2,15,23,28,34] have consistently shown marked upregulation of p16 in conjunction with downregulation of cyclin D1 and pRb. The same patterns of expression for p16 and pRb have been identified in HPV-16 positive anorectal cancers.[35] It has been suggested that loss of pRb through the activities of HPV *E7* overcomes the need for cyclin D1 in G1 and leads to upregulation of p16 through a feedback loop. The scenario in cervical cancer is not as well defined. While overexpression of p16 along with loss of cyclin D1 have been widely reported,[17,36,37] pRb has been conserved or upregulated in some series[20,21,29] but downregulated in others.[19] In this study, the majority of cervical cancers from both countries had upregulation of both p16 and pRb and downregulation of cyclin D1. The trend for upregulated pRb was particularly marked in the Chinese subset. The mechanisms underpinning such strong expression of pRb in the presence of HPV 16 *E7* in cervical, but not other HPV 16-positive mucosal cancers, are unknown. pRb mutations are reportedly rare in both tonsillar and cervical cancers[2,33] and there has been no strict correlation with HPV status.[38] Interplay between the p53 and pRb pathways has been reported,[39] but there was no evidence of a relationship between p53 positivity and pRb expression in our cervical cancers.

Interestingly, the overexpression of p21 was frequently observed in tumours from both countries and from both anatomic sites. However, both the intensity of staining and the proportion of upregulated tumours were greatest in Chinese cervical cancers. Overexpression of p27 was not nearly as common as p21 except in Chinese cervical cancers. The overexpression of p21 and p27 reported in some studies of cervical cancers has been explained in terms of stabilisation induced through interaction with HPV *E7*.[40] However, there was no association between HPV status and p21 or p27 expression in our previous study of tonsillar cancers.[15] These differences may, in part, reflect the complexity of the interlocking pathways. For example p21 is activated by p53 in response to stress, but can also be induced by p53-independent pathways.

The findings of this study suggest that inconsistencies in the expression of these cell cycle proteins across the various studies may be accounted for by genetic-based ethnic factors such as

HLA type in addition to other factors such as HPV type, tumour histology or the specificity or sensitivity of the particular antibodies. Even so, in this study there were only minor differences in the staining of normal epithelial cells of Australian and Chinese origin. The possibility that tumour stage may have been a contributing factor in our series cannot be excluded since the Chinese women were more likely to have advanced cervical cancers than their Australian counterparts. However, there was no evidence of disproportionate overexpression of these proteins in advanced cervical tumours, and to our knowledge no associations have been reported between tumour stage and protein expression.

The findings of this study highlight the complexities of the interlocking pathways mediating HPV-mediated cell cycle control in mucosal squamous cell carcinomas. Evidence is accumulating that HPV-positive head and neck cancers represent a distinct biologic group. Evidence that the precise mechanisms of HPV-induced carcinogenesis can vary along anatomic and genetic-based ethnic lines may have implications in terms of the use of immunohistochemistry as a diagnostic and prognostic tool in these cancers. Further studies will be needed to advance our understanding of the molecular mechanisms underpinning these apparent differences.

## Acknowledgements

We wish to thank Michael Veness for supply of some tonsillar cancer specimens and Lawrence Young for advice in regard to the immunohistochemistry.

## References

1 Zur Hausen H. Oncogenic DNA viruses. Oncogene 2001;20:7820–7823.
2 Andl T, Kahn T, Pfuhl A, *et al.* Etiological involvement of oncogenic human papillomavirus in tonsillar squamous cell carcinomas lacking retinoblastoma cell cycle control. Cancer Res 1998;58:5–13.
3 Wilczynski SP, Lin BT, Xie Y, *et al.* Detection of human papillomavirus DNA and oncoprotein overexpression are associated with distinct morphological patterns of tonsillar squamous cell carcinoma. Am J Pathol 1998; 152:145–156.
4 Mellin H, Friesland S, Lewensohn R, *et al.* Human papillomavirus (HPV) DNA in tonsillar cancer: clinical correlates, risk of relapse, and survival. Int J Cancer 2000;89:300–304.
5 Wiest T, Schwarz E, Enders C, *et al.* Involvement of intact HPV16 *E6/E7* gene expression in head and neck cancers with unaltered p53 status and perturbed pRb cell cycle control. Oncogene 2002;21:1510–1517.
6 Skomedal H, Kristensen GB, Lie AK, *et al.* Aberrant expression of the cell cycle associated proteins TP53, MDM2, p21, p27, cdk4, cyclin D1, RB, and EGFR in cervical carcinomas. Gynecol Oncol 1999;73:223–228.
7 Cheung TH, Lo KW, Yu MM, *et al.* Aberrant expression of p21(WAF1/CIP1) and p27(KIP1) in cervical carcinoma. Cancer Lett 2001;172:93–98.
8 Kim YT, Cho NH, Park SW, *et al.* Under expression of cyclin-dependent kinase (CDK) inhibitors in cervical carcinoma. Gynecol Oncol 1998;71:38–45.
9 Milde-Langosch K, Riethdorf S. Role of cell-cycle regulatory proteins in gynecological cancer. J Cell Physiol 2003;196:224–244.
10 Kim YT, Cho NH, Park SW, *et al.* Underexpression of cyclin-dependent kinase (CDK) inhibitors in cervical carcinoma. Gynecol Oncol 1998;71:38–45.
11 Milde-Langosch K, Albrecht K, Joram S, *et al.* Presence and persistence of HPV infection and p53 mutation in cancer of the cervix uteri and the vulva. Int J Cancer 1995;63:639–645.
12 Snijders PJ, Steenbergen RD, Top B, *et al.* Analysis of p53 status in tonsillar carcinomas associated with human papillomavirus. J Gen Virol 1994;75: 2769–2775.
13 Serrano M, Hannon GJ, Beach D. A new regulatory motif in cell-cycle control causing specific inhibition of cyclin D/CDK4. Nature 1993;366:704–707.
14 Klussmann JP, Weissenborn SJ, Wieland U, *et al.* Prevalence, distribution, and viral load of human papillomavirus 16 DNA in tonsillar carcinomas. Cancer 2001;92:2875–2884.
15 Li W, Thompson CH, Cossart YE, *et al.* The expression of key cell cycle markers and presence of human papillomavirus in squamous cell carcinoma of the tonsil. Head Neck 2004;26:1–9.
16 Lu DW, El-Mofty SK, Wang HL. Expression of p16, Rb, and p53 proteins in squamous cell carcinomas of the anorectal region harboring human papillomavirus DNA. Mod Pathol 2003;16:692–699.
17 Klaes R, Friedrich T, Spitkovsky D, *et al.* Overexpression of p16(INK4A) as a specific marker for dysplastic and neoplastic epithelial cells of the cervix uteri. Int J Cancer 2001;92:276–284.
18 Sano T, Oyama T, Kashiwabara K, *et al.* Expression status of p16 protein is associated with human papillomavirus oncogenic potential in cervical and genital lesions. Am J Pathol 1998;153:1741–1748.
19 Salcedo M, Taja L, Utrera D, *et al.* Changes in retinoblastoma gene expression during cervical cancer progression. Int J Exp Pathol 2002;83:275–286.
20 Parker MF, Arroyo GF, Geradts J, *et al.* Molecular characterization of adenocarcinoma of the cervix. Gynecol Oncol 1997;64:242–251.
21 Amortegui AJ, Meyer MP, Elborne VL, *et al.* p53, retinoblastoma gene product, and cyclin protein expression in human papillomavirus virus DNA-positive cervical intraepithelial neoplasia and invasive cancer. Mod Pathol 1995;8:907–912.
22 Werness BA, Wang HQ, Chance J, *et al.* p53-independent expression of p21waf1/cip1 in preinvasive and invasive squamous neoplasms of the uterine cervix. Mod Pathol 1997;10:578–584.
23 Li W, Thompson CH, O'Brien CJ, *et al.* Human papillomavirus positivity predicts favourable outcome for squamous carcinoma of the tonsil. Int J Cancer 2003;106:553–558.
24 Rose BR, Thompson CH, Simpson JM, *et al.* Human papillomavirus deoxyribonucleic acid as a prognostic indicator in early-stage cervical cancer: a possible role for type 18. Am J Obstet Gynecol 1995;173: 1461–1468.

25 Resnick RM, Cornelissen MT, Wright DK, *et al.* Detection and typing of human papillomavirus in archival cervical cancer specimens by DNA amplification with consensus primers. J Natl Cancer Inst 1990; 82:1477–1484.
26 de Roda Husman AM, Walboomers JM, van den Brule AJ, *et al.* The use of general primers GP5 and GP6 elongated at their 3′ ends with adjacent highly conserved sequences improves human papillomavirus detection by PCR. J Gen Virol 1995;76:1057–1062.
27 Tieben LM, ter Schegget J, Minnaar RP, *et al.* Detection of cutaneous and genital HPV types in clinical samples by PCR using consensus primers. J Virol Methods 1993;42:265–279.
28 Li W, Thompson CH, Xin D, *et al.* Absence of human papillomavirus in tonsillar squamous cell carcinomas from Chinese patients. Am J Pathol 2003; 163:2185–2189.
29 Sano T, Oyama T, Kashiwabara K, *et al.* Immunohistochemical overexpression of p16 protein associated with intact retinoblastoma protein expression in cervical cancer and cervical intraepithelial neoplasia. Pathol Int 1998;48:580–585.
30 Erber R, Klein W, Andl T, *et al.* Aberrant p21(CIP1/WAF1) protein accumulation in head-and-neck cancer. Int J Cancer 1997;74:383–389.
31 Mantel NHW. Statistical aspects of the analysis of data from retrospective studies of disease. J Natl Cancer Inst 1959;22:719–748.
32 Deacon JM, Evans CD, Yule R, *et al.* Sexual behaviour and smoking as determinants of cervical HPV infection and of CIN3 among those infected: a case–control study nested within the Manchester cohort. Br J Cancer 2000;83:1565–1572.
33 Choo KB, Chong KY. Absence of mutation in the p53 and the retinoblastoma susceptibility genes in primary cervical carcinomas. Virology 1993;193: 1042–1046.
34 Klussmann JP, Gultekin E, Weissenborn SJ, *et al.* Expression of p16 protein identifies a distinct entity of tonsillar carcinomas associated with human papillomavirus. Am J Pathol 2003;162:747–753.
35 Lu DW, El-Mofty SK, Wang HL. Expression of p16, Rb, and p53 proteins in squamous cell carcinomas of the anorectal region harboring human papillomavirus DNA. Mod Pathol 2003;16:692–699.
36 Murphy N, Ring M, Killalea AG, *et al.* p16INK4A as a marker for cervical dyskaryosis: CIN and cGIN in cervical biopsies and ThinPrep smears. J Clin Pathol 2003;56:56–63.
37 Cho NH, Kim YT, Kim JW. Correlation between G1 cyclins and HPV in the uterine cervix. Int J Gynecol Pathol 1997;16:339–347.
38 Clarke B, Chetty R. Cell cycle aberrations in the pathogenesis of squamous cell carcinoma of the uterine cervix. Gynecol Oncol 2001;82:238–246.
39 Saenz Robles MT, Symonds H, Chen J, *et al.* Induction versus progression of brain tumor development: differential functions for the pRB- and p53-targeting domains of simian virus 40 T antigen. Mol Cell Biol 1994;14:2686–2698.
40 Jones DL, Thompson DA, Suh-Burgmann E, *et al.* Expression of the HPV *E7* oncoprotein mimics but does not evoke a p53-dependent cellular DNA damage response pathway. Virology 1999;258:406–414.
41 Fleming I, Cooper JS, Henson DE, *et al.* American Joint Committee on Cancer Staging Manual, 5 ed. Lippincott-Raven:Philadelphia, 1997.