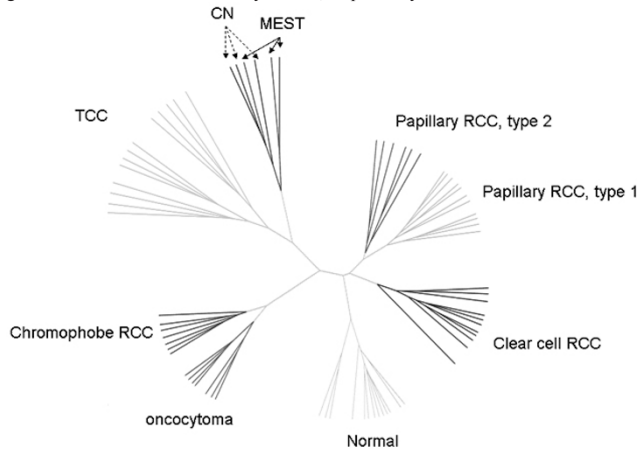


to selected 48 cases of renal carcinomas of various subtypes, 7 oncocytomas and 13 normal kidney. Histological examination focused on the presence of small branching glands, stromal cellularity, ovarian-type stroma, prominent vessels and estrogen and progesterone receptors.

Results: This study included 26 CN and 13 MEST. Patient' age (53.2 vs 53.8 years) and tumor size (6.5 vs 6.8 cm) were similar between CN and MEST. CN predominantly affected women (male/female=2/24), while MEST exclusively affected female. CN and MEST had many similar histological features, including size of cysts, stromal cellularity, presence of ovarian-type stroma, calcification and hemorrhage. ER and PR were positive in 4/5 (80%) and 3/5 (60%) CN, and 5/8 (62.5%) and 5/7 (71.4%) MEST. However, prominent vessels (4/13, 30.8%) and small branching glands (53.8%) were exclusively seen in MEST (p=0.000). Clustering analysis demonstrated that CN and MEST had very similar molecular profiles (Figure 1) that were distinct from other renal tumors. Of differentially expressed genes that best distinguish CN/MEST from other subtypes of kidney tumors, the highest and lowest differentially expressed genes are insulin-like growth factor 2 and carbonic anhydrase II, respectively.



Conclusions: CN and MEST are related lesions as they share similar clinical, histological and molecular characteristics.

887 Choriocarcinoma in the Testis: A Clinicopathological Study of 65 Cases

Z Zhou, EP Sotelo, P Tamboli, B Czerniak, C Guo. MD Anderson Cancer Center, Houston, TX.

Background: Choriocarcinoma is a rare germ cell tumor of the testis. Previous studies have been based on small series or case reports. We aim to study pathological and clinical features in a large series of testicular choriocarcinoma.

Design: We searched our pathology files from 1986 to 2007 and identified 65 patients with choriocarcinoma involving the testis. The H and E slides and clinicopathological data including follow-up were reviewed.

Results: The average age of the patients was 29.5 years (range: 14-71). The mean tumor size was 4.5 cm (range 1.0 to 9.0 cm). Only five of these cases were pure choriocarcinoma, the other 60 cases had choriocarcinoma mixed with other germ cell tumors types. The associated germ cell tumors included embryonal carcinoma (n=48), teratoma (n=42), yolk sac tumor (n=40) and seminoma (n=16). Thirty-one tumors had lymphovascular invasion (LVI). Seventeen tumors did not exhibit any LVI. Based on the percentage of choriocarcinoma in the tumor, the tumors were divided into four arbitrary groups: group I: 0-5% (30); group II: 6-20% (13); group III: 21-50% (10); and, group IV: 51-100% (12). The mean pre-operative β -human chorionic gonadotropin (β -hCG) levels were 2919, 8679, 48366, 244394 (mIU/ml) in Groups I-IV, respectively. Clinical follow-up was available for 49 patients with an average of 39.6 months (range: 1 to 192 months). In cases where choriocarcinoma was less than 50% (Groups I to III), 20 of 40 patients developed distant metastasis. In cases where choriocarcinoma accounted for more than 50% (Group IV), 8 of 9 patients developed distant metastasis. Four patients died of disease at a mean of 18 months (range: 12 to 36); all patients had distant metastases, but the choriocarcinoma component accounted for less than 10% of the total tumor volume in these patients.

Conclusions: Choriocarcinoma is often present as a minor component (<5%) in germ cell tumors. High volume of choriocarcinoma (>50%) in mixed germ cell tumors is associated with high β -hCG level and increased propensity for distant metastasis. However, in our series the four patients who died of disease had a low volume of choriocarcinoma.

Gynecologic

888 Overexpression of Heat Shock Protein (HSP27, HSP70 and HSP90) in Uterine Papillary Serous Carcinoma (UPSC)

BA Adeagbo, T Goldsmith, S Ghamande, K Gu, P Ramalingam. Medical College of Georgia, Augusta, GA; University of Nebraska, Nebraska, NE.

Background: Heat-shock protein (HSP) group is overexpressed in several malignancies and has been studied more extensively in uterine endometrioid adenocarcinomas (EC) than in uterine papillary serous carcinomas (UPSC). Expression of HSP70 correlates with poor prognosis while HSP90 expression is seen in well differentiated EC. This study evaluates HSP expression HSP27, HSP70 and HSP90 in UPSC.

Design: We identified cases diagnosed as UPSC or mixed EC and UPSC from 1996-2006. We included 7 EC and 6 clear cell carcinoma (CCC) as controls. 17 cases consisted predominantly of UPSC with only 1 mixed EC and UPSC. Immunohistochemical stains were performed using monoclonal antibodies to HSP27 (Abcam), HSP70 (Abcam) and HSP90 (Abcam) in all 31 cases. Staining was graded based on the intensity and percentage of tumor cells positive as negative (0), 1+, 2+ or 3+.

Results: Immunohistochemical stain results for HSP27, HSP70 and HSP90 are summarized in table 1.

Immunostains	Stain intensity	Uterine papillary serous carcinoma (UPSC)	Clear cell carcinoma	Endometrioid carcinoma
HSP27	0	1(5.6%)	1(16.6%)	0(0%)
HSP27	1	1(5.6%)	0(0%)	1(14.3%)
HSP27	2	6(33.3%)	0(0%)	3(42.9%)
HSP27	3	10(55.6%)	5(83.3%)	3(42.9%)
HSP70	0	0(0%)	0(0%)	0(0%)
HSP70	1	0(0%)	0(0%)	0(0%)
HSP70	2	0(0%)	0(0%)	0(0%)
HSP70	3	18(100%)	6(100%)	7(100%)
HSP90	0	2(11.1%)	0(0%)	3(42.9%)
HSP90	1	8(44.4%)	2(33.3%)	1(14.3%)
HSP90	2	8(44.4%)	4(66.7%)	3(42.9%)
HSP90	3	0(0%)	0(0%)	0(0%)

HSP27 was positive in 17 of 18 UPSC (94.4%); 5 of 6 CCC (83.3%), and 7 of 7 EC (100%). HSP70 was strongly positive in all cases of UPSC, EC and CCC. HSP90 showed mostly 1-2+ positivity in 16 of 18 UPSC (89%), 4 of 7 EC (57%) and 6 of 6 CCC (100%).

Conclusions: Our study found overexpression of HSP27 and HSP70 and comparatively weak HSP90 staining in UPSC similar to that reported in poorly differentiated endometrial carcinomas. The overexpression of HSPs in UPSC could be a potential target for therapy with anti-HSP inhibitors.

889 Serous and Endometrioid Components of Mixed Endometrial Adenocarcinoma Show Similar Immunostaining Profiles

RA Albarnai, A Alkushi, CB Gilks. University of British Columbia, Vancouver, BC, Canada; King Fahad National Guard Hospital, Riyadh, Saudi Arabia.

Background: Mixed endometrial adenocarcinoma is a tumor with two or more cell types present with each comprise at least 10% of the tumor. Mixed adenocarcinomas account for approximately 10% of cases of endometrial adenocarcinoma.

Design: To determine whether there are consistent differences in immunostaining between the endometrioid and serous components of mixed endometrial adenocarcinoma, and whether the components of mixed carcinomas are similar to pure endometrioid or serous carcinoma, ten cases of mixed endometrial adenocarcinoma with endometrioid and serous components were stained for PTE, ER, p53, and ki-67. The results were compared to the staining of pure endometrioid (n=139) and serous (n=11) carcinomas of the endometrium.

Results:

Table 1- staining of endometrioid (EM) and serous(S) components of mixed endometrioid adenocarcinoma

Case	ER		P53		PTEN		Ki-67	
	EM	S	EM	S	EM	S	EM	S
1	2	2	+	+	-	-	62%	64%
2	0	0	-	-	-	-	18%	72%
3	0	0	-	-	-	-	35%	58%
4	2	0	-	+	-	-	33%	55%
5	1	0	-	+	-	-	52%	42%
6	1	1	-	-	+	+	28%	56%
7	2	0	-	-	-	-	35%	61%
8	2	0	-	-	-	-	25%	49%
9	0	0	-	+	+	+	26%	62%
10	0	0	+	+	+	+	50%	44%

PTEN immunostaining was significantly less common in the serous component of mixed endometrial adenocarcinoma (3/10) than in pure serous adenocarcinoma (10/11, p=0.007). The staining of the endometrioid and serous components of mixed adenocarcinomas were otherwise not significantly different than pure endometrioid and serous carcinomas, respectively.

Conclusions: The immunophenotype of endometrioid and serous components of mixed endometrial adenocarcinoma are similar in most cases, with the notable exception of high proliferative index being characteristic of the serous component. The loss of PTEN staining in the serous component is significantly different from pure serous carcinoma, and similar to that of pure endometrioid carcinoma, where loss of PTEN is a common early event during. This suggests that the serous component of mixed endometrial adenocarcinoma arises through progression from the endometrioid component.

890 Clinicopathologic Characterization of Myxoid Mesenchymal Neoplasms of the Uterus

V Anandan, C Moosavi, M Miettinen. Armed Forces Institute of Pathology, Washington, DC.

Background: Relatively few data exist on myxoid neoplasms of the uterus, and diagnostic criteria suggested for myxoid leiomyosarcomas are based on relatively small series. Little immunophenotypic data exist on these neoplasms.

Design: In this study, we evaluated 30 uterine myxoid neoplasms variably designated as myxoid leiomyomas, smooth muscle tumors, or leiomyosarcomas. Sixteen otherwise typical leiomyomas with minute myxoid foci and 7 inflammatory myofibroblastic

tumors were excluded from the study. Immunohistochemical stains were performed, and assessed specifically for the myxoid component only.

Results: The median age of the patients was 44 years (range, 19-78 years). All tumors had extensive myxoid matrix comprising 40-95% of tumor area. Tumor size varied from 3.5-17.5 cm (median, 10 cm). Six tumors were intracavitary or protruded through the cervix, and the others were myometrial. Mitotic rate varied from 0-33 per 10 HPFs, and moderate atypia was present in 11 cases and severe atypia in 4 cases. Coagulative necrosis was present in 8 tumors. Immunohistochemically, only a portion of cases showed definitive smooth muscle differentiation in the myxoid component, including two cases with epithelioid and myxoid morphology. 12/17 cases studied were positive for SMA, 8/17 for desmin, 1/14 for caldesmon, and 5/13 for estrogen receptor. Nine of 19 patients with follow-up either developed metastases or died of tumor. These included 5/8 patients with tumor necrosis, 4/11 patients without tumor necrosis, and 4/7 patients with mitotic 1-5/10 HPFs, and 5/6 patients with mitotic activity >5/10 HPFs. However, all 6 patients with no detectable mitotic activity with follow-up data had a metastasis-free survival, or died of unrelated causes. Metastasis rate by degree of atypia was: 0/5 for no atypia, 2/5 for mild, 5/6 for moderate, and 2/3 for severe atypia.

Conclusions: Myxoid uterine neoplasms, excluding typical leiomyomas with myxoid foci and inflammatory myofibroblastic tumors, have metastatic risk even with mitotic rate of 1/10 HPFs. Degree of atypia and presence of tumor necrosis have a vague correlation with tumor behavior that cannot be fully elaborated on this small material. Myxoid uterine mesenchymal tumors show variable degree of smooth muscle differentiation, and often show ER-positivity indicating their composition of hormonally sensitive stromal cells.

891 Endometrial Carcinoma – Is the Staging System Accurate?

H Arabi, R Ali-Fehmi, S Bandyopadhyay, L Fathalla, D Thirabanjasak, A Munkarah, R Morris, E Silva. Wayne State University, Detroit, MI; MD Anderson Cancer Center, Houston, TX.

Background: Endometrial cancer is the most common gynecological cancer in the United States. The stage at diagnosis is one of the most important predictors of survival and treatment options. In this study, we compared cases of stage IC (invasion into outer half of myometrium) with stage II (cervical involvement, IIA: epithelia only, and IIB: stroma). It will be expected that stage IIB tumors will be of higher grade, deeply invasive and more aggressive neoplasms.

Design: We searched the endometrial carcinoma database from Wayne State University and Karmanos Cancer Institute pathology department over a period of 5 years (1995-2000). A total of 60 cases were recruited into this study including 29 from stage IC and 31 from stage IIA and IIB where staged in a similar way. Histological and clinical parameters were also recorded including patient's age, tumor size, FIGO grade, angiolymphatic invasion, follow up and incidence of recurrence.

Results: A total of 60 cases were included in this study (29,IC; 21, IIA; and 10, IIB). The mean age of the 3 groups ranged from 62 to 67 years. The mean maximum tumor dimension was 4.0 cm in stage IC, 4.2 cm in stage IIA and 3.0 cm in stage IIB. The grade of the tumor was predominantly low to intermediate in all three stages with only a minority of the cases being FIGO grade 3. The depth of myometrial invasion and angiolymphatic invasion was noted to be maximum in the stage IC group compared to the other groups. Also, no recurrence was noted in the stage IIB group while 2 of 29 cases in the stage IC group and 3 of 21 cases in the stage IIA group recurred.

	Result		
	STAGE 1C (29)	STAGE 2A (21)	STAGE 2B (10)
MEAN AGE	66	62.4	67
TUMOR SIZE (MAX DIMENSION; CM)	4.0	4.2	3.0
FIGO 1-2	27/29 (93.1%)	19/22 (89.4%)	7/9 (77.8%)
DEPTH OF MYOMETRIAL INVASION (CM.)	1.3	0.34	1.05 CM
ANGIOLYMPHATIC INVASION	13/29 (44.8%)	6/21 (28.6%)	4/10 (40%)
MEAN F/U (MONTHS)	36	18	20
RECURRENCE	2/29 (6.9%)	3/21 (14.3%)	0/10 (0%)

Conclusions: 1. There was no difference in the tumor grade, vascular invasion or tumor size between stages IC, IIA and IIB. 2. Patients with stage IIB had no recurrence while in stage IC 7% recurred, and in stage IIA 14% recurred. 3. The current staging system of endometrial cancer may need to be re-evaluated.

892 Ovarian Cancer Associated with Endometriosis Carries an Improved Prognosis

H Arabi, S Bandyopadhyay, D Thirabanjasak, A Munkarah, V Schimp, R Morris, R Ali-Fehmi. Wayne State University, Detroit, MI.

Background: Epidemiological and histological data have revealed an association between Endometriosis and ovarian carcinoma. The aim of this study is to evaluate the clinical features and survival outcomes of ovarian carcinoma patients who had associated pelvic endometriosis.

Design: Using our institutional database we identified 226 cases of ovarian carcinoma treated between 1992 and 2002 and on whom pathological specimens were available. Patient's information and tumor characteristics were collected based on institutional database and histopathology review. Survival data were retrieved from patient's charts and SEER database. Patients were categorized as having ovarian carcinoma associated with endometriosis (Oca-E) or ovarian cancer without endometriosis (Oca). Statistical analysis and survival data were calculated using multi-variant analysis, Kaplan-Meier method & Cox regression (after adjusting for other parameters).

Results: Table 1 compares the two patient subpopulations. Patients with Oca-E had a tendency to be younger than Oca. The most common histology seen in Oca-E was serous (54.8%) followed by clear (21.4%), endometrioid (14.3%), and mucinous (9.5%) (p=0.00). Oca-E patients had a higher chance of having early stage disease and better overall median survival.

Table 1

	Ovarian Carcinomas associated with endometriosis (n=42)	Ovarian cancer without endometriosis (n=184)	P value
Mean age at Dx in Years (SD)	53.86 (14)	58.39 (14)	0.060
Race			
	Caucasian 35 (83.2%)	130 (70.7%)	0.123
	African-American 7 (16.7%)	54 (29.3%)	
Stage			
	I & II 22 (52.4%)	46 (25.3%)	0.001
	III & IV 20 (47.6%)	136 (74.7%)	
Status			
	Alive 30 (71.4%)	88 (47.8%)	0.006
	Deceased 12 (28.6%)	96 (52.2%)	
Type			
	Serous 23 (54.8%)	148 (80.4%)	0.000
	Clear 9 (21.4%)	4 (2.2%)	
	Mucinous 4 (9.5%)	27 (14.7%)	
	Endometrioid 6 (14.3%)	5 (2.7%)	
Grade			
	Borderline 9 (21.4%)	39 (21.4%)	0.101
	LG 7 (16.7%)	12 (6.6%)	
	HG 26 (61.9%)	131 (72.0%)	
Median Survival in Month	199	45	0.021
Mean Survival in Months (SD)	136.8 (16.5)	82.3 (10)	0.021

Conclusions: 1- Ovarian carcinomas associated with endometriosis (Oca-E) seems to have a different biology and a better prognosis than carcinomas without endometriosis. 2- Clear Cell and Endometrioid carcinomas are seen in higher frequency in association with endometriosis; however, most of the Carcinomas seen in endometriosis patients are serous.

893 Follow-Up Findings for Women with hrHPV DNA Positive ASC-US Pap Test Results in a Large Clinical Practice

HB Armah, RM Austin, D Dabbs, C Zhao. Magee-Womens Hospital, UPMC, Pittsburgh, PA.

Background: Reflex hrHPV DNA testing is preferred for women with ASC-US Pap results. Women who test positive for hrHPV DNA are recommended for colposcopic evaluation. However, data from large clinical practices are limited. In this study, we analyzed subsequent follow-up data from patients who had an initial interpretation of ASC-US on ThinPrep Pap tests (TPPT) and positive hrHPV DNA test results. We also assessed the effect of presence or absence of an adequate TZ/ECS in TPPT on the follow-up biopsy diagnosis.

Design: The computerized records of our hospital were searched for cases that were diagnosed as ASC-US in TPPT and that also had positive hrHPV DNA testing from July 1, 2005 and March 31, 2007. Histologic follow diagnosis, the age groups of the women, and the presence or absence of TZ/ECS in TPPT were analyzed with Chi-Square test.

Results: A total of 4273 women had TPPT with ASC-US interpretations and also had positive hrHPV DNA testing. Total histologic CIN 2-3 and CIN1 rates among 2192 women that had subsequent biopsies (overall follow-up rate of 51.3%) were 5.1% and 43.6%, respectively. Average follow-up period was 7.5 months (1 to 20 months). CIN 2-3 rates for women with positive HPV ASC-US TPPT with and without TZ/ECS were 5.0% and 5.4%, respectively (p=0.736). CIN 1 rates for women with positive HPV ASC-US TPPT with and without TZ/ECS were 43.6% and 43.5%, respectively (p=0.980).

Conclusions: 1. Our data support the recommendation that women who have ASC-US Pap test results and positive hrHPV DNA results should be referred for colposcopic evaluation; however, the risk of CIN2-3 in this population was significantly lower than reported in some clinical trials. 2. Presence or absence of a TZ/ECS had no statistically significant relationship with subsequent biopsy diagnosis of CIN in all age groups. 3. The incidence of histologic CIN in women with hrHPV positive ASC-US Pap tests were similar across all age groups.

Table 1: Comparison of CIN in Women with Positive hrHPV and ASC-US TPPT with and without TZ/ECS

Age	F/U	TZ present CIN2-3 (%)	CIN1(%)	F/U	TZ absent CIN2-3 (%)	CIN1(%)
10-	258	12 (4.7)	103 (39.9)	44	3 (6.8)	18 (40.9)
20-	1079	59 (5.5)	488 (45.2)	189	10 (5.3)	89 (47.1)
30-	317	14 (4.4)	139 (43.8)	35	2 (5.7)	16 (45.7)
40-	146	6 (4.1)	56 (38.4)	30	2 (6.7)	10 (33.3)
50-	50	2 (4.0)	20 (40.0)	25	1(4.0)	8 (32.0)
60-	11	0	5 (45.5)	8	0	3 (37.5)
Total	1861	93 (5.0)	811 (43.6)	331	18 (5.4)	144 (43.5)

894 Clinicopathologic and Immunohistochemical Analysis of Mixed Epithelial Ovarian Tumors with a Clear Cell Carcinoma Component

H Asad, RA Soslow. Memorial Sloan-Kettering Cancer Center, New York, NY.

Background: The association of clear cell (CC) and endometrioid (EC) ovarian carcinomas is well known, but the occurrence of CC in the context of other types of epithelial ovarian neoplasms is poorly understood. Recent data have demonstrated that serous carcinomas containing foci resembling clear cell carcinoma are in most cases pure serous carcinomas. This study focuses on CCs associated with tumors diagnosed as ovarian mucinous neoplasms and evaluates the usefulness of hepatocyte nuclear factor 1β (HNF) immunohistochemistry (IHC) for the distinction of CC and mimics thereof.

Design: All CCs associated with tumors diagnosed between 1997 and 2006 as ovarian mucinous neoplasms were retrieved from our institutional files (n=7, 4 of which were consultation cases). 2 additional cases were reclassified as mixed epithelial borderline tumor (MEBT) associated with endometrioid carcinomas showing prominent secretory features and squamous metaplasia with glycogenated cytoplasm. Tissue microarrays (TMAs) representing 87 ovarian carcinomas (including all ovarian carcinoma subtypes and 8 CCs) and 4 of the study cases were evaluated immunohistochemically for HNF expression. Clinical data were abstracted from the medical record.

Results: Patients' ages ranged from 29-65 years (mean 46) and the clinical presentation were non-specific. One tumor was stage IA, 3 IC, 2 IIB and 1 IIIA. 6 CCs, all papillary, were associated with MEBT and 1 with an endocervical-type mucinous cystadenoma. 5 patients had coexisting endometriosis. The MEBTs showed admixtures of endocervical-

type mucinous, ciliated, eosinophilic and endometrioid cells, with endocervical-type mucinous cells predominating in most cases. Only CCs in the TMA showed diffuse, strong nuclear expression of HNF, as did the CC components of the 4 study cases evaluated. In addition, one mucinous borderline tumor in the TMA and scattered endocervical-type mucinous cells in MEBTs weakly expressed HNF. Clinical follow-up (4 months to 8 years) was available for 5 study patients, with 2 suffering recurrences. **Conclusions:** True CCs can rarely be associated with ovarian tumors containing a predominance of endocervical-type mucinous cells. The typical patient is younger than 50 years and has endometriosis, suggesting a kinship between MEBTs, pure endometrioid neoplasms and CCs. Accurate diagnosis can be enhanced using HNF IHC, which, when diffuse and strong, appears specific for CC. Pitfalls include HNF expression in endocervical-type mucinous cells.

895 Diagnostic Utility of Mammaglobin in Lesions of the Uterine Cervix

M Assaad, CN Otis, S Marconi, L Pantanowitz. Baystate Medical Center/Tufts University School of Medicine, Springfield, MA.

Background: Mammaglobin (MAM), a glycosylated peptide found in human breast tissue, has been shown in limited cases to be expressed in endometrial but not endocervical adenocarcinoma. The aim of this study was to systematically determine the diagnostic utility of MAM immunohistochemistry to help differentiate in-situ, primary and secondary adenocarcinoma of the uterine cervix.

Design: We selected 57 cases with formalin-fixed, paraffin-embedded routinely processed cervical tissue including (i) 18 cases with normal histology, (ii) 17 benign lesions (cervicitis, nabothian cysts, tubal metaplasia, tunnel clusters, microglandular hyperplasia, endosalpingiosis, mesonephric hyperplasia, Arias-Stella reaction, endometriosis, fallopian tube prolapse), (iii) 7 with endocervical adenocarcinoma in-situ (AIS), (iv) 8 endocervical adenocarcinomas (including 1 clear cell carcinoma), and (v) 7 endometrial adenocarcinomas (2 invading cervical stroma, i.e. pT2b). Immunohistochemistry was performed with mouse anti-human MAM (clone 304-1A5, 1:300 dilution, Dako). Immunoreactivity localization and intensity (graded 0-4) were recorded.

Results: MAM immunoreactivity was present in 20/35 (57%) normal/benign cases, 4/7 (57%) endometrial adenocarcinomas, and 1/8 (13%) endocervical adenocarcinomas. All cases of AIS were negative for MAM staining. MAM immunoreactivity in normal and benign cervical lesions such as endocervical cysts and tubal metaplasia was cytoplasmic, focal and ranged from low (1+) to high (4+) intensity. Immunoreactive endometrial adenocarcinomas were all strongly positive (3 and 4+). The single positive endocervical adenocarcinoma, with villoglandular features, was focal and only weakly (2+) immunoreactive for MAM.

Conclusions: Mammaglobin is expressed in normal endocervical glands, including several benign endocervical lesions. However, MAM expression is focal, which needs to be taken into consideration when interpreting biopsy material. MAM expression in the cervix appears to be lost with malignant transformation to AIS or endocervical adenocarcinoma. By comparison, MAM is strongly positive in immunoreactive endometrial adenocarcinomas. Therefore, inclusion of MAM into an immunohistochemical panel is recommended to differentiate endocervical and endometrial adenocarcinoma.

896 A Novel Immunohistochemical Assay (ProEx™ C) Aids in the Distinction of Cervical Adenocarcinoma In Situ and Adenocarcinoma from Benign Glandular Mimics

D Aximu, TJ Colgan, A Azad, R Ni, SS Nanji. Mount Sinai Hospital, Toronto, ON, Canada.

Background: The histopathologic distinction of cervical adenocarcinoma in situ (AIS) and invasive adenocarcinoma (AC) from some benign endocervical lesions can be challenging. The ProEx™ C antibody reagent targets nuclear proteins (microsome maintenance protein 2, MCM2 and topoisomerase II alpha, TOP2A) which are over expressed during the aberrant s-phase induction of HPV infected and neoplastic cells. An immunohistochemical (IHC) study using the ProEx™ C of a variety of neoplastic and non-neoplastic glandular lesions was performed to identify if this reagent would aid in the histological diagnosis of glandular lesions of the cervix.

Design: ProEx™ C IHC staining was performed on sections from formalin fixed, paraffin embedded tissue of 65 cervical tissues including 48 non-neoplastic cervixes [normal (n=10), microglandular hyperplasia (n=10), tubal metaplasia (n=11), cervical endometriosis (n=7), reactive endocervix (n=10)] and 17 cervixes with glandular malignancy [AIS (n=12) and AC (n=5)]. Immunoreactivity was scored using both intensity (1=none, 2=mild, 3=moderate, 4=marked) and prevalence of staining (1=none, 2<=1%, 3=1-10%, 4=11-33%, 5=34-66%, 6=67-100%) using the Allred method. The total score (intensity plus prevalence) was derived for each diagnostic category, and a Chi square analysis performed to identify significant variances in IHC staining between AIS and AC and each of the 5 benign lesions.

Results: With the exception of cervical endometriosis and repair cases, ProEx™ C immunostaining was generally scanty in benign endocervical lesions. AIS cases showed strong and prevalent IHC staining with ProEx™ C which was significantly different than each of the 5 benign and reactive glandular lesions (p < .01 in all cases). A similar trend was seen in AC cases.

Conclusions: ProEx™ C reagent may be an adjunctive testing tool in the histopathologic diagnosis of both AIS and AC, particularly in cases with small biopsies or foci.

897 Defining the Cut-Point between Low- and High- Grade Ovarian Serous Carcinomas with Nuclei Grade: A Clinicopathological and Molecular Genetic Analysis

A Ayhan, RJ Kurman, R Vang, S Logani, IM Shih. Johns Hopkins Medical Institutions, Baltimore, MD; Emory University School of Medicine, Atlanta, GA; Seirei Mikatahara General Hospital, Hamamatsu, Japan.

Background: Recently, it has been proposed that the current three-tier (well, moderately and poorly differentiated) system for grading ovarian serous carcinomas be replaced by a two-tier (low-grade and high-grade) system based on clinical, morphological and molecular studies. This system is primarily based on the nuclear grade. However, the morphological distinction between high-grade and low-grade carcinomas can be at times difficult, especially for those carcinomas with nuclear features that are intermediate between conventional high- and low-grade carcinomas. For example, some tumors have grade 2 nuclei that are of intermediate size and are more uniform as compared to typical high-grade neoplasms. On the other hand, these tumors with grade 2 nuclei are slightly larger and more atypical than the classical low-grade carcinomas.

Design: In this study, we analyzed six serous carcinomas displaying these intermediate features corresponding to what would be classified as moderately differentiated (nuclear grade 2) carcinomas for mutations of *TP53*, *KRAS*, *BRAF* and *ERBB2* genes together with their clinicopathological features.

Results: Our results demonstrated that all the cases were at high stage at the time of diagnosis and were of poor clinical outcome in all informative cases. Molecularly, none of the cases showed mutations in *KRAS*, *BRAF* and *ERBB2* genes which characterize most low-grade serous carcinomas. In contrast, all cases contained non-synonymous *TP53* mutations which represent the molecular genetic hallmark of high-grade serous carcinomas. The architectural features including solid growth pattern (so called "poorly differentiated"), papillary appearance (so called "moderately differentiated") or micropapillary/macropapillary structures (so called "well-differentiated") are not useful criteria distinguishing low-grade from high-grade serous carcinomas.

Conclusions: We have analyzed a series of ovarian serous carcinomas with grade 2 nuclei to delineate their relationship to the low-grade and high-grade serous carcinomas. Our findings that ovarian serous carcinomas with grade 2 nuclei shared clinical and molecular features to high-grade serous carcinomas support the view of two-tiered grading system for ovarian serous carcinomas.

898 Open Tumor Rings in Clear Cell Carcinoma: Role in Differential Diagnosis with Ovarian Yolk Sac Tumor and Serous Borderline Ovarian Tumor

H Bailey, JT Rabban. UCSF, San Francisco.

Background: Clear cell carcinoma (CCC) of the gynecologic tract is an aggressive, often chemotherapy-resistant tumor that may mimic serous borderline ovarian tumor (SBOT) and yolk sac tumor (YST). Open tumor rings (OTR) are free-floating round empty rings of tumor cells devoid of a central fibrovascular core or stroma. OTR have been proposed a diagnostic marker of CCC (Clement PB and Young RH. *Adv Anat Pathol* 2004; 11:117-142) but a formal study has not been conducted to date. This study defined the incidence of OTR in CCC, SBOT, and YST, with an emphasis on its association with the specific tumor growth patterns present in each tumor type.

Design: OTR were defined as free-floating round rings of tumor cells that were completely devoid of stroma or cells within the ring. The presence of vessels, fibroblasts or any other cells or stromal matrix within the ring excluded it from study. A total of 45 cases of CCC were examined (28 ovarian, 17 uterine). Growth patterns were categorized as papillary, solid, tubulocystic or mixed. Twelve SBOT were examined as well as 32 ovarian YST, which were categorized as to whether papillary growth pattern was present or not.

Results: OTR were identified in 15/45 (33%) CCC. They were present only in areas of papillary growth, not solid or tubulocystic. In most cases, several OTR were present on each slide. Most were about 0.1 mm in diameter but ranged up to 0.4 mm. Three of 12 (25%) SBOT contained OTR. In contrast to CCC, these OTR were generally fewer in number per slide, were less uniformly round in shape, and did not demonstrate high grade nuclear atypia. Many SBOT contained free-floating tumor rings with a fibroblastic or fibrovascular core, which we did not define as OTR. Only 2/32 YST contained OTR. They were few in number and present only in papillary areas. Abundant mimics of OTR were present in papillary YST but these all contained fibrovascular cores or were part of Schiller-Duval structures.

Conclusions: Open tumor rings are common in papillary patterns of clear cell carcinoma however they may also be present in some papillary patterns of yolk sac tumor and SBOT. Attention to nuclear atypia and the presence of other distinctive tumor growth patterns is required to avoid misinterpreting the presence of open tumor rings as a sole diagnostic criterion for clear cell carcinoma.

899 Role of Microsatellite Instability in Endometrial Carcinogenesis

S Bandyopadhyay, H Arabi, D Thirabanjasak, A Munkarah, R Morris, R Ali-Fehmi. Wayne State Univ-Harper Hospital, Detroit, MI; Wayne State University.

Background: Defective DNA mismatch repair is frequently present in 20-45% of sporadic endometrial carcinoma and its presence is evaluated as by looking for Microsatellite Instability (MSI). Complex atypical hyperplasia is a well known premalignant lesion for endometrial carcinoma. The aim of this study is to evaluate the significance of the presence of MSI in a series of cases of complex atypical hyperplasia by IHC.

Design: From our institutional database, we retrieved 40 cases diagnosed with complex atypical hyperplasia (CAH), 53 cases of endometrial carcinoma arising in a background of complex atypical hyperplasia (CA+CAH) and 198 cases of endometrial carcinoma, endometrioid type (CA). The FIGO grade (FIGO 1-3) of the endometrioid carcinoma cases was also noted. MSI status was evaluated based on presence or absence of strong

nuclear staining for MLH1, MSH2 and MSH6 in >90% of the epithelium, using IHC. The case was considered positive for MSI when at least 2 of 3 markers were negative. Adjacent normal epithelium and lymphocytes served as internal positive control.

Results: MSI was noted in 11 (27.5%) cases of CAH, 14 (26.4%) cases of CA + CAH, and 47 (23.7%) cases of CA. In CA + CAH cases, MSI was present in both hyperplasia and carcinoma components. In a subset of these cases, the staining intensity and percentage decreased from areas of CAH to areas of CA. Overall MSI was present in 72 cases and resulted from the combined loss of MLH1 & MSH6 in 44 (61.1%) cases, MLH1 & MSH2 in 6 (8.3%) cases, MSH2 & MSH6 in 7 (9.7%), and loss of all 3 markers in 15 (20.8%) cases. There was no difference in the presence of MSI when analyzed by FIGO grade.

CATEGORIES	MSI (%)	MSI in CAH, CAH+CA and CA				
		MLH1+ MSH6 *	MLH1 +MSH2 + MSH6 *	MLH1+ MSH2 *	MSH2+ MSH6 *	
CAH (40)	11 (27.5)	1	5	0	5	
CAH +CA (53)	14 (26.4)	8	4	2	0	
CA (198)	47 (23.7)	35	6	4	2	
		72	44 (61.1%)	15 (20.8%)	6 (8.3%)	7 (9.7%)

* Loss of nuclear expression

Conclusions: MSI appears to be an early molecular event in the development of endometrial cancer. This may be related to its presence in the precancerous stage and maintenance through carcinogenesis. In the majority of cases, MSI is caused by the combined loss of MLH1 and MSH6 expression. Additional prospective and molecular studies would be necessary to understand the prognostic significance of this marker in the development of endometrial cancer.

900 Endometrial Cancer Diagnosed in Young Patients Is Not Always a Low-Risk Cancer

S Bandyopadhyay, H Arabi, D Thirabanasak, MR Quddus, WD Lawrence, R Ali-Fehmi. Wayne State Univ-Harper Hospital, Detroit, MI; Women and Infant's Hospital/The Warren Alpert Medical School of Brown University, Providence, RI.

Background: Endometrial cancer does occur in younger patients, generally with a history of hormone dysfunction. Some of these patients desire conservative management and fertility preservation. The goal of this study was to evaluate the tumor characteristics in endometrial cancer patients 35 years and younger.

Design: A total of 37 cases were recruited for this study after review of the endometrial carcinoma database at Wayne State University and Women & Infants Hospital/The Warren Alpert Medical School of Brown University from 1995 to 2002. Tumor characteristics including grade, stage, vascular invasion, association with complex atypical hyperplasia (CAH) were evaluated in the D&C as well as in the hysterectomy specimen.

Results: The median age of our series was 32 years (range: 24-35 years). Of 37 cases, 29 (78.4%) cases were Stage I (1A: 14; 1B: 12; 1C: 3). Five patients (13.2%) were Stage II, one (2.7%) was stage III and two (5.4%) were Stage IV. Twenty five cases were grade 1 (67.6%); 9 (24.3%) cases were grade 2; 3 (8.1%) cases were grade 3. Three high stage carcinomas cases (\geq stage IC) were associated with low FIGO grade (Grade 1). Nineteen (51.3%) cases of endometrial carcinoma arose in a background of CAH. Prior biopsy results were available in 30 cases. The results were upgraded in the subsequent hysterectomy specimen in 6 (20%) cases (4 cases: CAH to FIGO 1, 1 case: FIGO1 to FIGO 2 and 1 case: FIGO 2 to FIGO 3). One case of recurrence was present among this subset. Vascular invasion was present in 5/37 (13.5%) cases, of which 2 cases were FIGO 1.

Conclusions: 1. Our study (patient population 35 years and younger), had substantial proportion of patients with high stage (29.7%) and high grade (24.3%) disease. Such findings raise concerns regarding the use of conservative management with fertility sparing in these patients. 2. Future studies need to focus on identifying pathologic and biologic markers that can help identify low risk disease and direct treatment decisions.

901 Aurora Kinase-B Expression Is Significantly Associated with Disease Recurrence in Ovarian and Primary Peritoneal Serous Papillary Cancers

A Bargaje, G Venkataraman, A Salhadar, R Hammadeh, R Potkul, S Alkan. Loyola University Medical Center, Maywood, IL.

Background: Papillary serous carcinoma is the most common ovarian malignancy and has a poor prognosis. Novel treatment strategies are being developed. Recently, expression of aurora kinases has been studied in numerous cancers. Aurora kinases are members of serine/threonine kinase superfamily and any alteration could result into chromosome instability and malignant transformation. Expression of aurora B has not been studied in ovarian cancers so far. We studied the expression of aurora kinase proteins A and B in serous tumors and analyzed in-vitro effect of pan-aurora kinase inhibitor on ovarian cancer cell line.

Design: The immunohistological expression of aurora kinases A and B was studied on tissue microarray blocks (total n=55) in ovarian serous papillary carcinoma (Group I, n=28), non-ovarian serous papillary carcinomas including primary peritoneal and uterine papillary serous types (Group II, n=17), and ovarian serous borderline and benign tumors (Group III, n=10). The weighted H-score was calculated to evaluate immunopositivity. The in-vitro effect of aurora kinase inhibitor, VE465 on ovarian carcinoma cell line, OVCAR429 was investigated. Kruskal-Wallis test and Cox proportional hazard modeling were performed using STATA 9.2 (StataCorp, College Station, TX) to correlate expression of these proteins with clinical parameters and recurrence data.

Results: The cytoplasmic expression of aurora A was noted in 86% of cases in group I and 100% of cases in groups II and III. The cytoplasmic aurora B staining was seen in 100% of all cases. In univariate and multivariate Cox analysis, only cytoplasmic aurora B expression was significantly associated with disease recurrence (HR=1.004; p=0.043). Age, tumor stage, grade, aurora A expression were not shown to be associated

with recurrence in this study. Cytotoxic studies with MTS assay indicated significant cytotoxicity to OVCAR429 cells after 24 hours of treatment (median IC₅₀=400-500ng) using VE465 in the dose range of 0-1000ng.

Conclusions: Over expression of aurora kinases A and B was observed in the cytoplasm of majority of ovarian, and primary peritoneal serous papillary cancer cells along with ovarian benign and borderline serous tumor cells. The ovarian cancer cell line showed cytotoxicity with aurora inhibitor indicating targeted therapy may offer significant survival benefit in ovarian serous cancer patients.

902 Occult Metastatic Breast Carcinoma and Its Morphologic Mimics in Risk Reducing Salpingo-Oophorectomies in Women with Breast Cancer

MJ Barnes, BB Crawford, CB Powell, L Chen, CJ Zaloudek, JT Rabban. UCSF, San Francisco.

Background: Rare cases of occult metastatic breast carcinoma in the ovary have been reported in breast cancer patients undergoing risk-reducing salpingo-oophorectomy (RRSO). Several neoplastic and non-neoplastic ovarian lesions may mimic metastatic breast cancer, particularly lobular breast carcinoma. They include hilar cell proliferations, stromal hyperthecosis, ectopic adrenal rests, adenomatoid tumor and early ovarian or tubal carcinoma. We defined the incidence of occult metastatic breast cancer and its mimics in 78 women with breast cancer undergoing RRSO.

Design: RRSO specimens from 78 women with breast cancer (76 ductal, 2 lobular) were evaluated by microscopic evaluation of the entire ovaries and fallopian tubes in serial section. None were clinically suspected to have malignant ovarian pathology. BRCA mutations were present in 42/78 women; the remainder were untested. In cases with carcinoma, p53, WT-1, and CA125 immunostains were used in conjunction with morphology to define primary ovarian/tubal origin versus breast origin. Negative keratin immunostaining was used to confirm suspicious hilar or steroid cell proliferations or stromal hyperthecosis that mimicked breast cancer cells.

Results: Occult metastatic breast cancer was found in 1/78 RRSO, consisting of 2 bland, mitotically inactive tumor cell aggregates (1.3 mm) resembling steroid cell nodules or histiocytes. The primary breast cancer was lobular. Occult ovarian serous carcinoma (11 mm) was found in 1/78. Fallopian tube serous carcinoma (up to 12 mm) was found in 2/78 and tubal dysplasia in 1/78. Hilar cell nests, most of which were multifocal and under 1 mm in size, were notable in 29/78; 4 mimicked breast cancer because of larger size (up to 5 mm), perineural involvement, or mild nuclear atypia. No mitoses were seen in hilar cell nests. Stromal hyperthecosis was notable in 6/78. Adrenal cell rests were in 2/78. Other primary ovarian neoplasms included struma ovarii (1), Brenner tumor (1), sex cord tumor with annular tubules (1), cystadenoma (3) fibroma (4) and adenomatoid tumor of fallopian tube (1).

Conclusions: Occult metastatic breast cancer is rare in RRSO specimens. More common are its mimickers, including hilar cell proliferations, stromal hyperthecosis and adrenal rests. Keratin immunostaining can be helpful, especially if the primary breast tumor shows lobular features.

903 KAI-1 Expression as a Predictor of Metastatic Potential in Squamous Cell Carcinoma of the Uterine Cervix

JE Barroeta, MR Quddus, M Lomme, CJ Sung, MM Steinhoff, WD Lawrence. Women & Infants Hospital of RI, Providence, RI.

Background: KAI-1 protein is a member of the transmembrane-4 superfamily, encoded in chromosome 11p11.2. Initially proposed as a metastasis suppressor gene in prostatic carcinoma, recent studies have described decreased expression in colorectal, lung, ovarian, and endometrial carcinomas. The purpose of this study is to determine the value of KAI expression as a predictor of metastatic potential in squamous cell carcinoma (SCC) of the uterine cervix.

Design: 65 cases of cervical SCC encountered over a 6-year period were collected, including 56 hysterectomy specimens with pelvic lymph node sampling, 6 cold-knife cone biopsies, and 3 colposcopic biopsies. Tumors were graded from well to poorly differentiated on a scale of 1 to 3. 18 cases exhibited lymphovascular invasion (LVI) and 10 had metastases (MT) diagnosed at the time of surgery (9 lymph nodal, 1 ovarian). Staining was performed using a monoclonal antibody against KAI and standard avidin-biotin complex technique in paraffin-embedded tissue. Analysis was based on distribution, strength, and pattern.

Results: There was strong/diffuse staining in the majority of primary SCC with associated LVI and/or MT. A significant difference was noted in the staining pattern; 94% of cases with LVI and 100% of the cases with MT had a membranous staining pattern in the primary tumor (p=<0.005). 50% of the MT showed a decrease in the distribution of KAI expression (20% diffuse) as compared to their corresponding primary tumors (70% diffuse). Regarding histologic differentiation, 100% cases of grade 1 SCC showed strong staining for KAI vs 29% of grade 3 SCC.

Conclusions: These data demonstrate an increased expression of KAI in primary SCC of the uterine cervix with associated lymphovascular invasion and/or metastases. KAI expression appears to be decreased in the concurrent metastases. These findings suggest an up-regulation of KAI in those primary tumors with metastatic potential and subsequent down-regulation in their metastatic clones. Immunohistochemical staining for this marker may prove useful as a predictor of metastatic behavior in cervical SCC.

KAI-1 Primary Tumor	LVI (%)		Metastases (%)	
	Absent	Present	Absent	Present
DISTRIBUTION				
Neg/Focal	18 (38)	3 (17)	8 (15)	4 (40)
Diffuse	29 (62)	15 (83)	47 (85)	6 (60)
STRENGTH				
Neg/Weak	20 (43)	3 (17)	8 (15)	4 (40)
Strong	27 (57)	15 (83)	47 (85)	6 (60)
PATTERN				
Cytoplasmic	16 (44)	1 (6)	17 (36)	0
Membranous	20 (56)	17 (94)	30 (64)	7 (100)

904 Identification of Markers for Targeted Therapy of Paget's Disease of the Vulva

B Behjatnia, J Rao, O Dorigo. University of California in Los Angeles, Los Angeles, CA.

Background: Paget's disease of the vulva (PDV) has a high recurrence rate after surgical excision. Only limited therapeutic options for non-invasive treatment are currently available. Recent studies have shown overexpression of the HER-2/neu protein in PDV. In addition, preliminary data has suggested that the epidermal growth factor receptor (EGFR), and the oncogenic phosphoinositide 3-kinase (PI3K)/Akt pathways are involved in the pathogenesis of PDV. These findings provide a rationale for HER-2/neu and PI3K/Akt targeted therapy for PDV. The goal of this project is to further elucidate the role of oncogenic signaling in PDV, focusing on HER-2/neu, EGFR, and pAkt expression by immunohistochemical analysis (IHC).

Design: Paraffin-embedded specimen from 16 patients with PDV from UCLA pathology database were collected for performing IHC with Hercep test for expression of HER-2/neu protein and rabbit anti-pAkt antibody for pAkt staining. Clinical data were tabulated by reviewing UCLA electronic records and medical charts to correlate with IHC data.

Results: Successful IHC analysis was performed in 13 out of 16 samples. HER-2/neu protein overexpression was found in 11/13 (85%) cases, whereas, pAkt staining showed overexpression in 10/13 (77%) cases. Chi-square test analysis suggested positive correlation between HER-2/neu expression and pAkt staining.

Conclusions: The HER-2/neu protein was found to be overexpressed in a high percentage of our PDV cases. In addition, strong activation of the oncogenic PI3K/Akt pathway was demonstrated in the majority of the specimens. These data suggest that HER-2/neu and PI3K/Akt might be important therapeutic targets in PDV for example by using agents such as trastuzumab, a monoclonal antibody against HER-2/neu.

905 Improving Diagnostic Accuracy and Inter-Observer Agreement for CIN2+ through the Conjunctive Use of p16 Immuno-Histochemistry on Cervical Biopsies

C Bergeron, J Ordi, D Schmidt, MJ Trunk, R Ridder. Laboratoire Pasteur-Cerba, Cergy, France; Hospital Clinic, Barcelona, Spain; Institute for Pathology, Mannheim, Germany; mtm laboratories, Heidelberg, Germany.

Background: The diagnostic interpretation of HE-stained cervical tissue sections is subject to substantial rates of discordance among pathologists. As biopsy diagnoses establish the basis for decisions to treat, the impact of inaccurate diagnoses is significant. Strong overexpression of the cell-cycle regulatory protein p16^{INK4a} has been demonstrated in dysplastic cervical epithelial lesions, and it could be closely linked at the molecular level to the activity of the HR-HPV E7 oncoprotein in transforming infections. Immunostaining of cervical biopsies for p16 has been suggested as a potential mean to improve the diagnostic assessment. In this study, we investigated whether the interpretation of p16-stained slides in conjunction with HE stained cervical histology slides may improve the accuracy in diagnosing high-grade CIN (CIN2+).

Design: A European, controlled study was performed on 500 cervical tissue specimens comprising both diagnostic punch and conization specimens with a distribution of cases categorized as Negative for dysplasia, CIN1, CIN2, and CIN3. Three European expert gynecopathologists established a morphology-based consensus diagnosis for each case. Twelve panel pathologists from France, Spain, Italy and Germany and reading cervical pathology on a regular basis established their individual diagnoses for all of the 500 cases on HE alone. The same set of HE-stained slides were interpreted again by all panel pathologists, together with consecutive slides stained for p16 using the CINtec Histology Kit.

Results: Overall sensitivity for the identification of CIN2+ in cervical biopsies was 77% for HE-slides versus 87% for HE- and p16-stained slides, resulting in an improvement by 13%. This translates into 231 individual diagnoses that have been classified as either negative for dysplasia or CIN1 on HE, and correctly upgraded to CIN2+ based on the p16-stained slides. Specificity was only slightly lower (-1%). The improvement in diagnostic accuracy was statistically highly significant (p=0.0004). Inter-observer agreement between the 12 panel pathologists was significantly improved by adding p16-stained slides (kappa value improved from 0.580 to 0.756, p<0.0001).

Conclusions: The conjunctive use of CINtec p16 Histology slides significantly increases the diagnostic accuracy and inter-observer agreement for the identification of CIN2+ lesions in cervical biopsies.

906 Molecular Genetic Analysis of High Grade Endometrial Carcinomas

JM Boland, LM Peterson, BR Kipp, DI Smith, GL Keeney, AC Clayton, KC Halling, F Medeiros. Mayo Clinic, Rochester, MN.

Background: Endometrial adenocarcinomas are categorized as endometrioid and non-endometrioid types, comprising approximately 80% and 20% of endometrial malignancies, respectively. Most non-endometrioid tumors are high grade neoplasms that can be further classified as papillary serous carcinoma, clear cell carcinoma and carcinosarcoma. Little is known about the molecular genetics and pathogenesis of high grade endometrial carcinomas (HGEC). The goal of this study is to investigate the most common types of genetic abnormalities in HGEC.

Design: The study comprised 20 cases of HGEC treated surgically at the Mayo Clinic with fresh-frozen tissue available for analysis (10 carcinosarcomas, 7 serous, 1 clear cell, 1 mixed endometrioid and serous and 1 mixed endometrioid and clear cell). All cases were tested for genomic copy number changes by array comparative genomic hybridization (aCGH) (Abbott Molecular, Des Plaines, IL), microsatellite instability (MSI), mismatch repair (MMR) expression, p53 expression, and *BRAF* mutations.

Results: There was good quality aCGH data for 15 of the 20 cases. The average number of observed DNA gains was 6.5 per case (range 0-13) and the average number of DNA losses was 4.7 (range 0-17). Microsatellite instability (MSI) testing (successful in 16

cases) and correspondent immunohistochemical staining for MLH1, MSH2, MSH6 and PMS2 showed that all 16 HGECs were microsatellite stable (14 cases by MSI testing) or MSI-low (2 cases by MSI testing) with preservation of MMR protein expression. Of the 4 cases that failed MSI testing, there was loss of MSH2 and MSH6 expression in one case, and normal MMR protein expression in the remaining 3 cases. Immunostaining for p53 was successful in 14 cases, and 13 of 14 cases showed p53 overexpression. *BRAF* mutations were not detected in any cases.

Conclusions: These results indicate that MSI does not play an important role in the pathogenesis of HGEC, while chromosomal alterations (gain and loss) and likely p53 mutations (as evidenced by p53 overexpression) are common findings in these tumors. This chromosomal instability is likely important in driving tumorigenesis in HGEC.

907 Ligneous Inflammation of the Female Genital Tract

G Caponetti, C Otis, I Mert, S Marconi, V Schuster, M Ziegler, K Tefs, J Hecht, M Tug, L Pantanowitz. Baystate Medical Center, Springfield; Zekai Tahir Burak Hospital, Ankara, Turkey; University of Leipzig, Leipzig, Germany; Beth Israel Deaconess Medical Center, Boston.

Background: Ligneous inflammation (LI) is characterized by pseudomembranes and inflammation. A possible autoimmune etiology similar to lichen sclerosus is proposed. There have been no series of LI involving the female genital tract (FGT). We aimed to characterize the morphology, genotype and immunophenotype of LI of the FGT.

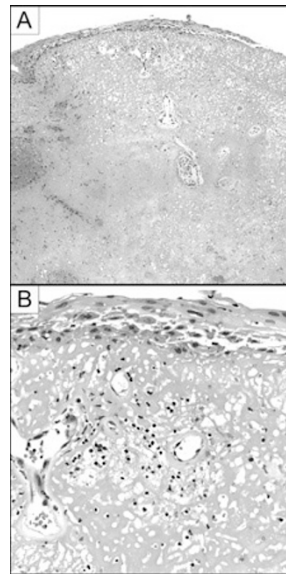
Design: Tissue from 4 patients with LI (12 specimens), 10 of chronic cervicitis (CC), and 10 of vulvar lichen sclerosus (LS) were studied. Sections were stained with H&E, PAS, PTAH, Congo Red, CD3, CD4, CD8 and CD20. The distribution and proportion (graded 0-4) of T & B cells was recorded. DNA from LI patients was studied for mutations in the plasminogen gene (PLG) by PCR and direct sequencing.

Results: LI patients were of mean age 41 years, 2 with low plasminogen antigen and functional activity (12% & 18% of normal). LI on biopsy showed abundant stromal deposits of eosinophilic, PAS+, PTAH+, Congo Red negative fibrin associated with chronic inflammation (Figures A&B). Table 1 shows the inflammatory infiltrate of LI resembles CC more than LS. In LI cases with low plasminogen, there was a homozygous mutation in 1 patient and heterozygous mutation in another. No mutations were found in the other 2 women with LI. Multiple PLG polymorphisms were detected in all four LI patients.

Conclusions: LI of the FGT is related to plasminogen deficiency secondary to PLG genetic defects. Mutations in unidentified regulatory sequences of the PLG may explain the lack of demonstrable genetic mutations in some cases. Failure of plasminogen to remove fibrin results in tissue deposition. Given this molecular mechanism, and evidence that the inflammatory infiltrate resembles a reactive process, a role for autoimmunity in LI appears unlikely.

Table 1: Distribution and proportion of lymphocytes in tissue biopsies.

Diagnosis	Lymphocyte distribution	Proportion of CD3+ Cells	Proportion of CD20+ Cells	Overall CD4:CD8
LI	Intraepithelial and subepithelial	3	2	CD4 predominant
CC	Intraepithelial and subepithelial	3	2	Equal CD4 and CD8
LS	Subepithelial and subsclerosal	4	1	CD4 predominant



908 Endometrial Intraepithelial Neoplasia Is Associated with Polyps and Frequently Has Metaplastic Change

JW Carlson, GL Mutter. Brigham and Women's Hospital, Boston, MA.

Background: The precursor lesion to endometrioid endometrial adenocarcinoma is Endometrial Intraepithelial Neoplasia (EIN), a lesion recently defined by its combined molecular, histological, and clinical outcome features. EIN is a benign neoplasm with a high propensity to undergo malignant transformation to carcinoma. Potential confounding factors such as presence of metaplastic changes and occurrence within an endometrial polyp are common. We here report the differentiation state, and polyp context, of 83 sequential EIN lesions diagnosed over a 2-year period.

Design: Review of pathology reports of 6,333 endometrial biopsies and curettages from 2004-2006 disclosed a total of 105 initial diagnoses of EIN in 105 women, of which 83 were available for review. Two gynecologic pathologists (GLM and JWC) scored

areas of EIN for presence of non-endometrioid differentiation, and co-occurrence of a polyp in the specimen.

Results: 39 of 83 EIN cases contained metaplastic changes (18% squamous morular, 14% tubal secretory, and 5% each of secretory, mucinous or ciliated change). Endometrial polyps were more likely (OR 5.19, $p < 0.001$) to occur in the endometrial biopsies of women with EIN lesions (43.3%), compared to the background polyp rate (12.9%) of comparable specimens from the same patient population.

Conclusions: EIN is a rare lesion, seen in only 1.4% of endometrial biopsies in a busy hospital based practice. Non-endometrioid differentiation within EIN lesions is a frequent cytologic alteration that offsets these neoplastic clones from background endometrium, and contributes to their altered cytologic appearance. EINs with altered glandular differentiation vary widely in their ease of recognition and frequency. The fivefold increase of endometrial polyps in women with EIN suggests an intriguing biologic relationship. One possibility is that non-shedding of polyp tissue creates a shelter for persistence of pre-existing neoplastic glands. Alternatively, the unique stroma of endometrial polyps may promote expansion of premalignant glandular clones. This study provides the first sequential practice based data that endometrial polyps are a risk factor for EIN and subsequent progression to carcinoma.

909 Observer Variation in the Recognition of Tubal Intraepithelial Carcinoma

JW Carlson, EA Jarboe, DW Kindelberger, CP Crum. Brigham and Women's Hospital, Boston, MA.

Background: The origin of pelvic serous cancers has been the subject of extensive research and controversy. Recently there has been increasing evidence that the fallopian tube plays a central role in the pathogenesis of some ovarian, peritoneal and possibly, uterine serous carcinomas, both in women with a BRCA mutation and in sporadic cases. Given this increased awareness, there is an interest in diagnosing tubal intraepithelial carcinoma (TIC) with improved consistency and accuracy.

Design: Twenty-one cases were reviewed, using both H&E and immunohistochemistry for p53 and MIB-1, for the presence or absence of tubal intraepithelial carcinoma (TIC). Thirty H&E foci of either TIC (n=14) or benign tubal epithelium (n=16) were selected and photographed. The images were randomized and a digital presentation was constructed. No information regarding immunohistochemistry or the presence of invasive serous carcinoma was included in the test presentation. This presentation was reviewed by 12 pathologists, 6 of whom were experienced gynecologic pathologists and 6 of whom were pathology residents.

Results: A generalized kappa statistic for multiple raters was calculated for all groups. Results were $\kappa=0.333$ for all 12 reviewers, $\kappa=0.453$ for the experienced gynecologic pathologists, and $\kappa=0.253$ for the pathology residents. The percentage of TICs that were recognized by each was 68 and 63 per cent respectively. In the experienced group, only 3/14 cases were diagnosed by all six reviewers and only 9/14 by a majority. One histologic feature of TIC that correlated with a lack of interobserver agreement was a lack of epithelial stratification. Histologic features that correlated with the overdiagnosis of benign mucosa were stratification and complex epithelial growth, both common in the normal salpingeal mucosa.

Conclusions: Interobserver concordance in the diagnosis of tubal intraepithelial carcinoma is at best fair to good for even experienced gynecologic pathologists, and a proportion cannot be consistently identified under the conditions of this study, even among experienced observers. Attention to multiple parameters is necessary and biomarkers such as p53 and MIB-1, may be particularly useful for excluding benign mimics. Cases resulting in both concordant and non-concordant interpretations are illustrated and discussed.

910 Ovarian Clear Cell Carcinomas Reliably Express an Immunophenotype That Is Different from High-Grade Serous Carcinoma

J Carrick, R Soslow, E Oliva, C Ewanowich, CB Gilks, M Köbel. Vancouver General Hospital and British Columbia Cancer Agency, Vancouver, BC, Canada; Memorial Sloan-Kettering Cancer Center, New York, NY; Massachusetts General Hospital, Boston, MA; University of Alberta, Edmonton, AB, Canada.

Background: Ovarian clear cell carcinomas (CCC) typically present in low stage and are less likely to respond to platinum based standard chemotherapy than usual high-grade serous carcinomas (HG-SC). CCC presents a diagnostic challenge especially distinguishing them from HG-SC with clear cell features. The purpose of this study was to test and validate a set immunohistochemical biomarkers in cases of CCC diagnosed in different centers.

Design: From our test set of 132 CCC and 200 HG-SC, we chose the following markers: WT-1, ER, p53, p21, CyclinE and Ki67 that show discrimination between these two cell types. For validation of this immunophenotype CCC were amassed from three other hospitals throughout North America. The paraffin embedded tumors were then used to construct TMAs with duplicate cores.

Results:

	N	WT-1 (%)	p53 (%)	ER (%)	p21 (%)	CyclinE (%)	Ki67 Median
CCC BC	132	2.2	5.3	11.4	72.8	80.5	7.5
CCC other	107	1.9	2.8	16.3	76.7	82.2	11.0
CCC All	239	2.1	4.2	13.1	74.5	81.2	8.6
HG-SC BC	200	79.6	48.5	75.5	34.2	51.5	22.0

(%) - percentage of positive cases, CCC BC - CCC from British Columbia, CCC other - CCC cases from other North American Centers, CCC All - all cases of CCC, HG-SC BC - HG-SC from British Columbia

Conclusions: This study confirms that CCC diagnosed in four different institutions consistently show a low expression of WT-1, p53 and ER, thus absence of these markers can be used to support the diagnosis of this cell type. Further, high expression of p21 and low Ki67 labeling index in CCC reflects differences in pathogenesis compared to HG-SC.

911 PIK3CA Mutations and p53 Alterations in High-Grade Endometrial Carcinomas

L Catusas, A Gallardo, M Cuatrecasas, C Pons, J Prat. Hospital de la Santa Creu i Sant Pau, Autonomous University of Barcelona, Barcelona, Spain.

Background: Mutations of the *PIK3CA* oncogene are common in endometrioid endometrial carcinomas (EEC). Tumors carrying *PIK3CA* mutations are often high-grade carcinomas associated with myometrial invasion. We have studied the impact of *PIK3CA* mutations on high-grade tumors (EECs, NEECs, and mixed carcinomas) and compared them with other genetic alterations.

Design: Genomic DNA was obtained from 59 high-grade endometrial carcinomas (29 grade 3 EEC, 6 serous (SC), 4 clear cell (CC), and 20 mixed carcinomas (9 EC-CC, 7 EC-SC, and 4 CC-SC). Mutational analysis for *PIK3CA* (exons 9 and 20), *PTEN*, and *K-RAS* was performed. Microsatellite instability (MI) for 5 different loci (BAT25, BAT26, D2S123, D5S346, and D17S250) was also done. Immunohistochemical analysis of p53 was done on tissue arrays. Clinicopathologic data were obtained.

Results: *PIK3CA* mutations were found in 33.9% (20/59) of cases including all histologic types. 95% (19/20) mutations occurred in exon 20. P53 overexpression was detected in 31.4% (16/51) of cases and was more frequent in NEEC and mixed carcinomas ($p=0.037$). *PIK3CA* mutations coexisted with p53 overexpression in 9.8% (5/51) of either pure EEC or mixed carcinomas with an endometrioid component. We found that *PIK3CA* mutations coexisted with *PTEN* and *K-Ras* mutations and MI in pure EEC but not in mixed carcinomas with an endometrioid component.

Conclusions: While exon 20 *PIK3CA* mutations are common in high-grade endometrial carcinomas of any histologic type, p53 overexpression is more frequent in NEEC and mixed carcinomas. Our results confirm that *PIK3CA* activation is an alternative pathway in high-grade endometrial carcinomas.

912 Clinico-Pathologic Features of Female Genital Tract Neuroendocrine Carcinoma: A Series Study of 25 Cases from Two Institutes

A Chan, W Bshara, K Odunsi, T Pejovic, P Mhawech-Fauceglia. Roswell Park Cancer Ins, Buffalo, NY; Oregon Health & Science Univ, Portland, OR.

Background: Neuroendocrine carcinomas (NEC) of the female genital tract are the most heterogeneous, clinically aggressive and the least genetically characterized tumors. These tumors are rare with few large series. Our goal is to examine series of cases and evaluate their clinical presentation, morphology, treatment and follow-up, and trying to identify potential prognostic factors.

Design: The archives were searched from 1995 to 2007 for NEC arising in the gynecologic tract. The cases were reviewed and extensively analyzed by immunohistochemistry. The follow-up data was retrieved from the patients medical records. Depending on the site in the gynecologic tract, cases were classified as small cell carcinoma (SCC), SCC hypercalcemic type (SCCOHT), large cell NEC, and NEC-NST. Patients are followed from the time of initial diagnosis to the time of death or last follow-up and grouped into alive with disease (AWD), no evidence of disease (NED), and dead of disease (DOD).

Results: Patient age ranged from 16-84 years old. Ten cases were ovarian, 12 uterine and 3 cervical primaries. The clinical symptoms were variable, and included abdominal pain, ascites, irregular menses, post menopausal bleeding and symptomatic hypercalcemia. Tumor size ranged from 2 to 14 cm. As for histological types, in the ovary 6 were diagnosed as SCC (3/6 were SCCOHT), and 4 NEC-NSCT. In the uterus, 6 were of small cell NEC, 6 were of large cell NEC. NEC was associated with adenocarcinoma and carcinosarcoma in 5/25 and 4/25 cases respectively. Finally, 3/3 cases of the cervix were small cell NEC. All patients had extensive surgery and were given multiagent chemotherapy except for 3 patients. Chemotherapy plus radiation therapy was administered to 11 patients. Three patients underwent surgery only and refused any adjuvant treatment. As for follow-up, 11 patients (44%) DOD within 3-50 months; five patients had NOD at period ranging from 3 to 34 months. Seven patients were AWD at a period ranging from 1-18 months. Finally two patients were lost for follow-up.

Conclusions: We concluded; 1- No matter what subtypes and stages neuroendocrine tumors of the female genital organ are, they all are very aggressive disease with poor prognosis. 2- Evaluation of the genetic pathways to explain their aggressive behavior is necessary. 3- The need of multi institutional effort to randomized clinical trials is a priority.

913 Immunohistochemical Staining for Embryonic Stem Cell Transcription Factors and D2-40 in Ovarian Germ Cell Tumors

MC Chang, SO Vargas, JL Hornick, MS Hirsch, CP Crum, MR Nucci. Brigham and Women's Hospital, Boston, MA; Children's Hospital of Boston, Boston, MA.

Background: The embryonic stem cell transcription factors (TFs) NANOG, SOX2, and OCT3/4 have been implicated in the regulation of germ cell tumor (GCT) growth and differentiation. They, and D2-40 (podoplanin), a membrane antigen expressed in seminomas, are emerging as diagnostically useful immunomarkers in testicular GCTs. The aim of this study was to determine whether these markers can distinguish dysgerminoma (DYS) from embryonal carcinoma (EC) and other mimics in the ovary.

Design: Paraffin-embedded sections from pure ovarian GCTs (N=28: 10 DYS, 3 yolk sac tumors (YST), 1 EC, 9 immature teratomas (IT), and 5 mature teratomas), mixed GCTs (N=3), and selected non-GCTs were reviewed and immunostained for NANOG, SOX2, OCT3/4, and D2-40. In the pure GCTs, staining for the TFs was scored as immunoreactive when >10% of tumor nuclei were positive. Only a diffuse membranous pattern was counted as positive for D2-40. In mixed GCTs, each component was evaluated independently with the same criteria.

Results: The staining results for each marker are summarized in Table 1.

Table 1. Immunohistochemistry in Ovarian Germ Cell Tumors

Tumor type	Number of Positive Cases			
	NANOG	SOX2	OCT3/4	D2-40*
Pure GCT				
DYS	8/10	0/10	8/10	10/10
EC	1/1	1/1	1/1	0/1
YST	0/3	0/3	0/3	0/3
IT	0/9	9/9	3/9	0/9
mature cystic teratoma	0/5	0/5	0/5	0/5
Mixed GCT component				
DYS	1/1	0/1	1/1	1/1
EC	3/3	3/3	3/3	0/3
YST	0/3	0/3	0/3	0/3
IT	0/1	0/1	0/1	0/1
choriocarcinoma	0/1	0/1	0/1	0/1
Non-GCT				
clear cell carcinoma	0/3	0/3	0/3	0/3
adult granulosa cell tumor	0/3	0/3	0/3	0/3
Sertoli-Leydig cell tumor	0/2	0/2	0/2	0/2

* Patchy cytoplasmic staining was considered negative.

Conclusions: Ovarian GCTs have distinct immunostaining profiles for NANOG, SOX2, OCT3/4, and D2-40, depending on the type of differentiation. DYS is positive for NANOG and OCT3/4, and is the only GCT to stain for D2-40 in a diffuse membranous pattern. SOX2 is useful in distinguishing DYS (negative) from EC (positive), but can also be expressed in IT. Clear cell carcinoma and other potential GCT mimics evaluated were negative for all markers. These findings indicate that immunostaining for NANOG, SOX2, OCT3/4, and D2-40 may be useful in the diagnosis of ovarian GCTs.

914 An Immunophenotypic Study of Fimbrial Mucosa

MC Chang, R Drapkin, FD McKeon, H Mei, EA Agoston, CP Crum. Brigham and Women's Hospital, Boston, MA; Dana Farber Cancer Institute, Boston, MA; Harvard Medical School, Boston, MA.

Background: The distal fallopian tube has been identified as one site of origin for pelvic serous carcinoma and a candidate serous cancer precursor, termed the "p53 signature". Both are presumed to originate in the secretory cell of salpingeal epithelium. Ciliation has been linked to the proliferative phase of the menstrual cycle and studies *in vitro* suggest that secretory cells are precursors to ciliated cells in the salpingeal mucosa. This study analyzed the distal fallopian tubes of women with benign disorders (leiomyomata) for biomarkers designed to address this concept.

Design: Consecutive cases of fallopian tubes from women undergoing surgery for leiomyomata were analyzed by the SEE-FIM protocol and immunostained with antibodies to p53, p73, BCL-2 (all cases), Cyclin D1, Cyclin E, and MIB-1 (selective slides). Immunostaining was designed to identify p53 signatures (p53+), ciliated cells (p73), secretory cells (BCL-2) and cells with cell cycle activity (Cyclin D1, Cyclin E, MIB-1). Extent of ciliation was correlated with age and menstrual cycle with ciliated cell presence estimated as mild (less than 33%), moderate (33-66%) and marked (>66%).

Results: Fallopian tubes from 46 consecutive cases were analyzed. Nine (20%) contained p53 signatures, all of which exhibited a secretory cell phenotype. There was no consistent correlation between phase of cycle, menopausal status and degree of ciliation. BCL-2 and p73 localization, including double staining, highlighted distinctly different populations of ciliated and secretory cells with minimal staining overlap. However, cell cycle activity appeared confined to the secretory cells and in areas of tufting or stratification, secretory cells oriented to the lower epithelial layers relative to ciliated cells.

Conclusions: The morphologic and immunophenotypic findings are consistent with the concept that ciliated and secretory cells in the fallopian tube share a common precursor. Morphologic intermediates appear to be distinctly uncommon, however, and stable populations of ciliated cells can persist in the postmenopausal fallopian tube. Because regulation of this pathway influences both secretory and ciliated cells differentiation, its susceptibility to neoplastic transformation, and subsequent capacity of neoplastic cells to differentiate may hold answers to the development of both low and high grade pelvic serous neoplasms.

915 Immunoprofile of Mucinous and Microglandular Adenocarcinomas of the Endometrium

MA Chekmareva, L Ellenson, EC Pirog. Weill Medical College of Cornell University, New York, NY.

Background: Mucinous and microglandular adenocarcinomas of the endometrium (MUC-AD and MIGL-AD) are uncommon types of endometrial cancer. When present in endometrial biopsy or curettage these tumors may display a unique microglandular architectural pattern mimicking benign microglandular hyperplasia (MGH) of the endocervix.

Design: We compared the immunoprofile of MUC-AD, MIGL-AD with that of MGH and benign endocervical glands, in order to identify the markers that would reliably separate these malignancies from benign endocervical tissue. The markers included vimentin, p16, Ki-67, bcl-2, survivin, CD10 and CD34. A total of 10 MIGL-AD and 30 MUC-AD cases were used for the study. Fifteen consecutive cases of benign endocervical glands and MGH were used as a control group.

Results: P16 was the only marker that showed significantly different staining profile in benign mucinous endocervical epithelium and MGH (no staining) versus MUC-AD and MIGL-AD (all, but one, cases positive). The staining for vimentin, Ki-67, bcl-2 and survivin showed significant overlap between the benign and malignant cases. The stromal cells of endocervix demonstrated weak to moderate positivity for CD10 and strong positivity for CD34. The stromal cells of endometrial tumors showed a reverse pattern, with strong positivity for CD10 and either no, or only weak staining for CD34.

Conclusions: In conclusion, epithelial p16 and stromal CD10/CD34 immunostaining can be useful in distinguishing MUC-AD and MIGL-AD from benign endocervical epithelium.

916 Molecular and Immunohistochemical Evidence for Origin of Uterine Leiomyosarcomas from Associated Leiomyoma and Symplastic Leiomyoma like Areas

F Chen, GA Toruner, JJ Wei, K Rijhvari, R Kurvathi, D Streck, J Dermody, K Mittal. New York University School of Medicine, New York, NY; UMDNJ-NJ Medical School, Institute of Genomic Medicine, Newark, NJ.

Background: It is uncertain whether uterine leiomyosarcoma (LMS) arises de novo or in pre-existing leiomyoma. Leiomyoma-like areas can be seen associated with uterine LMS, raising the possibility of precursor lesions for LMS. In this study, we examined the cases of uterine LMS associated with leiomyoma-like areas at histological, immunohistochemical and DNA level to further evaluate if benign looking leiomyoma-like and malignant LMS areas are related.

Design: Cases of uterine LMS seen at New York University Medical Center from 1994 to 2007 were reviewed for presence of leiomyoma-like areas. 16 of the 26 cases were examined immunohistochemically for Ki-67 (MIB-1), estrogen receptor (ER), progesterone receptor (PR) and p53. In four cases, the leiomyoma-like and LMS areas from each case were examined using high density oligonucleotide array-CGH (comparative genomic hybridization) technology (Agilent 44K arrays) to look for similar and different genetic aberrations in the two areas.

Results: Of the 26 cases of uterine LMS seen during this period, 18 cases had associated leiomyoma (18 cases) or symplastic leiomyoma (SL)-like areas (8 cases). Immunohistochemical profiles were as expected for leiomyoma like (the mean expression of p53, ER, PR and Ki-67 at 0.3, 63, 75, and 0.6 % respectively), SL-like areas (the mean expression of p53, ER, PR and Ki-67 at 0.6, 85, 89, and 5.5 % respectively) and LMS areas (the mean expression of p53, ER, PR and Ki-67 at 52, 38, 39 and 61% respectively). Of the four cases examined using array-CGH, two cases are associated with cellular leiomyomas and two cases are associated with SL. We observed that all the genetic aberrations found in leiomyoma-like areas are also found in corresponding LMS areas. In addition, LMS areas have additional genetic aberrations.

Conclusions: The immunohistochemical profiles and genetic aberrations of the examined cases suggest that uterine LMS could arise from the pre-existing leiomyoma or SL-like areas.

917 A Clinicopathologic Analysis of Primary Mucinous Adenocarcinoma of the Ovary in South Korea

G Choi, HI Lee, K-R Kim, SJ Robboy. University of Ulsan College of Medicine, Seoul, Republic of Korea; Dankook University Hospital, Cheonan-si, Republic of Korea; Duke University Medical Center, Durham.

Background: Even though bilaterality, surface involvement, infiltrative invasion, nodular invasion, hilar involvement, single cell invasion, and extraovarian spread suggest metastatic mucinous carcinoma to the ovary, we not infrequently have experienced cases with these features where no other primary site could be found despite extensive clinical examination and follow-up observation. This study analyzes the clinicopathologic characteristics of primary ovarian mucinous adenocarcinoma in Korean women to test the diagnostic utility of the above mentioned features.

Design: Of 1,090 primary mucinous ovarian tumors at AMC, Seoul, Korea during 1992-2007, we retrieved 35 primary mucinous adenocarcinomas (3.2%), which included 8 mucinous intraepithelial carcinoma (MIC), 5 MIC with microscopic invasion, 9 extensive stromal invasion and 13 with expansile growth but without destructive invasion. Other primary sites were excluded by various preoperative and postoperative examinations including abdominopelvic CT scan (33), PET scan (10), sonography (35).

Results: The patients' ages ranged from 15 to 80 years (mean 38.9). The tumor occurred before the age of 50 in 74%, and before the age of 40 in 63%. Only 1 ovary was involved in 83%, and both in 17%, and the size ranged from 2.5 to 33cm (mean 17.1 cm). The surface was involved or the capsule ruptured in 46% of cases. Expansile growth and nodular growth were difficult to differentiate from each other. All but one patient with expansile tumor growth but no destructive invasion are free of disease (mean: 59 months, range: 4-180 months), suggesting expansile tumor growth is a favorable attribute, and more closely functionally resembles intraglandular carcinoma rather than those with destructive invasion. Of 9 patients with stromal invasion, 4 died of disease, 1 is alive with disease, and 4 are free of disease.

Conclusions: Previously described clinicopathologic features favoring metastatic carcinoma are not infrequently seen in the primary ovarian mucinous carcinomas. Compared to the literature of patients with intestinal tumors metastatic to ovary, the distribution in younger age bracket may be a characteristic feature for the primary ovarian mucinous adenocarcinoma in Korean women.

918 Hormone Receptor, Cell Damage, and Proliferative Markers in "Normal" Appearing PTEN-Null Endometrial Glands

YK Chun, GL Mutter. Cheil General Hospital & Women's Healthcare Center, Kwandong University College of Medicine, Seoul, Korea; Brigham and Women's Hospital, Boston, MA.

Background: The PTEN tumor suppressor gene is a useful biomarker for endometrioid endometrial carcinoma, being inactivated in 60-80% of sporadic cases. PTEN loss of function by acquired mutation and/or deletion occurs very early, and commonly, in normal tissues, being seen in small numbers of unremarkable appearing endometrial glands in 43% of premenopausal women. Development of carcinoma from these normal appearing PTEN-null glands ("latent precancers") must be quite rare, because the lifetime risk of endometrial cancer is only 2.6%. This suggests that something other than PTEN inactivation is rate limiting, probably superimposition of additional genetic damage or

hormonally mediated selection of cells already bearing a non-functional PTEN gene. The goal of this study is to identify secondary events within PTEN-null glands that may contribute to progression.

Design: 55 cases of normal proliferative endometrium with PTEN-null glands localized by immunohistochemistry were stained for estrogen (ER) and progesterone (PR) receptors, markers of DNA and hypoxic damage (gamma-H2AX and HIF-1 alpha), and proliferation (MIB-1). In order to co-localize marker changes with loss of PTEN protein, we compared the marker staining pattern between those glands which were PTEN-null, and those containing PTEN protein. Then we screened the rest of the slide for foci in which the marker expression was locally altered.

Results: None of the 5 markers demonstrated specific alteration within PTEN-null glands, showing a staining pattern identical to that of PTEN expressing areas. Within the background PTEN expressing areas, 7% (4/55) of cases showed loss of PR in a clonal pattern of contiguous glands. PR deficient glands contained abundant ER and normal staining for other markers.

Conclusions: We did not co-localize changes in hormonal receptors, cell damage, or proliferation to PTEN-null endometrial glands. Progesterone receptor loss in a clonal pattern did, however, occur elsewhere in 7% of cases, indicating an abnormal hormonal response pathway due to changes in the PR gene itself or its upstream regulatory factors. These events of PTEN and PR inactivation seem to be independent, as they did not occur within the same glands. Our data supports frequent acquisition of genetic damage in normal tissues affecting multiple different cellular functions, of which PTEN and progesterone responsiveness are examples.

919 HNF-1 Beta Expression in Ovarian Clear Cell Carcinoma

J Cuff, GE Esheba, RA Soslow, TA Longacre. Stanford University Medical Center, Stanford; Memorial Sloan-Kettering Cancer Center, NY.

Background: Ovarian clear cell carcinoma (CCC) is a clinically distinct surface epithelial neoplasm that does not respond well to conventional platinum based chemotherapy. While studies have shown a worse prognosis in advanced stage pure CCC, the outcome of tumors with mixed histology is less certain. In addition, distinction from other surface epithelial, germ cell, and sex cord-stromal tumors can be problematic. A distinct genetic profile has been observed in CCC in comparison to other surface epithelial tumors. In particular, hepatocyte nuclear factor-1b (HNF-1b) is up-regulated in CCC and several studies suggest this may be useful in distinguishing CCC from other surface epithelial neoplasms.

Design: Tissue microarrays containing over 400 benign and malignant ovarian neoplasms, normal ovary, and endometriosis were stained with HNF-1 beta (clone C-20, Santa Cruz, titer 1:800). These arrays contained a wide assortment of surface epithelial, sex cord-stromal, and germ cell tumors.

Results: 20 out of 34 (59%) CCC showed nuclear positivity for HNF-1 beta defined as strong nuclear staining in greater than 50% of epithelial nuclei. Expression was highly specific for clear cell carcinoma with no reactivity observed in other surface epithelial tumors, including serous and endometrioid subtypes with clear cell change. No HNF-1 beta expression was identified in cases of endometriosis. All sex cord-stromal and germ cell tumors were also negative, with the exception of yolk sac tumors.

Tumor type	HNF-1 beta
	N/F/D/E
Clear cell carcinoma (n=34)	13/4/16/1
Endometrioid carcinoma (n=32)	30/0/0/2
Serous borderline tumor (n=59)	59/0/0/0
Serous carcinoma, ovary (n=157)	137/0/0/20
Serous carcinoma, peritoneum (n=38)	1/13/11/3
Mucinous neoplasms (n=10)	10/0/0/0
Sex cord-stromal neoplasms (n=14)	13/0/0/1
Germ cell tumors (n=4)	3/0/1/0
Undifferentiated carcinoma (n=2)	2/0/0/0

N-negative, F-focal (<50% of nuclei), D-diffuse (>50% of nuclei), E-equivocal (core absent or uninterpretable)

Conclusions: HNF-1 beta is a highly specific marker in identifying CCC among ovarian surface epithelial tumors and should prove useful in the distinction of problematic ovarian tumors with clear cell change and/or mixed histology. HNF-1 beta is also useful in the distinction of CCC from sex cord-stromal tumors, but may not reliably distinguish CCC from ovarian tumors with yolk sac differentiation.

920 p16^{INK4a} Immunostaining and Progression of LSIL to HSIL

CM Davidson, M Manduch, R Behjati, TJ Childs. Kingston General Hospital, Kingston, ON, Canada.

Background: HPV infection is associated with progression of cervical dysplasia to invasive squamous cell carcinoma. p16 expression is associated with high-risk HPV infection. This study examined whether clinical outcome varies with p16^{INK4a} expression in patients diagnosed with LSIL on surgical biopsies.

Design: A total of 60 patients diagnosed with LSIL were included in the study. Immunostaining of p16^{INK4a} was performed on formalin-fixed, paraffin-embedded sections. Staining intensity was graded as absent, mild, moderate or strong. The staining pattern was also assessed for diffuse or focal distribution and for staining present in more than the basal half of the epithelium. Clinical history was collected by searching for subsequent surgical diagnoses in the LIS. Patients who were subsequently diagnosed with HSIL were classified as "progressed", while those who did not were classified as "not-progressed."

Results: 3 cases did not decorate with p16^{INK4a} antibodies. 20%, 33% and 41% of cases exhibited mild, moderate and strong staining, respectively. Diffuse staining was seen in 58% of cases, while 37% exhibited focal staining. Staining in more than the basal half of the epithelium was seen in 67% and less than or equal to half in 28%. With respect to progression to HSIL, 8% (1/12), 10% (2/20) and 32% (8/25) of cases categorized as mild, moderate and strong, respectively, progressed. The 3 cases with absent staining

did not progress. More cases with strong intensity staining progressed to HSIL than those with less intense or absent staining (p<0.05, Fisher Exact Test). Progression was found in 26% (9/35) of diffusely staining cases and in 9% (2/22) of cases with focal p16^{INK4a} staining. 25% (10/40) of cases with staining in more than the basal half of the epithelium progressed compared to 6% (1/17) of cases with less extensive staining. Cases that exhibited diffuse staining in greater than the basal half of the epithelium progressed more frequently than those with other staining patterns or absent staining (p<0.05, Fisher Exact Test).

Conclusions: Thus, these preliminary data suggest that progression of histologically-diagnosed LSIL to histologically-diagnosed HSIL is more frequent in cases with strong intensity p16^{INK4a} immunostaining and in cases with a diffuse staining pattern in more than the basal half of the epithelium. It is suggested that p16 immunostaining may aid in stratifying patients who are at greater risk of developing HSIL. Further investigation including more cases with a longer follow-up period should help to refine the conclusions.

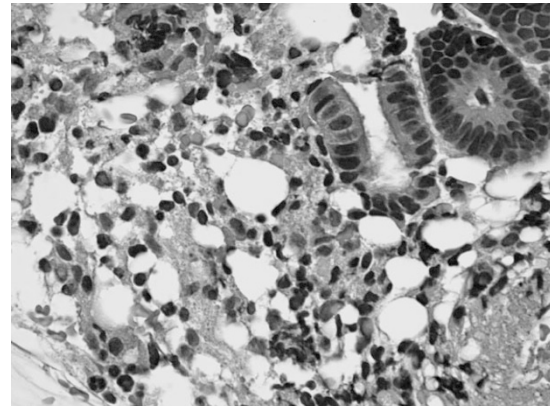
921 Pseudolipomatosis Affects Specimens from Endometrial Biopsies

SS Deshmukh, ML Wu. UC Irvine School of Medicine, Irvine, CA.

Background: Pseudolipomatosis refers to gas that artifactually contaminates specimens. Pseudolipomatosis often affects specimens from colonoscopic biopsies, and produces collections of optically clear vacuoles in the mucosa that closely resemble adipocytes. Pseudolipomatosis has yet to be reported to occur in specimens from endometrial biopsies. Most endometrial biopsies are performed with suction, which might produce pseudolipomatosis by mixing air with endometrial tissue and by allowing air to contaminate these specimens. Pseudolipomatosis in this setting could be mistaken for extraterine adipocytes and lead to a misdiagnosis of perforation.

Design: We retrospectively reviewed 50 consecutive specimens from endometrial biopsies to establish the existence of and to fully characterize pseudolipomatosis in specimens from endometrial biopsies. Pseudolipomatosis was divided into groups "A" and "B" depending on whether the ratio of the area of the largest vacuole to the area of the smallest vacuole was <3 or ≥3 respectively as described for colorectal pseudolipomatosis; and was quantified as mild, moderate, or severe when pseudolipomatosis involved <10%, 10% to 20%, or >20% of the specimens respectively.

Results: 50 of 50 specimens (100%) contained pseudolipomatosis, including 13 of group "A" and 37 of group "B". 21 specimens had mild pseudolipomatosis, 28 specimens had moderate pseudolipomatosis, and 1 specimen had severe pseudolipomatosis. Although the pseudolipomatosis often appeared identical to colorectal pseudolipomatosis, some vacuoles were up to 2.54 millimeters in diameter and were larger than those seen in the colorectum.



Pseudolipomatosis occupied stroma, mucus, and blood. Pseudolipomatosis often resembled adipocytes, yet to our knowledge none of the patients had signs or symptoms of perforation at follow-up.

Conclusions: We performed the first study of pseudolipomatosis occurring in the setting of endometrial biopsies. Pseudolipomatosis is an artifact that very frequently involves specimens from endometrial biopsies, is usually of group "B", can resemble colorectal pseudolipomatosis, and can also produce vacuoles larger than those seen in the colorectum. Awareness of pseudolipomatosis is necessary to avoid misdiagnosing uterine perforation.

922 Absence of Genetic Association between Exaggerated Placental Site Reaction and Placental Site Trophoblastic Tumor

J Dotto, P Hui. Brigham and Women's Hospital, Boston, MA; Yale University School of Medicine, New Haven, CT.

Background: Exaggerated placental site (EPS) is a reactive proliferative condition that consists of implantation site intermediate trophoblasts infiltrating the underlying endomyometrium. Sharing similar cytological and immunohistochemical features with the tumor cells of placental site trophoblastic tumor (PSTT), a biological link between the two lesions has been speculated. As PSTT has a unique sex chromosomal requirement in its genome that requires a paternal X chromosome, i.e. a female antecedent gestation, we investigated whether EPS carries the similar genetic profile by DNA genotypic analysis.

Design: Twenty-one cases of EPS were reviewed and the diagnosis was confirmed according to the current criteria. DNA was extracted from microdissected lesions of EPS and paired maternal endometrial tissue from unstained paraffin sections and analyzed by AmpFISTR® Identifier™ PCR Amplification system (Applied Biosystems, Inc.)

that amplifies 15 different tetranucleotide repeat loci and the presence of the X and Y chromosomes was determined by PCR amplification using primers for the amelogenin locus flanking a six-base pair deletion within intron 1 of the X homologue.

Results: DNA genotyping was informative in all 21 cases. The genetic profile of all cases identified unique paternal alleles to that of the paired maternal tissue, confirming the trophoblastic origin of EPS. The presence of an XY genome (male) was identified in 11 cases (52%), and an XX genome (female) was seen in the rest 10 cases (48%).

Conclusions: EPS is a trophoblastic lesion that can arise from either male or female gestations. The roughly even assignment of sex chromosomes in 21 cases in our study (XY, 52% and XX, 48%) essentially rules out a neoplastic association between PSTT and EPS.

923 Frequency of PTEN Loss in Benign Endometria of Premenopausal Women: A Preliminary Analysis

E Elishaev, R Guido, D Dabbs, N Chatterjee, J Lacey, Jr., C Mueller, ME Sherman. University of Pittsburgh School of Medicine, Magee Womens Hospital, Pittsburgh, PA; National Cancer Institute, Rockville, MD.

Background: The PTEN tumor suppressor gene is mutated in ~50% of endometria containing cancer or atypical endometrial hyperplasia (AEH). Previously, loss of PTEN immunohistochemical staining has been shown to be a good marker of PTEN mutation. A report suggesting that PTEN-null glands may be found in 43% of morphologically unremarkable endometrial biopsies, and may be found in some women repeatedly sampled over a year later suggests that PTEN may be involved in early endometrial carcinogenesis, but data related to PTEN status in histologically normal endometria are sparse. Using extensive sectioning of hysterectomy specimens from patients with benign conditions, we are evaluating the extent of PTEN loss and whether endometrial cancer risk factors (e.g. obesity) are associated with PTEN-null glands.

Design: PTEN stains were performed on 26 hysterectomy specimens removed for benign reasons (leiomyomata, n=21; abnormal uterine bleeding secondary to adenomyosis, n=4; and endometrial polyp, n=1) from consenting pre-menopausal women (ages 34-53 years) who had not recently used exogenous hormones. PTEN stains were evaluated for a median of 8 sections (range 2-12) per uterus and evaluated independently by one pathologist, masked to patient data.

Results: PTEN-null glands were present in 9 of 26 (35%) specimens. PTEN-null glands were detected in proliferative (n=5) and secretory endometrium (n=4) and were found with co-existing polyps in 4 uteri, including one with AEH. PTEN-null foci were typically composed of 2-4 glands. Compared with women whose uteri did not show PTEN-null glands, women with PTEN-null glands did not differ significantly in mean age or BMI. More extensive sectioning was non-significantly related to detection of PTEN-null glands.

Conclusions: Extensive sectioning of benign uteri revealed PTEN-null glands in approximately 35% of endometria from premenopausal women. Although BMI was not significantly associated with PTEN expression, future analyses will compare risk factors for PTEN-null glands with those for endometrial cancer and will compare molecular changes in PTEN-null and PTEN-expressing endometrium using statistical models to adjust for sampling and confounders.

924 Ovarian Frozen Section-Final Diagnosis Correlation: Common Discrepancies and Lessons from 1054 Cases

RE Emerson. Indiana University, Indianapolis, IN.

Background: Ovarian tumors may be difficult to classify by frozen section diagnosis because of the large array of diagnostic possibilities, the limited sampling possible during an intraoperative consultation, and the artifacts produced by frozen section slide preparations. Because of these factors, the diagnostic discrepancy rate reported for frozen section diagnoses of ovarian lesions is approximately 5-8%, higher than that of many other anatomic sites.

Design: In order to assess the accuracy of frozen section diagnosis, deferred diagnosis rates, and to identify causes of frozen section errors, a computer search was made for a 7.7-year period (January 2000 to August 2007) for all frozen section diagnoses of ovarian lesions performed at 3 hospitals. Intraoperative gross diagnosis cases were excluded. The frozen section diagnosis was compared to the final diagnosis given in the report. The discrepant cases were reviewed to investigate the cause of the discrepancy.

Results: The review identified 1054 consecutive frozen section diagnoses at the 3 hospitals. This included 920 unilateral and 67 bilateral ovarian frozen sections. The total number of deferred cases was 33 (3.1%) and the percentage of deferred diagnoses was similar among the 3 hospitals (2.8%, 2.8%, and 3.3%). The lesions most commonly resulting in deferred diagnoses were serous carcinomas, serous borderline tumors, and mucinous adenomas (4 cases each). The total number of discrepancies was 72 (6.8%). The percentage of discrepancies differed between the 3 hospitals (5.0%, 6.3%, and 11.8%). Under-diagnosis accounted for 53 errors (74%), over-diagnosis accounted for 14 errors (19%), and other misclassifications of a malignant or potentially malignant lesion accounted for 5 errors (7%). The most common discrepancy was under-diagnosis of a mucinous borderline tumor as a mucinous cystadenoma (14 cases). Sex cord-stromal tumors (5 cases), metastatic low-grade mucinous neoplasms of probable appendiceal origin (3 cases), germ cell tumors (3 cases), and mesothelioma (1 case) were present in a minority of discrepant cases.

Conclusions: Accuracy of frozen section diagnosis of ovarian lesions is limited by both sampling and interpretative error. Approximately 3% of diagnoses are deferred and the overall accuracy is approximately 93%.

925 Ultrastaging Improves Detection of Sentinel Lymph Node Metastases in Non Squamous Cervical Carcinoma

ED Euscher, MT Deavers, A Malpica. M.D. Anderson Cancer Center, Houston, TX.

Background: Sentinel lymph node (SLN) biopsy is a less morbid alternative to radical lymph node dissection. Ultrastaging (US) has been employed as a method to increase the rate of metastasis (MT) detection in SLNs, and such protocols have been shown to improve MT detection in SLNs of patients with cervical squamous cell CA. This study examines US in pts with non squamous cervical CA (NSqCA).

Design: The institutional database was searched for all cases of NSqCA with SLNs reported from the period 1998-2007. Clinicopathologic features recorded included: follow up, tumor size, presence/absence of vascular invasion, number and status of SLNs and non SLNs, and size of MT in SLNs. US (5 HE at 40µm intervals, if negative→pankeratin immunostain) was performed when all SLNs from a site were negative for MT by standard processing.

Results: 62 SLNs were identified in 12 pts. Three pts had 5 positive SLNs (2 SLNs in 2 pts by routine processing; 3 SLNs in 2 pts by US). One pt had positive SLNs detected during routine processing and a contralateral SLN detected by US. MT size ranged from 0.05 cm to 1.0 cm. One pt with a positive SLN also had a positive nonSLN. No pts had a negative SLN with a positive nonSLN (false negative). Table 1 contains the clinicopathologic features of the 12 cases.

Pt	Tumor Size	Histology	Clinicopathologic Features of SLN Biopsy in NSqCA			Follow up
			Vascular Invasion	+SLN/total SLN	+ nonSLN/total non SLN	
1	1.0 cm	Large cell neuro-endocrine + minimal deviation AC	extensive	0/5	0/14	NED 6 yrs
2	microscopic	AC	none	0/9	0/5	NED 7 yrs
3	2.0 cm	PD AC	rare	2/3	0/10	DOD 19 mo
4	4.0 cm	MD AC	none	0/11	0/15	NED 5 yrs
5	2.5 cm	AC	rare	0/3	0/9	NED 4 yrs
6	4.5 cm	Large Cell Neuroendocrine	extensive	1/1	1/31	DOD 16 mo
7	2.0 cm	MD AC	none	0/10	0/7	NED 18 mo
8	3.5 cm	MD AC	none	0/4	0/15	NED 2 yrs
9	no residual	MD AC	none	0/2	0/9	NED 2 yrs
10	4.5 cm	WD AC	rare	2/7	0/15	NED 20 mo
11	microscopic	MD AC	none	0/1	0/21	NED 5 mo
12	1.0 cm	PD AC	rare	0/6	0/10	NED 4 mo

AC, adenocarcinoma; WD, well differentiated; MD, moderately differentiated; PD, poorly differentiated; NED, no evidence of disease; DOD, dead of disease

Conclusions: US improved SLN MT detection by 60%. All pts with negative SLN had negative nonSLN. Two of 3 pts with positive SLN died emphasizing the importance of MT detection in pts with NSqCA to assist in prognosis determination.

926 The Role of Cytokeratin 17 in the Distinction of Primary from Metastatic Mucinous Tumors of the Ovary

ED Euscher, MT Deavers, A Malpica. M.D. Anderson Cancer Center, Houston, TX.

Background: Distinction of a primary mucinous ovarian tumor (PMOT) from metastatic (MT) mucinous carcinoma in the ovary can be problematic. This is particularly true for MT pancreatic carcinoma (CA), which can be occult and share histological and immunohistochemical features with PMOT. Cytokeratin (CK) 17 has been reported to be expressed in pancreatic CA but absent in PMOTs. This study compares the expression of CK17 in PMOTs and MT pancreatic CA to the ovary. Mucinous tumors in which the primary remained uncertain (ovary versus non Mullerian), in which an extraovarian primary was favored, and mucinous tumors known to be MT from other sites (appendix, colon and cervix) were included for additional comparison.

Design: The institutional database for the period 1988-2007 was searched for mucinous ovarian tumors to include known PMOT (borderline and carcinoma), mucinous tumors of uncertain origin, mucinous tumors favored to be MT, and known MT mucinous tumors (upper GI, pancreas, appendix, and colon). Slides were reviewed without knowledge of the H&E diagnosis and scored semiquantitatively (0, no staining; 1+, 1-25% staining; 2+, 26-50% staining; 3+, 51-75% staining; 4+, >75% staining).

Results: 67 mucinous tumors involving the ovary were identified. Results are summarized in Table 1.

Histologic type (n=# of cases)	Cytokeratin 17 Expression in Mucinous Tumors Involving the Ovary				
	0	1+	2+	3+	4+
Ovarian Mucinous Tumor, Low Malignant Potential (n=15)	5	9	0	1	0
Ovarian Mucinous Carcinoma (n=14)	4	6	4	0	0
Uncertain, Primary vs. Metastasis (n=8)	4	3	0	0	1
Metastasis Favored, Primary Unknown (n=7)	4	3	0	0	0
Metastatic Pancreaticobiliary (n=10)	5	4	0	1	0
Metastatic Appendix (n=5)	3	1	0	1	0
Metastatic Colon (n=5)	5	0	0	0	0
Metastatic Cervix (n=3)	0	0	0	3	0

Conclusions: CK 17 is not useful to distinguish PMOTs from MT pancreatic CA. Mucinous tumors involving the ovary with 3+ or greater CK 17 expression are more likely to be metastatic than primary in the ovary. This antibody may have a limited role, in the proper clinical setting, for distinguishing PMOT from MT cervical mucinous adenocarcinoma to the ovary. Only MT colon cancer (uniformly negative) and MT cervical carcinoma (uniformly 3+ positive) had consistent patterns of CK17 expression.

927 Adenosarcoma with Sarcomatous Overgrowth, a Clinicopathologic Study of 37 Cases

ED Euscher, A Malpica. M.D. Anderson Cancer Center, Houston, TX.

Background: Uterine adenosarcoma is an uncommon tumor typically considered to be of low malignant potential. Rarely, uterine adenosarcoma can have large areas comprised solely of sarcoma. When such foci account for at least 25% of the entire tumor, the

tumor is described as having sarcomatous overgrowth. In this study we present the clinicopathologic features of 37 such cases.

Design: The institutional database was searched for cases of uterine adenocarcinoma with reported sarcomatous overgrowth from the period 1988-2007. All available H&E slides were reviewed, and only cases in which sarcomatous overgrowth comprised at least 25 % of the tumor were included in this study. Clinicopathologic features recorded included patient (pt) age, FIGO stage, presence/absence of heterologous elements, and follow up.

Results: The median pt age was 61 years (37-98 years). The FIGO staging distribution was as follows: stage I, 19 cases; stage II, 7 cases; stage III, 5 cases; stage IV, 2 cases; unknown stage, 4 cases. In fourteen cases, the sarcomatous overgrowth was represented by rhabdomyosarcoma. Six of the cases with rhabdomyosarcoma also had cartilaginous differentiation. One of them also had liposarcoma. In one of the cases with rhabdomyosarcoma, osteoid was observed. One case without rhabdomyosarcoma had cartilaginous differentiation. Follow-up ranging from 2 to 235 months (median 42.5 months) was available in 34 pts. Eight (57%) pts with rhabdomyosarcoma died of disease (stage I, 2 pts; stage II, 3 pts; stage III, 1 pt; unknown stage, 2 pts). One pt with rhabdomyosarcoma (unknown stage) died of unknown causes. Two pts were lost to follow up. Eight (35%) pts without rhabdomyosarcoma died of disease (stage I, 4 pts; stage II, 1 pt; stage III, 2 pts; stage IV, 1 pt), and one pt (stage I) died of unknown causes. Two pts were lost to follow up.

Conclusions: Patients with uterine adenocarcinoma and sarcomatous overgrowth comprised of rhabdomyosarcoma had a tendency to present with disease greater than stage I. Twenty-three percent of pts (stages I + II) with sarcomatous overgrowth without rhabdomyosarcoma died of disease while 63% of pts (stages I + II) with sarcomatous overgrowth comprised of rhabdomyosarcoma died of disease. These results appear to indicate that cases with sarcomatous overgrowth containing rhabdomyosarcoma portend a worse prognosis.

928 Clinicopathologic Features Associated with Cytohistologic Non-Correlation in the Diagnosis of High-Grade Dysplasia of the Cervix: An Investigation Based on Concurrently Obtained Samples

O Fadare, B Carns. Wilford Hall Medical Center, Lackland AFB, TX.

Background: Using the unique subset our database comprised of patients that obtained a Papanicolaou (Pap) test and a cervical biopsy during the same clinic visit, we sought to determine whether there are any histologic features associated with cytohistologic non-correlation relative to the diagnosis of high-grade dysplasia or higher (CIN2+) in these concurrently obtained samples.

Design: Our database was searched for any patients with Pap test/cervical biopsy combinations that were accessioned within 24 hours of each other for the period between 1/3/06 and 7/27/07. All pathologic material were reviewed in detail. A cytohistologic non-correlation was deemed to be present when either modality (Pap test or biopsy) displayed a CIN2+/HSIL whilst the other showed a less severe diagnosis. Cytohistologically correlating and non-correlating cases were then compared regarding the various clinicopathologic variables outlined in table 1. Any combinations associated with ASC-H or ASC-US interpretations were excluded. Statistical analyses were performed with Student's t and Fisher's exact tests, with p<0.05 considered significant.

Results: During this period, there were 17 correlating and 17 non-correlating cases. The less severe interpretation was in the Pap test in all 17 non-correlating cases, as all displayed LGSIL. (see Table 1 below).

Table 1: A comparison of the correlating and non-correlating cases.

Parameter	Correlating Cytohistologic Combinations (n=17)	Non-Correlating Cytohistologic Combinations (n=17)	p value
Average patient age (years)	33.1	30.8	0.37
Average number of biopsies obtained (range)	3.6 (1-5)	3.2 (1-4)	0.81
Percentage of biopsies obtained involved by CIN2+ (average)	75%	52%	0.03
Endocervical curettage obtained	15/17	17/17	0.24
Endocervical curettage positive for CIN2+	3/15	4/17	1
Glandular involvement by CIN 2+	7/17	9/17	0.73
CIN2	7/17	14/17	0.02
CIN3 or worse	10/17	3/17	0.02
Background CIN 1 present	10/17	15/17	0.12
Dense Inflammation	5/17	3/17	0.46

Conclusions: When the Pap test failed to capture a high-grade dysplasia in the concurrently obtained biopsy, 1) the dysplasia was more likely to be CIN2 than CIN3 -suggesting that the absence of basaloid proliferation in the most superficial epithelial layers in CIN2 is a contributor to cytohistologic non-correlation, and 2) a comparatively lower percentage of biopsies were involved by high-grade dysplasia, consistent with a smaller disease extent.

929 Ovarian Frozen Section Diagnosis: Use of Whole Slide Digital Imaging Shows Excellent Correlation between Virtual Slide and Original Interpretations in a Large Series of Cases

MA Fallon, DC Wilbur, ML Prasad. UMASS Memorial Medical Center, Worcester, MA; Massachusetts General Hospital, Boston, MA.

Background: Compared to current real-time digital methods, whole slide digital imaging (WSI) has the potential for improvements in telepathology, slide archiving and teaching. To test the reproducibility of frozen section (FS) interpretation using this technology, series of cases from specific organ systems must be analyzed in order to understand the technology limits and interpretive pitfalls unique to each organ system. The current study examines the reproducibility of a sequential series of routine ovarian FS converted to WSI.

Design: A pathology information system search identified a sequential series of ovarian FS cases representative of routine practice. The original FS slides were

retrieved and converted to whole slide digital images (virtual slides) using a Zeiss Mirax scanning device. Virtual slides were examined by 2 pathologists, masked to all prior results. A third pathologist compiled and compared these results to all original interpretations. Correlation rates were tabulated and discordant case types were verified and analyzed.

Results: 52 individual cases were included, consisting of a total of 71 frozen section slides. 34 cases (65%) were benign, and 18 cases (35%) were malignant/borderline/tumors of uncertain potential (9/7/2, respectively). Overall the correlation between WSI and original FS interpretations was 97% (69/71) for each pathologist when considering the broad categorization of benign vs. malignant/borderline/uncertain entities. Each pathologist undercalled 2 virtual slides as benign cysts; these were interpreted on the initial FS as borderline malignancy and shown to be such on permanents. There were no overcalls of benign cases. Common issues of specific classification within the benign and malignant types involved endometriosis vs. hemorrhagic corpora lutea, and granulosa cell tumor vs. carcinoma, respectively.

Conclusions: Overall the correlation between original FS and WSI interpretations was very high (97%) in this unselected, sequential group of cases representative of routine practice in a large hospital. The few discordant cases represent recognized differential diagnostic issues. Ability to examine gross pathology and real-time consultation with surgeons might be expected to further improve performance. Ovarian FS diagnosis by WSI is accurate, and thus remote interpretation of such common FS specimens by this methodology can be reliably utilized.

930 Morphoproteomic Evidence of Activated mTOR Pathway in Cervical Squamous Carcinoma and High-Grade Squamous Intraepithelial Lesions

W Feng, X Duan, J Liu, J Xiao, RE Brown. The University of Texas Medical School, Houston; The University of Texas MD Anderson Cancer Center, Houston.

Background: Human papillomavirus (HPV) infection of the uterine cervix is linked to the pathogenesis of cervical cancer. Preclinical studies using HPV-containing human cervical squamous cell carcinoma (SCC) cell lines have shown that the mammalian target of rapamycin (mTOR) inhibitor, rapamycin, and epidermal growth factor receptor (EGFR)-tyrosine kinase inhibitor, erlotinib, can induce xenograft growth delay. Therefore, we investigated: the expression level of EGFR in cervical SCC, high-grade squamous intraepithelial lesions (HSIL), and non-neoplastic cervical squamous epithelium; the activation state of the mTOR pathway in these same tissues; and any impact of these signal transduction molecules on cell cycle.

Design: Formalin-fixed paraffin-embedded tissue microarray blocks containing 20 samples each of normal cervix, HSIL and invasive SCC, derived from a total of 60 cases of cervical biopsies and conizations were examined. Immunohistochemistry was utilized to detect the following antigens: EGFR; mTOR pathway markers, phosphorylated (p)-mTOR(Ser 2448) and p-p70S6K(Thr 389); and cell cycle associated proteins, Ki-67 and S phase kinase-associated protein (Skp-2). Protein compartmentalization and expression were quantified in regard to proportion (0-100%) and intensity (0-3+). Mitotic index (MI) was also assessed.

Results: Plasmalemmal EGFR expression was limited to the basal/parabasal cells (2-3+) in normal cervical epithelium (NL), and positive in all HSIL (3+ in 19/20) and SCC (3+ in 18/20). Cytoplasmic p-mTOR expression was present in NL (1-2+, 51%), and was increased in intensity and proportion in HSIL (2-3+, 87%) and SCC (2-3+, 87%). Proportion of nuclear p-mTOR translocation was 100% in SCC lesions (SCC>NL, p<0.025). The pattern of nuclear p-p70S6K expression was similar to that of p-mTOR. Concomitant increases in MI and proportion of nuclear Ki-67 and Skp-2 expression were noted in HSIL and SCC.

Conclusions: Morphoproteomic analysis reveals constitutive activation of the mTOR pathway in HSIL and SCC as evidenced by: increased nuclear translocation of p-mTOR and p-p70S6K, phosphorylated at putative sites of activation, Ser 2448 and Thr 389, respectively; correlative overexpression of upstream signal transducer, EGFR, and increases in the Skp-2 and mitotic indices. These results suggest that the mTOR pathway plays a key role in cervical carcinogenesis and targeted therapies may be developed for SCC as well as HSIL.

931 Immunohistochemical Characterization of Epithelial and Stromal Changes in Endocervical Adenocarcinoma In Situ (AIS) and Invasive Adenocarcinoma (IA)

MB Flanagan, M Chivukula, DJ Dabbs. Magee-Womens Hospital, Pittsburgh, PA.

Background: The distinction between cervical AIS and IA is almost entirely histomorphologic and can be difficult. The utility of stromal changes that accompany malignant glandular transformation in making this distinction is under study. Our goal was to characterize the epithelial and stromal immunophenotype of cervical AIS and IA.

Design: Cases of IA (20) and pure AIS (26) were reviewed and a representative block from each case was stained for ER, SMA, p120, E-cadherin, Maspin, CD44, Bcl-2, and cMET. The intensity of stromal reaction (SR) on H&E around AIS and IA was graded from 0-3+. For each type of glandular component, intensity of each stain (0-2+) was noted within epithelium and surrounding stroma.

Results: SR around IA was 2-3+ in 14/20 cases (70%) and 0-1+ in 6/20 (30%), vs 2-3+ around AIS in 6/26 cases (23.1%) and 0-1+ in 20/26 (76.9%). 10/20 IA cases had AIS and 10/20 had normal glands (NG). ER staining was predominantly 2+ in NG nuclei and progressively less moving from AIS to IA (Table 1).

Table 1: ER nuclear staining

	NG	AIS	IA
2+	9/10 (90.0%)	1/9 (11.1%)	1/20 (5.0%)
1+	1/10 (10.0%)	8/9 (88.9%)	2/20 (10.0%)
0	0/10 (0.0%)	0/9 (0.0%)	17/20 (85.0%)

SMA stromal positivity was most intense around IA and progressively less intense moving from AIS to NG (Table 2).

Table 2: SMA stromal staining

	NG	AIS	IA
2+	0/16 (0.0%)	0/5 (0.0%)	5/20 (25.0%)
1+	3/16 (18.8%)	5/10 (50.0%)	11/20 (55.0%)
0	13/16 (81.2%)	5/10 (50.0%)	4/20 (20.0%)

Maspin staining was more frequently 1-2+ in AIS (8/9, 88.9%) and IA (18/20, 90.0%) relative to NG (3/11, 27.3%), but did not distinguish between AIS and IA. Bcl-2, CD44, and eMET stained few stromal cells around all entities indiscriminately. Maspin showed cytoplasmic staining diffusely in all entities. E-cadherin showed strong membranous staining in normal, in situ and invasive, glandular and squamous cells. P120 showed strong membranous and weak variable cytoplasmic staining in AIS and IA.

Conclusions: SR is more intense around IA than AIS. Progressive loss of epithelial ER expression and increasing periglandular stromal SMA expression correlate with progression from NG to AIS to IA. Maspin may be useful in the assessment of AIS and IA. These markers potentially can be used in an immunopanel to assess invasion. Strong membranous staining of p120 has to be evaluated further.

932 Down-Regulation of MIR-195 and MIR-497 from the MicroRNA Cluster at Chromosome 17p13.1 in Papillary Serous Carcinoma of the Peritoneum

RJ Flavin, P Smyth, M Ring, S Russell, A Laios, S O'Toole, J Li, K Denning, S Aherne, C Martin, B Sheppard, K Lao, O Sheils, JJ O'Leary. Trinity College, Dublin, Ireland; Applied Biosystems, Foster City, CA.

Background: Chromosome 17 has been implicated as a potential location of genetic events important in the pathogenesis of papillary serous carcinoma of the peritoneum (PSCP) as well as ovarian serous carcinoma (PSC). High frequencies of LOH have been described at chromosomal band 17p13.1 (the genomic locus for p53 and microRNA cluster miR-195 and miR-497) in both tumour types. In addition, PSCP exhibits a higher rate of LOH at most loci on Chromosome 17 when compared to PSC (including 17p13.1). Recently, it has been shown that the genomic locus for miR-195 and miR-497 exhibits DNA copy number losses in ovarian cancer. Here we show decreased p53 expression and downregulation of the microRNA cluster (miR-195 and miR-497) in PSCP relative to PSC.

Design: Total RNA was extracted from 20 PSC and 20 PSCP FFPE cases of high grade and advanced FIGO stage using Ambion RecoverAll™ Total Nucleic Acid Extraction Kit. An early release stemloop RT/PCR kit was used for miRNA gene expression profiling (ABI). Analysis of relative miRNA expression data was performed using the $\Delta\Delta Ct$ method. Let-7 was used as normaliser. miRGen was used to analyse predicted miRNA targets. Pathway analysis was performed using the PANTHER™ Classification system. P53 mutations were detected by immunohistochemical protein overexpression on a TMA containing 73 PSCP/PSC tumours of high grade and advanced FIGO stage.

Results:

miRNA	Fold Change	p-value
miR-195	0.082943	2.29E-24
miR-497	0.002397	7.44E-60

Downregulation of miR-195/497 in PSCP v PSC

Over-representation of potential pathways ($p < 0.05$) affected by downregulated miRNAs includes the angiogenesis, FGF, T-cell activation and WNT signalling pathways. P53 overexpression was detected in 79% (23/29) of PSCP tumours versus 93% (41/44) of PSC tumours.

Conclusions: miR-195 and miR-497 may have a role as tumour suppressor genes in ovarian and primary peritoneal serous carcinoma pathogenesis.

933 Pathologic and Epidemiologic Study of a Candidate Precursor to Pelvic Serous Cancer in BRCA+ Women

A Folkins, L Garrett, A Saleemuddin, S Tworoger, CP Crum. Brigham and Women's Hospital, Boston, MA.

Background: Recent studies have described a putative precursor to pelvic serous cancer in the distal fallopian tube - the p53 signature - which shares location, cell type, p53 immunolocalization, DNA damage, and p53 mutations with its malignant counterpart. Because of this association, the p53 signature is a potential surrogate endpoint for pelvic serous cancer risk and provides the opportunity to ascertain the factors that are associated with the initial phase of serous carcinogenesis. This study examined a cohort of women with heritable BRCA mutations (BRCA+) and compared the presence of p53 signatures with demographic factors.

Design: Ovaries and fallopian tubes from 75 BRCA+ women were fully examined. All sections of ovaries and tubes were immunostained for p53 to identify p53 signatures. p53 signatures were correlated with age, age at first childbirth, age at menopause, basal metabolic index (BMI), gravidity, menarche, parity, use of OCPs, and presence of cystic follicles in the ovary. Statistical analysis was performed with the T-test.

Results: Thirty seven percent of tubes contained p53 signatures. Presence of p53 signatures correlated with age at first childbirth (30.7 v. 28.5 yrs; $p = 0.045$) and parity (1.32 v. 2.17; $p = 0.006$). There was a non-significant trend towards lower BMI ($p = 0.13$) and lower gravidity ($p = 0.15$).

Conclusions: This is the first epidemiologic study of a candidate precursor (p53 signature) to pelvic serous cancer in BRCA+ women. It reveals significant associations between the p53 signature and both lower parity and higher age at first childbirth, two risk factors that have been previously associated with ovarian cancer. The significance of these findings must be resolved by a multivariate regression model. However, correlations of this type provide the unique opportunity to address risk factors that operate at the earliest stages of pelvic carcinogenesis and to determine if the p53 signature is a marker for serous cancer risk.

934 A Multicentric Prospective Study of Hormonal Therapy for Atypical Endometrial Hyperplasia and Endometrial Carcinoma in Young Women: Histologic Changes and Treatment Outcome

M Fukunaga, K Ushijima, H Yahata, T Kamura, H Yoshikawa, H Tsuda, A Sakamoto. Jikei University Daisan Hospital, Komaeshi, Tokyo, Japan; Kurume University, Kurumeshi, Fukuoka, Japan; Tsukuba University, Tsukubashi, Ibaragi, Japan; National Defense Medical College, Tokorozawashi, Saitama, Japan; Kyorin University, Mitakashi, Tokyo, Japan.

Background: The conservative treatment for young women with atypical endometrial hyperplasia (AH) and endometrioid adenocarcinoma, grade 1 (EAG1) who desire to conceive has been challenging issue. Medroxyprogesterone acetate (MPA) is one of the options, but there have been few comprehensive reports of histologic effects by MPA therapy and its treatment outcome.

Design: This multicentric prospective study was carried out at 16 institutions in Japan. 28 patients having EAG1 at presumed stage IA and 17 patients with AH at younger than 40 years of age were enrolled. All patients were given MPA 600mg orally daily and the treatment was continued for 26 weeks if the patients responded. Endometrial tissue was histologically assessed by at 8, 16 and 26 weeks. Posthormonal treatment hysterectomy specimens were also evaluated. This study investigated the histologic effects and efficacy of treatment.

Results: Six patients with EAG1 voluntarily withdrew from this study and underwent hysterectomy before the completion of the therapy. Complete response, defined as the absence of any endometrioid adenocarcinoma or hyperplasia, was observed in 12 patients with EAG1 (53.5%) and 10 with AH (54.5%). Partial response, defined as regression to complex or simple hyperplasia, was observed in 1 with EAG1 (5.9%). Almost all cases showed a decreased gland-to-stromal ratio, decreased glandular cellularity, decreased N/C ratio of epithelial cells and various epithelial metaplasia but glandular confluent structures often persisted, leading to difficulties in the histologic evaluation of lesions. During the 3-year follow-up period, 12 pregnancies and 7 normal deliveries were achieved after MPA therapy. A recurrent lesion in the endometrium was found in 8 patients with EAG1 and 6 with AH.

Conclusions: The efficacy of fertility-sparing treatment with MPA for AH and EAG1 was proven by the prospective trial. New diagnostic criteria applicable to hormonally affected EAG1 or AH are needed for the precise evaluation of fertility-sparing treatment outcome. Even in the responders, close follow up is required because of their substantial recurrence rate.

935 Ovarian Atypical Endometriosis: Its Close Association with Malignant Epithelial Tumors

M Fukunaga. Jikei University Daisan Hospital, Komaeshi, Tokyo, Japan.

Background: Endometriosis is a relatively common condition found in up to 29% of women undergoing laparotomy. But little is known about the incidence of ovarian atypical endometriosis (AEM) and its relation to ovarian carcinomas.

Design: A series of consecutive cases coded as ovarian endometriosis (EM), ovarian carcinoma, or borderline tumor during the period 1987 to 2006 was retrieved from the surgical pathology files at our hospitals and was clinicopathologically analyzed. The diagnosis of AEM was based on the presence of epithelial features: large hyperchromatic or pale nuclei with moderate to marked pleomorphism; increased nuclear to cytoplasmic ratio; and cellular crowding, stratification, or tufting. Three or more of these criteria must be present.

Results: Atypical glandular changes without ovarian epithelial tumor were observed in 6 (1.1%) of 534 ovarian EM cases. The changes were always focal findings. One patient with ovarian AEM had synchronously endometrioid carcinoma and AEM in the subserosal of the uterus. One patient with ovarian AEM developed endometrioid carcinoma in the abdominal wall 18 months after left oophorectomy. The remaining four ovarian AEM patients without ovarian neoplasm did not develop any malignant epithelial tumors in a follow-up study with average of 6.5 years and a range of 4 to 9 years. Eighty-four (21.4%) of 393 ovarian cancers were associated with ovarian EM; 45 with typical EM and 39 with AEM. Clear cell and endometrioid carcinomas were most frequently associated with EM, with 42.0% (37 of 88 cases) and 32.8% (20 of 61), respectively. AEM was found in 20 clear cell carcinomas, in 12 endometrioid carcinomas, three serous carcinomas, three mucinous borderline tumors (Mullerian type) and one serous borderline tumor. In 15 cases, AEM was contiguous with carcinomas. Epithelial metaplasia, including eosinophilic, ciliated and mucinous metaplasia, was more often observed in AEM (45 of 45) than in ME (346 of 534).

Conclusions: Although ovarian AEM without neoplasms is a rare phenomenon, AEM possesses a precancerous potential and is most frequently associated with clear cell and endometrioid carcinomas. Epithelial metaplastic changes are also associated with AEM. EM with mucinous metaplasia and glandular hyperplasia may precede Mullerian mucinous borderline tumors. Close screening of cellular atypia, hyperplasia, or epithelial metaplasia in ovarian EM is required. It is proposed that a diagnosis of AEM be followed by careful long-term observations of the patient to detect possible subsequent development of neoplasia.

936 Diagnostic Yield of Cervicovaginal Samples in Patients with Uterine Serous Papillary Carcinomas

MT Garcia, E Jimenez, JM Pearson, P Ganjei-Azar. University of Miami / Jackson Memorial Hospital, Miami, FL.

Background: Routine cervicovaginal screening has had a little impact on the detection of the usual endometrial carcinomas with a sensitivity of 35 to 55%. However the diagnostic accuracy of this screening test in cases of high risk uterine carcinomas, i.e. uterine papillary serous carcinomas (USPC) has not been reported. The aim of this retrospective study is to determine the diagnostic yield of conventional cervicovaginal smears in patients with USPC who underwent hysterectomy.

Design: Of 140 cases of endometrial carcinoma, 32 patients were diagnosed with UPSC over a 5-year-period at our institution. The patients who had cervicovaginal smears obtained within six months prior to hysterectomy were included in this study. Routinely prepared (alcohol-fixed-Papanicolaou-stained) conventional cervicovaginal smears were reviewed and the cytologic findings were correlated with the size, location and stage of the uterine tumors.

Results: Twenty patients (62.5%) diagnosed with UPSC had cervicovaginal smears performed at our institution. Their age ranges from 46 to 74 years (mean 60.5 years). In the retrospective review, two (10%) were negative for malignant cells, 1 (5%) showed dysplasia, 2 (10%) atypical cells of glandular origin and 15 (75%) adenocarcinoma. Helpful diagnostic features included papillae formation and accentuated 3-dimensionality. The proportion of patients with adenocarcinoma diagnosed on the cervicovaginal smears with I, II, III or IV stage was 83.3%, 0%, 66.7%, and 100%, respectively. The cervicovaginal smears diagnosed as adenocarcinoma were located in the corpus (10/13, 76.9%), fundus (2/3, 66.7%), lower uterine segment (1/2, 50%) and in a polyp (1/1, 100%). The tumor size of cytologically positive cases ranged from 1 to 12 cm and in negative cases ranged from 2.2 to 7 cm.

Conclusions: Although conventional cervicovaginal smears are not sensitive screening tests for early detection of the usual endometrial carcinomas, the yield for positive diagnoses in patients with uterine papillary serous carcinomas is high. This high detection rate does not appear to correlate with the tumor size, location or pathologic stage but with the high histologic grade of these tumors.

937 IHC for DNA-MMR in EEC in a Selected Group of Patients

K Garg, N Kauff, J Hansen, K Kosarin, J Shia, RA Soslow MSKCC, New York, NY.

Background: Endometrioid adenocarcinoma of the endometrium (EEC) has been shown to be associated with defects in the DNA mismatch repair system (DNA-MMR) and is the most frequent extracolonic tumor in hereditary non polyposis colorectal cancer syndrome (HNPCC). Microsatellite instability (MSI) has been reported in 75-90% of retrospectively studied endometrial carcinomas associated with HNPCC and 20-30% of sporadic endometrial carcinomas. This study assessed the distribution DNA-MMR abnormalities using immunohistochemistry (IHC) and to study the morphology and clinical features in a selected group of patients.

Design: Selection criteria: We routinely perform DNA-MMR IHC in tumors from patients 50 years or younger, in patients with a strong personal or family history suggestive of HNPCC and when morphologic features are present that raise the possibility of MSI (such as numerous tumor infiltrating lymphocytes [TILs]). The DNA-MMR IHC panel, including stains for MLH1, MSH2, MSH6 and PMS2, was performed and analyzed on cases that met selection criteria. The results were interpreted as absent or intact expression for each marker in the presence of a positive internal control.

Results: 38 cases met selection criteria and 18 showed loss of at least one marker by IHC. One case was not interpreted due to lack of internal positive control. Of these 18 patients, 6 were age 50 years or younger (31-50 yrs) and 12 were older (54-76 yrs). In patients 50 years or younger, the prevalence of DNA-MMR by IHC was found to be 33%.

	Normal IHC (n = 19)	Abnormal DNA-MMR IHC (n = 18)
MEDIAN TIL's	51	174.5
LVI	2/19	8/18
FIGO GRADE	1-2: 16/19, 3 = 3/19	1-2: 9/18, 3: 9/18
STAGE	I: 19/19	I-II: 13/18, III-IV: 5/18
MEDULLARY LIKE	None	5/18
PERSONAL OR FAMILY HISTORY SUGGESTIVE OF HNPCC	None	9/18

	Abnormal IHC pattern
MLH1 and PMS2 loss	10/18 (55%)
MSH2 loss	2/18 (11%)
MSH6 loss	3/18 (17%)
MSH2 AND MSH6 loss	3/18 (17%)

Conclusions: The most common IHC defects were observed in MLH1 and PMS2 but abnormalities in MSH2 and/or MSH6 were almost as common. This is different from most sporadic MSI-high endometrial carcinomas, which show abnormal MSH2/MSH6 much less frequently. A significant number of these patients had personal history of extrauterine tumors and personal/family history suggestive of HNPCC. This suggests that these discussed selection criteria enable identification of a population of women with endometrial carcinoma enriched for those at highest risk of heritable endometrial carcinoma.

938 Histologically Indolent Thyroid Carcinoma Arising in Struma Ovarii Can Recur and Metastasize

K Garg, M Rivera, RA Soslow, R Ghossein MSKCC, New York, NY.

Background: Struma ovarii infrequently harbor carcinomas that are histologically similar to those arising in the eutopic thyroid. The pathologic and clinical data on these carcinomas is very scarce.

Design: We reviewed our surgical pathology database from 1980 to 2007 for thyroid type carcinomas arising in struma ovarii. 13 met the selection criteria. All available slides were reviewed (10 cases).

Results: The median age at presentation was 41.5 years (range: 32-64). Median follow up was 6 months (3-72 months). 8 patients presented with pelvic related symptoms and 2 were incidentally discovered during pregnancy. All patients presented with disease confined to the ovary including 1 patient with bilateral tumors. There were 8 papillary carcinomas (2 classical, 6 follicular variant) and 2 poorly differentiated thyroid carcinomas defined on the basis of high mitotic activity (5 mitosis per 10 HPF) and/or tumor necrosis. The median size of the carcinoma was 0.8 cm (range: 0.11 to 5 cm). 8 of the tumors were well defined without obvious invasion while 2 infiltrated the ovarian stroma. Vascular invasion was present in one FVPTC. There were 2 associated mucinous cystadenomas and a mature contralateral ovarian teratoma. 2 of the 10 thyroid

carcinomas relapsed after an initial diagnosis of "benign" struma, discovered during pregnancy. The 2 recurring tumors were well differentiated (see following).

AGE (yrs)	PRESENTATION	PATHOLOGY	EUTOPIC THYROID STATUS	RECURRENCE	THERAPY	LAST FOLLOW UP
34	cyst during pregnancy	FVPTC, infiltrative, confined to ovary	Benign	4 years after diagnosis in pelvic serosa, diaphragm and liver	Bilateral salpingo-oophorectomy (BSO) and radioactive iodine (RAI) therapy after thyroidectomy (TT)	No evidence of disease at 6 yrs
38	cyst during pregnancy	FVPTC, non-infiltrative, confined to ovary	Benign	3 years after diagnosis in pelvic serosa, omentum and contralateral ovary	BSO and RAI after TT	Alive with disease at 6 yrs

Conclusions: 1) The criteria separating hyperplastic nodules from well differentiated FVPTC in the thyroid gland appear to be applicable to thyroid type carcinomas arising in struma ovarii as shown by 2 cases of recurrent/metastatic FVPTC defined by nuclear features 2) Apparently histologically indolent thyroid carcinomas (such as well differentiated FVPTC) confined to the ovary can recur and metastasize. 3) The propensity for adverse behavior does not seem to be related to grade or histologic type of carcinoma 4) Clinicians should be informed of the potential for metastasis even in tumors with no adverse histologic features.

939 p53 Overexpression in Morphologically Ambiguous Endometrial Carcinomas Correlates with Adverse Clinical Outcomes

K Garg, RA Soslow, MW Guile, MM Leitao, Jr. MSKCC, New York, NY.

Background: Uterine papillary serous carcinomas (UPSCs) and endometrial endometrioid carcinomas (EEC) can occasionally be difficult to distinguish on routine histologic examination. p53 immunohistochemistry (IHC) is used in problematic cases, but this approach has been criticized because of philosophical differences involving nosology (but not clinical biology). This is a study of difficult to classify endometrial carcinomas using p53 IHC. The goal was to determine whether p53 overexpression (p53-O) had clinical significance. We hypothesized that histologically ambiguous endometrial carcinomas showing p53-O would be clinically aggressive, thereby supporting the idea that p53-O in tumors with some features of UPSC are in fact UPSCs.

Design: All difficult to classify endometrial carcinomas diagnosed at our institution were studied with p53 IHC (n=52). P53-O was defined as intense nuclear staining in more than 75% of tumor cells in any low power field. Statistical analyses were performed using SPSS 15.0 statistical package (Chicago, IL).

Results: Diffuse or geographic p53-O was found in 22 and 8 cases, respectively. The demographic and clinical features of these cases were similar but as a group they differed from cases lacking p53-O (n=22). 24 of 30 patients with p53-O and 15 of 22 patients lacking p53-O were treated with chemotherapy and/or radiation therapy. After adjustment for age and stage, patients with p53-O tumors had higher rates of recurrence and death due to disease (p=0.03 and 0.02, respectively). There was only 1 death in all 21 patients (p53-O and lacking p53-O) with stage I disease. In patients with stage III/IV disease, 7 (47%) of 15 with p53-O died of disease compared to none of the patients lacking p53-O (p = 0.05 and log-rank for disease specific survival (DSS) = 0.03).

	p53 overexpression (n = 30)	No p53 overexpression (n = 22)	P value
MEDIAN AGE	68	59	0.06
RACE	W = 77%, AA = 23%	W = 95%, AA = 5%	0.12
STAGE	Stage I: 40%, Stage III-IV: 60%	Stage I: 58%, Stage III-IV: 42%	0.24
RECURRENT	35%	5%	0.03
DEAD OF DISEASE	31%	0%	0.02

Conclusions: p53 overexpression in morphologically ambiguous endometrial carcinomas is predictive of adverse outcome, especially in advanced stage cases, irrespective of the diffuse or geographic nature of p53-O. These data may be useful for prognosis assessment and treatment planning and, depending on one's viewpoint, could be used as a diagnostic adjunct.

940 Clinical and Pathologic Findings in Women with Endometrial Carcinoma: Does the Pap Test Matter?

KN Gilbert-Lewis, VJ Schnadig, EM Betancourt University of Texas Medical Branch, Galveston, TX.

Background: The Bethesda System 2001 (TBS 2001) guidelines recommend reporting of benign endometrial cells only in women over age 40. Recent surveys suggest this may lead to excessive diagnostic procedures. At our institution, endometrial carcinoma has been found in women < 40 years of age, and benign endometrial cells are reported, as a comment only, in women of all ages. This study is to determine the contribution of the Pap test to the diagnosis of endometrial neoplasia after examining other risk factors including weight and presence of abnormal abdominal examination (AAE) or uterine bleeding (AUB).

Design: Computer search retrieved all cases of endometrial malignancy from 2003 through August, 2007. Clinical and laboratory records were reviewed to obtain patients' age, body mass index (BMI), findings on presentation that led to biopsy and results of Pap tests performed within one year prior to diagnosis. Pap tests were only considered as potentially significant if performed prior to diagnostic biopsy.

Results: One hundred seven cases were identified for which clinical information could be obtained. Ninety-five had endometrioid adenocarcinoma (EEA), and 12 had a high grade, non-endometrioid carcinoma (NEEA), such as papillary serous carcinoma. Of the EEA, there were 6 women < 40 years of age. Their mean BMI was 40, and 50% were obese with a BMI >30. All presented with abnormal uterine bleeding (AUB), and,

therefore, Pap tests did not instigate biopsy. There were 28 patients between the ages of 44 and 55 years. Their mean BMI was 35, and 64% had a BMI > 30. Twenty-three (82%) presented with either AUB or AAE. Two patients had AGUS Paps prior to diagnosis without recorded AAE or AUB. There were 68 women > 55 years of age with a mean BMI of 35 and 74% with a BMI > 30. Ninety percent presented with AUB. One AGUS Pap test was found without accompanying AUB or AAE. There were 12 women with NEEA. Sixty-six percent had a BMI > 30. Ten (83%) had AUB. In no cases was the Pap smear abnormal in the absence of AUB.

Conclusions: Most of the women in this series had BMI in the overweight to morbidly obese categories regardless of type of neoplasia or age. In this study, the Pap test alone was the likely instigator of biopsy in only 3 (3%) of the women with EEA or NEEA. There were 6 women under 40 with EEA. None had Pap tests at our institution, but by TBS 2001 guidelines, endometrial cells would not have been reported.

941 Epigenetic Mechanism Is Responsible for Downregulation of Prostate-Specific Membrane Antigen (PSMA) in a Subset of Endometrial Carcinomas

D Higgs, D Smiraglia, K Odunsi, F Herrmann, P Mhawech-Fauceglia. Roswell Park Cancer Institute, Buffalo, NY; HUG, Geneva, Switzerland.

Background: Previously, we reported that higher PSMA mRNA levels were significantly associated with stage I endometrial carcinoma (EC) and with PSMA protein intensity by immunohistochemistry (IHC). In addition, loss of PSMA expression was an independent predictive factor for worse disease free survival. The aim of this study was to explore the role of CpG methylation in downregulation of PSMA in EC.

Design: 3 prostate cell lines (DU145, LNCAP, pC3) and 2 endometrial cell lines (HECLA and RL-95), in addition to 30 samples with low, moderate, and high m-RNA values were evaluated by methylation specific PCR. Association of the methylation tumor status to variables such as age, tumor size, grade, stage, depth of invasion, histology subtypes, and disease outcome was evaluated using Fischer exact test to compare binary variables.

Results: In cell line, PSMA showed methylation in 2/3 prostate cell line (DU145, pC3) as already published in the literature, and in both endometrial cell lines. For patients samples, the analysis of DNA methylation was inconclusive in 12 samples (not shown in table 1). However, for the 18 other samples we have conclusive data; 3/18 showed methylation (samples 943, 957, 940), and another 2 showed very faint methylation (samples 945 and 946) as seen in table 1.

Table 1.

Sample	PSMA-MSP Meth	PSMA-RNA	IHC	Grade/Stage	Depth %	Histology	Tumor Size
941	No	Low	-	G1/I	82	Em	6
943	Yes	Low	-	G3/II	1	Em	7
957	Yes	Low	-	G3/IV	93	Ser+CC	7
942	No	Low	+	G3/II	89	Em	2.2
940	Yes	Low	-	G1/II	16	Em	4.5
945	Yes	Low	-	G3/I	75	Em+CC	9
947	No	Low	-	G1/I	6	Em	5.5
946	Yes	Low	-	G2/II	90	Em	6
932	No	Med	-	G1/I	0	Em	1.7
937	No	Med	+	G3/IV	90	Em	7.5
936	No	Med	+	G2/III	87	Em	4.5
938	No	Med	-	G1/I	12	Em	6
931	No	Med	+	G1/I	0	Em	2
933	No	Med	+	G1/I	8	Em	3.2
948	No	High	+	G2/I	30	Em	2.5
954	No	High	+	G1/I	15	Em	5
958	No	High	-	G2/I	10	Em	5.5
951	No	High	+	G3/I	75	Em	3
DU145	Yes						
HECLA	Yes						
LNCAP	No						
pC3	Yes						
RL-95	Yes						

EM=endometrioid; Ser=serous; CC=clear cell; -=neg; +=pos

There was a significant association between PSMA methylation and loss of protein expression by IHC ($p=0.036$) and PSMA-RNA level ($p=0.011$). In addition, there was an association between PSMA-methylation and tumor size ($p=0.025$).

Conclusions: We conclude that CpG methylation plays a crucial role in downregulation of PSMA at least in a subset of endometrial carcinomas.

942 Are the Endometrial Serous Carcinomas Underdiagnosed? Histomorphologic and Immunohistochemical Correlates in High Grade Endometrial Carcinomas, Initially Diagnosed as High Grade Endometrioid Adenocarcinomas

JL Hinson, ML Cibull, RG Karabaktshian. University of Kentucky, Lexington, KY.

Background: High grade (HG) endometrial adenocarcinomas (EAs) are a group of diverse and often diagnostically challenging tumors associated with different molecular oncogenesis and clinical outcome. In retrospective studies it appears that the biological behavior of some "HG EMCs" is worse than that expected for these neoplasms. The important question remains whether a subset of HG EMCs actually represents a SC with endometrioid-like architectural pattern. The aim of this study is to determine the utility of selected IHC markers in separating these distinct subtypes as they relate to clinical outcome.

Design: 43 HG EAs initially classified as pure HG EMC ($n=32$), mixed HG EMC/ SC ($n=9$), and mixed HG EMC/CC ($n=2$) were stained with p53, p16, ER, and MG cocktail antibodies. P53 and p16 were scored positive if >75% tumor cells, and ER if >5% of tumor cells showed immunoreactivity. MG was evaluated as described previously (Abstract, USCAP 2006, Onuma, Dabbs, Bhargava). Clinical follow-up information was obtained (mean interval 41 months). Clinical outcomes for stage-to-stage disease were compared for different subtypes.

Results: Based on positivity for p53 and p16, 17/43 (39%) of initially diagnosed HG EMCs were reclassified as SCs. All 17 cases were negative for MG, while ER was negative in 11/17 (65%). The remaining HG EMCs were negative for p53 and p16 in 25/26 (96%) and 20/26 (77%) cases, respectively; MG was positive in 8/26 (31%), and ER in 19/26 (73%). The reclassified 17 cases initially presented as FIGO stage1 in 6/17 (35%), stage2 in 2/17 (12%), stage3 in 8/17 (47%) and stage4 in 1/17 (6%). The remaining HG EMCs ($n=26$) were stage1 in 13/26 (50%), stage2 in 4/26 (15%), stage3 in 7/26 (27%), and stage4 in 2/26 (7%).

Initial Dx	Reclassified HG EAs by Selected IHC Markers			Total	Alive/Disease Free at follow-up
	Pure HG EMC	Mixed HG EMC/SC	Mixed HG EMC/CC		
Total No of EAs	32/43 (74%)	9/43 (21%)	2/43 (5%)	43/43 (100%)	18/43 (42%)
Reclassified as SCs	11/32 (34%)	5/9 (56%)	1/2 (50%)	17/43 (39%)	3/17 (18%)
Remaining HG EMCs	21/32 (66%)	4/9 (44%)	1/2 (50%)	26/43 (61%)	15/26 (58%)

Conclusions: 1) HG EMCs and SCs with glandular morphology are difficult to distinguish by histology alone. 2) Selected IHC panel (p53, p16, MG, ER) may be helpful in distinguishing a subgroup of tumors with a serous rather than endometrioid phenotype. 3) MG demonstrates higher specificity than ER, and is superior to ER in differentiating HG EMCs from SCs.

943 The Metastasis-Associated Protein 1 (MTA1) Is a Prognostic Biomarker for Papillary Serous Ovarian Carcinoma

MD Hofer, J Liu, MA Rubin, UA Matulonis, MS Hirsch. Brigham and Women's Hospital, Boston, MA; Dana Farber Cancer Institute, Boston, MA.

Background: Advanced papillary serous ovarian carcinoma (PSOC) is currently associated with poor outcome, so identifying biomarkers that could stratify prognosis would be clinically useful. Prior reports have shown moderate to high expression of metastasis-associated gene 1 (MTA1) in PSOC, but the findings were not correlated with menopausal (hormonal) status or clinical outcome. We evaluated MTA1 expression in advanced PSOC in young and older patients, and correlated the findings with clinical outcome, hypothesizing that menopausal status may affect MTA1 expression.

Design: MTA1, ER and PR immunostaining was performed on 4 TMAs with 132 high grade, high stage (III-IV) PSOC. Patients were divided into 2 cohorts by age: ≥ 65 and ≤ 55 at diagnosis. MTA1 was scored using an automated microscope system (ACIS II). Clinical data were obtained by chart/database review. MTA1 expression was scored as high (>median) or low (<median) staining intensity.

Results: For all cases, high MTA1 expression was significantly associated with risk of death in univariate regression (HR 1.60; 95% CI 1.01-2.51; $p=0.04$) and Kaplan-Meier (log-rank $p=0.04$) analyses, but not in a multivariate model which also included age, stage, optimal debulking, and platinum-sensitivity. Subgroup analyses were performed for age and platinum-sensitivity after statistical analysis suggested the presence of effect modification. In univariate and multivariate regression models, high MTA1 expression was an independent predictor for risk of death in the older cohort ($N=48$; HR=2.66; 95%CI 1.06-6.68; $p=0.04$) and in patients with platinum-sensitive PSOC ($N=65$; HR=2.48, 95%CI 1.05-5.84; $p=0.04$). MTA1 expression did not predict adverse outcome in the younger cohort, or platinum-resistant PSOC. Older patients were more likely to express ER and less likely to express PR than younger patients ($p=0.01$); however, ER and PR expression did not correlate with survival.

Conclusions: High MTA1 expression significantly correlates with increased risk of death in older patients (age ≥ 65) and in patients with platinum-sensitive PSOC. This data demonstrates statistical differences of MTA1 expression in younger vs. older women with PSOC, and suggests that MTA1 may be a useful biomarker of poor prognosis in post-menopausal women and in those with platinum-sensitive PSOC. Further analysis is warranted to address the association of MTA1 with ER and PR expression, as ER is also overexpressed in the older patients.

944 Cytologic and Immunohistochemical Features (p16^{INK4a}, p53, pRb, and Ki-67) of Cervical Papillary Immature Metaplasia (Immature Condyloma)

W-C Huang, C-W Liang, K-T Kuo, Y-T Lin, M-C Lin. National Taiwan University Hospital, Taipei, Taiwan; Cathay General Hospital, Taipei, Taiwan.

Background: Papillary immature metaplasia (PIM) is an uncommon variant of low-grade squamous intraepithelial lesion (LSIL). It is characterized by a distinct filiform papillary growth pattern and composed of squamous cells that fail to mature by maintaining a picture closely resembling immature metaplasia. Most lesions are infected by low-risk HPV types, especially 6 and 11. However, the etiology and biologic behavior of the disease are still not well-established, and, meanwhile, due to its immature appearance, it shares some histologic and cytologic features with papillary squamous carcinoma in situ (PSCIS) and papillary squamous carcinoma (PSC) that sometimes makes distinction between them difficult.

Design: Fifteen PIM and 9 PSCIS/PSC specimens diagnosed in National Taiwan University Hospital from 1999-2004 were collected. We compared the immunohistochemical expression of p16, pRb, p53, and Ki-67, and nested-polymerase chain reaction based genechip HPV typing between these two groups in order to identify the biomarkers that would be helpful for the differential diagnosis. In addition, conventional Papanicolaou (Pap) smears for 13 PIM cases, which were performed before each biopsy, were reviewed to evaluate the value of cytology in diagnosing PIM.

Results: Pap smears of PIM cases showed normal (47%), reactive changes (29%), atypical squamous cells of undetermined significance (ASCUS) (6%), or LSIL (18%). All PIM were confirmed to have low-risk HPV infection (3 HPV6, 11 HPV11, and 1 HPV70), while all PSCIS/PSC were proved having HPV16. The Ki-67 index of PIM (30±9%) was higher than that of adjacent uninvolved squamous epithelium (9±3%), but markedly lower than that of PSCIS/PSC (78±11%) ($p<0.01$). p53 staining was much lower in the PSCIS/PSC (15±17%) than in PIM (50±10%) ($p<0.01$). All PSCIS/PSC were negative for pRb, while 10 PIM (66.7%) were focally to diffusely positive ($p<0.01$). p16 staining

showed a spectrum of changes in PIM, ranging from negative or sporadic to patchy. In contrast, p16 staining in PSCIS/PSC showed diffuse full-thickness positivity.

Conclusions: Conventional Pap smear is not a reliable tool in diagnosing PIM. Combining HPV typing and immunohistochemical stains of Ki-67, p53, pRb, and p16 is useful for distinguishing PIM from PSCIS/PSC.

945 Overexpression of Insulin-Like Growth Factor Receptor 1 (IGF-1R) Protein Is Associated with Grade and Stage in Endometrial Carcinoma

CK Ibrahim, JJ Xiong, E Slodkowska, CE Sheehan, JS Ross. Albany Medical Center, Albany, NY.

Background: Traditional histologic features of resected endometrial adenocarcinomas (EC) have successfully predicted tumor stage and clinical course of the disease. However, in an individual patient, biopsy results may not always accurately predict the tumor stage and aggressiveness. The IGF-1R is a tyrosine kinase growth factor receptor that has been linked to prognosis in a variety of malignancies. Activation of IGF-1R by autocrine, paracrine and endocrine stimulation via exposure to its activating ligand, insulin, leads to cell growth. The prognostic significance of IGF-1R expression in EC has not been previously studied.

Design: Formalin-fixed paraffin-embedded tissue sections from 81 endometrioid carcinomas (EC) and 17 uterine papillary serous carcinomas (PSC) were immunostained by an automated method (Ventana Medical Systems Inc., Tucson, AZ) using mouse anti-human IGF-1R antibody (sc-462; Santa Cruz Biotechnology, Santa Cruz, CA). Cytoplasmic immunoreactivity was semiquantitatively scored based on staining intensity and distribution and the results were correlated with morphologic and prognostic variables.

Results: Overexpression of IGF-1R was observed in 54% (44/81) EC and 41% (7/17) PSC and correlated with overall tumor grade ($p=0.002$) and stage ($p=0.05$). In the endometrioid carcinoma subtype, along with grade ($p=0.001$) and stage ($p<0.0001$), IGF-1R overexpression also correlated with the depth of myometrial invasion ($p=0.04$). No significant correlation was found with lymph node status or survival.

Conclusions: IGF-1R appears to be overexpressed in similar rates in both endometrioid and non-endometrioid EC. Overexpression of IGF-1R also appears to associate with adverse prognostic features including tumor grade and stage in both endometrioid and papillary serous carcinomas. Given these findings and the current clinical development of IGF-1R targeted therapies, further study of IGF-1R expression in EC appears warranted.

946 Microcystic Stromal Tumor of the Ovary: Report of 12 Cases of a Hitherto Uncharacterized Distinctive Ovarian Neoplasm

JA Irving, RH Young. Royal Jubilee Hospital, Victoria, Canada; Massachusetts General Hospital, Boston.

Background: 12 distinctive ovarian stromal neoplasms with a prominent microcystic pattern, "microcystic stromal tumor", are described for the first time.

Design: All 12 cases were retrieved from our consultation files. Available blocks had immunohistochemistry performed for inhibin, calretinin, cytokeratin, vimentin, CD10, and epithelial membrane antigen.

Results: Patients ranged from 26 to 63 (mean 47) years. Most presented with a pelvic mass. None had evidence of extra-ovarian spread. All tumors were unilateral, with a mean size of 10.1 (range 4–27) cm. The encapsulated tumors were solid-cystic (9 cases), predominantly cystic (2 cases), or solid (1 case). All had lobulated cellular masses with intervening hyalinized fibrous bands and plaques reminiscent of thecoma. The cellular areas exhibited a striking microcystic pattern, characterized by small cystic spaces, in areas coalescing to larger irregular channels; intracytoplasmic vacuoles were also frequent. The cells had finely granular, faintly eosinophilic cytoplasm, with generally bland nuclei with fine chromatin and indistinct nucleoli. Bizarre nuclei with degenerative features were present in 10 cases. Mitotic rate was low, ranging from 0-2 mitoses per 10 high power fields. Immunohistochemical results were: Vimentin, 12/12 cases positive; CD10, 12/12 cases positive; cytokeratin, 4/12 cases positive; inhibin, 1/11 cases weakly positive; calretinin, 1/11 cases positive; EMA, 0/12 cases positive.

Conclusions: Microcystic change can be observed in a variety of ovarian sex cord-stromal tumors. For tumors which exhibit (1) a predominant or exclusive microcystic pattern, (2) a low power appearance of lobulated cellular masses with intervening hyalinized fibrous plaques, (3) an absence of morphologic features enabling another diagnosis in the sex cord-stromal category, and (4) an absence of epithelial elements, we propose the designation "microcystic stromal tumor". These tumors occur in adult women, are characteristically unilateral, and confined to the ovary at presentation. They likely have a good prognosis, although follow-up of appreciable duration is not yet available. The characteristic immunophenotype is vimentin +/CD10+/EMA-, with cytokeratin-positivity in one-third of cases; inhibin and/or calretinin are usually negative. They represent, in addition to the sclerosing stromal tumor (segregated out 3 decades ago), a distinctive subtype of ovarian stromal tumor.

947 CDX-2 Expression in Intestinal-Type Endocervical Adenocarcinoma: A Potential Pitfall in the Differential Diagnosis with Adenocarcinoma of Intestinal Origin Involving the Cervix

JR Jalas, JT Rabban. UCSF, San Francisco.

Background: Intestinal-type endocervical adenocarcinoma is a rare variant of cervical cancer that exhibits an intestinal appearance, including goblet cells. The main differential diagnosis is colorectal adenocarcinoma that has directly spread or metastasized to the cervix. CDX-2 is a marker of intestinal differentiation that is often used to evaluate adenocarcinomas of unknown origin. Recent studies, however, show that it is more likely a marker of intestinal phenotype rather than intestinal origin since some primary ovarian and primary lung cancers with intestinal/mucinous appearance may also express

CDX-2. Expression of CDX-2 by intestinal-type endocervical adenocarcinoma has not been well examined and is the aim of this study.

Design: Immunohistochemical staining for CDX-2 (BioGenex, 1:100 dilution) was performed on sections of formalin-fixed paraffin-embedded tissue from 9 cases of intestinal-type endocervical adenocarcinoma, defined as primary endocervical adenocarcinoma with a predominance of intestinal-like epithelium. All cases contained abundant well-developed goblet cells. Adenocarcinoma in-situ was present in all 9 cases and invasion was present in 5. Staining for CDX-2 was also performed on 3 cases of cervical metastases of intestinal adenocarcinoma (2 colonic, 1 gastric). Nuclear expression was defined as a positive result.

Results: All 9 cases of intestinal-type endocervical adenocarcinoma expressed CDX-2. The staining pattern was strong and diffuse in 8/9 cases and strong but focal in 1/9 cases. Both the invasive component and the in-situ component demonstrated the same intensity and distribution of CDX-2 within each case. The non-neoplastic endocervical glands did not express CDX-2 in any of the cases. All 3 cervical metastases of intestinal origin expressed CDX-2 in a strong diffuse manner; none of the non-neoplastic endocervical glands in these metastatic cases expressed CDX-2. None of the metastatic cases contained any growth patterns that morphologically resembled an in-situ component of endocervical adenocarcinoma.

Conclusions: CDX-2 cannot be used to define a site of origin for intestinal appearing adenocarcinoma in the cervix since it is strongly expressed by both primary intestinal-type endocervical adenocarcinoma and metastatic gastrointestinal adenocarcinoma. Presence of an in-situ growth pattern is a microscopic feature that supports a primary endocervical origin.

948 Comparative Analysis of CD 56, Calretinin, and Inhibin Immunohistochemical Staining in the Diagnosis of Ovarian Granulosa Cell Tumors

PA Jani, D El Demellawy. Thunder Bay Regional Health Science Centre, Thunder Bay, ON, Canada.

Background: Granulosa cell tumors (GCTs) represent 1.5% to 3% of primary and 6% to 10% of malignant ovarian neoplasms, and present little diagnostic difficulty in a classic case. However, other primary or metastatic tumors may mimic their various histologic patterns. For this reason, immunohistochemistry can be used to supplement routine histology to help determine a final tissue diagnosis. Although inhibin and Calretinin has been shown to be a sensitive marker for ovarian granulosa cell tumors, it may be negative in some cases. CD56, an adhesion molecule, has shown promise as a marker for granulosa cell tumors. The aim of this study was to evaluate and compare CD56 with Calretinin and inhibin as immunohistochemical markers for granulosa cell tumors of the ovary.

Design: A total of 30 cases of ovarian granulosa cell tumors were reviewed for their clinicopathologic findings and were immunostained with antibodies to CD56, Calretinin and inhibin, using standard avidin-biotin complex method. Results of the immunostains were evaluated on a 0-4 scale based on percentage of neoplastic cells labeling: 0 = none; 1+ = 1-25%; 2+ = 26-50%; 3+ = 51-75%; 4+ = 76-100%. Intensity of staining was recorded.

Results: All the cases (100%) of granulosa cell tumors demonstrated diffuse (4+) strong membranous staining for CD56. Calretinin was positive (3+) in 75% of the cases. It was focal weak (1 to 2+) positive in 25% of cases. Inhibin demonstrated diffuse weak (3+) staining in 70% of cases. Sixteen percent of cases were weak focally positive and 14% of cases were negative for inhibin.

Conclusions: In our present study, 100% of granulosa cell tumors of ovary demonstrated strong diffuse (4+) membranous positivity for CD 56. CD 56 has been reported to be positive in carcinoid tumors, setoli-stromal cell tumors, fibrothecoma, endometrioid adenocarcinoma and poorly differentiated serous adenocarcinoma. Thus CD56 is a more sensitive but less specific marker for granulosa cell tumors of ovary as compared with Calretinin and inhibin. CD56 is particularly useful in the diagnosis of granulosa cell tumors of ovary in cases that are inhibin and Calretinin negative. Awareness of CD 56 expression in granulosa cell tumors may prevent the potential diagnostic pitfall, particularly in metastatic site and in fine needle aspiration.

949 A Weakly Positive HPV Hybrid Capture II Result Correlates with a Significantly Lower Risk of HSIL Following ASC-US Cytology

EA Jarboe, P Venkat, MS Hirsch, ES Cibas, CP Crum, EO Garner. Brigham and Women's Hospital, Boston, MA; Yale University Medical School, New Haven, CT.

Background: The Hybrid Capture II (Digene) assay for high-risk human papillomavirus (hrHPV) is an *in vitro* nucleic acid hybridization assay with signal amplification using chemiluminescence for the qualitative detection of hrHPV DNA in cervical samples. Results are reported as a ratio of relative light units (RLU) to a cutoff value (CO) based on a positive control. Specimens with RLU/CO ratios ≥ 1.0 are considered positive for hrHPV. The current study tested the hypothesis that hrHPV positives with lower RLU/CO values (1-10) correlate with a lower prevalence of HSIL on follow-up.

Design: The RLU/CO ratios for 388 consecutive hrHPV-positive cervical cytologic specimens diagnosed in our institution as ASC-US were reviewed. hrHPV testing was performed on Thin-Prep (Cytec) liquid-based cervical cytology specimens using the Hybrid Capture II assay. Individual RLU/CO values were compared to outcome histologic diagnosis in cases with colposcopic tissue sampling (biopsy and/or endocervical curettage (ECC)).

Results: Table 1 summarizes a comparison of RLU/CO values with follow-up histologic diagnosis of either negative (ECC or biopsy), low-grade intraepithelial neoplasia (LSIL), or high-grade intraepithelial neoplasia (HSIL). The difference in HSIL outcome between

RLU values of 1-10 (3.2%) versus over 10 (17.4%) was significant at $p = 0.009$. The difference in rates of LSIL was not significant ($p = .61$).

Table 1

RLU/CO	Total cases	F/U Biopsy and/or ECC	Histologic Diagnosis		
			Negative	LSIL	HSIL
1-10	101	63**	52/63(82.5%)	7/63(11.1%)	2/63(3.2%)*
10-100	134	82**	60/82(73.2%)	5/82(6.1%)	14/82(17.1%)
100-1000	153	91	56/91(61.5%)	20/91(22%)	16/91(17.6%)

One case reported as SIL, cannot grade; * $p=0.009$

Conclusions: An RLU/CO value less than 10 was associated with a significantly lower rate of HSIL biopsy outcome following a diagnosis of ASCUS. The much lower prevalence of underlying HSIL in weakly HPV positives may justify a modification of the management algorithm for this subset of women with ASCUS.

950 Evidence of a Latent Precursor (p53 Signature) to Uterine Serous Carcinoma

EA Jarboe, E Pizer, A Miron, CP Crum. Brigham and Women's Hospital, Boston, MA; CellNetix Pathology, Seattle, WA; Dana Farber Cancer Institute, Boston, MA.

Background: Uterine serous carcinomas have been associated with pre-existing endometrioid carcinomas, intraepithelial carcinomas (EIC) and lesser atypias (endometrial glandular dysplasia or EGD). Recent studies of pelvic serous carcinogenesis have identified a candidate "latent" precursor containing p53 mutations in morphologically benign tubal epithelium (p53 signatures). In the current study, we analyzed endometrial serous carcinomas for a similar precursor.

Design: Nine consecutive cases of EIC, some co-existent with invasive serous carcinoma, were collected. All were immunohistochemically stained for p53 and MIB-1. When detected, p53 signatures and EICs were analyzed for p53 mutations by laser capture microdissection, PCR amplification and replicate sequencing of exons 1-11. p53 mutation data in both signatures and concurrent EIC/carcinomas were compared.

Results: p53 signatures were identified in 3 cases, and were multiple in 1. In one case, the signature was in continuity with EIC. The MIB-1 index for all the signatures was $\leq 5\%$, and ranged from 50-90% in EICs. DNA was successfully amplified in 2 of 3 cases. Shared p53 mutations were found in paired signatures and EICs in each case, including the case with multiple signatures. The two p53 alterations identified included a missense mutation in codon 273 (described in multiple cancers including uterine cancer) and a frameshift mutation in codon 321 (described in uterine serous cancers). In one of these cases, a co-existent invasive serous cancer was not found to contain a p53 mutation.

Conclusions: The pathogenesis of uterine serous carcinoma is multifactorial. One pathway appears to initiate as a latent precursor (p53 signature) in morphologically benign epithelium.

951 Epithelial Mesenchymal Transition (EMT) Regulator, Snail: Expression in Uterine Carcinosarcoma

NE Joseph, T Stricker, A Montag. University of Chicago, Chicago, IL.

Background: Epithelial mesenchymal transition (EMT) is defined as the dynamic transition from polarized, immotile epithelia to highly motile, mesenchyme-like cells. EMT is hypothesized to promote metastasis of carcinomas, and is ultimately regulated by transcriptional regulators, such as Snail, that result in the downregulation of epithelial genes and the upregulation of mesenchymal genes. This transition is accompanied by a morphologic switch, as the polarized epithelial cells become more spindled and mesenchyme-like. However, EMT is thought to occur only in a small percentage of tumor cells at any one time. Therefore we hypothesized that carcinosarcomas, which have both epithelial and mesenchymal components derived from the same clone, may show EMT, and increased expression of Snail, throughout the tumor.

Design: Archival paraffin embedded uterine carcinosarcomas were examined by IHC for the expression and localization of Snail utilizing a rabbit polyclonal antibody (Aviva) and the Envision Plus (DAKO) detection system. Staining was evaluated by two pathologists and graded for intensity in both the epithelial and stromal components as well as nuclear and cytoplasmic location. A minimum of 5% staining of the total cell population was required for a positive result. Statistical comparison was done using Fischer Exact Test.

Results: A total of 31 cases of uterine carcinosarcomas were examined. 23/31 (74%) cases showed positive staining in either the epithelial or stromal component. 21/29 (72%) tumors showed cytoplasmic expression in the epithelial component, as compared to 16/30 (53%) in the stromal component. Only 1/29 (3%) of epithelial tumor cells showed nuclear expression as compared to 7/30 (14%) in the stromal component. ($p=0.05$). Thus Snail was expressed mainly in the cytoplasm of both epithelial and stromal components of carcinosarcomas, however, nuclear expression was much more prevalent in stromal cells.

Conclusions: Epithelial mesenchymal transition (EMT) is hypothesized to allow epithelial-derived tumors to acquire a more aggressive phenotype through the loss of epithelial cell polarity. During embryogenesis Snail is involved in gastrulation and neural-crest migration, while in tumor progression, Snail has been observed to repress E-Cadherin expression, allowing the acquisition of invasive and migratory properties critical for metastasis of carcinoma cells. The expression of Snail in uterine carcinosarcoma suggests that it may play a role in EMT in this and other biphasic tumors.

952 The Polycomb Protein, Enhancer of Zeste (Homolog) 2 (EZH-2), Is Consistently Expressed in Uterine Carcinosarcomas

NE Joseph, TP Stricker, AG Montag. University of Chicago, Chicago, IL.

Background: The Polycomb proteins are involved in development, stem cell maintenance and cancer. Enhancer of zeste (homolog) 2 (EZH2) is the enzymatic component of Polycomb Repressive Complex 2 (PRC2), which is involved in the epigenetic regulation of transcription. High levels of expression of EZH2 have been

correlated with aggressiveness in prostate and breast adenocarcinomas. Additionally, pharmacologic disruption of PRC2 gene repression has been shown to selectively induce apoptosis in breast cancer cells. As EZH2 expression has not been previously reported in carcinosarcomas, we decided to study its expression in this rare and aggressive tumor.

Design: Archival paraffin embedded uterine carcinosarcomas were examined by IHC for the expression and localization of EZH2 using a rabbit polyclonal antibody (Zymed) and the Envision plus (DAKO) detection system. Staining was evaluated by two pathologists and graded for both percentage of cells expressing the marker, as well as the intensity of the expression. For percentage of positive tumor cells a score of 1 for was given to tumors with $<50\%$, 2 for 50-90% and 3 for $>90\%$ of positive cells. For intensity a score of 1 was given for weak, 2 for moderate and 3 for strong staining.

Results: 31/32 (96%) uterine carcinosarcomas showed positive nuclear staining in either the epithelial or stromal component or both. 24/26 (91%) and 31/32 (96%) displayed staining in the epithelial and stromal components respectively. In both epithelial and stromal components over 80% of cases displayed greater than 50% nuclear staining (Table 1). Both epithelial and stromal cells displayed approximately 75% moderate to strong staining.

Table 1: Percentage of tumor cells staining

	0%	<50%	50-90%	>90%
Epithelial	7%	11.5%	23%	57%
Stromal	3%	9%	25%	62%

Conclusions: Uterine carcinosarcomas show equally strong nuclear expression of EZH2 in the epithelial and mesenchymal components. Epigenetic changes have been implicated in carcinogenesis in many systems. The diffuse expression of EZH2 throughout the vast majority of carcinosarcomas in our study suggests that epigenetic mechanisms may be important for the biology of carcinosarcomas as well. The recent report that pharmacologic inhibition of the PRC2 complex, of which EZH2 is a part, led to apoptosis in breast cancer cells expressing EZH2, suggest that carcinosarcomas may benefit from pharmacologic inhibition of PRC2.

953 Diagnostic Use of Nuclear beta-Catenin Expression in Assessing Endometrial Stromal Tumors

CK Jung, JH Jung, YS Lee, ES Jung, YJ Choi, KY Lee. College of Medicine, The Catholic University of Korea, Seoul, Republic of Korea.

Background: When there are alterations in β -catenin degradation, it accumulates to a sufficient extent to be detected in the nuclei of tumor cells immunohistochemically. Nuclear β -catenin immunostaining has been demonstrated in some mesenchymal tumors as a diagnostic use. However, there is little known about β -catenin expression in endometrial stromal tumors.

Design: Neoplasms included in the study were endometrial stromal nodule ($n = 2$), low-grade endometrial stromal sarcoma (ESS, $n = 12$), undifferentiated endometrial sarcoma (UES, $n = 8$) and uterine cellular leiomyoma (UCL, $n = 8$). We compared the utility of nuclear β -catenin immunostaining with that of CD10 in these tumors.

Results: All 8 cases of UCL were completely negative for both CD10 and β -catenin. Ten cases of ESS (83%) and six cases of UES (75%) were positive for CD10. Nuclear β -catenin immunoreactivity was detected in 11 cases of ESS (92%) and 6 cases of UES (75%). In ESS cases, there were some differences in staining pattern/intensity between CD10 and β -catenin immunoreactivity. Eight cases of ESS (67%) exhibited diffuse, strong nuclear immunoreactivity with β -catenin, whereas only 4 cases (33%) expressed diffuse, strong immunoreactivity with CD10.

Conclusions: Nuclear β -catenin immunostaining is a reliable and sensitive immunohistochemical marker in differentiating ESS from cellular leiomyoma, and appears to be more useful than CD10.

954 Biomarker Expression in Ovarian Carcinoma Reflects Histological Subtype and Not Stage: Implications for Biomarker Studies

M Köbel, SE Kallinger, N Boyd, E Mehl, C Palmer, N Bowen, D Ionescu, A Rajput, L Prentice, J Santos, K Swenerton, D Miller, CB Gilks, D Huntsman. Vancouver General Hospital and British Columbia Cancer Agency, Vancouver, BC, Canada; Canary Foundation, San Jose, CA; Georgia Institute of Technology, Atlanta, GA.

Background: Current treatment protocols for ovarian carcinoma are not subtype specific. The most important prognostic factor for ovarian carcinoma is tumour stage. The biology of tumour progression and in particular the role of ovarian carcinoma subtype in predicting clinical behavior and biomarker expression is poorly understood.

Design: In an attempt to determine the role of tissue-based biomarkers across ovarian carcinoma subtypes we investigated the expression of a panel of 21 biomarkers by immunohistochemistry on a TMA containing 541 clinically annotated ovarian carcinomas. All patients were optimally debulked. Survival analysis was restricted to 499 patients who received at least six cycles of platinum based chemotherapy.

Results: Expression of 20 of the 21 biomarkers is subtype specific and does not vary across FIGO stages within each subtype. This indicates that biomarker expression within a carcinoma subtype is usually stable during tumour progression to advanced stage disease. WT-1 is an unfavorable prognostic marker in the whole cohort ($p=0.0017$) and a favorable prognostic marker within the high grade serous carcinoma subtype ($n=190$, $p=0.0089$) demonstrating how subtype can confound the analysis of biomarkers. Also, tumour proliferation as assessed by Ki67 staining varies markedly between different subtypes and no universal cut-off point can be assessed for prognostic analysis across all types.

Conclusions: The different subtypes of ovarian carcinoma have distinct clinical behavior in terms of stage at diagnosis, response to chemotherapy, and outcomes; they also exhibit distinct biomarker expression profiles. Therefore, biomarker studies that combine ovarian carcinoma subtypes can lead to misleading conclusions. To avoid the confounding effects of subtype on biomarker studies, each subtype within a cohort

should be discretely analyzed. Ovarian carcinoma subtypes are different diseases, this should be reflected in biomarker studies and ultimately in the management of ovarian carcinoma.

955 IMP3 Is an Extremely Poor Prognostic Marker for Ovarian Clear Cell Carcinoma

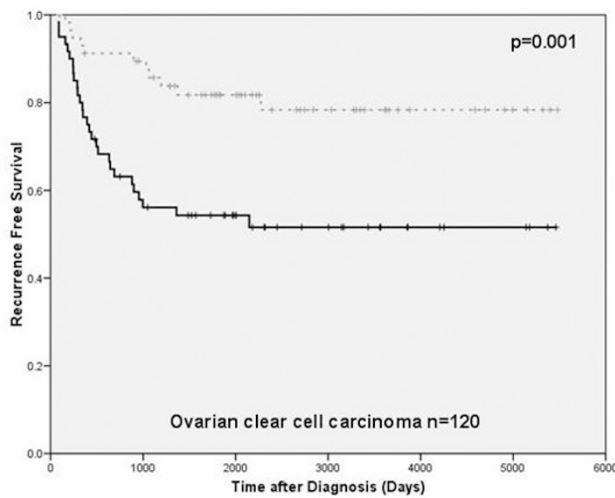
M Köbel, H Xu, PA Bourne, BO Spoulding, D Huntsman, CB Gilks. Vancouver General Hospital and British Columbia Cancer Agency, Vancouver, BC, Canada; University of Rochester Medical Center, Rochester, NY; Dako North America, Carpinteria, CA.

Background: The IMP (IGF-II mRNA binding protein) family comprises a group of three RNA binding proteins involved in the regulation of cytoplasmic mRNA-fate. Recent studies identified IMP proteins as oncofetal factors in various neoplasias, but knowledge of a potential role in ovarian carcinomas is still lacking.

Design: We characterized IMP3 expression on a TMA consisting of 504 clinically annotated ovarian carcinomas by immunohistochemistry. All patients were optimally debulked without any macroscopic residual tumor. Statistical survival analysis was restricted to patients that received at least six cycles of platinum based chemotherapy.

Results: IMP3 was expressed in 26/30 (87%) of mucinous, 65/127 (52%) of clear cell, 98/196 (50%) of high-grade serous, 34/122 (28%) of endometrioid carcinomas and 13/29 (45%) of other types. In clear cell carcinomas (n=120), but not tumors of other cell types, IMP3 was identified to be independent prognostic significance for shorter recurrence free survival (HR 3.2, CI 1.6-6.6 P=0.001) and disease specific survival (HR 3.2, CI 1.5-6.7 P=0.002) in multivariate analysis.

Conclusions: IMP3 is one of the first identified biomarker of prognostic significance in ovarian clear cell carcinoma.



956 A Novel Immunohistochemical Panel of CK5/6, CD10, and HLA-G Is Useful in Distinguishing Trophoblastic Tumors from Primary Cervical Carcinomas

N Kalhor, E Kling, MT Deavers, A Malpica, EG Silva. MD Anderson Cancer Center, Houston, TX.

Background: Several immunohistochemical (IHC) markers have been shown to be helpful in identifying intermediate trophoblastic tumors (ITT), including CD10 and HLA-G. However, interpretation of these markers can be misleading due to variable expression (extent and intensity) in trophoblastic tumors. Our initial review showed lack of CK5/6 reactivity in some ITTs. This study was designed to establish an IHC panel of markers which can differentiate ITTs from cervical carcinomas and to determine if CK5/6 is useful for this distinction.

Design: 14 cases of ITTs and 10 cases of poorly differentiated squamous cell carcinoma (Ca) and adenocarcinoma Ca of the cervix with available blocks were retrieved from the files of MD Anderson Cancer Center accessioned between the years of 1976-2005. An IHC panel, including CK5/6, HLA-G and CD10 was performed on paraffin-embedded tissue sections. Immunoreactivity was assessed by a semiquantitative scoring method.

Results: The IHC results are summarized in table 1.

Table 1. The results of IHC in ITTs and CAs

	CD10		HLA-G		CK5/6	
	Positive cases/total # of cases	Extent of expression	Positive cases/total # of cases	Extent of expression	Positive cases/total # of cases	Extent of expression
ITT	14/14	1+ to 4+	13/14	1+ to 4+	2/14	1+
CA	1/10	2+	1/10	1+	10/10	2+ to 4+

Scoring of proportion of cells showing a positive reaction: 1-25%=1+, 26-50%=2+, 51-75%=3+ and 76-100%=4+

Conclusions: No single marker is consistently sensitive and/or specific for ITTs, however an IHC panel of CK5/6, CD10, and HLA-G can differentiate ITTs from primary cervical Ca. In the appropriate clinical setting, a CK5/6-negative, CD10 or HLA-G-positive tumor strongly supports the diagnosis of ITT over poorly differentiated squamous/adenosquamous Ca of the cervix.

957 Distinguishing Breast Carcinoma from Mullerian Serous Carcinoma with Mammaglobin and Mesothelin

WA Kanner, MT Galgano, MH Stoler, SE Mills, KA Atkins. University of Virginia, Charlottesville, VA.

Background: Distinguishing müllerian serous papillary carcinomas from breast cancer, particularly micropapillary breast carcinoma (MBC), can be diagnostically challenging. Current immunohistochemical tests such as BRST-2, WT-1, and CA125 are fraught with either low sensitivity or low specificity. We assessed the utility of mammaglobin and mesothelin immunohistochemical patterns with respect to this differential diagnosis.

Design: The tumor cohort consisted of paraffin- embedded tissue from 10 primary MBCs, 11 usual type ductal carcinomas, 8 ovarian serous carcinomas, and 6 uterine papillary serous carcinomas. 12/14 serous carcinomas were metastatic to lymph nodes or omentum. All cases were stained with mammaglobin (1:50, monoclonal, Zeta Corp.) and mesothelin (1:30, monoclonal, BioGenex). The breast carcinomas were also stained with BRST-2 (1:200, monoclonal, Signet Labs Inc.) to compare the sensitivity of mammaglobin. Staining was scored as 0, 1, or 2 (none, mild, strong) and classified as diffuse (>50% staining) or patchy (<50%).

Results: See Table 1.

Tumor	Mammaglobin	BRST-2	Mesothelin
Breast Carcinomas (Total)	14/21	8/21	0
Micropapillary	7/10	4/10	0
Ductal Grade 2	5/6	3/6	0
Ductal Grade 3	2/5	1/5	0
Ovarian SP Carcinoma	0	n/a	4/8
UPSC	0	n/a	2/6

UPSC (Uterine Papillary Serous Carcinoma), SP (serous papillary) n/a (staining not performed)

Mammaglobin 7/10 MBCs had diffuse 2+ staining. 7/11 usual ductal carcinomas had patchy 1-2+ positivity. All müllerian tumors were negative. **BRST-2** 8/21 breast cancers had patchy 1-2+ staining. Seven of these cases were also positive for mammaglobin.

Mesothelin None of the breast carcinomas had mesothelin expression. Mesothelin was positive in 6/14 serous carcinomas.

Conclusions: When the differential diagnosis is between breast carcinoma and müllerian serous papillary carcinoma, our study suggests the following conclusions: 1. Mammaglobin has the same specificity as BRST-2 in identifying breast carcinoma but has an increased sensitivity (mammaglobin 67% sensitivity, BRST-2 38% sensitivity). 2. Mammaglobin staining is observed in almost every breast carcinoma that had BRST-2 positivity. However, given the patchy staining seen in the usual ductal carcinomas with both of these antibodies, a combination may be warranted, particularly in small biopsies. 3. Mesothelin is specific for müllerian serous papillary carcinomas but is not very sensitive (43%) and may have only limited utility.

958 Array Comparative Genomic Hybridization (aCGH) Detects Discriminatory Chromosomal Abnormalities between Primary Peritoneal Papillary Serous Carcinoma (PPSC) and Ovarian Papillary Serous Carcinomas (OPSC)

M Kapali, C Cieply, M Chivukula, S Dacic. University of Pittsburgh Medical Center, Pittsburgh, PA; Southern Arizona VA Health System, Tucson, AZ.

Background: PPSC is currently treated the same way as OPSC, though recent literature has shown that PPSC as a group has significantly worse prognosis than OPSC. The aim of this study was to identify if there are discriminating chromosomal abnormalities between the two entities using aCGH which might have diagnostic and therapeutic implications.

Design: Genomic DNA was extracted from microdissected, paraffin embedded, formalin fixed tumor tissue. Gene gains and losses were detected by commercially available genomic DNA microarray kit GenoSensor™ Array 300 (Abbott Molecular, Des Plaines, IL) which contains triplicates of 287 target clone DNAs (P1 or BAC clones) representing oncogenes and tumor suppressor genes. The cut-off fluorescence ratio between normal and aberrant DNA copy numbers was at mean 1.00 +/- 2 standard deviations. Fluorescence ratios ≥1.2 were considered as a DNA sequence copy number gain, and ratios ≤ 0.80 were considered as losses. Three chromosomal loci were validated by FISH on formalin fixed paraffin embedded histologic sections.

Results: PPSC and OPSC had a number of overlapping as well as discriminating gains and losses. **Overlapping abnormalities** included gains at chromosomes 6p 21, 8q24.12-q24.13, 17q23, 22q13.1, 2p24.1, 17q23, 17q21-q22, and 8q24. The most significant **discriminating abnormalities** appear to be gain at chromosome 17q11.2-17q12, which is identified in 50% of PPSC and none of the OPSC and gain at 5p15.2 identified in 40% of PPSC and none of the OPSC. Overall, 80% of PPSC had chromosome 17 abnormality in contrast to 30% of OPSC and 60% of PPSC had chromosome 5 abnormality and none of the OPSC.

Conclusions: It appears that PPSC has more chromosomal abnormalities than OPSC which might explain the significantly worse prognosis for this group. Our study suggests that gains at chromosomal loci 17q and 5p are more likely present in PPSC than in OPSC. These abnormalities have diagnostic value and may represent potential candidates for targeted therapies.

959 EGFR and Her-2 Expression and Gene Amplification in Ovarian Tumors

H Kim, A Kim, HK Kim, I Kim. Korea University Medical College, Seoul, Republic of Korea.

Background: EGFR (Her-1) and Her-2 are growth-promoting factors found to be overexpressed in a variety of human tumors, including a subset of ovarian surface epithelial tumors. Currently, monoclonal antibody targeted therapy directed against EGFR or Her-2/neu are being tried. This study evaluated the frequency and degree of EGFR and Her-2 protein overexpression and gene amplification in a variety of histologic types of ovarian tumors originating from surface epithelium and sex cord-

stromal components as well as germ cell tumors and metastatic carcinomas to seek the possibility of targeted therapy in ovarian tumors.

Design: Ovarian tumors consisted of 40 mucinous tumors, 87 serous tumors, 12 clear cell carcinomas, 10 endometrioid carcinomas, 2 Brenner tumors, 1 transitional cell carcinoma and 2 undifferentiated carcinoma, and 16 sex cord-stromal tumors, 4 germ cell tumors, and 9 metastatic adenocarcinomas from colorectum. All patients were staged according to the FIGO criteria, and the surface epithelial carcinomas were graded according to the Silverberg's histologic grading system. Immunohistochemical staining for EGFR and Her-2, and FISH using LSI EGFR/CEP 7 Dual Color Probe and Her-2/CEP17 Dual Color Probe were performed in tissue microarray.

Results: High EGFR protein expression was seen in 54.4% of mucinous carcinoma, 44.4% of metastatic carcinomas, 30% of endometrioid carcinomas, 25% of clear cell carcinomas and 12.3% of serous carcinomas, whereas only one serous carcinoma and 2 mucinous carcinomas showed Her-2 protein overexpression. Polysomy and amplification of EGFR gene was seen in 35 of 183 tumors (19%). By histologic types, polysomy and amplification of EGFR gene was seen in 33.3% of clear cell carcinomas and serous carcinomas, 22.2% of metastatic carcinomas, 10% of endometrioid carcinomas, and 9% of mucinous carcinomas. Polysomy and amplification were positively correlated with FIGO grade and clinical stage, but not with protein overexpression. Polysomy and amplification of Her-2 gene were seen in 22 of 183 tumors (12%). By histologic types, polysomy and amplification of Her-2 gene was seen in 41.7% of clear cell carcinomas, 27.3% of mucinous carcinomas, 15.8% of serous carcinomas and 22.2% of metastatic carcinomas. Polysomy and amplification of Her-2 were not correlated with histologic grades and clinical stages.

Conclusions: The gene alterations and protein overexpression of EGFR and Her-2 in primary and metastatic ovarian tumors may suggest the possible therapeutic applicability in treatment of ovarian cancers.

960 Maturation Delayed in Villous Stromal Components in Complete Hydatidiform Mole in Early Pregnancy

K-R Kim, B-H Park, Y-O Hong, S-J Robboy. University of Ulsan College of Medicine, Asan Medical Center, Seoul, Republic of Korea; Duke University Medical Center, Durham, NC.

Background: High-resolution ultrasonography, while enabling detection of disease earlier in pregnancy than ever before, suggests that in the earliest weeks the differences between complete hydatidiform mole and non-molar abortus are quite subtle. This study focuses on the histology of and differences between normal and molar placenta during the very earliest weeks of pregnancy.

Design: The morphology of 63 normal placentas and 73 molar pregnancies of 4-12th weeks' gestation were compared to find significant diagnostically useful differences.

Results: Normal chorionic villi showed a gradual, but recognizable stromal change from basophilic/hypocellular stroma (4th wk) to basophilic/cellular stroma with angiogenic cell cords (5-6th wks) to loose, edematous stroma containing mature blood vessels and immature or mature red blood cells (RBCs) (6-12th wks). Basophilic stroma was rarely seen after the 8th wk. Angiogenic cell cords (immature blood vessels) appeared before the 6th wks in the normal placenta, and then matured to contain immature RBCs, but they were not matured in molar pregnancies throughout the study period. The appearance of Hofbauer cells spatially and temporally corresponded to the onset of edematous change from basophilic stroma and maturing of blood vessels, suggesting that Hofbauer cells play a crucial role in vascular maturation. In early moles by contrast, the number of both Hofbauer cell and mature stromal vessels were significantly reduced, suggesting they are closely involved in developing molar disease. Normal placenta during the 5th-8th weeks exhibit florid villous sprouts, stromal karyorrhexis (up to 3%), and apoptosis defined by caspase-3 immunostainings (up to 6%), which often lead to confusion with young moles, but karyorrhexis and apoptosis were significantly lower compared to early moles. Young moles have many features of normal villous stroma in very early developmental stages, but immature features of the villous stroma were retained for abnormally prolonged periods without timely differentiation.

Conclusions: Complete hydatidiform mole is a disease not only of trophoblastic proliferation, but also of defective angiogenesis and delayed maturation of villous stromal constituents.

961 Vascular "Pseudoinvasion" in Laparoscopic Hysterectomy Specimens for Endometrial Carcinoma: Iatrogenic or Grossing Artifact?

S Kitahara, C Walsh, M Frumovitz, A Malpica, EG Silva. Cedars-Sinai Medical Center, Los Angeles, CA; University of Texas MD Anderson Cancer Center, Houston, TX.

Background: Early-stage endometrial cancers (ECa) may be managed effectively and safely by laparoscopically-assisted vaginal hysterectomy (LAVH). However, LAVH requires placement of a uterine manipulator and creation of a positive pressure system in the uterine cavity. This method may disrupt the integrity of the tumor, the adjacent blood vessels and lymphatics, potentially resulting in displacement of cancer cells into lymphovascular spaces in an otherwise low-risk, early-stage ECa.

Design: 21 cases of ECa that were managed by LAVH were retrieved from our department files and were compared with 30 cases of ECa that were managed by laparotomy/total abdominal hysterectomy. All these cases were grade 1 or 2, stage IA or IB, and endometrioid type adenocarcinomas. 3 of the 21 LAVH cases were converted to laparotomy and were included in the study group since placement of a uterine manipulator did occur. H&E slides were reviewed for the presence or absence of tumor cells in lymphovascular spaces.

Results: Among the LAVH specimens, 12 out of 21 had residual polypoid tumor and the remaining 9 had flat tumor. Tumor in blood vessels were noted in 8 of 21 (38%) specimens. In all 8 cases: only large caliber vessels, mainly in the outer half of the myometrium, showed tumor within vascular lumina; no small caliber vessels were involved; tumors were polypoid. 8 of the 12 polypoid tumors had vascular space involvement (VSI). 7 of 8 cases also showed tumor within non-vascular spaces

or artifactual clefts. Among the laparotomy specimens, none of the 30 cases (0%) showed VSI.

Conclusions: Laparoscopic hysterectomy specimens demonstrated more vascular space involvement by tumor cells than laparotomy specimens, suggesting that the operative technique during this procedure (i.e. utilization of a uterine manipulator) may cause displacement of tumor cells. However, we made the observations that tumor cells were identified only in large caliber vessels in the absence of tumor cells in small vessels, and that tumor cells were also lodged in non-vascular, artifactual clefts. Based on these findings, the possibility that uterine manipulator-generated tumor fragments are carried over into larger spaces (e.g. large vessels and tissue defects) in the resected specimen during the grossing process must be entertained and warrants further study.

962 Histological Grading in a Large Series of Advanced-Stage Ovarian Carcinomas by Three Widely Used Grading Systems: Prognostic Significance, Concordance Rates and Reproducibility

S Kommoss, D Schmidt, A du Bois, J Pfisterer, F Kommoss. Dr.-Horst-Schmidt-Kliniken Wiesbaden, Wiesbaden, Germany; Institute of Pathology, A2/2, Mannheim, Germany; Klinik fuer Gynaekologie und Geburtshilfe Campus Kiel, Kiel, Germany.

Background: While grading of tumor differentiation has been shown to be of prognostic significance in early stage ovarian carcinoma, the latter assumption is still in controversial discussion concerning advanced-stage ovarian carcinoma. There is no universally accepted grading system such as it has been established for breast and endometrium. It was the aim of this study to assess the three most widely used grading systems for ovarian carcinoma in terms of prognostic significance, concordance rates and reproducibility in a large number of advanced-stage ovarian carcinomas of all types after cytoreductive surgery and standardized chemotherapy.

Design: After completion of a prospective randomized, multi-center, phase III study of a total of 798 patients with ovarian cancer, FIGO-stages IIB-IV, comparing cisplatin plus paclitaxel with paclitaxel plus carboplatin, tissue blocks were requested for scientific analysis. Paraffin sections were cut from all blocks and stained with Haematoxylin and Eosin from a total of 334 study cases. First round: grading of all cases according to FIGO, GOG and Silverberg by one author. Second round (after 1 year): 30 randomly selected cases graded by 3 authors. Survival analysis by Kaplan-Meier method. Measurement of intra- and interobserver reproducibility by kappa statistics.

Results: None of the three grading systems was prognostically significant (FIGO: $p=0.38$, GOG: $p=0.70$, Silverberg: $p=0.92$). The concordance rates between the three systems were as follows: FIGO/GOG: 95.5%, $\kappa=0.929$; Silverberg/FIGO: 69.9%, $\kappa=0.533$; Silverberg/GOG: 66.8%, $\kappa=0.481$. Intraobserver reproducibility was: FIGO 100%, GOG 96.7% ($\kappa=0.953$), Silverberg 80% ($\kappa=0.692$). Interobserver reproducibility for the 3 investigators using all three grading systems was similar: FIGO: 80% ($\kappa=0.716$), GOG: 80% ($\kappa=0.691$), Silverberg: 77.8% ($\kappa=0.651$).

Conclusions: All three currently used grading systems were applicable in our study. The most complicated system (Silverberg) proved to be the least reproducible. Irrespective of the applied system, histopathological grading had no prognostic significance after radical surgery and standardized chemotherapy in this homogeneously treated series of advanced-stage ovarian carcinomas.

963 Chronic Vestibulitis in Young and Postmenopausal Women: Significance of Inflammation, Mast Cells, and Neural Proliferation

V Korcheva, TK Morgan. Oregon Health & Science University, Portland, OR.

Background: Chronic vestibulitis is severe localized pain elicited by vaginal entry. It affects 15% of women. The cause is unknown and currently the only effective therapy is surgical resection of the affected vestibular tissue. The characteristic histologic feature of chronic vestibulitis is localized cutaneous nerve proliferation. There may also be increased chronic inflammation, mast cells, and downregulation of the estrogen receptor (ER), but these features are less certain. Our objective was to characterize the pathologic features in both young (primary vestibulitis) and postmenopausal (secondary vestibulitis) women to better understand the pathophysiology of this disease.

Design: Archived vestibular biopsies obtained at the OHSU Vestibulodynia Clinic from 2002-2007 were identified, including all clinical cases of vestibulitis (n=86) and control biopsies (n=30; e.g. cysts, or to exclude dysplasia). Cases were segregated according to hormone status (premenopausal and postmenopausal; +/- exogenous hormone therapy). Patient records and HE stained sections were reviewed. As a pilot study, we tested 18 cases and 9 controls randomly selected from our larger sample. We immunostained sections for nerve fibers (S100), mast cells (CD117), and ER. Sections were scored for inflammation, nerve proliferation, mast cells, and ER expression using previously published criteria. Results were scored in duplicate by two pathologists. Significance between groups was tested using the Mann-Whitney U test.

Results: Reproducibility in scoring between pathologists was high (pair-wise kappa statistic 0.70-0.90). We observed significantly increased neural proliferation in cases compared to controls ($P<0.001$). There was also more inflammation ($P<0.001$) and mast cells ($P<0.05$). Estrogen receptor expression was decreased in cases compared to normal skin, but controls with chronic reactive changes showed significantly less ER staining as well (10-20% of basal cells; $P<0.001$). Exogenous hormone therapy had no effect on staining patterns. However, we observed significantly more nerve fibers in primary vestibulitis compared secondary vestibulitis ($P<0.05$).

Conclusions: Our preliminary data suggest chronic inflammation leads to ER downregulation in both cases and controls. Women with vestibulitis, however, appear to respond differently, culminating in localized nerve proliferation. The etiology remains elusive, but this is the first study to compare primary and secondary vestibulitis, which may yield insights into this common disease.

964 TSC2 Dysfunction in Uterine Leiomyosarcomas and Leiomyomas: A Molecular Distinction

JS Laser, K Mittal, HF Zhu, P Lee, PP Pandolfi, E Hernando, JJ Wei. New York University, New York, NY.

Background: TSC2 (tuberin) is a tumor suppressor which binds TSC1 to form a complex that inhibits IGF-Akt/mTOR pathway. Disruption of TSC1/TSC2 complex, via mutation or phosphorylation, releases this inhibition and results in cellular biogenesis and proliferation. More recently, TSC1/TSC2 complex has been implicated in cross-talk with the Wnt/ β -catenin pathway, via binding to β -catenin, resulting in its degradation. Recent reports demonstrate that activation of Wnt/ β -catenin and IGF-Akt-mTOR pathways are induced in leiomyosarcoma animal models. We propose that TSC2 disruptions are a critical step in this oncogenic pathway.

Design: Thirty leiomyosarcomas (LMS) and 120 uterine leiomyomas (ULM) were selected. All tumor and matched myometrial tissues were collected and prepared in high density tissue microarray (TMA). Antibodies against TSC2, pTSC2 (Ser664), β -catenin, and TSC1 were selected and expression of the proteins were examined by immunohistochemistry (IHC). Immunoreactivity were scored by a semiquantitative measurements of combining intensity and percentage.

Results: TSC2 was slightly increased in almost all LMS (26/29) in comparison to matched myometrium, with a net change of 1.15. In contrast, ULM had very low level of TSC2, with a net change of -0.29. When we examined pTSC2(Ser664), specifically following phosphorylation by p-ERK, about 62% (18/29) of LMS showed diffuse immunoreactivity for pTSC2, however ULM and myometrium was completely negative. Expression of β -catenin was observed in both the cytoplasm (mean value of 2.36) and the nucleus (mean value of 4.28), with a significant increase in nuclear (active) localization in LMS. A moderate correlation of p-TSC2 and β -catenin-N ($r=0.6$) was observed in LMS. There was no significant overexpression of β -catenin in ULM in comparison to myometrium. Expression of TSC1 (hamartin) was slightly increased both in LMS and ULM but no difference between malignant and benign tumors was noted ($p>0.05$).

Conclusions: Loss of TSC2 function was found both in benign and malignant uterine smooth muscle tumors (ULM and LMS). However, the molecular mechanisms for TSC2 dysfunction are different among these two entities: loss of TSC2 in ULM and inactivation by phosphorylation of TSC2 in LMS. There is moderate correlation of β -catenin in nuclei with pTSC2, supportive of recent findings linking the Wnt/ β -catenin pathway with the Akt/mTOR pathway through the TSC1/TSC2 complex. Furthermore, expression of pTSC2 may be a useful tool in the differential diagnosis of LMS from ULM.

965 Squamous Cell Carcinoma of the Uterine Cervix Seems To Develop Frequently from Multifocal Microinvasion

SF Lax, F Moynfar, K Prein, U Bargfrieder, P Lang. General Hospital Graz West, Graz, Austria; Medical University Graz, Graz, Austria; Brothers of Charity Hospital Graz, Graz, Austria.

Background: Microinvasive carcinoma (MIC) is the earliest stage of uterine cervical carcinoma and usually diagnosed by histopathological examination of cone biopsy. MIC is supposed to develop from high grade cervical intraepithelial neoplasia (or CIN 3). The aim of this analysis is to determine whether MIC may develop as a multifocal process.

Design: 1014 consecutive cone biopsies which were submitted to our institution during the last 57 months were retrieved from our Pathology database. Cone biopsies processed at our institution were totally embedded and serially sectioned according to a standardized protocol. A median of 60 sections were obtained per cone (range 50-80). The slides of all MIC cases were reviewed at a multiheaded microscope by 2 pathologists.

Results: A CIN 3 was diagnosed in 702 cases (69.2%) and an invasive carcinoma was detected in 37 cases (3.6%). The remaining 27.2% of cone biopsies contained CIN 2 (8.8%), CIN 1 (4.4%) and benign reactive changes (14%), the latter following biopsy and endocervical curettage of cases with CIN2 and 3. Six of the 37 carcinomas were small pT1b1 tumors with a maximum horizontal diameter of 10 mm and a maximum depth of invasion of 7 mm. 27 (87%) of the 31 microcarcinomas were pT1a1, 4 (13%) pT1a2. Histologically, 31 squamous cell carcinomas, 5 adenocarcinomas (of endocervical type) and one adenosquamous carcinoma were diagnosed. Associated CIN 3 was found in all cases of squamous cell carcinoma. Multiple foci of invasion ($2 > 10$) were detected in 20 of the 37 cases (54%) and in 58% of the squamous cell carcinomas and in the adenosquamous carcinoma. With respect to the histological type, multifocal invasion was found more frequently in squamous cell carcinoma (including the adenosquamous carcinoma) compared to pure adenocarcinoma (59% versus 20%) but due to the small number of cases the difference was not statistically significant ($p=0.16$, Fisher's exact test). Within a median follow up period of 28 months no local or distant recurrence was observed.

Conclusions: A subset of CIN3 seems to have the potential to progress at multiple sites into squamous cell carcinoma. This may have further implications on the assessment of tumor stage and therapy.

966 MicroRNA and mRNA Expression Profiling of 48 Ovarian Surface Epithelial Neoplasms

C-H Lee, S Subramanian, I Espinosa, S Zhu, KA Blood, M van de Rijn, D Huntsman, CB Gilks. Vancouver General Hospital, Vancouver, BC, Canada; Stanford University Medical Center, Stanford, CA; British Columbia Cancer Agency, Vancouver, BC, Canada.

Background: MicroRNAs (miRNA) are 20-25 nucleotide non-coding RNAs that inhibit the translation of targeted mRNA. miRNA have been implicated in the development and progression of human malignancies. Little is known regarding the importance of miRNA in ovarian cancer.

Design: Global miRNA and mRNA expression profiling was performed on a series of 36 high-grade serous carcinomas (9 with BRCA1 mutation, 3 with BRCA2 mutation,

10 with BRCA1 epigenetic loss, 11 with no demonstrable BRCA1 loss and 3 with equivocal BRCA1 status), 5 endometrioid carcinomas, 3 clear cell carcinomas, 2 low-grade serous carcinomas and 2 serous borderline tumors, as well as 3 normal fallopian tubes, using miRNA microarrays that include 328 known human miRNA (Stanford, CA) and human exonic evidence-based oligonucleotide microarrays that include 30718 exonic probes (Stanford, CA) respectively. Unsupervised hierarchical clustering analysis and significance analysis of microarrays (SAM) were used for data analysis.

Results: Unsupervised hierarchical clustering based on both miRNA and mRNA expression profiles concurrently showed tight clustering of the 3 normal fallopian tube samples. There was no clear separation as seen by hierarchical clustering and other methods between the high-grade serous carcinomas with different BRCA abnormalities for mRNA and miRNA expression. However, there were differentially expressed mRNAs and miRNAs between the different histologic types. SAM comparison between 36 high-grade serous carcinomas and the 3 normal fallopian tubes showed a relative downregulation in both miRNA and mRNA levels, with miR-93, miR-210, miR-200c and miR-106b being the only miRNA that showed significant upregulation.

Conclusions: Significant differences in miRNA and mRNA expression profiles exist among the different histologic subtypes of ovarian surface epithelial carcinomas and between high-grade serous carcinomas and normal fallopian tube. The lack of differences observed in miRNA and mRNA profiles between the high-grade serous carcinoma with different BRCA abnormalities points to similar molecular pathways during oncogenesis of these genomically unstable tumors, regardless of the status of BRCA1 and BRCA2.

967 Endometrial Polyps with Complex (CH) and Complex Atypical Hyperplasia (CAH): Follow-Up (FU) Findings

R Lee, DA Popiolek. New York University, New York.

Background: Based on GOG Protocol 167 article, the prevalence of endometrial carcinoma (ECA) and myoinvasive ECA (MIECA) was 39% and 13%, respectively, in follow-up hysterectomies (FUH) performed after a diagnosis of CAH was made on endometrial biopsy/curettage (EMBx/C). Our goals were to assess: 1) the prevalence of ECA in FUH or FUEMBx/C after a diagnosis of CAH or CH within endometrial polyp (EMP); 2) the likelihood of CH/CAH being confined to EMP; and 3) the incidence of CH/CAH within EMP.

Design: We performed a computer-based search; from 2004 to 2006 (2.5-year period) using "natural language search"; of the pathology files to identify all women with a diagnosis (dx) of EMP, and then selected those patients with a dx of EMP with CAH and/or CH to obtain the FU information, including review of the H&E-stained slides.

Results: We identified 2541 women with a dx of EMP, and 68 of them had EMP with CAH and/or CH (2.6%), including 52 with a dx of EMP with CAH (2%) and 16 with a dx of EMP with CH (0.6%). In the 68 cases with a dx of EMP with CAH and/or CH, FU was available in 40 cases (34 cases with FUH and 6 cases with FUEMBx/C). There were 8 cases of ECA (all FIGO grade I, endometrioid type) and 3 of them were MIECA (3mm - 1 case, and 4 mm - 2 cases), all identified in FUH (34 cases) with the prevalence of 23% for ECA and 0.8% for MIECA; all were preceded by a dx of EMP with CAH and were present in the non-polyp endometrium (EM). In 24 of 40 cases with available FU (FUH - 22 case and FUEMBx - 2 cases) the CAH (20 cases) / CH (4 cases) was confined to EMP (60%). Out of the 68 cases with a dx of EMP with CAH and/or CH, there was no tissue FU in 28 cases, and among those 17 and 11 cases had CAH and CH, respectively.

Conclusions: The incidence of ECA and MIECA in FUH is significantly lower in women with CAH in EMP (23% and 0.8%) versus CAH in non-polyp EM (39% and 13%). Also, in 60% of women CAH and/or CH was limited to EMP, suggesting that less aggressive management might be an option for this group of women. Further, if we assume, that the group of women with a dx of EMP with CAH and/or CH but with no tissue FU, had no clinical evidence of residual CAH/CH or suspicion for ECA, the likelihood of CAH/CH being limited to EMP might be even greater.

968 LOH at $p16^{INK4a}$ Is Frequent in HPV Related Vulvar Carcinomas

E Lerma, L Catusas, I Landin, M Romero, A Ribe, A Gallardo, J Prat. Hospital de la Santa Creu i Sant Pau, Barcelona, Spain.

Background: Alterations of $p16^{INK4a}$ are very common in human neoplasms and its role in vulvar cancer is controvert. Absence of p16 in vulvar neoplasms was frequently related with gene promoter hypermethylation, and rarely with LOH or mutations. Nevertheless, p16 overexpression has been considered as a marker for identification of vulvar HPV related neoplasms. In this presentation, LOH at 9p21 were analyzed in selected cases with previously known results of $p16^{INK4a}$ promoter hypermethylation and immunohistochemical expression.

Design: Paraffin blocks were selected from our Pathology Department. They include 9 invasive squamous cell carcinomas (6 conventional, HPV-unrelated and 3 basaloid/warty or HPV-related) and 6 VIN III (2 simplex HPV-unrelated; and 4 warty or basaloid-HPV-related). Clinical histories, pathological material and HPV status were assessed. DNA was isolated from neoplasms and normal vulvar tissues from paraffin-embedded material and loss of heterocigosity (LOH) at the 9p21 region were assess in IFNA, D9S157, D9S161 and D9S171. DNA methylation in the CpG island by methylation-Specific PCR (MSP) and immunohistochemistry of $p16^{INK4a}$ with a commercial kit (Dako, Denmark) had been previously determined.

Results: $p16^{INK4a}$ LOH appeared only in invasive neoplasias (5/9), mostly in those HPV-related (3/3). LOH was unrelated with promoter hypermethylation, nor p16 overexpression, which was present in all HPV-related neoplasms and in ~ 25% of HPV-unrelated invasive neoplasias.

Conclusions: LOH in the $p16^{INK4a}$ region (9p21) is a late event in vulvar carcinogenesis. LOH may occur in one allele whereas the other could induce protein overexpression, under the HPV effect.

969 Adenoid Cystic Carcinoma of Bartholin's Gland: Immunohistochemical Studies of Selected Markers with Potential Clinicopathological Implications

SX Liang, M Pearl, W Zheng, K Patel, J Chumas, C Tornos. Stony Brook University Medical Center, Stony Brook; University of Arizona, Tucson; St. Charles Hospital, Port Jefferson.

Background: Adenoid cystic carcinoma (ACC) of Bartholin's gland (BG) is a rare tumor with unknown histogenesis, unpredictable behavior and frequent late recurrences or distant metastases. Lack of effective chemotherapy might have contributed to its unfavorable long-term outcome. Recent studies have demonstrated c-kit and EGFR expression in ACC of salivary gland. This study examines the expression of ER, PR, Her-2, c-kit, Ki67, p53, EGFR and p16 by immunohistochemistry, and HPV by in situ hybridization in ACC of BG.

Design: Six cases of ACC of BG were retrieved from our files. Histological diagnosis was confirmed and representative sections from 5 cases were selected for immunohistochemistry. Evaluation of immunostains was based on percentage of positive stained cells (0=<10%; 1=10-25%; 2=25-50%; 3=>50%).

Results: The median age of patients was 54.4years (40-70). Positive immunostain for c-kit was present in 5/5 cases (100%), strong and diffuse in 4, moderate and focal in 1. Four of five cases (80%) showed moderate to diffuse immunoreactivity for p16. Among these 4 cases, 1 had local recurrence at 14 month, 2 had distant metastasis with stable disease at 13 and 124 month, respectively, and 1 was free of disease at 1-month follow-up. Patient with negative p16 stain was free of disease at 71-month follow-up. Focal and weak EGFR stain was present in 4/5 cases. The rest of the markers were either negative (ER, PR, Her-2) or not significant (ki-67, p53). All cases were negative for HPV.

Conclusions: ACC of BG frequently expresses c-kit and p16 by immunohistochemistry. P16 positivity seems to correlate with more advanced or recurrent disease, although the case number is too small to be statistically significant. Most ACCs also express EGFR at low levels. Pharmacotherapy against c-kit tyrosin kinase or EGFR might be an alternative therapy for patients with ACC. HPV does not seem to play a role in the pathogenesis of these tumors.

Clinicopathologic Features of 5 Adenoid Cystic Carcinomas

Case	Recurrence (month)	Lymph node	p16	C-kit	Her-2	EGFR	HPV
1	Distant (124)	N/A	3+	3+	-	1+	-
2	No (71)	-	-	3+	-	-	-
3	Local (14)	+	3+	1+	-	1+	-
4	Distant (13)	+	1+	3+	-	1+	-
5	No (1)	-	3+	3+	-	2+	-

-: negative; +: positiv; N/A: not available

970 The von Hippel-Lindau Gene Product (pVHL): A Diagnostic Marker for Clear Cell Carcinoma of the Ovary and Uterus

H Liu, J Shi, J Zhang, J Pritchard, W Dupree, F Lin. Geisinger Medical Center, Danville, PA; Mayo Clinic, Rochester, MN.

Background: Genetic alteration of the von Hippel-Lindau (VHL) tumor suppressor gene has been linked to both hereditary and sporadic clear cell renal cell carcinomas (RCCs). Inconsistent data on cellular immunolocalization and distribution of the von Hippel-Lindau gene product (pVHL) in human normal tissues and tumors have been reported in the literature. In this study, we test pVHL expression in non-renal tumors.

Design: A series of 213 cases of non-renal tumors from various organs, including 38 cases of clear cell carcinoma of the ovary (N=19) and uterus (N=19) on routine sections and 94 non-renal tumors on tissue microarray sections were immunohistochemically stained with an anti-pVHL rabbit polyclonal antibody. The staining intensity was graded as weak or strong. The distribution was recorded as negative (less than 5% of tumor cells stained), 1+ (5-25% of tumor cells stained), 2+ (26-50% of tumor cells stained), 3+ (51-75% of tumor cells stained), or 4+ (more than 75% of tumor cells stained). Western blot was done on one case of each clear cell carcinoma of the ovary, uterus, adenocarcinoma of the lung, and the pancreas.

Results: A cytoplasmic/membranous staining pattern for pVHL was observed in a total of 37 cases. Of the 37 cases, 34 were clear cell carcinomas of the ovary and uterus. Seventeen of 19 (90%) clear cell carcinomas of the ovary and the uterus were positive for pVHL, with about 50% of cases showing diffuse staining (>3+). All cases of endometrioid carcinoma (N=17) and papillary serous carcinoma (N=27) were negative for pVHL. In normal tissues, positive immunoreactivity was only observed in renal tubules, exocrine pancreas, islets and bile ducts. The remaining tested tumors, except 3 cases of hepatocellular carcinoma, showed loss of expression of pVHL. Two of three clear cell carcinomas of the ovary in TMA sections were positive for pVHL and the remaining cases were negative. Western blots confirmed the immunostaining results.

Conclusions: These data indicate that this polyclonal anti-pVHL antibody may serve as a diagnostic marker for clear cell carcinoma of the ovary and uterus. Further study is warranted to understand the possible role of pVHL in the carcinogenesis of clear cell carcinoma of the uterus and ovary.

971 Immunohistochemical Profile of Atypical Endometrial Syncytial Papillary & Eosinophilic Metaplasia Versus Serous Carcinoma

RK Malhotra, S Qiu, M Eltorok. University of Texas Medical Branch, Galveston, TX.

Background: Endometrial epithelial metaplasia is replacement of normal glandular epithelium by mature epithelium of another type. Endometrial metaplasia is usually estrogen-induced and the atypical syncytial papillary metaplastic changes in the endometrial biopsy can be misdiagnosed as serous adenocarcinoma. In this study, we evaluated the H&E morphology and the results of Ki-67, p53 and pTEN immunohistochemical markers in distinguishing between these two diagnostic entities.

Design: The purpose of this study is to investigate the clinicopathologic and immunohistochemical profile of Ki-67, p53 and pTEN in endometrial biopsies showing

syncytial papillary & eosinophilic metaplasia with atypical features and compare the results with serous carcinoma. The 13 women with metaplastic changes ranged from 36-67 years and the majority presented with abnormal uterine bleeding. 2 patients were on estrogen therapy and 8 patients had coincidental endometrial hyperplasia. The majority of patients with papillary serous carcinoma (10 cases) presented with post menopausal bleeding and the age ranged from 51-84 years.

Results: The histology and the immunohistochemical profile of the above markers are compared between syncytial papillary & eosinophilic metaplasia and serous carcinoma.

Histology	Ki-67	p53	pTEN
Syncytial papillary & eosinophilic metaplasia	3-15%(32%)	Weak to 1+(72%)	3+(100%)
Serous Carcinoma	60-90%(100%)	3+(100%)	Negative
p value	<.001	<.001	<.001

Conclusions: Endometrial biopsies showing features of atypical eosinophilic and syncytial papillary metaplasia in architecturally complex glands can be misinterpreted as serous carcinoma by the practicing pathologist. The presence of eosinophilic and syncytial metaplasia in a limited biopsy tissue should be appropriately recognized and the use of above markers can aid in differentiating between these two different entities.

972 Cytokeratin 17 Expression in Non-Mucinous Carcinomas of the Ovary

A Malpica, MT Deavers, E Euscher. The University of Texas MD Anderson Cancer Center, Houston, TX; University of Texas MD Anderson Cancer Center, Houston, TX.

Background: Cytokeratin 17 is a low-molecular weight keratin mainly expressed in pancreaticobiliary adenocarcinoma, squamous carcinoma, basal cell carcinoma, transitional cell carcinoma, and adenocarcinomas with squamous differentiation. Although several studies have emphasized its importance as a diagnostic tool to distinguish tumors of the pancreaticobiliary tract from other sites of origin, its expression has not been thoroughly assessed in ovarian carcinomas. The purpose of this study is to evaluate the expression of cytokeratin 17 in ovarian carcinomas of the non-mucinous type.

Design: Forty-four cases of ovarian non-mucinous carcinomas were retrieved from our files. These included 15 serous carcinomas (SeCa), 14 endometrioid carcinomas (Eca), 8 clear cell carcinomas (CCCa), and 7 transitional cell carcinomas (TCC). H&E slides were reviewed in all cases to confirm the diagnosis, using the World Health Organization classification. Cases of serous carcinoma were divided into high grade (HG, 9 cases) and low grade (LG, 6 cases) using the two-tier grading system. Immunoperoxidase study for keratin 17 (clone E3, 1:20, Dako, Carpinteria, CA) was performed using an automated immunostainer and polymer detection system (Vision Biosystems, Norwell, MA). Staining was assessed with a semiquantitative method as follows: 0, no staining; 1+, 1%-25% of the cells staining; 2+, 26%-50% of the cells staining; 3+, 51%-75% of the cells staining; and 4+, more than 75% of the cell staining.

Results: Results are summarized in Table 1.

Ca Types/# cases	0	1+	2+	3+	4+
HGSeCa/9	0	3	1	5	0
LGSeCa/6	0	1	1	1	3
Eca/14	2	9	2	1	0
CCCa/8	4	4	0	0	0
TCC/7	3	3	0	1	0
Total # cases/44	9	20	4	8	3

In all cases the intensity was moderate to strong

Conclusions: 1. Cytokeratin 17 is expressed in 80% of ovarian non-mucinous carcinomas. 2. All cases with serous differentiation expressed this marker. 3. In 67% of the cases of low grade serous carcinoma, the staining was present in more than 50% of the cells. 4. Cytokeratin 17 is less frequently expressed in clear cell and transitional cell carcinomas than in serous and endometrioid carcinomas.

973 Malignant Mesothelioma Presenting as, and Mimicking, Ovarian Cancer

H Mani, MJ Merino. National Cancer Institute, NIH, Bethesda, MD.

Background: Malignant mesotheliomas of the abdominal cavity are rare tumors that primarily involve the peritoneum, mesentery and omentum. Involvement of viscera is usually secondary to bulky and extensive serosal disease. We describe five cases of malignant mesothelioma in which the initial manifestation was that of an ovarian mass.

Design: We encountered five patients who underwent surgery with a diagnosis of ovarian cancer. Clinical presentations, gross features and histology slides were reviewed. Results of immunohistochemical stains using commercial antibodies against a variety of antigens including pan-cytokeratin, calretinin, cytokeratin 5/6, WT-1, BER-EP4, CD31, CD34, ER and PR were evaluated. Electron microscopy was performed in some cases.

Results: The patients ranged in age from 22 to 34 years (mean 28 years), and presented with abdominal pain. Clinical and imaging studies showed the presence of ovarian/tubo-ovarian masses leading to a diagnosis of ovarian cancer. Three patients had predominantly cystic lesions, whereas two had a predominantly solid mass. At surgery, there were, in addition, papillary and/or cystic lesions involving the ovarian surface and/or foci of pelvic peritoneum. On gross examination, the lesions varied from smooth thin-walled cysts to solid masses, measuring from 3.8 cm to 9 cm in largest dimension. Histologically, the cystic lesions showed features of multicystic mesothelioma. In one case, the solid mass showed a malignant epithelioid neoplasm with areas mimicking serous carcinoma and clear cell carcinoma, but was proven to be a diffuse malignant mesothelioma, epithelioid type, by immunohistochemistry and electron microscopy. The fifth case showed a malignant spindle and epithelioid neoplasm in association

with a borderline mucinous tumor, raising a possibility of a sarcomatoid mural nodule. However, there was focal involvement of the peritoneal serosa and special studies confirmed the diagnosis of mesothelioma.

Conclusions: The cases described exemplify a rare clinical presentation of malignant mesothelioma. Mesotheliomas can be mistaken for ovarian tumor on clinical, radiological and histologic examination. Immunohistochemistry and ultrastructural studies are required to differentiate these tumors from primary ovarian neoplasms including serous, clear cell and mucinous carcinomas. Awareness of this presentation is important to establish appropriate surgical and adjuvant therapies.

974 Distinct Signatures of DNA Copy Number Changes in Ovarian Surface Epithelial Tumors

T-L Mao, N Jinawath, RJ Kurman, T-L Wang, I-M Shih. Johns Hopkins Medical Institutions, Baltimore, MD; National Taiwan University Hospital, Taipei, Taiwan.

Background: Chromosomal instability characterizes human cancer and is reflected by DNA copy number changes on chromosomes. Different histologic types of ovarian surface epithelial tumors have been well recognized but it is not known whether they demonstrate unique DNA copy number changes at the genome-wide scale.

Design: We employed high-density (250K) Single nucleotide polymorphism (SNP) array analysis on 13 high-grade serous carcinomas (HG), 6 low-grade serous carcinomas (LG), 10 serous borderline tumors (SBT), and 6 clear cell carcinomas (CC). All tumors are affinity purified (>98% purity) from fresh specimens to avoid potential stromal cell contamination and culture artifacts. Chromosomal instability index was defined as the total number of gain and loss of discrete chromosomal loci in tumor genomes.

Results: Among all tumor types examined, HG (including one with clear cell feature) demonstrated the highest level of genetic instability (Fig 1). They are characterized by diffuse DNA copy number gain and loss in most chromosomes including frequent loss of Ch4 and ChX. In contrast, SBT exhibited a remarkably low level of DNA copy number change. As compared to SBT, LG and CC showed an increased chromosomal instability index which was significantly lower than that in HG. Loss of Ch1p was unique to LG as 4 out of 6 LG exhibited such loss which was also observed in one SBT but not in CC and less frequently in HG. CC showed a similar chromosomal instability index to LG but exhibited a different pattern from LG.

Conclusions: Our high-resolution genome-wide analysis demonstrates that the pattern of DNA copy number changes is unique among different histologic types of ovarian surface epithelial tumors and supports that HG are highly chromosomally unstable neoplasms as compared to LG and CC. Although the majority of CC exhibit high-grade nuclei, they do not show high levels of chromosomal instability that is comparable to HG. Ch1p36 loss appears to be a specific marker during tumor progression from SBT to LG.




Fig. 1

975 HSD3B1 as a Novel Trophoblast-Associated Marker That Assists in the Differential Diagnosis of Trophoblastic Tumors and Tumor-Like Lesions

TL Mao, EF Veras, RJ Kurman, YM Jeng, W Huang, IM Shih. Johns Hopkins Medical Institutions, Baltimore, MD; National Taiwan University Hospital, Taipei, Taiwan; Abnova Cooperation, Taipei, Taiwan.

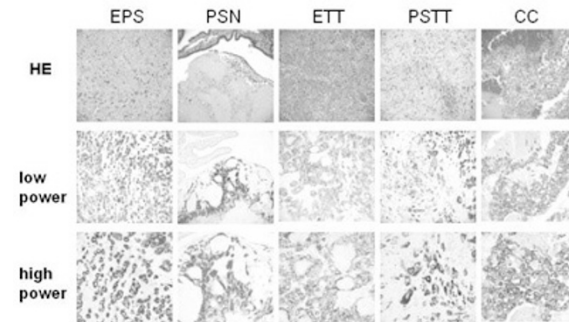
Background: Trophoblastic tumors and tumor-like lesions can be confused with a variety of non-trophoblastic tumors, therefore a trophoblast-associated marker that is expressed in all types of trophoblastic lesions is useful in differential diagnosis. In this

report, we assessed the potential of hydroxyl- δ -5-steroid dehydrogenase (HSD3B1), an enzyme that is involved in steroid hormone synthesis, as a diagnostic trophoblastic marker.

Design: First, the gene expression profile of HSD3B1 was analyzed using serial analysis of gene expression in the database deposited in the public domain and found that HSD3B1 was not expressed in 159 libraries of a wide variety of carcinomas and normal adult and fetal tissues. Second, an immunohistochemical analysis was performed using a commercially available anti-HSD3B1 monoclonal antibody on paraffin sections.


Results: HSD3B1 immunoreactivity was detected in intermediate trophoblast and syncytiotrophoblast in 21 early placentas, 18 complete moles, and 97 trophoblastic tumors and tumor-like lesions. HSD3B1 immunoreactivity was diffuse and intense in the majority of trophoblastic lesions with the exception of a few choriocarcinomas (Fig. 1).

Fig. 1 Immunoreactivity of HSD3B1 in trophoblastic lesions. EPS: exaggerated placental site, PSN: placental site nodule, ETT: epithelioid trophoblastic tumor, PSTT: placental site trophoblastic tumor, CC: choriocarcinoma



In contrast, all 32 ovarian granulosa cell tumors were negative. Only 3 (<1%) of 319 non-trophoblastic carcinomas from the uterus, lung and breast and 2 of 12 adrenal cortical adenomas reacted with the HSD3B1 antibody. Moreover, the immunoreactivity in these tumors was focal and weak (Fig 2).

Fig. 2 Scatter plot of H-scores of HSD3B1 immunostaining in different trophoblastic lesions as well as other types of tumors. ETT epithelioid trophoblastic tumor; PSN: placental site nodule, PSTT: placental site trophoblastic tumor, EPS: exaggerated placental site, CC: choriocarcinoma, NGTN: non-gestational trophoblastic neoplasms.



Conclusions: As compared to other known trophoblastic markers, HSD3B1 is highly specific and sensitive, being expressed in all types of trophoblastic lesions but not in a variety of non-trophoblastic tumors of the uterus, lung and breast and tumors related to steroid hormone synthesis.

976 Significant Genes and Pathways Involved in Low Grade Ovarian Carcinogenesis

T May, M Sharma, I Jurisica, H Begley, B Rosen, KJ Murphy, T Brown, P Shaw. University of Toronto, Toronto, ON, Canada; Ontario Cancer Institute, Toronto, ON, Canada; University Health Network, Toronto, ON, Canada; Princess Margaret Hospital, Toronto, ON, Canada.

Background: Low Grade Serous Carcinoma (LGSC) is a chemoresistant ovarian neoplasm that may arise from Low Malignant Potential Tumor (LMP). Micropapillary features within LMP (LMP-MP) may indicate an increased risk of tumor progression. The aim of this study was to determine the differential gene expression of tumors designed as LMP, LMP-MP, and LGSC and identify genes involved in malignant transformation and carcinogenesis.

Design: Tumors designated as ovarian LMP or LGSC over a ten year period were selected from the Toronto Ovarian Tissue Bank, H&E sections reviewed and classified as LMP (n=18), LMP-MP (n=9), or LGSC (n=11). Matched snap-frozen tissues were retrieved, and sections reviewed to confirm histological classification. Laser capture microdissection was used to isolate epithelial cells from tumor cryosections. RNA was extracted, amplified, reverse transcribed to cDNA and hybridized to Affymetrix U133 Plus 2 arrays. The expression data was analyzed by Significance Analysis of Microarrays (SAM), ArrayAssist and Binary Tree Structured Vector Quantization (BTSVQ). Differentially expressed genes were integrated with a database of known and predicted

protein-protein interactions (OPHID) to identify key genes for validation with real-time PCR and immunohistochemistry applied to tissue microarrays.

Results: SAM analysis has indicated 47 probe sets (representing genes) as differentially expressed between LMP and LMP-MP and 134 probes between LMP and LGSC. No differential gene expression was detected between LMP-MP and LGSC. OPHID analysis suggested gene members of the EGFR and MAPK1/3 pathways to be differentially regulated between the non-invasive disease (LMP) and the invasive tumors (LMP-MP&LGSC). To date, we have successfully validated 2 members of the MAPK1/3 pathway using real-time PCR and are currently validating 5 other genes.

Conclusions: The differential gene expression between the three tumors appears to support the hypothesis that LMP-MP is an intermediate lesion in the malignant progression of LMP to LGSC. Members of the MAPK1/3 and EGFR pathways appear to play a key role in this malignancy continuum. Discovery of novel pathways associated with low grade serous carcinogenesis may lead to development of more effective targeted therapy.

977 HMGA2 Expression as a Biomarker for Aggressive Angiomyxoma

F Medeiros, AM Oliveira, RV Lloyd, L Jin, M Erickson-Johnson, X Wang, BJ Quade. Mayo Clinic, Rochester, MN; Brigham and Women's Hospital, Boston, MA.

Background: Mesenchymal tumors of the lower genital tract include site-specific neoplasms, such as aggressive angiomyxoma (AAM), angiofibroma (AMF) and cellular angiofibroma (CA), as well as other soft tissue tumors, such as leiomyomas (LM) and superficial angiomyxomas (SA). Rearrangements of the chromatin remodeling factor *HMGA2* occur in about one third of AAMs, but not in other genital mesenchymal tumors apart from some LMs. In order to evaluate *HMGA2* as a biomarker in the differential diagnosis of lower genital tract mesenchymal tumors, we investigated *HMGA2* protein expression in a large number of tumors and compared it to their gene rearrangement and transcriptional status.

Design: A total of 86 cases, including 40 AAMs, 17 AMFs, 6 CAs, 5 fibroepithelial stromal polyps, 15 lower genital tract LMs and 3 SAs, were evaluated for *HMGA2* immunohistochemistry (IHC) (Biocheck 59170AP). IHC scoring was blinded to diagnosis, FISH and RT-PCR results. Nuclear staining was scored 0 to 4, but was considered as negative (no staining) or positive (weak to strong). *HMGA2* rearrangements were analyzed by FISH in tissue sections with probes 5' and 3' of *HMGA2*. RT-PCR for *HMGA2* transcripts was performed in 19 AAM, 5 AMFs and 3 CA.

Results: *HMGA2* rearrangements were identified in 15 AAMs (37%) and 1 genital LM by FISH. All other tumors were negative for *HMGA2* rearrangements. *HMGA2* protein was detected in 20 AAMs (50%). Of these, gene rearrangement was found in 13 cases (65%). In contrast, only 2 of 20 AAMs lacking *HMGA2* expression had gene rearrangement by FISH. *HMGA2* immunoreactivity was also present in 2 genital LMs, one of which had *HMGA2* rearrangement. *HMGA2* transcript was upregulated in 10 (52%) AAM, concordant with FISH and IHC results in 8 cases. Of 9 AAM negative by RT-PCR, 3 were positive by FISH or immunohistochemistry. RT-PCR was negative in all AMF and CA tested.

Conclusions: *HMGA2* protein was aberrantly expressed in about 50% of AAM, which was more than would be expected by FISH-detected gene rearrangement and suggests that there is another mechanism of gene deregulation. *HMGA2*, however, was not found in other tumors in the differential diagnosis of AAM. Moreover, *HMGA2* IHC appears to be more sensitive and easier to implement than FISH or RT-PCR. In addition, evaluation of surgical margins and prediction of recurrence risk should be facilitated by the high frequency of aberrant *HMGA2* expression in AAM.

978 Presence of Endometrial Adenocarcinoma-In-Situ (AIS) in Complex Atypical Endometrial Hyperplasia (CAH) Is Associated with Increased Risk of Endometrial Adenocarcinoma (EMCA) in Subsequent Hysterectomy

K Mittal, M Sebenik, C Irwin, Z Yan, D Popiolek, J Curtin, J Palazzo. New York University School of Medicine, New York, NY; North Broward Medical Center, Deerfield Beach, FL; Thomas Jefferson University Hospital, Philadelphia, PA.

Background: The distinction of CAH from EMCA is often problematic. Foci of back-to-back arrangement of glands or foci of cribriforming smaller than 2.1 mm in diameter are considered insufficient for the diagnosis of EMCA by some authors, and sufficient to be diagnosed as EMCA by other authors. We refer to these foci as endometrial adenocarcinoma in situ (AIS). In this study we evaluated findings in subsequent hysterectomy in CAH patients with and without AIS.

Design: Cases with the diagnosis of CAH on endometrial curettage/biopsy and subsequent hysterectomy were examined for the presence of AIS. AIS was defined as foci of back to back arrangement of glands or foci of cribriforming composed of at least 4 glands and smaller than 2.1 mm in diameter. When AIS was present, the size of the largest AIS focus was noted. Follow-up findings, including the presence or absence of EMCA in the hysterectomy specimen, the grade of the carcinoma and the depth of myometrial invasion were analyzed.

Results: Of the total 87 patients with CAH, thirty-three patients had AIS and 54 lacked AIS. Twenty-two of 33 (66%) patients with AIS had EMCA on subsequent hysterectomy versus 13 of 54 (24%) patients without AIS ($p = 0.0001$). Myo-invasive EMCA was present in 20 of 33 (61%) patients with AIS versus 8 of the 54 (15%) patients without AIS ($p < 0.0001$). The depth of myometrial invasion in cases with myo-invasion was $24.5 \pm 19.4\%$ in patients with AIS and $12.8 \pm 8.5\%$ in patients without AIS ($p = 0.05$). A depth of invasion of greater than 50% was seen in 3 of the 33 patients with AIS, but in none of the 54 patients without AIS ($p = 0.05$). None of the EMCA in either group were FIGO grade III. The size of the AIS focus was not predictive of subsequent carcinoma ($p = 0.68$). Amongst patients younger than age of 50, 5 of the 7 (71%) with AIS had myo-invasive carcinoma versus 2 of the 13 (15%) without AIS ($p = 0.02$).

Conclusions: The likelihood of finding EMCA in subsequent hysterectomy in patients with CAH is significantly increased if AIS is present in prior endometrial sampling.

EMCA in patients with AIS are far more frequently myo-invasive, and invade to a greater depth than EMCA seen in patients without AIS. Use of AIS terminology could lead to improved management of patients with CAH.

979 PTEN Is a Biomarker for Endometrial Glandular Neoplasms That Detects Histologically Occult Precursors ("Latent Precancers") Years in Advance of Clinically Diagnosable Disease

NM Monte, MC Lin, LJ Phang, YK Chun, A Ferenczy, C Eng, K Zbuk, GL Mutter. Brigham and Women's Hospital, Boston, MA; National Taiwan University Hospital, Taipei, Taiwan; SMBD-Jewish General Hospital, Montreal, QC, Canada; Cheil General Hospital & Womens Healthcare Center, Kwandong University College of Medicine, Seoul, Korea; Cleveland Clinic Foundation, Cleveland, OH.

Background: Sporadic mutational inactivation of the PTEN tumor suppressor gene occurs in 60-80% of premalignant (EIN) and malignant (cancer) endometrioid endometrial glandular lesions. This is an early and common event in normal endometrial tissues, with 43% of premenopausal women having scattered PTEN-null glands. Mutations are widely scattered throughout the PTEN gene, making them clone specific markers to determine whether null glands seen at two points in time are of the same or different clones. We used sequenced PTEN mutations to study the clonal relationships between latent and overt stages of neoplastic endometrial disease separated by years.

Design: Six women with PTEN-null endometrial glands in each of paired benign endometrial biopsies followed by neoplastic endometrial disease (5 EIN, 1 cancer) underwent microdissection and DNA isolation. All biopsies were obtained due to bleeding or other clinical indications. DNA was screened for PTEN mutations, which were then confirmed by sequencing.

Results: Only glands lacking PTEN protein contained sequence confirmed PTEN mutations, with the exception of one silent mutation. Of the six women studied, 3 had identical mutations between initial normal appearing, and later neoplastic tissues, separated by 2-7 years. One patient was non-informative (lacked mutation). Two patients had differing PTEN mutations at different timepoints, consistent with independent events.

Conclusions: Half of women with sporadic PTEN defective neoplastic endometrial disease have histologically normal "latent precancers" containing mutations carried forward years later into overtly neoplastic clones. Another third show turnover of multiple clones in the years preceding development of histologic disease. These data prove the principle that initial events of carcinogenesis are detectable with appropriate biomarkers in normal tissues long before histologic changes diagnostic of EIN or carcinoma.

980 Epithelial-Mesenchymal Transition (EMT) in Early Stages of Endometrioid Endometrial Carcinomas

N Monserrat, L Catusas, J Pena, A Gallardo, M Cuatrecasas, X Matias-Guiu, J Prat. Hospital de la Santa Creu i Sant Pau, Autonomous University of Barcelona, Barcelona, Spain; Hospital Armau de Vilanova, University of Lleida, Lleida, Spain.

Background: Epithelial-mesenchymal transition (EMT) is involved in the development of invasion and metastasis. Twist is a transcription factor that regulates the EMT program. We investigated some of the EMT genes and other molecular alterations in early stages of endometrioid endometrial carcinomas (EEC).

Design: Genomic DNA was obtained from 26 early stage EEC (8 Ia, 4 Ib and 14 Ic). Ic samples both from surface and myoinvasive fronts were taken. Mutational analysis for *PIK3CA* (exons 9 and 20), *PTEN*, *K-RAS*, and *CTNNB1* were performed. Loss of heterozygosity (LOH) at the PTEN locus was measured by analyzing 3 different microsatellite markers (D10S579, D10S532, D10S2491). Microsatellite instability (MI) for 5 different loci (BAT25, BAT26, D2S123, D5S346 and D17S250) was also done. Tissue-arrays for immunohistochemical analysis of Twist, E-cadherin, and vimentin were done. Expression of Twist, E-cadherin, Snail, and *HMGA2* was evaluated by RT-PCR. Clinicopathologic data were obtained.

Results: In Ia carcinomas, LOH of *PTEN* (5%), MI (38%), and mutations of *PTEN* (62.5%), *KRAS* (12.5%) and *PIK3CA* (exon 20) (12.5%) were found; exons 9 and 20 *PIK3CA* mutations (50% each) were found in Ib tumors; in Ic cases, LOH of *PTEN* (14.5%) and mutations of *PTEN* (58%), *KRAS* (14.3%), *CTNNB1* (7.15%), and *PIK3CA* (exon 9 and 20) (14.5%) were detected both in surface and myoinvasive fronts. *KRAS* mutations coexisted with exon 8 *PTEN* mutations in all cases. Twist, vimentin, *HMGA2*, and *SNAIL* expressions were found to be increased in the myoinvasive front compared with normal tissue ($p < 0.05$).

Conclusions: Molecular alterations were similar in Ia, Ib, and Ic carcinomas. The expression of EMT markers was higher in the myoinvasive front.

981 Activating C-kit Mutations in Dysgerminoma of the Ovary

MJ Morton, MS Wang, LM Roth, WX Zheng, FW Abdul Karim, L Cheng. Indiana University, Indianapolis, IN; University of Arizona, Tucson, AZ; Case Western Reserve University, Cleveland, OH.

Background: The expression of the tyrosine kinase receptor c-kit is necessary for normal germ cell migration and development, and this expression appears to be important in the majority of their malignant counterparts (seminomas and dysgerminomas) as demonstrated by immunohistochemistry. Also, point mutations imparting constitutive activity to c-kit's tyrosine kinase domain occur in a subset of seminomas and likely function in their pathogenesis. Dysgerminomas are much less common, and activating c-kit mutations have been demonstrated in only 7 of the 28 cases tested. To gain further knowledge about the role of c-kit mutations in the pathogenesis of dysgerminomas, we analyzed 22 cases using PCR screening and direct sequencing of codon 816.

Design: H&E stained tissue sections from 22 cases of dysgerminoma were obtained. Dysgerminoma cells were dissected under direct microscopic visualization followed by DNA extraction and PCR amplification using exon 17 primers. After AatII digestion, the

PCR products underwent gel electrophoresis. Additional PCR products were directly sequenced using an ABI sequencer.

Results: C-kit codon 816 mutations were found in 6 cases (27%) by both the screening and direct sequencing methods. The mutations included D816Y (2), D186H (2), and D816V (2). Interestingly, 4 of these positive cases were stage III tumors, while only 2 of the negative cases were stage III with the remainder being stage I (P<0.01).

Conclusions: Our findings indicate that activating c-kit mutations occur in dysgerminomas with a similar frequency as in seminomas and are likely involved in the pathogenesis of both these tumors. The association with advanced stage dysgerminomas suggests that these mutations may impart more aggressive behavior. The identification of activating mutations may be important for the treatment of germinomas with the development of tyrosine kinase inhibitors specific for codon 816 mutations.

982 Immunophenotyping of Serous Carcinoma of the Female Genital Tract

S Nofech-Mozes, MA Khalifa, N Ismiil, RS Saad, Z Ghorab. Sunnybrook Health Sciences Centre, Toronto, Canada.

Background: Serous carcinoma may arise from various organs along the female genital tract and peritoneum. The aim of this study is to update our knowledge of this tumor's immunophenotype in view of the limited, recently published data suggesting the expression of "mesothelioma markers" by ovarian serous tumors.

Design: Consecutive cases of pure serous carcinoma from the ovary (n=56), endometrium (n=34), fallopian tube (n=6), primary peritoneum (n=5) and cervix (n=3) were retrieved from our archives (1999-2007). Two gynecologic pathologists reviewed the cases and studied the immunohistochemical profile using a panel of antibodies against: WT1, p53, estrogen receptor (ER), HER2/neu (SP3), D2-40, cytokeratin 5/6 (CK5/6) and E-cadherin. Immunostaining was recorded semiquantitatively; Negative (0%); Focal (1-50%); Strong (>50%). HER2/neu was considered positive only when complete strong membrane staining was identified.

Results: All the ovarian carcinomas demonstrated strong reactivity for WT1, 84% for p53, 64% for ER, 0% for HER2/neu, 13% for any D2-40 reactivity and 55% for any CK 5/6 reactivity and 14% for strong CK 5/6 reactivity. Endometrial carcinomas demonstrated strong reactivity for the following: 44% for WT1, 91% for p53, 3% for ER, and 21% for HER2/neu. Any D2-40 reactivity was seen in 47% of cases and only focal CK 5/6 reactivity in 41%. All carcinomas exhibited diffuse E-cadherin reactivity. The D2-40 staining pattern was predominantly focal, however strong reactivity was identified in 18% of endometrial and 11% of ovarian carcinomas. There was a significant difference in staining of ovarian and endometrial carcinomas regarding WT1 (p<0.001) and ER (p<0.001) reactivity. The expression in other sites is summarized in table 1.

	Score	Fallopian tube n=6	Primary perito. n=5	Cervical n=3
WT1	N			2
	F		4	
	S	6	1	1
P53	N	1		1
	F		1	
	S	5	4	2
ER	N	1	2	2
	F	3	3	1
	S	1		
HER2/NEU	N	6	5	3
	F			
	S			
D2-40	N	5	5	3
	F	1		
	S			
CK5/6	N	5	5	
	F	1		
	S			3

N=negative, F=focal, S=strong, P=positive

Conclusions: D2-40 and CK 5/6 are expressed in considerable proportion of serous carcinomas and should be used cautiously in a "mesothelioma panel". The focal CK 5/6 and D2-40 expression in substantial number of cases may limit the value of microarray studies. HER2/neu was exclusively overexpressed in serous carcinomas of endometrial origin and could be used to differentiate it from metastases of other sites in cases with advanced disease.

983 Expression of PAX8 as a Useful Marker in the Differential Diagnosis of Ovarian and Mammary Carcinomas

D Nonaka, L Chiriboga, RA Soslow. New York University School of Medicine, New York, NY; Memorial Sloan-Kettering Cancer Center, New York, NY.

Background: Ovarian metastasis is common in patients with breast cancer, and can be seen in 30% of prophylactic oophorectomy specimens from patients with breast cancer. Ovarian metastasis is rarely found prior to a diagnosis of breast tumor, and such a case may clinically mimic a primary ovarian tumor. Additionally patients with mammary carcinomas have an increased risk of developing second malignant tumors, among which ovarian carcinoma is one of the most common. Conversely ovarian carcinomas can rarely metastasize to axillary lymph nodes and even mammary glands. Both ovarian and mammary carcinomas share similar morphologic and immunohistochemical features. In problematic cases, stains for WT1 and GCDFFP-15 are useful for a determination of the primary site. Pax8 is a crucial transcription factor for organogenesis of thyroid gland, kidney and Mullerian system, and it also regulates WT1 expression. A DNA microarray study reported Pax8 expression to be one of the best discriminatory markers between ovarian and mammary carcinomas.

Design: A total of 135 cases of ovarian carcinomas (83 serous papillary, 18 endometrioid, 12 mucinous, 10 clear cell, 8 mixed, 3 serous borderline, 1 malignant Brenner) and 213 cases of invasive mammary carcinomas (168 ductal, 41 lobular, 2 medullary, 1

micropapillary, 1 mucinous) were immunostained with Pax8 by tissue microarrays. The extent of staining was graded as 1+, 1-25%; 2+, 25-50%; 3+, 50-75%; 4+, >75%.

Results: Ages ranged from 36 to 79 (median 61) for ovarian carcinomas and from 27 to 89 (median 48) for mammary carcinomas. Pax8 reaction was found in 117/135 ovarian carcinomas (86.7%), and 116/123 cases (94.3%) of non-mucinous ovarian carcinomas. The reaction was generally diffuse (3+/4+) and seen in 80/83 (96.4%) serous papillary carcinomas, 15/18 (83.3%) endometrioid carcinomas, 10/10 (100%) clear cell carcinomas, and 7/8 (87.5%) mixed type, while the expression was seen in only 1/12 (8.3%) mucinous carcinomas with 2+ reaction. It was also strongly expressed in Malignant Brenner tumor and serous borderline tumors. All the mammary carcinomas were completely negative for Pax8.

Conclusions: Pax8 is a useful marker in the differential diagnosis of ovarian and mammary carcinomas, and it appears to be superior to WT1 for the diagnosis of all types of non-mucinous ovarian carcinomas, notably clear cell and endometrioid types where WT1 expression is generally negative or only focal.

984 High-Risk Human Papilloma Virus Testing: A Comparison of Two Signal Amplification Testing Methodologies Via a Cytologic/Histologic Review of 2264 Cases

CA Novotny, PM Houser, D Holloman, D Quigley, C Blair, A McJumkin, K Metcalfe, M Fraig, SM Knoepf. Medical University of South Carolina, Charleston, SC.

Background: The ALTS trial has previously established high-risk (hr) HPV testing as a major tool used in the triage of cervical cytology specimens with ASC-US results. hrHPV testing methods based on signal amplification such as the Digene Hybrid Capture II (HC II) and Third Wave Technologies Invader High Risk Assay (TWT) have been shown to correlate well utilizing PCR as the standard for hrHPV detection, however, limited data is available demonstrating correlation of these methods with histologic follow-up in similar patient populations. We sought to compare these testing methodologies as our institution recently switched from DiGene HCII at an external lab to performing in-house testing utilizing TWT Invader. We examined the results of these tests with regard to both cytologic diagnoses as well as histologic follow-up.

Design: Over a 7 year period, results of 1345 HCII tests and 919 TWT tests were examined and correlated to corresponding cytologic diagnoses. The available corresponding histologic follow up (within 6 months of hrHPV testing) was reviewed and correlated with hrHPV testing data.

Results: A total of 2264 hrHPV tests were evaluated. ASC-US diagnoses accounted for 60.5% of the 1345 HCII hrHPV tests and 80.2% of the 919 TWT hrHPV tests. Overall, 44% of HC-II hrHPV tests were positive, compared to 27% of TWT. ASC-US cases tested with HCII were positive for hrHPV in 44% of cases. ASC-US cases tested with TWT were positive for hrHPV in 27% of cases. Available histologic follow-up of ASC-US cases revealed 13% CIN 1 and 4% CIN 2/3 after a positive HCII hrHPV test and 15% CIN 1 and 2.5% CIN 2 after a positive TWT hrHPV test.

Conclusions: Our study revealed a notable difference in hrHPV positivity rates of HCII and TWT tests over the study time period. However, when histologic follow-up was examined, no significant difference was observed between HCII or TWT. Rates of dysplasia in our medical center population were compatible with rates in other similar populations. The differences seen in the number of positive and negative tests with regard to the different testing methodologies may reflect changing practice patterns among gynecologists at our institution, as more reflex testing of ASC-US cases may result in a greater proportion of hrHPV-negative ASC-US cases. This is consistent with lower rates of positive hrHPV tests seen in TWT testing at our institution.

985 Intravenous Leiomyomatosis: An Unusual Intermediate between Benign and Malignant Uterine Smooth Muscle Tumors

MR Nucci, P Dal Cin, J Hodge, M Hollowell, CN Otis, JL Hornick, CC Morton, BJ Quade. Brigham and Women's Hospital/Harvard Medical School, Boston, MA; Baystate Medical Center, Springfield, MA.

Background: Intravenous leiomyomatosis (IVL) is a curious smooth muscle lesion with quasi-malignant intravascular growth but a histologically banal appearance. IVL may be confused with other uterine tumors showing prominent intravascular extension, such as endometrial stromal sarcoma and low-grade leiomyosarcoma (LMS). We have reported der(14)t(12;14)(q15;q24) in each of two previously karyotyped IVL cases. This unbalanced alteration is similar to a subset of balanced rearrangements found in uterine leiomyomata (UL) and suggests a pathogenetic relationship between IVL and UL based on dysregulation of the chromatin remodeling factor *HMG2* at 12q15.

Design: To better understand the pathogenesis of IVL, we analyzed a series of 12 cases for HMG2, MDM2 and CDK4 protein expression. One of these samples also was karyotyped (for a total of 3 cases). Expression profiling also was performed on 2 cases and an additional sample from the Cooperative Human Tissue Network. These 3 IVL expression profiles were compared to those of myometrium, UL and LMS using a gene set that distinguishes benign from malignant smooth muscle.

Results: Seven of 12 (58%) cases of IVL showed strong, diffuse nuclear staining for HMG2 protein. Karyotypic analysis of the third case demonstrated 45,XX,del(12)(q174q175),hsr(14)(q271)-22[7].ish del(12)(HMG2-MDM2-),hsr(14)amp(3' HMG2,MDM2) in all metaphases. This apparent interstitial deletion of 12q was associated with *HMG2* and *MDM2* amplification on the abnormal 14q by FISH; however, overexpression of MDM2 or CDK4 protein by immunohistochemistry was not present in this or any of the other IVL cases. Hierarchical cluster analysis of the expression profiles segregated the IVL case with LMS rather than with myometrium and UL of the usual histology.

Conclusions: The frequency of HMG2 protein expression in IVL (58%) was higher than that reported in UL (32%), which suggests that HMG2 expression plays an important pathogenetic role in IVL, possibly by altering chromatin structure and thus epigenetic control of gene expression. Although one case showed evidence of 12q amplification, lack of MDM2 and CDK4 protein expression excludes their involvement.

Interestingly, although IVL is histologically similar to UL, gene expression profiling reveals a closer relationship of IVL to LMS than was expected and further study may provide a molecular explanation for vascular invasiveness.

986 Use of PAX-2 Antibody To Distinguish Metastatic Ovarian Serous Papillary Carcinoma from Primary Breast Carcinoma

SM O'Connor, R Bhargava, R Karabakhtian, DJ Dabbs, M Chivukula. Magee Womens Hospital at University of Pittsburgh Medical Center, Pittsburgh, PA; University of Kentucky, Lexington, KY.

Background: Ovarian serous papillary carcinoma (OSC) rarely metastasizes to the breast, but distinction from primary breast carcinoma (PBC) is often challenging based on morphology alone, particularly in the micropapillary subtype (MP). Immunohistochemical stains such as CK7 and CK20, which are useful in differentiating breast and ovarian carcinomas from other adenocarcinomas, are not helpful in this situation. Although p53 expression is more common in OSC, it may also be positive in a substantial minority of PBC. GCDFFP-15 is very specific for breast cancer, but it is less sensitive, and may be negative in up to 50% of breast carcinomas. WT-1 has been identified as a useful marker to differentiate metastatic OSC from PBC. However, WT-1 expression is demonstrated in some PBC making it a less sensitive marker in distinguishing it from metastatic OSC. PAX-2 gene encodes a transcription factor which is expressed in the intermediate mesoderm from which the Wolffian duct and kidneys originate as well as müllerian ducts. PAX-2 expression was recently demonstrated in epithelial cells of the female genital tract from the fimbriae to the cervix as well as OSC.

Design: Twenty-six (26) PBC designated as "micropapillary" (MP) or with "MP features" were retrieved from the pathology case archives. The specimens were reviewed and classified as IDC pure MP type (12), mixed MP and mucinous type (2), mixed no special type and MP (6), and no special type carcinoma with retraction artifact (6). A tissue microarray with 3-fold redundancy was created for these cases, consisting of cores with a diameter of 0.6 mm. In comparison, three (3) cases of OSC metastatic to breast and one (1) infiltrating ductal carcinoma (IDC) metastatic to ovary were retrieved from the archives. All cases were stained with rabbit polyclonal PAX-2 antibody (Invitrogen). A strong nuclear staining was considered positive, and graded as negative (0), weak (1+), moderate (2+), and strong (3+), and percentage of positive staining was recorded as negative (0%), 5-20%, 25-80%, and greater than 80%.

Results: All the subtypes of IDC in the TMA were entirely negative 100% (26/26), while 100% (3/3) metastatic OSC showed 3+ staining. One case of metastatic IDC to ovary was negative.

Conclusions: PAX-2 is a useful marker in distinguishing metastatic OSC from PBC and may also serve as an adjunct in differentiating metastatic IDC from primary ovarian carcinoma.

987 Differential MicroRNA Expression in Primary Peritoneal Serous Carcinoma Versus Ovarian Serous Carcinoma

JJ O'Leary, P Smyth, A Laios, S O'Toole, S Russell, J Li, K Denning, S Aherne, M Ring, C Martin, B Sheppard, K Lao, O Sheils, RJ Flavin. Trinity College, Dublin, Ireland; Applied Biosystems, Foster City, CA.

Background: Papillary serous carcinoma of the peritoneum (PSCP) closely resembles papillary serous ovarian carcinoma (PSOC) histologically and clinically however PSCP is characterised by minimal involvement of the ovary. Though both tumours share similar genetic events; PSCP has been classified as a unique biological entity. MicroRNAs (miRNAs) are a group of small ncRNA's approximately 22 nt in length. Unique miRNA expression profiles having been able to subclassify various cancers, however PSOC/PSCP have not been specifically looked at. We characterized the expression profiles of miR-16, miR-323, miR-495 and miR-181a in both tumour types, and analysed the protein expression of bcl-2, a validated target of miR-16.

Design: Total RNA was extracted from 20 PSOC and 20 PSCP FFPE cases of high grade and advanced FIGO stage using Ambion RecoverAll™ Total Nucleic Acid Extraction Kit. An early release stemloop RT/PCR kit was used for miRNA gene expression profiling (ABI). Analysis of relative miRNA expression data was performed using the $\Delta\Delta Ct$ method. Let-7 was used as normaliser. miRGen was used to analyse predicted miRNA targets. Pathway analysis was performed using the PANTHER™ Classification system. Bcl-2 expression was detected by immunohistochemical staining of a TMA containing 66 PSCP/PSOC tumours of high grade and advanced FIGO stage and scored semiquantitatively based on intensity (0-3) and percentage of tumour cells staining (1-4).

Results:

miRNA	Fold Change	p-value
miR-181a	0.022	3.14E-34
miR-16	0.025	2.95E-33
miR-495	0.406	0.0015
miR-323	5.058	7.12E-09

Differential miRNA expression in PSCP v PSOC

Over-representation of potential pathways affected by upregulated miRNA miR-323 include the EGF receptor, Interleukin signalling and WNT signalling pathways. Over-representation of potential pathways affected by downregulated miRNAs includes the PDGF, TGF- β and apoptotic signalling pathways. There was both a quantitative and qualitative increase in bcl-2 protein expression in PSCP (6/29 cases + =20.6%; median score=5) relative to PSOC (7/38 cases + = 18.4%; median score=3).

Conclusions: PSCP has distinctive miRNA expression profiles relative to PSOC. These up/down regulated miRNAs may have a role in ovarian and primary peritoneal serous carcinoma pathogenesis.

988 Frequent Lymphovascular Invasion but Not Aggressive Behavior Is Characteristic of Endometrioid Endometrial Carcinomas with "MELF" Features: A Clinicopathologic Study of 22 Cases

E Oliva, G Toledo. Massachusetts General Hospital, Boston, MA.

Background: Some endometrioid endometrial carcinomas (EECs) show a very characteristic microscopic appearance which has been termed "MELF". It is defined by the following features: glands with frequent microcystic (M) architecture which appear elongated (EL) and typically fragmented (F) and are lined by flattened epithelium. These tumors usually display a prominent fibromyxoid stromal reaction (FMSR) associated with neutrophilic microabscesses and lymphovascular invasion (LVI). Only one previously reported series showed that the presence of "MELF" with prominent FMSR in EECs is not associated with adverse outcome.

Design: 229 EECs from patients diagnosed from 1993 to 2001 were reviewed. Histologic parameters assessed besides "MELF" morphology included histologic grade, presence of squamous and mucinous differentiation, type and degree of inflammatory and stromal reactions, lymphovascular invasion and presence of lymph node metastases (when available). Clinical data including stage, recurrences and/or metastases and follow-up were collected.

Results: "MELF" features were seen in 22/229 cases (9.6%) and ranged from focal (<10% in 7 cases to diffuse (>50%) in 13 EECs and it was more prominent along the infiltrative border of the tumor. Squamous and mucinous differentiation were seen in 18 (81.8%) and 10 (45.5%) EECs respectively. Prominent acute inflammatory response with microabscess formation was present in 14 (63.6%) cases, while marked lymphoplasmacytic reaction was seen in 8 (36.3%). Intense FMSR was observed in 13 EECs (59%). Twelve tumors were G1 (54.5%), 9 were G2 (40.9%) and 1 was G3. LVI was present in 18 EECs (81.8%) and not infrequently showed isolated or small clusters of deceptively appearing cells. Lymph node metastases were detected in 7 of 13 cases where lymph nodes were available. Twelve patients had stage I tumors (54.5%), 5 had stage II and 5 had either stage III or IV. Follow-up, available in 19 patients, ranged from 38 to 172 (mean 105) months. Only one patient died from disease and one had a recurrence.

Conclusions: EECs with a "MELF" pattern are not uncommon. Even though the worrisome morphologic appearance and the high rate of LVI and lymph node metastases observed in these tumors, these patients still have long survival rates. These results parallel the only series previously reported. The prominent inflammatory-stromal reaction seen in these EECs may be potentially responsible for the less than expected aggressive behavior of these tumors.

989 Comparison of Glut1, p16, and Ki-67 Immunostaining in the Assessment of Endocervical Lesions

SA Oman, SA Rosen, S Lathrop, A Chakerian, NE Joste. University of New Mexico School of Medicine, Albuquerque, NM.

Background: Diagnostic difficulties associated with distinguishing endocervical dysplasia and neoplasia from benign mimics have stimulated interest in utilization of molecular biomarkers to aid in accurately characterizing endocervical lesions. Given the involvement of HPV infection in malignant transformation of cervical epithelial cells, some candidate biomarkers may be upregulated in HPV-infected cells, including p16 and Ki-67. Glut1, a glucose transport protein, is an additional candidate biomarker for endocervical neoplasia as its expression has been shown to increase with severity of dysplasia in cervical squamous cell neoplasia. The purpose of this study was to examine the relative utility of Glut1, p16 and Ki-67 immunostains in resolving diagnostic challenges presented by endocervical lesions.

Design: Immunohistochemical analysis of Glut1, p16 and Ki-67 was performed on tissue from 118 cases, including reactive atypia (n=19), low grade dysplasia (LG; n=22), adenocarcinoma in-situ (AIS; n=34), invasive adenocarcinoma (AI; n=26), and benign endocervix (n=17). Staining intensity was scored (weak, moderate, strong) as was the percentage of cells staining positive (negative; low, 1-24%; moderate, 25-49%; high, 50-100%).

Results: Cases diagnosed as AIS or AI were significantly more likely to demonstrate positive staining for each of the 3 biomarkers than cases diagnosed as benign, reactive, or low grade (p<0.0001 for all 3). Positive staining for p16, Ki-67, and Glut1 was seen in 93%, 91%, and 47% of neoplastic lesions (AIS or IA) and 15%, 15%, and 2% of non-neoplastic lesions (LG, reactive, or benign endocervix), respectively. Glut1 showed moderate or strong intensity staining in 56% of neoplastic lesions compared with 88% with p16 and 92% with Ki-67. Only 42% of neoplastic lesions were positive for all 3 biomarkers. Glut1 paired with either p16 or Ki-67 was positive in 43% of neoplastic lesions. Ki-67 paired with p16 was positive in 86% of neoplastic lesions.

Conclusions: Glut1 overexpression is considered an early step in cervical squamous cell carcinoma; however, our results show a weaker association in endocervical neoplasia. These results do not suggest a role for Glut1 in distinguishing early endocervical neoplastic lesions from cases of benign or reactive endocervix. We confirm that Ki-67 and p16 are both strongly associated with endocervical neoplasia, in both in-situ and invasive lesions. Used together, these two biomarkers are useful in identifying endocervical neoplasia, including ambiguous lesions.

990 Comparative Study of Methods To Determine Depth of Invasion in Vulvar Squamous Cell Carcinoma

DA Ostler, A Malpica, CC Sun, AG Perna, AH Diwan, AJ Lazar, MT Deavers, VG Prieto. MD Anderson Cancer Center, Houston, TX; Beth Israel Deaconess, Boston, MA.

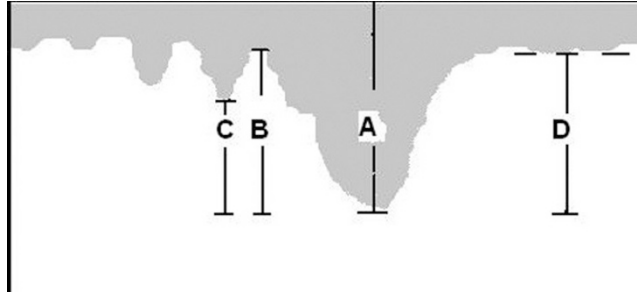
Background: Depth of invasion and tumor thickness are important prognostic factors in vulvar squamous cell carcinoma (vSCC). However, it is not clear whether one means of measurement is superior to another.

Design: Seventy-four cases of vulvar squamous cell carcinoma from 1986 to 2004 had adequate material for evaluation. The tumor depth of invasion (DOI) was measured to the deepest invasive component in four manners (see figure1): (A) from the tumor

surface (total tumor thickness), (B) from the adjacent most superficial dermal papilla (FIGO staging system), (C) from the bottom of the deepest rete ridge, and (D) from an imaginary line drawn from the tips of normal rete tips in the adjacent epithelium. Logistic regression and Cox proportional hazards were used to assess the impact of each method of measuring DOI on the presence of metastasis and progression-free survival (PFS), respectively.

Results: The median age of patients at diagnosis was 67.6 years and the mean age was 66.0. FIGO stages were: I=43, II=13, III=16, and IV=2. The median progression-free survival for all patients was 5.1 years, and the median overall survival was 9.1 years. The median follow-up was 8.2 years. Of the 74 patients, 28 had recurrences (21/43 Stage I, 4/13 Stage II, and 3/16 stage III). For all four methods of measurement, increasing values were associated with increased risk of metastases (p-value range=0.04-0.08). For stages III/IV, a trend was observed for larger values of DOI and reduced PFS (hazard ratio=1.09, p=0.14; hazard ratio=1.10, p=0.11 for methods A and B, respectively).

Conclusions: Our study demonstrates that larger values for depth of invasion in vSCC, regardless of method employed, are associated with greater risk of metastases and may be associated with decreased progression-free survival. Method C, analogous to the method used in cervical SCC, appears to be the strongest predictor of lymph node metastasis.



991 Protein Kinase CK2 Plays a Role in Apoptosis Resistance in Endometrial Carcinoma, by Regulating FLIP

J Pallares, X Dolcet, D Llobet, N Eritja, X Matias-Guiu. Hospital U Arnau de Vilanova, Lleida, Spain.

Background: Protein kinase CK2 (CK2) is a serine/threonine kinase that participates in some important cellular processes including cell differentiation, proliferation, and survival. CK2 activity has been found to be enhanced in some human tumors and has been related to apoptosis resistance. Apoptosis resistance is frequent in endometrial carcinoma (EC). One of the critical regulators of apoptosis resistance in EC is FLIP.

Design: CK2 immunostaining was assessed in one tissue microarray (TMA) constructed from paraffin-embedded blocks of 80 samples of normal endometrium in different phases of the menstrual cycle (NE), and in another TMA from 95 endometrial carcinomas (EC). Immunohistochemical evaluation included percentage of positive cells, and intensity of the staining. In EC, CK2 expression was correlated with stage, histological type and grade, apoptotic index, and immunostaining for PTEN, AKT, beta-catenin, and FLIP. Moreover, four different endometrial adenocarcinoma cell lines, which are known to exhibit resistance to TRAIL-induced apoptosis (Ishikawa, KLE, HEC1A, and RL-95) were subjected to down-regulation of CK2 (pharmacological inhibition or siRNA). Cell viability and apoptotic morphology was determined.

Results: CK2 was expressed in NE, and the staining pattern was similar in different phases of the menstrual cycle. Immunostaining for CK2 was frequent in EC (100%). In EC, CK2 was expressed in the nucleus (100%), and in the cytoplasm (87,8%), but the intensity of the staining was variable. Nuclear and cytoplasmic CK2 expression was stronger in EC than in NE (p = 0.000). CK2 immunostaining was stronger in non-endometrioid EC. No correlation was seen between CK2 immunostaining and stage, histological type and grade. However, CK2 immunostaining showed a positive correlation with AKT immunostaining (r=0.24; p=0.025) and with FLIP immunoreactivity (r=0.23, p=0.03), and a nearly significant negative correlation with PTEN. Treatment of the four cell lines with TRAIL failed to induce cell death. However, downregulation of CK2 by pharmacological inhibition, or siRNA, reduced FLIP cellular levels, and overcame apoptosis induced by TRAIL.

Conclusions: The results suggest that CK2 immunostaining is frequent in endometrial carcinoma, and correlates with AKT and FLIP. Results obtained from cell lines suggest that CK2 may participate in the process of apoptosis resistance in endometrial carcinoma, by regulating FLIP.

992 Urothelial Carcinoma Involving the Gynecologic Tract: A Clinicopathologic Analysis of 4 Novel Cases

KJ Park, RA Soslow, O Lin, A Gopalan, SK Tickoo, VE Reuter, SW Fine. Memorial Sloan-Kettering Cancer Center, New York, NY.

Background: Urothelial carcinoma (UC) is typically diagnosed by sampling the urinary tract, mainly bladder, renal pelvis, and ureters. UC extending to and invading the lower gynecologic (GYN) tract, for which primary lesions are a significant differential diagnostic consideration, has not been well studied.

Design: 4 women presenting with histologically proven UC involving the lower GYN tract (cervix, vagina, vulva) were included in this study. The medical records, biopsy/resection slides, and cytology preparations were evaluated for anatomic distribution and UC growth patterns.

Results:

Case #	Initial Site of Detection (lesion)	Other Sites of Involvement in Chronologic Order (#recurrences) [growth pattern]
1	Bladder (papillary HG)	Cervix* (3) [pagetoid CIS] / Vagina* (3) [papillary and invasive] / Pelvic soft tissue / Inguinal LN
2	Renal Pelvis/Distal Ureter (invasive HG)	Vagina (3) [pagetoid CIS, papillary, and invasive] / Urethra [pagetoid CIS] / Rectum [invasive] / Vulva [pagetoid CIS and invasive]
3	Bladder (invasive papillary HG)	Renal pelvis / Ureter / UEA** / Vagina* / Clitoris [papillary]
4	Ureters (flat CIS)	Bladder / Vagina [pagetoid CIS] / Cervix / LUS [pagetoid CIS and invasive]

HG: high grade; CIS: carcinoma in situ; UEA: uretero-enteric anastomosis; B/L: bilateral; LUS: lower uterine segment. * also detected on cytology; **ASCUS on voided urine

The results are summarized in the table above. All initial sites of involvement were in the urothelial tract and showed HG UC: 2 invasive (pT3 in renal pelvis; pT1 in bladder) and 2 non-invasive (papillary in bladder; flat carcinoma in situ (CIS) in ureters). UC involved vagina in 4/4 patients, cervix in 2/4 patients (1 initially detected on Pap smear/ECC), and vulva/rectum and clitoris in 1 patient each. In 2 cases, invasion was seen only in: vagina (subsequently invading pelvic soft tissue) or cervix/lower uterine segment. One case showed tumor spread from renal pelvis/ureter to GYN tract without detectable disease in the bladder.

Conclusions: UC can extend along the lower GYN tract as pagetoid CIS or as multiple papillary lesions. These tumors are not necessarily detected in an anatomically contiguous fashion. Otherwise non-invasive UC in the urothelial tract may invade only in GYN sites. Because UC can mimic both squamous and "pagetoid" lesions, as well as manifest overt squamous differentiation, this differential diagnosis should be considered in biopsies of cervix, vulva and vagina, and especially in cytologic Pap preparations.

993 Unusual Endocervical Adenocarcinomas: An Immunohistochemical Analysis with Molecular Detection of Human Papillomavirus

KJ Park, C Lamb, E Oliva, RA Soslow, T Kiyokawa. Memorial Sloan-Kettering Cancer Center, New York, NY; Massachusetts General Hospital, Boston, MA; Jikei University School of Medicine, Tokyo, Japan.

Background: Endocervical adenocarcinoma (EAC) of the usual type is associated with the human papillomavirus (HPV) as a necessary agent in its pathogenesis and is usually strongly positive for p16 and CEAm immunohistochemical (IHC) stains. The association with HPV in unusual types of EAC, including clear cell (CC), serous (S), minimal deviation (MD), gastric (GA) and mesonephric (MN) carcinomas, as well as the IHC staining patterns of these tumors, is less well studied.

Design: We retrospectively collected 30 cases of unusual EAC using WHO and established criteria by Kojima et al. (for GA) and performed IHC stains for p16 and CEAm, as well as markers used in the detection of tumors of similar morphology in other gynecologic sites (p53/serous, hepatocyte nuclear factor [HNF]/CC). Molecular analysis for the presence of high risk HPV using PCR amplification was also performed.

Results: There were 11 CC, 4 S, 9 GA, 3 MD and 3 MN carcinomas. p16 was diffusely positive in 8 cases (5 CC, 2 S, 1 GA), the remaining tumors showing no or only patchy (<25%) staining. p53 was diffusely and strongly positive in 8 cases (5 GA, 1 S, 1 CC, 1 MD), while all were negative for HNF. CEAm was positive in 16 and negative in 14 cases: most CC (9/11) and all MN (3/3) were negative for CEAm, while most GA (8/9) and all MD (3/3) were positive. HPV DNA was detected in only 1 GA carcinoma, which was also diffusely p16 and CEAm positive. In five cases, the HPV status was not evaluable (n/a).

Conclusions: Unusual types of endocervical adenocarcinoma appear to only rarely be associated with high risk HPV infection. The IHC staining patterns for p16 do not necessarily correlate with HPV status in CC carcinomas and the staining of serous and clear cell tumors for p53 and HNF, respectively, is different from their endometrial and ovarian counterparts. CEAm, as expected, is positive in tumors with mucinous morphology. GA carcinomas have a high proportion of p53 positivity which may reflect an alternative non-HPV related carcinogenic pathway.

IHC and HPV status of unusual endocervical adenocarcinomas					
Tumor type (n)	p16*	p53*	CEAm*	HNF*	HPV
CC (11)	5	1	2	0	0 (2 n/a)
S (4)	2	1	3	0	0 (1 n/a)
GA (9)	1	5	8	0	1 (1 n/a)
MD (3)	0	1	3	0	0
MN (3)	0	0	0	0	0 (1 n/a)

*Diffusely positive cases

994 The Extracellular Portion of the MUC16 Cytoplasmic Domain Is Detectable in Ovarian Carcinoma Using a Novel Monoclonal Antibody, 4H11

KJ Park, RA Soslow, I Linkov, D Thapi, D Spriggs. Memorial Sloan-Kettering Cancer Center, New York, NY.

Background: The glycoprotein encoded by *MUC16*, CA125, likely plays a role in tumor invasion and platinum chemo-resistance. The OC125 antibody that recognizes CA125 binds to epitopes in the repeating, glycosylated elements in the external domain of the mucin, distal to a cleavage site. It is currently not known whether serum levels of CA125 (representing cleaved elements) or OC125 expression levels are indicative of the status of the retained molecule. A better understanding of MUC16 may lead to novel therapeutic strategies using portions of the MUC16 molecule and its interactions with potential molecular partners, both in the cancer cell and in the local environment.

Design: Investigators at our institution developed a novel monoclonal antibody, 4H11, that recognizes the extracellular portion of the MUC16 cytoplasmic domain. Its expression and that of OC125 were evaluated in tissue microarrays (TMAs) representing

87 FIGO stages III and IV high grade ovarian serous carcinomas (OSC). 3 microcores from each tumor site were present in the TMA and in many cases, primaries, metastases and recurrences were represented (518 cores total). Expression was semiquantitatively scored using a 0-3 scale in one-half (+) increments. OC125 and 4H11 scores were then compared to determine concordance. Concordant cases had scores that differed by up to one-half, discordant cases had scores that differed by more than 1+ and partially concordant cases differed by 1 to 1+.

Results: 65% of cores showed 2-3 OC125 staining whereas 24% showed 1-1+ and 11% no staining. 53% of cores showed 2-3 4H11 staining whereas 22% showed 1-1+ and 25% showed none. Scores were concordant in 55% of cores; they were partially concordant in 37% and discordant in 8%. 31% of discordant and partially concordant cores together showed higher 4H11 scores than OC125, while 41% of discordant cores demonstrated higher 4H11 scores.

Conclusions: The extracellular portion of the MUC16 cytoplasmic domain is detectable in OSC using a novel monoclonal antibody, 4H11, but there is some appreciable expression discordance with respect to OC125. Discordant cases demonstrated higher levels of 4H11 than other cases, indicating that some tumors negative with OC125 retain cytoplasmic and extracellular portions of this glycoprotein, portions of the molecule that are likely involved in transduction of signals important in the malignant phenotype.

995 Adenocarcinomas of the Lower Uterine Segment: Immunohistochemical Studies of 13 Cases

K Patel, SX Liang, M Pearl, K Park, C Tornos. Stony Brook University Medical Center, Stony Brook; Memorial Sloan-Kettering Cancer Center, New York.

Background: Endometrial and endocervical adenocarcinomas have fairly distinct immunophenotypes that have been used routinely to differentiate one from the other when there is an issue regarding tumor origin, especially in endometrial curettage specimens. However, immunophenotypic features of adenocarcinomas of lower uterine segment have not been well characterized and this was the purpose of the study.

Design: Adenocarcinomas of endometrioid type with or without squamous or mucinous differentiation were included in the study if the epicenter of the tumor was in the lower uterine segment both grossly and microscopically. Cases were excluded if lower uterine segment was only secondarily involved by direct extension from uterine corpus or endocervix. A total of 13 cases met the study criteria. Immunohistochemical studies for estrogen receptor (ER), progesterone receptor (PR), vimentin, p16 and carcinoembryonic antigen (CEA) were performed on selected blocks on Ventana using streptavidin-biotin-peroxidase methodology. Results of immunostains were evaluated based on the percentage, intensity as well as homogeneity of the staining on tumor cells.

Results: Positive immunostains were present in 77% (10/13), 41.7% (5/12), 46.2% (6/13), 84.6% (11/13) and 75% (9/12) of the study cases for ER, PR, vimentin, p16 and CEA, respectively. Most immunoreactivity for ER or vimentin was intermediate or weak staining, while most immunoreactivity for CEA was strong staining. Ten of 11 positive p16 staining was at least intermediate and their staining pattern was unrelated to either ER or CEA pattern. In two p16 negative cases, one was strongly positive for CEA only, and the other was weakly positive for ER and CEA. Four cases showed positive staining for all 5 markers, three of which had intermediate to strong staining for all 5 markers.

Conclusions: Adenocarcinomas of the lower uterine segment have an immunophenotype with mixed features of endometrial and endocervical adenocarcinoma, suggesting that carcinomas in this region may represent a heterogeneous group of tumors. High frequency of positive p16 staining warrants further studies to determine possible carcinogenic role of HPV in this location.

996 Is Depth of Myoinvasion in Low Grade Endometrioid Carcinomas Related to Loss of *KAI1* Expression? A Comparative Study of 62 FIGO Grade I Endometrioid Carcinomas of the Uterine Corpus with Variable Myoinvasion

R Pathi, MR Qudus, ML Lomme, MM Steinhoff, WD Lawrence, CJ Sung. Women & Infants Hospital and The Warren Alpert Medical School of Brown University, Providence, RI.

Background: *KAI1* is a metastasis suppressor gene, located on human chromosome 11p11.2, that was initially demonstrated to suppress metastasis of rat prostate tumor cells. Generally, there is an inverse relationship between the grade of endometrioid carcinoma and the depth of myoinvasion; however, some low grade carcinomas show paradoxically deep invasion. Our aim, therefore, was to study the expression of *KAI1* in low grade endometrioid carcinomas with varying depths of invasion to determine whether *KAI1* plays a role in invasive capability of such tumors.

Design: Sixty two cases of FIGO grade 1 primary endometrioid type endometrial carcinomas were retrieved from the archival files of our institution. The cases were divided into 3 groups, group 1: FIGO stage 1A (noninvasive; 10 cases), group 2: FIGO stage IB ("superficial" myoinvasion < 1/2; 39 cases) and Group 3: FIGO stage IC (> 1/2 "deep" myoinvasion; 13 cases). *KAI1* IHC staining was performed and the intensity of staining was scored as 0, 1+, 2+ and 3+. The extent of staining was expressed as the percentage of staining scored as 0 (< 10%), 1+ (11-25%), 2+ (26-50%) and 3+ (> 50%). The sum of the scores of each case were tabulated and compared.

Results: Mean depths of invasion were 21% and 71 in Group 2 and Group 3 respectively.

Groups	No. Cases positive for <i>KAI1</i> (%)	Immunohistochemical Scores for <i>KAI1</i>		
		Extent of Positivity Range (Median)	Intensity of Staining Range (Median)	Mean of Sum of Scores (Median)
Group 1 Noninvasive (N=10)	8 (80%)	0-3 (1.5)	0-3 (1.5)	3.3 (3)
Group 2 <1/2 Myoinvasion (N=39)	17 (67%)	0-3 (1)	0-3 (1)	2.1 (2)
Group 3 >1/2 Myoinvasion (N=13)	13 (31%)	0-3 (0)	0-3 (0)	1.15 (0)

Conclusions: Comparison of the down regulation of *KAI1* expression in FIGO grade 1 tumors at varying depths of myoinvasion shows a progressive diminution in *KAI1* immunoreexpression from noninvasive, to superficially invasive, to deeply invasive carcinomas. Although the % decrease in immunostaining is not statistically significant (possibly due to sample size), there is a readily observable trend toward concomitant down regulation of *KAI1* and increasing depth of invasion. These findings support at least some role for *KAI1* in the behavior of low grade endometrial carcinomas with other high risk histologic parameters such as deep myoinvasion.

997 Mismatch Repair Protein Expression and MSI Status Are Not Related with BRAF V600E Mutation in Endometrial Carcinoma

G Peiro, L Sanchez-Tejada, C Alenda, FM Peiro, A Paya, S Benlloch, FI Aranda. Hospital General Universitari, Alacant, Spain.

Background: Microsatellite instability (MSI) due to replication errors occurs in hereditary endometrial carcinoma (EC) as well as in sporadic. In both cases, an association of functional inactivation of the mismatch repair (MMR) genes with lack of protein expression is seen. Furthermore, in tumors with defective MMR genes, the RAS/RAF pathway has been suggested an early mutational target. This study investigated the frequency of MSI, MMR gene expression and BRAF status in a series of EC.

Design: Two hundred twenty three EC were evaluated for MMR gene expression (hMLH1, hMSH2, hMSH6 and PMS2) by immunohistochemical methods. Tissue microarrays were constructed using a Beecher manual tissue arrayer and 1 mm cores. Staining of tumor nuclei were evaluated as absent (no protein) or present (any evidence). MSI was analyzed in 103 tumors using a pentaplex polymerase chain reaction assay with five mononucleotide repeats: NR21, NR24, NR27, BAT25 and BAT26. BRAF V600E mutation was analyzed by real-time chemistry TaqMan MGB probes in 138 cases.

Results: Median age of the patients was 63 years (range 34-90 years). Tumors were predominantly of endometrioid type (93%) and FIGO grade 2 (51%). Lack of PMS2 expression (22%) correlated with lack of hMLH1 (20.7%) (p<0.000). Only 3.2% of tumors showed loss of hMSH2. In 20.4% of tumors, MSI was found at >2 loci (MSI-H), being NR27 the most frequent (22.4%). There was a statistical correlation between tumors with loss of expression of at least two MMR gene products and MSI-H status (p<0.000). We identified no BRAF V600E mutations (0%; 0/138). In addition, no significant association was found between MMR and MSI status with histologic type or FIGO grade (p>0.05).

Conclusions: BRAF is not influenced by the MMR gene expression and MSI status in EC. In our hands, among the five recommended mononucleotide repeats, NR27 is the most useful for the evaluation of MSI-H.

998 Predictors of Residual Disease on Hysterectomy after Electrosurgical Excisional Procedure with Positive Margins

D Perez Montiel, D Cantu de Leon, M Gomez Alvarado, Y Copado Mendoza, J Chanona Vilchis, L Bornstein Quevedo. Instituto Nacional de Cancerologia, Mexico City, Mexico; Tecnologico de Monterrey, Monterrey, Mexico; Laboratorios Brax, Mexico City, Mexico.

Background: Loop electrosurgical excisional procedure (LEEP) is the treatment of choice in patients with cervical intraepithelial neoplasia (CIN). Patients with positive margins have to undergo hysterectomy for definitive treatment with a rate as high as 50% of specimens negative. This study was performed in intent to identify predictors for residual disease in hysterectomy specimens of patients with positive margins in LEEP specimens.

Design: Patients treated by hysterectomy after LEEP with positive margins and CIN were included. Cases with invasion and glandular neoplasia were excluded. Pathological features evaluated were: Size of the LEEP, safe hat, size of the lesion, percent of affected fragments, number of fragments with positive margins (endocervical, exocervical, or both), and presence or not of inflammatory response. Variables such as age and time from LEEP to hysterectomy, were also recorded. Univariate analysis was performed using Chi-square test, t test, and Wilcoxon Rank Sum. Multivariate logistic regression analysis was used to test relationships between preoperative factors and presence of residual disease on the final pathologic report. Results were considered statistically significant if p < 0.05.

Results: Ninety-eight specimens were evaluated, median age was 42 years. Of LEEP specimens median size of lesion 0.5 cms (range 0.1 to 2cm.). Median of percent of fragments affected was 40% (5-100%). Inflammatory response of the stroma was present in 56 cases (57%). Exocervical involvement was present in 6%, endocervical 64% and both 30%. On hysterectomy specimens 58% were negative for residual disease, 2.1% CIN II, 2.1% CIN III, 32.3% In situ carcinoma, 2.1% microinvasive, 3.2% invasive carcinoma. On multivariate analysis variables that independently predicted residual disease were age (OR= 1.049, p= 0.05) and percent of affected fragments (OR= 9.74, p=0.038).

Conclusions: High rates of negative hysterectomy specimens are found after LEEP with positive margins. Age and extent of disease, evaluated by the number of fragments affected in the LEEP specimen, seemed to be the best predictors of residual disease instead of the positiveness of the margins or the number of positive margins as others have previously reported.

999 Biomarker (ProEx™ C, p16^{INK4A} and Mib-1) Distinction of High Grade Squamous Intraepithelial Lesions (HSIL) from Its Mimics

AP Pinto, N Schlecht, T Woo, CP Crum, E Cibas. Brigham and Women's Hospital, Harvard Medical School, Boston, MA; Federal University of Paraná, Curitiba, PR, Brazil; Albert Einstein College of Medicine, Bronx, NY.

Background: Topoisomerase II alpha (TOP2A) and minichromosome maintenance protein 2 (MCM2) are proteins associated with aberrant S-phase induction. The current study evaluated the performance of these biomarkers (ProEx™ C-TriPath Oncology,

Burlington, NC) in the context of p16^{INK4A} and MiB-1 to distinguish high-grade squamous intraepithelial lesions (HSIL) from HSIL mimics.

Design: 96 archived cervical biopsies in which immunostains for p16 and/or MiB-1 were employed to resolve a diagnosis of HSIL vs. reactive epithelial changes were analyzed for ProEx C. Immunostains for ProEx C, p16 and MiB-1 were available for 95, 96 and 59 samples, respectively, and were classified according to distribution (on a graded system of percentage cell involved), intensity (weak or strong), and staining pattern (horizontally continuous vs. discontinuous for p16 and vertical extent in terms of layers involved for MiB-1 and ProEx C). p16 staining of >5% positive cells was scored positive; MiB-1 and ProEx C staining extending beyond the lower third was scored as positive. H-E stained slides were reviewed independently by three pathologists, scored for the presence or absence of SIL and compared across pathologists by Kappa statistic. A diagnosis of SIL or absence of SIL (NoSIL) was based on agreement by at least 2 of 3 pathologists. Chi-square test was used for statistical comparison between biomarker immunostaining and consensus diagnosis of SIL.

Results: Agreement in diagnosis of SIL across pathologists in this selected series ranged from fair to moderate (kappa=0.37 to 0.57). All three biomarkers correlated positively with the consensus diagnosis of SIL (p<0.001). Positive staining for ProEx C, p16 and MiB-1 was observed in 87% (N=52/60), 84% (N=51/61) and 94% (34/36) of SIL and negative in 71% (N=25/35), 63% (N=22/35) and 52% (N=12/23) of diagnoses of NoSIL. The combination of p16/ProEx C predicted more SIL (92%, N=33/36) and NoSIL (61%, N=14/23) than p16 plus MiB-1 (94%, N=34/36 and 43%, N=10/23), but this difference was not statistically significant.

Conclusions: ProEx C appears to have the best combination of sensitivity plus specificity for distinguishing HSIL from its mimics. The combination of p16/ProEx C may be a better discriminant than p16/MiB-1 pending confirmation by a larger case series.

1000 Prevalence of Mucosal and Cutaneous Human Papillomaviruses in Different Histologic Subtypes of Vulvar Carcinoma and Correlation with p16 Overexpression

EC Pirog, M De Koning, W Quint. Weil Med Coll of Cornell University, New York, NY; DDL Diagnostic Laboratory, Voorburg, Netherlands.

Background: Two independent pathways of vulvar carcinogenesis have currently been identified, one - related to infection with mucosal human papillomaviruses (HPVs), and second - related to chronic inflammatory or autoimmune processes. The goal of the study was to examine a possible role of cutaneous HPVs from the beta genus (beta-PV) in vulvar carcinogenesis and to evaluate the distribution of intratypic variants of HPV16 in HPV16-positive vulvar cancer.

Design: Consecutive cases of vulvar carcinoma were retrieved from the files and included the following histologic subtypes: keratinizing (n=21), basaloid (n=7), warty (n=1), mixed basaloid-warty (n=4), verrucous (n=4), keratoacanthoma (n=1), basal cell carcinoma (n=1). All tumors were microdissected and tested for 25 beta-PVs and 25 mucosal HPVs. Cases identified as positive for HPV16 were further tested for intratypic variants. All cases were immunostained for p16.

Results: Beta-PVs were not detected in any of the tumor cases. Mucosal HPVs were detected in all but one basaloid/warty carcinomas; of these, 9 cases (82%) were positive for HPV16, including 5 European subtypes, 1 African subtype, 1 North-American subtype and two indeterminate subtypes. Two of four verrucous carcinomas were positive for HPV6. Mucosal HPVs were not detected in keratinizing carcinomas, keratoacanthoma and basal cell carcinoma. All cases of basaloid/warty carcinomas and none of the remaining tumors overexpressed p16 protein.

Conclusions: Our data do not support a role of beta-PVs in the pathogenesis of vulvar carcinoma. The study reaffirms the role of mucosal HPVs, in particular that of HPV16, in the pathogenesis of basaloid and warty tumor subtypes. The HPV16 intratypic variation showed correlation with patients' ethnic background. P16 immunostaining is a sensitive and specific marker of vulvar carcinomas positive for oncogenic mucosal HPVs.

1001 Histological Findings in the Nonmyoinvasive Component of FIGO Grade I Endometrial Endometrioid Adenocarcinoma (EEA) Associated with Myoinvasion: Analysis of 100 Cases

DA Popiolek, K Mittal. New York University, New York.

Background: The distinction of complex atypical hyperplasia (CAH) from FIGO grade I EEA is difficult in many cases, particularly in EMBx/C. This is reflected in poor diagnostic reproducibility of CAH and significant prevalence of EEA, including myoinvasive EEA, in follow-up hysterectomy specimens, performed after a diagnosis of CAH. The possible explanations include sampling/interpretive error and flawed diagnostic criteria. This study attempted to recognize morphologic features helpful to make this distinction.

Design: We identified 100 cases of myoinvasive (≥2 mm) FIGO grade I EEA in hysterectomy specimens. All cases had nonmyoinvasive component for morphologic evaluations of the following architectural (A), nuclear (N) and stromal (S) features: A: cribriform pattern (cbf≥2.1 mm, <2.1mm), maze pattern (mp, endless glands), papillary pattern (pp, with fibrovascular core), squamous differentiation (sq dif≥2.1 mm, <2.1mm); N: presence of nucleoli; and S: presence of collagen, fibroblasts, endometrial stroma (ES). The presence of single, separate glands and their size: small (sm gl<0.5 mm), median (m gl≥0.5 & ≤1mm), large (l gl > 1mm) were also recorded.

Results: By application of the diagnostic criteria of Kurman et al. to the nonmyoinvasive component of EEA, 78 of 100 cases were classified as adenocarcinoma (cbf≥2.1 mm, sq dif≥2.1 mm, mp, pp, altered stroma), and 22 fell short of this diagnosis (EEA*). When the altered stroma criterion was not applied, the EEA* group increased to 33 cases. In EEA* group, myometrial invasion range from 2 to 15 mm (median 4 mm, mean 4.6 mm), and 4 cases had vascular invasion. The architectural patterns, in the EEA* group (22 cases), were: cbf<2.1/sm gl -8, sm gl -5, sm/m gl -3, cbf<2.1/sm/m gl -3, cbf<2.1/sm/l gl -1, cbf<2.1/m/l gl -1, sm/m/l gl -1. In the EEA* group, 13 cases (59%) had cbf<2.1 mm pattern and all had small glands with very scant stroma. Thus 9 EEA*

cases met criteria for CAH. Also, 7 and 15 cases in this group had ES and very scant stroma, respectively. All 100 cases, except 3 (all in EEA* group), had nucleoli.

Conclusions: These results suggest that the current criteria identified majority of myoinvasive EEA (78%), but 22% of them would be classified as CAH. It appears that lowering the threshold, by inclusion of cbf<2.1 mm pattern and tightly packed small glands, would decrease the number of cases which yield myoinvasive EEA after CAH diagnosis and lessen the impulse to perform upfront hysterectomy and lymph node dissection after the diagnosis of CAH.

1002 Do Locations of Endosalpingiosis and Proliferative Endosalpingiosis Pose a Higher Risk of "Recurrence" after Ovarian Serous Borderline Tumors? A Clinicopathologic Study of 188 Cases

MR Quddus, CJ Sung, MM Steinhoff, C Zhang, R Moore, WD Lawrence. Women & Infants Hospital and The Warren Alpert Medical School of Brown University, Providence, RI.

Background: In a previous study (Abs# 895, 2006) we demonstrated that the presence of endosalpingiosis (ES) and proliferative ES (PES) portends a higher risk for recurrence of serous borderline tumor (RSBT) in patients who had undergone surgical removal of serous borderline ovarian tumors (SBOT). ES is commonly encountered on the surfaces of the pelvic peritoneum, omentum, fallopian tubes, and ovaries. We investigated whether the anatomical site of occurrence of ES and PES and/or its unicentricity or multicentricity pose a higher risk for the development of recurrent SBT.

Design: 188 cases of serous BOT, over the period of 01 January through 30 April 2005, were retrieved. The following parameters were compared in the SBOTs with and without recurrence: 1) unilaterality vs bilaterality 2) surface and/or intracystic SBOT 3) presence of concurrent ES, PES. The anatomical sites of ES and PES (e.g., ipsilateral and/or contralateral ovary, omentum, pelvic lymph nodes) were compared. Also compared was the presence of noninvasive omental implants. Statistical analyses were performed using the Chi-square test.

Results: Table 1 and Table 2.

Table:1

Total no. of primary serous BOT	188	
	With recurrence (N=17)	With no recurrence (N=161)
No Endosalpingiosis	0	56
ES	11 (10%)	95
PES	6 (23%)+	20

++ p<0.05

Table 2

	Bilateral BOT	Ovarian surface	Isilateral ovary	Contralateral ovary	Omentum	Omental noninvasive SBT implants	Pelvic LN
ES with recurrence (N=11)	82%*	82%*	91%*	82%*	45%*	9%*	9%*
ES without recurrence (N=95)	61%*	63%*	87%*	80%*	38%*	11%*	6%*
PES with recurrence (N=6)	100%**	100%**	100%**	100%**	100%**	100%**	33%**
PES without recurrence (N=20)	55%**	65%**	75%**	65%**	80%**	55%**	35%**

*p>0.05, **p<0.05

Conclusions: Our study reveals that the anatomical sites of ES and PES do not pose a statistically significant higher risk for RSBT. In those patients who had PES at the time of the primary resection, there was an increased risk of recurrence (p <0.05) if the patients had bilateral primary BOTs accompanied by noninvasive omental implants. Presence of PES involving multiple sites appears to pose a higher risk of recurrent SBT. The overall proliferative activity of the epithelium of the secondary mullerian system may be the underlying risk factor for recurrent serous BT.

1003 Transitional Cell Metaplasia of the Fallopian Tube Fimbria in Risk Reducing Salpingo-Oophorectomy: A Mimic of Early Tubal Carcinoma That Lacks p53 or MIB-1 Expression

JT Rabban, BB Crawford, CB Powell, L Chen, CJ Zaloudek. UCSF, San Francisco.

Background: Transitional cell metaplasia (TCM) of the serosal surface of the broad ligament and fallopian tube, forming so-called Walthard rests, is a common incidental metaplasia of the peritoneum that resembles benign urothelial mucosa. TCM of the fallopian tube fimbrial mucosa (TCMF) is not well described. TCMF may mimic early tubal carcinoma and pose a diagnostic pitfall in evaluation of risk-reducing salpingo-oophorectomies (RRSO) in women with increased risk for ovarian/tubal carcinoma. This study defines the incidence of TCMF in this population and compares the morphology and p53/MIB-1 status to early tubal carcinoma.

Design: 112 RRSO specimens from women at increased risk for ovarian/tubal carcinoma were evaluated by total embedding for microscopic examination of the entire fimbria, tubes, and ovaries. 68 women were known to be BRCA mutation carriers. BRCA mutation status was not tested in the remainder. 70 women had breast cancer, including 39/68 women with BRCA mutations. 7 cases of TCMF in non-RRSO specimens were also studied. Immunostaining for p53 and MIB-1 was performed in cases with TCMF or early tubal carcinoma.

Results: TCMF was identified in 27/112 (24%) RRSO; 19/27 (70%) TCMF occurred in BRCA carriers. TCMF was often multifocal (18/27). The largest single focus was 4 mm but most foci were less than 1 mm. Though stratification, mild crowding and nuclear hyperchromasia were common, no nuclear atypia or mitoses were present. TCMF did not express p53. Most cases did not express MIB-1 except in rare cells (<1% of cells). The 7 non-RRSO examples of TCMF showed identical features. Walthard rests were present in 69/112 RRSO and none that were tested expressed p53 or MIB-1. Occult

tubal serous carcinoma was found in 5/112 RRSO. Crowding, stratification, nuclear pleomorphism, hyperchromasia, and mitotic activity occurred in all cases. Tumor size was 2 mm or more in 4/5 cases and was 1 mm in one case. p53 was strongly expressed in all cases, as was MIB-1.

Conclusions: Transitional cell metaplasia of the fimbria is a common benign finding in RRSO that can mimic early tubal carcinoma. It occurs most frequently among BRCA mutation carriers. Absence of nuclear atypia, mitoses, and lack of expression of p53 / MIB-1 distinguish TCMF from occult early tubal carcinoma.

1004 Ovarian Carcinoid Tumors of Primary Versus Metastatic Origin: Pitfalls in Diagnostic Use of the Intestinal Marker CDX-2

JT Rabban, MF Lerwill, WG McCluggage, JP Grenert, CJ Zaloudek. UCSF, San Francisco; Massachusetts General Hospital, Boston; Royal Group of Hospitals Trust, Belfast, United Kingdom.

Background: Carcinoid tumors of the ovary are rare neoplasms that may be primary or metastatic. The former are more common than the latter and have a significantly better prognosis. CDX-2 is a marker of intestinal differentiation that has been proposed as a marker of mid-gut origin for metastatic carcinoid tumors. CDX-2 expression has not been tested in ovarian carcinoids. We evaluated the diagnostic role of CDX-2, along with cytokeratins 7 and 20 and TTF-1 in primary and metastatic ovarian carcinoid tumors.

Design: Immunostaining was performed on formalin-fixed, paraffin-embedded tissue from 13 primary ovarian carcinoid tumors (5 insular, 7 trabecular, 1 mucinous type), 9 metastatic ovarian carcinoids of mid-gut origin (8 insular, 1 mucinous type), 10 non-ovarian carcinoids (all trabecular type from foregut or hindgut) and 10 normal premenopausal ovaries. Antibodies included CDX-2 (Biogenix, 1:100), TTF-1 (Signet, 1:8), cytokeratin 7 (DAKO, 1:500) and cytokeratin 20 (DAKO, 1:200). Each carcinoid was required to express synaptophysin or chromogranin to confirm the diagnosis and demonstrate immunoreactivity.

Results: CDX-2 was not expressed in any cells in normal ovaries. Among primary ovarian carcinoids, there was diffuse strong nuclear expression of CDX-2 in 3 of 5 insular, 0 of 7 trabecular, and 1 of 1 mucinous carcinoids. CDX-2 was diffusely and strongly expressed in all 8 metastatic insular carcinoids and in the one metastatic mucinous carcinoid in the ovary. None of the 10 non-ovarian trabecular carcinoid tumors expressed CDX-2. None of the ovarian carcinoids expressed TTF-1, CK7 or CK20, except for the primary and metastatic mucinous carcinoids, both of which were CK20 positive.

Conclusions: CDX-2 is expressed by both primary and metastatic insular and mucinous ovarian carcinoid tumors. Thus, CDX-2 appears to be a marker of intestinal phenotype rather than intestinal origin and it should not be used to determine the site of origin of an ovarian carcinoid tumor. CDX-2 likewise is not useful in evaluation of trabecular carcinoid tumors since neither ovarian nor extraovarian trabecular carcinoids express this marker. A CDX-2 positive potential precursor cell for primary ovarian insular carcinoid tumors was not identified in normal ovaries. TTF-1, CK7 and CK20 are not helpful in distinguishing primary carcinoids from those that are metastatic from the intestine.

1005 A Molecular Genetic Approach Using Array Comparative Genomic Hybridization (aCGH) Analysis in Distinguishing Synchronous Versus Metastatic Carcinoma Arising Concurrently in the Ovary and the Endometrium

H Rai, O Kunle, S Lele, P Mhawech-Fauceglia. Roswell Park Cancer Institute, Buffalo, NY.

Background: Concurrent tumors arising in the ovary and the endometrium can be separate primaries or metastatic. As several morphologic features allowed us to make the diagnosis, it is not always an easy task for the surgical pathologists. The need to make a correct diagnosis is not only an academic exercise but it is also affects patient prognosis, management and counseling. The aim of this study is to evaluate the usefulness of the aCGH technique in solving this dilemma.

Design: 9 cases of concurrent tumors arising in the ovary and the endometrium were evaluated by morphologic criteria. aCGH was performed on paraffin-block from each of the ovarian and endometrial tumors. Hybridization of the tumors with each other was done in all 9 cases and hybridization with a normal DNA human control in 5 cases.

Results: The results are summarized in table 1.

Table 1

	Endometrial Tumor		Ovarian Tumor		Histological Diagnosis	a-CGH	
	Histology	Depth	Side	Histology		Findings	Interpretation
#1	Em	a	Rt	Em	Synchronous	No genetic abnormalities	Inconclusive
#2	Em	a	Lt	Em	Synchronous	No genetic abnormalities	Inconclusive
#3	Em	a	Bil	Ser	Indeterminate favor synchronous	Two separate tumors	Synchronous
#4	Em, Ser	a	Bil	Ser	Indeterminate	No genetic abnormalities	Inconclusive
#5	Em	c	Lt	Ser, Em, Tr	Indeterminate favor synchronous	Two separate tumors	Synchronous
#6	Em	c	Rt	Em	Endometrial→Ovary	No genetic abnormalities	Inconclusive
#7	Em	c	Rt	Em	Endometrial→Ovary	Two different but common origin	Metastatic
#8	Em	c	Bil	Em	Endometrial→Ovary	Two different but common origin	Metastatic
#9	Em	c	Bil	Em, Ser	Indeterminate favor synchronous	Two separate tumors	Synchronous

Em, endometrioid; Ser, serous; Tr, transitional; Depth a, no myometrial invasion; Depth b, <1/2; Depth c, >1/2; Rt, right; Lt, left; Bil, bilateral

Both ovarian and endometrial carcinomas did not show any remarkable genetic abnormalities in 4/9 cases (1,2,4,6). Thus, aCGH was inconclusive in those cases. aCGH was in accordance with the morphologic criteria in 5/9 cases.

Conclusions: 1- In comparison to histology, a-CGH is an effective method in distinguishing primary vs. metastatic tumors of concurrent ovarian and endometrial carcinomas. However, this method has limitation and in a subset of cases such as very early disease, well-differentiated tumors, and endometrioid subtype, aCGH might show no genetic abnormalities and thus inconclusive results.

1006 Statistical Analysis and Diagnostic Value of HPV Detection by PCR-Based Method in Formalin-Fixed, Paraffin-Embedded Tissue

G Rasty, B Bandarchi, F Siadat, A Seth. University of Toronto, Toronto, ON, Canada.

Background: Large number of Human Papilloma Virus (HPV) genotypes has been identified and the strains are divided into high-risk and low-risk types. The high-risk types are more frequently associated with premalignant and malignant lesions of cervix. Infection by high-risk HPV types has been demonstrated in nearly 100% of cervical carcinomas. In this study we attempted to demonstrate the presence of high-risk HPV genotypes in formalin fixed, paraffin-embedded tissue in uterine cervix and other organs by AMPLICOR HPV test (Roche Molecular Diagnostics, CA USA).

Design: 50 cases have been selected from the archives of the Sunnybrook health Sciences Center between 2000-2007. Majority of these cases were selected from cervical lesions. The patients' age ranged between 23- 76 (mean 39.5, SD: 13.689). 15 (30%) cases had the diagnosis of HGSIL, 3 (6%) LGSIL, 7 (14%) AIS, and 15 (30%) cervical carcinomas. 10 (20%) cases were randomly selected from non-neoplastic primary cervical lesions, metastatic tumors to cervix, metastatic carcinomas in lymph nodes, penile squamous cell carcinoma, endometrial carcinomas, vulvar intraepithelial lesion and products of conception. The formalin-fixed, paraffin-embedded sections were analyzed for high-risk HPV by AMPLICOR HPV test method.

Results: Of a total of 50 formalin-fixed, paraffin-embedded tissues, 37 (74%) had positive and 13 (26%) had negative results by AMPLICOR HPV test. 7 (14%) cases were not related to HPV etiology with 43 (86%) associated with HPV oncogenic virus. The sensitivity of the test was 86% (95% CI: 72.7%-93.4%) with the specificity of 100% (95% CI: 64.6%-100%). Total agreement between histological diagnoses and AMPLICOR HPV test was 88% (95% C: 76.2%-94.4%).

Conclusions: Although applied in limited number of cases, the AMPLICOR HPV test is highly specific and relatively sensitive tool and can be used as a complimentary assay to histological diagnosis in HPV related lesions/neoplasia. This may also have a possible role in targeted therapy in future.

1007 Morphoproteomic Evidence of Constitutively Activated and Overexpressed mTOR Pathway in Uterine Leiomyosarcomas vs STUMP, Leiomyoma and Myometrium

ME Rodriguez, ML Stanton, X Duan, JH Connelly, RE Brown. University of Texas Medical School, Houston, TX; St. Luke's Episcopal Hospital, Houston, TX.

Background: Uterine leiomyosarcomas are rare malignancies with poor outcomes. Preclinical studies on human cell lines, a limited study on primary human leiomyosarcoma and xenograft studies in transgenic mice have demonstrated a role for the mammalian target of rapamycin (mTOR) pathway in leiomyosarcomas. We used morphoproteomics to examine the expression of the mTOR pathway in uterine leiomyosarcomas (LMS), uterine smooth muscle tumors of uncertain malignant potential (STUMPs), gestational and nongestational leiomyomas and normal myometrium.

Design: A formalin-fixed, paraffin-embedded tissue microarray containing samples from 9 normal myometria, 12 uterine LMS, 8 STUMPs, 9 gestational leiomyomas and 19 non-gestational leiomyomas was constructed. Immunohistochemistry was used to detect the following antigens: p-mTOR (Ser 2448) and p-p70S6K (Thr 389); cell cycle proteins, Ki-67 and S phase kinase-associated protein (Skp-2); cyclin D1, bcl-2, and VEGF. Protein expression was quantified in regard to proportion (0-100%) and intensity (0-3+). Mitotic index (MI) was assessed as number of mitoses per 10 high power fields.

Results: Nuclear mTOR expression was present in all specimens; however, 2-3+ intensity was seen in 83% LMS and in 43% STUMPs versus 22% in controls and 10% in leiomyomas. Nuclear p-p70S6K 2-3+ intensity was seen in 90% LMS and in 57% STUMPs, versus 22% in gestational leiomyomas, 37% in nongestational leiomyomas and 33% in controls. Skp-2 2-3+ intensity was seen in 92% LMS and in 25% STUMPs versus 4% of all leiomyomas and none in myometria. The leiomyosarcomas demonstrated 2-3+ intensity of VEGF (64%), cyclin D1 (38%) and higher Ki-67 (mean 32%) and MI (20/10 hpf). Leiomyomas and controls have lower VEGF intensity and nearly negative expression of cyclin D1 and Ki-67 with lower mitotic activity. 39% of STUMPs had increased expression of VEGF.

Conclusions: Morphoproteomic analysis reveals constitutively activated and overexpression of the mTOR pathway in uterine leiomyosarcomas evidenced by: increased intensity of p-mTOR and p-p70S6K with nuclear translocation and phosphorylation at putative sites of activation (Ser 2448 and Thr 389, respectively) and correlative overexpressions of VEGF, cyclin D1, Skp-2 and higher mitotic index. This supports a role for the mTOR pathway in tumorigenesis and as a therapeutic target in uterine leiomyosarcomas.

1008 P16 Immunostaining Patterns in Microglandular Hyperplasia of the Cervix and Their Significance

M Roh, EA Agoston, C Birch, CP Crum. Brigham and Women's Hospital, Boston, MA.

Background: P16INK immunostaining is an important adjunct in the differential diagnosis of difficult squamous and glandular intraepithelial lesions of the cervix. However, unexpected staining of epithelium other than the target lesion can pose a problem in the interpretation. This study examined a common entity in the cervix - microglandular hyperplasia (MGH) - that is associated with proliferations of both

columnar and squamous epithelial cells and ascertained the frequency of p16 staining, its pattern, and relationship to HPV.

Design: Cases of MGH were identified from the pathology files and analyzed by p16 immunostaining. Degree and distribution of staining was ascertained in both columnar and squamous epithelium. In selected positive cases, the positive staining areas and appropriate control epithelia from the same biopsy were removed by scalpel and analyzed for HPV nucleic acids by PCR. Additional cases were analyzed for Cyclin E and MIB-1.

Results: Fifty-seven cases of MGH were analyzed; 25 scored strongly immunopositive (44%). In 18, staining of the superficial columnar epithelium was patchy, involving 10-20% of cells on the surface; in 4 cases, 30-40% of cells and in another 3, over 70% of the cells in a given area were strongly positive. Staining involved both nucleus and cytoplasm of columnar cells. Adjacent non-MGH-related columnar epithelium scored negative. Of 20 p16-positive columnar epithelia analyzed, all were HPV negative. p-16 positivity did not co-localize with either cyclin E or MIB-1, including 7 adjacent areas of weakly positive metaplastic epithelium.

Conclusions: The superficial columnar epithelium of MGH, and to a lesser extent squamous metaplasia, can stain strongly for p16 in a level of intensity that can equal or exceed that seen in glandular neoplasia. This staining pattern is confined principally to the superficial columnar cells and will distinguish this epithelium from adjacent non-MGH cervical mucosa. Although HPV-negative p16 positive columnar and squamous epithelia in MGH can be distinguished from intraepithelial neoplasia, practitioners should be wary of these patterns when evaluating problematic epithelial changes in the setting of MGH.

1009 Tumor Presentation in Pelvic Serous Cancer: A Clue to Pathogenesis?

M Roh, D Kindelberger, CP Crum. Brigham and Women's Hospital, Boston, MA.

Background: Pelvic serous cancer is a diverse disease, and the distinction of an ovarian from a tubal primary is controversial. Recent studies indicate that a proportion of tumors arise from the distal fallopian tube. This study analyzed the interrelationship of two parameters that correlate with primary tubal and ovarian malignancies respectively and the degree to which they segregated.

Design: Consecutive cases of pelvic serous cancer diagnosed in the years 2005 and 2006 were selected. The presence of involvement of the fimbrial mucosa (Fim+) – frequently associated with if not diagnostic of a tubal origin - and a dominant ovarian mass (DOM) – commonly seen in primary ovarian malignancies - were correlated.

Results: Eighty one consecutive cases with a diagnosis of pure serous carcinomas were evaluated in which both tubes and ovaries were submitted. Excluding 15 cases in which the tube could not be evaluated due to replacement by tumor, 66 remained for analysis. In fourteen cases in which a DOM (containing the majority of tumor was identified) was present, three (21%) were FIM+. Of 52 cases lacking a DOM, 41 (79%) were FIM+. 57 and 8 percent of cases with and without a DOM involved both ovaries, but virtually all had spread beyond the ovary.

Conclusions: There is a significant inverse correlation between a dominant ovarian mass and involvement of the fimbrial mucosa by pelvic serous carcinoma. This is consistent with existence of at least three mechanisms of serous carcinogenesis, including the interior of the ovary (DOM+/FIM(-)), fallopian tube mucosa (DOM(-)/FIM+) and ovarian or peritoneal surface (DOM(-)/FIM (-)).

1010 Notch1 and Notch3 Overexpression in Young Women with Papillary Serous Ovarian Carcinoma

MH Roh, J Liu, JC Aster, UA Matuloinis, MS Hirsch. Brigham and Women's Hospital, Boston, MA; Dan Farber Cancer Institute, Boston, MA.

Background: In vivo and in vitro studies have demonstrated that Notch3 amplification has an important role in the pathogenesis of papillary serous ovarian carcinoma (PSOC). Notch3 has also been shown to be a target of Notch1 signaling in non-ovarian tumors. In cultured rat kidney epithelial cells containing an estrogen-inducible activated Notch1, cyclinD1 has been implicated as the downstream target, but there are no known associations between Notch3 and cyclinD1. In PSOC, the association of Notch1 with Notch3 and cyclinD1 has not been evaluated in vivo, nor has its association with hormone status/receptors been tested. This study evaluated Notch1, Notch3, cyclinD1, ER and PR protein expression in advanced PSOC in young and older patients, and correlated the findings with clinical outcome.

Design: Notch1, Notch3, cyclinD1, ER, and PR immunostaining was performed on 4 high density tissue microarrays (N=131) with high grade, high stage (III-IV) PSOC. Patients were divided into 2 cohorts based on age: ≥ 65 and ≤ 55 at diagnosis. Clinical data were obtained by chart/database review. Expression was scored as negative/low (0, 1+) or positive (2+, 3+).

Results: Notch1 and Notch3 were significantly overexpressed in the younger cohort ($p < 0.0001$ for both), but not in the older cohort. CyclinD1 expression was not associated with age. Increased cyclinD1 expression correlated in a borderline significant manner with Notch1 overexpression ($p = 0.05$), but not with Notch3 overexpression ($p = 0.088$). There was a strong correlation between Notch1 and Notch3 expression with 75% of Notch1 positive cases also expressing Notch3 (RR 3.46; 95%CI 1.98-6.07, $p < 0.0001$). Younger patients were less likely to express ER and more likely to express PR than older patients ($p = 0.01$ for both), and there was a strong association of Notch1 with PR expression ($p = 0.0009$), but not ER expression. Although multivariate analysis revealed that optimal debulking (HR 0.05, $p = 0.03$) and platinum-sensitivity (HR 0.12, $p < 0.0001$) were independent risk factors for better outcome, there was no association between biomarker expression and overall survival.

Conclusions: This is the first study to demonstrate a direct association of both Notch1 and Notch3 in vivo in PSOC. Although no significant correlation with survival was identified, the strong association between increased expression of Notch1, Notch3 and

PR in younger patients with PSOC suggests that the Notch genes may be regulated by age specific and/or hormonal factors.

1011 Ovarian Serous Borderline Tumors with a Predominant Micropapillary Pattern Are Aggressive Neoplasms with an Increased Risk for Low Grade Serous Carcinoma

AA Roma, A Malpica, MT Deavers, EG Silva. MD Anderson Cancer Center, Houston, TX.

Background: The significance of the micropapillary pattern (MP) in ovarian serous borderline tumors (OSBT) is controversial. Some investigators have considered them to be low grade serous carcinoma, while others have not found a significant difference in survival between OSBT with and without MP. The purpose of this study is to evaluate if the amount of MP in an OSBT has a significant impact on the prognosis.

Design: H&E slides from 56 cases of advanced stage OSBT with MP were retrieved from the files of our department. Cases with any amount of MP were included, and the extent of MP was estimated as a percentage of the tumor. No areas of invasion were identified in the ovarian tumor. All patients (pts) who did not have a recurrence had a minimum follow-up (F/U) of 5 years (yrs). Statistical analysis was performed using Pearson's chi-square.

Results: Pts age ranged from 18 to 79 yrs (mean 38.4 yrs). Tumor size ranged from 3 to 22 cm (mean 8.5 cm). Thirteen pts had stage II and 43 pts had stage III disease. F/U ranged from 0.9 to 36 yrs, (mean 13.8 yrs, median 13.8 yrs). Thirteen pts had more than 50% of MP in the OSBT. Of these pts, 6 (46%) had invasive implants and all 6 (100%) either died of disease (DOD) (2) or were alive with disease (AWD) (4). Mean time from diagnosis to death was 7.4 yrs, mean time to recurrence was 6.0 yrs. The remaining 7 pts (54%) with more than 50% MP had noninvasive implants, and all 7 (100%) either DOD (4) or AWD (3). Mean time from diagnosis to death was 15.9 yrs, mean time to recurrence was 8.2 yrs. In comparison, 44 pts had less than 50% of MP. Eight (19%) of them had invasive implants and 4 (50%) either DOD (3) or AWD (1). Mean time from diagnosis to death was 12.1 yrs, mean time to recurrence was 5.2 yrs. Thirty-five pts (81%) had noninvasive implants and 16 (46%) either DOD (11) or AWD (5). Mean time from diagnosis to death was 15.2 yrs, mean time to recurrence was 8.2 yrs. Based on progression of disease, the OSBT with more than 50% MP were statistically different from the group with less than 50% MP ($p < 0.003$).

Conclusions: 1- Pts with more than 50% MP in the OSBT have an increased percentage of invasive implants. 2- Independent of the type of implant, all the pts in this group had progressive disease (DOD or AWD). 3- Based on this analysis, OSBT with more than 50% MP should be considered aggressive neoplasms with an increased risk for low grade serous carcinoma.

1012 Primary Retroperitoneal Mucinous Tumors: A Clinicopathologic Study of 17 Cases

AA Roma, A Malpica. MD Anderson Cancer Center, Houston, TX.

Background: Primary retroperitoneal mucinous tumors (PRMTs) are uncommon neoplasms occurring in women with a wide age range. Similar to their counterparts arising in the ovary, they are divided in: mucinous cystadenomas (MC), borderline tumors or tumors of low malignant potential (MLMP) and carcinomas (MCa). In this study, we present the clinicopathologic features of 17 such cases.

Design: Seventeen cases of PRMTs were retrieved from our department files. All cases were reviewed by a gynecologic pathologist. Information was obtained from the pathology reports, from the patients' (pts') charts or from the attending physicians.

Results: All 17 pts were female. The pts' age ranged from 20-63 years (yrs) (mean 38 yrs). All tumors were located exclusively in the retroperitoneum (one case involved the kidney and another was attached to the sigmoid serosa). Tumor size ranged from 7-18 cm (mean 12.3 cm). The gross appearance was variable: unilocular thin-walled cyst (4 cases), predominantly cystic with papillary areas or nodule(s) (7 cases), multiloculated cyst with or without nodules (1 case each), predominantly solid with cystic areas (4 cases). In 7 cases the ovaries were removed showing normal histology. In 6 additional cases, the ovaries were normal either by imaging studies or by the surgeon's intraoperative examination. Histologically, the cases were distributed as follows: MC (2 cases), MLMP (7 cases); three of them with intraepithelial carcinoma and one with microinvasion), MCa (8 cases, 4 of them associated with MLMP, and 1 associated with MC). Two of the MCas had areas of anaplastic carcinoma, and two had either a sarcoma or a sarcomatoid area. All pts were treated surgically with resection of the entire tumor. The pts with MCa and sarcoma or sarcomatoid areas received also chemotherapy. Follow-up was available in 15 cases, ranging from 1-148 months (mos) (mean 39 mos, median 20 mos). Two pts died of disease at 5 and 9 mos, respectively, both had MCa with either anaplastic carcinoma or associated sarcoma. One pt with MCa and sarcomatoid areas was alive with disease (AWD) at 26 mos. Another pt with MCa developed metastasis to the liver and is AWD at 14 mos. Eleven pts were alive with no evidence of disease, including 1pt with MC at 34 mos, 7 pts with MLMP at 1 mo, 1 mo, 2 mos, 11 mos, 13 mos, 34 mos and 148 mos; and 3 pts with MCa at 58 mos, 91 mos and 130 mos.

Conclusions: 1- PRMTs are extremely rare tumors. 2- In this study, MLMP and Ca were more common than the MC. 3- They appear to be non-aggressive neoplasms except in cases containing anaplastic carcinoma or sarcoma.

1013 Co-Regulated Levels of PIK3CA, PTEN and AKT mRNA in Ovarian Carcinomas

M Romero-Sanchez, L Catusas, S Hyer, A Gallardo, I Gich, J Prat. Hospital de la Santa Creu i Sant Pau. Autonomous University of Barcelona, Barcelona, Spain.

Background: PIK3CA-PTEN-AKT pathway plays a critical role in tumorigenesis. The relationship between this pathway and chemoresistance, overall survival, or time to disease progression is unclear.

Design: Tissue-microarrays (TMA) from 70 FIGO stage II-IV ovarian carcinomas (51% serous, 12% endometrioid, 13% poorly differentiated, and 24% clear cell carcinomas) treated with CBCDA-Paclitaxel were prepared. TMAs included normal tissue and primary and metastatic tumor. Tumors were stratified into 2 groups according to onset of recurrence after chemotherapy: sensitive > 6 months; and resistant < 6 months. Immunohistochemistry (IHC) for PTEN was done. In 37 of these tumors, LOH analysis for PTEN, mutational analysis for PIK3CA and PTEN and mRNA quantitation for PIK3CA, AKT1, AKT2, and PTEN were done.

Results: Although IHC loss of PTEN was significant ($p < 0.001$) in tumors compared with normal tissues, sensitive and resistant tumors did not differ in PTEN (mRNA and protein) or PIK3CA levels. Correlation between PIK3CA and AKT1 ($p < 0.05$, $r = 0.84$), PIK3CA and PTEN ($p < 0.05$, $r = 0.76$), and PTEN and AKT1 ($p < 0.05$, $r = 0.70$) mRNA levels was detected. In patients with altered PTEN, time to disease progression was higher than in patients without PTEN alterations ($p = 0.06$).

Conclusions: Co-regulation of PIK3CA, PTEN, and AKT1 mRNAs levels suggests qualitative rather than quantitative changes in these proteins. PTEN and PIK3CA alterations are not involved in paclitaxel chemotherapy resistance. Altered PTEN slightly delays the onset of recurrence.

1014 Overexpression of Insulin-Like Growth Factor Receptor 1 (IGF-1R) Is Associated with Poor Outcomes in Epithelial Ovarian Tumors

JS Ross, A Glazyrin, DM Jones, CE Sheehan, JJ Xiong. Albany Medical College, Albany, NY.

Background: Ovarian epithelial neoplasms of similar histology and pathologic stage may have significantly different responses to therapy and overall disease outcome. The IGF-1R gene mapped to 15q26.3 encodes a tyrosine kinase growth factor receptor gene that has been shown to regulate tumor cell growth by autocrine, paracrine and endocrine stimulation via exposure to its activating ligand, insulin. To date, IGF-1R expression in ovarian epithelial tumors has not been correlated to clinicopathologic variables and disease outcome.

Design: Sections from 87 formalin-fixed, paraffin-embedded primary ovarian tumors including benign tumors, tumors of low malignant potential (LMP), and carcinomas were immunostained by an automated method (Ventana Medical Systems Inc., Tucson, AZ) using mouse anti-human IGF-1R antibody (sc-462; Santa Cruz Biotechnology, Santa Cruz, CA). Cytoplasmic immunoreactivity was semiquantitatively scored based on staining intensity and distribution and the results were correlated with morphologic and prognostic variables.

Results: IGF-1R overexpression was noted in 1/11 (9%) cystadenomas, 2/12 (17%) tumors of LMP, and 24/64 (38%) carcinomas. A trend for correlation with regard to benign versus LMP versus carcinoma was noted, but did not reach statistical significance ($p = 0.08$). Cytoplasmic overexpression correlated with tumor grade (13% grade I vs. 21% grade 2 vs. 49% grade 3, $p = 0.039$), tumor stage (5% stage I vs. 57% stage II vs. 41% stage III vs. 100% stage IV, $p = 0.002$), and survival (17% alive vs. 44% deceased, $p = 0.019$). On multivariate analysis, only tumor stage independently predicted disease recurrence.

Conclusions: These results indicate that increased expression of IGF-1R in epithelial ovarian neoplasms is associated with tumor grade, advanced tumor stage and shortened patient survival. Given the widespread current clinical development of therapies targeting IGF-1R, further study of this targeted biomarker in ovarian cancer appears warranted.

1015 Stage I Ovarian Carcinoma: Implications for Screening

M Rouzbahman, H Begley, B Rosen, PA Shaw. University Health Network, Toronto, Canada.

Background: Advanced stage ovarian carcinoma has a low survival rate despite advances in adjuvant chemotherapy, and outcome data suggests survival would increase with improved early detection. To date, proposed screening tests have not demonstrated improved outcomes, and it is possible the excellent outcome of cancers confined to the ovary at diagnosis reflects biological behavior as well as stage at presentation. The aim of this study was to characterize stage I ovarian carcinomas in a series of patients undergoing surgery in a university-based division of gynecologic oncology, and to correlate tumor factors other than stage with clinical outcome.

Design: A total of 570 primary ovarian carcinomas were identified in the Toronto Ovarian Tissue Bank and Database, with 95 (17%) confined to the ovary at surgical debulking. At least one H&E section was reviewed from each case to confirm histological classification and grade using the Silverberg 3-tiered system. Maximum tumor dimension, disease-free interval and overall survival were documented.

Results: Of 95 stage I ovarian carcinomas, 39 were endometrioid (41%), 22 clear cell (23%), 22 mucinous (23%) and 7 serous (7%). Overall, of 570 invasive carcinomas, 80% of endometrioid, 47% of clear cell, 76% of mucinous, and only 2% of serous carcinomas presented at stage I. The mean maximum dimension of stage I serous carcinoma was 13 cm, compared to 8.9 cm, for stage II-IV ($p = 0.022$). Adjuvant treatment was offered to 57% of endometrioid, 77% of clear cell, 50% of mucinous, and 100% of serous carcinomas. Recurrent disease was documented within 5 to 31 months after diagnosis in 10% of endometrioid, 15% of clear cell, 5% of mucinous, and 25% of serous cancers.

Conclusions: Unlike endometrioid, clear cell and mucinous carcinomas, high grade serous carcinoma is infrequently diagnosed while confined to the ovary. Those that are detected at stage I have a significantly greater maximum dimension than serous carcinomas presenting at an advanced stage, facilitating earlier detection. Although the number of cases is small, the data in this study suggests stage I serous carcinoma is associated with an increased risk of recurrence compared to the non-serous types, but have a decreased risk of recurrence compared to advanced stage serous carcinoma.

1016 Lymphatic Microvessel Density as a Prognostic Marker in Endometrial Carcinoma

RS Saad, N Ismiil, Z Ghorab, JF Silverman, S Nofech-Mozes, MA Khalifa. Sunnybrook Health Science Center, Toronto, ON, Canada; Allegheny General Hospital, Pittsburgh, PA.

Background: Carcinoma of the uterus is a highly aggressive tumor with both malignant epithelial and mesenchymal components. Lymph node (LN) metastasis serves as a prognostic indicator for disease progression and as a guide for therapeutic decisions. There is limited data evaluating the significance of lymphatic microvessel density (LMD) as a prognostic marker in uterine carcinoma. In this study, we investigated LMD, using the lymphatic marker: D2-40, as a prognostic marker in uterine carcinoma patients.

Design: Surgical specimens from 45 consecutive patients with uterine carcinoma treated with total abdominal hysterectomy and surgical staging were reviewed. Selected tumor blocks were immunostained for D2-40 and CD31. Positively stained microvessels (MV) were counted in densely vascular/lymphatic foci (hot spots) at x400 field in each specimen ($= 0.17 \text{ mm}^2$) by 2 pathologists. Results were expressed as the highest number of MV count identified within any single field and correlated with other prognostic parameters and survival.

Results: CD31 MV showed significant correlation with tumor stage, depth of myometrial invasion and cervical involvement ($r = 0.44, 0.40, 0.38$; respectively, $P < 0.05$). It also showed significant correlation with disease free and overall patient survivals (log rank $P < 0.05$). D2-40 did not identify any lymphatics in sarcomatous component in our patients. Peritumoral D2-40 LMD in carcinomatous component demonstrated a significant correlation with LN metastases ($r = 0.39, P < 0.01$), presence of angiolymphatic invasion ($r = 0.41, P < 0.01$), but not tumor stage. It also correlated with overall survival. Intratumoral lymphatics were identified in 32/45 (71%) patients and their presence demonstrated significant correlation with shorter disease free survival. D2-40 detected angiolymphatic invasion in 25/45 (56%) cases, more than CD31 (21/45, 47%) and H&E (20/45, 44%). LVI detected with D2-40 showed significant correlation with LN metastases ($r = 0.5$) and shorter overall survival ($P < 0.05$).

Conclusions: Our study showed that both angiogenesis and lymphangiogenesis play an important role in the progression of uterine carcinoma. Carcinomatous component plays the major role in prognosis of uterine carcinoma. Peritumoral D2-40 LMD, in carcinomatous component, is prognostically significant and positively correlates with angiolymphatic invasion, LN metastases and worse survival.

1017 Superiority of a Four-Color FISH Test in Conjunction of p57 Immunohistochemistry for the Assessment of DNA Ploidy and Accurate Classification of Molar Pregnancy

B Sanchez, E Saiz, M Rodriguez, E Gould, N Cartagena, A Renshaw, H Yaziji. Vitro Molecular Laboratories, Miami, FL; Mt. Sinai Medical Center, Miami Beach, FL; University of Miami, Miami, FL; Baptist Hospital of Miami, Miami, FL.

Background: Diagnosis of hydatidiform moles is accomplished by ultrasonography, gross and microscopic examination of involved placental villi, along with serologic testing. However, given the frequent practice of early imaging and urinerie evacuation, most of the diagnostic features are no longer recognizable at early gestational age. Therefore, a diagnostic tool that can reliably diagnose and classify the type of gestational disease would be extremely useful. Theoretically, if chromosome enumeration by fluorescence in situ hybridization (FISH) is reliable and can provide direct visualization of DNA ploidy status, it may have an advantage over flow cytometry because of the ability to localize and limit the analysis to the area of interest.

Design: 42 cases of previously diagnosed molar pregnancies (12 complete moles, 30 partial moles) were re-evaluated, in addition to 40 cases of hydropic aborti as controls. DNA ploidy status by flow cytometry was available on 30 cases. Formalin-fixed, paraffin embedded tissues (one per case) were evaluated for p57 protein by immunohistochemistry (clone 57P06, Lab Vision, Fremont, CA) using a previously validated protocol. FISH testing using a modified protocol of a bladder cancer detection kit (UroVysion, Abbott Molecular, Downers Grove, IL) was performed which includes 3 centromere probes against chromosomes 3, 7 and 17 and a locus-specific probe against 9p24. FISH scoring was limited only to hydropic villi.

Results: All complete moles (100%) showed loss of p57 expression. All hydropic aborti and partial moles showed complete p57 expression. Most partial moles (95%) showed easily identifiable triploid DNA in > 40% of cells per sample. 100% correlation on DNA ploidy status between flow cytometry and FISH was accomplished. Flow cytometry misclassified 3 partial moles, which were detected by FISH. FISH failed to adequately classify ploidy status in 2 cases. All complete moles (100%) showed diploid DNA.

Conclusions: FISH Detection of DNA ploidy is at least as robust in comparison to flow cytometry for accurate classification of gestational trophoblastic disease. However, the real advantage of multi-color FISH over flow cytometry is its better ability to limit the analysis to the foci of interest and exclude non-diseased areas.

1018 P16, Ki67 and BD ProEx™ C (Pxc): A Comparative Analysis for Diagnosis of High Grade Cervical Intraepithelial Neoplasia (CIN)

L Sandweiss, A Wals, S Bose. Cedars Sinai Medical Center, Los Angeles, CA; UCLA School of Public Health, Los Angeles, CA.

Background: Histological assessment constitutes the standard determinant for management of women with CIN. Studies have demonstrated that the detection and grading of CIN are limited by intra- and interobserver variability and poor reproducibility. Biomarkers such as p16, Pxc, Ki67 and cyclin E, have been investigated as adjuncts with potential to refine morphologic diagnosis and improve reproducibility. This study was designed to determine the efficacy of p16, Ki67 and Pxc alone and in combinations for the diagnosis of high grade CIN (CIN II/III).

Design: Immunohistochemical (IHC) staining for p16, Ki67 and Pxc was performed on serial sections of 100 cervical samples (37 negative cases, 24 CIN I, 39 CIN II/III)

with consensus diagnoses. Positive staining for Ki67 and Pxc was defined as nuclear staining in >50% lesional cells and for p16 as diffuse band-like nuclear staining in >90% contiguous lesional cells. IHC stains were reviewed by two pathologists, correlated with HE diagnoses and analyzed to determine the efficacy of the stains.

Results: Each of the three markers correctly diagnosed 90% or more of the high grade CIN (HGCIN). All three markers were concordant and correct in the diagnosis of 76 cases while they were concordant but incorrect in the diagnosis of 3 cases. In 21 cases the markers were discordant. p16 was the most sensitive and specific marker. When the IHC stains were utilized as panels of 2 or 3 (final result = concordant results for both or all 3 of the stains) there was a reduction in sensitivity but an increase in the specificity for detecting HGCIN. When the IHC stains were utilized as cocktails (final result = any positive result) sensitivity increased at the cost of specificity (Table 1).

Table 1: Efficacy of p16, Ki67 and Pxc in the diagnosis of HGCIN

IHC stains	Sensitivity (%)	Specificity (%)	PPV (%)	NPV (%)
Individual stains	90-92	80-89	75-84	93-95
Panels of 2 or 3, all positive	77-85	88-96	83-91	87-90
Cocktails of 2 or 3, any positive	97-100	75-82	72-78	98-100
Panel of all 3 stains, any 2 concordant	97	87	83	98

Conclusions: P16, Ki67 and Pxc are each sensitive and specific markers for HGCIN with p16 being the best. Utilizing a panel of all three IHC stains improves sensitivity with minimal reduction in specificity, when final result equals any two concordant results. The best odds for a correct diagnosis are achieved when p16 and ki67 are both positive.

1019 P16, Ki67 and BD ProEx™ C (Pxc): A Comparative Analysis for Diagnosis of Cervical Intraepithelial Neoplasia (CIN)

L Sandweiss, A Walts, S Bose. Cedars Sinai Medical Center, Los Angeles, CA; UCLA School of Public Health, Los Angeles, CA.

Background: Histological assessment is the standard determinant for management of women with HPV-induced CIN. The histological detection and grading of CIN, especially CIN I, is poorly reproducible and is limited by intra- and interobserver variability. In-situ hybridization for HPV has low sensitivity and specificity while PCR is labor intensive and overly sensitive. This study investigates the role of three biomarkers (p16, Ki67 and Pxc) in the diagnosis of CIN irrespective of grade in tissue sections.

Design: Immunohistochemical (IHC) staining for p16, Ki67 and Pxc was performed on serial sections of 100 cervical tissues (37 negative cases, 24 CIN I, 39 CIN II/III) with consensus diagnoses. Positive IHC staining for each marker was defined as positive nuclear staining in >25% lesional cells. Results were reviewed by two pathologists, correlated with HE diagnoses and analyzed to determine the efficacy of the stains.

Results: The three markers individually diagnosed 78-83% of CIN lesions. All three markers were concordant and correct in the diagnosis of 81 cases while they were concordant but incorrect in 7 cases. 12 cases were discordant. Pxc was the most sensitive but p16 was the most specific marker. There was a reduction in sensitivity but an increase in the specificity for detecting CIN when the stains were utilized as panels of 2 or 3 (final result = concordant results of both or all 3 stains). When used as cocktails (final result = any positive result) sensitivity increased at the cost of specificity (Table 1). The highest sensitivity (89%) was achieved with the p16/Pxc cocktail whereas the highest specificity (95%) was achieved with the p16/Ki67 cocktail.

Table 1. Efficacy of p16, Ki67 and Pxc in the diagnosis of CIN

IHC stains	Sensitivity (%)	Specificity (%)	PPV (%)	NPV (%)
Individual stains	78-83	76-100	85-96	72-74
Panels of 2 or 3, all positive	70-76	100	100	66-71
Cocktails of 2 or 3, any one positive	84-89	70-95	84-96	74-81
Panel of all 3 stains, any 2 concordant	83	100	100	77

Conclusions: P16, Ki67 and Pxc are moderately sensitive and specific markers for CIN and are useful in its histologic diagnosis with Pxc being the most sensitive but least specific. Using a panel of all three stains improves sensitivity and is highly specific. Individual stains or cocktails may be applied to Pap smears for diagnosis of HPV associated lesions with p16/Ki67 providing the best result.

1020 Evaluation of p27 as an Endometrial Biomarker of Response to Progesterin

Z Sangale, K Lu, R Broaddus. M.D. Anderson Cancer Center, Houston, TX.

Background: Progesterin-based therapy, such as combined oral contraceptive (OCP) or depo-provera (DEPO), are commonly used for the treatment of endometrial hyperplasia and grade 1 endometrioid carcinoma, especially in younger women wishing to retain fertility and in women who are poor health risks for surgery. There is little published data examining the comparative efficacy of these agents. Decreased levels of p27, a cyclin dependent kinase inhibitor that regulates cell proliferation, is associated with endometrial hyperplasia and carcinoma. Progesterin-induced up-regulation of p27 has been recently described in rodents, but no data is available in humans. The goal of this study was to determine if progestins increase p27 expression in the human endometrium and to determine if p27 expression could be used as an endometrial biomarker of responsiveness to progestin.

Design: Baseline and 3 month post-treatment endometrial biopsies were obtained from 37 cancer-free, premenopausal women at high risk for endometrial cancer (positive HNPCC mutation). All biopsies were timed at days 14-15 of the menstrual cycle (proliferative phase). Following the baseline biopsy, women were randomized to receive either daily combined OCP LoOvral (ethinyl estradiol/norgestrel) or one i.m. dose of Depo-Provera (medroxyprogesterone acetate). Routine H and E staining and immunohistochemistry were used to evaluate the histologic response to progestin therapy and p27 expression, respectively.

Results: Eighty-six percent (32/37) of the women displayed a histological response to progestin. Four of the histological non-responders were from the DEPO group. Increased epithelial nuclear p27 expression was noted in the post-treatment biopsies of 27/37 (73%) of the patients. 15/17 (88%) of patients taking OCP showed increased p27 expression compared to 12/20 (60%) of those taking DEPO.

Conclusions: Our results do indicate that progestin-based therapy induces p27 expression in the nuclei of epithelial cells. From the perspective of both the H and E based microscopy and p27 immunohistochemistry, OCP is more effective than DEPO. Interestingly, p27 immunohistochemistry detects more non-responders than does routine histology. This may mean that a small percentage of responders by-pass up-regulation of p27 expression, or p27 expression may be predictive of future recurrence of hyperplasia/carcinoma following withdrawal of progestin. Longitudinal studies are necessary to sort out these possibilities.

1021 Genetic Alterations of Uterine Fibroids in Hereditary Leiomyomatosis and Renal Cancer (HLRCC) Syndrome

J Sanz, L Teller, C Vockes, WM Linehan, J Sanz-Esponera, MJ Merino. Hospital Clinico San Carlos, Madrid, Spain; NCI, Bethesda, MD.

Background: Hereditary leiomyomatosis and renal cell cancer (HLRCC) is a hereditary syndrome where individuals are predisposed to the development of skin and uterine leiomyomas as well as aggressive renal cancer. Affected patients harbor a germline heterozygous loss-of-function mutation of fumarate hydratase (FH) gene. Uterine leiomyomas are the most common tumor affecting women in reproductive life. Genetic alterations in sporadic leiomyomas are rare and consist of gains on chromosomes 14 and 19 and losses on chromosomes 1, 4 and 7q.

Design: 16 uterine fibroids from 11 patients with known FH germline mutations were studied. Patients range in age from 24-47 y. DNA was extracted by microdissection and LOH analysis of D1S17, D1S2875, D1S180, AFM214, D1S547, D1S2842 microsatellite markers was performed.

Results: LOH at 1q42 was found in 8 out of 11 patients (72.7%). All cases were informative with at least 3 markers. In 2 cases, different fibroids from the same patient were analyzed. They all displayed an identical LOH pattern. Uterine leiomyomas in our HLRCC series have young age of onset, fibroids are multiple, with size ranging from 1 to 8 cm. Histopathologically, all cases showed tumor nuclei with inclusion-like nucleoli that were orangiophilic, with a perinucleolar halo similar to the changes found in HLRCC renal cancer nuclei. Thus, fibroids frequently had increased cellularity, multinucleated cells and atypia. Although occasionally mitoses were found and three cases were reported as smooth muscle tumours of uncertain malignant potential, they did not fulfill the criteria of malignancy.

Conclusions: Fibroids in HLRCC have characteristic clinical, histopathological and genetic changes. Both, uterine leiomyomas and renal cancer cells share morphological and genotypical features: 1) Frequent LOH at 1q42 (>70%) as the acquired second hit that inactivates the FH gene in HLRCC patients (The first hit is the inherited germline mutation). In patients with multiple leiomyomas, all of them displayed the same LOH pattern. 2) Inclusion-like nucleoli, orangiophilic with a perinucleolar halo. Fibroids also had increased cellularity, multinucleated cells and atypia. The morphological and genetic changes of the uterine fibroids occurring in very young women may assist in identifying patients that may be part of HLRCC families and will require appropriate work up to rule out the presence of kidney cancer.

1022 BRAF, ERK and p16 in Ovarian Serous Tumorigenesis

PW Schlosshauer, D Fatemi, M Pearl, L Deligdisch, F Penault-Llorca, R Qiao, H Shen, J Dong. The Mount Sinai School of Medicine, New York, NY; Weill Medical College of Cornell University, New York, NY; Centre Jean Perrin, Clermont-Ferrand, France; University of Texas Medical Branch, Galveston, TX.

Background: The theory that some ovarian atypical proliferative serous tumors (APST) may progress to micropapillary and low grade invasive carcinomas is supported by the frequent finding of *KRAS* and *BRAF* mutations in these lesions. High grade serous carcinomas show a different molecular genetic profile, including frequent *p53* mutations, and are thought to be a separate entity. We analyzed the frequency of *BRAF* mutations, expression of the downstream signaling molecule and cyclin D inducer Extracellular signal Regulated Kinase (ERK) and the cyclin D inhibitor p16 in various ovarian serous neoplasms.

Design: 24 regular APSTs, 14 micropapillary tumors, 7 low grade and 22 high grade invasive ovarian serous carcinomas were examined. For *BRAF* mutational analysis, DNA was extracted from laser capture microdissected tissue sections, PCR amplified and screened for the T1796A mutation using a restriction fragment length polymorphism (RFLP) assay. Formalin fixed, paraffin embedded tissue sections were stained immunohistochemically for p16, total and phosphorylated ERK. Stains were visually evaluated, assigned an immunoreactive score and statistically analyzed using the analysis of variance and Tukey post-hoc tests.

Results: We found heterozygous RFLP patterns in 11/24 regular APSTs (46%), 3/14 micropapillary tumors (21%), 1/7 low grade carcinomas (14%) and 1/22 (4.5%) high grade carcinomas. There was a decline in p16 expression from atypical proliferative serous tumors to micropapillary tumors ($p=0.001$) and to low grade invasive carcinomas ($p<0.001$). High grade carcinomas had a variable p16 expression pattern. No correlation was found between p16 and phosphorylated ERK expression. The one *BRAF* mutation positive low grade carcinoma had strong total and phosphorylated ERK expression. In the other study groups, no correlation between *BRAF* mutational status and ERK expression was found.

Conclusions: Loss of p16 expression may be a pathogenetic factor in the progression from APSTs to micropapillary tumors and low grade invasive carcinomas. The divergent expression pattern of high-grade carcinomas supports the theory that those are unrelated to APSTs or low-grade carcinomas. In addition to the *KRAS/BRAF* pathway, ERK activation may be regulated by other mechanisms. The role of *BRAF* alterations in ovarian serous tumorigenesis needs further investigation.

1023 Helpful Histologic Features of Serous Carcinoma during Intraoperative Diagnosis of Ovarian Tumors

Z Schreiber, S Liang, M Pearl, E Chalas, C Tornos. Stony Brook University Medical Center, Stony Brook, NY.

Background: In most ovarian tumors, intraoperative frozen section (FS) diagnosis is used to decide further surgical treatment. For patients with a primary ovarian carcinoma, the treatment of choice is hysterectomy (TAH), bilateral salpingo-oophorectomy (BSO), staging and possible tumor debulking. An intraperitoneal catheter may also be placed if chemotherapy is needed. The most common primary ovarian malignancy is serous carcinoma (SC). At the time of FS if the tumor is predominantly solid it may be difficult for the pathologist to render a diagnosis of SC. The aim of the study is to draw attention to histologic features supporting the diagnosis of SC in solid tumors found during FS of ovarian lesions.

Design: FS slides of ovarian serous carcinomas seen in the last two years were reviewed to select cases in which the tumors were predominantly solid and high grade. Fifty six cases met these criteria. The histologic features evaluated include: presence of isolated large nuclei more than two times larger than the average (averaging 15 – 16 microns); multinucleated tumor cells (having more than 2 nuclei, measuring on average 28-30 microns); macronucleoli (measuring at least 3 microns); psammomatous calcifications; and uniformity and size of the nuclei (considered not uniform if there was marked variation in size defined as $\geq 3:1$). These histologic features were evaluated in the FS of the ovarian carcinomas and compared with 31 cases of solid high grade breast carcinomas (5 metastatic to the ovary with available FS, 6 metastatic to sentinel lymph nodes with available FS, and 20 primary breast carcinomas).

Results: Table 1

	ovarian carcinoma	breast carcinoma
isolated large cells	54/56 (96%)	0/31
multinucleated cells	50/56 (89%)	2/31 (6%)
macronucleoli	44/56 (78%)	13/31 (45%)
psammoma bodies	12/56 (21%)	1/31 (3%)
Uniform nuclei	1/56 (1.7%)	23/31 (80%)

Conclusions: The presence of isolated large nuclei, multinucleated tumor cells, and the lack of uniform nuclear size as defined above in the frozen section of a solid ovarian tumor strongly supports the diagnosis of serous carcinoma. Although psammomatous calcifications are known to be a characteristic feature of serous carcinomas, they were only observed in 21% of the high grade tumors in this study.

1024 Serous Cancer Precursors in Fallopian Tube Epithelium of BRCA1/2 Mutation Carriers

PA Shaw, M Rouzbahman, ES Pizer, M Pintilie, H Begley. University Health Network, Toronto, Canada; Cellnetix Pathology, Seattle.

Background: Occult invasive and intraepithelial carcinomas have been identified in the tubal fimbria of BRCA carriers undergoing prophylactic surgery, and recently, p53 positive lesions in tubal fimbria of carriers and non-carriers have been proposed as precursors of high grade serous carcinoma. The aim of this study was to confirm these findings in a larger, independent case set, to further characterize the cancer precursor lesions, and to determine their frequency in BRCA+ and Control groups.

Design: We identified 268 prophylactic salpingo-oophorectomy specimens at our center. For the purposes of this study, we excluded cases without documentation of a germline mutation of BRCA1/2, and without histologic examination of the entire tube. Controls included bilateral tubes from women undergoing surgery for reasons other than ovarian malignancy. Paraffin blocks were retrieved and all sections immunostained for p53 and Ki67. All sections and immunohistochemistry were reviewed without knowledge of BRCA mutation status. Diagnoses were assigned based on combined histology and immunostaining results.

Results: Cases included tubes from 103 BRCA1+, 73 BRCA2+, and 64 Control patients. As shown in Table 1, there was no significant difference in the median age, frequency of abnormalities, p53 signatures, or Tubal Intraepithelial Carcinoma (TIC) between the BRCA+ and Control groups.

Table 1. Summary of Results

	Overall	BRCA1/2	Control
Number	238	176	64
Median Age	47	46	48.5
Abnormal	56 (24%)	40 (23%)	16 (22%)
p53 signature	31 (13%)	19 (11%)	12 (19%)
Pre-TIC	4 (2%)	3 (2%)	1 (2%)
TIC	17 (7%)	15 (8%)	2 (3%)
p53 neg TIC	4 (1%)	4 (2%)	0

Conclusions: This large, blinded review of tubes from BRCA carriers confirms previous reports of cancer precursors in distal and fimbria tubal mucosa, but there is no significant difference in the frequency of histological abnormalities or p53 overexpression between the BRCA and Control groups. TIC, which, like invasive serous cancer, usually but not always overexpresses p53, is more frequent in the BRCA group, but this is not statistically significant.

1025 Comparative Study of Maspin Expression in Type I and Type II Endometrial Carcinoma

D Shi, D Thirabanjasak, S Bandyopadhyay, K Sanjeev, H Arabi, V Schimp, R Morris, A Munkarah, R Ali-Fehmi. Wayne State Univ, Detroit, MI.

Background: Maspin (Ma), a serine protease inhibitor, is considered to have tumor suppressor activity. It has been noted that a nuclear localization of Maspin, opposed to a combined nuclear and cytoplasmic localization, is associated with favorable outcome, low histological grades, and increased overall survival in breast and ovary cancer. The aim of this study is to analyze and compare Ma expression, including its subcellular localization in type I and type II endometrial carcinoma (EMCA).

Design: Using our database, we identified 367 patients diagnosed with EMCA (1995-2002). Patient's information and tumor characteristics were retrieved from patient's charts and SEER database. Two paraffin blocks from each case were immunostained for Ma. Cases were considered positive when stain occurred in > 10% of the tumor cells. The cellular distribution of staining was scored as nuclear (Nu) or cytoplasmic (Cyto); the latter including cases with cytoplasmic or combined nuclear and cytoplasmic stain.

Results: Of 367 patients, 294 were type I and 73 were type II EMCA. We classified low stage as stage I and II, high stage as stage III and IV. The relationship between Ma expression and its subcellular localization with tumor stage and vascular invasion is shown in Table 1. In type II EMCA, cytoplasmic (not nuclear) Maspin is correlated with high stage ($p < 0.003$) and vascular invasion ($p < 0.03$). In type I EMCA, Maspin expression did not significantly correlate with stage or vascular invasion.

		Maspin	Type I	Type II *
Vascular Invasion	Absent	Nu	71/104 (68%)	6/7 (86%)
		Cyto	87/113 (77%)	6/29 (21%)
(type I n=294, type II n=66**)	Present	Neg	55/77 (71%)	14/30 (47%)
		Nu	33/104 (32%)	1/7 (14%)
		Cyto	26/113 (23%)	23/29 (79%)
		Neg	22/77 (29%)	16/30 (53%)
Stage	Low	Nu	79/99 (80%)	7/8 (88%)
		Cyto	96/113 (85%)	15/35 (43%)
(type I n=280***, type II n=73)	High	Neg	59/68 (87%)	19/30 (63%)
		Nu	20/99 (20%)	1/8 (12%)
		Cyto	17/113 (15%)	20/35 (57%)
		Neg	9/68 (13%)	11/30 (37%)

* significant p value in all parameters. ** 7 cases not survived stain process. *** 14 cases not survived stain process

Conclusions: The shifting of Maspin expression from nuclear to nucleocytoplasmic is significantly correlated with higher stage and vascular invasion in type II but not in type I EMCA. This finding supports the hypothesis that Maspin cellular expression has different biologic significance in different types of EMCA.

1026 Regulation of HMGA2 Expression by let-7 microRNAs in Uterine Leiomyosarcoma

GZ Shi, K Mittal, P Yi, J Laser, P Lee, E Hernando, JJ Wei. New York University, New York, NY.

Background: Overexpression of HMGA2 is common in benign uterine leiomyoma. Let-7, a key negative regulator of HMGA2, is lost in most large leiomyomas and disruption of the let-7:HMGA2 pairs plays a major role in leiomyoma growth. Overexpression of HMGA2 has been reported in uterine leiomyosarcomas (ULMS). The functional relationship between the let-7:HMGA2 pairs and tumorigenesis of ULMS is as yet to be undetermined.

Design: A total of 29 ULMS and 3 uterine leiomyosarcoma cell lines (SK-LMS-1, SK-UT-1 and SK-UT-1b) were used for the study. The expression of HMGA2 and let-7 was analyzed by RT-PCR, in situ hybridization, Western blot, and immunohistochemistry (IHC). Regulation of HMGA2 by let-7 was analyzed by transfection of exogenous let-7c and a let-7 inhibitor. The pro-mitogenic role of HMGA2 in ULMS cell lines was analyzed by disruption of the let-7:HMGA2 pairs *in vitro*.

Results: Among 29 ULMS, 5 (17%) tumors showed diffuse immunoreactivity for HMGA2. Expression of let-7c was examined by in situ hybridization. Let-7c was upregulated in 57% of tumors, downregulated in 17% and showed no change in 22%, compared to normal myometrium. Among 5 HMGA2 positive ULMS, 3 cases had downregulated and 2 had minimal let-7 expression. The levels of let-7c negatively correlated with HMGA2 expression ($r = -0.36$). HMGA2 mRNA expression was examined by RT-PCR in 5 randomly selected ULMS and 3 ULMS cell lines. All ULMS and cell lines had moderate to high levels of HMGA2 mRNA and low levels of let-7c, d, f expression. Western blot analysis of same group of ULMS and cell lines revealed either no detectable or very low levels of HMGA2 protein. By transfection of a let-7 inhibitor in ULMS cell lines, a 5-12 fold increase of HMGA2 protein was observed. Moreover, disruption of the let-7:HMGA2 pairs by let-7 inhibitor in ULMS cell lines significantly increased cell proliferation rate.

Conclusions: HMGA2 may be constitutively expressed in ULMS at transcriptional levels. Presence of low levels of endogenous let-7 in most ULMS can efficiently repress HMGA2 translation but may not completely destabilize HMGA2 mRNA. Overexpression of HMGA2 either by loss of let-7 in tumors or by transfection of a let-7 inhibitor promotes tumor growth in ULMS.

1027 The Non-Epithelial Lined Spaces Pattern of Invasion and the Disorganized Individual Papillae, Non-Invasive Component, of Low Grade Serous Carcinoma

EG Silva, MT Deavers, A Malpica. The University of Texas MD Anderson Cancer Center, Houston, TX.

Background: Low grade serous carcinoma (LGSCa) is a relatively recently recognized entity; however, the patterns of invasion of this Ca and whether it can be diagnosed in the absence of an invasive component have not been determined yet.

Design: We studied the patterns of invasion and the noninvasive areas of 65 cases of ovarian LGSCa and compared them to 60 ovarian serous borderline tumors.

Results: The most common pattern of invasion is the presence of tumor cells within non-epithelial lined spaces (NELS) which are clefts created by fixation. The predominant patterns within the NELS were: groups or nests (nidi pattern) in 100% of the cases, micropapillae 69%, macropapillae 25%, large solid groups 6%, psammomas 3%, and single cells 2%. A significantly less common pattern of invasion, without NELS, is small irregular glands with a haphazard distribution and a stromal reaction. Disorganized individual papillae (DIP) within a space lined by epithelial cells is a noninvasive pattern of LGSCa and it was present in 40% of the cases. Groups of tumor cells within NELS, glandular pattern of invasion, and DIP, were absent in borderline tumors. In LGSCa, calcifications were present in all cases, and mucin in 39 cases.

Conclusions: 1. The nidi pattern of cells within NELS is the most common pattern of invasion of LGSCa. 2. Micropapillae and macropapillae can also be found in NELS but less frequently than the nidi pattern. 3. A glandular pattern of invasion is rare and is the only one without NELS. 4. DIP within cysts are noninvasive and diagnostic of low grade serous ca.

1028 Differential Expression of ProExC as a Diagnostic Tool in Evaluating Cervical Squamous Metaplasia and High Grade Dysplasia

RA Simon, JN Warner, PA Bourne, TA Bonfiglio. University of Rochester Medical Center, Rochester, NY.

Background: Overexpression of minichromosome maintenance protein 2 (MCM2) and topoisomerase II- α (TOP2A) in cervical cells indicates aberrant S-phase induction due to high-risk HPV infection. The ProExC immunostain (TriPath Imaging), a cocktail of MCM2 and TOP2A, has been evaluated in liquid based cervical cytology smears and cervical tissue biopsies as a potentially diagnostic marker for high grade cervical dysplasia (HGD). Cervical squamous metaplasia can mimic HGD, creating a diagnostic dilemma. The purpose of the present study is to evaluate staining patterns of ProExC in immature squamous metaplasia, atypical squamous metaplasia, and HGD to determine whether ProExC is a useful marker in differentiating these processes, which have very different clinical implications.

Design: A total of 32 cervical biopsies were evaluated, including 11 immature metaplasias (IM), 11 atypical metaplasias (AM), and 10 HGDs. Each case was stained with ProExC, Ki67 (Dako), and p16 (Biocare). Nuclear staining was considered positive for all stains. ProExC staining was noted in basal and parabasal cells in negative control cases. The p16 stain was performed as a positive control, as it is known to stain most cases of HGD. Patterns of expression were recorded.

Results: In both IM and AM, ProExC expression was interpreted as negative in 92% of cases (10/11, each). In contrast, in HGD, diffuse expression of ProExC was detected in the basal and middle thirds of the epithelium in 70% (7/10) of cases and full thickness staining was seen in the remaining 3 cases. Staining with p16 was negative in the majority of IM (82%, 9/11) and AM (73%, 8/11), with basal or focal full thickness staining in the remaining cases. In all HGDs (100%, 10/10), there was diffuse p16 nuclear expression from two thirds to full epithelial thickness. Ki67 expression in all metaplasias was either negative (64%, 14/22) or seen in scattered epithelial cells (36%, 8/22). In all HGDs (100%, 10/10), Ki67 was expressed in scattered cells in up to two thirds of the epithelial thickness.

Conclusions: ProExC is a useful diagnostic tool in differentiating IM or AM from HGD in cervical biopsies, when used alone or in conjunction with p16. ProExC and p16 staining results are similarly positive in HGD. However, ProExC shows fewer false positive results in IM and AM than p16. Ki67 does not appear useful in differentiating between metaplasias and HGD.

1029 Undifferentiated Uterine Sarcomas: A Diagnosis of Exclusion with Apparent Prognostic Significance

RA Soslow, K Garg, M Guile, MM Leitao, Jr. MSKCC, New York, NY.

Background: Undifferentiated sarcomas of the uterus (UUSs) are diagnosed in the presence of a uterine mesenchymal neoplasm without light microscopic features of smooth muscle or stromal differentiation and without evidence of sarcomatous overgrowth in an adenocarcinoma. We reviewed our institutional experience with these uterine sarcomas.

Design: We reviewed our surgical pathology database from 1996 to 2007 to identify 33 cases diagnosed as UUSs. Of the 33 cases, immunohistochemical analysis (IHC) was performed in 23 cases (70%) and electron microscopy was performed in one case. 6 cases showed weak and focal (less than 5% of tumor cells) staining for desmin while 1 case showed focal staining for actin. 3 of 9 cases showed focal keratin staining. The medical records for these patients were reviewed for relevant clinical attributes. The data was compared to a historical control group of uterine leiomyosarcomas (ULs) from our institution (previously published data).

Results: The UUSs were observed to present with advanced stage disease more frequently and showed higher rates of recurrence or progression compared to ULs. They also showed a much higher rate of lymph node metastasis (LNM) and ovarian metastases (OM) even in the early stage cases. The median progression free survival (PFS) (overall 8.4 months) was low irrespective of stage (early stage PFS 10.7 versus advanced stage PFS 7.8).

Clinical features of USSs

AGE (yrs)	59 (31-80)
STAGE	I-II:7 (21.3%), III-IV: 21 (63.3%), unstaged: 5 (15.2%)
GROSS EXTRAUTERINE DISEASE	Present in 15 (45.5%), absent in 17 (51.6%), N/A in 1 (3%)
RECURRENCE/PROGRESSION	21/28 (75%)
MEDIAN FOLLOW UP (mths)	10.9 (2.3-100.1)

Rate of LNM and OM in UUSs and ULs

	UUSs	ULs
OVERALL	LNM 8/19 (42%)	LNM 3/37 (8.1%)
	OM 7/30 (23%)	OM 4/108 (3.9%)
NO GROSS EXTRAUTERINE DISEASE	LNM 3/11 (27%)	LNM 0/37 (0%)
	OM 2/16 (12.5%)	OM 2/71 (2.8%)
GROS EXTRAUTERINE DISEASE	LNM 5/8 (63%)	LNM 3/37 (8.1%)
	OM 5/14 (36%)	OM 2/37 (5.4%)

Conclusions: Tumors diagnosed as UUSs appear to be even more aggressive than ULs. These patients' tumors are more frequently advanced stage at presentation with higher rates of progression and recurrence and show higher rates of LNM and OM in a stage for stage comparison with leiomyosarcomas. The PFS was dismal even in early stage cases. Hence the criteria separating UUSs from other poorly differentiated uterine neoplasms should be better characterized because of their apparent potential for adverse clinical outcome.

1030 Uterine Tumors Resembling Ovarian Sex Cord Tumors (UTROSCT) Lack the JAZF1-JJAZ1 Gene Fusion Commonly Seen in Endometrial Stromal Tumors

PN Staats, G Kuhlmann, JJ Garcia, WG McCluggage, M De Nicolis, RA Soslow, AJ Iafrate, E Oliva. Massachusetts General Hospital, Boston, MA; Memorial Sloan Kettering Cancer Center, New York, NY; Royal Group of Hospitals Trust, Belfast, Northern Ireland, United Kingdom; Universita' Degli Studi Di Ancona, Ancona, Italy.

Background: UTROSCT is a rare tumor initially described by Clement and Scully, which the WHO defines as a neoplasm closely resembling a true ovarian sex cord tumor. Tumors with sex cord-like elements which have clear cut areas of endometrial stromal tumor (EST) are excluded, and are referred to as EST with sex cord-like elements. That UTROSCT is related to EST has often been assumed but is unproven. Several investigators have recently demonstrated a recurrent translocation in ESTs between two novel genes, the JAZF1 gene on chromosome 7p15 and the JJAZ1 gene on chromosome 17q12. This translocation is seen in more than 50% of ESTs, and in up to 80% of them in one study. Of the reported cases, four had sex cord-like elements, and the JAZF1-JJAZ1 gene fusion was found in two of them. To our knowledge, no cases of UTROSCTs have been probed for this gene fusion.

Design: We looked for the JAZF1-JJAZ1 gene fusion in 24 UTROSCTs by dual-color dual-fusion fluorescent in-situ hybridization (FISH). One EST previously demonstrated to harbor the t(7;17) was used as a positive control.

Results: Hybridization with the FISH probes was effective in 14 of 24 cases and the control case. None of the 14 cases showed evidence of the JAZF1-JJAZ1 gene fusion. The control case showed the expected gene fusion.

Conclusions: UTROSCTs appear to lack the JAZF1-JJAZ1 gene fusion seen in at least 50% of typical EST and half of the reported EST with sex cord-like elements. These findings suggest that UTROSCT may represent a genetically distinct tumor, not directly related to EST. Our results challenge the often assumed concept that UTROSCTs represent overgrowth of sex cord-like elements in an EST. Whether a distinct translocation, involving either of these genes with an alternative fusion partner, is present in some of these tumors remains unresolved.

1031 Morphoproteomic Evidence of an Activated and Overexpressed mTOR Pathway in Endometrial Carcinoma

ML Stanton, ME Rodriguez, RE Brown, X Duan. The University of Texas Medical School at Houston, Houston, TX.

Background: Morphoproteomics assesses the activation of signal transduction pathways by utilizing probes against putative activation sites on protein analytes, cellular compartmentalization and correlative expression of upstream initiators and downstream effectors. Loss of PTEN, a moderator of the PI3-K/Akt/mTOR pathway, is well known in endometrial cancer, and activation of the mammalian target of rapamycin (mTOR) has also been reported in endometrial cancer. We investigated the activation of the mTOR pathway and its downstream effectors in endometrial carcinoma (Eca), proliferative- (PE) and secretory-phase (SE) endometrium to provide further evidence for the use of an mTOR inhibitor, rapamycin or one of its analogs, in Eca.

Design: A formalin-fixed, paraffin-embedded tissue microarray containing 41 samples of Eca, 29 PE and 25 SE was created. Immunohistochemistry was utilized to detect the following antigens: p-mTOR (Ser 2448) and p-p70S6K (Thr 389); VEGF; and cell cycle associated proteins, cyclin D1, Ki-67 and S-phase kinase-associated protein (Skp-2). Protein compartmentalization and expression were quantified in regard to proportion (0-100%) and intensity (0-3+).

Results: Plasmalemmal and cytoplasmic expression of VEGF was observed in PE (0-2+, 83%) and SE (0-2+, 81%) and was increased in proportion and intensity in Eca (2-3+, 55%). Cytoplasmic p-mTOR expression was present in PE (2-3+, 79%) with comparable expression in SE (2-3+, 46%) and Eca (2-3+, 45%). However, the proportion of nuclear p-mTOR expression was 100% in Eca (1-3+) with absence of staining in the majority of PE and SE. Nuclear p-p70S6K expression was similar to that of cytoplasmic p-mTOR. Ki-67 was very low in SE and higher in a few PE, however it was increased in most Eca (73% of cases >20%). Moreover, Ki-67 was >40% in 43% of Eca cases with a positive correlation with nuclear expression of mTOR.

Conclusions: Morphoproteomics reveals activation and overexpression of the mTOR pathway in Eca as evidenced by increased nuclear translocation of p-mTOR; with p-mTOR and p-p70S6K, phosphorylated at putative activation sites, Ser 2448 and Thr 389, respectively; correlative overexpression of a downstream effector of mTOR signaling, VEGF, and an increase in nuclear Skp-2 expression and Ki-67 labeling index consistent with mTOR signaling in G1-to-S phase progression. This suggests that the mTOR pathway plays a key role in endometrial carcinogenesis and supports the incorporation of mTOR inhibitors into therapy for Eca.

1032 Histopathologic Features and Clinical Outcomes of Uterine Leiomyomas in Pregnancy

ML Stanton, MT Deavers, A Malpica, X Duan. The University of Texas Medical School at Houston, Houston, TX; MD Anderson Cancer Center, Houston, TX.

Background: The diagnosis of leiomyomas is relatively straightforward in most cases; however, it is often complicated by the presence of secondary changes, such as hemorrhage, necrosis and degeneration. Such changes are more prominent under hormonal treatment and during pregnancy. In this study, we examined the histological features, clinical behavior and cell cycle and proliferation-related immunomarkers in leiomyomas removed during pregnancy or delivery.

Design: A database search of the pathology records at Hermann and Lyndon B. Johnson Hospitals from 2000-2006 identified 33 leiomyomas removed during pregnancy or delivery. Surgical pathology reports and slides were reviewed, and the presence of hemorrhage, necrosis, atypia, mitosis and circumscription were recorded. A retrospective review of the electronic medical record was performed to obtain clinical information

and follow-up. Immunohistochemical stains for Ki-67 and S-phase kinase-associated protein (Skp-2) were performed in cases with extensive necrosis and degenerative changes using conventional leiomyomas as controls.

Results: Degenerative and atypical changes were identified in 29 cases (88%) and included extensive necrosis (hyaline and infarct-type) in 15 cases (45%), hemorrhage in 9 cases (27%) focal mild to moderate cellular atypia in 5 cases (15%) and necrosis with atypia in 4 cases (12%). All cases had very low (0-2/10hpf) or no mitotic activity. Ki-67 labeling index and Skp-2 expression were performed on 9 cases with extensive degenerative changes and showed negligible expression for both markers, which was similar to conventional leiomyomas. Of the 15 patients whose tumors had extensive necrosis, clinical follow-up information was available for 10 patients, all of whom had no evidence of recurrence or metastatic disease at a median of 8 months (range 4-44 months).

Conclusions: Morphologic features of leiomyomas excised during pregnancy include extensive hyaline and infarct-type necrosis, hemorrhage and focal mild to moderate cellular atypia, all to a lesser degree than defined by malignant criteria. None of the patients in our study with follow-up information had any evidence of residual disease or recurrence. Similar expression of selected molecular markers supports the notion that degenerative changes in gestational leiomyomas are not indicative of malignancy.

1033 The Accuracy of Colposcopic Biopsy: A Report from the Gardasil Clinical Trials Pathology Panel

M Stoler, A Ferenczy, B Ronnett, R Kurman, E Franco, K-L Liaw, A Saah, R Radha, E Barr. University of Virginia Health System, Charlottesville, VA; McGill University, Montreal, QC, Canada; Johns Hopkins Medical Institutions, Baltimore, MD; Merck Research Laboratories, Blue Bell, PA.

Background: For patients with abnormal Pap smears, colposcopic biopsy is considered the gold standard for guiding therapy, yet recent large-scale trials (like ALTS) have called the accuracy of colposcopic biopsy into question. The poor correlation between biopsy and final pathology on LEEP specimens has been blamed on the effect of biopsy removing the pathology or inducing regression. The algorithms used to manage cervical HPV disease within the Phase III efficacy studies of GARDASIL™ (quadrivalent HPV [Types 6, 11, 16, 18] L1 VLP vaccine) afforded a unique opportunity to examine the accuracy of colposcopic biopsy.

Design: The trials enrolled 17,599 16- to 26-year-old subjects. At the time of definitive therapy, each colposcopist was to obtain a biopsy just prior to LEEP as the best estimate of the worst prevalent pathology. All biopsies were given histopathologic diagnoses by an expert panel. Among subjects undergoing LEEP in these studies, 319 had biopsy and LEEP specimens obtained at the same visit. Consensus Pathology Panel diagnoses of the biopsy and LEEP for each pair were compared.

Results: The overall agreement was 54.5%, with an overall kappa of 0.36 (95% C.I. 0.29-0.43). The biopsy underestimated the final pathology in 41% of cases and overestimated or removed the worst pathology in 4.4%. There were 82 cases of CIN3, and the biopsy was NEG, CIN1 or CIN2 in 33%, 15%, and 18%, respectively. Thus, 48% of the time, patients with CIN3 had biopsies that were less than CIN2, and 66% of the time, CIN3 was not present on the biopsy that preceded it on LEEP. Conversely, if the biopsy was called NEG, CIN1, CIN2 or CIN3, the pathology on LEEP was really CIN3 in 15%, 15%, 48% and 80% of cases, respectively.

Conclusions: (1) Even with specialized training and experience, colposcopic biopsy frequently misses the most significant pathology, including 66% of CIN3 cases. The data demonstrate the negligible effect of pre-LEEP biopsy for removing pre-existent disease. (2) Experimental protocols using colposcopy with or without single "target" biopsy for diagnostic gold standards are likely to suffer from pitfalls in disease ascertainment. (3) These data should be taken into account in planning therapy especially for patients in whom the biopsy is less severe than the referral cytology.

1034 Secretory Leukocyte Protease Inhibitor: Immunohistochemical Evidence Supporting a Fallopian Tube Origin for Serous Papillary Carcinoma

J Sun, F Chen, WD Mojica. University at Buffalo, The State University of New York, Buffalo, NY.

Background: The cell of origin for serous papillary carcinoma (SPC) of the pelvis remains controversial, with the leading candidates being the epithelial cells from either the surface of the ovary or the fimbriated end of the fallopian tube (FT). One approach in resolving this uncertainty is through immunohistochemistry. Identification of the expression of a protein integral to a cell's function and its retained expression during tumor differentiation is one venue that could help clarify tumor origin. The aim of this study was to further investigate the cell of origin for SPC by comparing the expression of Secretory Leukocyte Protease Inhibitor (SLPI), a protein previously reported to be involved in the immunodefense of FT epithelial cells, among FT epithelium, ovarian surface epithelium (OSE) and SPC.

Design: Nine cases of formalin fixed, paraffin embedded tissue blocks containing the fimbriated end of the FT, sections of ovarian tissue with intact OSE, and nine separate cases of SPC were selected from the archival files from the Department of Pathology. Slides were prepared using standard antigen retrieval techniques and immunohistochemistry performed using a monoclonal antibody to SLPI (Santa Cruz Biotechnology, CA) at a dilution of 1:100, and detected using an avidin-biotin detection kit.

Results: SLPI expression was observed in all (n=9) cases of the FT epithelium as cytoplasmic staining with no predilection to either ciliated or non-ciliated cells. SLPI expression was observed in all (n=9) cases of SPC, predominantly in areas retaining a papillary architecture but generally lost in areas of solid tumor growth. No SLPI expression was noted in any (n=9) cells of the OSE.

Conclusions: Expression profiling is a common approach utilized to help delineate cell lineage. The presence of SLPI in FT epithelium, its absence in OSE, and its expression in SPC further supports the contention that the FT epithelium may be the cell of origin for SPC.

1035 Mib-1(Ki67), p53, Estrogen Receptor, Progesterone Receptor Expression in Atypical Cells in Uterine Bizarre (Symplastic) Leiomyomas

X Sun, K Mittal. New York University Medical Center, New York, NY.

Background: Despite the fact that there are only a limited number of reported cases and even fewer studies with long-term clinical follow-up, symplastic or bizarre uterine leiomyomas are considered a morphologic variant of leiomyomas with good prognosis. The bizarre cells are generally thought to be degenerative. In this study we examined these cells for expression of Ki-67, p53, ER and PR to further evaluate if these cells are actively proliferating or degenerative.

Design: Nine cases of Uterine symplastic leiomyoma were identified from the files of New York University Medical Center. An immunohistochemical study of the expressions of Ki-67, p53, ER and PR was performed using monoclonal antibodies for MIB-1 (Immunotech, Cedex, France), p53 (Ventana, Tucson, AZ), estrogen receptor (ER; Ventana), progesterone receptor (PR; Ventana), and the avidin-biotin-peroxidase method. Two cell populations were identified in each case, those having bizarre features and the others with bland nuclear features. The percentages of the positively stained bizarre cells and the bland cells were subjectively assessed to the nearest 5% with 1% used for rare positive cells. The data was analyzed statistically using the student *t*-test.

Results: The bizarre cells had a significantly greater number of cells expressing Ki-67 compared to the adjacent bland cells (Mean \pm SE: 17 \pm 20% versus 3 \pm 3.9%, *p* < 0.05). Both the bizarre and bland cells had identical ER and PR staining profiles. In two cases, there was loss of ER staining which affected both the atypical and non-atypical cells. PR staining was preserved in all cases. P53 expression was 0 to 5% in bland areas and 0 to 10% overall in bizarre areas with focal expression in up to 50% of the bizarre cells in one case. These differences were not statistically significant.

Conclusions: Rather than being degenerative in nature, the bizarre cells in uterine bizarre (symplastic) leiomyomas are cells in active proliferation.

1036 Microsatellite Instability Status and Clinicopathologic Profile of Endometrial Cancer (EC) in Young Women (\leq 50 Years)

G Toledo, WB Growdon, D Dias-Santagata, A Ganguly, M Aubá, AJ Iafrate, E Oliva. Massachusetts General Hospital, Boston, MA; University Hospital, Pamplona, Spain.

Background: Microsatellite instability (MSI) results from failure of the DNA mismatch repair (MMR) system to correct errors during DNA replication. MSI is seen in both Lynch's syndrome-associated and sporadic ECs, with a higher frequency in young women. Data concerning correlation between MSI status, PTEN expression, histopathologic features and clinical outcome in young women with sporadic ECs are limited and/or controversial.

Design: Archival material from 74 patients with endometrioid EC (EEC) aged \leq 50 yrs and 39 matching patients $>$ 50 yrs were identified from 1993 to 2001. Clinicopathologic data included race, morphologic features [type(s) of differentiation, histologic grade, tumor infiltrating lymphocytes (TIL), lymphovascular invasion, necrosis and hyperplasia], stage, therapy and follow-up. Immunohistochemical analysis was performed for hMLH1, hMSH2, hMSH6, PMS2 (loss in all tumor cells) and PTEN (loss in $>$ 10% of tumor cells). Cases with loss of at least one MMR protein were tested for MSI. MLH1 methylation status was determined in high-MSI EECs.

Results: Lack of at least 1 MMR protein was seen in 33 EECs (29%); 18 (16%) showed high-MSI with 8 (7%) displaying MLH1 methylation. Significantly, 8/10 (80%) unmethylated EECs occurred in women \leq 50 yrs, 4 with concomitant MSH2 and MSH6 loss and personal/family history of cancer. Lack of PTEN was seen in 20 cases, correlating strongly with H-MSI status (*p* < 0.0001) and age $>$ 50 (*p* = 0.033). No specific clinicopathologic or molecular features differentiated EECs in women of \leq 50 and $>$ 50 years. There was no correlation between MSI or MLH1 methylation status and clinicopathologic parameters. Specifically, TIL and mucinous differentiation were not related with MSI (*p* > 0.05). Follow-up, available in 102 patients, ranged from 11 to 183 (mean 95) months. Only 8 patients had recurrences and 3 died of disease. MSI, MLH1 methylation and PTEN status were not associated with overall or disease-free survival.

Conclusions: Our data support the absence of correlation between MSI status, histopathologic features and clinical outcome in young women and confirms the association between loss of PTEN and MSI in EECs. The high number of MLH1 unmethylated EECs in young women suggests that these patients may potentially be considered at risk for Lynch's syndrome. In contrast to data reported in hereditary colon cancer, the morphologic features in these EECs are not distinctive.

1037 Utility of the Mitosis Marker Anti-Phosphohistone H3 (PHH3) in Precise and Rapid Evaluation of Mitotic Index in Leiomyomas with Bizarre Nuclei

G Toledo, WB Growdon, MLD Palmeri, BR Rueda, E Oliva. Massachusetts General Hospital, Boston, MA.

Background: Mitotic index (MI) is one of the most helpful morphologic features in the differential diagnosis between leiomyoma with bizarre nuclei (LMB) and leiomyosarcoma. However, bizarre nuclei and apoptotic cells may often mimic mitoses -including atypical forms- by H&E examination and MI in LMBs may vary substantially among pathologists. Ki67 has been used as an ancillary tool to assess proliferation in these tumors. PHH3 is an antibody that specifically detects histone H3 only when phosphorylated at serine10, a parallel event with mitotic chromatin condensation not observed in apoptosis. The aim of our study was to determine the utility of PHH3 in assessment of MI and compare it to Ki67 labeling index in LMBs.

Design: Eighteen slides from 13 LMBs were tested with PHH3 and Ki67. Immunostaining was evaluated in 100 high power fields (HPFs) chosen from the most cellular areas. The definition of mitotic figure in the PHH3 staining was adopted according to known established criteria used for H&E and excluded positively stained interphase nuclei with no obvious prophase chromosomal condensation. The Ki67 staining was evaluated by determining the number of positive tumor cell nuclei.

Results: The distribution of the bizarre nuclei was diffuse in 10 LMBs and focal in 3. Overall, Ki67 immunostaining ranged from 2-200 positive nuclei/10HPFs (mean 52.5) with a high rate of positive cells in interphase. PHH3 showed 0-6 mitoses/10 HPFs (mean 1.3) and the stained nuclei conserved the morphologic characteristics of mitoses. Only two true atypical mitoses were discovered with PHH3 staining.

Case	Bizarre nuclei distribution	Ki-67/10HPFs (mean)	PHH3/10HPFs (mean)
1	Diffuse	70.3	0.1
2	Focal	2.1	0
3	Diffuse	5.2	0
4	Diffuse	21.4	2
5	Diffuse	32.2	0.8
6	Diffuse	52.6	1.5
7	Focal	20.8	0.2
8	Diffuse	193.2	3
9	Diffuse	183.4	2.1
10	Diffuse	72.2	2.5
11	Diffuse	145.7	2.2
12	Focal	37.5	0.1
13	Diffuse	20.4	0.1

Conclusions: PHH3 labeling is useful to highlight true mitoses and aids in their differentiation from bizarre nuclei and apoptotic cells in LMB. PHH3 appears to be a much better marker for MI assessment than Ki67 in these tumors. Application of this marker in daily practice results in a more reliable and objective estimation of MI compared to H&E and Ki67 labeling. Furthermore, the overall time needed to establish an accurate mitotic count can be substantially reduced with PHH3.

1038 Expression of Potential Biomarkers MCM5 and CDC6 in Coexisting In-Situ and Invasive Squamous Cell Carcinomas of the Uterine Cervix

MM Tovar, ML Cibull, CP DeSimone, RG Karabaktstian. University of Kentucky, Lexington, KY.

Background: Cervical cancer is directly related to human papillomavirus (HPV) infection, and P16 oncoprotein has been used as a marker for high-grade dysplasia and invasive squamous cell carcinoma (ISCC). Other potential biomarkers, such as MCM5 (human minichromosome maintenance protein-5) and CDC6 (cell division cycle-6 protein) are known to play an essential role in the activation/control of DNA replication, and may be involved in pathogenesis of cervical neoplasia. The aim of this study is to compare the coexpression of MCM5 and CDC6 with oncoproteins p16 and p53 in cases with coexisting preinvasive cervical lesions (PCLs) and ISCCs, and to evaluate their diagnostic usefulness as potential and predictive biomarkers of invasiveness in PCLs.

Design: Twenty-four nonkeratinizing ISCCs with coexisting carcinoma in-situ (CIS) from 24 patients were studied by whole tissue section immunohistochemistry (IHC). A representative block showing coexisting CIS and ISCC was selected for each case. Tissue sections were stained with a panel of IHC stains, using monoclonal antibodies to p53 (Dako, CA), p16 (Neomarkers, CA), MCM5 (Novocastra Laboratories, UK), and CDC6 (Santa Cruz Biotechnology, Inc.). Immunostained slides have been scored independently by two pathologists. Immunostaining for p53 and p16 was scored positive, if more than 50% of the tumor cell nuclei stained with strong intensity, and negative otherwise. Immunoreactivity for MCM5 and CDC6 was scored positive with patchy/moderate or diffuse/strong nuclear staining, and negative otherwise.

Results: All 24 cases show P16 expression in both CIS and ISCC components. Staining for P53, MCM5 and CDC6 showed synchronous pattern in both components in 75%, 46%, and 13%, respectively (see table).

Coexpression of p16, p53, MCM5 and CDC6 in Coexisting CIS and ISCCs of the Cervix

IHC	P16	P53	MCM5	CDC6
CIS (n=24)	24/24 (100%)	20/24 (83%)	16/24 (67%)	8/24 (33%)
ISCC (n=24)	24/24 (100%)	21/24 (87%)	17/24 (71%)	5/24 (21%)
Synchronous Staining in CIS & ISCC	24/24 (100%)	18/24 (75%)	11/24 (46%)	3/24 (13%)

Conclusions: 1) P16 expression shows the highest sensitivity in both CIS and ISCCs of the uterine cervix, and is superior to other potential biomarkers. 2) P53 and MCM5 may be candidate molecular markers for identifying PCLs that are destined to progress to invasive carcinoma. 3) On the other hand, CDC6 expression in our study, contrary to few other reports, does not appear to be of a diagnostic or prognostic value.

1039 Is Retrograde Menstruation the Source of Endometriosis?

OE Vele, MM Shevchuk, M daSilva. Lenox Hill Hospital, New York City, NY; Genzyme, Los Angeles, CA.

Background: Retrograde menstruation is one of the leading theories for the etiology of endometriosis, a benign proliferation with features of neoplasia.

Design: We examined 25 cases of endometriosis and/or endometrioma for the expression of the components of the DNA mismatch repair pathway (encoded by hmlh-1, hmsh-2, hmsh-6, and pms) as well for B-catenin, because these are often associated with low grade endometrial neoplasia. Controls consisted of 20 endometrioma from cases of total hysterectomy with oophorectomy, removed incidentally or for benign disease, in which there was no evidence of endometriosis/endometrioma. Staining of 0 or +1 (loss of expression of any of the above gene products) was considered "abnormal", while +2 or +3 (intact expression for all 4 of these enzymes) were "normal".

Results: 68% of case endometria showed some abnormality, but surprisingly 90% of control endometria were "abnormal". Most abnormalities in both groups were in the expression of hmlh-1 gene (56% of cases and 70% of controls). Also basalis had more abnormalities than the overlying functionalis. In 16% of cases and 10% of controls, the basalis was "abnormal" and the functionalis "normal". Foci of endometriosis showed abnormal gene expression in 37.5% of cases, and endometrioma in 21% of cases. The concordance in staining between endometriosis and eutopic corresponding endometrium was 62.5% and between endometrioma and the endometrium was 43%.

Conclusions: The mismatch and B-catenin genes do not share the same expression profile in endometriosis and endometrioma with the matching native endometria, and therefore this study does not provide positive evidence for retrograde menstruation. However, the unusually high rate of abnormality in "control" endometria, and the greater "abnormalities" seen in the progenitor cells of basalis suggest that endometrial cell expression of mismatch genes and B-catenin may be affected by post-transcriptional, epigenetic factors. Thus although this study does not show evidence for retrograde menstruation as a source of endometriosis, it does not disprove it.

1040 Ovarian Clear Cell Carcinoma May Arise from Two Different Precursors with Different Clinico-Pathologic Features

E Veras, TL Mao, A Ayhan, IM Shih, R Kurman. Johns Hopkins Hospital, Baltimore, MD; National Taiwan University Hospital, Taiwan; Seirei Mikatahara General Hospital, Hamamatsu, Japan.

Background: Ovarian clear cell carcinomas (CCC) often present as stage I tumors yet are conventionally considered high-grade tumors with aggressive behavior. They exhibit a variety of gross and microscopic patterns and have an association with endometriosis. The aim of this study was to compare CCCs subdivided by microscopic patterns to identify any distinctive clinicopathological features which could assist in understanding their pathogenesis and behavior.

Design: Clinicopathologic features of 116 CCCs retrieved from the surgical pathology files of National Taiwan University Hospital (74), The Johns Hopkins Hospital (25), and Seirei Mikatahara General Hospital (17) [1985-2006] were analyzed. Tumors were divided into 3 groups: those associated with a cyst (CCC-Cy), those associated with an adenofibromatous pattern (CCC-AF) and those lacking these patterns (CCC-NOS).

Results:

	CCC-Cy	CCC-AF	CCC-NOS
Frequency (n=116)	35% (41)	19% (22)	46% (53)
Age (mean)	49	54	48
% Bilateral (n=108)	8% (3/39)	11% (2/18)	10% (5/51)
Size (cm) (mean)	12.2	12.6	13.3
Stage I (n=70)	78% (29/37)*	41% (9/22)*	64% (32/50)
Advanced stage (II-IV) (n=39)	22% (8/37)*	59% (13/22)*	36% (18/50)
Association with endometriosis (n=54)	71% (29/41)*	32% (7/22)*	34% (18/53)*
Association with IEC (n=34)	54% (22/41)*	9% (2/22)*	19% (10/53)
No evidence of disease (2-169 mo) (n=65)	63% (26/41)	45% (10/22)	55% (29/53)
Alive with disease (1-128 mo) (n=16)	7% (3/41)	23% (5/22)	15% (8/53)
Dead of disease (1-94 mo) (n=35)	29% (12/41)	39% (7/22)	30% (16/53)

IEC= intraepithelial carcinoma; *p <= 0.004

Conclusions: Distinctive patterns of ovarian CCC suggest this tumor may arise via at least two pathways, one from underlying adenofibroma and a second from a cyst. The significantly more frequent finding of endometriosis and intraepithelial carcinoma in cyst-associated tumors suggests these lesions are precursors in a progression model for this subtype. The finding that cyst-associated tumors were significantly more frequently stage I than adenofibromatous tumors yet survival for these two types was not significantly different warrants further investigation.

1041 Adenocarcinoma of the Lower Uterine Segment: A Unique Subset of Endometrial Carcinoma

S Westin, R Broaddus. M.D. Anderson Cancer Center, Houston, TX.

Background: Adenocarcinomas of the lower uterine segment (LUS) present diagnostic dilemmas pathologically, and clinically they can pose difficult treatment issues. Our understanding of these tumors is limited to a few small published reports. The purpose of this study was to better characterize this class of endometrial carcinomas.

Design: We reviewed the pathology reports for 3,490 patients from 1996-2006 with a diagnosis of either endometrial or endocervical adenocarcinoma, 1020 of which had their hysterectomy performed at our institution. Subjects were included in the LUS group only if the tumor was clearly originating from the area between the lower corpus and upper endocervix upon gross pathologic examination of the hysterectomy specimen. Tumors of the corpus or cervix that secondarily extended to the LUS were excluded. Pathologic evaluations were performed by gynecologic pathologists at our institution. We performed IHC for p16, vimentin, ER, and pCEA, a panel previously shown to be useful in the differential diagnosis of adenocarcinomas of endometrial vs. endocervical origin. In situ hybridization for HPV high risk types was also performed. The control group was all women who underwent hysterectomy for endometrial cancer at our institution in a 12 month period. Pearson chi-square test and the student T-test were utilized for statistical analysis.

Results: Of the 1,020 women who had hysterectomy at our institution, 34 (3.3%) had adenocarcinomas that were clearly arising in the LUS. The median age of the LUS patients was 50.5 years. Seventy-four per cent of the tumors were endometrioid. Compared to controls, the LUS patients were significantly younger (p=.004), had lower stage tumors (p=.030), less myometrial invasion (p=.005), and less lymphatic/vascular invasion (p=.007). Clinically, differential diagnosis of the LUS tumors more frequently included the possibility of endocervical adenocarcinoma (p<.0001), leading to preoperative radiation therapy in 5 patients. All of the LUS tumors expressed vimentin, ER, and pCEA, similar to endometrial carcinoma arising in the corpus. All of the LUS tumors were negative for HPV, and p16 expression was variable. Surprisingly, 4/34 (12%) of the LUS patients had HNPCC mutations.

Conclusions: Adenocarcinoma of the LUS has unique clinical and pathological characteristics compared to conventional endometrial carcinoma, although immunohistochemically they are quite similar. Based on our results, young women with LUS tumors should be tested for HNPCC mutations.

1042 Biomarker Clustering Segregates Endometrial Carcinoma into Two Distinct Groups

S Westin, K Lu, D Loose, R Broaddus. M.D. Anderson Cancer Center, Houston, TX; UT-Houston Medical School, Houston, TX.

Background: The use of molecular biomarkers to guide therapy is the standard of care for patients with certain types of leukemia and is being vigorously tested in women with ER positive, lymph node negative breast cancer. Innovative molecular diagnostics have not been incorporated into the care of women with endometrial cancer. Traditional pathological and clinical evaluation of these patients does not allow for optimal management of intermediate risk disease, nor does it accurately predict the subset of patients who would benefit from full surgical staging to detect microscopic disease. Using microarray analysis, we have identified a set of endometrial genes that are highly induced by estrogen. We hypothesized that high expression of such estrogen-regulated genes would be associated with lower grade, better prognosis tumors and would therefore be prognostically useful.

Design: Using qRT-PCR, we quantified the expression of six estrogen-induced genes (IGF-1, IGF-IR, EIG121, sFRP4, sFRP1, and RALDH2) in a set of endometrial carcinomas for which we had staging information and at least 2 year clinical follow-up (n=72; 58 endometrioid and 14 non-endometrioid). Medians were calculated for each gene, and expression was compared to clinical and pathological characteristics.

Results: Gene expression in the grade 1 endometrioid tumors was significantly greater than that for the non-endometrioid tumors, thus validating our approach. An unsupervised cluster analysis yielded two distinct groups with an agglomerative coefficient of 0.79. Nearly all of the non-endometrioid tumors (11/14) segregated to cluster 1, the low expression group. Twelve of the patients had tumor recurrence by 2 years post-hysterectomy. Ten of these patients had tumors that segregated to cluster 1, including 2 patients with grade 1 endometrioid tumors. Grade 2 endometrioid tumors were split equally between the two clusters. Grade 2 endometrioid tumors are common (62% of all endometrioid tumors at our hospital), and these tumors frequently present dilemmas regarding post-surgical adjuvant treatment decisions.

Conclusions: Clustering endometrial cancer patients based on tumor expression of estrogen-regulated genes partitions these patients into two distinct groups. Such analyses may serve as a useful molecular adjuncts to standard clinical and pathological assessments in treatment decisions regarding endometrial cancer patients.

1043 p16^{INK4a} Immunostaining of LSIL Cervical Biopsies Yields Significantly Increased Positive Predictive Value Compared to HPV Testing and ProEx C

GR Wettach, A Schreiner, N Gordon, G Countryman, TK Morgan. Oregon Health & Science University, Portland, OR.

Background: The positive predictive value (PPV) of a low grade dysplasia (LSIL) diagnosis in a cervical biopsy for progression to high grade dysplasia (HSIL) is approximately 20%. Most cases of LSIL are also positive for transient high risk HPV infection; therefore, the PPV of HPV testing is negligible (reported as 20% for LSIL) and is not recommended. In contrast, p16 (CINtec®) and ProEx C (TriPath Imaging®) immunostaining have been associated with HSIL and may provide improved PPV for neoplastic transformation in LSIL biopsies. Our objective was to compare the PPV of LSIL diagnoses to HPV testing, p16 positivity, and ProEx C.

Design: Retrospective review of the OHSU pathology database (1996-2007) revealed 96 cervical biopsies diagnosed as LSIL after LSIL pap, or ASCUS pap with high risk HPV. Seventy-one cases had at least 3 years of negative follow-up (mean 4.6 years ± 1.4) and 25 had biopsy proven progression to HSIL (2.8 years ± 1.2). All biopsies were reviewed by three pathologists, and diagnoses confirmed by at least 2 pathologists were included in subsequent analyses (n=52/96). HPV results were obtained when available (n=20/52). Sections were immunostained in duplicate for both p16 and ProEx C and scored by 3 independent pathologists as either positive or negative for diffuse strong basal staining.

Results: LSIL diagnoses showed agreement between at least 2 pathologists in 54% of cases (52/96), similar to prior reports. Scoring reproducibility between pathologists was high for p16 (pairwise kappa statistic 0.88; P<0.0001), but only moderate for ProEx C (kappa 0.48). The only statistically significant association between scoring and progression to HSIL was observed with p16 staining (X² 5.4; p-value = 0.02).

Test	PPV	NPV	Sensitivity	Specificity	Likelihood Ratio
LSIL Diagnosis	22%	-	100%	-	1.0
Reproducible LSIL	35%	84%	72%	52%	1.5
HPV Test	42%	75%	71%	46%	1.3
ProExC	48%	72%	72%	48%	1.4
p16	70%	71%	41%	89%	3.7

Conclusions: Positive p16 staining yielded significantly improved predictive value for progression to HSIL within 3 years when compared to histologic diagnosis, ProEx C, and HPV testing. Given the limitations of colposcopic examination (e.g. sensitivity of 66% and occasional curative excision of the lesion by biopsy), our results may represent the upper limit of this methodology. Whether positive p16 staining in this context justifies closer clinical follow-up remains to be seen.

1044 Vulvar Squamous Cell Carcinoma: Should We Be More Selective in Determining Suitable Candidates for Inguinal Lymph Node Evaluation?

AM Winkler, S Logani. Emory University Hospital, Atlanta.

Background: Current recommendations for surgical treatment of vulvar squamous cell carcinoma (SCC) include wide local excision (WLE) and inguinal lymph node dissection (LND). The decision to perform LND is determined by the tumor size (>2cm) and depth of invasion (>1mm); however, the positive predictive value of these criteria appears to be low. This study was designed to evaluate additional pathologic features that may facilitate prediction of lymph node status and therefore help guide management.

Design: The study group comprised patients who underwent surgical staging for SCC of the vulva at our institution from 1985-2007. All histologic slides were reviewed and pathologic data including tumor size, pattern of growth (endophytic, exophytic or flat), surface ulceration (present or absent), depth of invasion, pattern of invasion (1:small nests from base of VIN, 2:large confluent nests with smooth outlines, 3:large confluent nests with irregular outlines, 4:irregular cords and nests of tumor cells in desmoplastic stroma) and the number of positive lymph node(s) were recorded. Lymph node status was correlated with the above histologic parameters using the Pearson Chi-square test. P value of ≤0.05 was considered statistically significant.

Results: 36 patients (mean age 64 yr) fit the study criteria. Lymph node metastasis (mean examined=13) were seen in 36% of cases. 12 of 13 patients with positive lymph nodes had invasion >1mm (mean 8.05 mm) but 20 cases (62%) with depth of invasion >1mm had negative lymph nodes (mean 5.8 mm, p≤0.19). None of the cases with negative lymph nodes showed surface ulceration, a feature observed in 11 patients with lymph node involvement (p≤0.005). Invasion patterns 3 and 4, as defined earlier, were significantly more likely to show lymph node involvement when compared to tumors with patterns 1 and 2 (p≤0.01). Tumor size was not a significant predictor of lymph node status in this study (p≤0.53).

Conclusions: Our study supports the current recommendation of WLE without LND for tumor invasion <1mm. A significant percentage of patients with depth of invasion >1mm or tumor size >2cm have negative lymph node status suggesting additional pathologic or clinical parameters need to be assessed to determine the need for LND. The presence of surface ulceration and certain patterns of invasion may be helpful in predicting lymph node status. Our study provides data to support focusing efforts on techniques such as sentinel lymph node biopsy to offer the best risk:benefit for determining the need for LND for each patient.

1045 Overexpression of REG Gamma in Uterine Leiomyosarcoma

J Xiao, X Li, PK Johnston, M Stanton, M Rodriguez, R Brown, X Duan. The University of Texas Houston Medical School, Houston, TX; Baylor College of Medicine, Houston, TX.

Background: REG gamma is the activator of 20 S proteasomes and is considered as an antiapoptotic factor. Recent studies also demonstrated overexpression of this protein in poorly differentiated thyroid papillary carcinoma and colorectal cancer. The expression of REG gamma in gynecologic tumor has not been investigated. In this study, we evaluated the expression of REG gamma in uterine leiomyosarcoma, normal uterine smooth muscle, pregnant uterine smooth muscle, conventional leiomyoma and smooth muscle tumor of uncertain malignant potential (STUMPs).

Design: Pathology database from two teaching hospitals were retrospectively reviewed. 12 uterine leiomyosarcoma, 9 STUMPs, 12 myometrium, 10 gestational leiomyoma, 19 conventional leiomyoma were identified and tissue microarray blocks were derived from these specimens. The expressions of REG gamma and p53 in tissue microarrays were examined and semiquantified in regard to proportion (0-100%) and intensity (0-3+). Mitotic index was also evaluated.

Results: The REG gamma immunostains were predominately distributed in nucleus. Overexpression of REG gamma was observed in all leiomyosarcoma (2-3+, 100%), while its expression is lower in STUMPs (1-2+, 71%), 77% and 80% in gestational leiomyoma and conventional leiomyomas respectively. Expression of REG gamma in normal uterine smooth muscle was negative or very weak (0-1+, 39%). Overexpression of p53 was seen in 7/12 leiomyosarcoma (2-3+, 100%) and there is also a positive correlation between overexpression of p53 and high mitotic index.

Conclusions: REG gamma is overexpressed in uterine leiomyosarcoma compared to normal uterine smooth muscle, gestational uterine smooth muscle, conventional leiomyoma and STUMPs. The results suggest that the REG gamma may play an important role in carcinogenesis of uterine leiomyosarcoma. The overexpression of p53 and its positive correlation with high mitotic index support the statement that p53 and mitotic index may serve as markers of more aggressive tumor.

1046 Epithelioid Trophoblastic Tumor: Comparative Genomic Hybridization and Parental Genotyping Studies

ML Xu, Y Bin, ML Carcangiu, P Hui. Yale-New Haven Hospital, New Haven, CT; Cleveland Clinic, Cleveland, OH; Istituto Nazionale Tumori, Milan, Italy.

Background: Arising from the putative "chorionic-type" intermediate trophoblast, epithelioid trophoblastic tumor is a recent addition to the spectrum of gestational trophoblastic diseases. Frequently, the tumor involves the uterine cervix and is misdiagnosed as invasive squamous cell carcinoma. The pathogenesis of the tumor is poorly understood, and its molecular analysis is essentially lacking. This study was designed to explore chromosomal alterations in epithelioid trophoblastic tumor and to use DNA genotyping to demonstrate its trophoblastic origin, therefore separating the tumor from its mimics of the maternal origin.

Design: Five cases of epithelioid trophoblastic tumors were included in this study and paired DNA samples from the tumor and normal tissue were extracted from paraffin embedded archival materials. The status of chromosomal alterations was analyzed by comparative genomic hybridization using conventional metaphase chromosome

preparations. The parental genetic contribution was determined by DNA genotyping analysis using AmpFISTR® Identifier™ Amplification system (Applied Biosystems, Inc.).

Results: Comparative genomic hybridization analysis was successful in three cases, all of which showed a balanced chromosomal profile without detectable gain or loss of the genome. DNA genotyping was informative in four cases with anatomic locations involving cervix (2 cases), endomyometrium (1 case) and metastatic tumor to lung (1 case). All four cases were found to have unique paternal alleles, confirming the trophoblastic nature of the tumors.

Conclusions: Chromosomal alterations detectable by conventional comparative genomic hybridization are not features of epithelioid trophoblastic tumors. A demonstration of the paternal alleles by DNA genotyping is a powerful diagnostic application in separating an epithelioid trophoblastic tumor from its maternal mimics, particularly squamous cell carcinoma, a far more common malignancy of the uterine cervix.

1047 HER-2/neu Receptor Gene Amplification and Protein Expression in Endometrial Serous Cancer: A Comprehensive Tissue Microarray Study

ML Xu, P Schwartz, P Hui. Yale-New Haven Hospital, New Haven, CT.

Background: Endometrial serous carcinoma, a major histological subtype of uterine cancers, has a dismal survival rate regardless of aggressive clinical therapies. Recent studies have suggested that a significant percentage of the tumors expressed high levels of HER-2/neu protein and that such an overexpression may be responsible for its aggressiveness and high resistance to chemotherapy. Moreover, Herceptin treatment has been reported successful in anecdotally. We investigated this issue by analyzing a large number of cases using tissue microarray platform.

Design: The study included 75 cases of uterine pure serous carcinoma and 199 cases of endometrioid carcinoma consecutively accessioned at our institution, along with 65 non-malignant control endometrial samples. A standard tissue microarray was constructed. Immunohistochemistry and FISH were used to explore HER-2/neu protein expression and its gene copy status, respectively. These were scored according to standard criteria.

Results: HER-2/neu over-expression ($\geq 2+$) by immunohistochemistry was seen in 13.3% (10/75) of serous and 1% (2/199) of endometrioid cancers. FISH study showed that 10.7% (8/75) of serous carcinomas had HER-2/neu gene amplification, including high copy number increase (4 cases) and low copy number increase (4 cases). Three serous carcinomas showed positive immunohistochemistry in the absence of gene amplification. A high concordance between protein over-expression and gene amplification was seen in cases (4/4) with high copy number increase. Nine of 12 serous carcinomas which showed gene amplification had Stage III or Stage IV disease. Only one (1/199) of the endometrioid cancers showed low copy number amplification. Nonmalignant control endometrial samples did not show either protein expression or gene amplification.

Conclusions: Overall, 10.7% of endometrial serous carcinomas demonstrated HER-2/neu gene amplification, and an additional 4% showed protein over-expression in the absence of gene amplification in our study. HER2/neu gene amplification and/or protein over-expression are very rare in endometrioid carcinomas. In contrast to breast cancers, mechanisms other than gene amplification may be responsible for the high levels of protein expression in some endometrial serous cancers. Further prospective studies are needed to ascertain whether serous tumors with elevated HER2/neu status are susceptible to Herceptin treatment.

1048 Thinner CIN2-3 Associates with Low Sensitivity of Colposcopic-Directed Biopsy

B Yang, RG Pretorius, X Zhang, R Burchette, YL Qiao, JL Belinson. Cleveland Clinic, Cleveland, OH; Southern California Permanente Medical Group-Fontana, Fontana, CA; Chinese Academy of Medical Sciences, Beijing, China.

Background: Colposcopic-directed biopsy of CIN2-3 lesions has the poor reproducibility and limited accuracy. Recent ALTS study shows only 53% of CIN2+ had a positive colposcopic impression/biopsy. The underlying mechanism of low sensitivity of colposcopic-guided biopsy is largely unknown and is difficult to be investigated in hospital-based setting. During the population-based cervical cancer screening in China, we found about 37% of CIN2+ lesions were diagnosed by random quadrant biopsy without colposcopic abnormality. To determine whether false negative colposcopic impressions are affected by histopathologic features, we studied the epithelial thickness and cell density of CIN lesions and correlation with colposcopic impression.

Design: Total 271 cases were randomly selected from 7,687 cervical quadrant biopsies obtained from 1,924 women. Pathologic diagnoses were reviewed and the thickness and cell density of squamous epithelium were measured without knowledge of colposcopic impression. Average epithelial thickness (AET, microns) was defined as the thinnest area plus the thickest area divided by two. Average cell density (ACD) was defined as the number of nuclei in a 2,500 μ^2 grid at the junction of the superficial and intermediate zones plus that at the junction of the intermediate and parabasal zones divided by two.

Results: ACD is gradually increased from histopathologic Normal (7.81) to CIN-1 (8.26), CIN-2 (13.28) and CIN-3 (14.31). However, ACD for CIN 2-3 with colposcopic impression of normal (14.9) is similar to CIN 2-3 with impression of Low or High (13.4, $p=0.15$). In contrast, there is significant difference ($p<0.001$) of AET among colposcopically normal (184), CIN-1 (251), CIN-2 (353) and CIN-3 (407), although AET is similar among histopathologically normal, CIN-1, CIN-2 and CIN-3 (408, 367, 264 and 326 μ respectively). The sensitivity for colposcopy-directed biopsy in detection of CIN2-3 lesions is 88.6% when AET is above 290, but only 31.3% when AET is under 140. The majority of colposcopically under diagnosed CIN2-3 lesions are those thinner lesions with AET between 181 and 230.

Conclusions: False negative colposcopic impressions are associated with thinner CIN2-3 epithelium while false positive colposcopic impressions are associated with thicker Normal or CIN 1 epithelium. Nuclear density has no significant impact on colposcopic impression.

1049 Ovarian Cancer Associated T Cell Coinhibitory B7-H3 and B7x

X Zang, RA Soslow, R Waitz, VE Reuter, A Wilton, HT Thaler, M Arul, SF Slovin, J Wei, J Dupont, JP Allison. Ludwig Center of Cancer Immunotherapy, New York; Memorial Sloan-Kettering Cancer Center, New York.

Background: The B7 family, which includes B7-H3 and B7x, provides critical costimulatory and coinhibitory signals that regulate T cell-mediated immunity. Cell mediated immunity has been shown to be prognostically important in ovarian carcinoma.

Design: Ovarian carcinomas and borderline tumors of various types in tissue microarrays were studied using immunohistochemistry (IHC) with anti-B7-H3 and B7x antibodies. Serum from ovarian cancer patients and controls were studied for the presence of B7x using ELISA methodology. Human ovarian carcinoma cell lines were studied by flow cytometry for B7-H3 and B7x expression. Cytotoxic T lymphocyte mediated cytotoxicity was studied in C57BL/6 mice using a cell line engineered by retrovirus transduction to express B7x (B7x/RMA). Clinical follow-up information was abstracted from medical records.

Results: IHC analysis of 103 ovarian cancers showed that tumor cell expression of B7-H3 and B7x was 93.2% and 100%, respectively, with cell membrane and cytoplasmic localization. Only scattered B7-H3 and B7x expression was detected in non-neoplastic ovaries. B7-H3 was also expressed in tumor-associated vasculature in 44.1% of tumors. 78.1% of late stage tumors exhibited B7-H3 positive tumor vasculature compared to 26.2% of early stage tumors ($P<0.001$). Analysis of cumulative survival time and competing risks models revealed carcinoma patients with B7-H3 positive tumor vasculature had significantly shorter survival times ($P=0.02$) and more incidences of recurrence ($P=0.03$) than patients without positive tumor vasculature. In addition, we found that a soluble form of B7x in the blood was age-dependent in normal women and that elevated levels of soluble B7x in the blood were detected in 48.3% ovarian cancer patients. Finally, overexpression of B7x on tumor cells inhibited antigen specific cytotoxic T lymphocyte mediated cytotoxicity *in vivo*.

Conclusions: These results demonstrate that ovarian cancer cells overexpress B7-H3 and B7x and that the presence of B7-H3-positive tumor vasculature correlates with reduced survival and increased recurrence. These results also encourage evaluation of tumor-associated B7-H3 and B7x as potential new tumor immune evasion pathways and therapeutic targets.

1050 Routine Histologic Parameters Can Predict the Presence of Endometrial Carcinoma Following an Endometrial Biopsy Showing Complex Atypical Hyperplasia: A Clinicopathologic Study of 204 Cases

C Zhang, YE Wang, F Liu, CJ Sung, MM Steinhoff, MLomme, J Barroeta, WD Lawrence. Women & Infants Hospital of Rhode Island, Warren Alpert Medical School of Brown University, Providence, RI.

Background: We arbitrarily divided complex atypical hyperplasia of the endometrium (CAH) into two subtypes, types I and II, diagnosed in the following manner: i) in type I CAH, glands are back-to-back but the lesion is smaller than 2 mm, and ii) in type II CAH, glands show marked cytological atypia and crowded glands but there is still intervening stroma. The diagnosis of CAH in an endometrial sampling often leads to hysterectomy to exclude adenocarcinoma (ADCA). Our aim was to derive practical histopathologic parameters, using routine H&E stains, to determine whether histologic subtyping of CAH can predict which uteri will contain overt ADCA.

Design: We retrieved from our institutional pathology archives all cases of CAH diagnosed by endometrial biopsy (EmBx) and followed by hysterectomy during the period from 2001 to 2006. EmBx cases were reviewed to confirm the diagnosis and to categorize the lesions into either type I or type II CAH as defined above. The findings in the hysterectomy specimens were correlated with each type of CAH noted in the prior endometrial biopsy. The Chi-Square Test was used to compare the frequencies of ADCA in the resected uteri that were associated with either type I or II CAH.

Results: Of a total of 226 cases, the original EmBx diagnosis of CAH was confirmed in 204. 92 of 204 (45.1%) exhibited ADCA in the subsequent hysterectomy specimens. 45 of 204 EmBx cases fell into our type I CAH, and 159 of 204 into our type II CAH. The diagnosis of ADCA in the resected uteri followed type I CAH in 39 of 45 cases (86.7%) and followed type II CAH in 53 of 159 cases (33.3%) ($p<0.001$). Type II CAH was further separated by size into cases showing an aggregate lesion area ≥ 5 mm and cases showing an aggregate lesion area <5 mm. ADCA was found in 41 of 96 cases (42.7%) that showed ≥ 5 mm lesions and in 12 of 63 cases (19.0%) that exhibited smaller lesions ($p<0.01$).

Conclusions: Our so-called type I CAH is more frequently associated with ADCA than type II CAH. Within type II CAH, those showing an aggregate lesion area ≥ 5 mm are more often accompanied by carcinoma of the corpus than smaller lesions. Specifying the histologic type and size of CAH in the pathology report of an endometrial biopsy may prove useful in predicting the presence of ADCA in the uterine corpus.

1051 Comparative Immunohistochemical Analysis of Various Sex Cord-Stromal Markers in Different Categories of Ovarian Sex Cord-Stromal Tumors

C Zhao, TN Vinh, K McManus, D Dabbs, R Vang. Magee-Womens Hospital, UPMC, Pittsburgh, PA; AFIP, Washington, DC; Johns Hopkins Hospital, Baltimore, MD.

Background: Multiple IHC markers have been evaluated in different categories of ovarian sex cord-stromal tumors (SCSTs); however, very few studies with large numbers

of cases from each of the different SCST categories have compared the utility of the more commonly used older SCST markers with ones that have been utilized more recently. **Design:** IHC stains for WT1, SF1, Mart-1, Inhibin, Calretinin, and CD99 were performed in 127 cases from 5 different categories of ovarian SCSTs: Sertoli cell tumor (SertCT), adult granulosa cell tumor (AGCT), steroid cell tumor (SterCT), Sertoli-Leydig cell tumor (SLCT), and fibroma/fibrothecoma (F/FT). Extent of staining was based on the percentage of positive cells: 0, <5%; 1+, 6-25%; 2+, 26-50%; 3+, 51-75%; and 4+ 76-100%. Intensity of staining was scored as 1+, 2+, or 3+. IHC composite scores=extent score x intensity score.

Results: Table 1 and Table 2.

Tumors	n	WT1	SF1	Mart-1	Inhibin	Calretinin	CD99
SertCT	27	100%	100%	0%	96%	48%	59%
AGCT	32	78%	100%	0%	94%	81%	88%
SterCT	25	0%	100%	96%	100%	100%	32%
SLCT (SC)	18	100%	100%	0%	94%	44%	50%
SLCT (LC)	18	0%	100%	94%	100%	100%	6%
F/FT	25	100%	100%	0%	56%	36%	0%

SC, Sertoli cell component; LC, Leydig cell component.

Antigen	SertCT	AGCT	SterCT	SLCT (SC)	SLCT (LC)	F/FT
WT1	10.8 (4-12)	4.2 (1-12)	-	10.4 (6-12)	-	8.9 (3-12)
SF1	6.1 (1-12)	6.2 (1-12)	10.1 (2-12)	9.9 (1-12)	8.9 (1-12)	8.3 (2-12)
Mart-1	-	-	8.6 (1-12)	-	7.9 (2-12)	-
Inhibin	7.8 (1-12)	10.0 (4-12)	11.2 (8-12)	6.5 (2-12)	11.8 (9-12)	4.3 (1-9)
Calretinin	7.2 (1-12)	5.6 (1-12)	10.8 (4-12)	6.4 (2-12)	10.8 (2-12)	3.4 (2-6)
CD99	4.7 (1-12)	8.6 (1-12)	8.6 (6-12)	6.3 (1-12)	2*	-

* Scores calculated only for positive cases; **, Results reported as: Mean (range); ***, Only one case positive.

Conclusions: SF1 is the most diagnostically sensitive SCST IHC marker, and some markers are slightly more sensitive than others for detecting sex cord-stromal lineage. Within each different category of SCST, there are slightly unique differences in terms of which markers are more sensitive than others. Mart-1 is particularly sensitive and specific for SterC and SLCT.

1052 SF1 Is Diagnostically Useful and Comparable to Other Sex Cord-Stromal Tumor Immunohistochemical Markers for the Differential Diagnosis of Ovarian Sertoli Cell Tumor

C Zhao, TN Vinh, K McManus, D Dabbs, R Yang. Magee-Womens Hospital, University of Pittsburgh, Pittsburgh, PA; Armed Forces Institute of Pathology, Washington, DC; Johns Hopkins Hospital, Baltimore, MD.

Background: Steroidogenic factor 1 (SF1, Ad4-Binding protein) is a transcription factor that regulates the expression of steroidogenic enzymes. SF1 has been shown to be expressed in ovarian sex cord-stromal tumors; however data is limited. Expression in ovarian pure Sertoli cell tumor (SCT) and potential application for the differential diagnosis of SCT have not been studied.

Design: Immunohistochemical staining for SF1 (Clone N1665, R&D System), Inhibin (Clone R1, Dako), and WT1 (Clone Cell Marque) was performed in 111 ovarian tumors: pure SCT, endometrioid borderline tumor, sertoliiform endometrioid carcinoma, well-differentiated endometrioid carcinoma, and carcinosarcoma. Extent of staining was based on the percentage of positive cells: 0, <5%; 1+, 6-25%; 2+, 26-50%; 3+, 51-75%; and 4+ 76-100%. Intensity of staining was scored as 1+ (weak), 2+ (moderate), or 3+ (strong). Immunohistochemical composite scores were calculated (extent score x intensity score).

Results: See table 1 and 2.

Antigen	Sertoli cell tumor (n=27)	Endometrioid borderline tumor (n=25)	sertoliiform endometrioid carcinoma (n=12)	well-differentiated endometrioid carcinoma (n=23)	Carcinosarcoma (n=24)
SF1	100%	0	0	0	0
WT1	100%	16	25	13	0
Inhibin	96%	0	0	4	0

TABLE 2. Extent and Immunohistochemical Composite Scores of Expression of SF1, Inhibin, and WT1 in Sertoli Cell Tumor (n=27)

Antigen	0	Extent				IHC Comp Score*	
		1+	2+	3+	4+	Mean	Range
SF1	0	11%	26%	33%	30%	6.1	1-12
WT1	0	0	4%	7%	89%	10.8	4-12
Inhibin	4%	4%	15%	22%	55%	7.8	1-12

* Immunohistochemical composite score (calculated only for positive cases).

Conclusions: SF1 is a sensitive immunohistochemical marker for ovarian SCT and helpful for distinction from other non-sex cord-stromal tumors in the differential diagnosis. The diagnostic usefulness of this marker is comparable to that of inhibin and WT1.

1053 Expression of a Panel of Immunohistochemical Stains in Normal Cervix, Endometrium, and Uterine Carcinomas

J Zhou, A Khyami, J Tomashefsky, K Zilch, J Sawady. MetroHealth Medical Center, Case Western Reserve University, Cleveland, OH.

Background: The diagnosis of endometrial carcinoma can be difficult, especially in small surgical biopsy samples. A panel of immunohistochemical stains, including the new marker PK-M2, was performed in a variety of normal and neoplastic uterine tissue, to assess its diagnostic utility.

Design: Monoclonal antibodies against vimentin, EMA, PK-M2, and p53 using the Vector Immpress Mouse kit (Burlingame, CA 94010) were performed in 57 paraffin-embedded specimens including 28 endometrial carcinomas, 5 endometrial polyps, 9 samples of normal endometrium, 9 samples of normal endocervical tissue, and 6 endocervical carcinomas. Results were recorded as negative (-), weakly positive (+),

positive (++) and strongly positive (+++). The results were analyzed statistically using chi-square test.

Results: See Table 1 for a summary of the results.

	Vimentin*	EMA*	PK-M2*	P53*
Endometrial				
Benign	14/14 (100%)	14/14 (100%)	14/14 (100%)	3/14 (21.4%)
Malignant	27/28 (96.4%)	27/28 (96.4%)	26/28 (92.9%)	14/28 (50%)
Endocervical				
Benign	0/9 (0%)	5/9 (55.5%)	9/9 (100%)	0/9 (0%)
Malignant	1/6 (16.7%)	5/6 (83.3%)	6/6 (100%)	1/6 (16.7%)

* including +, ++, and +++

Significant findings include: (1) 96.4% (27/28) of endometrial carcinomas were positive for vimentin, compared to 16.7% (1/6) of endocervical carcinomas ($p < 0.001$). (2) 83.3% of endocervical carcinomas showed strong positivity in EMA expression, compared to 0% (0/9) of normal endocervical glands with strong positivity ($p < 0.001$). 55.5% (5/9) of normal endocervical glands demonstrated weakly positive or positive stain on EMA. In addition, only 17.9% (5/28) endometrial carcinomas were strongly positive for EMA. (3) Endometrial carcinomas were weakly positive (32.1%) or negative (7.1%) in PK-M2 expression, in contrast to benign endometrium (all cases with strong positivity) ($p < 0.05$). (4) 50% of endometrial carcinomas were positive for P53 as opposed to 11.1% (1/9) of normal endometrial samples ($p < 0.05$). In addition, 2 out of 5 endometrial polyps were also weakly positive for P53.

Conclusions: A panel of immunohistochemical stains including vimentin, EMA, PK-M2, and P53 can be used in difficult small biopsies to help differentiate endometrial carcinoma from endocervical carcinoma, and/or their benign counterparts.

Head & Neck

1054 Angiogenesis, MIB 1, DNA Ploidy and p53 in Mucosa Adjacent to Oral Squamous Cell Carcinomas

N Aggarwal, SG Sharma, SD Gupta, AK Dinda, BK Mohanty, MK Singh. All India Institute of Medical Sciences, Delhi, India.

Background: Histopathology is gold standard to determine completeness of surgical therapy in oral squamous cell carcinoma (OSCC). However, the status of the histologically benign area adjacent to tumor (shoulder) is unknown. We studied p53 expression, MIB 1, DNA ploidy and angiogenesis in OSCCs, shoulder and normal mucosa.

Design: This is a prospective study on surgical resection specimens from 33 patients of OSCC. We compared the tumor, shoulder (1 to 2 cms) and normal oral mucosa for angiogenesis by counting microvessel density (MVD) on CD34 immunohistochemical (IHC) stained slides and DNA ploidy (measuring integrated optical density on fuelsen stained slides) by computerized image analysis system. MIB 1 and p53 expression were evaluated on IHC stained slides. p53 was considered to be overexpressed if > 10% of the cells showed nuclear staining. Non parametric tests were used for statistical analysis. The clinical follow up is pending.

Results: The study population consisted of 27 males and 7 female, mean age was 49.81 yrs (30-70 yrs). 27/33 patients consumed tobacco. The sites involved were buccal mucosa (5/33), gingiva (14/33), anterior 2/3rd of the tongue (12/33) and lip (2/33). The TNM stage of tumors was stage 1 (7/33), stage 2 (7/33), stage 3 (2/33) and stage 4 (17/33). The tumor showed a higher MIB1 and p53 expression as compared to the shoulder region and normal area (p value <0.05). The staining for MIB 1 and P53 was restricted to the basal cells in normal mucosa, extended to suprabasal cells in the shoulder and was diffuse or along the infiltrating edge in the tumor. p53 overexpression was seen in 17/33 (51.5%) of the tumors and 8/31 (25.51%) of the shoulder. Except for one, tumor in all the cases showed aneuploid cell lines. The shoulder region had aneuploid cell lines in 50% of cases while all normal mucosae were diploid. The difference in MVD between the tumor (median 143.48 vessels/mm²), shoulder region (median 147.82 vessels/mm²) and normal mucosa (median 163.04 vessels/mm²) was not significant ($p = 0.28$). Correlation of MVD, p53 and MIB1 within tumor was not significant.

Conclusions: The pattern of p53 and MIB-1 expression, coupled with presence of aneuploid cell lines in the shoulder suggest that this area may be significantly abnormal though it appears histologically benign. This field effect may have a clinical impact in terms of local recurrence. Angiogenesis was not significantly increased in tumor making the role of antiangiogenic drugs questionable.

1055 Nodular Fasciitis of the Salivary Gland. A Clinicopathologic Study of 14 Cases

W Al-Daraji, ELB Childers, JC Fanburg-Smith. Armed Forces Institute of Pathology, Washington, DC; Howard University College of Dentistry, Washington, DC.

Background: Nodular fasciitis of the salivary gland is rare; there are only 13 cases total reported to date, all in the parotid gland. We reviewed our clinicopathologic experience with salivary gland nodular fasciitis.

Design: Cases coded as "nodular fasciitis" in all salivary glands were culled for clinicopathologic review.

Results: There were 14 cases from 1971-2003, 7 males and 7 females. Patient ages ranged from 4-51 (median 31.5) years; only 2 were less than 20 years. No patients recalled antecedent trauma. Symptoms ranged from rapid to one year of a painless to painful mobile mass, 2 "near the facial nerve." There were no changes of overlying skin. One patient had trismus. 10 cases were in the parotid gland (5 right, 5 left sided); 4 in submandibular gland (3 left, 1 right). Tumor size ranged from 1-4 (median 1.5) cm in greatest dimension. All but 1 case were well-circumscribed and had alternating spindle tissue culture like myofibroblasts with myxoid degeneration and extravasated erythrocytes and lymphocytes. Three cases demonstrated stromal keloidal collagen.