

### 395 Melanomas with and without Contiguous Nevi Have Different Clinicopathologic Features, Risk Factor Profiles, and Patterns of Site Specificity

NE Thomas, RL Barnhill, KL Brown, JL Johnson, JA Fine, M Berwick. University of North Carolina at Chapel Hill, Chapel Hill, NC; George Washington University, Washington, DC; University of Connecticut Health Center, Farmington, CT; Memorial Sloan-Kettering Cancer Center, New York, NY.

**Background:** Melanoma has been hypothesized to arise by two different pathways: one associated with melanocyte proliferation and the other with chronic exposure to sunlight (J Natl Cancer Inst 2003;95:806-12). If this model is correct, then a reasonable corollary is that the risk factors associated with each pathway should differ. We analyzed melanoma associated with the presence or absence of a nevus, as a potential marker for the nevoid, or melanocyte proliferation pathway.

**Design:** Data was obtained from a population-based case-control study conducted in Connecticut in 1987-89 in which melanoma cases were identified through the Connecticut Tumor Registry (n = 650), and a series of age and sex-frequency matched controls were obtained by random digit dialing (n = 549) (Int J Cancer 1996;67:636-643). Phenotype, family history and sun exposure history in relation to melanoma characterized by presence or absence of nevus-association were analyzed using a case-control approach extended to two distinct events: melanoma with (MN+) or without (MN-) an associated nevus. Odds ratios and chi-square tests were used to measure associations.

**Results:** Our results show that MN+ melanomas were more often truncal, of the superficial spreading subtype, and thinner than MN- melanomas. The percentage of total melanomas that were MN+ peaked in the same age group (40-49 years) as did mean number of nevi. Having numerous nevi increased risk for MN+ more than MN- melanoma ( $P = .03$ ). Having numerous back nevi conferred a site-specific risk for MN+ back melanoma ( $P = .002$ ). Family history of melanoma showed a borderline differential association with MN+ melanoma ( $P = .05$ ), while fair pigimentary traits and sun exposure history were not associated with differences in risk.

**Conclusions:** Our findings, that nevus-associated and de novo melanomas have different risk factors as well as different clinical and pathologic features, are compatible with the hypothesis that there may be two separate pathways to melanocyte transformation.

### 396 Fluorescence *In-Situ* Hybridization Confirmation of Cutaneous Acute Promyelocytic Leukemia

JE Wrede, U Sundram, S Kohler, AM Cherry, DA Arber, TI George. Stanford University School of Medicine, Stanford, CA.

**Background:** Cutaneous manifestations of acute promyelocytic leukemia (APL) are rare but well documented. Skin biopsies of APL can be difficult to confirm using morphology alone, and paraffin section immunophenotyping is not specific in separating APL from other acute myeloid leukemias involving the skin or inflammatory conditions with may mimic leukemia cutis. Fluorescence *in-situ* hybridization (FISH) has been shown to be a fast and effective method of detecting the PML/RARA gene fusion characteristic of APL in fresh blood and bone marrow samples. FISH has also been demonstrated to be effective in detecting other chromosomal rearrangements in paraffin embedded tissue (PET). This retrospective study of cutaneous lesions from patients with a history of APL evaluates the utility of performing PET FISH to confirm the presence of cutaneous manifestations of APL in formalin-fixed paraffin embedded skin biopsies.

**Design:** Three patients were identified with a history of APL and suspicious skin lesions that were biopsied. All patients had previous bone marrow findings of APL with characteristic morphologic findings, typical flow cytometry immunophenotype and cytogenetic studies which detailed the presence of the t(15;17) rearrangement. Nuclei were extracted from core biopsies performed on the formalin-fixed PET through a process of deparaffinization and enzyme digestion. FISH was performed using a dual color dual fusion PML/RARA probe. 200 nuclei were examined from each specimen.

**Results:** All cases showed evidence of the t(15;17) rearrangement by FISH, with 79%, 51%, and 16% positive signal patterns, each well above background limits. FISH performed on reactive tonsil (1000 total nuclei) yielded an average positive signal pattern of 0.3%. From this, a statistically significant background limit of 3.3% was determined for the PML/RARA probe (maximum range of positive signals for 200 nuclei plus two standard deviations). A skin-specific negative control was also used from a patient with lichenoid dermatitis which yielded a positive signal pattern of 0.5% (200 nuclei scored).

**Conclusions:** PET FISH appears to be a robust technique to detect cutaneous manifestations of APL in formalin-fixed paraffin-embedded skin biopsies.

## Endocrine

### 397 Correlation between Genetic Alterations and Microscopic Features of Papillary Thyroid Carcinomas

AJ Adeniran, Z Zhu, R Ciampi, YE Nikiforov. University of Cincinnati, Cincinnati, OH.

**Background:** It has been recently shown that papillary thyroid carcinomas can be initiated by one of three distinct molecular events: BRAF point mutations, RET/PTC rearrangements, or RAS point mutations. These alterations rarely overlap in one tumor and are found in at least two-thirds of all papillary carcinomas. In this study, we analyzed the association between these genetic events and microscopic features of papillary carcinoma as well as with their clinical and prognostic characteristics.

**Design:** Ninety-five papillary carcinomas were studied, of which 40 were positive for BRAF mutation, 16 for RET/PTC rearrangements, and 14 for RAS mutations. Histologic slides were evaluated in 64 cases and eight microscopic features were scored. This included six nuclear features: nuclear enlargement, irregularity of nuclear contours, chromatin clearing, nuclear crowding/overlapping, nuclear grooves, and nuclear pseudoinclusions. They were scored as 0, 1+ when present in < 10% of cells, 2+ when present in 10-50%, and 3+ when present in > 50% of tumor cells. Two additional characteristics, tumor fibrosis and psammoma bodies, were also scored.

**Results:** At least 4 nuclear features were found in each tumor, with nuclear pseudoinclusions being the least frequent finding in all groups. BRAF mutations were more frequently associated with irregularity of nuclear contours and nuclear crowding, and with classic papillary growth and tall cell variant. RET/PTC had significant correlation with classic papillary morphology and psammoma bodies, whereas RAS mutations correlated with follicular variant and with lower frequency of psammoma bodies and tumor fibrosis. In addition, BRAF positive papillary carcinomas were associated with older age, higher frequency of extrathyroid extension, and more advanced tumor stage at presentation.

**Conclusions:** Papillary carcinomas harboring BRAF, RET/PTC, and RAS mutations all demonstrate at least 4 diagnostic nuclear features of papillary carcinoma. However, several significant variations in the frequency of nuclear features, psammoma bodies, and tumor fibrosis were observed between tumors harboring different mutations. In addition, significant correlation was found between BRAF mutations and tall cell variant, RET/PTC mutations and classic papillary carcinoma, and RAS mutations and follicular variant of papillary carcinoma. BRAF point mutations also showed significant association with features of more aggressive behavior of papillary carcinomas.

### 398 Allelic Imbalance of Tumor Suppressor Gene Loci in Benign and Malignant Lesions of the Thyroid in Patients Who Had Radiation as Children

AM Assaad, JL Hunt. University of Pittsburgh, Pittsburgh, PA.

**Background:** Radiation in childhood is a known risk factor for thyroid carcinoma, but may also be related to benign nodular hyperplasias. Recent evidence indicates that radiation can induce clonal DNA damage at specific genetic loci in cell culture experiments that were analyzed by comparative genomic hybridization (CGH). In this study we analyzed lesions in thyroids from patients who had undergone radiation as children, patients with recent radiation for laryngeal carcinomas, and patients without radiation and with normal thyroids. We used a loss of heterozygosity analysis for the loci identified in the prior cell culture experiments.

**Design:** Thyroids from patients with a history of radiation, patients who had recent therapeutic external beam radiation for laryngeal carcinoma, and patients who had no radiation and underwent incidental thyroidectomy with laryngectomy for laryngeal carcinoma were included. Microdissection, DNA extraction, and PCR were performed for 18 different genetic loci defined by prior reported CGH studies of radiation damage in cell lines. A semiquantitative capillary electrophoresis analysis was used and loss of heterozygosity was considered present when the tumor allele ratio/normal allele ratio was <0.7 or >1.43. Frequency of allelic loss (FAL) was calculated from the number of losses/the number of informative loci.

**Results:** Forty cases of thyroids from patients with childhood radiation, 14 cases of recently radiated thyroids, and 15 cases of non-radiated thyroids were included. In the non-radiated and recently radiated thyroids, there were only extremely rare loci that had any evidence of allelic imbalance. In the thyroids from patients radiated as children, there were 10 cases with malignancy, 6 cases with adenomas, and 24 cases with nodular hyperplasia. Allelic losses were seen in carcinomas and in benign diseases at high frequency. Losses were seen at every locus with a range of 7 to 100% of the cases analyzed (mean 49.6%).

**Conclusions:** Radiation in childhood was associated with both benign nodular disease and carcinomas of the thyroid. The frequency of allelic imbalance was very high in all lesions in these patients, as compared to recently radiated and normal non-radiated thyroid glands. These data from human subjects support prior cell culture experiments detailing the genetic loci that are affected in radiation induced DNA damage in the thyroid and show that radiation induces genetic mutational damage even in benign proliferative processes in these thyroids.

### 399 Utility of Thyroglobulin Measurement in Fine-Needle Aspiration Biopsy Specimens of Lymph Nodes in the Diagnosis of Recurrent Thyroid Carcinoma

ZW Baloch, J Walsh, VA LiVolsi, JE Langer, SJ Mandel. UPENN Med Ctr, Philadelphia, PA.

**Background:** The most common site for the recurrence of papillary carcinoma of thyroid (PTC) is in regional lymph nodes. Ultrasound (US) imaging may identify abnormal appearing lymph nodes, suspicious for PTC recurrence. Although fine needle aspiration biopsy (FNAB) of abnormal lymph nodes is often diagnostic of recurrence, small (< 10 mm) or cystic lymph nodes may be non-diagnostic due to small numbers of tumor cells, and/or fibrosis in the tumor (either spontaneous or secondary to therapy). The measurement of thyroglobulin (TG) levels in FNAB specimens from lymph nodes suspicious for recurrent PTC can serve as an adjunct to the cytologic diagnosis.

**Design:** Nineteen abnormal appearing lymph nodes were aspirated under ultrasound guidance in 17 patients with a diagnosis of PTC. In addition to obtaining material for cytologic interpretation, an additional aspirate was obtained by FNAB and rinsed in 1 ml of normal saline for TG level measurements.

**Results:** The cytologic diagnosis included: reactive lymph node (RLN) 5, PTC 5 and inadequate for evaluation due to lack of epithelial cells (IE) 9 cases. TG levels were markedly elevated (539-17197250 ng/ml; normal <10 ng/ml) in all 5 patients with

lymph node recurrence identified on cytology. TG measurements were also elevated in 5 lymph nodes classified as IE on cytology due to lack of epithelial cells. The addition of TG assay decreased the rate of IE from 47% to 21% of lymph nodes.

**Conclusions:** The measurement of TG in FNAB specimens from lymph node in patients with history of PTC is useful in detecting recurrent disease, and should be used in those cases when the specimen is known to be or likely to be inadequate for cytologic evaluation.

#### 400 Somatic Down-Regulation of Mismatch Repair Proteins Correlates with Accumulation of Microsatellite Abnormalities in Pheochromocytomas

*A Blanes, SJ Diaz-Cano.* University of Malaga School of Medicine, Malaga, Spain; King's College Hospital, London, England, United Kingdom.

**Background:** Adrenal pheochromocytomas (PCC) have been extensively studied at the molecular level, but no information is available on the microsatellite profile by topographic compartments of malignant and locally invasive PCC. The contribution of DNA mismatch repair abnormalities to this profile remains unknown.

**Design:** Microdissected samples from the peripheral and internal zones of 143 pheochromocytomas (95 sporadic, 48 associated to MEN-2A) were selected for loss of heterozygosity (LOH) and single nucleotide polymorphism (SNP) analyses. Five polymorphic DNA regions from TP53, RB1, WT1, and NF1 were systematically studied by polymerase chain reaction-denaturing gradient gel electrophoresis. Pheochromocytomas were classified malignant (16 sporadic tumors with distant metastases), locally invasive (30 sporadic tumors showing retroperitoneal infiltration only), and benign (all remaining tumors). Statistical differences were evaluated using Fisher's exact test. Mismatch repair was assessed by MLH1 and MSH2 sequencing and immunostaining in PCC with  $\geq 2$  abnormal microsatellite loci.

**Results:** LOH/SNP involved TP53 in 40/134 informative cases (29.9%), RB1 in 22/106 informative cases (20.8%), WT1 in 32/120 informative cases (26.7%), and NF1 in 32/80 informative cases (40.0%). More genetic abnormalities involving the peripheral compartment were revealed in 34 pheochromocytomas (23.8%): 12/16 malignant, 10/30 locally invasive, and 12/97 benign. Multiple and coexistent genetic abnormalities characterized malignant PCC ( $P < 0.001$ ), whereas locally invasive PCC showed significantly higher incidence of NF1 alterations ( $P < 0.001$ ).

A significant decrease of MLH1 or MSH2 protein expression was observed in the peripheral compartments, but with no gene mutations identified in PCC with high microsatellite instability.

**Conclusions:** 1. Somatic topographic down-regulation of mismatch repair proteins contributes to both the accumulation of microsatellite lesions in the peripheral compartment and intratumor heterogeneity, the two key features characterizing malignant PCC and supporting a multistep tumorigenesis for these neoplasms.

2. In contrast, locally invasive PCC frequently reveals single locus alterations, especially involving NF1.

#### 401 Hormonal Status Correlates with EGF-R or Ki-67 Expression in Women with Differentiated Papillary Thyroid Carcinoma (D-PTC)

*FA Candanedo-Gonzalez, M Saqui-Salces, B Rocha, A Gamboa-Dominguez.* National Institute of Medical Sciences and Nutrition, Mexico City, Tlalpan, Mexico.

**Background:** Postmenopause has an adverse effect on D-PTC and it is associated with a higher recurrence rate of the disease. Aim: To determine if CDH1, EGF-R or Ki-67 expression correlates with D-PTC recurrence in post-menopausal women.

**Design:** D-PTCs of a single institution with follow-up and hormonal status were included. Post-menopause was defined as absence of uterine bleeding during the past year. Four 3mm tissue cores were punched and arrayed on a recipient paraffin block, including one of remnant tissue. IHC detection of E-cadherin (Dako, clone NH-38), EGF-R (EGFRpharmDx, Carpinteria, CA), and Ki-67 (Dako) was blindly performed. CDH1 reactivity was graded as normal (100%+ve cells), heterogeneous (75, 50 or >25%+cells) or negative. EGF-R was graded as 0,1,2,3, and Ki-67 as an index of positive cells. Tumor staging was performed using the 6th ed.-AJCC and tumor classification according to WHO system.

**Results:** 215 women with D-PTC were included (mean follow-up 69 months), 154(72%) pre-menopausal and 61(28%) post-menopausal. Recurrences were observed in 15/154 pre and in 17/61 post-menopausal ( $p < 0.005$ ). Abnormal CDH1 expression was observed in 145(94%) pre-menopausal and 53(87%) post-menopausal patients, while positive EGF-R expression in 17(11%) vs. 14(23%), both markers without correlation with pTNM or recurrences. However, EGF-R was mainly expressed in post-menopausal women ( $p < 0.02$ ). Ki-67 correlates with pre-menopausal and tumor size, but not with CDH1, EGF-R or post-menopause. Multivariate analysis showed that post-menopause ( $p < 0.003$ ) and stage ( $p < 0.03$ ) correlate with recurrences.

**Conclusions:** Recurrences of D-PTC in post-menopause are related with EGF-R overexpression, while in pre-menopause with Ki-67 expression, in neoplastic cells.

#### 402 Clinicopathologic and Anti-Utrophin Immunohistochemical Correlation in Sporadic Pancreatic Endocrine Tumors

*MC Chang, S Xiao, V Nosé.* Brigham and Women's Hospital, Harvard Medical School, Boston, MA.

**Background:** Pancreatic endocrine tumors (PETs) arise both in association with inherited syndromes (Multiple Endocrine Neoplasia type I and von Hippel Lindau) and sporadically. It remains difficult to predict the biologic behavior of these tumors based on clinical presentation or morphologic findings alone. Utrophin is a ubiquitously expressed homolog of dystrophin, encoding large cytoskeletal proteins. Its gene is located on chromosome 6q, on which structural abnormalities have been reported in human sporadic PETs. Utrophin may be a helpful marker in determining the malignant potential of sporadic PETs.

**Design:** Sporadic PETs resected or biopsied from 60 patients were identified and reviewed with respect to tumor size, mitotic rate, hormone-functional status, local invasion, lymphangitic spread, lymph node/distant metastasis, and known clinical outcome. The tumors were classified according to WHO criteria and clinical course as benign/uncertain (well-differentiated only, 20 cases, mean age 52 years, 1.2:1 M:F) and malignant (well and poorly differentiated, 40 cases, mean age 54 years, 1.2:1 M:F). Paraffin-embedded sections from primary and metastatic tumors, normal pancreatic sections, and control epithelial tissues were assessed for expression of utrophin, using a monoclonal antibody against a carboxy-terminal epitope of utrophin.

**Results:** Benign PETs displayed weak and diffuse nuclear and cytoplasmic utrophin expression by immunoperoxidase staining, similar to the pattern seen in non-neoplastic islet cells. By contrast, malignant PETs displayed strong membrane localization, and diffuse cytoplasmic staining, similar to control epithelial tissues (exocrine pancreas, breast, lung). Among tumors of uncertain potential, non-functioning tumors of large size (> 4 cm) and insulinomas tend to stain similarly to benign PETs.

**Conclusions:** Anti-utrophin immunohistochemical staining in sporadic PETs of known malignant behavior is distinct both in pattern and intensity from those of benign behavior. Further studies are warranted, to evaluate the utility and basis of anti-utrophin, in predicting biologic behavior of PETs.

#### 403 Various Mechanisms of BRAF Activation in Thyroid Tumors

*R Ciampi, M Gandhi, YE Nikiforov.* University of Cincinnati, Cincinnati, OH.

**Background:** Activating point mutations of the BRAF gene have been recently described as the most common genetic event in papillary thyroid carcinomas. They are found in approximately 40% of cases and are associated with classic papillary growth pattern and tall cell variant. Here we investigated if BRAF can be activated by other mechanisms, and explored the prevalence of these events in various types of thyroid tumors.

**Design:** We studied 102 sporadic papillary carcinomas, 29 radiation-induced papillary carcinomas, 17 follicular adenomas, 10 Hurthle cell adenomas, 7 follicular carcinomas, and 7 Hurthle cell carcinomas. Using PCR and fluorescence in situ hybridization (FISH), all cases were studied for BRAF point mutations, chromosomal rearrangements, and numerical changes in the BRAF gene locus/gene amplification. A contig of three PAC clones spanning the entire BRAF gene was used as a probe for FISH, so that a split of the probe would indicate the BRAF rearrangement. A chromosome 7 centromeric probe was used to evaluate the chromosome ploidy.

**Results:** BRAF point mutations were detected in 37% of sporadic papillary carcinomas and in none of other tumor types. BRAF involvement in chromosomal rearrangement was detected in 1 (1%) sporadic papillary carcinoma and in 3 (11%) radiation-induced papillary carcinomas, but not in follicular tumors. Numerical change of the BRAF locus on chromosome 7 were detected in 4 (24%) follicular adenomas, 5 (50%) Hurthle cell adenomas, 1 (14%) follicular carcinomas, and 2 (28%) Hurthle cell carcinomas. In follicular adenomas, all cases showed three BRAF signals either due to chromosome 7 trisomy (3 cases) or BRAF amplification (1 case). Follicular carcinomas and Hurthle cell tumors showed 4-6 BRAF signals and in all cases except one they were associated with numerical changes of chromosome 7.

**Conclusions:** We demonstrate for the first time that BRAF gene can be affected in thyroid tumors not only by point mutation, but also by chromosomal rearrangement and gene amplification. BRAF point mutations are common and specific for papillary carcinomas. BRAF rearrangements are rare in sporadic tumors and more frequent in papillary carcinomas associated with radiation exposure. In contrast, benign and malignant follicular tumors are associated with changes in copy number/amplification of the BRAF locus, which is more common in Hurthle cell tumors.

#### 404 Expression of NOTCH3 Protein Identifies a Distinctive Subset of Pheochromocytomas

*PL Dahia, JF Powers, SA Ehsani, AS Tischler.* Dana-Farber Cancer Institute, Boston, MA; Tufts New England Medical Center, Boston, MA.

**Background:** NOTCH proteins are transmembrane receptors that participate in cell fate decisions during development and may play a role in tumor cell differentiation. Notch has also been implicated in defining the maturation stage of neuroblastomas. An ongoing expression profiling study of pheochromocytomas, which are embryologically related to neuroblastomas, identified a highly significant association between increased expression of the NOTCH3 gene and a distinct subset of pheochromocytomas. The present study was performed to validate these findings at the protein level and to establish a genotype-phenotype correlation.

**Design:** A series of pheochromocytomas, including 6 apparently sporadic, 10 MEN2A, 8 VHL, 6 PGL (2 SDHB- and 4 SDHD-mutated), 2 NF1 and 4 hereditary of unknown origin was stained immunohistochemically for NOTCH3 using a rabbit polyclonal antibody after microwave antigen retrieval. Neuroblastoma tissue served as a positive control and irrelevant IgG as a negative control.

**Results:** IHC demonstrated focal or diffuse NOTCH3 immunoreactivity in 5/8 VHL pheochromocytomas, 1 apparently sporadic tumor, and 1 SDHB tumor, while none of the MEN and NF1 tumors showed positive staining, in agreement with the expression pattern indicated by array profiling. In all cases immunoreactivity was present predominantly in tumor cell nuclei.

**Conclusions:** Our findings in this pilot series suggest that increased NOTCH3 expression may be associated with specific genetic subtypes of pheochromocytoma. These studies need to be validated in extended and independent cohorts. As associations between certain genetic subforms and tumor prognosis start to emerge, further studies will be necessary to determine the utility of NOTCH3 as a new prognostic marker for pheochromocytomas. Intranuclear truncated NOTCH proteins with transforming activity have previously been reported in human T-cell leukemia. These developmentally important proteins may also play important roles in other tumors. Supported by NIH grant CA48017 (AST)

#### 405 Cytokeratin Expression in Adrenocortical Carcinoma

*Y Ding, BI Aswad, SJ Shin, RA DeLellis.* Rhode Island and The Miriam Hospitals and Brown Medical School, Providence, RI; Weill Medical College of Cornell University and New York Presbyterian Hospital, New York, NY.

**Background:** Adrenocortical carcinomas (ACCs) have been traditionally characterized as having a vimentin (VIM) positive and cytokeratin (CK) negative immunoprofile. Some degree of CK immunoreactivity in these tumors has been demonstrated in fresh frozen sections (Gaffer, et al. *Hum Pathol* 1992;32:144) or formalin fixed paraffin embedded sections pretreated with trypsin (Wick, et al. *Am J Pathol* 1986;122:343). The effects of heat induced antigen retrieval on CK expression in these tumors, however, have not been studied systematically.

**Design:** Ten formalin fixed paraffin embedded ACCs were analyzed for the distribution of CKs using AE1/AE3 (DakoCytomation, Carpinteria, CA), 34βE12 (Enzo Life Sciences, Farmingdale, NY), MAK-6 (Zymed Laboratories Inc., South San Francisco, CA), CAM5.2 (Becton Dickinson, San Jose, CA), CK7 (DakoCytomation), CK20 (DakoCytomation), and a CK cocktail (including AE1/AE3, CAM5.2, and MAK-6) and VIM (BioGenex, San Ramon, CA) using the Dako En Vision™ System on a Dako Autostainer. All cases were subjected to standard 95°C steamer heat induced antigen retrieval in a citrate buffer, pH 6.0, for 25 minutes prior to staining.

**Results:** All ten cases exhibited diffuse strong VIM immunoreactivity. Seven of ten cases were positive using the CK cocktail and/or AE1/AE3 while none of the cases was positive for 34βE12, CAM5.2, CK7, CK20, or MAK-6. Three of the cases exhibited positivity in 50 to 75% of the cells, three cases were positive in 25 to 50% of the cells, and one case was positive in less than 25% of the cells. The intensity of the stain was moderate to strong.

**Conclusions:** This study confirms the expression of cytokeratin in ACCs. Seventy percent of ACCs studied exhibit some degree of CK positivity using AE1/AE3 and/or the CK cocktail following standard heat induced antigen retrieval. The presence of CKs in a retroperitoneal tumor does not exclude the possibility of ACC. The differential diagnosis of ACC should include retroperitoneal tumors showing positivity for AE1/AE3 and/or CK cocktail, negativity for CAM5.2, CK7, CK20, MAK-6, and 34βE12, and strong positivity for VIM. More specific stains including A103 (melanin A), inhibin or calretinin can be used to confirm the adrenal cortical origin of the tumor.

#### 406 Expression of Transcription Factors CDX-2 and TTF-1 in Extrapulmonary Neuroendocrine Carcinomas

*YM EL-Gohary, P Cho, RS Saad, YL Liu, JF Silverman.* Allegheny General Hospital, Pittsburgh, PA.

**Background:** Organ specific transcription factors intestinal transcription factor (CDX-2) and thyroid transcription factor (TTF-1) have been widely used as specific epithelial immunohistochemical (IHC) markers in the work-up of metastatic carcinoma of unknown origin. In addition, they have also recently been shown to be expressed in some neuroendocrine carcinomas (NEC). However, the expression and distribution of TTF-1 in extrapulmonary neuroendocrine carcinoma (EPNEC) are still controversial and limited data is available regarding the expression and distribution of CDX-2 in neuroendocrine carcinomas from various sites.

**Design:** A total of 20 cases of extrapulmonary neuroendocrine carcinomas were retrieved, including 9 well differentiated and 11 poorly differentiated EPNEC. EPNEC of the following organs and sites were studied: 5 pancreas, 3 ampulla of Vater, 1 case each from stomach, gallbladder, sigmoid colon, duodenum, anal canal, pelvic wall, vulva, nasal cavity, breast, urinary bladder, uterus, and prostate. Cases were excluded if there was any possibility of previous or current history of pulmonary neuroendocrine carcinoma. Immunohistochemical studies for CDX-2, TTF-1, synaptophysin, chromogranin, microtubule-associated protein-2 (MAP-2) and NSE (neuron specific enolase) were performed on an automated stainer with positive and negative controls.

**Results:** The neuroendocrine differentiation of the neoplasms was confirmed in all the cases with conventional neuroendocrine IHC markers. MAP-2 was positive in 18/20 cases, NSE positive in 17/20, synaptophysin positive in 16/20, and chromogranin positive in 11/20. Positive TTF-1 nuclear immunoreactivity was demonstrated in three (3/20, 15%) extrapulmonary neuroendocrine carcinomas, including one case each from the ampulla of vater, pancreas, and anal canal. All three positive cases are poorly differentiated neuroendocrine/small cell carcinomas without an identifiable pulmonary lesion. CDX-2 immunoreactivity was present in three cases (3/20, 15%), including one each from stomach, gallbladder and sigmoid colon. No CDX-2 immunoreactivity was observed in neuroendocrine carcinomas of other organs or sites.

**Conclusions:** 1. TTF-1 is not specific for pulmonary neuroendocrine carcinoma and can be expressed in 15% extrapulmonary neuroendocrine carcinomas.

2. TTF-1 is expressed in poorly differentiated extrapulmonary neuroendocrine carcinoma, but not well differentiated neuroendocrine carcinoma.

3. CDX-2 can be expressed in gastrointestinal and biliary tract neuroendocrine carcinomas.

#### 407 Growth Factor Receptor Expression in Anaplastic Thyroid Carcinoma, Implications for a Therapeutic Approach

*DD Elliott, AK El-Naggar.* UT, MD Anderson Cancer Center, Houston, TX.

**Background:** Anaplastic thyroid carcinoma (ATC) is one of the most fatal thyroid malignancies. Despite many therapeutic modalities, successful cure has not been established. Tyrosine kinase and growth factor inhibitors are known to play a role in the therapy of many tumors. Components of cell growth and regulation pathways including Her2neu(H2N), epidermal growth factor receptor (EGFR) and platelet derived growth receptor (PDGFR) have proven to be of both therapeutic and prognostic

importance in the evaluation of such tumors. The current objective was to investigate these 3 related growth factor receptors using immunohistochemistry (IHC) in order to assess their potential as therapeutic targets in the management of ATC.

**Design:** The pathology files were searched for all cases of ATC from 1957 to 2003. A total of 35 cases were available for review and the diagnoses were confirmed. Each case was classified according to the predominant subtype: spindle, squamoid or giant cell. The type of well-differentiated thyroid carcinoma (WDTC) was also noted. Formalin-fixed, paraffin-embedded tissue sections were stained with antibodies to EGFR, PDGFR and H2N. The staining distribution and intensity were scored: 0=none, 1+ = weak, 2+ = moderate, 3+ = strong staining. Cases demonstrating a score of 0-1+ and 2-3+ were categorized as low and high expression, respectively.

**Results:** The study cases included 35 tumors from 21 females and 14 males. The mean was 60.8 years. Histologic subtypes included 13 spindle, 10 giant cell and 12 squamoid. WDTC components were identified in 12 cases: 11 papillary thyroid carcinomas and one Hurtle cell carcinoma. One case had a pre-existing goiter and two cases had an insular carcinoma. One case with PTC also had lymphocytic thyroiditis. None of the histologic features or immunoprofiles was found to be associated with a specific histologic subtype. A high level of expression for EGFR, PDGFR and H2N was observed in 70%, 80% and 32% of cases, respectively; 53% showed high expression for both EGFR and PDGFR, 24% had high expression for all 3 antibodies.

**Conclusions:** In our series of ATC, a high level of expression of EGFR and PDGFR was observed in the majority of cases. A minority of cases also demonstrated high expression for H2N. These findings have implications for a possible therapeutic role for growth factor and tyrosine kinase inhibitors in ATC. Such differential expression also suggests a role for growth factor expression in thyroid tumorigenesis and may have an impact on the biologic stratification of these tumors.

#### 408 Gene Expression Profile of PTC: Comparison of Follicular Variant and Classic Morphology PTC with Benign Follicular Patterned Lesions

*SP Finn, PC Smyth, EM O'Regan, S Cahill, M Toner, C Timon, RJ Flavin, JJ O'Leary, OM Sheils.* University of Dublin, Trinity College, Dublin, Ireland; Dublin Dental School and Hospital, Dublin, Ireland.

**Background:** The Follicular Variant of Papillary Thyroid Carcinoma (FVPTC) is a controversial entity with potential for diagnostic uncertainty, because of:

a) Poorly developed/displayed diagnostic nuclear features in Fine Needle Aspiration Cytology material and

b) marked observer variation on surgical excision specimens.

Identifying biomarkers of malignancy specific to FVPTC would potentially enhance our diagnostic capabilities in borderline cases and lead to more accurate diagnosis and treatment planning.

**Design:** The aim of this study was to identify potential candidate biomarkers of FVPTC on well-characterised surgical samples using a chemiluminescence based expression array system to study the expression of 31,600 genes. Transcripts were curated to the public and Celera databases.

DNA and RNA were extracted from fresh frozen thyroid samples, comprising PTC (N=8, 4 classic and 4 FVPTC) and benign thyroid samples (N=5, 2 follicular adenomas, 1 normal thyroid, 1 Graves' disease and 1 case of lymphocytic thyroiditis). Rearrangement and BRAF mutation status was assessed by TaqMan RT-PCR and allelic discrimination assays respectively.

**Results:** Mutant BRAF was exclusively associated with classic morphology PTC. Transcripts of rearranged ret/PTC 1 or 3 were not detected in any sample. After appropriate filtering, hierarchical clustering with Pearson correlation of 2639 genes revealed distinct clusters associated with FVPTC and benign follicular patterned lesions. Further data analysis was applied using fold change determination, t-test comparisons and False Discovery Rate analysis to define a panel of genes showing altered expression in FVPTC and classic morphology PTC in comparison to benign lesions and normal thyroid tissue.

Over-representation of genes involved in DNA replication (Calgizarin), cell cycle regulation (TGFBI and Casein kinase 1), DNA metabolism (RAD 23 B), and small nuclear riboprotein metabolism (LSM7) are associated with both FVPTC and classic morphology PTC relative to benign lesions and tissue. In addition, over-representation of molecules of the small GTPase family (RAB 27 and MRAS) are associated with FVPTC.

**Conclusions:** In conclusion, we have identified biomarkers of classic morphology PTC and FVPTC, which require further investigation, but have potential to improve the diagnostic accuracy of thyroid carcinoma and particularly FVPTC.

#### 409 Postmenopause and Papillary Thyroid Carcinoma Recurrence. A Multivariate Analysis

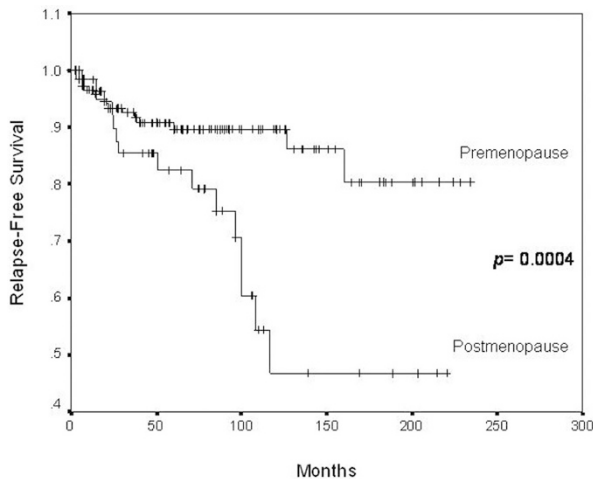
*A Gamba-Dominguez, FA Candanedo-Gonzalez.* National Institute of Medical Sciences and Nutrition, Mexico City, Tlalpan, Mexico.

**Background:** Differentiated papillary thyroid carcinoma (D-PTC) is a common malignancy in women and has a worse prognosis in patients over 45-years old. **Aim:** To identify if hormonal changes due to menopause in women with D-PTC correlate with shorter relapse-free survival rates.

**Design:** A hospital-based case control study with blinded histopathological review of tumor slides was conducted. Clinical data, hormonal status information and follow-up were obtained from clinical charts. Tumor staging and histological classification were performed using AJCC and WHO systems, respectively. Tumor size, multicentricity and residual thyroid diseases were obtained from the original surgical pathology reports. Post menopause was defined as the absence of uterine bleeding during the last year or longer, and all included patients were submitted to similar surgical procedures. Post menopause, age and stage correlate highly with each other, and therefore were analyzed separately. Uni and multivariate analysis were performed.

**Results:** Two hundred and fifteen women were included in the study, 154 pre menopausal and 61 postmenopausal with a mean follow-up of 71 months. At the time of diagnosis no differences were observed in pT, pN, pM or extra thyroidal extension between groups. Recurrences were observed in 30 patients (14%); 15 (10%) of them pre and 15 (24.5%) postmenopausal ( $p=0.008$ ). A trend for tumor recurrence was observed in postmenopausal women submitted to estrogen replacement therapy. Relapse-free survival differences were observed (Graphic) between pre and post menopause patients ( $p=0.0004$ ). Cox regression model controlled by tumor size (< or > 4 cm), lymph node metastases (positive or negative), distant metastases (positive or negative) and, extra thyroidal invasion (positive or negative) showed that post menopause has an adverse effect on recurrence-free survival ( $p=0.041$ ).

**Conclusions:** Post menopause is an adverse prognostic factor for tumor recurrence in women with similarly treated D-PTC. Post menopause can be considered a biological explanation, in addition to patient age, for adverse prognosis in women over 45 years old. This variable should be considered in tumor staging of differentiated papillary thyroid carcinoma.



#### 410 Papillary Thyroid Carcinomas Display Lower Amounts of Histone H3 Lysine 4 Methylation Compared to Follicular-Type Neoplasms

S George, K Dresser, A Khan, A Fischer. Umass Memorial Medical Center, Worcester, MA.

**Background:** Various modifications of the amino-terminal tail of histones appear to be major determinants of large-scale chromatin packaging, and they directly regulate diverse nuclear functions including gene expression. Since papillary thyroid carcinoma (PTC) displays a different large-scale organization of chromatin compared to follicular-type epithelium, we tested the hypothesis that histone modification distinguishes PTC from follicular-type lesions.

**Design:** Rabbit polyclonal antibody (Abcam) specific to histone H3 mono-methylated at lysine 4 was applied to paraffin sections in 9 cases of PTC (including 3 conventional, 2 micro and 4 follicular variant of PTC), 4 cases of follicular adenoma (FA), and 2 cases of follicular carcinoma (FC). Non-immune rabbit serum was used as a negative control. Non-neoplastic follicular cells and mature lymphocytes showed strong positive nuclear staining and were used as positive internal control. Two independent observers scored the percentage of tumor nuclei that were negative, 1+ (less than normal thyroid epithelium or mature lymphocytes), and 2+ (as strong as normal thyroid epithelium or mature lymphocytes).

**Results:** Except for one follicular variant of PTC which showed 5% of nuclei with 2+ staining, no other PTC showed nuclei with 2+ staining. The conventional PTCs showed no more than 10% 1+ staining. One micro PTC showed 40% 1+ staining and one showed only 5% 1+ staining. Follicular variant of PTC was more variable, with 10 to 90% of nuclei showing 1+ staining. All FA cases showed at least 50% 2+ staining and no more than 10% of nuclei were negative. The 2 FC showed 80 and 95% 2+ staining and neither showed absent staining. Large lymphoid cells within germinal centers with open chromatin showed absent staining, and there appeared to be a tendency for non-neoplastic thyroid epithelium reactive to adjacent lymphocytic thyroiditis to show decreased staining. Preliminary studies with oncocytic lesions show a more heterogeneous staining reaction.

**Conclusions:** PTCs show lower amounts of a histone H3 methylated at lysine 4 compared to normal thyroid or non-oncogenic follicular-type neoplasms. The loss of H3 methylation may be an early event in the formation of a PTC. Histone modifications could provide a molecular explanation for the diagnostic pale chromatin of PTC.

#### 411 Immunohistochemical Expression of Neuroendocrine Secretory Protein-55 (NESP-55) in Pituitary Adenomas

M Gupta, A Srivastava, RV Lloyd, R Fischer-Colbrie, AS Tischler, Y Dayal. Tufts-New England Medical Center, Boston, MA; Mayo Clinic, Rochester, MN; University of Innsbruck, Innsbruck, Austria.

**Background:** Neuroendocrine secretory protein-55 (NESP-55) is a recently described member of the chromogranin family and appears to be a marker of the constitutive secretory pathway in certain neural and endocrine cell types. It has been shown to have

a more restricted distribution than that of chromogranin A in normal and neoplastic tissues of endocrine origin and is selectively expressed in tumors differentiating towards the adrenal chromaffin and pancreatic islet phenotypes. The highest levels of NESP-55 expression, at least in animals, appear to be in the adrenal medulla and the pituitary gland. We therefore studied the immunohistochemical profile of NESP-55 expression in a series of normal human pituitaries and pituitary adenomas.

**Design:** Thirty pituitary adenomas (5 each of FSH/LH and ACTH, 4GH, 3TSH, 7PRL and 6 null cell) and four normal pituitary glands were selected for study. All cases were positive for a generic marker(s) of neuroendocrine differentiation (chromogranin A, synaptophysin, neuron-specific enolase). All cases were stained for NESP-55 after microwave antigen retrieval using a rabbit polyclonal antibody at a dilution of 1:1000 and appropriate positive and negative controls. NESP-55 immunoreactivity, seen as brown finely granular cytoplasmic staining with prominent perinuclear accentuation, was graded as focal (<10%), moderate (10-50%) and diffuse (>50%).

**Results:** Four of seven prolactinomas were positive for NESP-55 (1 focal, 2 moderate and 1 diffuse). Two of four GH adenomas were also positive (1 focal and 1 diffuse) while 1/5 FSH tumors showed moderately intense immunoreactivity. All other pituitary adenomas were completely negative for NESP-55. Patchy but variably strong immunostaining was seen in all normal pituitary glands suggesting reactivity for specific cell types.

**Conclusions:** Our results indicate that in humans, NESP55 reactivity in pituitary adenomas has a more restricted pattern of expression than that of chromogranin A. The presence of immunohistochemical expression only in prolactinomas, GH and FSH adenomas raises the possibility that NESP-55 may somehow be involved in the secretory pathways of these specific cell types.

#### 412 Immunohistochemical Expression of Bcl-2, Bcl-x and Bax in Follicular Carcinomas of the Thyroid

DM Haynik, RA Prayson. Cleveland Clinic Foundation, Cleveland, OH.

**Background:** Bcl-2, bcl-x, and bax are regulatory proteins involved in the regulation of apoptosis; bcl-2 and bcl-x inhibit apoptosis and bax generally promotes apoptosis. Aberrant expression of apoptosis regulatory proteins is a characteristic feature of many human carcinomas; however, there is limited data on the expression of these proteins in follicular carcinomas of the thyroid.

**Design:** A retrospective clinicopathologic review with bcl-2, bcl-x, and bax immunohistochemical staining of 34 follicular carcinomas (FC) and 7 follicular adenomas with capsular infiltration (FACI) was performed.

**Results:** The study included 41 patients (pts) (25 females, 16 males; age range 16-84 yrs, mean 50.9 yrs). All pts underwent surgical resection of the neoplasm (lobectomy n=7, lobectomy with isthmusectomy n=26, thyroidectomy n=7, and thyroidectomy with radical neck dissection n=1). Thirty-four tumors were classified as FC and 7 were classified as FACI. Seven FC pts developed recurrent disease: 3 pts were alive (mean 10.1 yrs) and 4 pts died with metastatic disease (3.5 yrs). All remaining pts were disease free (mean follow up 5.9 yrs). Only one FACI recurred (pt alive at 9 yrs). The remaining pts were disease free (mean follow up 4.9 yrs). Normal thyroid tissue stained positively for bcl-2 and bcl-x, and did not stain with bax. In contrast to normal thyroid, only 15 tumors (12 FC and 3 FACI) stained positively for bcl-2. None of the recurrent tumors demonstrated evidence of bcl-2 staining. The majority of tumors stained positively for bax (83%, 29 FC and 5 FACI) and for bcl-x (93%, 32 FC and 6 FACI); there was no obvious correlation of staining with outcome.

**Conclusions:** The majority of follicular neoplasms were positive for bax and a subset of follicular neoplasms were negative for bcl-2 by immunohistochemistry. Such aberrant expression of apoptosis-associated proteins may play a role in the pathogenesis of follicular carcinoma of the thyroid. Furthermore, all recurrences and tumor related deaths were negative for bcl-2. This data suggests that the loss of bcl-2 expression may correlate with increased tumor recurrence and death.

#### 413 Mutational Activation of BRAF Is Not a Major Event in Sporadic Childhood Papillary Thyroid Carcinoma

GA Hosler, E Rosenbaum, M Zahurak, Y Cohen, D Sidransky, WH Westra. The Johns Hopkins Medical Institutions, Baltimore, MD.

**Background:** Papillary thyroid carcinoma (PTC) may encompass a mixed group of neoplasms where divergence in clinical behavior may reflect distinct genetic alterations. For example, young patients with PTC have a better prognosis than affected adults, and their carcinomas are much more likely to harbor chromosomal rearrangements involving the *RET* protooncogene. Mutational activation of the *BRAF* oncogene has recently been identified as the most common genetic alteration in PTC, but little is known about its frequency as a function of patient age.

**Design:** We tested 20 PTCs from young patients ranging from 10 to 17 years of age for the thymine (T) → adenine (A) missense mutation at nucleotide 1796 in the *BRAF* gene using a newly developed assay that employs a novel primer extension method (Mutector® assay). The prevalence of *BRAF* mutation was compared with a larger group of PTCs from previously tested adult patients (>20 years).

**Results:** *BRAF* mutations were not common in PTCs from young patients compared to their counterparts in adults (20% vs. 77%; OR = 13.3, 95% confidence interval [CI] = 3.4 - 56.5;  $P < .0001$ ), but they become increasingly prevalent with advancing patient age (OR as a function of age at 10 year intervals = 1.80 CI = 1.33 - 2.44;  $P < .001$ ).

**Conclusions:** Unlike PTCs that arise in adults, mutational activation of *BRAF* is not a major genetic alteration in PTCs that arise in young patients. The increasing frequency of *BRAF* mutations as a function of age could help account for the well documented but poorly understood observation that age is a relevant prognostic indicator for patients with PTC.

#### 414 Fractional Allelic Loss Can Assist in Differentiating Benign from Malignant Parathyroid Neoplasia

*JL Hunt, J Murphy, EL Barnes.* University of Pittsburgh, Pittsburgh, PA.

**Background:** The diagnosis of parathyroid malignancy can be difficult and may rest on identifying subtle histologic changes and obtaining surgical correlation. There have been no absolute markers reported that can predict malignancy. This study uses fractional allelic loss (FAL) across a series of tumor suppressor genes to sub-classify primary parathyroid disease based on mutation rates.

**Design:** Primary parathyroid diseases, including adenoma (4 cases), atypical adenoma (4 cases), primary hyperplasia (5 cases) and carcinoma (2 cases) were included. All cases had clinical follow-up available. The diagnosis was made based on clinical and histopathologic factors (gross local invasion, vascular invasion, capsular invasion, fibrosis, increased and atypical mitoses). Fluorescence based PCR and semi-quantitative capillary electrophoresis were used to assess 20 different short tandem repeat loci that co-localize with 14 known tumor suppressor genes. Ratios of the peak heights in heterozygous cases were compared between normal and tumor and those with >30% loss were scored as allelic imbalance.

**Results:** The average number of informative loci was 12.5. All cases had at least one locus with allelic loss. Average allelic loss was 7% for adenomas, 27% for atypical adenomas, 59% for carcinomas, and 21% for hyperplasia. Loss of 1p was present in every case. Other gene loci with high frequency of allelic loss were loci on 7p (MET gene, 7q31) at 67%, and on 10q (PTEN gene, 10q23) at 55%.

**Conclusions:** There are significant differences in the mean FAL between the various categories of neoplasia, which is especially evident between adenoma (7%) and carcinoma (59%). Borderline malignant lesions that were diagnosed as "atypical adenoma", due to conflicting histologic and clinical data, were intermediate in their mean FAL (27%). These results indicate that molecular profiling may be a useful adjunctive test in the diagnosis of parathyroid neoplasia, and especially so for cases that have conflicting histologic and clinical data.

#### 415 Allelic Imbalance in Sporadic and Syndromic Pheochromocytomas: Implicating the PTEN Gene Locus

*JL Hunt, J Murphy.* University of Pittsburgh, Pittsburgh, PA.

**Background:** Pheochromocytomas are unusual tumors that can be associated with hereditary syndromes or can arise sporadically. Predicting malignancy is difficult, and ultimately relies upon the presence of metastatic disease. Our understanding of the genetic profiles of pheochromocytomas has centered primarily around chromosome 3p25 (VHL locus) and chromosome 11q13 (MEN 1 gene locus). Other important tumor suppressor gene loci have not been investigated in pheochromocytomas.

**Design:** Sporadic (9 cases) and syndromic (10 cases) pheochromocytomas were included. All cases had clinical follow-up available. Fluorescence based PCR and semi-quantitative capillary electrophoresis were used to assess 19 different short tandem repeat loci that co-localize with 13 known tumor suppressor genes. Ratios of the peak heights in heterozygous cases were compared between normal and tumor and those with > 30% loss were scored as allelic imbalance. An additional five markers (the NCI-recommended panel) were utilized to assess for microsatellite instability.

**Results:** Syndromic pheochromocytomas had significantly lower mean fractional allelic loss (FAL) at 36% than that in sporadic pheochromocytomas, at 63% (p<.019). A high frequency of allelic loss was seen for the markers co-localizing with the PTEN gene (from 50-60%). Microsatellite instability was very rare, occurring in only 5 cases, and it did not affect the genes in the NCI panel, but was seen in other dinucleotide repeats. Loss of 3p and 11p were present in the majority of the cases in this series.

**Conclusions:** There is a significantly higher rate of allelic imbalance in sporadic pheochromocytomas than in syndromic tumors. This observation suggests that tumor suppressor gene inactivation is not widespread in syndromic tumors, but is prevalent during tumorigenesis for sporadic tumors. Given the fact that patients with hereditary syndromes have a germline mutation, the onset of tumorigenesis may occur via a simple pathway of biallelic inactivation of just one gene. The significance of allelic imbalance of the PTEN, the VHL, and the MEN 1 genes in both sporadic and hereditary tumors is not known, but may provide additional insight into pathogenesis of these unusual tumors.

#### 416 Type IV Collagen Immunostaining Provides a Simple, Reliable Way To Distinguish between Adenoma and Normal Pituitary

*JA Jarzembowski, RV Lloyd, PE McKeever.* University of Michigan Hospitals and Clinics, Ann Arbor, MI; Mayo Clinic, Rochester, MN.

**Background:** Pituitary adenomas are clinically diagnosed by radiologic studies and/or secondary effects of hormone production. Definitive pathologic diagnosis relies on immunostaining to detect a clonal population of hormone-producing cells. However, not all pituitary adenomas produce hormones and in these cases, diagnosis is more tenuous, especially for a general pathologist. Also, ordering a battery of hormone stains to find one (or no) clonally produced hormone is an inefficient use of time and laboratory resources. Published reports have shown decreased expression of type IV collagen in the stroma of epithelial tumors such as colorectal adenocarcinoma, ameloblastoma, and bile duct carcinoma. Our preliminary investigations suggested that pituitary adenomas have less type IV collagen in their basement membranes than their benign counterparts.

**Design:** We performed type IV collagen immunostaining on 50 pituitary specimens. Each author independently reviewed the slides from each case. H&E-stained slides were first used to identify fragments of anterior pituitary and potential adenoma, which were then evaluated on the immunostained slides. Areas with the sparsest type IV collagen fibers were viewed under three different magnifications (10, 20, and 40X), counting 1, 3, or 10 microscopic fields. A field was scored as "traversable" if a

path existed from any point on the periphery of the field to a point on the opposite side that did not cross any stained fibers. Results were compared to the existing pathologic diagnosis previously determined with hormone immunostaining and clinical correlation.

**Results:** Pituitary adenomas have less stainable collagen IV in their basement membranes than benign glands, leading to sparse, trabecular staining in adenomas and a more rigid, meshwork pattern in normal glands. One way of considering these patterns is to envision the type IV collagen-stained fibers as the walls of a maze - one can traverse medium-powered fields in an adenoma, but continually gets trapped in the dead-ends of a normal gland. The most consistent results were obtained by evaluating a single field of type IV collagen-immunostained anterior pituitary fragments at 10X magnification. Under these conditions, finding the field to be traversable was 98.2% sensitive and 100% specific for an adenoma.

**Conclusions:** Type IV collagen immunostaining is an easy, inexpensive, and reliable method to distinguish between normal pituitaries and adenomas.

#### 417 Double Adenomas of the Pituitary: Transcription Factors Pit-1, T-pit, and SF-1 Identify Cytogenesis and Differentiation

*RA Jastania, KO Alsaad, K Kovacs, SL Asa.* University Health Network, University of Toronto, Toronto, ON, Canada; St. Michael's Hospital, University of Toronto, Toronto, ON, Canada.

**Background:** The diagnosis of double or multiple adenomas in the pituitary gland can be very complex. Surgically and grossly, it is difficult to appreciate multiplicity of a lesion due to fragmentation of specimens that are often mixed with blood. The diagnosis of multiple adenomas can be suspected on histological assessment of a specimen and is usually confirmed by immunohistochemical and ultrastructural studies. However, this approach requires extensive evaluation, and failure to suspect or evaluate this possibility may explain the much lower number of double adenomas detected in surgical specimens compared with autopsy series.

**Design:** We examined 14 paraffin-embedded tissue blocks from the pituitaries of eight patients diagnosed with double adenomas over a 15-year period (1989-2004). The adenomas were characterized by histology, hormonal profile using immunohistochemistry, and ultrastructural studies. We tested the ability to detect the difference in the two adenomas in each case using three immunostains for pituitary transcription factors, Pit-1, T-pit and SF-1.

**Results:** The 5 female and 3 male patients ranged in age from 23 to 80 (average 55 years). One patient had discrete lactotroph and somatotroph adenomas that were both positive for Pit-1. Three patients had adenomas containing prolactin and ACTH. There was discrete expression of Pit-1 and T-pit in the individual adenomas. Two patients had a silent corticotroph adenoma associated with a separate adenoma containing growth hormone/prolactin/TSH; the former expressed T-pit and the latter contained Pit-1. Two patients had gonadotroph and silent ACTH adenomas and again each tumor contained the appropriate transcription factor, either SF-1 or T-pit.

**Conclusions:** Using immunohistochemical localization, the transcription factors Pit-1, T-pit and SF-1 are useful to detect multiple adenomas of the pituitary. The use of these markers allows accurate classification of the cytodifferentiation of pituitary tumor cells.

#### 418 Bilateral Adrenal Myelolipomas: Association with Adrenal Cortical Hyperplasia and Congenital Syndromes

*D Koutsogiannis, RH Young, CA Meier, M Bongiovanni, JC Pache, WC Faquin.* University of Western Ontario, London, ON, Canada; Massachusetts General Hospital, Boston, MA; University Hospital Geneva, Geneva, Switzerland.

**Background:** Myelolipomas of the adrenal gland are rare benign tumors composed of hematopoietic elements and adipose tissue. Rarely, these tumors can be bilateral, and while the pathogenesis for these lesions is poorly understood, some evidence suggests that adrenocortical hyperfunction could be a significant etiologic factor, especially in bilateral cases. Here, we present a series of 46 cases of myelolipoma of which 3 adrenal cases were bilateral, and one case was associated with congenital 11-beta hydroxylase deficiency.

**Design:** Forty-six cases of myelolipoma were identified from the archival files of the Massachusetts General Hospital between 1977 and 2004. Of these, 3 cases represent bilateral adrenal myelolipomas which served as the focus of this study. Correlation of clinicopathologic information including evidence of endocrine dysfunction and histologic findings were made.

**Results:** Forty-six myelolipomas from 21 men and 20 women with a mean age of 60 yrs (range: 15-104 yrs) were identified arising in the adrenal (N=27), retroperitoneum (N=8), uterus (N=3), bone (N=1), colon (N=1), and mediastinum (N=1). Unilateral myelolipoma cases were associated with clinical hypertension, obesity, diabetes, as well as chronic illnesses; 29% of cases were incidental findings. Three of the 46 cases were bilateral adrenal tumors from 2 men and 1 woman. All 3 bilateral cases were associated with adrenal cortical hyperplasia, and one of the bilateral cases is the first example from a patient with congenital 11-beta hydroxylase deficiency. Microscopically, the bilateral tumors were composed of 20-60% adipose tissue and all 3 contained trilineage hematopoietic cells. In one case, the myelolipoma presented as discrete bilateral nodular masses within the adrenal glands, while in two cases the involvement was diffuse and included a lymphoid infiltrate within the cortical parenchyma.

**Conclusions:** Myelolipomas are uncommon tumors that can rarely present bilaterally within the adrenal gland. In our study, all 3 bilateral myelolipomas were associated with adrenocortical hyperplasia supporting a possible etiologic role in the pathogenesis of this lesion.

**419 A CREB3L2-PPARG Fusion Oncoprotein with Unique Activities in Thyroid Cancer**

W Lui, S Deshpande, P Michalewicz, I Leibiger, B Leibiger, S Thoppe, U Enberg, J Liden, A Hoog, L Farnebo, J Fletcher, C Larsson, T Kroll. Karolinska Hospital, Stockholm, Sweden; Emory University, Atlanta, GA; University of Chicago, Chicago, IL; Brigham and Women's Hospital, Boston, MA.

**Background:** Few fusion oncoproteins formed by gene rearrangements have been identified in human carcinomas and thus their roles in epithelial cell transformation and their resemblance to fusion proteins in non-carcinomas are incompletely defined. Characterization of different chromosomal translocations in gene rearrangement families has consistently defined new mechanisms of oncogenesis. Human thyroid cancer is unique because it is the only adult carcinoma in which multiple gene rearrangement families have been identified

**Design:** Achromosomal rearrangement, t(3;7)(p25;q34), in human thyroid follicular carcinoma was mapped by fluorescence in situ hybridization and the expressed fusion mRNA transcript was cloned by rapid amplification of cDNA ends. The structural and functional properties of this novel human fusion oncoprotein were examined.

**Results:** t(3;7)(p25;q34) in thyroid follicular carcinoma resulted in fusion of the cAMP responsive element binding protein 3-like 2 (CREB3L2) to the peroxisome proliferator-activated receptor gamma (PPARG) genes. CREB3L2 is a BZIP transcription factor and PPARG is a nuclear receptor. The encoded CREB3L2-PPARG fusion protein contains the identical PPARG1 domains as the PAX8-PPARG fusion protein identified previously in thyroid follicular carcinoma. The CREB3L2-PPARG fusion protein contains the transactivation domain of CREB3L2, whereas the FUS-CREB3L2 fusion protein identified recently in human fibromyxoid sarcoma contains the CREB3L2 DNA binding domain. Both CREB3L2-PPARG and PAX8-PPARG stimulated the growth of immortalized human thyroid follicular cells in vitro but they differed markedly in their ability to stimulate transcription from classic PPARG reporters. CREB3L2-PPARG stimulated transcription from PPARG reporters at levels greater than wild-type PPARG whereas PAX8-PPARG had little effect.

**Conclusions:** Our experiments: (1) demonstrate that a family of PPARG rearrangements exists in thyroid follicular carcinoma, (2) further implicate CREB3L2 pathways in human oncogenesis, (3) show that the activities of PPARG fusion proteins are influenced by their non-PPARG domains, and (4) demonstrate that a primary mechanism of growth stimulation by PPARG fusion proteins in thyroid cancer is independent of classic/known PPARG functions.

**420 Study on the Expression of Pituitary Tumor-Transforming Gene (PTTG) in Human Pituitary Adenomas by Real Time RT-PCR and Immunohistochemistry**

T Minematsu, M Yamazaki, S Takekoshi, S Miyai, N Sanno, A Teramoto, RY Osamura. Tokai University School of Medicine, Kanagawa, Japan; Nippon Medical School, Tokyo, Japan.

**Background:** Pituitary tumor-transforming gene (PTTG) has been isolated from rat pituitary adenoma cells by Pei and Melmed (1997). There are three subtypes of PTTG in human, and PTTG1, a peptide of 202 amino acids, has been proved to be overexpressed in pituitary tumors and associated with invasiveness. This study was aimed at to analyze the expression of PTTG1 in human functioning and non-functioning pituitary adenomas and compared with normal pituitary tissues.

**Design:** The tissues from total 92 cases of surgically resected human pituitary adenomas were subjected to real time RT-PCR and compared with that from the 4 cases of normal human pituitary cDNA purchased from Biochain. The tumors include 41 functioning adenomas (21 GHomas, 12 PRLomas, 4 ACTHomas, 3 TSHomas and an FSHoma) and 51 non-functioning adenomas. Immunohistochemistry was also performed by anti-PTTG antibody (Zymed) on formalin fixed paraffin sections of 36 cases of functioning adenomas, 43 cases of non-functioning adenomas and 7 autopsy samples.

**Results:** All pituitary adenomas showed mRNA expression of *pttg1* by real time RT-PCR, and average of functioning adenomas and non-functioning adenomas were 21.66±105.36 and 849.21±5693.23, respectively (mean±SD). Although the difference in the amount of mRNA among these human pituitary adenomas was not statistically significant, the expression of *pttg1* mRNA was higher than that of the normal pituitary tissues (0.56±0.09). When the normal range of *pttg1* expression was defined as mean±2SD of normal pituitary tissue, *pttg1* was overexpressed in 65.85% of functioning adenomas and 48.0% of non-functioning adenomas. PTTG1 was detected in the cytoplasm of most adenomas and normal tissues by immunohistochemistry. The immunoreactivity was stronger in adenomas compared with normal tissue, and correlated with the result by real time RT-PCR.

**Conclusions:** These results indicate that PTTG1 is more frequently and strongly expressed in most of human pituitary adenomas, and suggested some roles of PTTG1 in human pituitary tumorigenesis.

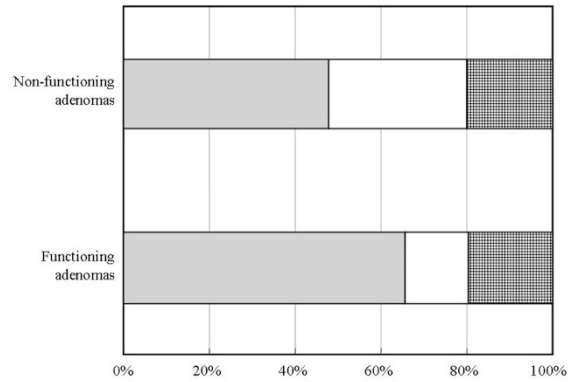


Figure 1 Expression of *ptg1* mRNA in human pituitary adenomas analyzed by real time RT-PCR

**421 Mutation Analysis of the Succinate Dehydrogenase Subunits SDHB, SDHC and SDHD in Sporadic and Familial Medullary Thyroid Carcinoma**

M Montani, S Schmid, T Locher, P Komminoth, A Perren. University Hospital, Zurich, Switzerland; Institute for Pathology, Baden, Switzerland.

**Background:** Medullary thyroid carcinomas (MTC) share certain similarities with pheochromocytomas regarding morphology, immunohistochemical expression patterns and molecular markers. Both tumors exhibit activating *Ret* mutations and are part of the MEN2 phenotype. Recently, germline mutations of the mitochondrial complex II subunits *SDHB*, *SDHC* and *SDHD* were identified in patients with familial pheochromocytomas and paragangliomas. The genes are located on the chromosomal bands 1p35-36, 1q21 and 11q23, regions which are lost in a subset of MTC. Additionally, the *SDHD* germline variant H50R in exon 2 was described in six members of a family with non-RET-associated C-cell-hyperplasia. We therefore decided to examine sporadic and familial MTC for mutations and deletions of the tumor suppressor genes *SDHB*, *SDHC* and *SDHD*.

**Design:** We examined 35 MTC (10 familial and 25 sporadic) as well as 80 normal controls for alterations in all *SDH*- genes by PCR / DGGE, direct sequencing and LOH analysis.

**Results:** No mutations of *SDHB*, *SDHC* and *SDHD* were detected any of the tumors tested. LOH of *SDHB* locus was detected in 30% of MTC, only one tumor (4%) showed LOH of the *SDHD* locus. However, coding polymorphisms of *SDHB* (S163P) and *SDHD* (G12S, H50R) were more frequent in patients with familial and sporadic MTC.

Polymorphisms of SDHD, SDHC and SDHB	SDHB 2	SDHB 2	SDHB 5	SDHC 3	SDHD 1	SDHD 2
Exon	ivs2+33A>G	ivs2+35G>A	S163P	ivs2-39T>C	G12S	H50R
sporadic MTC	4/40 (10%)	1/40 (3%)	1/36 (3%)	1/42 (2%)	0/46	2/46 (4%)
familial MTC	2/16 (13%)	1/16 (6%)	1/16 (6%)	0/20	1/24 (4%)	1/20 (5%)
Control	8/68 (12%)	3/68 (4%)	0/72	0/74	0/166	1/166 (1%)

**Conclusions:** In contrast to pheochromocytomas/paragangliomas, mutations of *SDHD*, *SDHB* and *SDHD* are not an important event in MTC. Familial MTC are associated with an increased rate of germline polymorphisms in the *SDH*-genes and further studies are needed to assess whether these polymorphisms have a disease modifying aspect regarding development of MTC or other MEN2 associated tumors.

**422 RASSF1A Methylation and BRAF Mutation in Thyroid Tumors**

N Nakamura, JA Carney, L Jin, LA Erickson, H Zhang, RV Lloyd. Mayo Clinic, Rochester, MN.

**Background:** The RAS-association domain family 1(RASSF1A) is a tumor suppressor gene which is inactivated by methylation in various tumors. BRAF mutations are highly specific for papillary thyroid carcinoma (PTC) and are not commonly seen in benign thyroid tissues. Hyalinizing trabecular tumors (HTT) share nuclear cytologic features with PTC. However, the molecular relationship between PTC and HTT remains uncertain.

**Design:** A total of 76 thyroid tumors and 42 normal thyroid tissues were analyzed for RASSF1A gene methylation by methylation specific PCR (MS-PCR) and for BRAF mutations by PCR and DNA sequencing using fresh frozen and paraffin-embedded tissue sections. The tumors included PTC, HTT, anaplastic thyroid carcinoma (ATC) and follicular adenoma (FA).

**Results:**

Diagnosis	N	RASSF1A Methylation (%)	BRAF Mutation (%)
Normal thyroid	42	0	0
PTC	42	32	38
HTT	23	25	0
FTC	5	100	0
ATC	2	100	50
FA	4	25	0

N = number of cases

**Conclusions:** Methylation of the RASSF1A gene is present in benign and malignant thyroid tumors indicating an early event in thyroid tumorigenesis. BRAF mutations are largely restricted to PTC. Although some HTT have methylation of RASSF1A, BRAF mutations were not present in HTT.

#### 423 Bcl-2 Downregulation at RNA and Protein Level in Papillary Thyroid Carcinoma Is Associated with Methylation of Bcl-2 DNA Promoter Region

*M Nassiri, C Solorzano, G Irvin, M Nadji.* University of Miami/Jackson Memorial Hospital, Miami, FL.

**Background:** We have previously observed lower expression of bcl-2 in papillary thyroid cancers using cDNA microarray. This study is now designed to validate microarray result and to investigate role of DNA methylation.

**Design:** Paired normal thyroid and neoplastic (papillary thyroid carcinoma, PTC) samples from the same patients (n=19) were studied. Real-time PCR was performed from total RNA isolated from morphologically verified fresh samples. Paraffin block immunohistochemistry for Bcl-2 was performed on adjacent tissue fixed in formalin. DNA was isolated from fresh samples and DNA methylation studies were performed after bisulfite modification for DNA and PCR for promoter region as well as a predicted CpG island outside the promoter region.

**Results:** Bcl-2 was significantly down-regulated in PTC compared to normal tissue, both at the RNA level (average copy number/microgram RNA normal=  $8.4 \times 10^3$  vs tumor=  $2.2 \times 10^3$  p<0.005) and the protein level (average IHC score normal=3 tumor=1.2 p<0.05). DNA methylation of promoter region was found only in tumor samples (70%). In contrast, CpG island methylation was much less frequent in tumor samples (42%) and was also observed in normal samples (27%).

**Conclusions:** Bcl-2 gene expression is dramatically suppressed in papillary thyroid carcinomas at RNA and protein levels compared to their matched normal tissue. This might be due to bcl-2 promoter methylation.

#### 424 Immunohistochemical Study of Tumor Angiogenic Factors in Human Pituitary Adenomas

*M Niveiro, FI Aranda, G Peiró, C Alenda, A Payá, FM Peiró, A Picó.* Hospital General Universitario, Alicante, Spain.

**Background:** Several investigators have studied microvessel density (MVD) in a number of neoplasias to determine the relationship between angiogenesis and tumor behaviour. However, the role of angiogenesis in endocrine tumors is not fully elucidated.

**Design:** To investigate MVD and VEGF/Flk-1 expression in pituitary adenomas, we selected 60 cases: 13 GH, 7 PRL, 5 ACTH, 2 TSH, and 33 non-functioning adenomas (30 gonadotroph and 3 null cell). We performed immunohistochemistry (IHC) for CD34, Ki-67, VEGF and Flk-1. For MVD, two methods were used: the number of vessels per mm<sup>2</sup> and the Chalkley method. Expression of VEGF and Flk-1 was evaluated assessing the percentage of positive cells and the intensity of staining (1-3+). The IHC results were correlated, as well as with clinical-pathological factors.

**Results:** Patients age ranged from 15 to 83 years (mean 51); 30 males and 30 females; 44 (73.3%) had extrasellar extension. Adenomas with higher MVD were TSH adenomas (299.9±87.5) and those with lower were prolactinomas (168.6±63.3, p=0.43, Anova). We found a trend toward higher MVD in older patients (<50 years old 211.1±78.7 vessels/mm<sup>2</sup> and ≥50 249.7±120.6; p=0.142), but no difference were found with sex (p=0.91), extrasellar extension (p=0.30) or Ki67 (r=-0.12 p=0.35, Pearson correlation). However, extrasellar extension was nearly significant when the Chalkley method score was high (p=0.056, chi-square). The levels of VEGF score ranged from 0 to 300 (mean 70.8±71.3). Low expression was seen predominantly in prolactinomas (15.7±28.2), and high in non-functioning adenomas (94.7±82.2; p=0.032, Anova), as well as in cases of older patients (<50= 48.9± 52.2, ≥50 95.6± 82.2, p=0.010, t-Student). Nevertheless, no statistical difference were seen with gender, extrasellar extension, proliferative activity, MVD, or by Chalkley method. Regarding Flk-1 score ranged from 0 to 285 (mean 104.8±80.2), which correlated with the levels of VEGF (r=0.35; p=0.006, Pearson). High expression were observed in non-functioning adenomas (mean:138.6 ±75.8; p=0.003, Anova), cases presenting at older ages and with extrasellar extension, but no differences were found regarding gender, Ki-67 or MVD.

**Conclusions:** VEGF and Flk-1 are widely expressed in pituitary adenomas, predominantly in non-functioning adenomas and those presenting at older ages. Moreover, Flk-1 is associated with more aggressive phenotype, since it is present in cases with extrasellar extension.

#### 425 p63 Expression in Carcinoma Showing Thymus-Like Differentiation of the Thyroid (CASTLE): Evidence of Thymic Differentiation and Solid Cell Nest Origin

*JD Reimann, DM Dorfman, V Nosé.* Brigham and Women's Hospital and Harvard Medical School, Boston, MA.

**Background:** Different isoforms of p63, a transcription factor belonging to the p53 gene family, have specific functions, including transactivation, apoptosis, oncogenesis and maintenance of stem cell phenotype. The p63 isoform preferentially expressed in the epithelial basal cells of different organs is considered a marker of stem/reserve cells, and is consistently expressed in thyroid solid cell nests. Carcinoembryonic antigen (CEA) is also expressed in thyroid solid cell nests. CASTLE, a rare intrathyroidal epithelial neoplasm with evidence of thymic differentiation, is a member of a family of tumors that arises from ectopic thymus, vestiges of thymopharyngeal duct, or branchial pouch remnants present in soft tissue of the neck or within the thyroid gland, including in the latter, remnants of the fourth/fifth branchial pouch (ultimobranchial body). We compared p63 staining of thyroid solid cell nests with that of thyroid carcinomas and CD5-positive, CEA-positive CASTLE to determine whether these neoplasms are related or derived from solid cell nests.

**Design:** We performed p63 immunohistochemical staining of paraffin-embedded tissue sections of normal thyroid with solid cell nests (5 cases), thyroid follicular hyperplasia (10 cases) and follicular neoplasms, including follicular carcinoma (10 cases), thyroid papillary carcinoma (10 cases), CASTLE (9 cases) and thymic carcinoma (5 cases).

**Results:** In normal thyroid tissue, only solid cell nests exhibited nuclear staining for p63. C-cells and follicular cells were negative for p63, as were epithelial cells in cases of thyroid follicular hyperplasia and carcinoma and papillary carcinoma, with rare cases showing only focal positivity in foci of squamous metaplasia. In contrast, all cases of CASTLE and thymic carcinoma exhibited intense and diffuse p63 staining within the epithelial component of the tumor.

**Conclusions:** These findings, in addition to prior CD5 immunostaining, provide further evidence that CASTLE is distinct from other thyroid neoplasms and is likely of thymic origin. CEA and p63 staining in CASTLE raises the possibility that CASTLE may arise from remnants of branchial pouch, the thyroid solid cell nests.

#### 426 Thyroid Tissue within Cervical Lymph Nodes: Benign Thyroid Inclusions or Metastasis from Occult Thyroid Cancer?

*AG Saad, PW Biddinger, RV Lloyd, YE Nikiforov.* University of Cincinnati, Cincinnati, OH; Mayo Clinic, Rochester, MN.

**Background:** The existence of benign thyroid inclusions in cervical lymph nodes is not universally accepted. However, when small foci of thyroid tissue showing no or only some nuclear features of papillary thyroid carcinoma (PTC) are found in lymph nodes removed during neck dissection for non-thyroid malignancies, the diagnosis is difficult and has significant clinical and prognostic implications. The aim of this work was to quantitate the nuclear features of PTC and evaluate the role of galectin-3 and HBME-1 immunostains in distinguishing metastatic thyroid cancer from benign thyroid inclusions.

**Design:** We studied 2 groups of lymph nodes. Group I consisted of 38 known metastatic PTC (31 cases of classic papillary and 7 follicular variants of PTC). Group II included 12 cases of radical neck dissection for non-thyroid neoplasia in which small foci of intranodal thyroid tissue were identified. Six distinct nuclear features of PTC were scored in each case: nuclear enlargement, nuclear overlapping, irregularity of nuclear contours, clearing of chromatin, intranuclear pseudoinclusions and nuclear grooves. 3+ score was given when 5-6 nuclear features were present, 2+ for cases with 3-4 features, and 1+ for those with ≤ 2 features. Immunostains were performed with antibodies against HBME-1 (Dako, 1:80) and galectin-3 (Novocastra, 1:100).

**Results:** In Group I, 28 cases (74%) showed 3+ and 10 cases (26%) showed 2+ nuclear score. In Group II, 4 cases (33.3%) showed 3+, 4 cases (33.3%) showed 2+ and 4 cases (33.3%) showed 0-1+ score. HBME-1 and galectin-3 were positive in all cases (100%) in Group I. In Group II, HBME-1 and galectin-3 were positive in 8 cases (72%), all with either 3+ or 2+ nuclear score. All 4 cases from this group with available follow-up revealed the presence of PTC on subsequent thyroid surgery. The remaining 4 cases with 0-1+ nuclear score were all negative for both HBME-1 and galectin-3.

**Conclusions:** We demonstrate that in a control group, HBME-1 and galectin-3 immunostains have a 100% sensitivity in the detection of PTC metastatic to lymph nodes. We also show a good correlation between the presence of nuclear features of PTC and HBME-1 and galectin-3 positivity when at least 3 nuclear features are present. The finding of 4 cases of thyroid tissue with minimal or no nuclear features of PTC which were negative for both immunostains support the notion that benign thyroid inclusions may exist within the cervical lymph nodes.

#### 427 The Pituitary in Klinefelter Syndrome

*BW Scheithauer, M Moschopoulos, Ö Kurtkaya-Yapicier, K Kovacs, BS Jhaveri, T Percek, RV Lloyd.* Mayo Clinic, Rochester, MN; Marmara University, Istanbul, Turkey; St. Michael's Hospital, University of Toronto, Toronto, ON, Canada; St. John's Hospital, Springfield, IL.

**Background:** Klinefelter syndrome (KS) is due to a genetic defect (XXY karyotype). The testes are small, blood testosterone levels are low, and blood FSH/LH levels are elevated. Pituitary changes in patients with KS have not been evaluated in detail. Herein, we described the immunohistochemical changes in the pituitaries of three patients.

**Design:** The first patient, a 76-year-old man, was operated for a large sellar mass. The second and third patients, 62 and a 52 year-old men, died of cardiac failure. The glands were evaluated for hormone immunoreactivity by the ABC method with GH, PRL, ACTH, LH/FSH, TSH, and alpha subunit directed antibodies.

**Results:** In the non-tumorous portion of the gland, immunoreactivity for all hormones but LH/FSH appeared normal. Acini were normal. The only alteration was a mild increase in gonadotrophs. Of these, some were vacuolated and resembled the "gonadal deficiency" cells as seen in the pituitaries of humans with gonadal failure and in castrated rats.

One of the two microadenoma found measured 8 mm in largest diameter. Its cells were chromophobic, PAS-negative and FSH/ LH immunopositive. Mitotic figures were lacking. In another gland a minute GH-positive adenoma was found.

**Conclusions:** Few studies of morphologic changes in the pituitaries of patients with KS have rarely been reported. Most antedated the immunohistochemical era. Using hematoxylin-eosin, PAS and various trichrome stains, cells interpreted as gonadotrophs were often increased in number. "Gonadal deficiency cells" were also described, as were pituitary adenomas. In other instances no alterations were found. Pituitary adenomas are known to occur more frequently in rodents and in humans with primary target gland failure, such as protracted hypothyroidism, hypoparathyroidism, and hypogonadism. The tumors appear to be due to the loss of negative feedback effect in that chronic stimulation of adeno/hypophysial cells results in hyperplasia which in turn appears to give rise to adenomas. Whether LH/FSH adenomas in KS are



due to chronic androgen deficiency or to the genetic abnormality per se remains to be elucidated. Molecular genetic studies are required to obtain deeper insight into the pathogenesis of pituitary tumors in patients with this disorder.

#### 428 CEACAM1 Is Expressed by Human Thyroid Carcinoma Cells and Represents a Target for Vitamin D<sub>3</sub> Therapy

W Wei, W Liu, D Winer, AM Bamberger, S Ezzat, SL Asa. University Health Network, University of Toronto, Toronto, ON, Canada; University Hospital, University of Hamburg, Hamburg, Germany; Mount Sinai Hospital, University of Toronto, Toronto, ON, Canada.

**Background:** CEACAM1, formerly known as biliary glycoprotein, CD66a, C-CAM1 and pp120, is a member of the CEA immunoglobulin superfamily. CEACAM1 is a putative tumor suppressor based on its diminished expression in some tumors including colon carcinoma. However, CEACAM1 is also over-expressed in tumors such as non-small cell lung cancer. The role of CEACAM1 in thyroid tissue remains unknown.

**Design:** In the present study we investigated the expression of CEACAM1 in thyroid tissue and tumor cell lines, and its relationship to thyroid cell growth and adhesion. Since Vitamin D (VD) and its analogues, EB1089 and KH1060 are known to inhibit thyroid cancer cell growth, we examined the effect of these compounds on the expression of CEACAM1 in thyroid cancer.

**Results:** Using a tissue array of primary human thyroid samples, CEACAM1 was identified in a subset of papillary carcinomas that had lymph node metastases and in poorly-differentiated and anaplastic carcinomas. There is a marked apical luminal localization of CEACAM1 in differentiated thyroid carcinomas that is dysregulated in dedifferentiated malignancies. No expression was found in normal thyroid tissue or benign tumors however there was focal staining in atypical cells of chronic lymphocytic thyroiditis. CEACAM1 is expressed by the aggressive ARO (anaplastic) and MRO (follicular) carcinoma cell lines but not in the papillary carcinoma cell lines TPC-1 and NPA as determined by multiple techniques. Treatment of ARO and MRO cells with VD and its analogues, EB1089 and KH1060, significantly decreased CEACAM1 levels, reduced S-phase entry, and up-regulated p27 protein accumulation.

**Conclusions:** These findings suggest that CEACAM1 is expressed in a more aggressive group of thyroid malignancies where it may play a role in architecture, stromal interactions and metastasis. It represents a target for VD therapy which modulates its expression and may have potential therapeutic applications.

#### 429 Significance of GLUT-1 Expression in Thyroid Gland Tumors: Its Availability for Discrimination between Papillary Carcinoma and Follicular Carcinoma

M Yasuda, H Kajiwara, N Ogane, Y-I Kameda, K-I Tsukinoki, YR Osamura. Tokai University School of Medicine, Isehara, Kanagawa, Japan; Kanagawa Cancer Center, Yokohama, Kanagawa, Japan; Kanagawa Dental College, Yokosuka, Kanagawa, Japan.

**Background:** Glucose transporter-1 (GLUT-1), one of GLUT isoforms, has been demonstrated to play a role in facilitating effective transportation of glucose. It is well known that GLUT-1 expression is associated with an increased uptake of glucose during malignant transformation. The purpose of this study focused on clarifying whether GLUT-1 would be useful in discriminating between papillary carcinoma and follicular carcinoma and whether it would be a biological marker associated with a tumor development.

**Design:** Materials: Two hundred and sixty-five thyroidectomy specimens used were composed as follows: papillary carcinoma, 126 cases; follicular carcinoma, 60 cases; follicular adenoma, 57 cases; adenomatous goiter, 22 cases. Tissue blocks were routinely processed for histological diagnosis. Methods: Immunohistochemical expression GLUT-1 (DAKO, polyclonal, rabbit, diluted at 1:50) was studied using an indirect peroxidase method. More than 10% of immunoreaction was regarded as positive.

**Results:** GLUT-1 expression was observed in 71% (89/126) of papillary carcinomas and 5% (3/60) of follicular carcinomas. Follicular adenomas and adenomatous goiters failed to show positive reaction. Strong expression on the cell membrane was limited to 24 cases of papillary carcinoma. Among them, 92% (22/24) developed the metastatic disease in the regional lymph nodes. There was no tendency that the expression was strengthened according to an increase of tumor size.

**Conclusions:** GLUT-1 is considered to be related to a tumor development of papillary carcinoma and is also helpful in discriminating between papillary carcinomas and follicular carcinomas. GLUT-1 overexpression on the cell membrane may demonstrate an aggressive biological behavior of papillary carcinomas, resulting in lymph node metastasis.

#### 430 Stromal Cell-Derived Factor-1 Expression in Malignant Thyroid Neoplasms of Follicular Cell Origin and in Atypical Foci in Hashimoto's Thyroiditis

SF Zaidi, J Liu, DS Zander. University of Texas Health Science Center at Houston Medical School, Houston, TX.

**Background:** The alpha-chemokine stromal cell-derived factor-1 (SDF-1) and its receptor CXCR4 have been recognized for their roles in stem cell trafficking, and recent data suggests that the CXCR4/SDF-1 pathway may also be important for regulating tumor metastasis. Little information exists regarding the role of SDF-1 in thyroid neoplasia.

**Design:** Formalin-fixed paraffin-embedded recut sections of 16 normal thyroid glands, 15 multinodular goiters, 11 cases of Hashimoto's thyroiditis, 14 follicular adenomas, 2 follicular carcinomas, 16 papillary carcinomas, and 2 anaplastic carcinomas were immunostained for SDF-1 (1:25, R&D Systems) using standard avidin-biotin techniques. As appropriate for the process, the percentage of tumor cells or non-

neoplastic follicular cells that demonstrated immunoreactivity for SDF-1 was scored as follows: 0=<10%, 1=10-50%, 2=>50%. A positive stain was defined as 10% or more immunoreactivity. Staining intensity was graded as 0 (negative), 1+ (weak), 2+ (moderate), or 3+ (strong).

**Results:** SDF-1 staining was observed in 12/16 papillary carcinomas, 1/2 follicular carcinomas, and 2/2 anaplastic carcinomas, while only 1/45 benign processes, a partially infarcted follicular adenoma, demonstrated immunoreactivity. 8/11 examples of Hashimoto's thyroiditis showed SDF-1 expression in atypical microscopic foci consisting of cells with incomplete morphologic features of papillary carcinoma and/or Hurthle cell-like features, in most cases accounting for 10-20% of follicular cells in the section. Statistical analysis of SDF-1 staining in malignant neoplasms of follicular cell origin revealed sensitivity=75.0%, specificity=97.8%, PPV=93.8%, NPV= 89.8%.

**Conclusions:** SDF-1 is a highly specific marker of malignant neoplasms of follicular cell origin that may be useful for supporting a malignant interpretation. Focal SDF-1 staining, however, should be interpreted with caution in a setting of Hashimoto's thyroiditis. The expression of SDF-1 in Hashimoto's thyroiditis correlates with abnormal histopathologic features and parallels published descriptions of RET immunoreactivity in atypical foci in Hashimoto's thyroiditis (*Am J Pathol* 2002,160:2157-2167). The relationship of these foci to thyroid carcinogenesis merits further investigation.

## Gastrointestinal

#### 431 Genetic Interactions and Histologic Associations of NOD2, DLG5, OCTN1 and OCTN2 Polymorphisms in Ileal Crohn's Disease

DW Abbott, RD Odze, LC Cantley, M Redston. Brigham and Women's Hospital, Boston, MA; Harvard Medical School, Boston, MA.

**Background:** Crohn's Disease (CD) develops as a result of an inappropriate immune response to normal bacterial flora of the intestine. To date, four genes (DLG5, NOD2, OCTN1 and OCTN2) that harbor relatively common polymorphisms have been implicated in both familial and sporadic CD. Linkage studies have implicated seven separate alleles in these four separate genes as major genetic determinants of CD. Little is known about the genetic interactions between these genes or the histologic manifestations of CD in patient's who carry these alleles.

**Design:** 82 cases of ileal CD requiring surgical resection were identified. DNA was retrieved from archival, paraffin-embedded tissue from these cases and was genotyped for the R30Q DLG5, P1371Q DLG5, R908G NOD2, L503F OCTN1 and -G207C OCTN2 polymorphisms in multiplex format using Sequenom technology. Disease-associated alleles were correlated with the histologic features.

**Results:** Disease-associated alleles were present in 67/82 (81.7%) of patients. 100% of patients carrying the G908R NOD2 risk (4/82, 3.8% carrier frequency of G908R NOD2) allele were also carriers of OCTN1 and OCTN2 alleles, compared to only 36/78 (46.1%) of patients without the G908R NOD2 allele (P<0.05). No association was identified between DLG5 and either the G908R NOD2 allele or the OCTN genes in ileal CD. Ulceration was significantly more frequent in homozygous (3/3; 100%) and heterozygous (12/20; 60%) carriers of DLG5 risk alleles compared to non-carriers (8/65; 12.3%; P<0.001). No association was identified between any of the risk alleles and granuloma formation or with any of the other histologic features evaluated.

**Conclusions:** These results suggest that risk alleles may play a role in a substantial proportion of CD patients and that a genetic interaction exists between the OCTN1 and OCTN2 genes and NOD2. Ulceration may be frequent in patients carrying a risk allele for DLG5.

#### 432 Role of Leukocyte $\beta_2$ Integrins in Pathophysiology of Colitis

M Abdelbaqi, J Chidlow, K Mathews, M Fowler, CG Kevil. LSU Health Science Centre, Shreveport, LA.

**Background:** Inflammatory bowel diseases (IBD), are chronic inflammatory disorders whose etiology remains unknown. Several reports have suggested that infiltration of leukocytes into intestinal tissue is a pathognomonic hallmark for this disease. Pathological features of colitis are inflammatory adhesion molecule up-regulation, increased leukocyte recruitment, and increased oxidative stress in the colon. The leukocyte  $\beta_2$  integrins are heterodimeric adhesion molecules that participate in immune cell adhesion that are exclusively expressed on leukocytes. They consist of a common CD18  $\beta$ -chain that is non-covalently linked to one of four  $\alpha$ -chains termed CD11a (LFA-1), CD11b (Mac-1), and CD11c (p150), and CD11d. In this study, we examined the pathophysiological role of the  $\beta_2$  integrins CD18, CD11a, and CD11b in the pathogenesis of experimental colitis.

**Design:** A total of 24 various gene targeted deficient mice 10-12 weeks of age were used for this study. The study groups included CD18 null (n=6), CD11b Null (n=6), CD11a Null (n=6), and wild type (n=6) mice. 3% Dextran Sodium Sulphate (DSS) dissolved in the drinking water was used to induce experimental colitis. Daily assessment of clinical disease activity was measured utilizing the following parameters: stool consistency, weight loss, stool occult blood, and gross rectal bleeding. Three independent histopathological parameters were measured including severity of inflammation, surface epithelial/ crypt damage, and depth of injury of the distal and proximal segments of the colon

**Results:** Our study demonstrates that the leukocyte  $\beta_2$  integrins play an important role in the development of inflammatory colitis. The CD18 null mice and CD11a null mice had statistically significant lower cumulative pathological scores of  $0.333 \pm 0.333$  and  $5.92 \pm 1.03$  respectively versus  $22.8 \pm 4.73$  in wild type mice, which indicates attenuation